
# Anatomy

## Sheet

*Lec No:* 1

*Subject:* Introduction to CNS

*Done By:* Mohammad Da'as

*Corrected By:* Omar Mahafza

*Doctor:* Faraj Al-bustami

00/00/2017

بِسْمِ ٱللَّهِ ٱلرَّحْمَٰنِ ٱلرَّحِيمِ

# Central Nervous System

**Some notes to start with:**

- ✓ CNS = Brain + Spinal cord
- ✓ The brain is found inside the cranial cavity
- ✓ The <u>lowest part</u> of the brain is called "**medulla oblongata**"
- ✓ Medulla oblongata emerged from "foramen magnum" to become → Spinal cord
- ✓ Spinal cord occupies upper 2/3 of the vertebral canal; it ends at the lower border of (L1)
- ✓ The rest of the vertebral canal contains lumbar and sacral nerves.

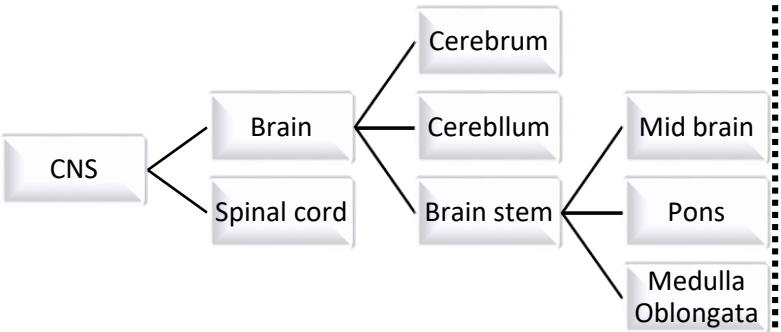


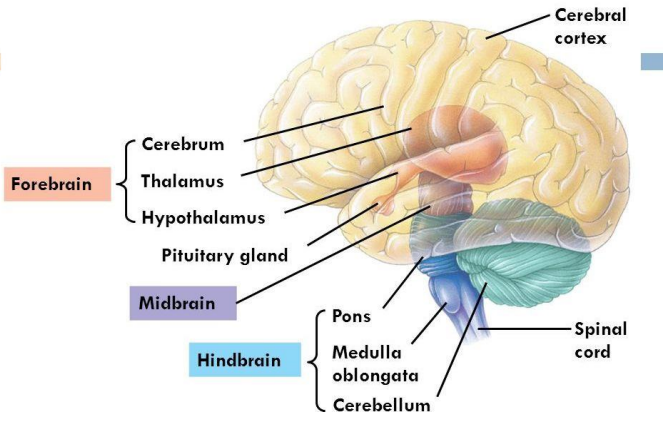


## Cerebrum "المخّ"

There are 2 cerebral hemispheres "right and left" connected to each other by a commissural fiber called → **Corpus callosum.**
Each cerebral hemisphere has a medial surface and superio-lateral surface.

- **Developmentally:** "in the embryo the brain was made of 3 vesicles"

** Medulla + Cerebellum + pons are found in a cavity called → 4th ventricle

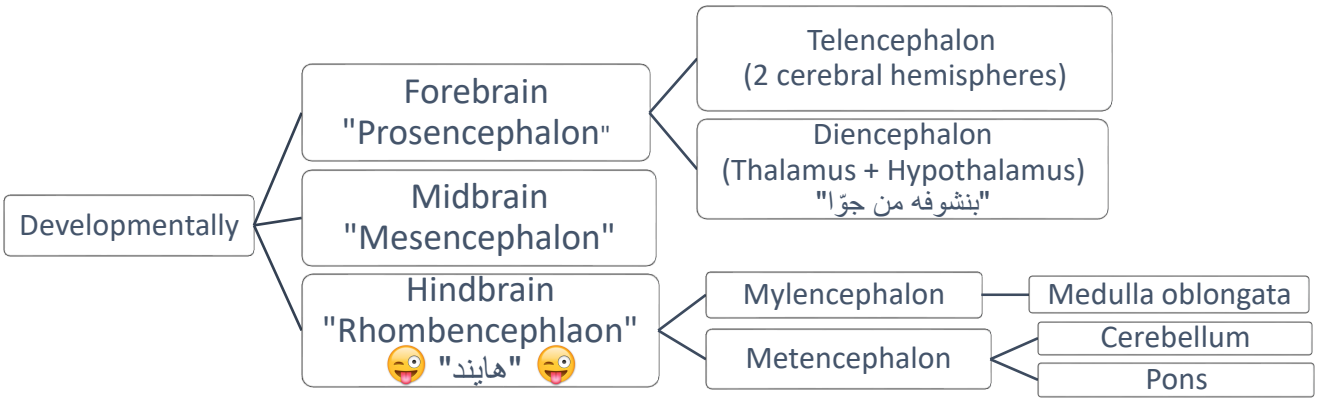

Somehow we should've known these notes from the past two years:-

- ✓ Main cell in the CNS → Neuron, Supporting cells → Neuroglia.
- ✓ Both will form the "**Gray matter** - المادة السّنجابية -"
- ✓ **Gray matter** = Neurons, **White matter** = Axons of Neurons.
- ✓ A Neuron has a cell body (Perikaryon), many dendrites "receives nerve impulse" and an axon (**NERVE FIBER**) "sends the Action Potential".
- ✓ **Tract** or a **pathway** "المسار العصبي" is a Group of axons (bundle of nerve fibers) that have the same origin, same termination and carry out the same function.
  E.g. corticospinal tract; origin → cortex "outer part of cerebral hemisphere", termination → spinal cord.

- ✓ **Ganglion** → a Group of neurons that have the same function "outside the brain and spinal cord"
  **Nucleus** → a Groups of neurons that have the same function "inside the brain…"

- ✓ Each spinal nerve has a dorsal root → sensory, and a ventral root → motor.
- ✓ Dorsal root ganglion or spinal ganglion or sensory ganglion → clusters of the cell bodies of the sensory neurons in the dorsal root that doesn't have synapse.
- ✓ Synapse is only found in autonomic ganglion.
- ✓ Synapse might be between the axon of a neuron and the dendrites of other neuron → Axon-dendritic synapse "sends the nerve impulse between neurons"
  OR between the axon of a neuron and the cell body of other neuron → Axo-somatic, OR between 2 Axons → Axo-Axonic.

## Cerebral Hemisphere :

- ➢ The outer part is a Gray matter neurons → Cerebral Cortex "leader of CNS"
- ➢ Neurons might be **motor** → muscles movement though tracts,
  OR **sensory** → sensation OR **association** neurons "interneurons" → links between motor and sensory.
- ➢ In the Cerebral cortex we have sulcus followed by gyrus, and we have many sulci and gyri → to increase the surface area and the number of neurons "billions of neurons" because after birth there is no way to replace a dead neuron "postmitotic→ unable to divide after birth.

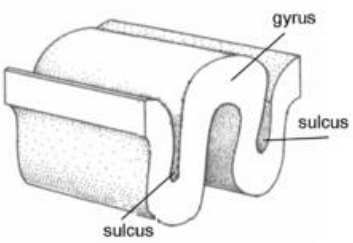

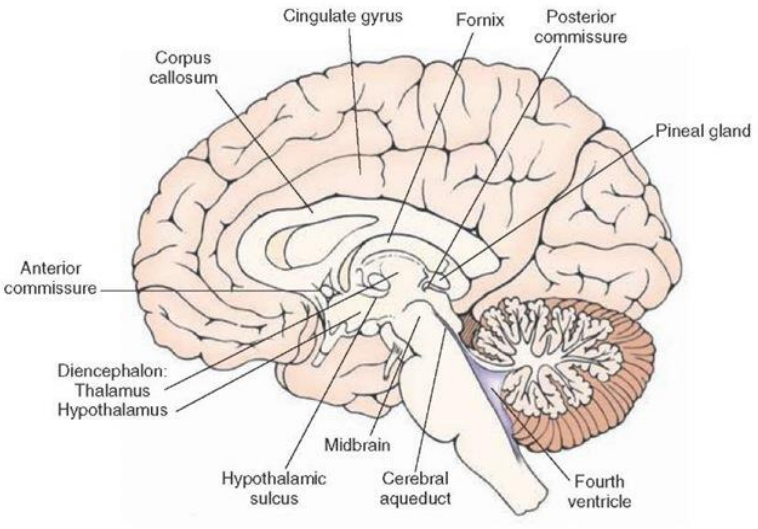


This is the medial surface of midsagittal section of the brain.

- We've cut through the corpus callosum.
- Notice the Diencephalon (thalamus & hypothalamus) "not visible from the outside".
- Below the thalamus we have the brain stem →mid brain, pons & medulla.

- Recall from MSS; There are 3 membranes that covers the brain & spinal cord: 1st one is **Pia matter** then **Arachnoid** then the outermost membrane **Dura matter** "a dense fibrous tissue" part of the dura matter folds and covers the Hindbrain→ post cranial fossa this part is called **Tentorium cerebelli**, and between the right & left hemispheres there is another fold of dura matter to separate them and it's called **Falx cerebri.**

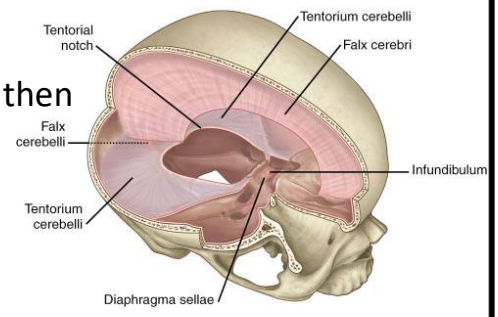


- Medulla oblongata passes through the foramen magnum then it gives spinal cord.

- Clinical correlate: if someone had a trauma in the head that lead to hematoma OR having a tumor that will start on pushing the brain downwards until the medulla oblongata herniates through the foramen magnum, this is very dangerous cause the medulla contains vital centers such as respiratory center, so if it was damaged, the person will die from respiratory failure.

Hematoma→ pushing the brain downwards→ herniation of medulla through foramen magnum → closure of arteries→ ischemia→ death of neurons→ RS failure → death.

Lateral view for a 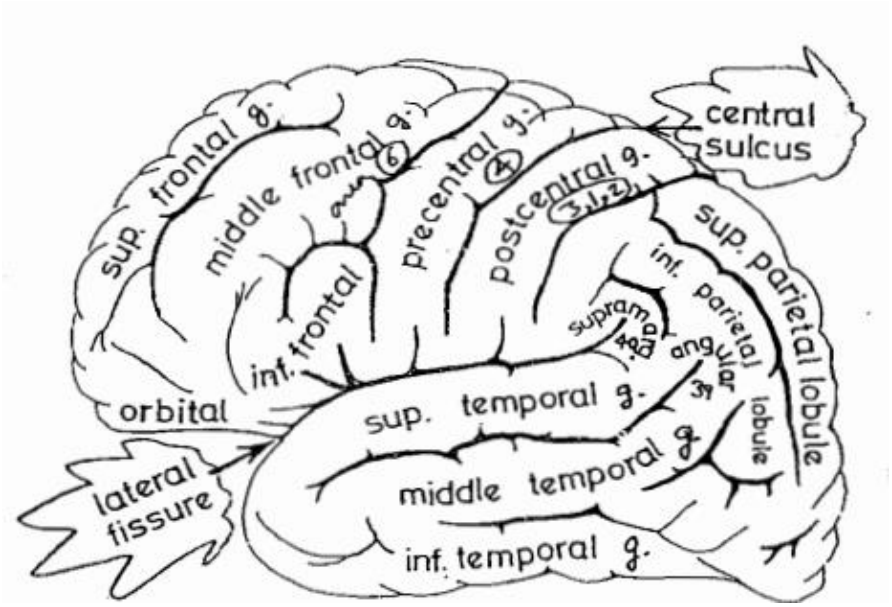

one cerebral hemisphere

- Notice the sulci & gyri, some of the sulci are key factors, for example **Central sulcus**.
- Central sulcus divides the cerebral cortex into frontal lobe & parietal lobe.
- **Lateral fissure** or "sulcus" it separates the temporal lobe from the frontal and parietal downwards.
- From the inside there is a parieto-occepital sulcus, it separates the parietal from the occipital.
- Lobes are named based on the bone above them.
- Each lobe has its own sulci & gyri in addition to other "**functional areas**" a scientist named brodmann gave each area a specific number "**brodmann map".**
- **Frontal lobe** is mainly <u>motor</u> in function → stimulating its neurons will move your <u>upper</u> and <u>lower limbs</u> and <u>face</u> muscles.
  **Parietal lobe** is mainly sensory→<u>sensation</u>, **occipital lobe**→mainly <u>vision</u>**,**
  **temporal lobe**→mainly <u>hearing</u>.
- The 1st gyrus in front of the central sulcus is called anatomically→ **Precentral gyrus** functionally → **Primary motor area.** It was given number **4**, located in frontal lobe. stimulating specific area in area 4 by an electrode while the human is awake will cause movement of his upper limb, if we stimulate a higher area in area 4 it'll cause the movement of his legs و هكذا, so each muscle is occupies a certain area based on the accuracy need for movement not based on the volume of the muscle e.g. hands, tongue occupies a larger area than gluteus Maximus.
- A precentral sulcus is In front of the precentral gyrus, and in front of this sulcus is **area 6**, from the outer surface we'll call area 6 → **premotor cortex** "**area**" from the inside surface → **supplementary motor area**.

- Primary motor area "4" تنفّذ الحركة → simple movement "doesn't need programming"
  area "6" تبرمج الحركة → complex movement especially supplementary motor area.
  E.g. a quick reflex in the hand is simple, but in order to carry something heavy you need an idea where & how to put your hands on the object this is the complex area.
- Within area 6 we have **superior frontal sulcus** & **inferior frontal sulcus** → will give us 3 gyri → superior frontal gyrus, middle and inferior.
- In the back part of the superior frontal gyrus we have **Brodmann area 8,** functionally it's called "**FEF**" **Frontal eye field,** so stimulating FEF in the right hemisphere→ both eyes will move to left, abduction in one eye and adduction in the other, so if area 8 on the left side was damaged, the eyes will move to the **left** "the right side will function"
- In the back of inferior frontal gyrus "is special in the left hemisphere" is the area responsible for the speech "**Broca's area"** Brodmann area **44 & 45.**
- Each hemisphere has some special function that is not found in the other, for example in most people the left hemisphere is responsible for the speech.
- Areas 4, 6, 8, 44, 45 are in frontal lobe.
- The frontal part of the front lobe is called **prefrontal cortex** "**frontal association cortex"** it's responsible of→ social behavior, judgment and thoughts.

- Now let's talk about the parietal lobe, behind the central sulcus there's **Post central gyrus** "**brodmann area <u>3,1, 2</u>"** from the central sulcus toward the apex of the postcentral gyrus (3a, 3b, 1, and 2) respectively. Functionally it's called → **somatosensory cortex**; sensation that comes from the body wall, it might come from the <u>skin</u>, <u>muscles</u> or <u>joints</u>.
  Skin → cutaneous sensation → exteroception such as pain, temperature, simple touch.
  muscles and joints sensation→ proprioception for example while standing you can feel that your knee is flexed without even looking "إحساس داخلي".
- Posteriorly we'll have postcentral sulcus and the rest of parietal lobe (superio & inferio parietal lobule)
- Superio parietal lobule "**brodmann area 5 & 7**" → **Association sensory cortex**
  It is involved in somatosensory <u>processing</u> and association "إدراك طبيعة الإحساس"
  ** if you've been pinched with a pin you'll be able to sense where you're pinched by your somatosensory cortex ,if it was in your index , thumb or the big toe <u>BUT</u> knowing the type of pain if it was from a pin or a cigarette sting "التفاصيل" is the function of the association sensory cortex.
- Note: each sensory area has an association area next to it "to illustrate the sensation"
- Inferio parietal lobule → **angular gyrus** "**39**", **supramarginal** "**40**" both of them are responsible for "**speech mechanism"**.

- Temporal lobe is located inferior to the lateral fissure it has (superior, middle & inferior temporal gyri), (superior & inferior temporal sulci).
- If you put your fingers through the depth of the lateral fissure → hearing area "**auditory area"** will be inferior to your fingers.
  A part of cortex (parietal & temporal) is going through the lateral fissure forming an inner region called **INSULA** "some books consider it the 5th lobe but not dr Faraj cause it doesn't have functional areas".
  https://www.youtube.com/watch?v=BR_b0d6TRcw

**this figure is really really really important; you must memorize "بصماً".
It will be in the exam with a lot of questions.

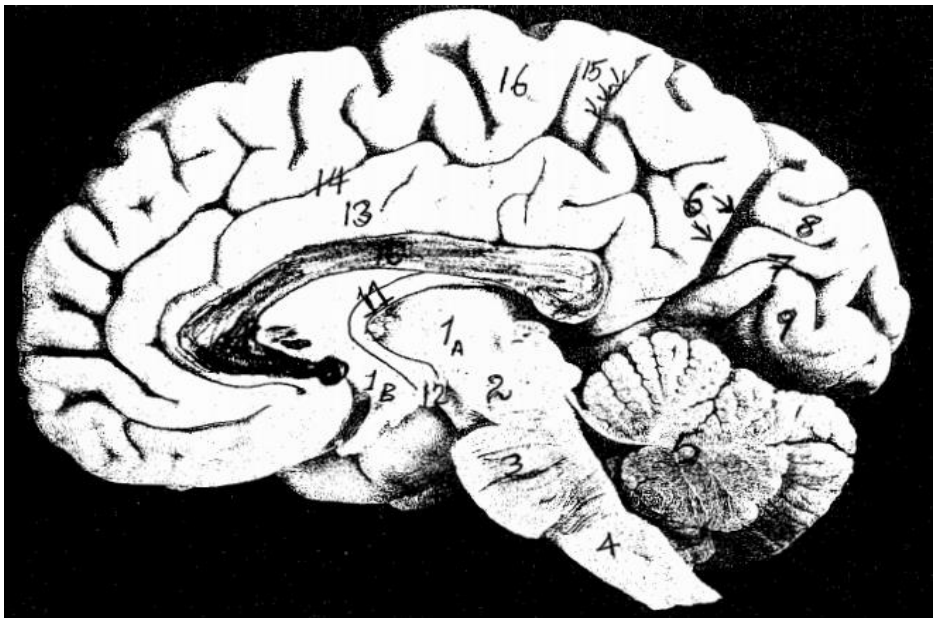


- (1A) Thalamus → all sensation before reaching the somatic sensory cortex "3,1,2" nerve fibers will synapse in the nucleus of thalamus. It's the <u>secretary of sensation</u>.
  It has some <u>motor</u> effects we'll talk about them later.
- (1B) Hypothalamus → <u>homeostasis</u>
  recall from Endocrine system "regulation of PH, HR, BP, temp…"
  it's linked with the pituitary by pituitary stalk that contain vessels and nerves,
  it releases inhibitory factors to inhibit pituitary hormones secretions,
  it has supraoptic & paraventricular nuclei → produce ADH & oxytocin, then store them in the post. Pituitary, so hypothalamus is a link between CNS and Endocrine system.
- 1A & 1B are called **"Diencephalon"** (only seen from the inside).
- (2) Midbrain / (3) pons / (4) medulla
- 2+3+4 → brain stem they have ascending sensory & descending motor pathways.
  in brain stem there are nuclei of cranial nerves "cell body of the cranial nerves which we consider them axons"
- In the midbrain →the nuclei of the 3rd and 4th cranial nerves
- In pons → 5th, 6th, 7th 8th
- In medulla → 9th ,10th ,11th ,12th

Cranial nerves :
Oculomotor (III) Trochlear (IV)

Abducens (VI) Trigeminal (V)
Facial (VII) Vestibulocochlear (VIII)

Glossopharyngeal (IX)
Vagus (X) Accessory (X
Hypoglossal (XII)

In brain stem → there is a network of Neurons & nerve fibers called "**Reticular formation"** it contains vital centers.
In medulla → cardiac center, vasomotor center & respiratory center, there is other centers coughing, vomiting & sneezing centers.
Any damage to medulla → RS failure → death.
Increased intracranial pressure is the main cause of medullary damage.
Surgeons operate fast without the need of sterilization in order to inhibit RS failure.

(5) Vermis "the center of cerebellum" الدّودة.

(6) parieto-occipital sulcus "fissure".

## occipital lobe :-

(7) calcarine fissure → in the center of occipital lobe.

(8) cuneus → superior to (7)

(9) Lingual gyrus.

In 8 & 9 there are the visual areas "**17, 18, 19"**
17 → near the calcarine "**Primary visual area"**, if nerve impulse reached area 17 you'll see without recognizing and knowing what are you seeing **"**أشوف ولا أدرك ما أشوف**"**
18 & 19 are superior to 17 and we have another 18 & 19 inferior to it, they are called "**secondary or association visual area"** to recognize what you see "إدراك".

(10) Corpus callusum → nerve fibers that connects the right & left hemispheres "**commissural fibers".**

(11) Fornix "we'll talk about it later"

(13) **Cingulate gyrus** → part of limbic lobe which is "part of limbic system" limbic systems is responsible for: emotions, motivations & memory.

(14) Cingulate Sulcus → becomes (15) marginal sulcus "posteriorly".

(16) **Paracentral lobule** → controls the motor "area 4" and sensory "area 3,1,2" innervation of lower limbs & sphincters .
Falx cerebri is the fold of the dura matter between the right & left hemispheres so if a tumor there is called "**meningioma**" it'll start pushing and damaging the Paracentral lobule on the left & right side which will lead to paralysis of the lower extremities & the sphincters that are responsible of controlling urination and defecation.

Corpus callusum parts: The posterior (back) portion of the corpus callosum is called the **splenium**; the anterior (front) is called the **genu** (or "knee"); between the two is the **truncus**, or "body".

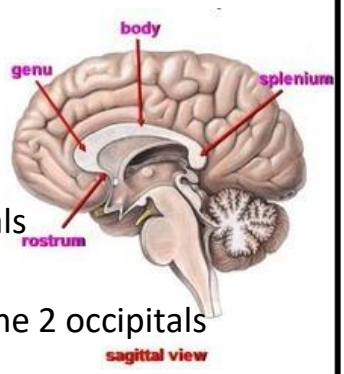


- ✓ The extension of genu in front is called forceps minor → it links the (right & left) frontal lobes with each other.
- ✓ The body has fibers called **Tapetum** → it links the 2 parietals And the 2 Temporals lobes
- ✓ The Splenium extension is called forceps major → it links the 2 occipitals

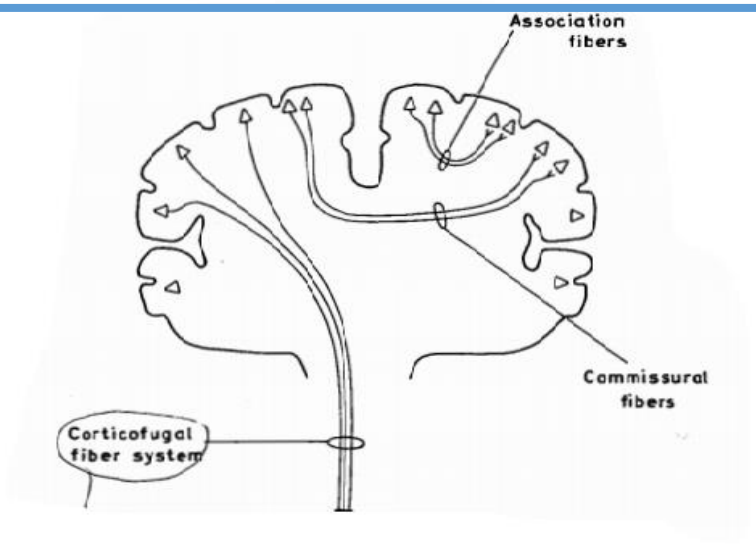


- Cerebral cortex is made of <u>Gray matter</u> that contains neurons:

A. motor B. Sensory C. Association

the axons of neurons may descends forming projecting fibers "**Centrifuged fibers or Corticofugal"** these fibers forms pathways :

1. Corticospinal → to move the extremities,
2. Corticobulbur → movement of face and the pharynx.
3. Corticoreticular → from cortex to reticular formation
4. Corticopontine → from cortex to pons
5. Corticothalamic →from cortex to thalamus

OR the axons may links between 2 gyri on the <u>same</u> hemisphere forming "**Association"** association fibers might be long and links Frontal lobe with occipital lobe.

OR cross from one cerebral hemisphere to the other forming "**commissural fibers"** (pass in the middle e.g. Corpus callusum).

** to sum up: any neuron in the cerebral cortex has fibers that might be (commissural, association or centrifugation Fibers).

# Hindbrain

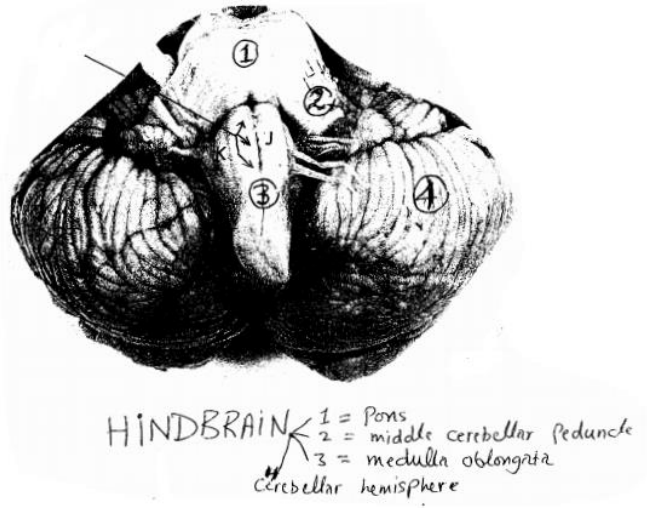


- ✓ Remember pons, medulla & cerebellum = Hindbrain, and it's found in the lowest part of cranium cavity "posterior cranial fossa" OR "infratentorial compartment".
  From now on we'll forget the ~~anterior~~, ~~middle~~ and ~~posterior~~ fossa and we'll use (infratentorial compartment → the space where you locate hindbrain, the rest of the brain is in supratentorial compartment.
- ✓ (1) pons , it has a part embedded in the cerebellum called (2) **middle cerebellar peduncle** "**brachia Pontis**".
- ✓ (3) medulla oblongata: the front part contains **pyramid** lateral to it **inferior olive** posterolateral to inferior olive → inferiorcerebellar peduncle,
  contents of pyramid is the **pyramidal tract** "corticospinal & corticobulbar"
- ✓ (4) cerebellar Hemisphere.

- ✓ Cerebellum is connected to the brainstem by 3 pairs of peduncles:
  Superior cerebellar peduncle →between the cerebellum and the midbrain.
  Middle cerebellar peduncle →between the cerebellum & pons peduncles.
  Inferior cerebellar peduncle → between the cerebellum and medulla.

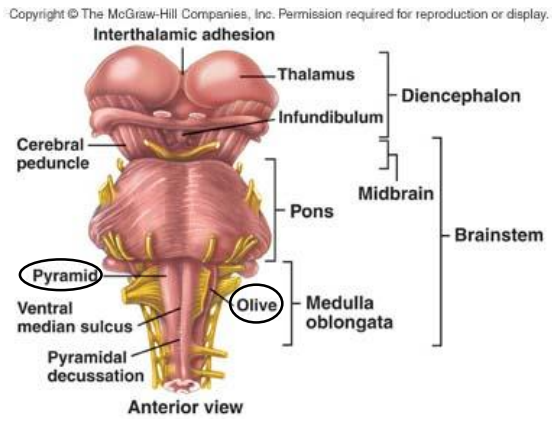


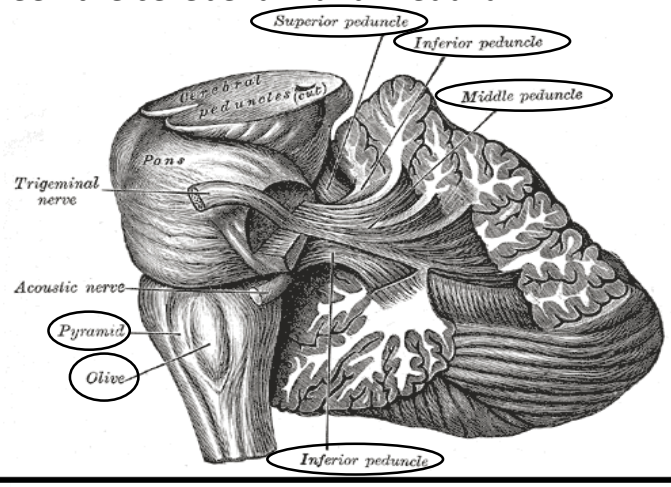

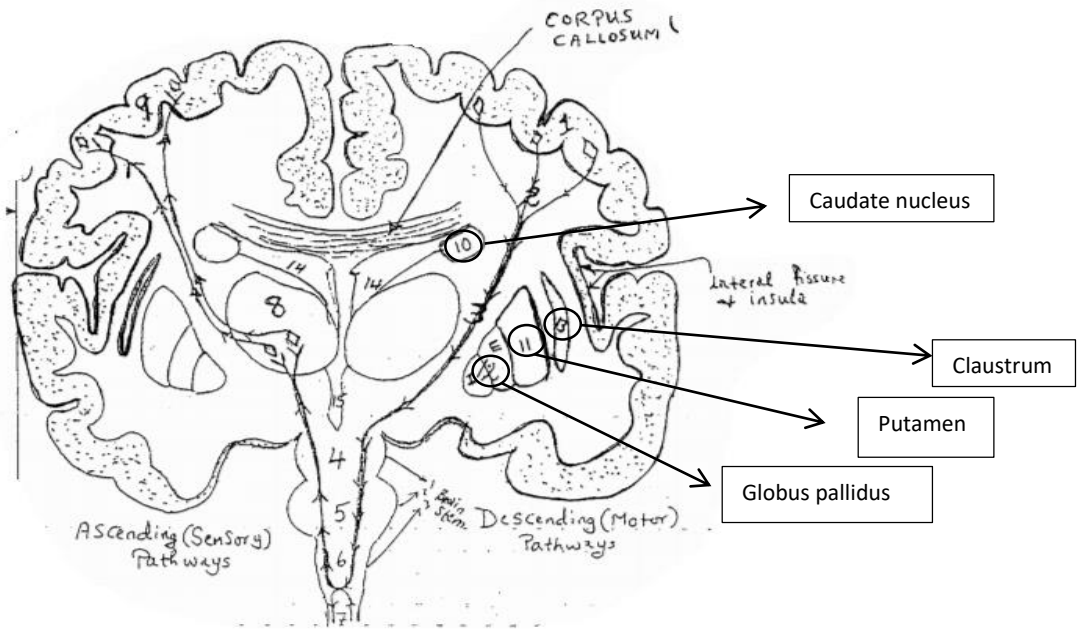


Coronal "frontal" section of cerebrum and brain stem

- (1) Cerebral cortex → is formed of gray matter that contains neurons:
  A. motor B. Sensory C. Association
- Corpus callusum → it links between right & left hemispheres "**commissural fibers"**
- Outside is gray matter
- Inside is white matter "it contains axons" these nerve fibers will produce pathways ascending & descending tracts, these tracts have to synapse in the thalamus.
- We have a lot of grey matter regions such as; (Thalamus & hypothalamus), (**basal nuclei** "**basal ganglia**")
- Basal nuclei parts: (13) claustrum, (11) putamen, (12) Globus pallidus (external & internal segments).
  these three parts are called "**lenticular or lentiform nucleus"**
- (10) Caudate nucleus.

- Notice the insula"الجزيرة" inside the lateral fissure, superiorly → parietal or frontal, inferiorly → temporal**.**