MEDIASTINUM

29

* It is the median space of the chest cavity extending from its inlet to its outlet, and is bounded on each side by pleura and lung.

* For the purpose of description, it is divided into :

1) **Superior mediastinum :**

It is the area above a line extending from the sternal angle to the lower border of 4th thoracic vertebra. It extends from the manubrium sterni (anteriorly) to the vertebral column (posteriorly).

Abusrami

2) The part below the superior mediastinum (inferior mediastinum) is divided into 3 parts :

a — **Anterior mediastinum** : anterior to the heart.

b — **Middle mediastinum** : occupied by the heart and pericardium.

c — **Posterior mediastinum** : posterior to the heart.

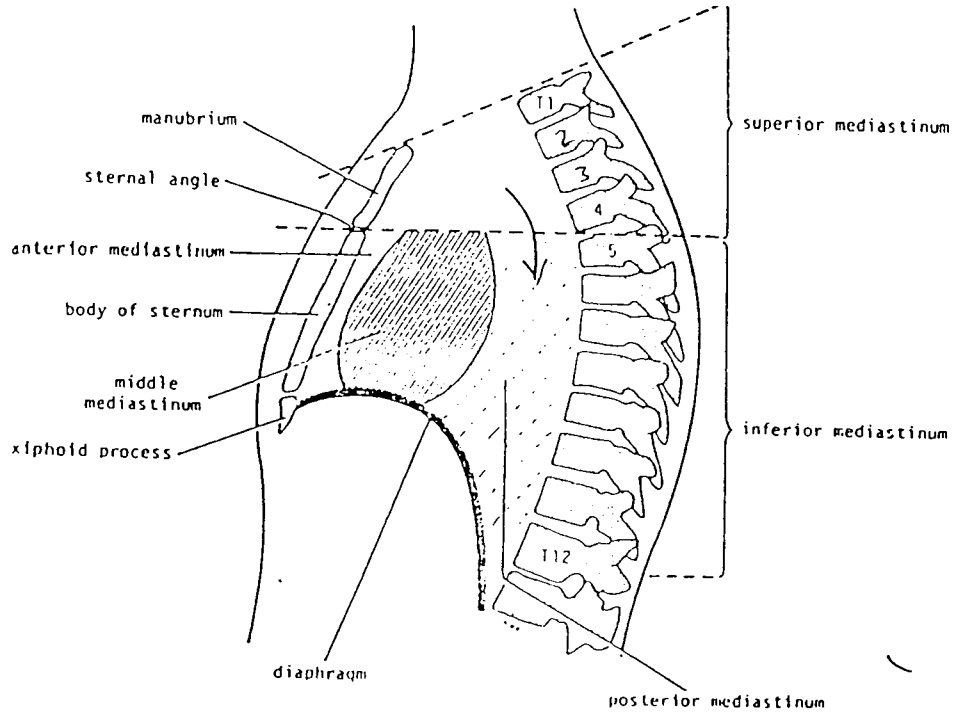

Superior mediastinum

Anterior → Manubrium Sterni

Posterior → $T_1 - T_4$ Vertebrae

Sup. → thoracic inlet
inf. → imaginary plane passing from sternal angle anteriorly to the lower border of the body of 4th thoracic vertebra posteriorly

Contents: Arch of Aorta and related structures

Inferior mediastinum

Anteriorly → Body of Sternum
Posteriorly → lower 8 thoracic vertebrae ($T_5 - T_{12}$)
Superiorly → imaginary plane .....
Inferiorly → thoracic outlet (largely closed by diaphragm)

Divisions → (1) Ant. mediastinum
(2) Middle med.
(3) Post. med.

Contents → Fat ⊕ lymph nodes

a. Pericardium and its contents
b. 2 phrenic nerves

a. oesophagus
b. descending aorta
c. others

PERICARDIUM

Obustami

* A fibroserous sac which encloses the heart and the roots of the great vessels. It is situated in the middle mediastinum.

* 2 Sacs of Pericardium
  - outer single-layered fibrous Pericardium
  - inner double-layered serous Pericardium
    - parietal layer
    - visceral »

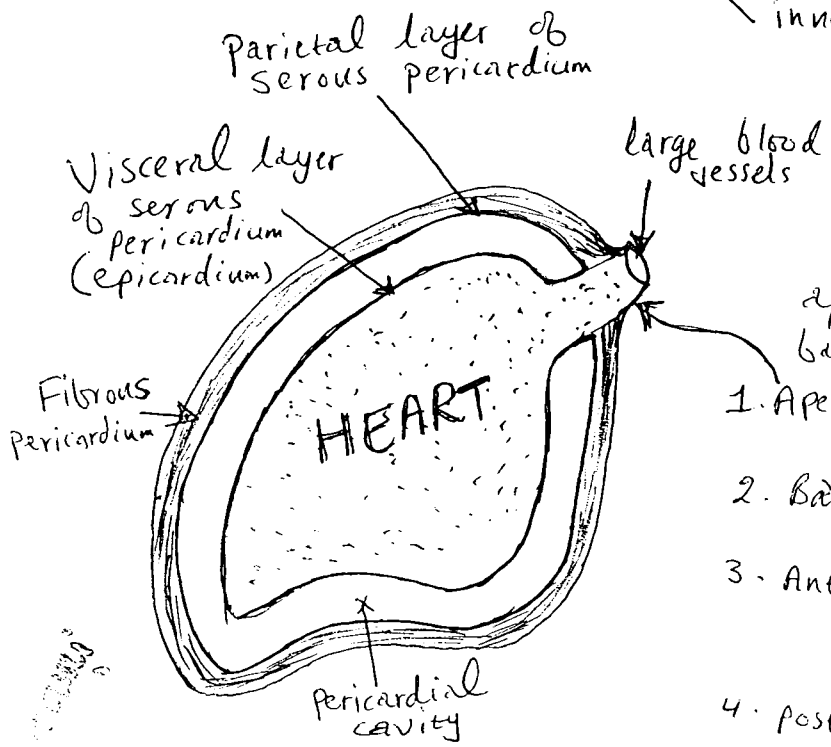

Fibrous pericardium

Conical in shape with its apex directed upwards and its base downwards (reverse of the heart)

1. Apex → fused with the roots of great vessels e.g ascending aorta, Pulmonary trunk...
2. Base → fused with the central tendon of diaphragm
3. Anteriorly → connected to the body of sternum by superior and inferior sternopericardial ligaments
4. Posteriorly → related to
   - Principle bronchi
   - descending aorta
   - oesophagus
5. on each side → related to
   - mediastinal pleura
   - mediastinal surface of lung
   - Phrenic Nerve
   - Pericardio-Phrenic vessels

Serous pericardium ⇒ It is a serous sac that has been invaginated in foetal life by the developing heart, so it becomes formed of 2 layers
- → visceral layer (epicardium) adherent to the wall of the heart Except along the cardiac grooves where it is separated from the heart by the blood vessels (supplied by autonomic nerves)
- → parietal layer lines the fibrous pericardium (supplied by Phrenic nerves)

* The two layers {visceral, parietal} are continuous with each other at the roots of great vessels
* Pericardial cavity ⇒ a potential space between the visceral and parietal layers
  - → contains a thin film of serous fluid which lubricates the apposed surfaces

Contents of the Pericardium
- All chambers of the heart (+) Cardiac vessels & nerves
- ascending aorta (+) Pulmonary trunk
- lower 1/2 of superior vena cava (+) terminal part of inferior vena cava
- terminal parts of the (4) pulmonary veins
- 2 Sinuses

Sinuses of Pericardium → The visceral pericardium (epicardium) at the roots of the great vessels is arranged in the form of two tubes. The ARTERIAL TUBE encloses the ascending aorta and pulmonary trunk i.e arterial end of the heart tube. and the VENOUS TUBE encloses < 2 venae cavae, 4 pulmonary veins i.e venous end of the heart tube ⟹ The passage between the two tubes is known as the transverse sinus of pericardium

The arrangement of the venous tube encloses a recess → the oblique sinus of pericardium which opens downwards into the general pericardial cavity.

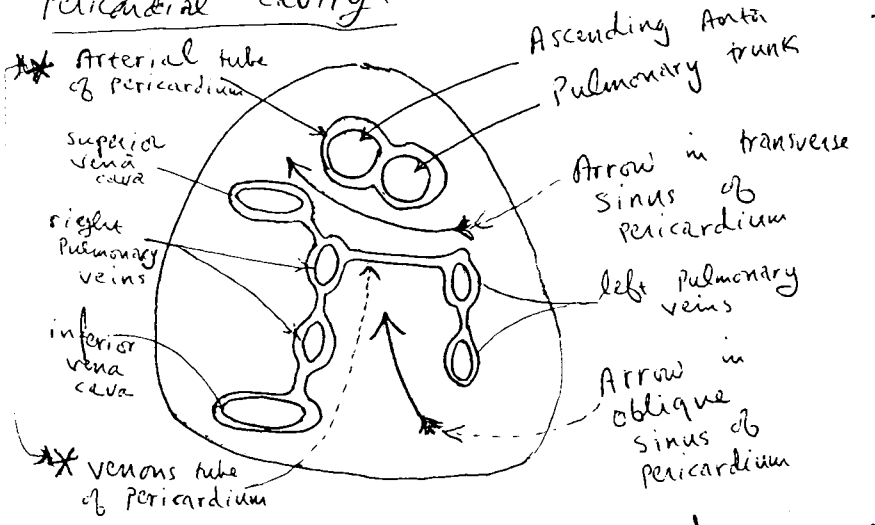

⟹ The Pericardial Cavity seen after removal of the heart → Note the great vessels piercing the pericardium and the reflection of the pericardium forms (2) tubes & (2) sinuses

The transverse Sinus
- → a horizontal gap between the arterial & venous ends of the heart tube
- → bounded anteriorly by < ascending aorta, pulmonary trunk; posteriorly by < sup. vena cava, left atrium
- → develops from → breaking down of dorsal mesocardium
- → through this sinus a temporary ligature is passed to occlude pulmonary trunk & ascending aorta during cardiac operations

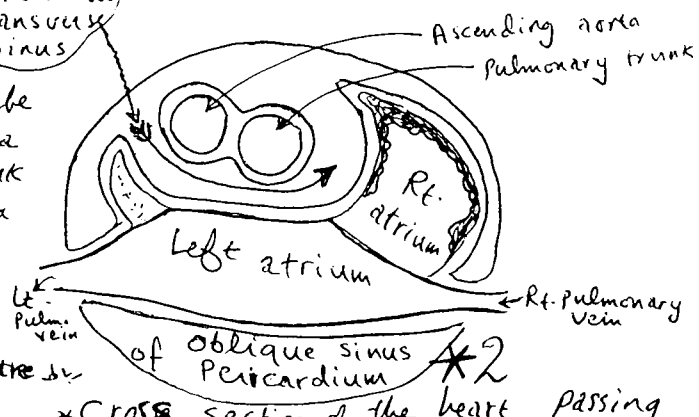

*Cross section of the heart passing through the atria showing reflection of pericardium to form two sinuses.

Obusrami

The oblique sinus of pericardium

- a narrow gap behind the heart (like the lesser sac behind the stomach
- bounded
  - anteriorly by → left atrium
  - posteriorly by → parietal pericardium (outside this the oesophagus and descending aorta).

N.B 1. Stand on the right side of the cadaver → put your left index finger in the transverse sinus of pericardium and the right index finger in the oblique sinus → the (LEFT ATRIUM) lies between the two fingers

2. The sinuses lie INSIDE the pericardium → they DO NOT communicate with the pleural sacs.

Arterial supply

The fibrous and parietal pericardia are supplied by branches from (a) internal thoracic (b) musculophrenic (c) descending thoracic aorta

Nerve supply

The fibrous and parietal pericardia are supplied by the phrenic nerve and are Pain Sensitive. The visceral pericardium (epicardium) is supplied by autonomic nerves of the heart and is insensitive. Cardiac pain (angina) originates in the cardiac muscle or the vessels.

Obusrami

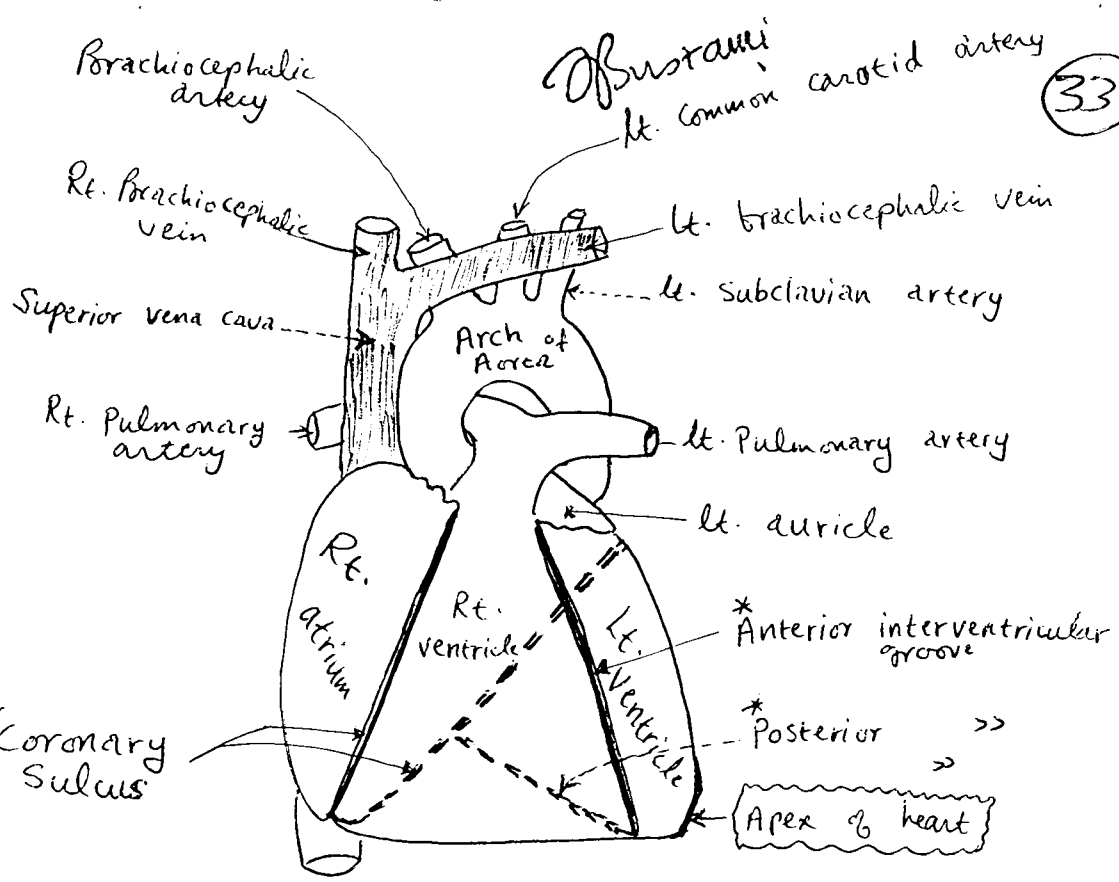

Human heart → 4 chambers < 2 atria, 2 ventricles
→ 3 grooves or sulci < atrioventricular (coronary), interatrial, interventricular
→ An Apex
→ A base (Posterior surface)
→ 4 borders < upper, lower, Rt. & lt.
→ 3 Surfaces < anterior, inferior, left

* On account of Rotation of the heart through 45° during development
- 2/3 of it is shifted towards the left
- 2/3 of Rt. atrium & Rt. ventricle face anteriorly
- 2/3 of lt. ventricle (+) most of lt. atrium face posteriorly

Grooves or Sulci

1. Atrio-ventricular or Coronary groove → Separate atria from ventricles
   - obliterated anteriorly by ascending aorta & pulmonary trunk
   - contains trunks of coronary arteries (+) small cardiac vein (+) Coronary Sinus
2. Interatrial groove — anteriorly → hidden by aorta & pulmonary trunk; faintly visible posteriorly
3. Anterior interventricular groove — nearer to lt. margin of heart; contains — anterior interventricular branch of lt. coronary a., great cardiac vein

Dr Bustami

34

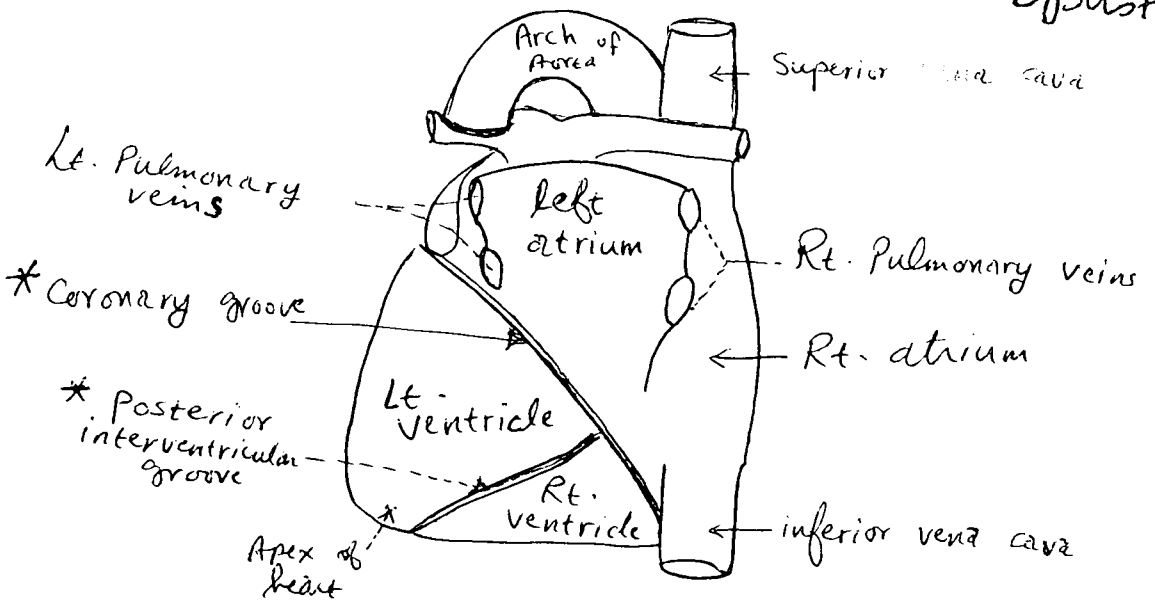

Posterior view of heart (base & diaphragmatic surface)

4. The posterior interventricular groove → Situated on diaphragmatic (inferior) surface of heart
→ nearer to the Rt. margin
→ contains posterior interventricular branch of Rt. coronary artery ⊕ middle cardiac vein

Apex of heart →
- formed by the left ventricle
- directed downward forwards & to the left
- overlapped by the anterior border of the left lung
- Situated in the left 5th intercostal space 3.5 inches lateral to the midsternal line → JUST inner to the midclavicular line.
- In the living subject it is seen & palpated as apex beat

Base →
- forms the posterior surface of the heart
- formed mainly by the left atrium ⊕ a small part of Rt. atrium
- It is related to middle 4 thoracic vertebrae (T5-8) in the lying posture and descends by one vertebra (T6-9) in the standing posture.
- It is separated from vertebral column by pericardium, oesophagus, descending aorta

Borders →
- upper → Slightly oblique and formed by the two atria, chiefly the left atrium
- right → formed by Rt. atrium
- Inferior → formed by Rt. ventricle
- left → oblique, formed mainly by left ventricle & partly by Lt. auricle

Surfaces of the heart

① Anterior (Sternocostal) surface → formed
- mainly by Rt. { atrium, ventricle
- partly by lt. { ventricle, auricle

* the left atrium is hidden from the front by the ascending aorta and pulmonary trunk
* A part of this surface is uncovered by the left lung (within the cardiac notch) is known as the area of superficial cardiac dullness.

② Inferior (diaphragmatic) surface → Rests on central tendon of diaphragm
- formed → in the left 2/3 → by left ventricle
  → in the right 1/3 → " right "
- traversed by posterior interventricular groove

(35)

③ left surface – formed by { left ventricle, left auricle
- crossed in its upper part by the coronary groove containing the left coronary artery ⊕ great cardiac vein

---

Chambers of the heart

Rt. atrium → receives venous blood from the whole body (except lungs) and pumps it to the right ventricle through the right atrioventricular (tricuspid) opening

→ forms → **Rt. border**

→ parts of { upper border, Sternocostal surface, base

External features

1- receives Superior vena cava at the upper end and inferior vena cava at the lower end

2- Sulcus terminalis → a shallow groove along the right border between the superior and inferior vena cavae
- not always obvious
- Produced by an internal muscular ridge called Crista terminalis
- Its upper part contains (SA) node which acts as the pace maker of heart

Internal features of Rt. atrium

Bustami

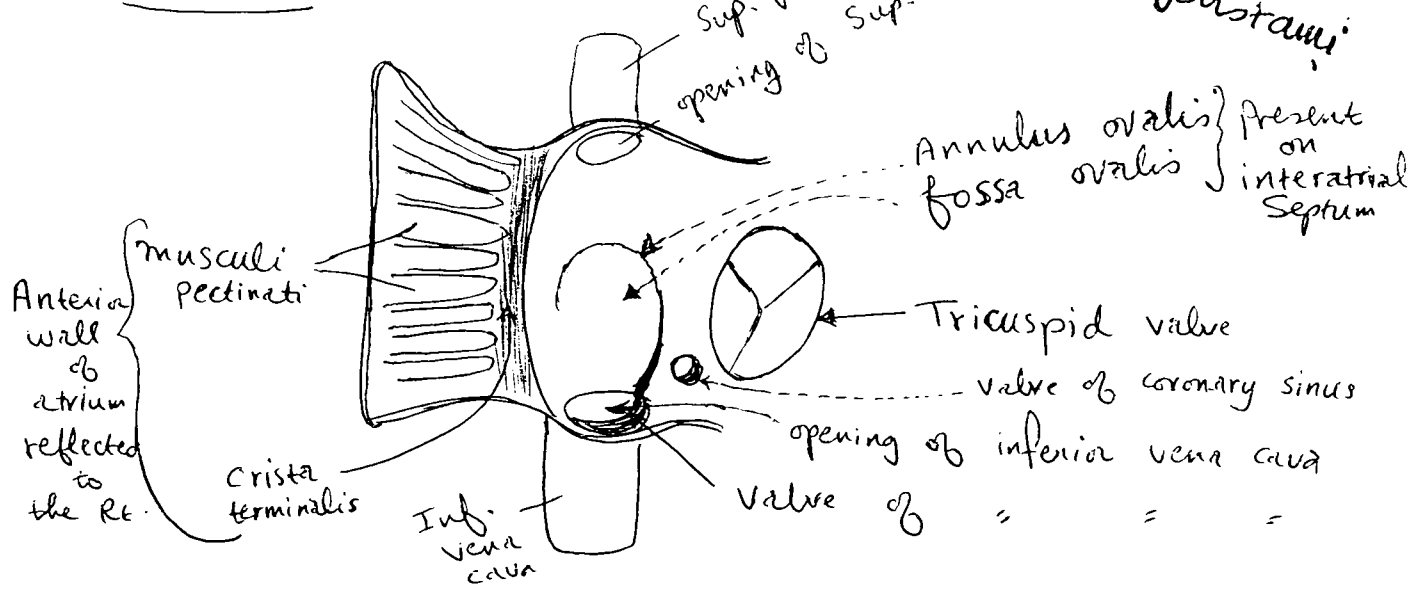

The interior of the right atrium can be divided into the following parts
- The Smooth Posterior part OR Sinus Venarum
- The rough anterior part OR Pectinate part including the auricle
- The posterior wall formed largely by the interatrial septum

1 The smooth posterior part

a. developmentally it is derived from the right horn of the sinus venosus

b. It receives
- the superior vena cava at its upper end
- the inferior vena cava at its lower end
  The opening is gaurded by a rudimentary valve of the inferior vena cava (during embryonic life it directs i.v.c blood to the left atrium through the foramen ovale)
- Rt. atrio-ventricular opening → guarded by the tricuspid valve
- Coronary sinus: opens between the inferior vena cava and the right atrioventricular opening (the opening is guarded by a valve)
- Venae cordis minimae: small pits which brings blood from the myocardium

2 The rough anterior part

a. developmentally it is derived from the primitive atrial chamber

b. It presents a series of transverse muscular ridges called musculi pectinati. They arise from the crista terminalis and run towards the A-V opening giving the appearance of the teeth of a comb.

[3] The posterior septal wall of right atrium: Offsustami

a. developmentally it is derived from the septum primum and septum secondum (37)

b. It presents FOSSA OVALIS → a shallow saucer-shaped depression, in the lower part formed by the septum primum

c. the ANNULUS OVALIS OR limbus fossae ovalis is the prominent margin of the fossa ovalis and represents the free edge of septum secundum. It is distinct above and at the sides, but deficient inferiorly. Its anterior edge is continuous with the left end of the valve of inferior vena cava.

Remember that the left atrium lies posterior to the Right atrium

Right ventricle

a triangular chamber of the heart which receives blood from the right atrium and pumps it to the lungs through the pulmonary trunk and pulmonary arteries.

It forms → the inferior border
→ a large part of sternocostal surface
→ a small part of the diaphragmatic surface

Cavity of Rt. ventricle → separated in 2 parts

① Inflowing part → rough due to muscular ridges called trabeculae carnae
→ it develops from [redacted] of heart tube??

② Outflowing part of Infundibulum → Smooth & forms the upper 1 inch conical part of right ventricle which gives rise to the pulmonary trunk
It develops from the bulbus cordis

* The two parts are separated by a muscular ridge called Supraventricular Crest situated between the tricuspid & pulmonary orifices

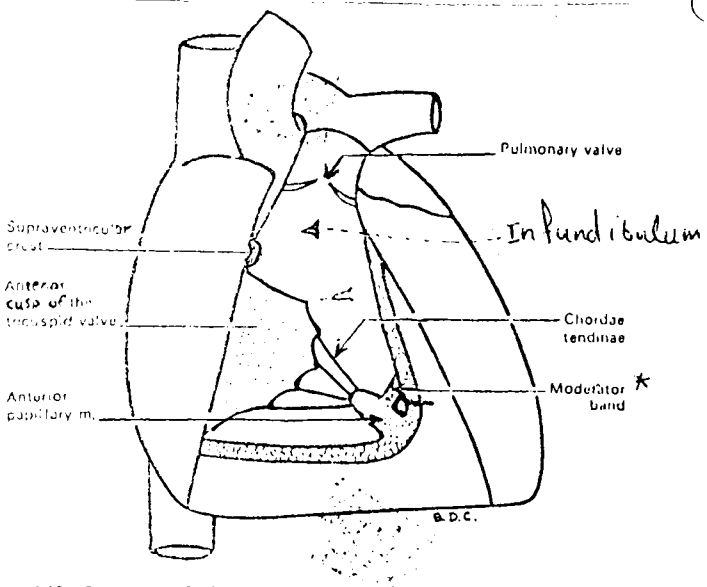

g. 169 Interior of the right ventricle of the heart, showing the moderator band and the supraventricular crest.

The cavity of the Rt. ventricle shows two openings (orifices):

1. the right atrio-ventricular or tricuspid orifice guarded by the tricuspid valve
2. Pulmonary orifice guarded by the Pulmonary valve

Bustrami

* The trabeculae carnae (muscular ridges) present in the inflowing part are of 3 types → Ridges (fixed elevations)
→ Bridges (with two ends fixed but with a free centre)
→ Pillars (papillary muscles)



with one end attached to the ventricular wall and the other end connected to the cusps of the tricuspid valve by chordae tendinae

* There are 3 papillary muscles in the Rt. ventricle
  - The anterior is the largest
  - The posterior or inferior → small and irregular
  - The septal → divided into a number of little nipples

EACH PAPILLARY MUSCLE IS ATTACHED BY THE CHORDAE TENDINAE TO THE CONTIGUOUS SIDES OF TWO CUSPS ?
→ To ensure competency of the valve ←

* The SEPTOMARGINAL TRABECULA (moderator band) is a muscular ridge extending from the ventricular septum to the base of the anterior papillary muscle (1) It contains Rt. branch of A-V bundle (2) It prevents overdistension of the right ventricle
* The cavity of the right ventricle ⟹ CRESENTIC, by the forward bulge of interventricular septum
* The wall of the Rt. ventricle is thinner than that of the left ventricle, in a ratio of 1 : 3

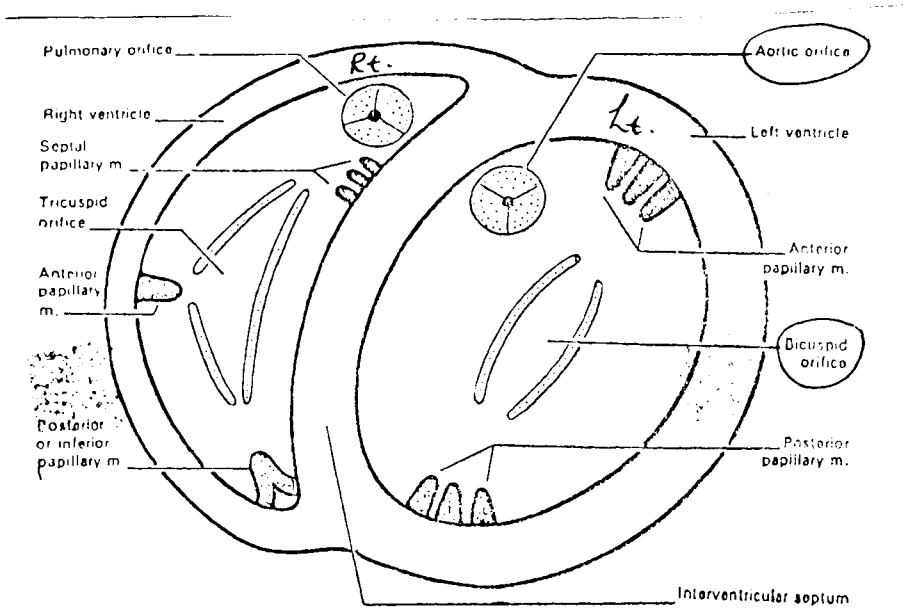

Fig. 168 Schematic transverse section passing through the ventricles of the heart, showing the atrioventricular orifices, papillary muscles and the pulmonary and aortic orifices.

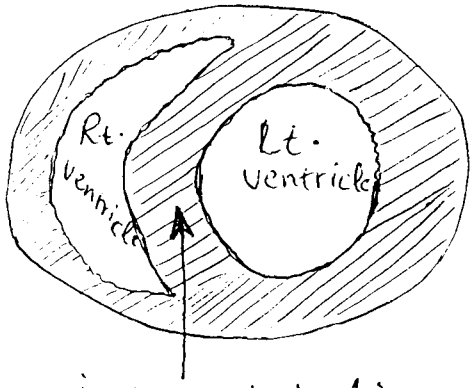

interventricular Septum (bulges forward towards the Rt. ventricle)

The left ventricle: receives oxygenated blood from the left atrium and pumps it to the aorta.

It forms
- the apex
- a part of the sternocostal surface (1/3)
- left (2/3) of the diaphragmatic surface
- most of the left border & left surface

Cavity of Lt. ventricle
- lower rough part with trabeculae carnae (It develops from the primitive ventricle)
- upper smooth part → aortic vestibule → which gives origin to the ascending aorta (It develops from the bulbus cordis)

* The {vestibule} lies between
  - the membranous part of the interventricular septum
  - the anterior (aortic) cusp of mitral valve

* The cavity of the left ventricle shows two orifices
  1. The left atrioventricular (bicuspid or mitral) orifice guarded by the bicuspid or mitral valve
  2. The aortic orifice guarded by the aortic valve

* There are [two papillary muscles] < anterior, posterior } both are attached to both cusps of mitral valve by chordae tendinae

* The walls of the left ventricle are (3) times thicker than those of the right ventricle

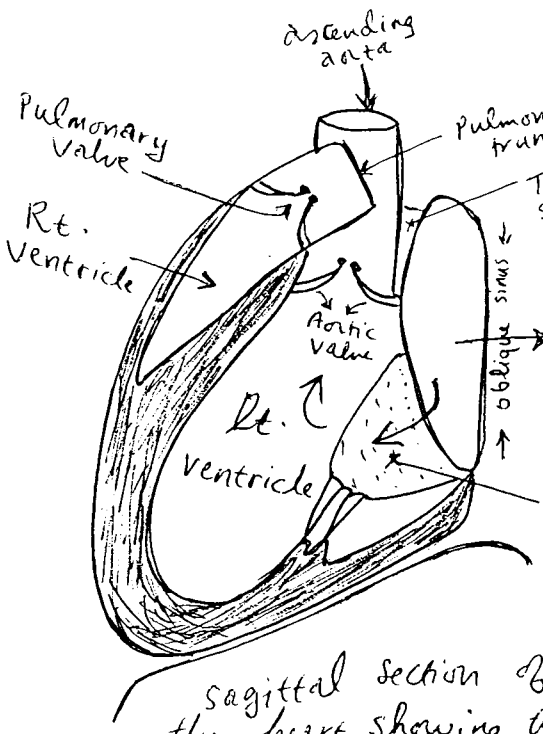

sagittal section of the heart showing the posterior position of the left atrium

Lt. atrium → forms

- major part of the base (left 2/3)
- its auricle projects anteriorly and forms part of the left border
- forms part of sternocostal surface and (upper border) (greater part)
- Receives oxygenated blood from the lungs through the (4) pulmonary veins and pumps it to the left ventricle through the left A-V (mitral) orifice

features

1. Its posterior surface forms the anterior wall of the oblique sinus of pericardium
2. It intervenes between the transverse sinus of pericardium (infront) and the oblique sinus behind
3. Its anterior wall forms the interatrial septum
4. Two pulmonary veins open on each side of the posterior wall
5. Greater part of its wall is smooth (derived from absorption of the pulmonary veins which open into it)
6. Musculi pectinati → present only in the auricle where they form a reticulum (this portion is derived from the primitive atrial chamber of the heart)

→ Valves of the heart ← Obsurtaine

* The valves MAINTAIN UNIDIRECTIONAL FLOW OF THE BLOOD and PREVENT ITS REGURGITATION in the opposite direction.

* There are two pairs of valves in the heart
  - a pair of atrio ventricular (A-V) valves
  - a pair of Semilunar valves

1. The Right atrioventricular valve is known as the tricuspid valve because it has 3 cusps
2. The left atrioventricular valve is known as the bicuspid or mitral valve because it has two cusps
3. The semilunar valves include
   - aortic
   - pulmonary

   } each one has 3 semilunar cusps.
4. The cusps are folds of endocardium, strengthened by the intervening layer of fibrous tissue

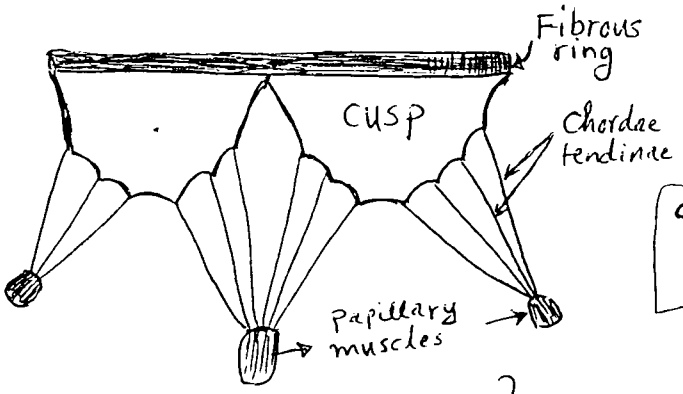

{Basic structure of an atrioventricular AV valve (unfolded)}

Components of A-V valve
- A fibrous ring to which the cusps are attached
- Cusps flat and project into the ventricular cavity
- Each cusp has
  - attached & free margins
  - atrial & ventricular surfaces
- atrial surfaces of cusps → Smooth
- the free margins & ventricular surfaces → rough (due to the attachment of chordae tendinae

* The chordae tendinae → Connect the free margins and ventricular surfaces of the cusps to the apices of papillary muscles → They prevent Eversion of the free margins and limit the amount of ballooning of the cusps towards the cavity of the atrium

* The atrioventricular valves (A-V valves) are kept competent by ACTIVE contraction of the papillary muscles which pull on the chordae tendinae during ventricular systole

Remember → Each papillary muscle is connected to the adjacent halves of two cusps

Bustami

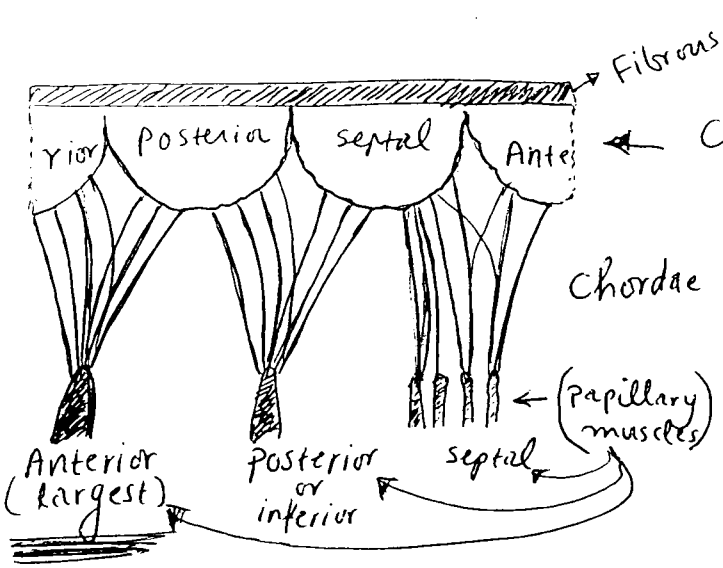

Tricuspid valve (Unfolded)

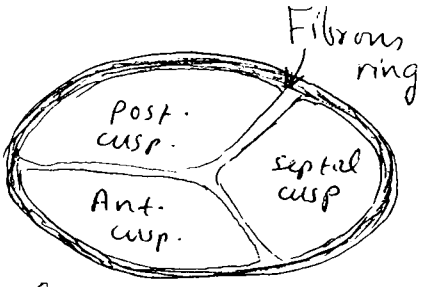

Tricuspid valve as seen from the Rt. atrial cavity

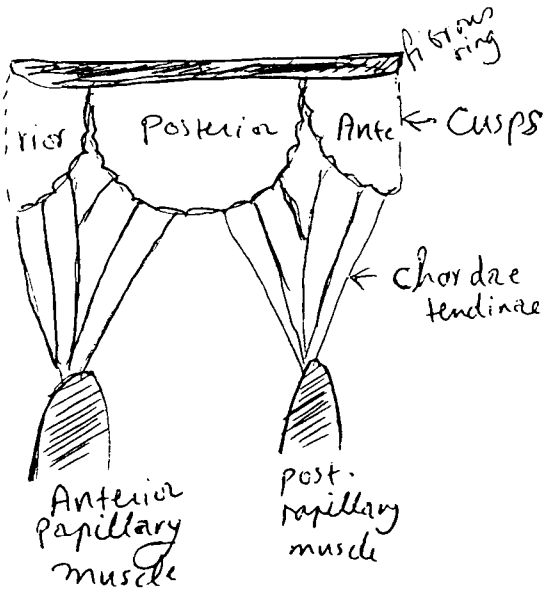

Mitral valve (Unfolded)

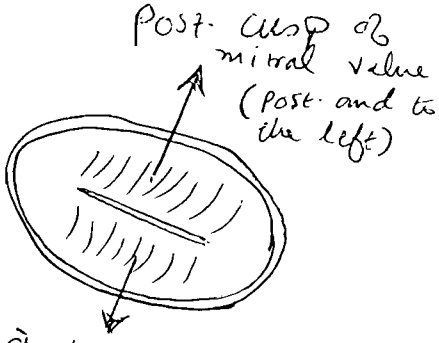

The tricuspid valve → has 3 cusps and admits the tips of 3 fingers
→ The 3 cusps < ant. / post. / septal } lie against the three walls of the ventricle

The mitral (bicuspid) valve → has two cusps < a large anterior or aortic cusp / a small post. cusp.
→ admits the tips of 2 fingers

The anterior cusp → lies between the mitral and aortic orifices (accordingly called aortic cusp of mitral)
→ Both atrial & ventricular surfaces are smooth
→ Subjected to 2 streams of blood
1st stream → from Lt. atrium → Lt. ventricle
2nd " → from Lt. ventricle → ascending aorta

Semilunar valves < Aortic, Pulmonary } → Their cusps are Semilunar

Obusrami (43)



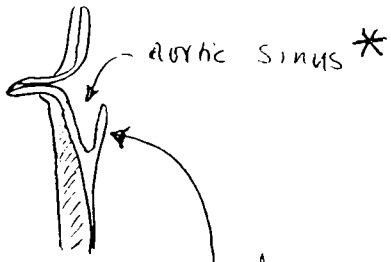

The cusps form small pockets with their mouths directed away from ventricular wall

* Each valve (A, P) has 3 cusps which are attached directly to the vessel wall (fibrous ring is absent) ? one view ?
* The free margin of each cusp contains a central fibrous nodule from each side of which a thin margin (lunule) extends up to the base

* Semilunar valves → are closed during Ventricular diastole

Each cusp - filled with blood - bulges down into a globular convexity towards the ventricular cavity

* (opposite to the cusps) the vessel walls < of ascending aorta, " pulmonary trunk are slightly dilated to form the aortic & pulmonary Sinuses.

* CORONARY ARTERIES: arise from the aortic sinuses < Anterior, left Posterior

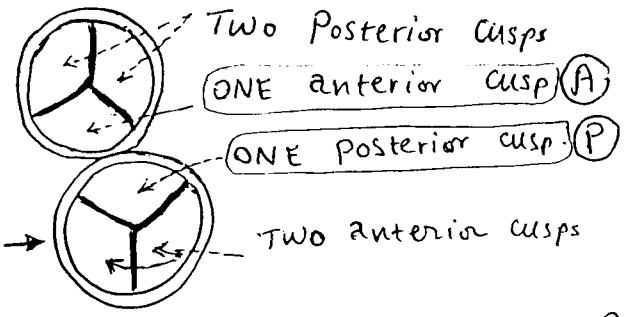

→ Receive blood during diastole ??? ? ? ? ?

Dr Bustami

Skeleton of the heart → The fibrous rings

Surrounding the atrioventricular and arterial orifices constitutes the fibrous skeleton of the heart.

Function → it provides attachment to the cardiac muscle & keeps the cardiac valves competent.

Notice → There is NO muscular continuity between the atria and ventricles across the atrioventricular fibrous ring EXCEPT for the atrioventricular (A-V) bundle (bundle of His) of the conducting tissue

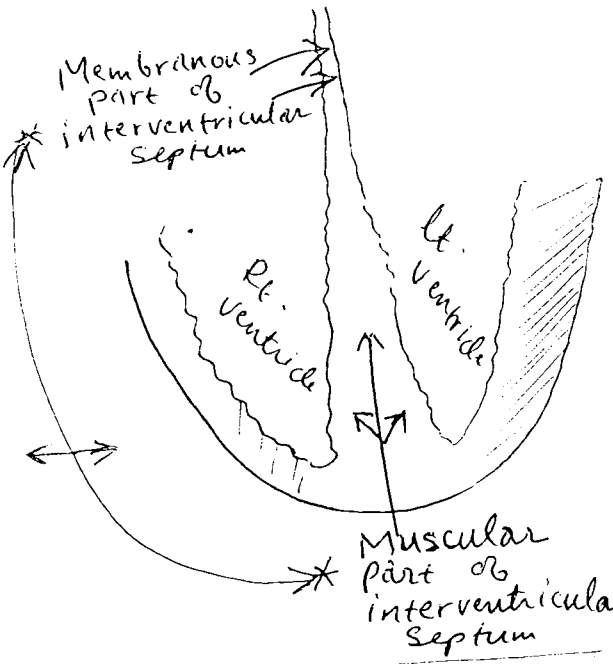

The membranous part of interventricular septum

- Formed of fibrous tissue (+ endocardium)
- Its anterior part intervenes between the 2 ventricles
- Its posterior part intervenes between the aortic vestibule of left ventricle + right atrium i.e it is Atrio-ventricular septum

1. Sinuatrial (SA) node
   - * is the pacemaker where the contraction of the heart is initiated
   - * situated in the upper part of sulcus terminalis just to the right of the opening of sup. vena cava into the right atrium
2. atrioventricular (AV) node
   situated in the lower part of atrial septum just above the opening of coronary sinus

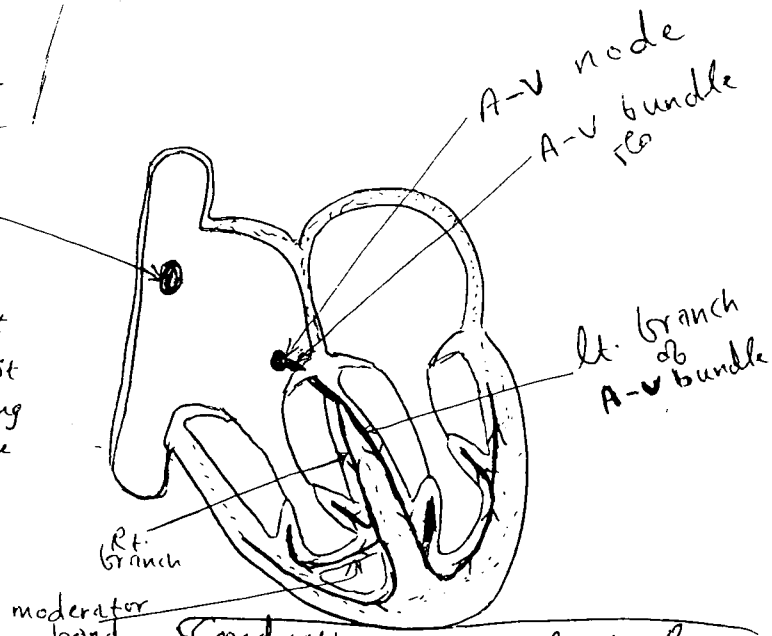

Conducting system of the heart

* made up of specialized cardiac muscle fibres called Purkinje fibres

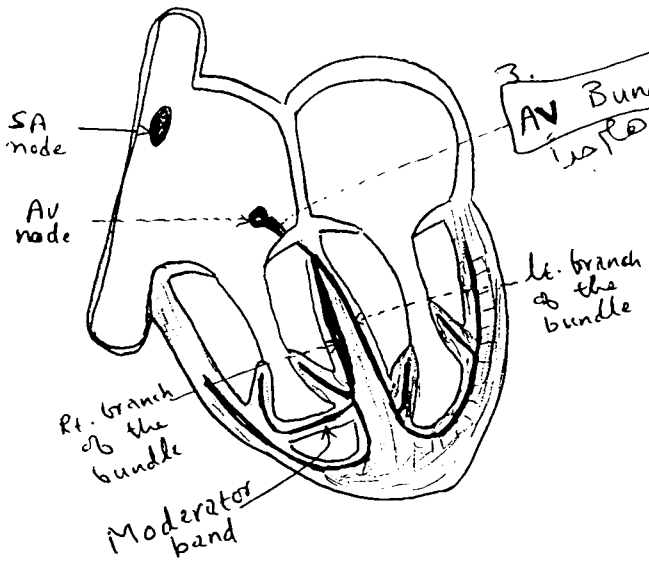

It is the ONLY muscular connection between the atrial and ventricular musculature

begins at the A-V node → Crosses the A-V ring → Descends along the postero-inferior border of the membranous part of the ventricular septum.

↓

At the upper border of the muscular part of the septum it divides into Rt. & Lt. branches.

4. The right branch of the A-V bundle → passes down the right side of the interventricular septum ⇒ A large part enters the moderator band to reach the anterior wall of the right ventricle where it divides into Purkinje fibres

5. The left branch of the A-V bundle → descends on the left side of the interventricular septum and is distributed to the left ventricle

N.B The Purkinje fibres ⇒ form a Subendocardial plexus
- large pale fibres striated only at their margins
- usually possess double nuclei

* Defects or damage (interference with blood supply) to the conducting system of the heart ⇒ CARDIAC ARRHYTHMIAS

Blood supply

The sinu-atrial (SA) node → in 60% of cases → supplied by a branch of right coronary artery
→ in 40% → from left coronary artery

A-V node ⊕ A-V bundle → supplied by the inferior interventricular artery
- in 90% of cases arises from Rt. coronary a.
- in 10% " " " " Lt. " "

In general ⇒ Except for a part of the left branch of A-V bundle (supplied by the left coronary artery) → the whole of the conducting system is usually supplied by the right coronary artery.

Blood supply of the heart

Dbustami

Dbustami

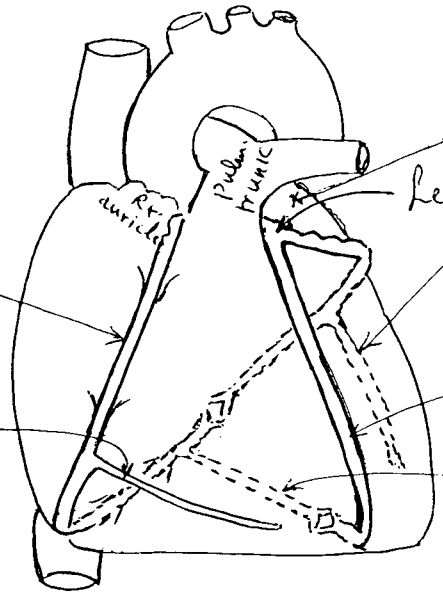

Right coronary artery → smaller than the left
→ origin → from the anterior aortic sinus

Course: emerges between root of pulmonary trunk and Rt. auricle
→ runs downward in the coronary groove till the inferior border
→ winds round and continues in the posterior coronary groove where it anastomose with the left coronary artery

branches — Marginal
Posterior interventricular "
Nodal in 60% of cases "
Rt. atrial
terminal

Areas of distribution ① Rt. atrium ② ventricles as in the diagram
③ whole of conducting system ----- (see before)

Left coronary artery → larger than the right
→ origin → from the left posterior aortic sinus

Course: emerges between the pulmonary trunk and left auricle
it gives the anterior interventricular branch ← Here
runs to the left in the left posterior coronary groove where it terminates by anastomosing with the Rt. coronary a.

branches — Anterior interventricular
a branch to diaphragmatic surface of Lt. ventricle
left atrial + pulmonary + terminal

Areas of distribution ① left atrium ② ventricles as in diagram ----
③ a part of the left branch of the AV bundle

Obustami

47

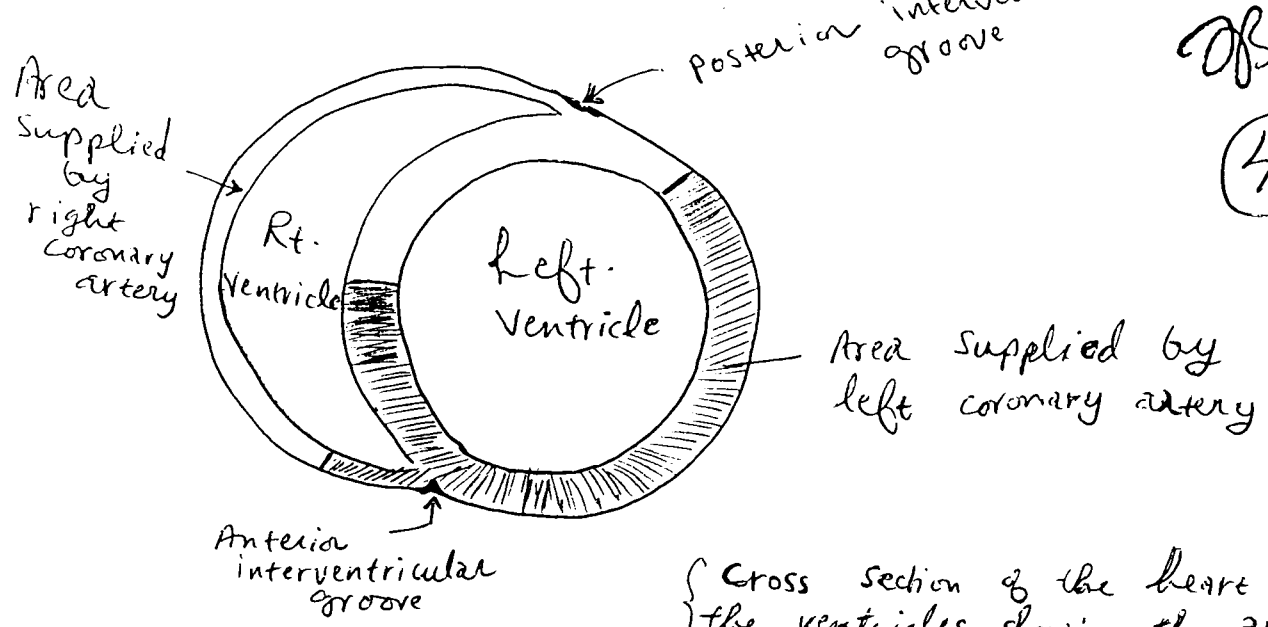

Cross section of the heart through the ventricles, showing the areas supplied by the two coronary arteries

Obustami

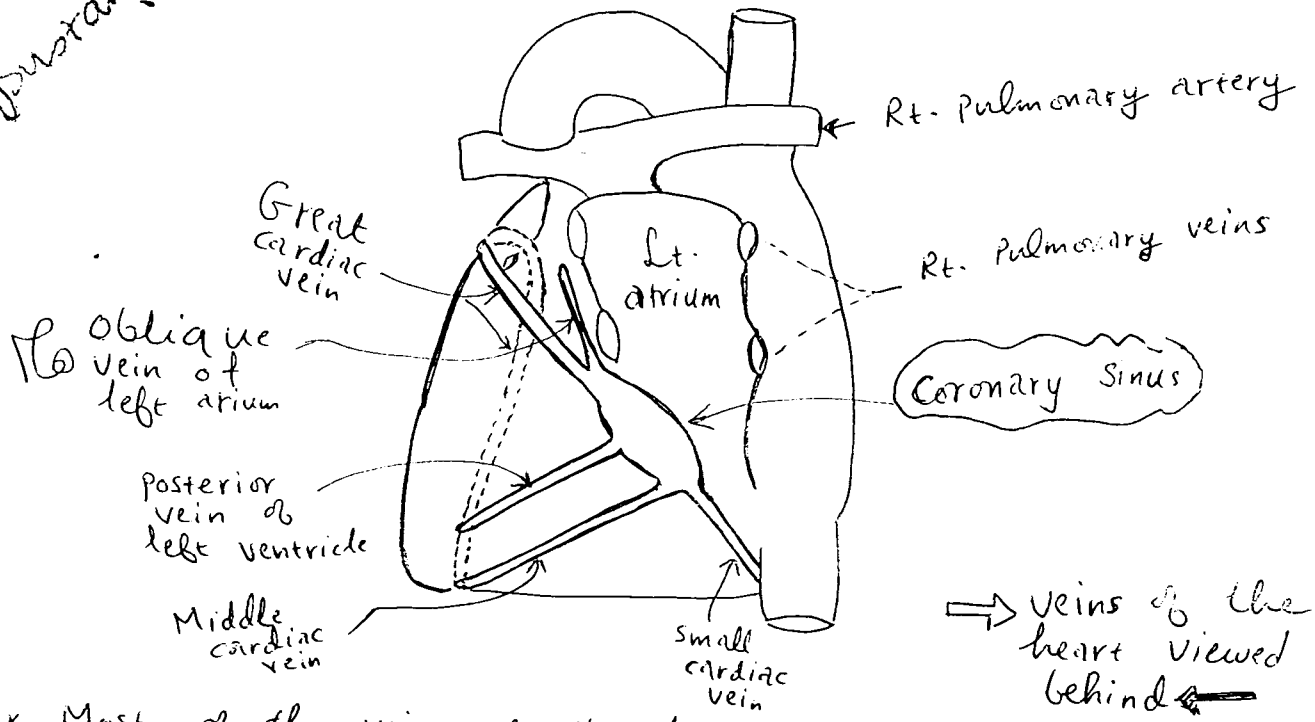

⇒ Veins of the heart viewed from behind ⇐

* Most of the veins of the heart drain into the coronary sinus which opens into the right atrium
* Coronary sinus: the largest vein of the heart situated in the left posterior part of coronary groove
  - It is 3cm long, begins at the termination of the oblique vein of Marshall and ends by opening into the posterior wall of the right atrium.
  - develops from left horn of sinus venosus (+) part of lt. common cardinal vein.
  - It receives the following tributaries:-
    1. great cardiac vein accompanies first the anterior interventricular artery and then the left coronary artery to enter the left end of the coronary sinus
    2. middle cardiac vein accompanies the posterior interventricular artery and joins the right end of coronary sinus

Dr Bustami

3. Small cardiac vein: accompanies the right coronary artery in the Rt. posterior coronary groove and joins the right end of the coronary sinus (48) A

4. Posterior vein of the left ventricle: runs on the diaphragmatic surface of the left ventricle and ends in the middle of the coronary sinus

(*) 5. oblique vein of the left atrium (of Marshall) it is a small vein running on the posterior surface of the left atrium to terminate in the left end of the coronary sinus. It develops from the left common cardinal vein which sometimes may form a large left superior vena cava. So a left superior vena cava — when present — opens into the coronary sinus and NOT DIRECTLY into the Rt. atrium

* The anterior cardiac veins (2-3) (+) the venae cordis minimae ⟹ open directly into the right atrium

Collateral circulation

A. Cardiac anastomosis → the two coronary arteries anastomose with each on the surface (insignificant) and in the myocardium. Intercoronary anastomosis is found in less than 10% of normal hearts, in 40% of anaemic hearts, and in 100% of hearts with old coronary occlusion.

B. Extracardiac anastomosis → Coronary arteries anastomose with (a) vasa vasora of aorta and pulmonary trunk
(b) internal thoracic arteries
(c) bronchial arteries
(d) phrenic arteries
} ⟹ through the pericardium

→ In spite of these collateral circulations there occurs myocardial infarction (i.e death of cardiac muscle) in coronary thrombosis. All collateral circulations therefore appear to be too poor to meet the demands during emergencies.

Jordan University Hospital

مستشفى الجامعة الأردنية

CATH # ..... Patient Name : ..... Age: .....

DOCTOR ..... Patient No: ..... Date .....

48 B

نموذج قسطرة شرايين القلب

CORONARY ARTERIAL DIAGRAM

Ao - p .....

LV p .....

LVED p .....

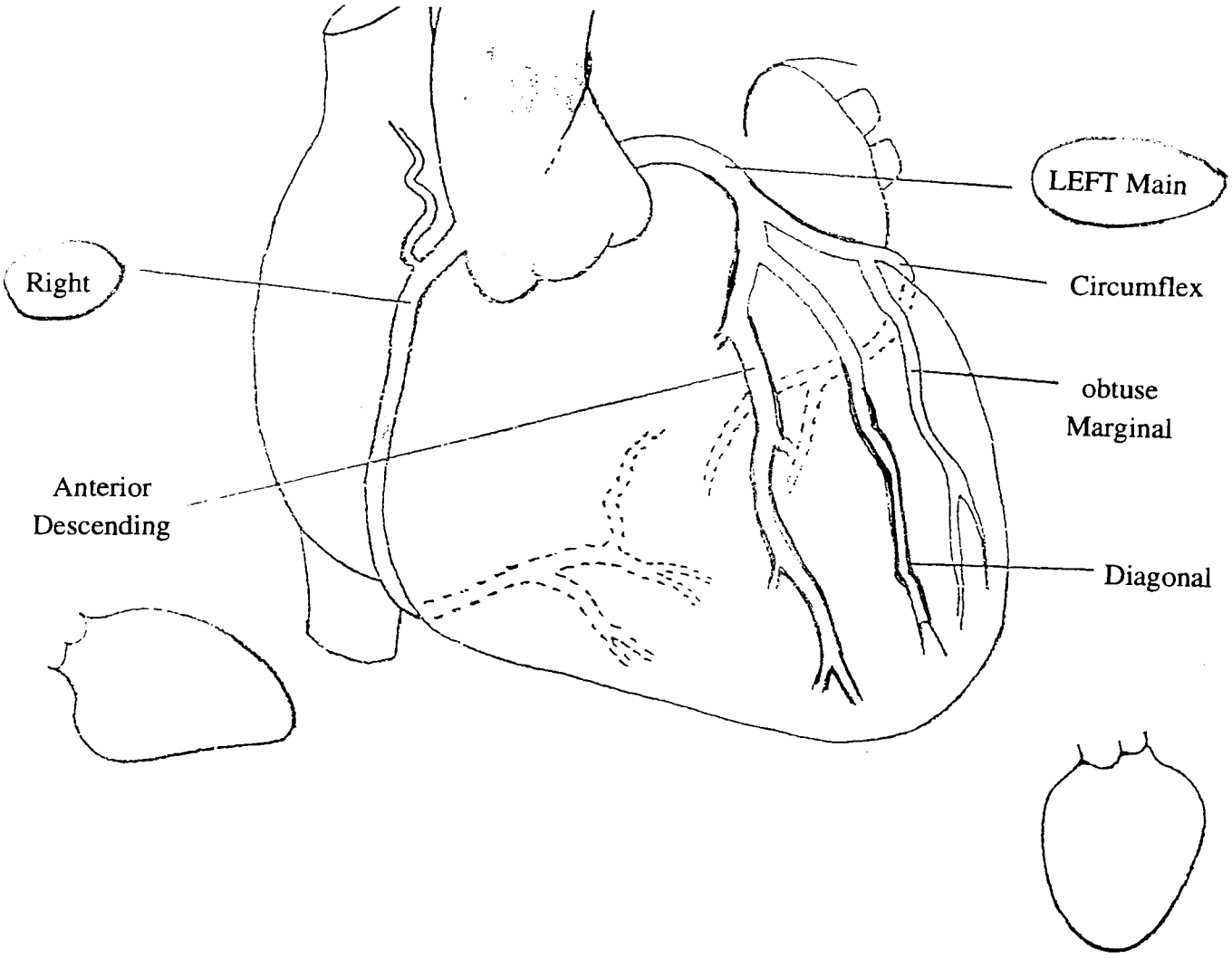

COMMENTS: LV: .....

LM: ..... LAD: .....

DIAG .....

: ..... RAMUS: .....

CX&OM .....

RCA: .....

: .....

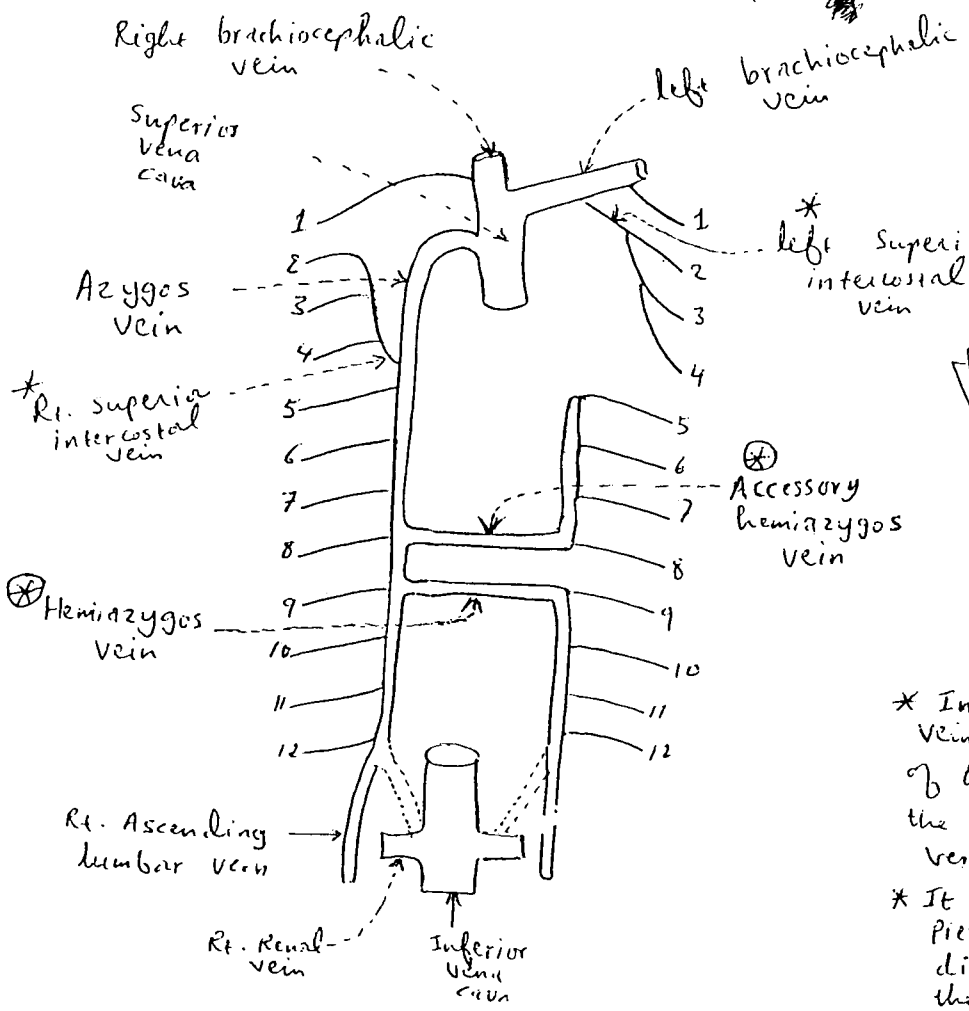

Azygos vein

* drains the thoracic wall & upper lumbar region
* FORMS IMPORTANT CHANNEL CONNECTING THE TWO VENAE CAVAE
* on developmental ground it should originate from the posterior surface of the inferior vena cava near the renal veins → This is known as Lumbar azygos vein
* In the absence of lumbar azygos vein it is formed by the union of the right ascending lumbar with the right subcostal vein at T_{12} vertebra
* It enters the thorax either by piercing the Rt. crus of the diaphragm or by passing through the aortic opening of diaphragm

Posterior intercostal veins

Right side

1st : into right brachiocephalic or vertebral vein

2nd, 3rd, 4th : form Rt. Superior intercostal vein which end in azygos vein

5th to 11th : into azygos vein

subcostal vein : drains into azygos vein

left side

1st : into left brachiocephalic vein

2nd, 3rd, 4th : form left superior intercostal vein which end in lt. brachiocephalic vein

5th to 8th : into the accessory hemiazygos vein

9th to 11th → hemiazygos vein

subcostal vein : drains into hemiazygos vein

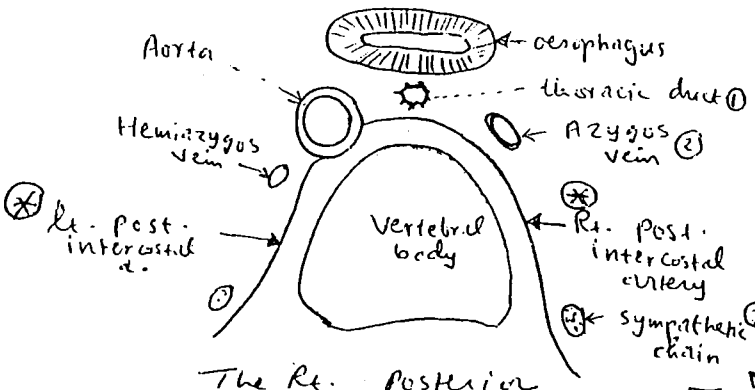

The Rt. posterior intercostal arteries are longer than the left

Post. intercostal arteries

1st & 2nd : arise from the sup. intercostal artery which is a branch of costo-cervical trunk (subclavian a.)

3rd to 11th : from descending thoracic aorta

Notice → sympathetic chain, azygos vein, thoracic duct } Run anterior to the Rt. post. intercostal arteries

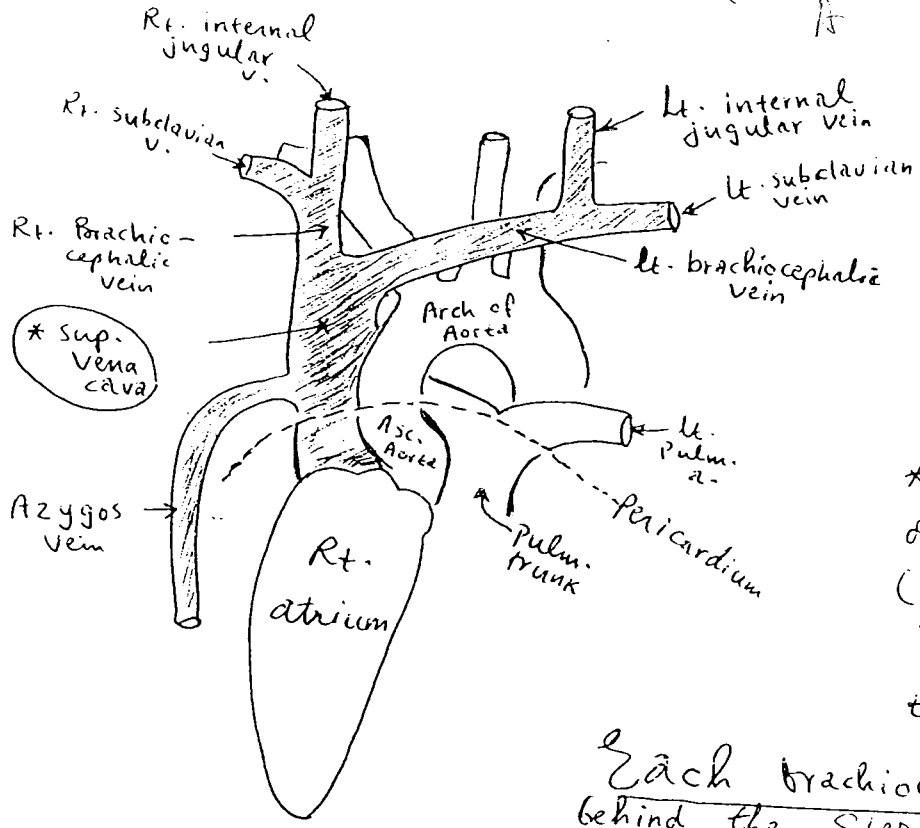

S.V.C

Sup. vena cava (5C) (7 cm long)

* a great vein which collects venous blood from the upper half of the body and drains it into the Rt. atrium.
* formed by the union of two brachiocephalic (innominate) veins behind the lower border of the first costal cartilage close to the sternum

Each brachiocephalic vein is formed behind the sternoclavicular joint by the union of the internal jugular & subclavian veins

Sup. vena cava → its upper ½ lies in the sup. mediastinum
→ its lower ½ lies in the middle mediastinum (inside the pericardium)

Sup. vena cava → begins behind the lower border of first costal cartilage
→ pierces pericardium opposite the second Rt. costal ... (It receives the azygos vein just before it enters the pericardium)
→ terminates by opening into the upper part of Rt. atrium behind the third Rt. costal cartilage

Sup. vena cava → Medial → Ascending aorta
→ lateral → Phrenic nerve
→ Rt. Pleura & lung

Remember ⇒ A (left) superior vena cava when present will open into the coronary sinus

→ Sup. vena cava ALWAYS communicate with the inf. vena cava (directly or indirectly ..... see before)

50 B

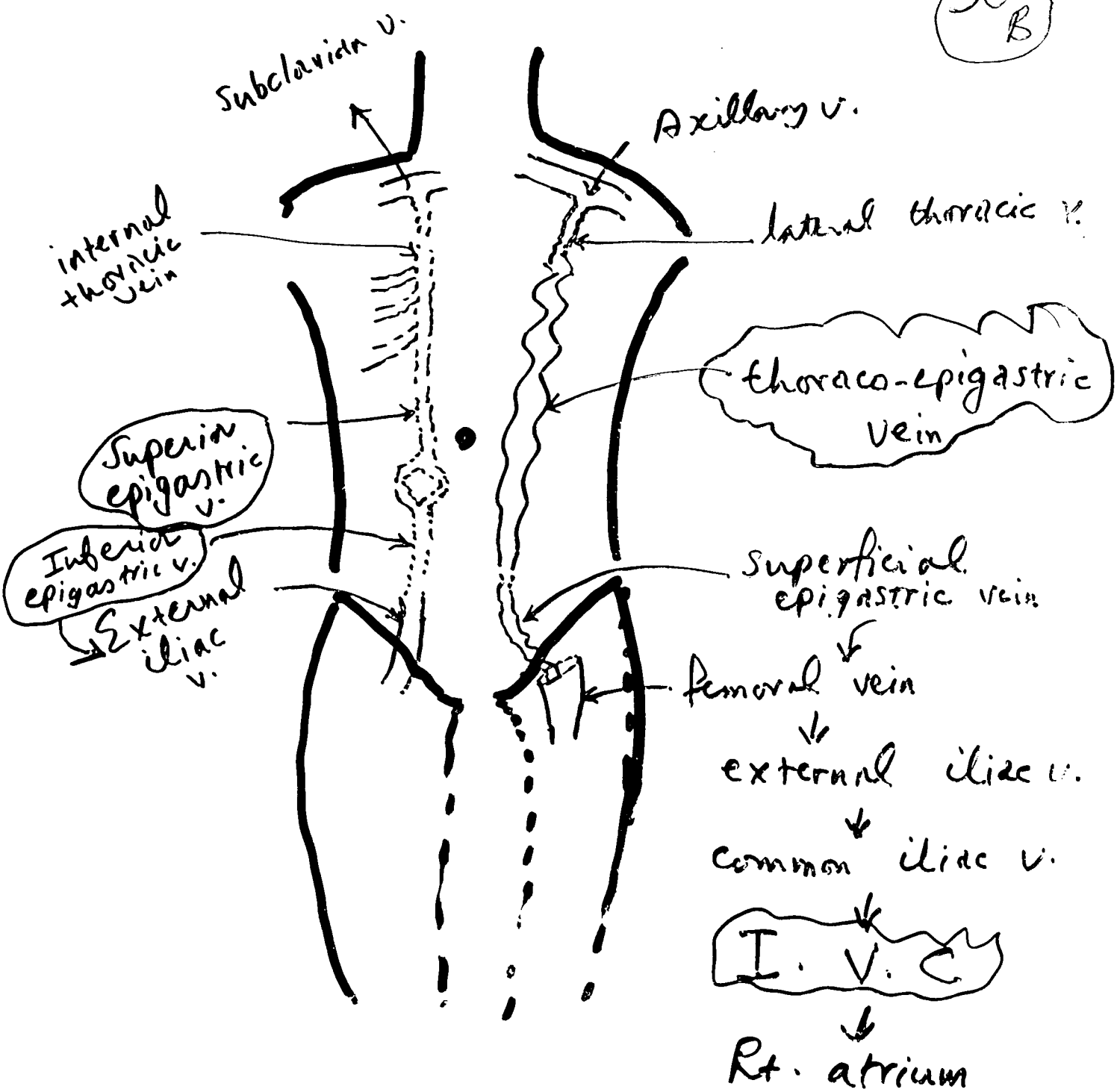
Subclavian v.
Axillary v.
internal thoracic vein
lateral thoracic v.
thoraco-epigastric vein
Superior epigastric v.
Inferior epigastric v.
External iliac v.
superficial epigastric vein
femoral vein
external iliac v.
common iliac v.
I. V. C
Rt. atrium

Bustami

51

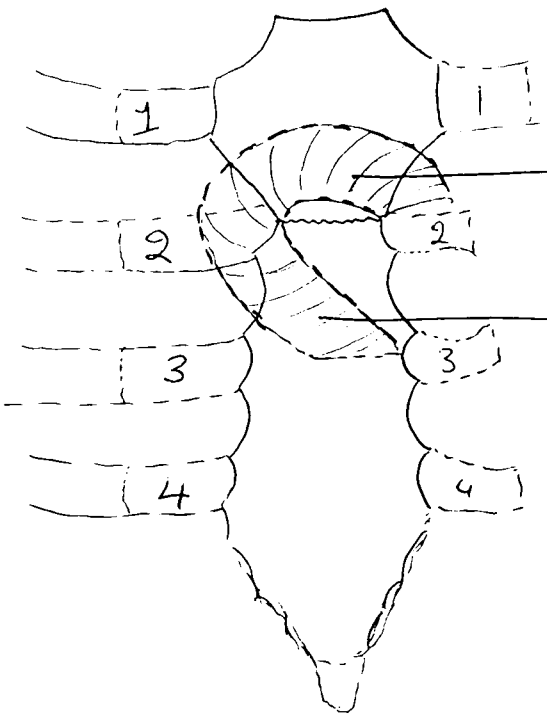

Aorta — Ascending, Arch, Descending

(2) Arch of Aorta
- outside the pericardium
- posterior to the lower ½ of manubrium sterni
- in superior mediastinum

(1) Ascending Aorta
- inside the pericardium
- in middle mediastinum
- posterior to the body of sternum
- begins at the aortic orifice of the left ventricle opposite the sternal end of left 3rd costal cartilage
- ends at the sternal end of the right 2nd costal cartilage where it continues as the arch of aorta
- Branches → Rt. & Lt coronary arteries

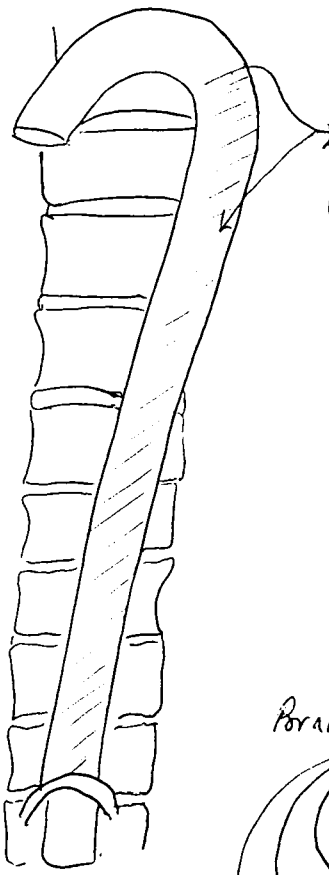

(3) Descending aorta

begins → at the lower border of 4th thoracic vertebra (i.e at sternal angle) to the left side of vertebral column

ends → at the lower border of 12th thoracic vertebra in the median plane

runs in the Post. mediastinum
i.e the oblique sinus of pericardium and the fibrous pericardium separate the base of the heart (left atrium) from the descending thoracic aorta

Branches
- 9 posterior intercostal arteries on each side for 3–11 spaces
- subcostal artery on each side
- 2 left bronchial arteries
- oesophageal branches to middle ⅓ of oesophagus
- pericardial branches
- mediastinal → to lymph nodes in post. mediastinum
- superior phrenic arteries

Bustami

Arch of Aorta

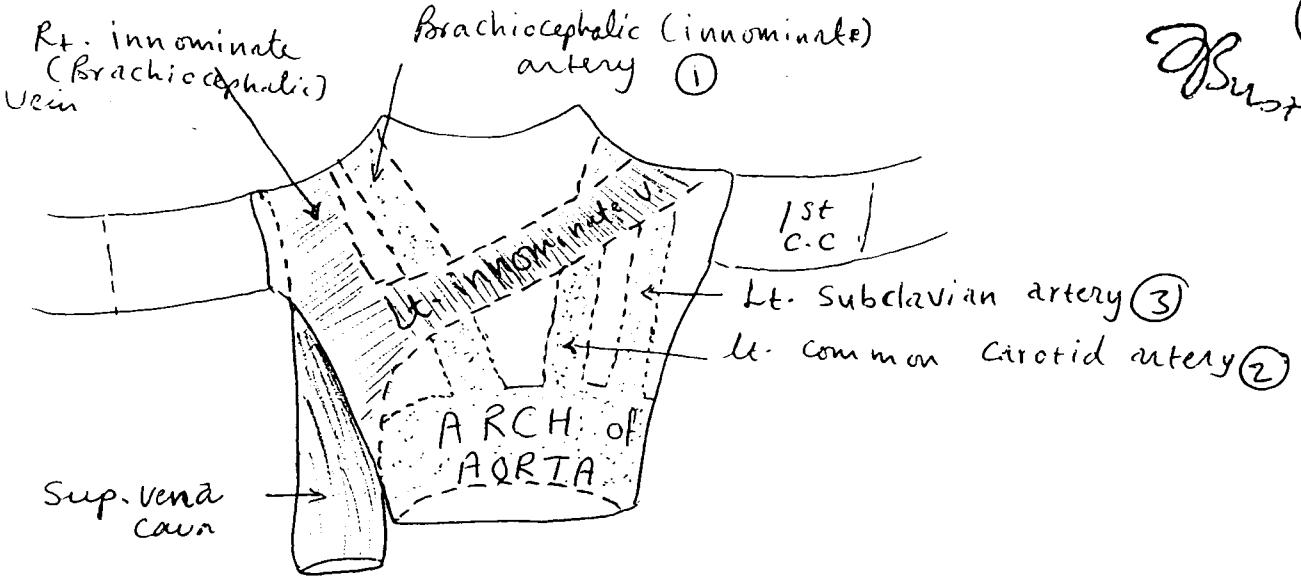

Arch of Aorta

- → Continuation of the ascending aorta
- → Situated in Superior mediastinum posterior to lower ½ of the manubrium sterni
- → begins behind the upper border of 2nd Rt. sternochondral joint (i.e sternal angle)

⇩

Runs upwards, backwards and to the left ACROSS THE LEFT SIDE OF THE BIFURCATION OF TRACHEA

⇩

Then passes downward behind the left bronchus

⇩

ends on the left side of the body of 4th thoracic vertebra (i.e level of sternal angle)

Thus the beginning and the end of the aortic arch are at the same level, although it begins anteriorly and ends posteriorly

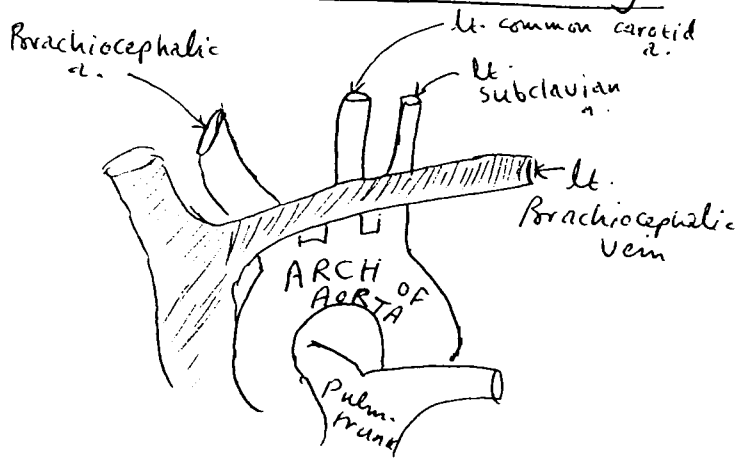

Superior relations

* 3 branches of the arch of aorta { Brachiocephalic, Lt. common carotid a., Lt. subclavian a.
* left brachiocephalic (innominate) vein → infront of the lower part of the 3 branches
* Remnants of thymus gland

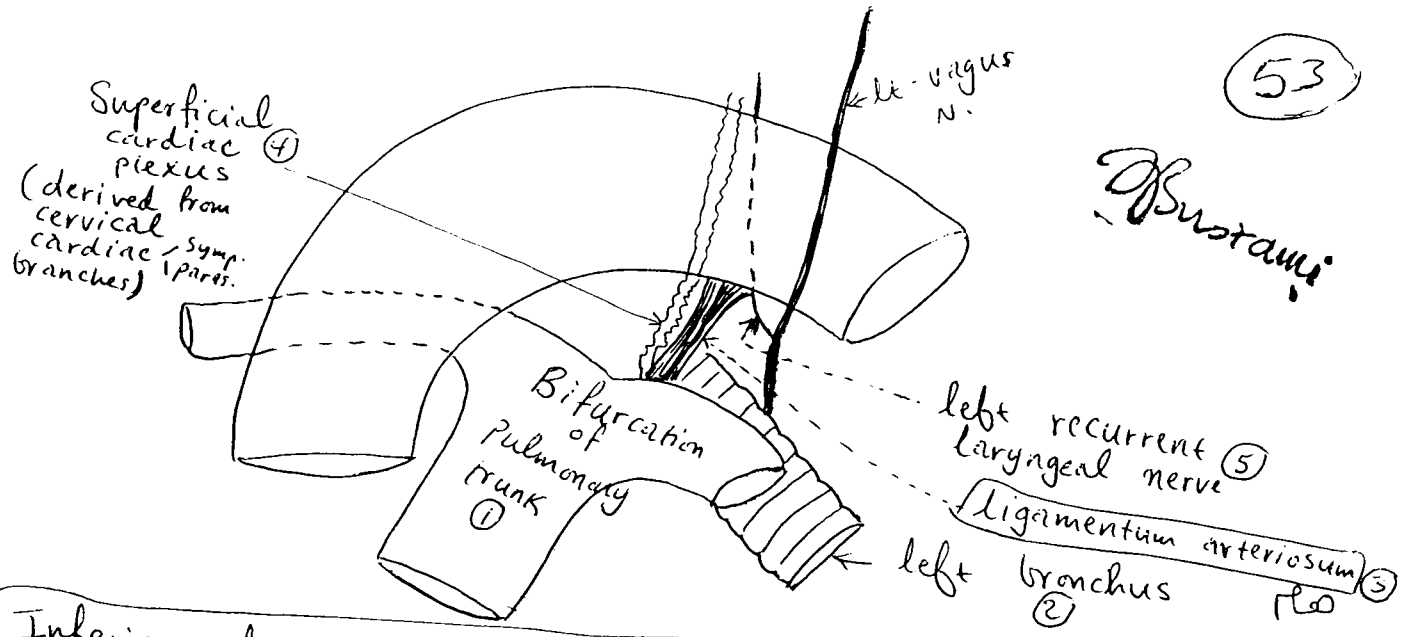

53

Bostani

Inferior relations of the arch of aorta

1. Bifurcation of the pulmonary trunk
2. left bronchus
3. ligamentum arteriosum é
   - superficial cardiac plexus anterior to it (4)
   - left recurrent laryngeal nerve posterior to it (5)

Remember → the ligamentum arteriosum extends between the left pulmonary artery (at its beginning) and lower surface of the arch of aorta DISTAL TO ITS LAST BRANCH (left subclavian a.)

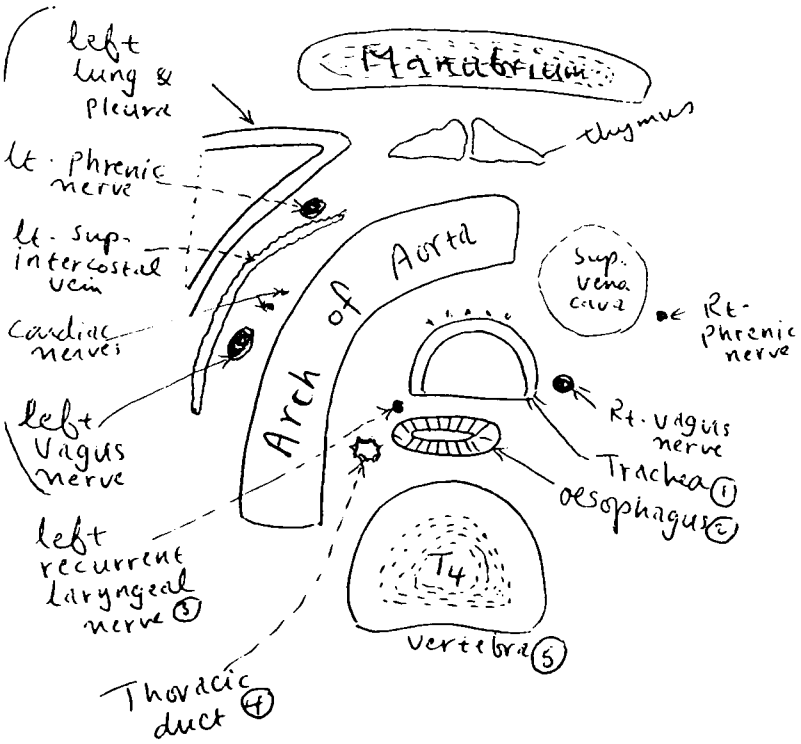

→ Transverse section of thorax passing through T4 showing superficial and deep relations of arch of aorta ←

Anterior & to the left (Superficial) relations

1. left phrenic nerve
2. left vagus nerve
3. left superior intercostal vein (deep to phrenic but superficial to vagus)
4. 2 cardiac nerves < symp. / parasymp. to superficial cardiac plexus
5. Left pleura + lung

Posterior & to the right (deep) relations

1. Trachea (with deep cardiac plexus)
2. oesophagus
3. left recurrent laryngeal nerve (in the groove between trachea + oesophagus)
4. thoracic duct (on the left side of oesophagus)
5. vertebral column

PULMONARY TRUNK

COURSE : (The left pleura & lung separates it from it Intercostal space)

* It arises from the right ventricle at the pulmonary orifice opposite the sternal end of **3rd left costal cartilage.**
* It is at 1st in front of the ascending aorta, **enclosed together** within a single sheath of serous pericardium (both develop from the **truncus arteriosus).**
* It then passes upwards to gain the left side of the ascending aorta and **ends** below the arch of aorta (opposite the 2nd left costal cartilage) by dividing into right and left pulmonary **arteries.**
* The point of division is to the **left of the median plane** (bifurcation of trachea is to the right of the median plane).
* It runs in the **2nd** left space **close to the sternal margin.**

BRANCHES : (only 2 terminal branches)

1. **RIGHT PULMONARY ARTERY :**

   * **It is longer than the left one.**
   * **It passes to the right in the roof of the transverse sinus of pericardium to join the root of the right lung.**
   * **Relations :**

     a) **Anterior relations :**

     * **Ascending aorta.**
     * **S.V.C.**

     b) **Posterior relations :**

     * **Oesophagus.**
     * **Right bronchus.**

2. **LEFT PULMONARY ARTERY :**

   * **It is shorter and passes to the left to join the root of left lung.**
   * **It is joined to lower surface of the arch of aorta by the ligamentum arteriosum (fibrosed ductus arteriosus of the foetus).**
   * **Posterior relations :**

     Descending aorta
     left bronchus

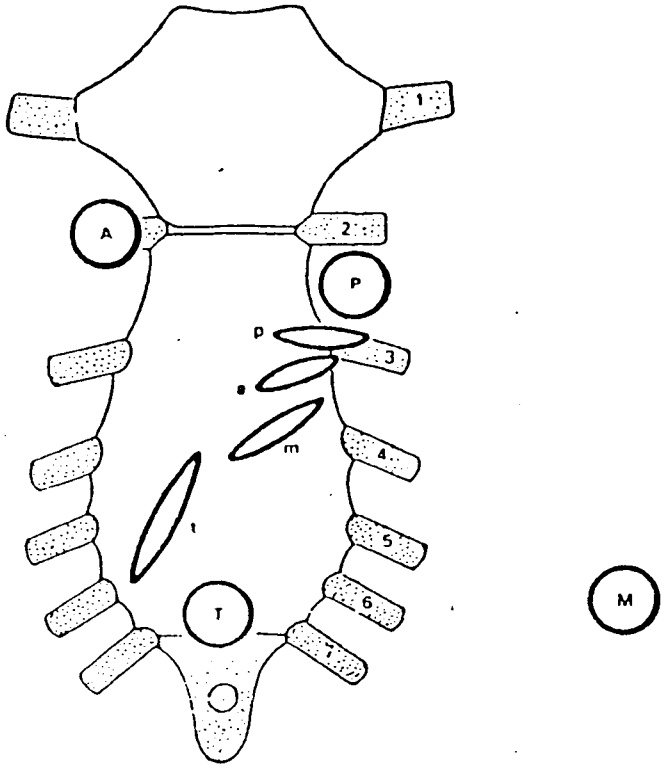

Fig. 173 Surface marking of the cardiac valves ; p = polumonary, a = aortic, m = mitral, andt = tricuspid. The position of the auscultatory areas is shown by circles and they are named by block letters.

Table 18. Surface marking of the cardiac valves, and the sites of the auscultatory areas

Valve	*Diameter of orifice*	*Surface marking*	*Auscultatory area*
1. Pulmonary	2.5 cm	A horizontal line, 2.5 cm long; behind the upper border of 3rd left costal cartilage and adjoining part of the sternum.	Second left interspace near the sternum.
2. Aortic	2.5 cm	A slightly oblique line, 2.5 cm long; behind the left 1/2 of the sternum at the level of the lower border of the 3rd costal cartilage.	Second right costal cartilage near the sternum,
3. Mitral	3 cm	An oblique line, 3 cm long; behind the left 1/2 of the sternum opposite the 4th costal cartilage.	Cardiac apex.
4. Tricuspid	4 cm	Most oblique of all valves, being nearly vertical, 4 cm long: behind the right 1/2 of the sternum opposite to the 4th and 5th spaces.	Lower end of the sternum.

SURFACE MARKING OF THE HEART

The *upper border* is marked by a straight line joining (i) a point at the lower border of the 2nd left costal cartilage about 1/2 inch (1.3 cm) from the sternal margin to (ii) a point at the upper border of the 3rd right costal cartilage 1/2 inch (1.3 cm) from the sternal margin.

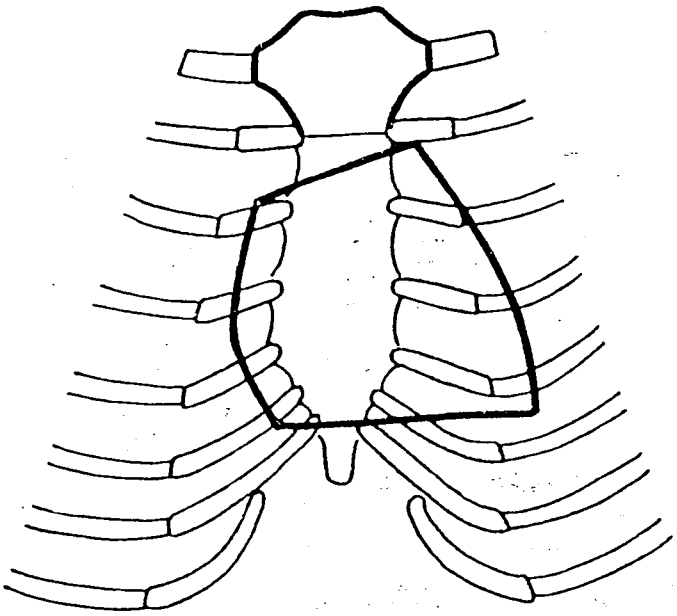

Fig. 175 Surface marking of the heart.

The *lower border* is marked by a straight line joining (i) a point at the lower border of 6th right costal cartilage 2 cm from the sternal margin to (ii) a point at the apex of the heart in the 5th intercostal space 3½ inches (9 cm) from the midsternal line.

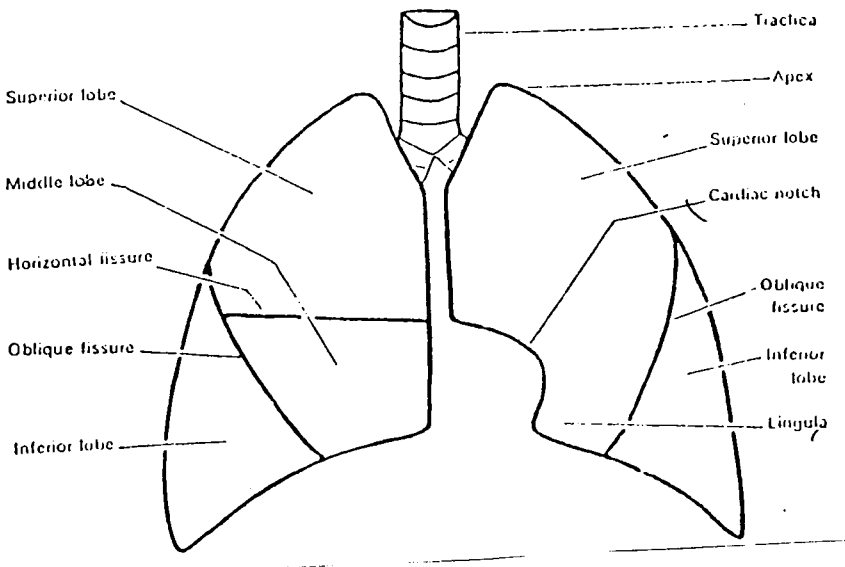

57

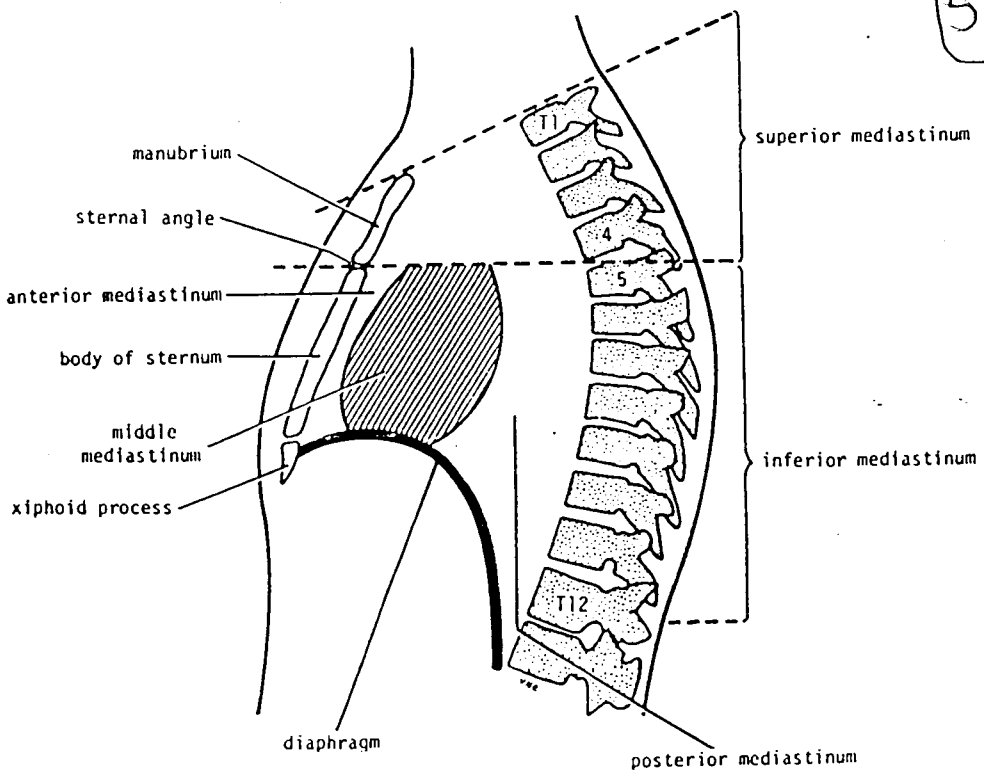

Fig. 1. Subdivisions of mediastinum.

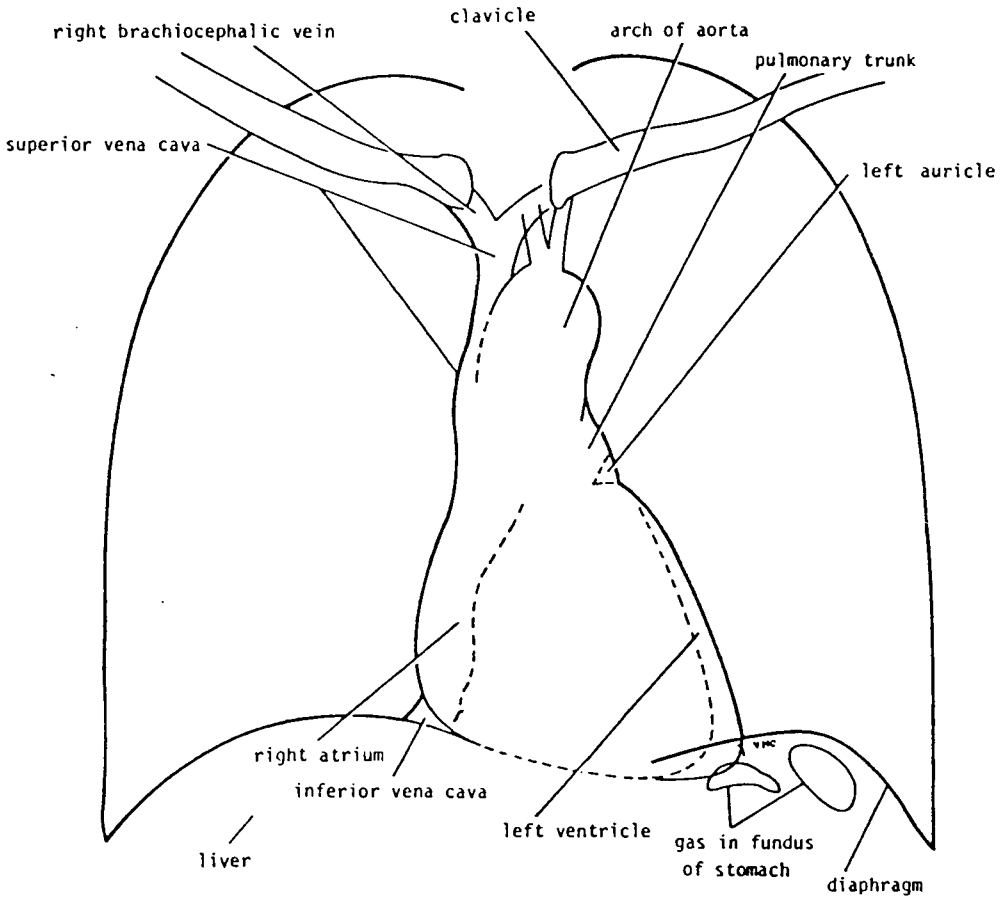

Comment on this x-ray Chest ??

(58)

(1)

(2)

(3)

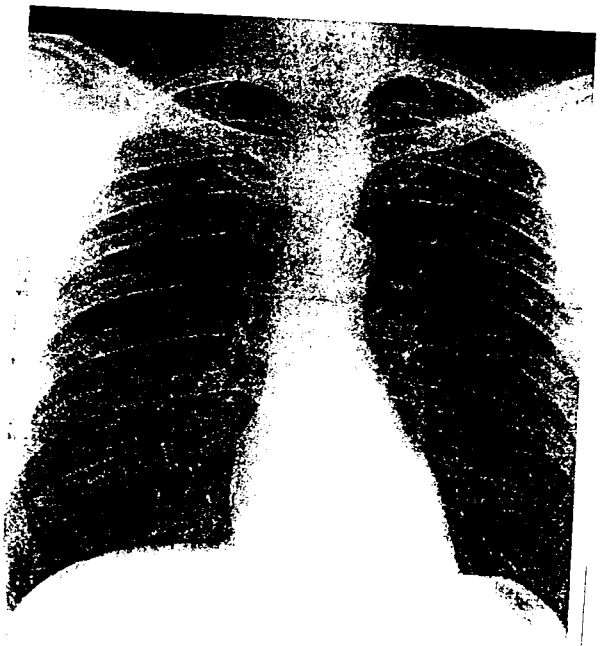

Which of these x-rays of Chest is the NORMAL ??? 1, 2, 3 ??

A Portal System of veins is one which begins & also ends in Capillaries e.g Liver, Kidney, Pituitary gland (58) B

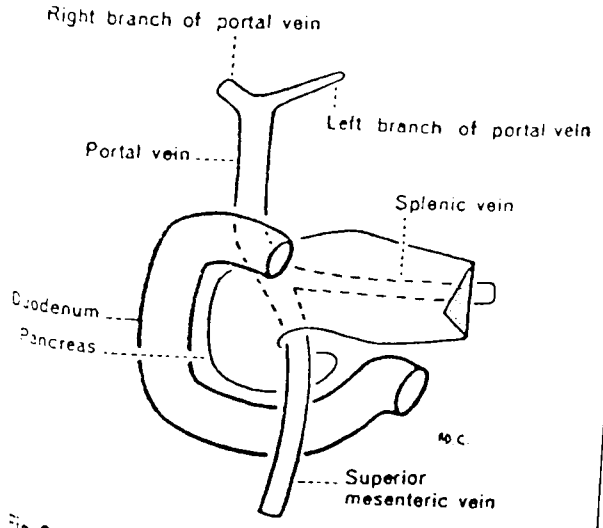

Fig. 237 Formation and course of the portal vein.

Relations

A. Infraduodenal part (Figs. 203, 230)
   1. Anteriorly: neck of pancreas.
   2. Posteriorly: inferior vena cava.

B. Retroduodenal part (Fig. 230)
   1. Anteriorly: (a) first part of duodenum; (b) common bile duct; and (c) gastro-duodenal artery.
   2. Posteriorly: inferior vena cava. 'Upurstami'

C. Supraduodenal part, in the free margin of lesser omentum (Fig. 178)
   1. Anteriorly: (a) hepatic artery; and (b) bile duct.
   2. Posteriorly; inferior vena cava.
   3. Surrounded by: (a) hepatic plexus of nerves; and (b) lymph nodes and lymphatics.

PORTAL CIRCULATION

* The portal circulation carries the venous blood from the stomach, small intestine, large intestine as well as from the spleen, gall bladder and pancreas **through the portal vein** to the liver.

* The portal blood circulates in fine capillaries inside the liver and is collected by the hepatic veins which end in the I.V.C.

N.B.: The upper part of the gut (oesophagus) as well as its lower part (anal canal and part of the rectum) are **drained into the systemic circulation.**

PORTAL VEIN

ORIGIN AND COURSE :

* It is only ~~4~~ 2-3 inches long and is **characterized** by the fact that it begins as a vein (by tributaries) but ends as an artery (by giving branches).

* It begins behind the **neck of pancreas** at L_2 by union of the splenic and superior mesenteric veins.

* It ascends behind the 1st part of the duodenum to enter the free margin of lesser omentum.

* It enters the **porta hepatis** where it divides into right and left branches.

* It is **devoid of valves.**

ANASTOMOSIS BETWEEN THE PORTAL AND SYSTEMIC CIRCULATIONS : form collateral circulation in Portal obstruction

59

1. AT THE LOWER END OF OESOPHAGUS : between :

   a) Oesophageal tributaries of the **left gastric vein** (portal).

   b) Oesophageal tributaries of the **azygos vein** (systemic).

   In portal hypertension this anastomosis enlarges to form **oesophageal varices** (dilated and tortuous veins in the submucosa of lower end of oesophagus). Its rupture leads to bleeding in the stomach **(haematemesis).**

2. AT THE LOWER END OF RECTUM : between : Obstruction

   a) **Superior rectal vein** (portal).

   b) **Middle and inferior rectal veins** (systemic).

   If this anastomosis enlarges, the veins in the submucosa of the rectum become dilated and tortuous leading to formation of **piles (haemorrhoids).**

3. AT THE SKIN AROUND UMBILICUS : between :

   a) **Para-umbilical veins** (portal).

   b) Veins of **anterior abdominal wall** (systemic).

   Enlargement of this anastomosis leads to dilatation of the skin veins in a radial direction around the umbilicus, a condition called **caput medusae.**

4. LESS EFFECTIVE SITES OF ANASTOMOSIS :

   * **At the bare area of liver** : between :

     a) Capillaries within the liver (portal).

     b) Phrenic tributaries on the under surface of diaphragm (systemic).

   * **On posterior abdominal wall** : between :

     a) Lumbar veins (systemic).

     b) Colic veins (portal).

N.B. :

The portal vein is **2 inches long, formed by 2 veins** (splenic and superior mesenteric), **ends by 2 branches** (to right and left lobes of the liver), **receives 2 main tributaries** (right and left gastric veins) and **2 ligaments** are attached to its left branch (ligamentum teres and ligamentum venosum).

Branches of Portal Vein

1. The *right branch* is shorter and wider. After receiving the cystic vein, it enters the right lobe of liver.

2. The left branch is longer and narrower. It traverses the whole porta hepatis from right to the left end, and furnishes branches to the caudate and quadrate lobes. Just before entering the left lobe of liver, it receives: (a) paraumbilical veins; (b) ligamentum teres; and (c) ligamentum venosum.

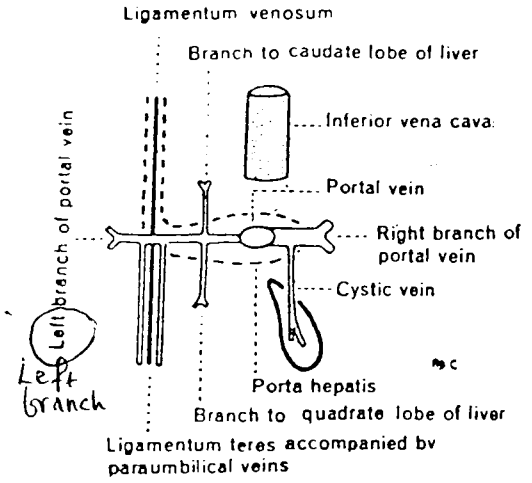

Fig. 238 Branches of the portal vein; their sub-branches and tributaries.

Intrahepatic Course

After entering the liver, each branch divides and redivides along with the hepatic artery, enclosed in the Glisson's capsule, to end ultimately in the hepatic sinusoids, where the portal venous blood mixes with the hepatic arterial blood.

Tributaries

These are: (i) the splenic (p. 180); (ii) superior mesenteric (p. 193); (iii) left gastric; (iv) right gastric; (v) superior pancreaticoduodenal; (vi) cystic; and (vii) paraumbilical veins.

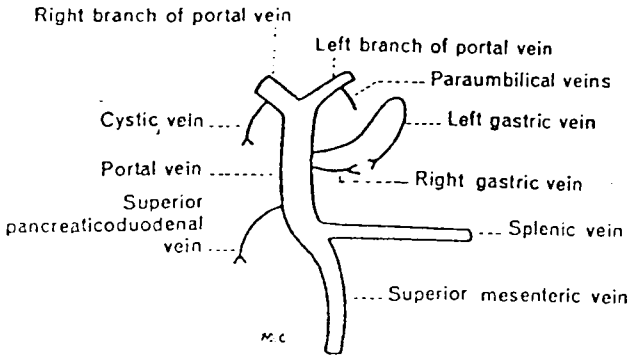

Fig. 239 Tributaries of the portal vein.

The left gastric vein receives at the cardiac end of stomach a few oesophageal veins; the right gastric receives the prepyloric vein.

The para-umbilical veins are small veins that run in the falciform ligament, along the ligamentum teres, and establish anastomosis between the veins of the anterior abdominal wall around the umbilicus and the portal vein.

Bustami 60

امتحان شعير

Bustami

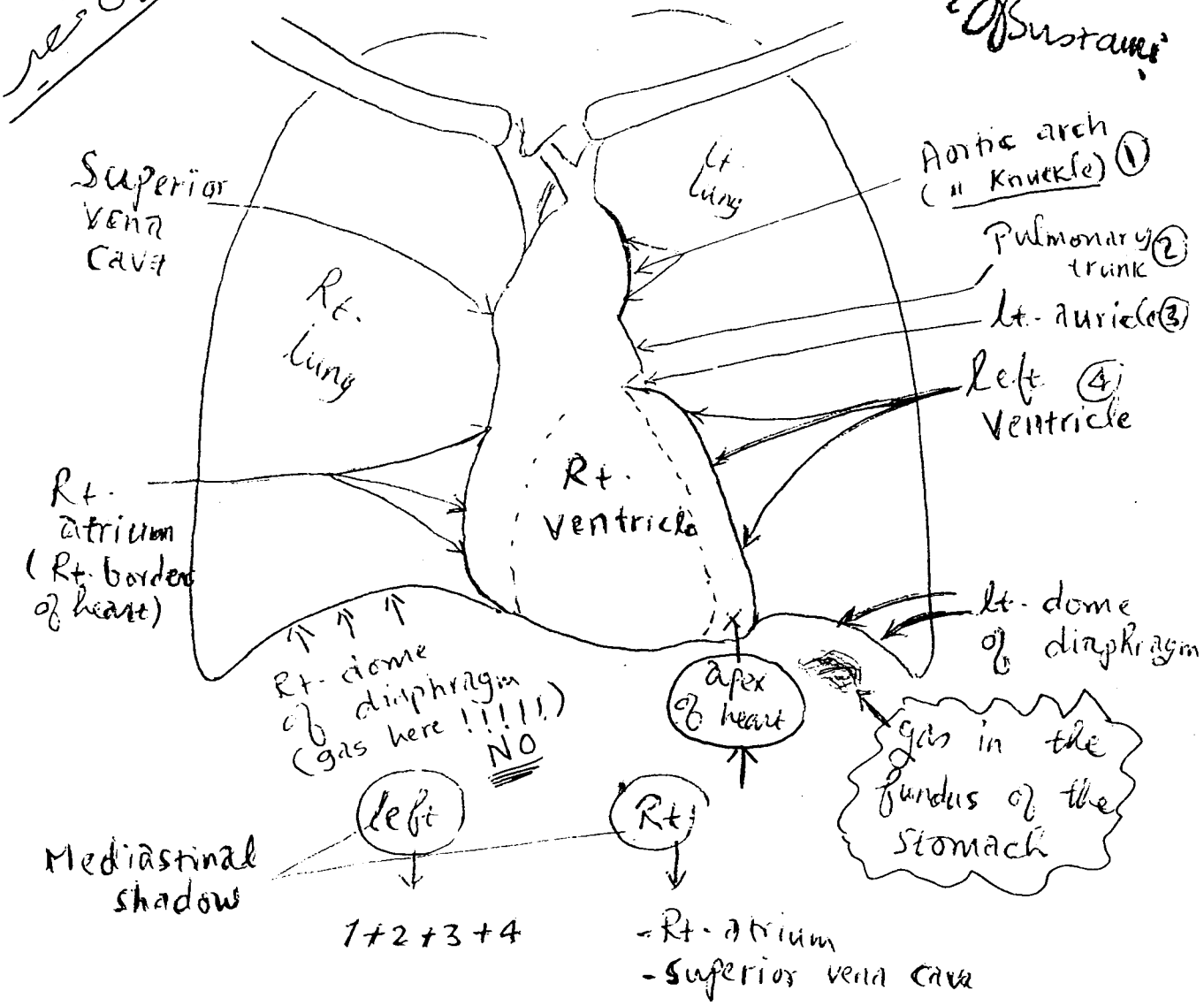

Remember → Most of the (anterior surface) of the heart is formed by the Rt. ventricle

Lt. atrium → form the base of the heart (opposite the apex formed by the lt. ventricle)

How blood enters and leaves the heart

SVC & IVC receive deoxygenated blood from all over the body (except the lungs) → blood passes to the Rt. ~~ventricle~~ atrium → Rt. ventricle → along pulmonary trunk to the lungs → back to the lt. atrium along 4 pulmonary veins → lt. ventricle (strong pump) → Ascending aorta ---> arch of aorta & its branches → descending aorta ---> Systemic circulation

امتحان متعب

Obustami

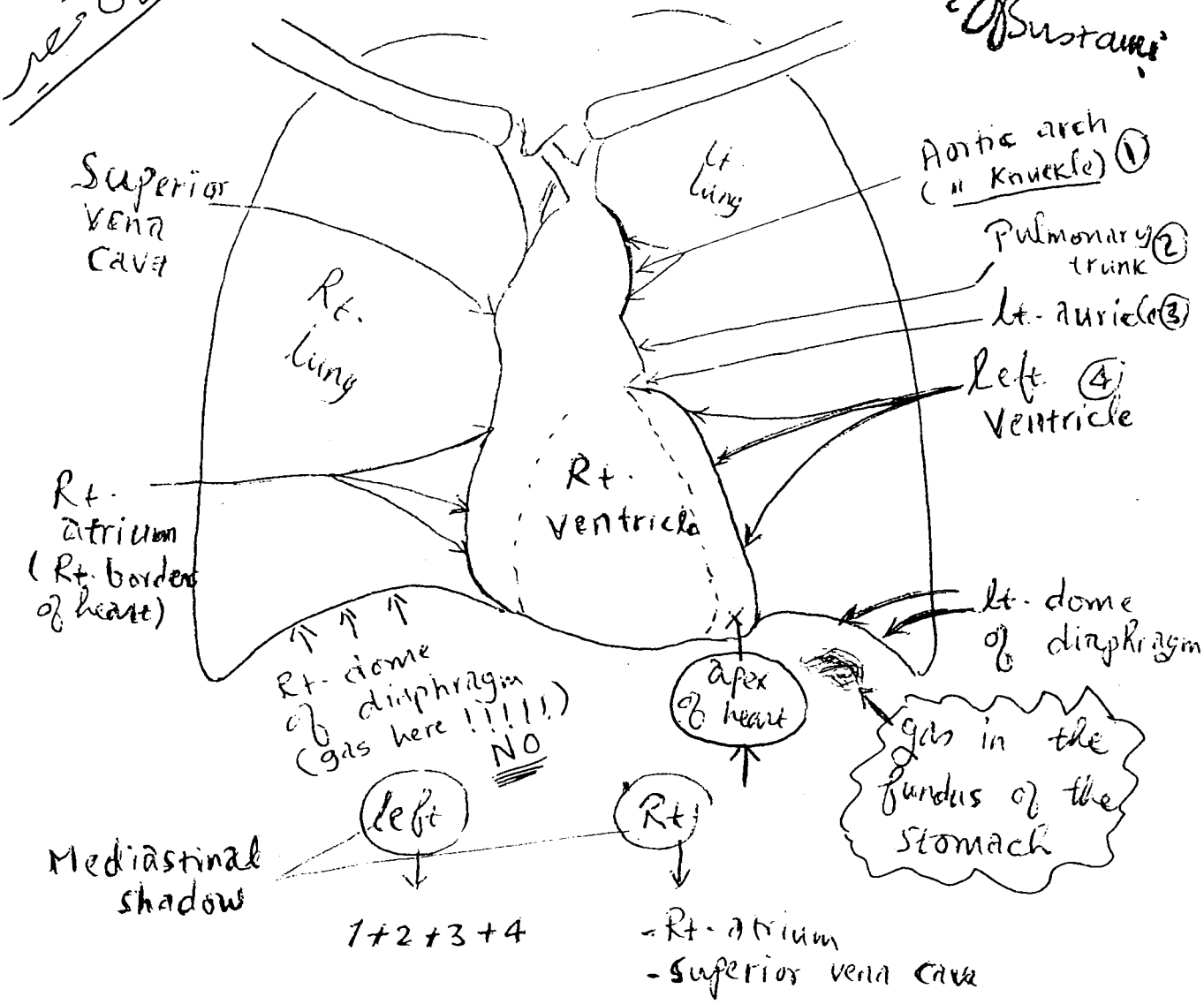

Remember → Most of the (anterior surface) of the heart is formed by the Rt. ventricle

Lt. atrium → form the base of the heart (opposite the apex formed by the Lt. ventricle)

How blood enters and leaves the heart

SVC & IVC receive deoxygenated blood from all over the body (except the lungs) → blood passes to the Rt. atrium → Rt. ventricle → along pulmonary trunk to the lungs → back to the Lt. atrium along 4 pulmonary veins → Lt. ventricle (strong pump) → Ascending aorta ---> Arch of aorta & its branches → descending aorta ---> Systemic circulation

امتحان متعب

Bustami

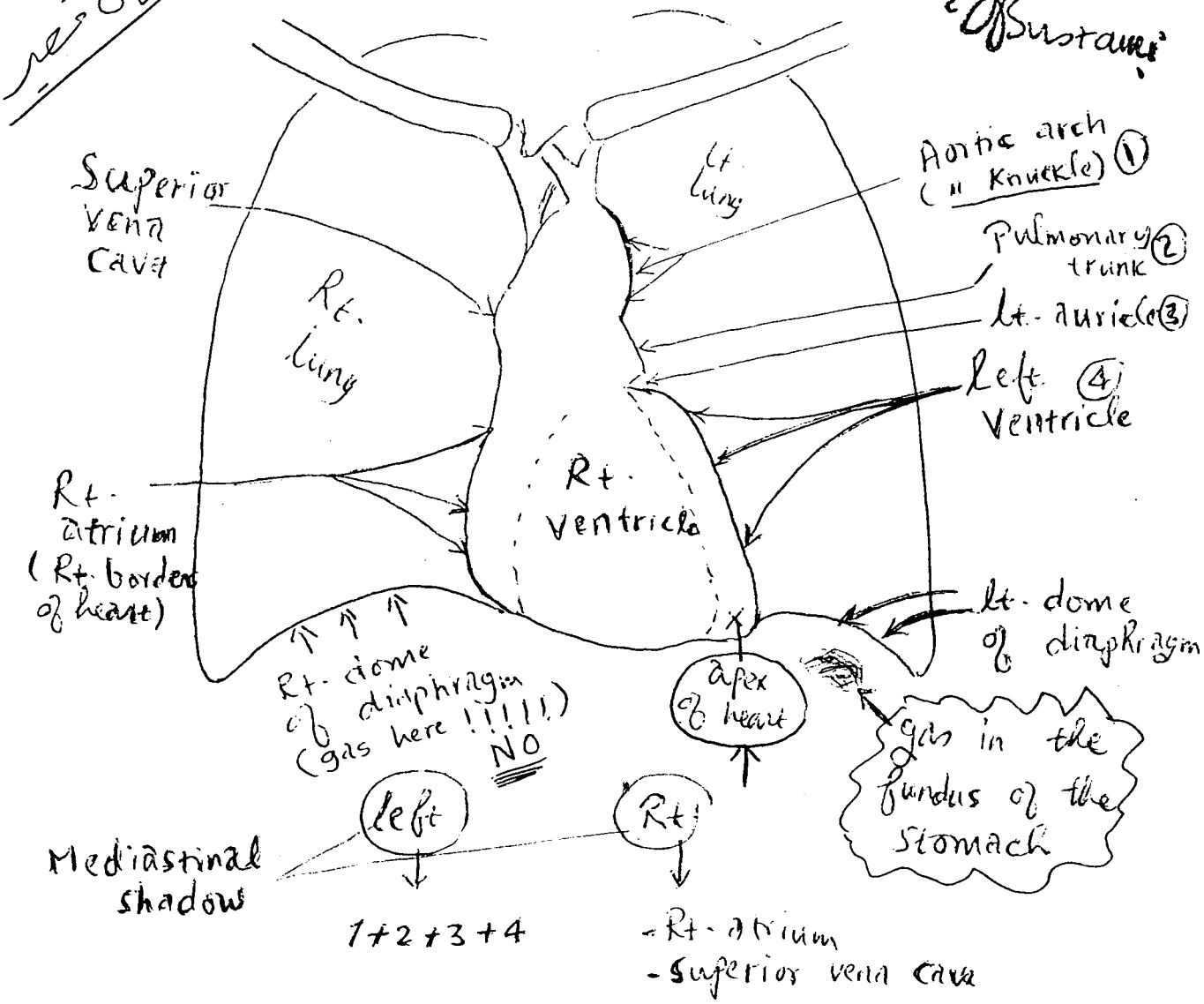

Remember → Most of the (anterior surface) of the heart is formed by the Rt. ventricle

Lt. atrium → form the base of the heart (opposite the apex formed by the Lt. ventricle)

How blood enters and leaves the heart

SVC & IVC receive deoxygenated blood from all over the body (except the lungs) → blood passes to the Rt. atrium → Rt. ventricle → along pulmonary trunk to the lungs → back to the Lt. atrium along 4 pulmonary veins → Lt. ventricle (strong pump) → Ascending aorta ---> arch of aorta with its branches → descending aorta ---> Systemic circulation

امتحان متعب

Bustami

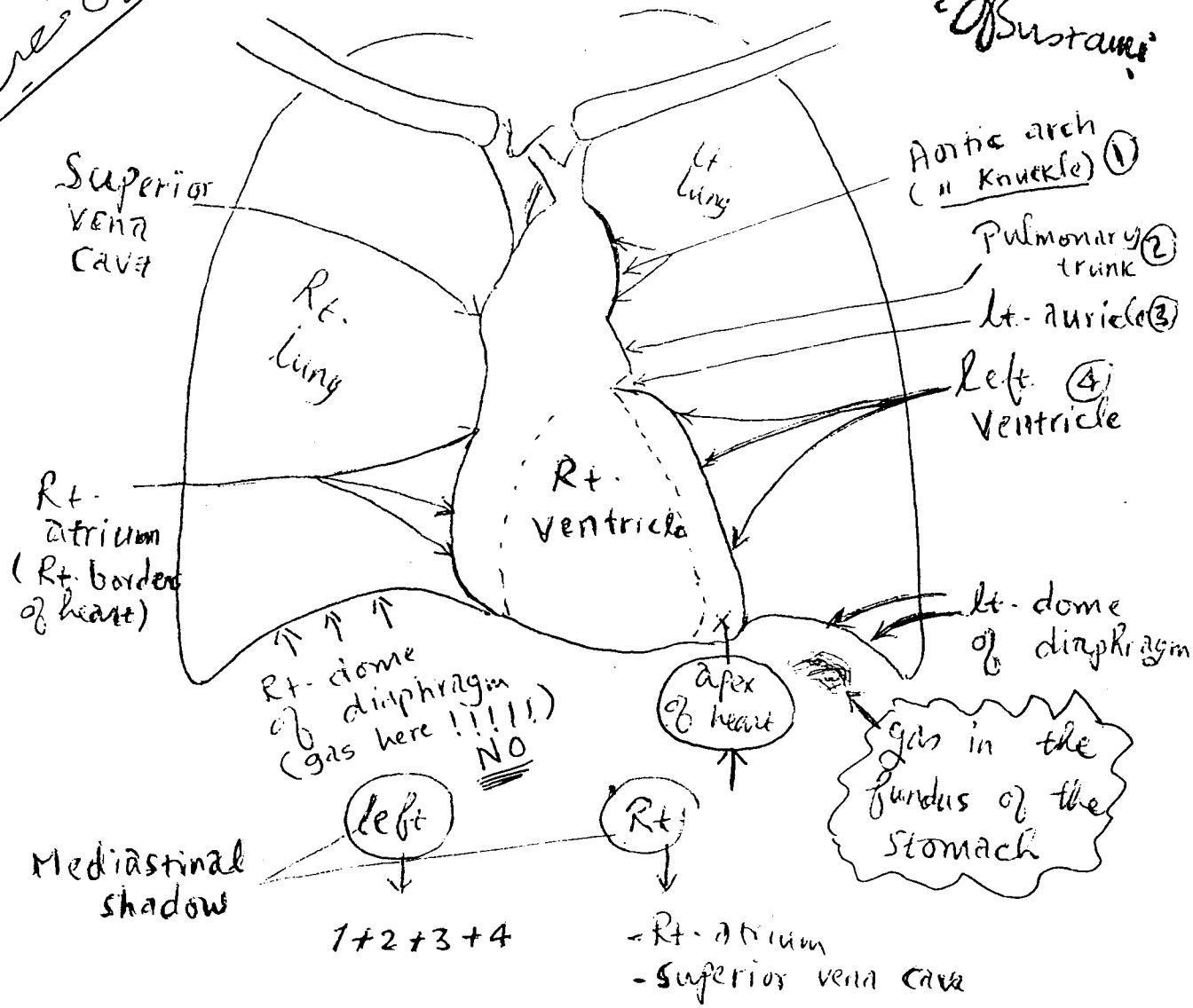

Remember → Most of the (anterior surface) of the heart is formed by the $\boxed{\text{Rt. ventricle}}$

Lt. atrium → form the base of the heart (opposite the apex formed by the lt. ventricle)

How blood enters and leaves the heart

SVC & IVC receive deoxygenated blood from all over the body (except the lungs) → blood passes to the Rt. atrium → Rt. ventricle → along pulmonary trunk to the lungs → back to the lt. atrium along 4 pulmonary veins → lt. ventricle (strong pump) → Ascending aorta ---→ arch of aorta with branches → descending aorta ---→ Systemic circulation