- Lecturer: Dr. Tariq Al-Adaily
- Email: TNALADILY@ju.edu.jo
- Office: JUH- outpatient building
- 3rd floor, Hematology Lab
- Office hours: Thursday 12-1
- Reference: Robbins Basic Pathology 9th ed

A-LAB 0004

Lab. Request Form

مستشفى الجامعة الأردنية
Jordan University Hospital

Surname : .....
Forname : .....
Sex : ..... Date of Birth : .....
Hospital No. : .....
Ward / Clinic : .....
Consultant : .....
Address : .....

Lab. Ref. No. : .....
Rec. Date : .....
Rec. Hr. : .....
Charges J. D. Fils
.....
.....

Nature of Specimen / s .....
Date .....
Hr .....
Dr. Sig. .....

HEMATOLOGY I

Code No.			Result	
C B C 103001	103005	❑ WBC × 12^{12}/L		4.0 - 10
	103004	❑ RBC × 10^9/L		M 5.5 ± 1.0 F 4.8 ± 1.0
	103003	❑ Hemoglobin g/dl		M 16 ± 2 F 14 ± 2
	103003	❑ HCT		M 0.46 ± 0.05 F 0.42 ± 0.05
		❑ MCV fl		80 - 100
		❑ MCH pg / cell		26 - 34
		❑ MCHC g / dl		31 - 36
103006		❑ Platelet × 10^9/L		140 - 440
103011		❑ ESR mm / hr		M 0 - 15 F 0 - 20
103010		❑ Retic. Count		0.005 - 0.015
103009		❑ Eosin. Count t × 10^9/L		0.05 - 0.45
103020		❑ Sickle Cell		Nil
103007		❑ Blood Film		
103025		❑ Malaria Smear		
103031		❑ PT		
103032		❑ PTT		
103033		❑ E G T		

			Result	
103012	❑ Hb. Electrophoresis			
103008	❑ DIFFERENTIAL	Neut - Band %		0
		Neut - Sig. %		40 - 75
		Eosinophil %		1 - 6
		Basophil %		0 - 1
		Lymphocyte %		20 - 45
		Monocyte %		2 - 10

LAB COMMENTS

.....
.....
.....
.....
.....
.....
.....
.....
.....
.....

Date Reported Reported By

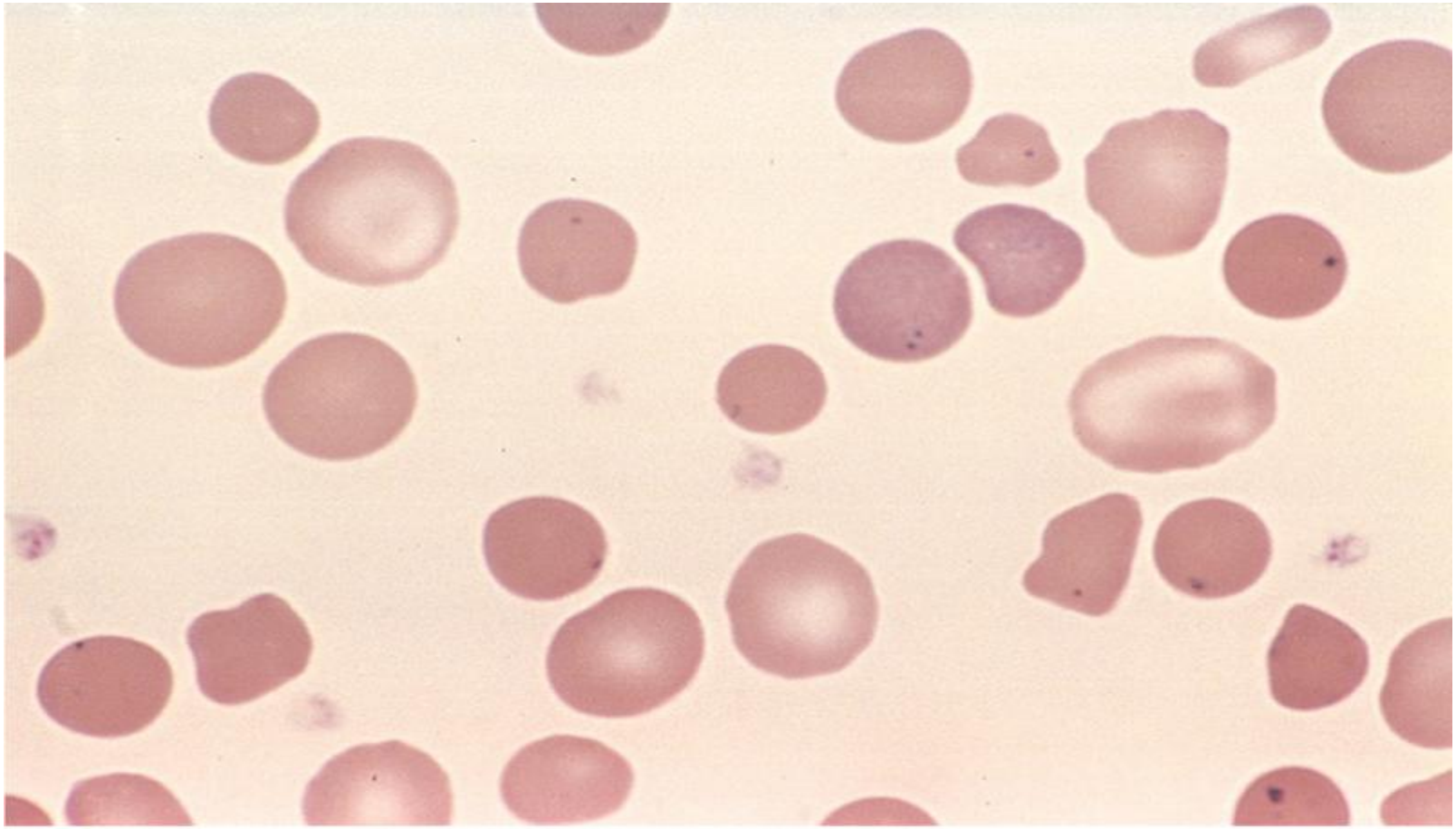

- Spherocytes appear as small, round cells without the central pallor. Howell Jolly bodies are noted

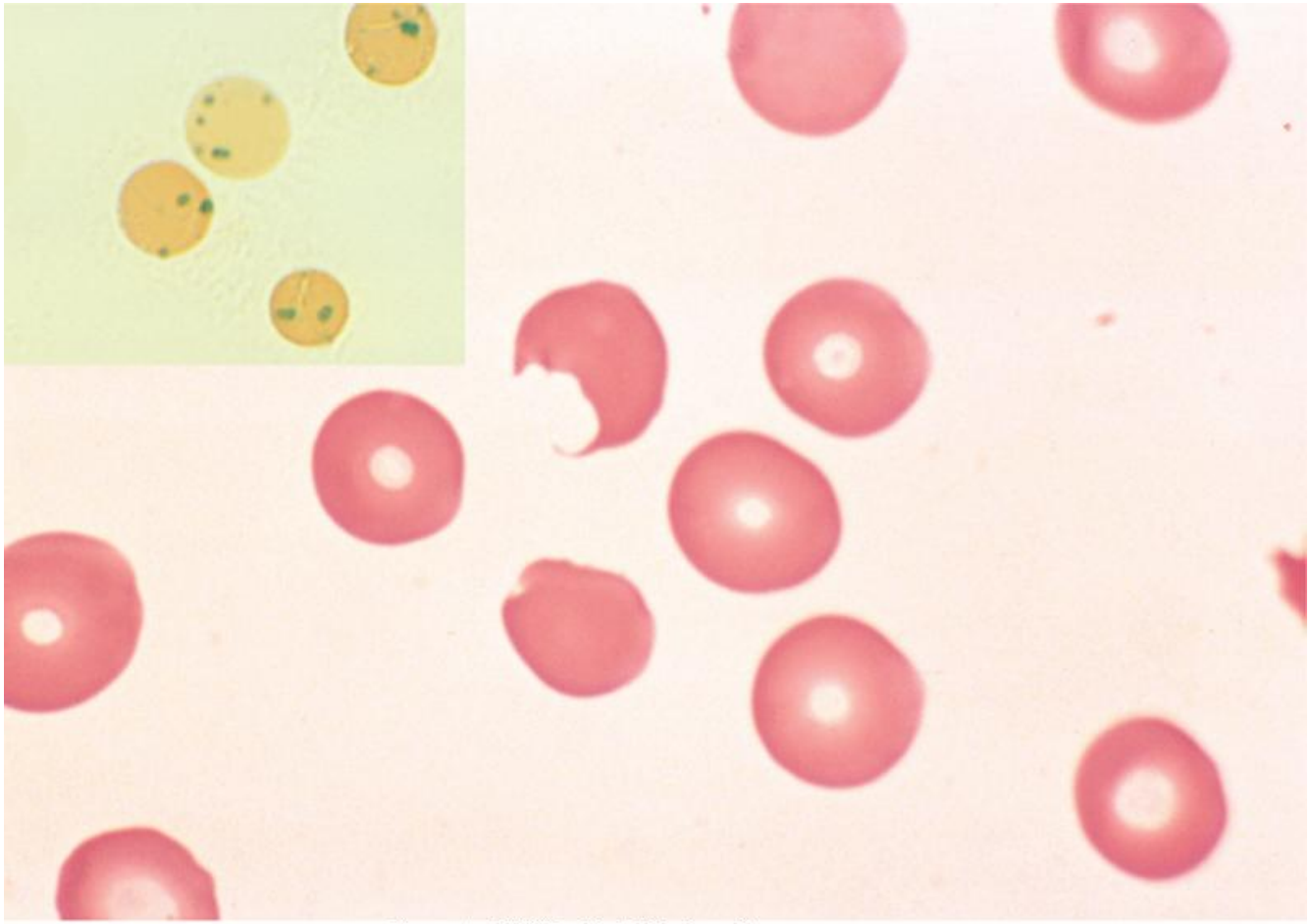

- Bite cells: seen in G6PD deficiency. Supravital stain (crystal violet) highlights Heins bodies

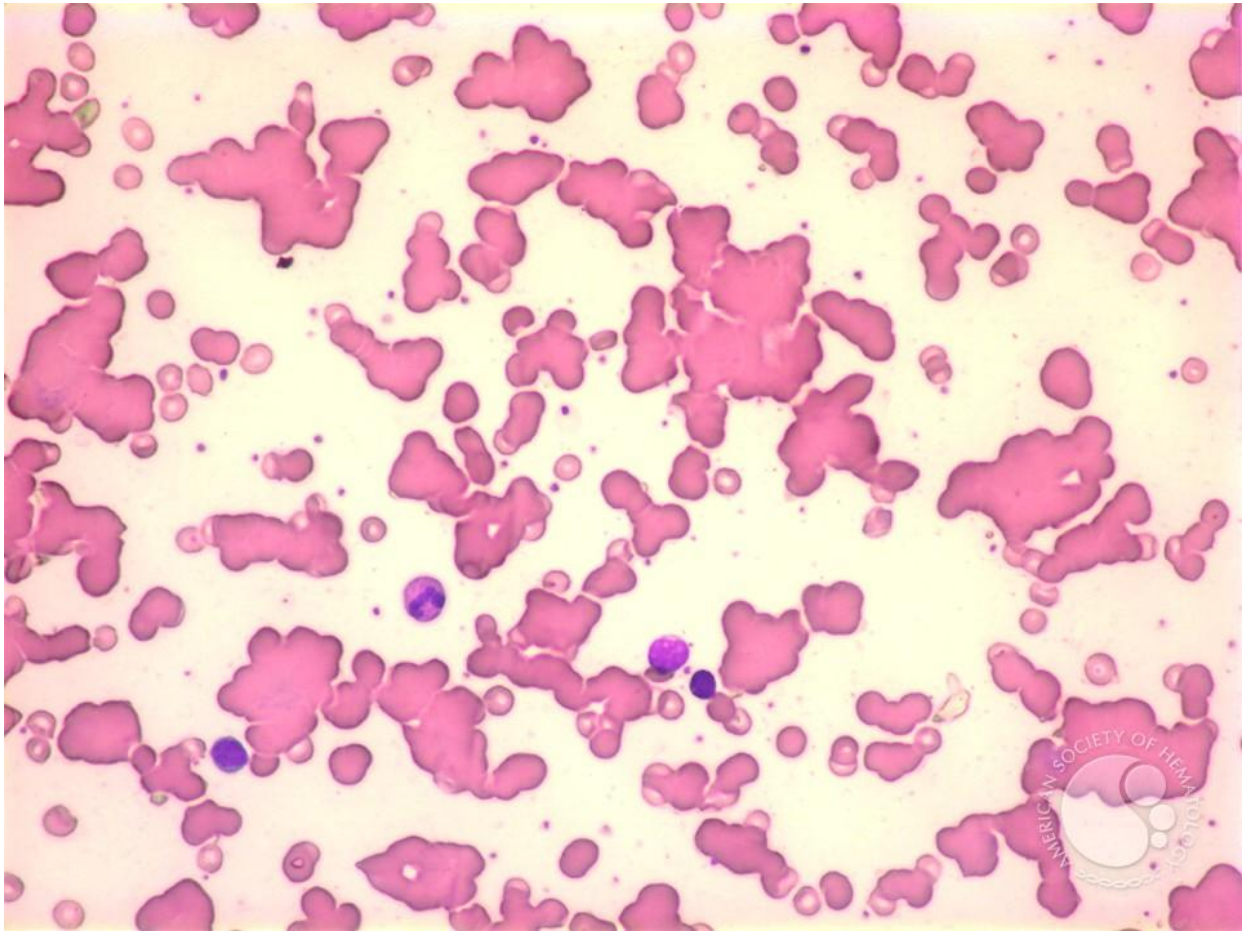

- RBC agglutination in autoimmune hemolytic anemia

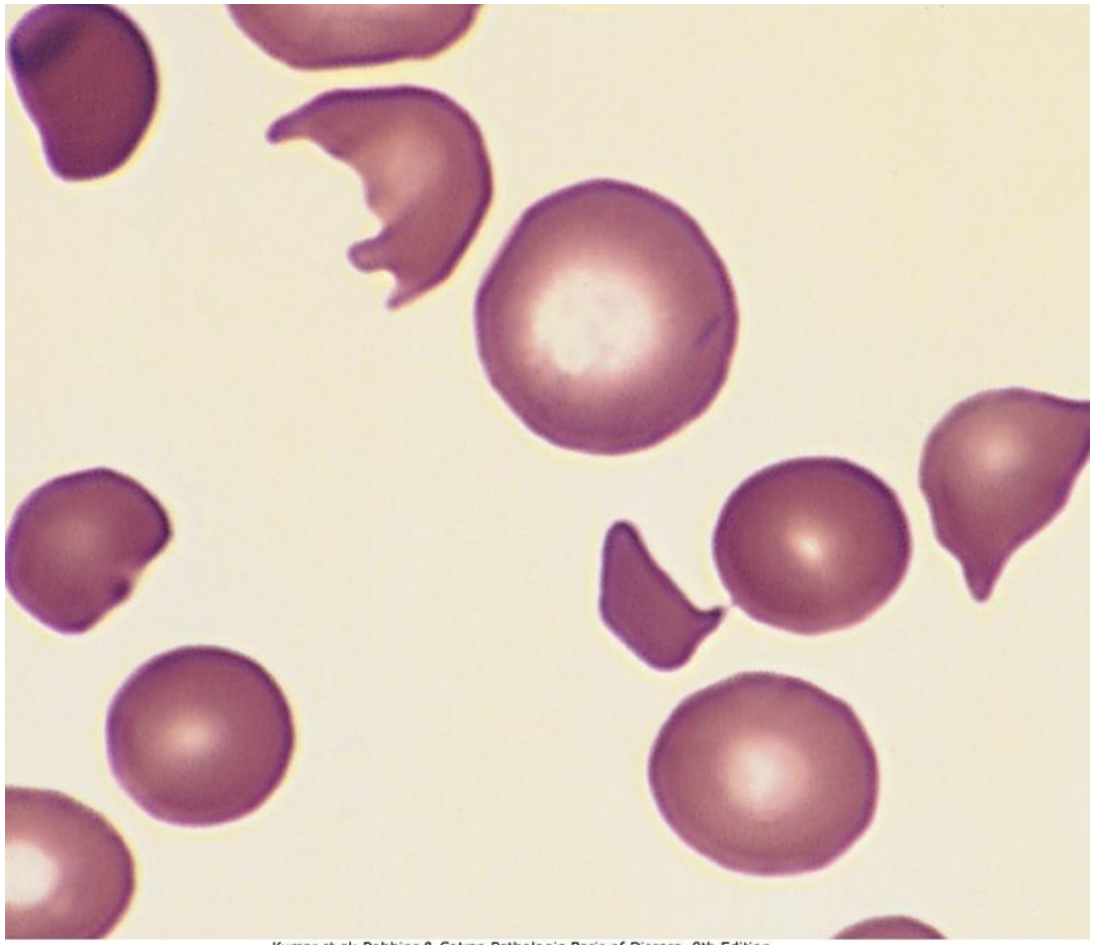

- Schistocytes: fragmented RBCs seen of different shapes

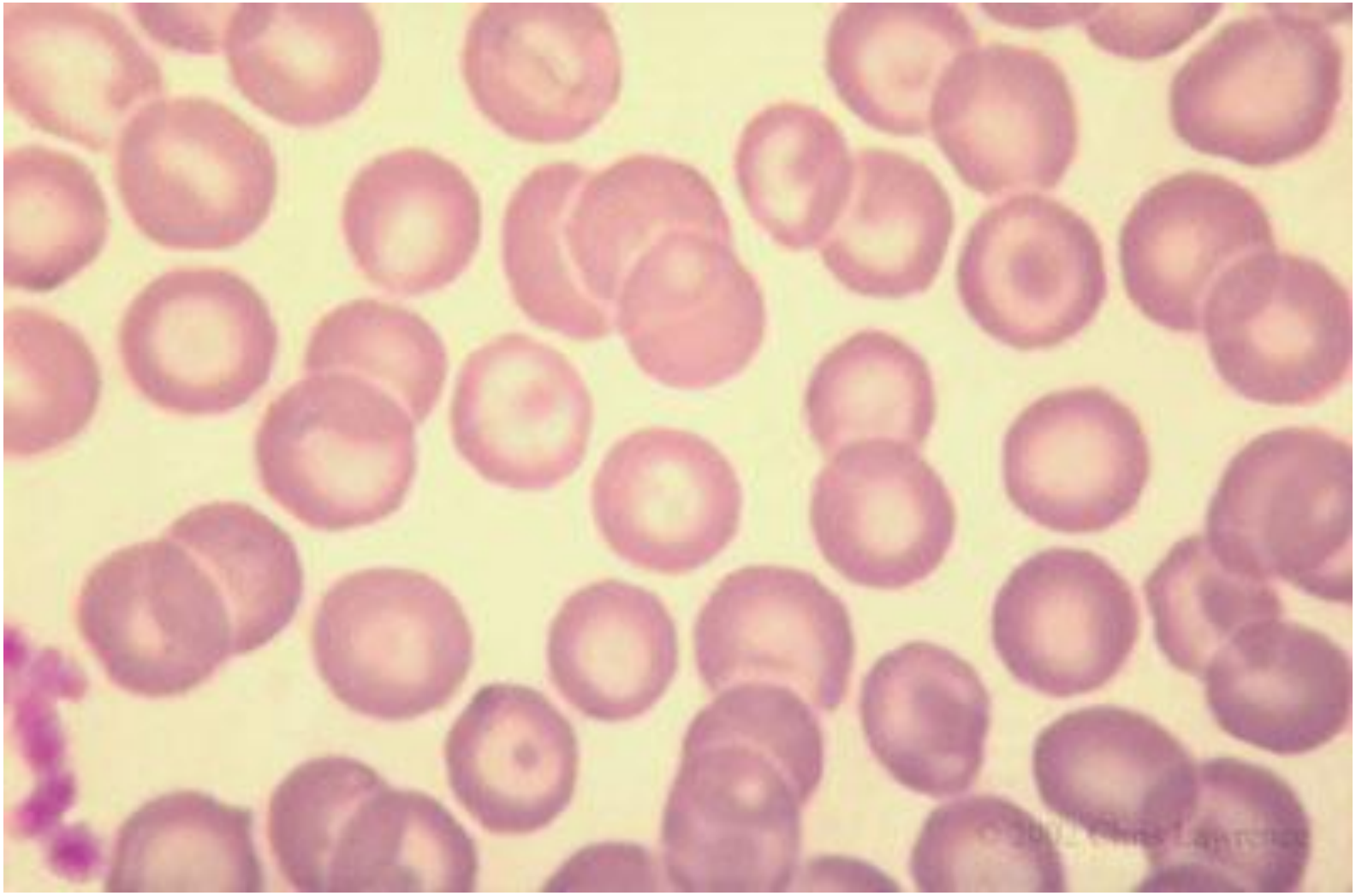

- Monomorphic hypochromic microcytic anemia with target cells, seen in thalassemia

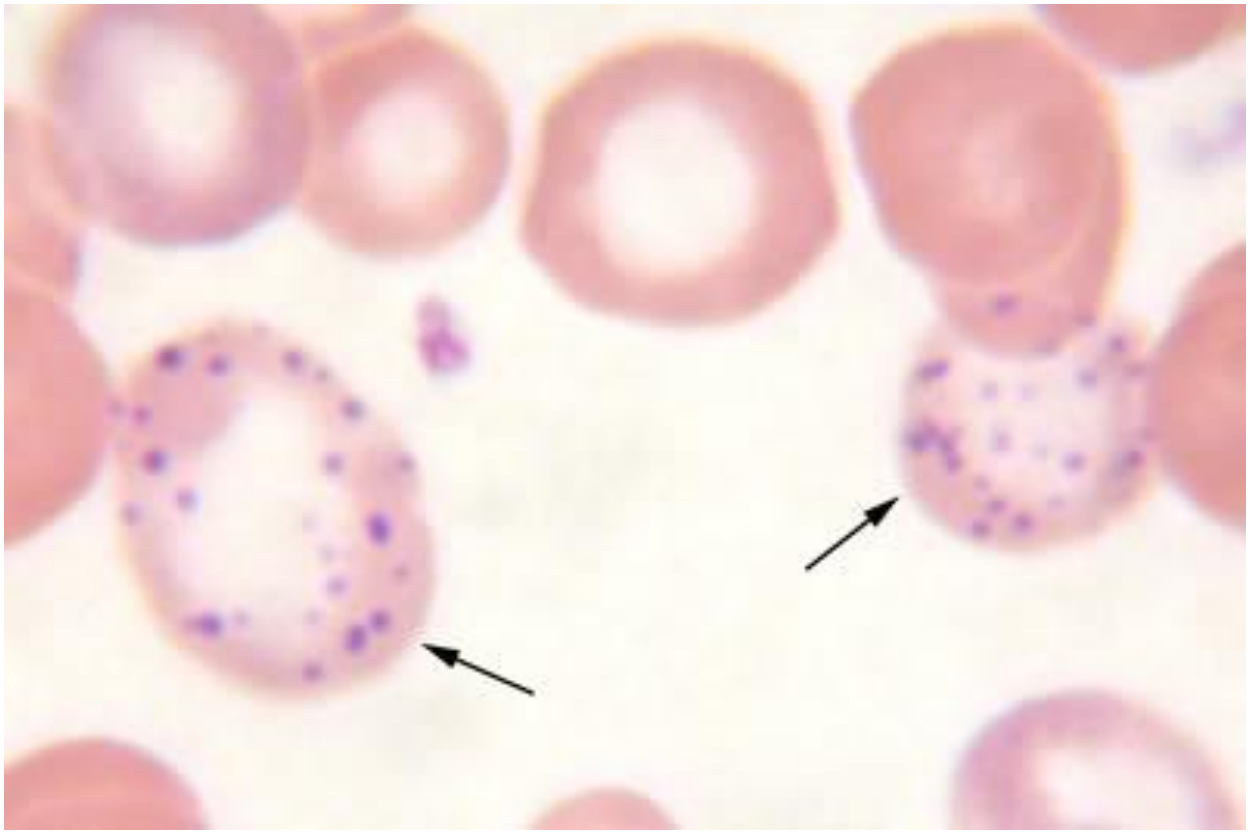

- Basophilic stippling: aggregates of ribosomes, appear as fine blue inclusions in RBCs

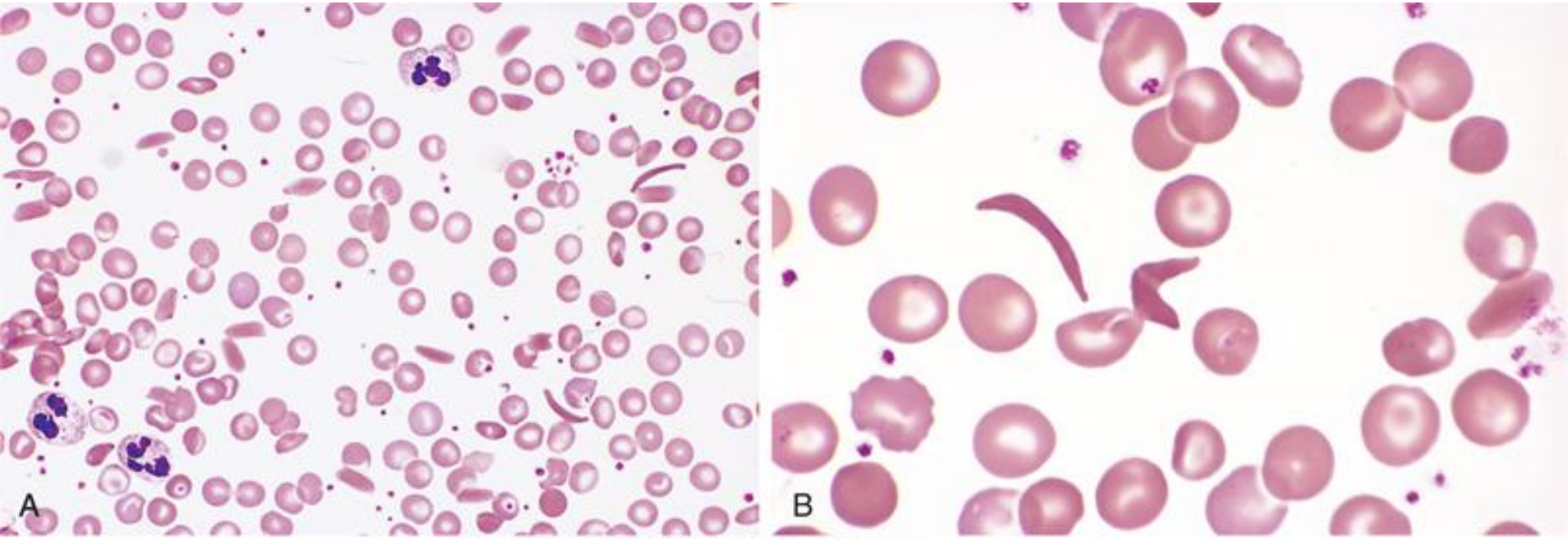

- Sickle cell anemia: numerous sickle cells and target cells

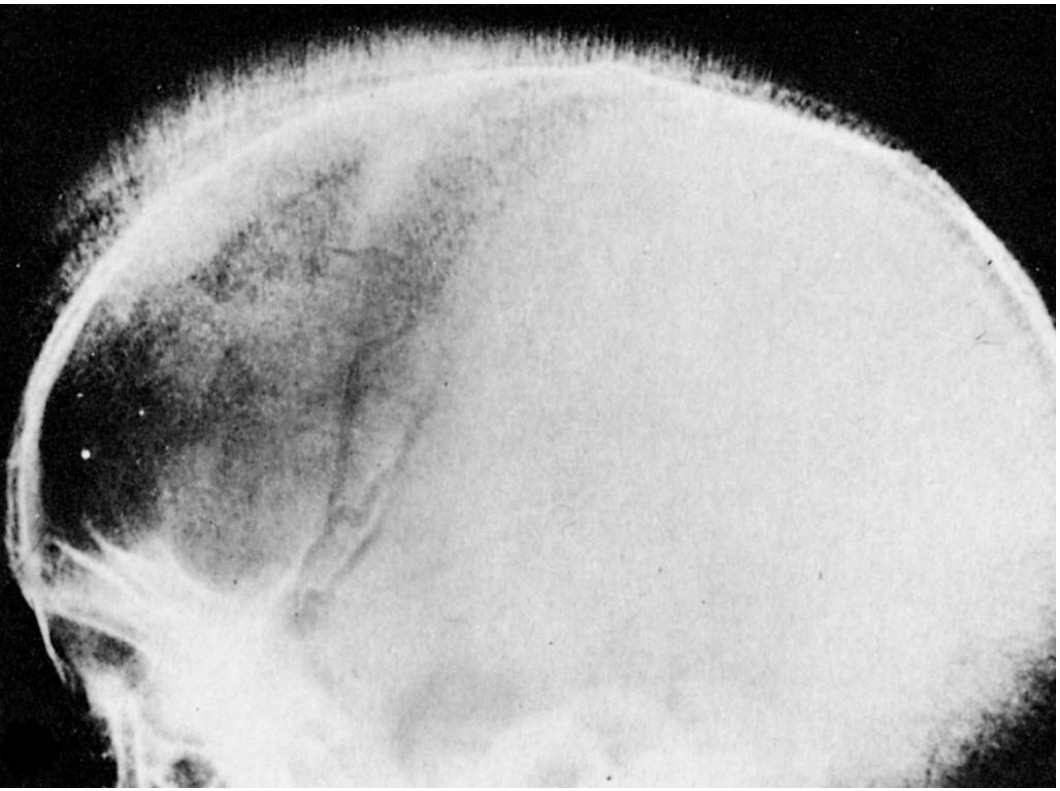

- Crew-cut appearance of skull of X ray: secondary to marked erythropoiesis in sickle cell anemia and B-thal

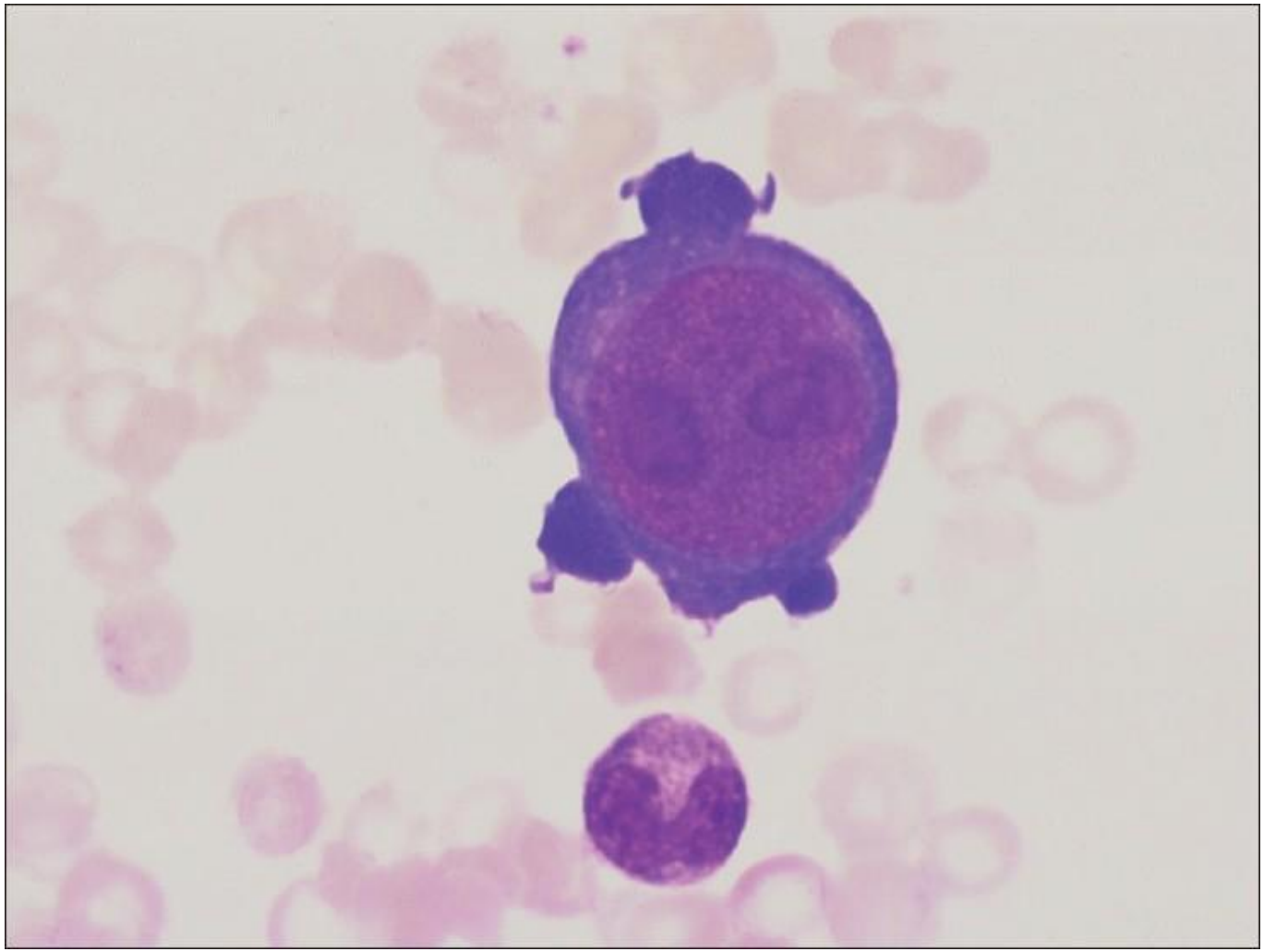

- Aplastic crisis: pronormoblast shows nuclear inclusions

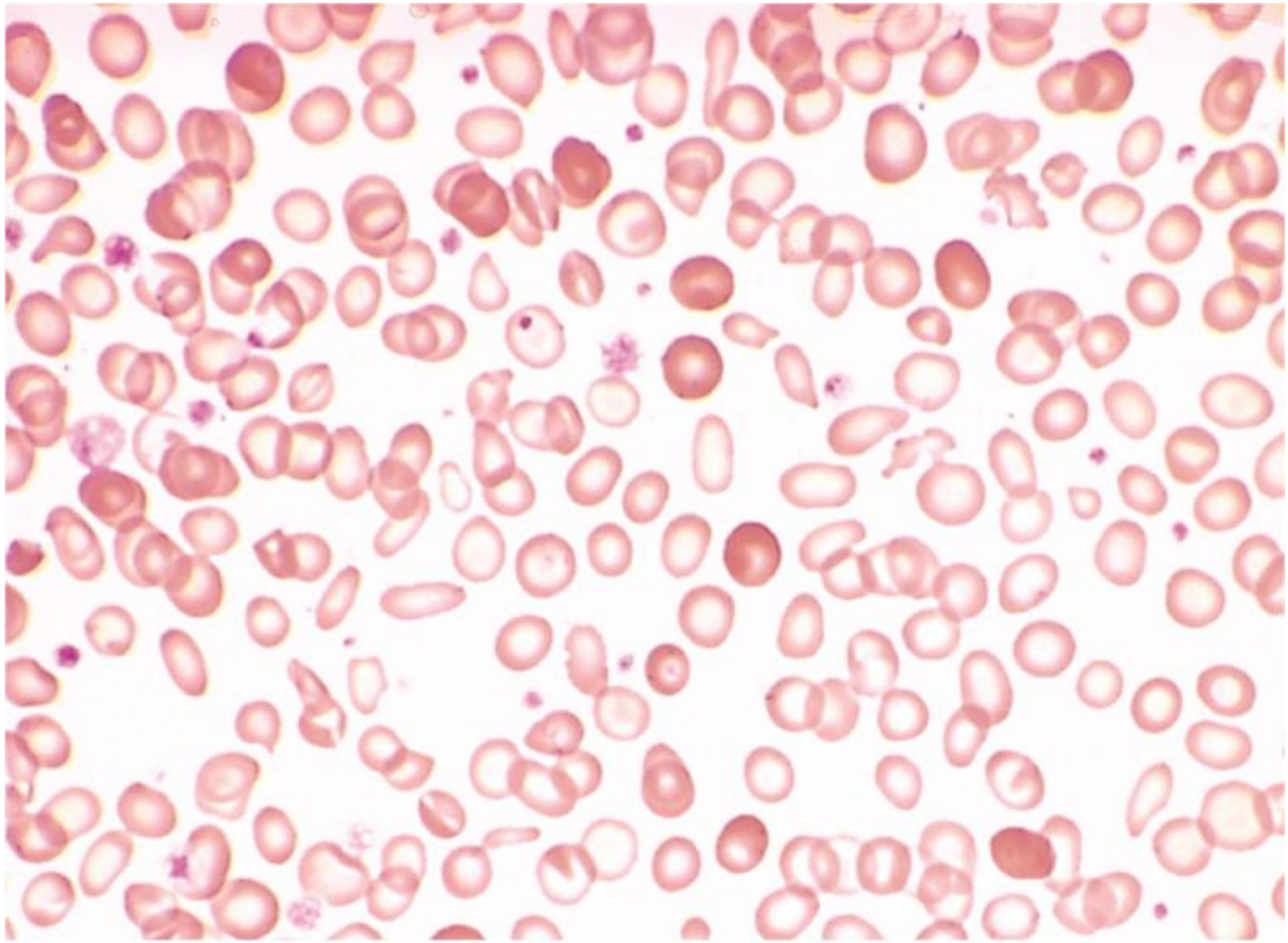

- Iron deficiency anemia: hypochromic mircocytic RBCs, poikelocytosis, target cells

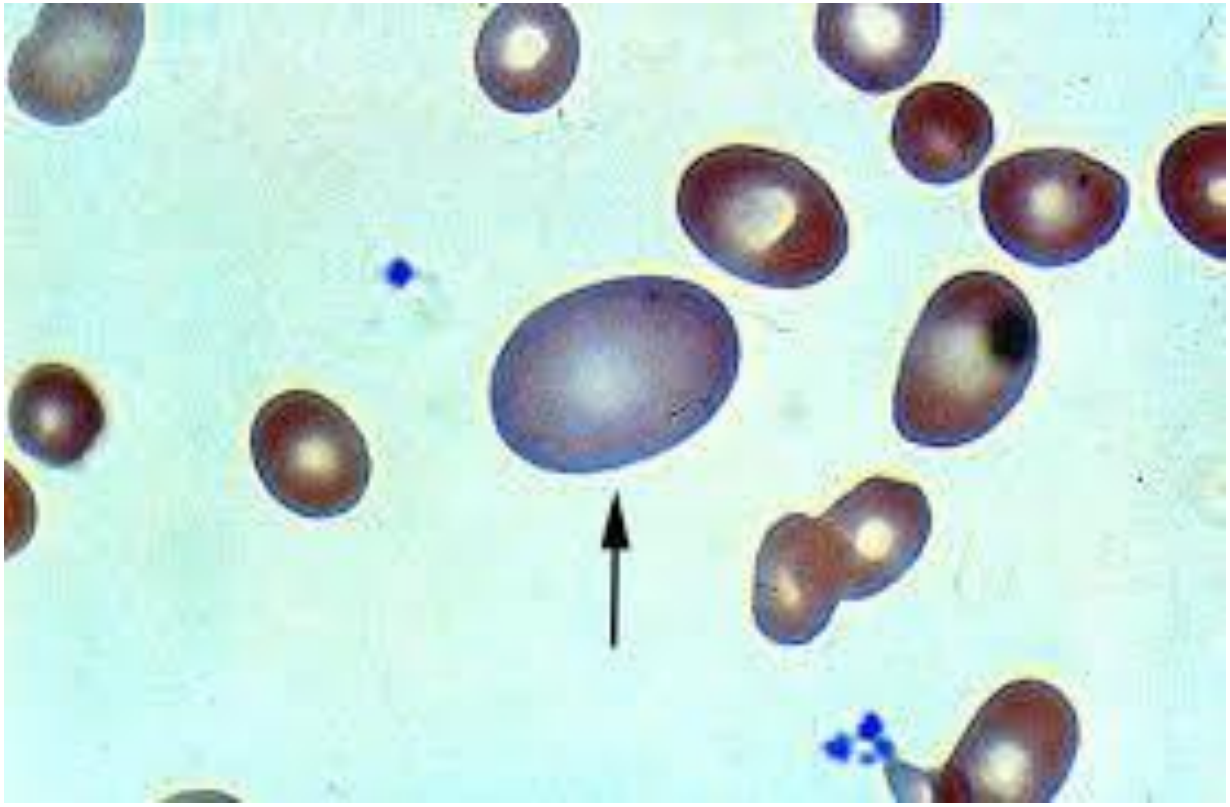

- PB: large ovalocyte is specific for megaloblastic anemia

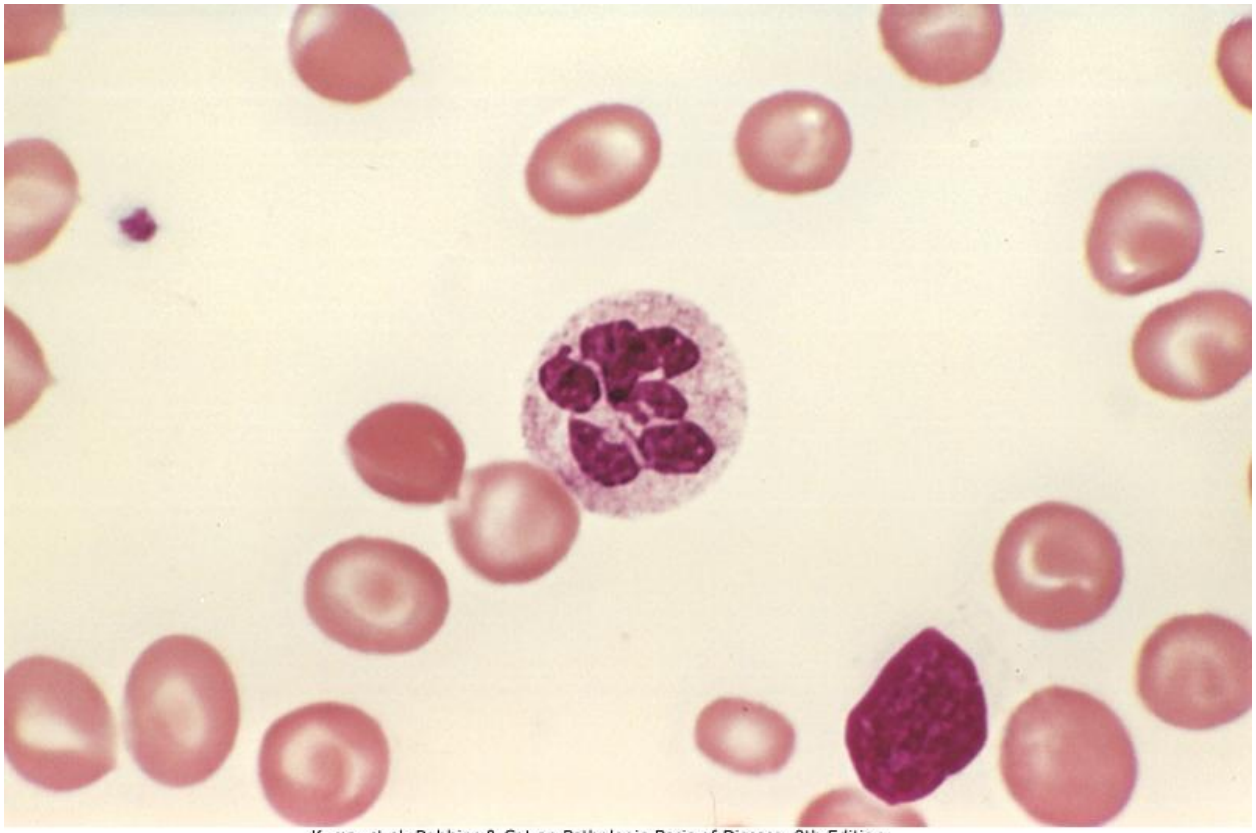

- Megaloblastic anemia: hypersegmented neutrophil

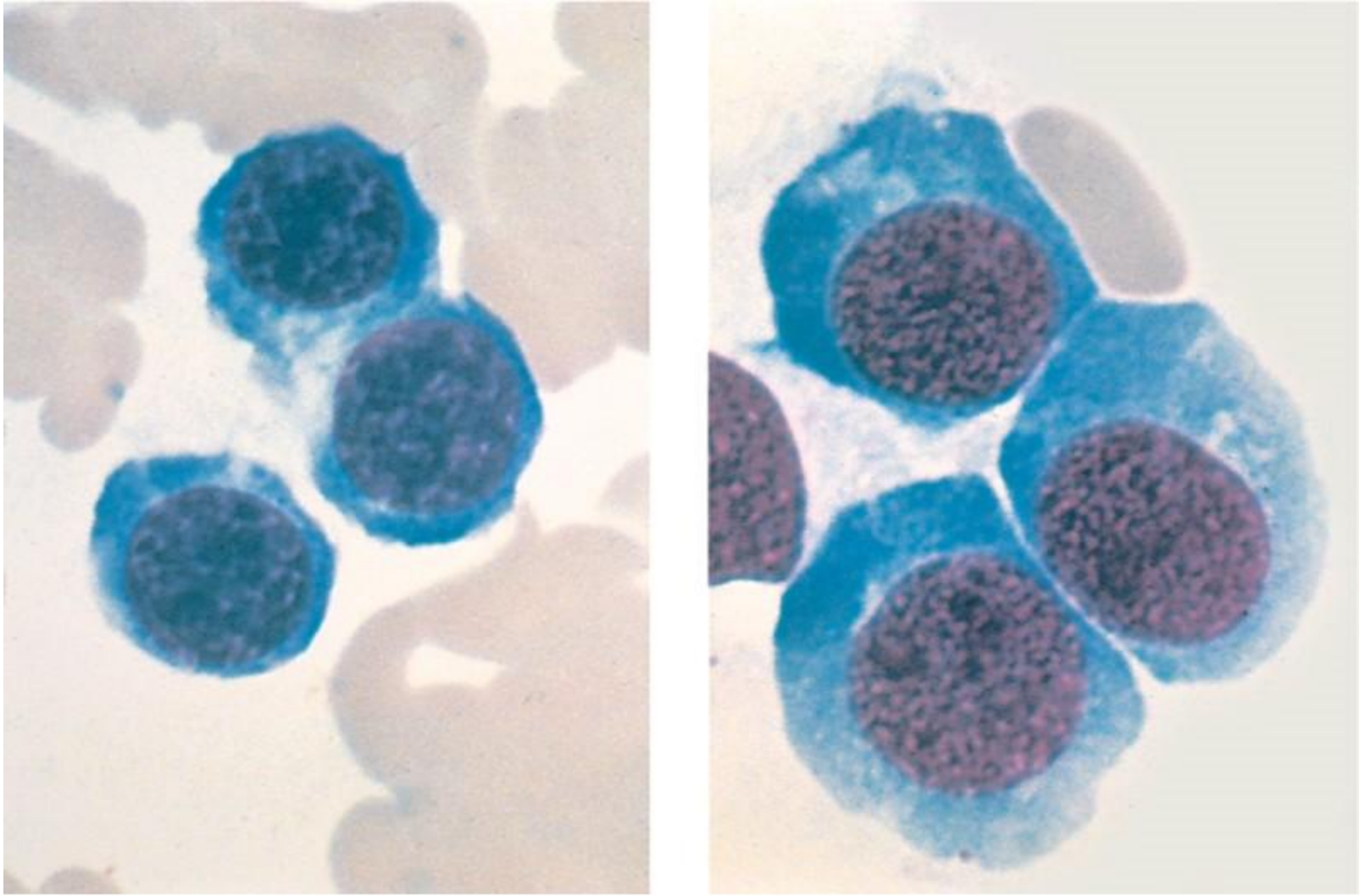

- Comparison of normoblasts (*left*) and megaloblasts (*right*). The megaloblasts are larger, have relatively immature nuclei with finely reticulated chromatin, and have an abundant basophilic cytoplasm

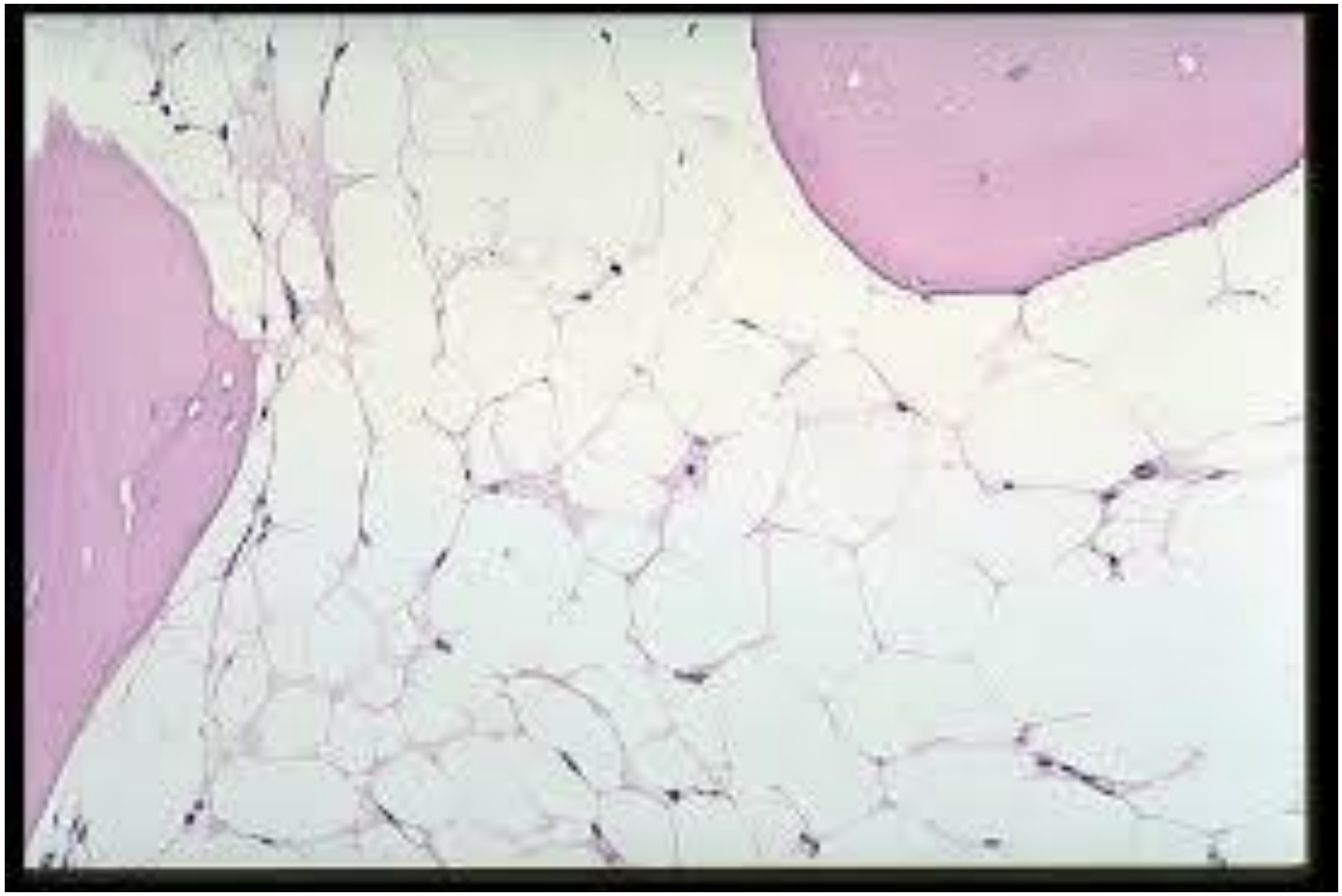

- Aplastic anemia: bone marrow is composed of adipose tissue with very scarce hematopoietic cells

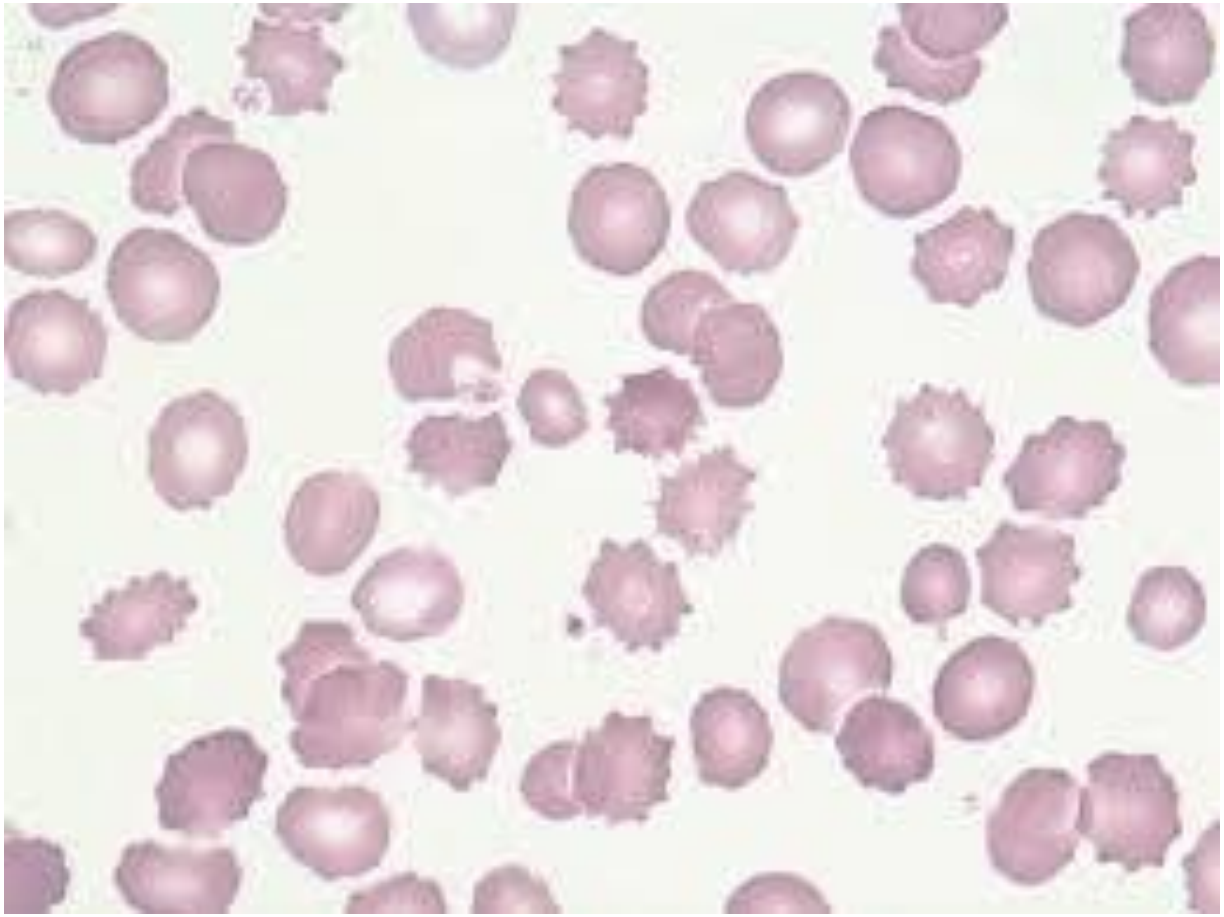

- Echinocytes: circumferential small cytoplasmic projections, seen in uremia

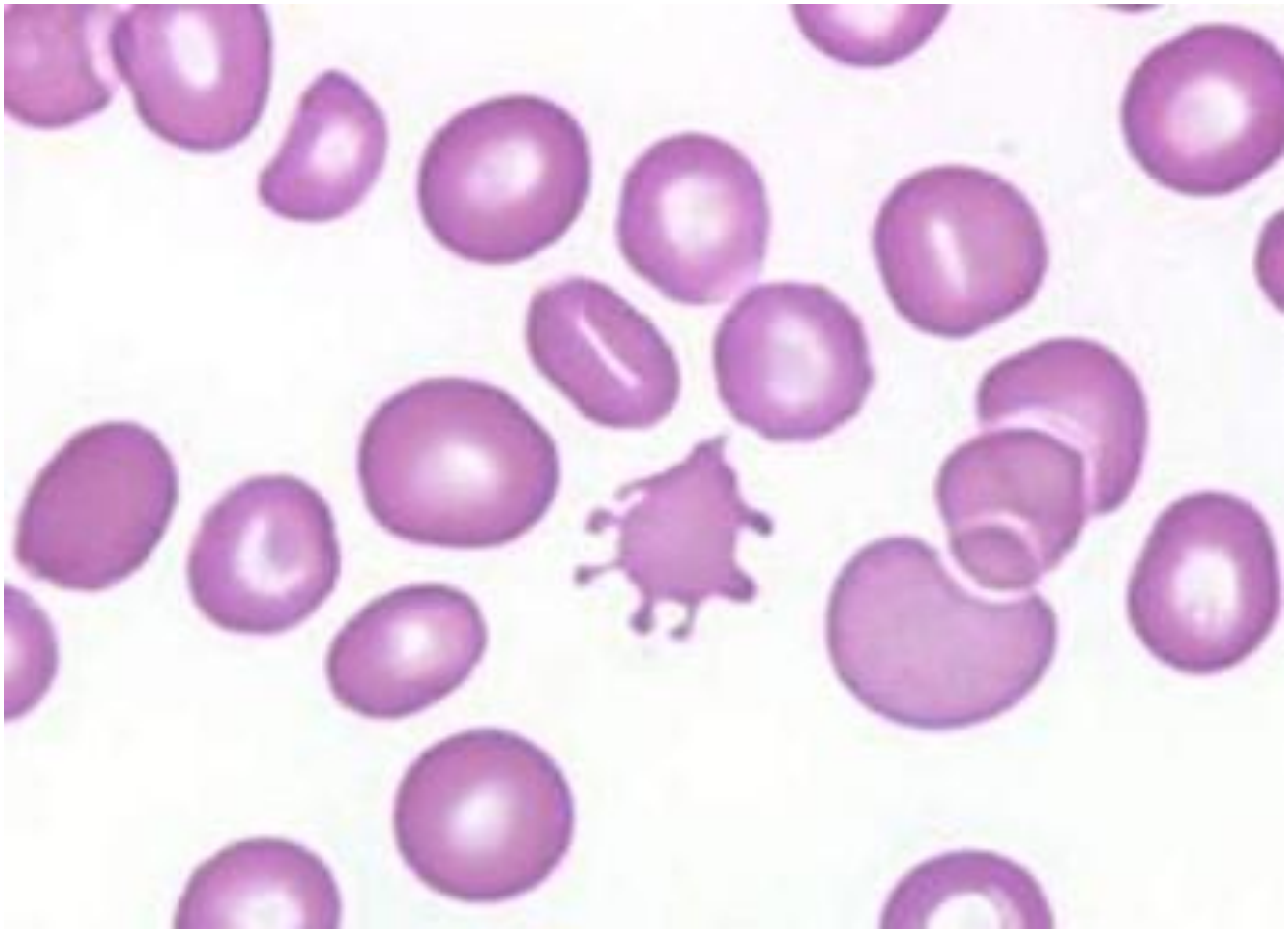

- Acanthocyte: long membrane projections