Pathology of The Stomach

(Edited Slides)

- Before discussing stomach diseases, it's important to mention that the most obvious manifestation is usually **abdominal pain**, and especially, epigastric pain. The patient usually bends down and forward to try to ease the pain.
- Stomach diseases can affect any age group.
- It's also important to differentiate between normal and abnormal endoscopic images of the gastric pylorus and antrum. See next 2 slides.

NORMAL

GASTRIC PYLORUS & ANTRUM

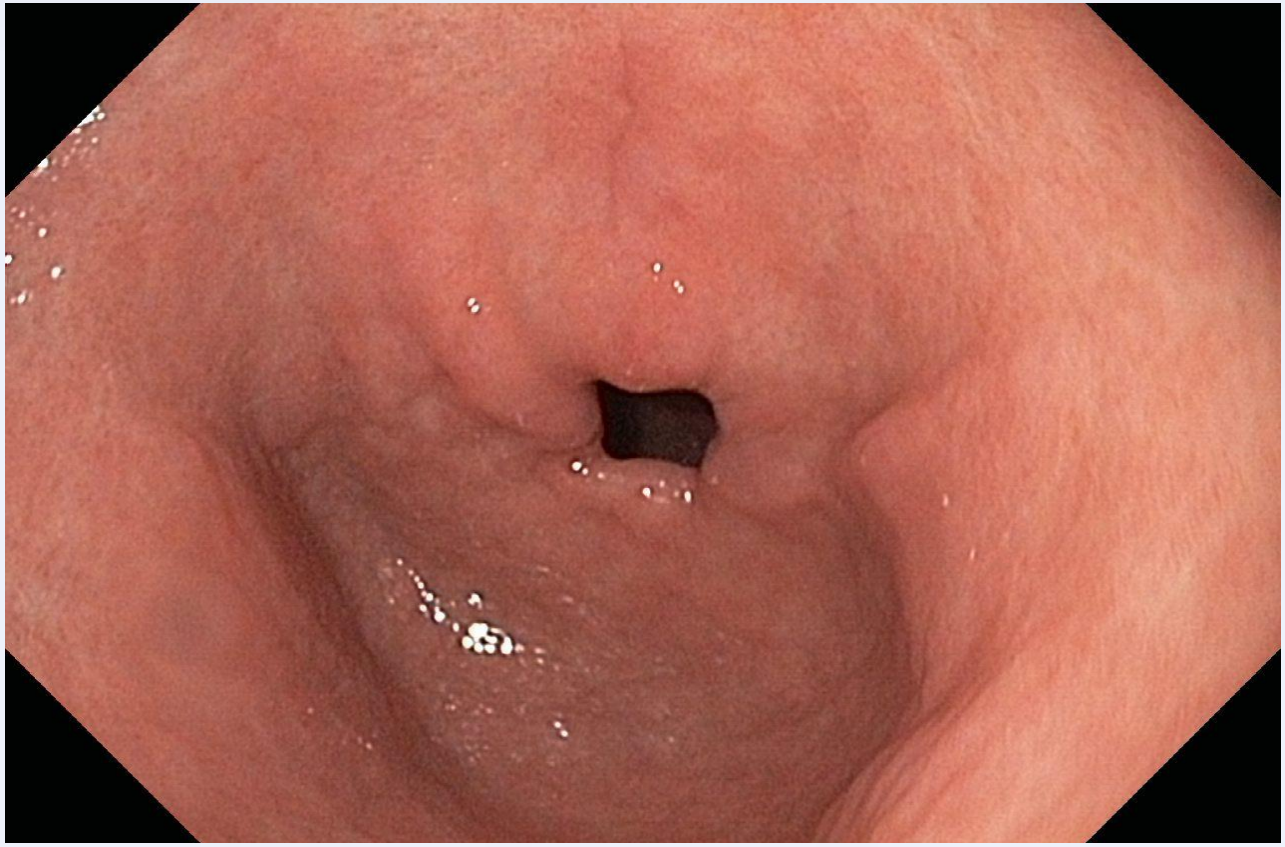

The mucosa of the stomach is smooth, shiny, and the color is homogenous.

ABNORMAL

GASTRIC PYLORUS & ANTRUM

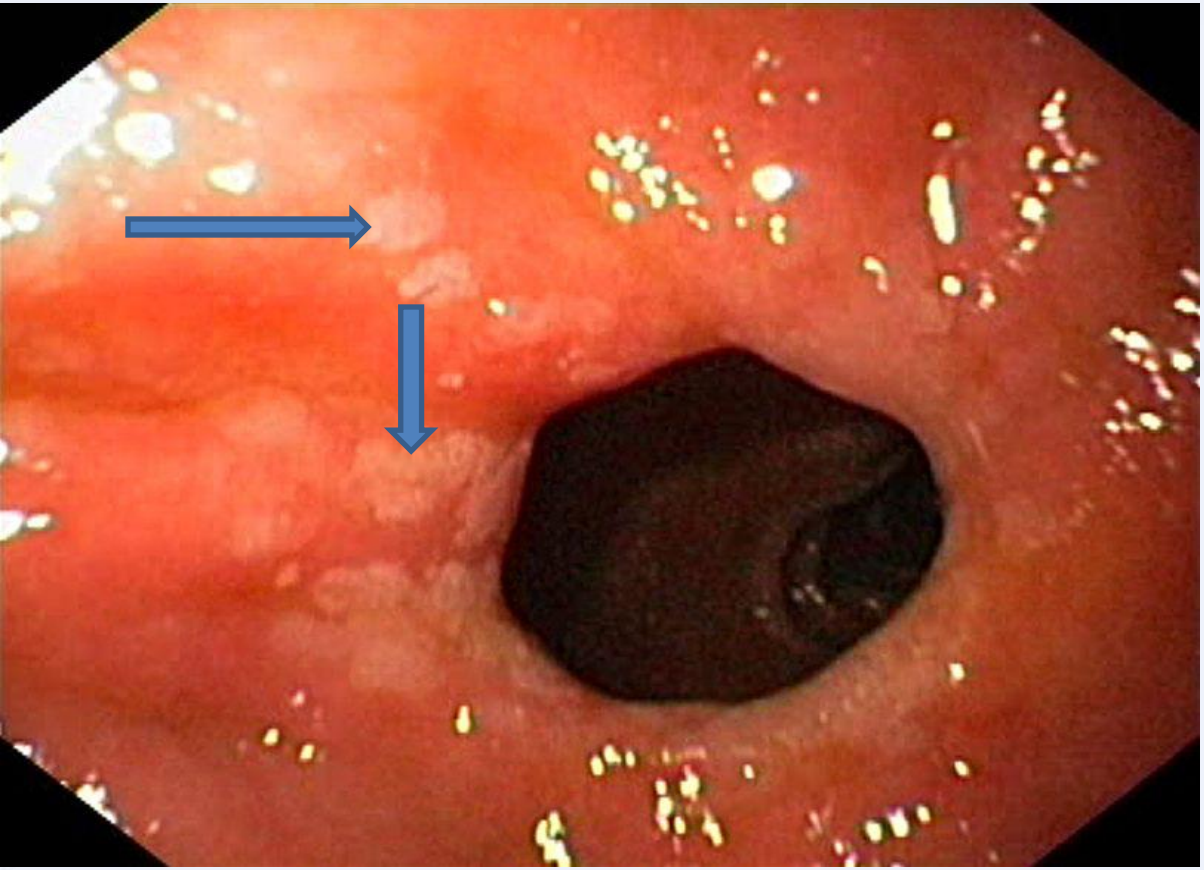

- The mucosa is more reddish in color that the normal case.
- There are white or pale spots that might be the result of inflammation.
- We might find ulcers.

Pathologic conditions of the Stomach

- Chronic Gastritis
- Acute Gastritis
- Gastric Ulcerations
- Gastric Tumors

1. Chronic Gastritis

- Gastritis means gastric **inflammation**.
- Note: Inflammation of gastric mucosa is of two types; acute and chronic. In acute gastritis, the predisposing factors are well known and taking history will usually reveal the cause. On the other hand, chronic gastritis is more important due to different reasons:
  - Chronic gastritis is one of the common diseases to encounter in clinical practice.
  - It must be treated because it can develop into malignancy.
  - It can end up with atrophy due to continuous inflammation of the mucosa. This atrophy can lead to malignancy.

- Chronic gastritis is the presence of **chronic inflammatory changes** in the mucosa leading eventually to mucosal atrophy and epithelial metaplasia.
- All age groups are affected.
- In the Western world the prevalence of chronic gastritis is **higher than 50%** in the later decades of life.

Pathogenesis

- **H. pylori** is the most common cause.

  The stomach was thought to be sterile but then it was found out that H. pylori can live in the stomach.
- This organism is a worldwide pathogen that has the highest infection rates in developing countries.

  Recurrent infection can occur, that's why infection should be treated.
- Prevalence rates approaching 50% is seen in American adults older than age 50.
- In areas where the infection is endemic it is acquired in childhood and persists for decades.
- **Most individuals with the infection also have the associated gastritis but are asymptomatic.**

- Robin Warren, a pathologist, and Barry Marshall, a medical student at the time of the discovery, received the 2005 Nobel prize in Medicine for their identification in 1982 of *H. pylori*, originally called *Campylobacter.*

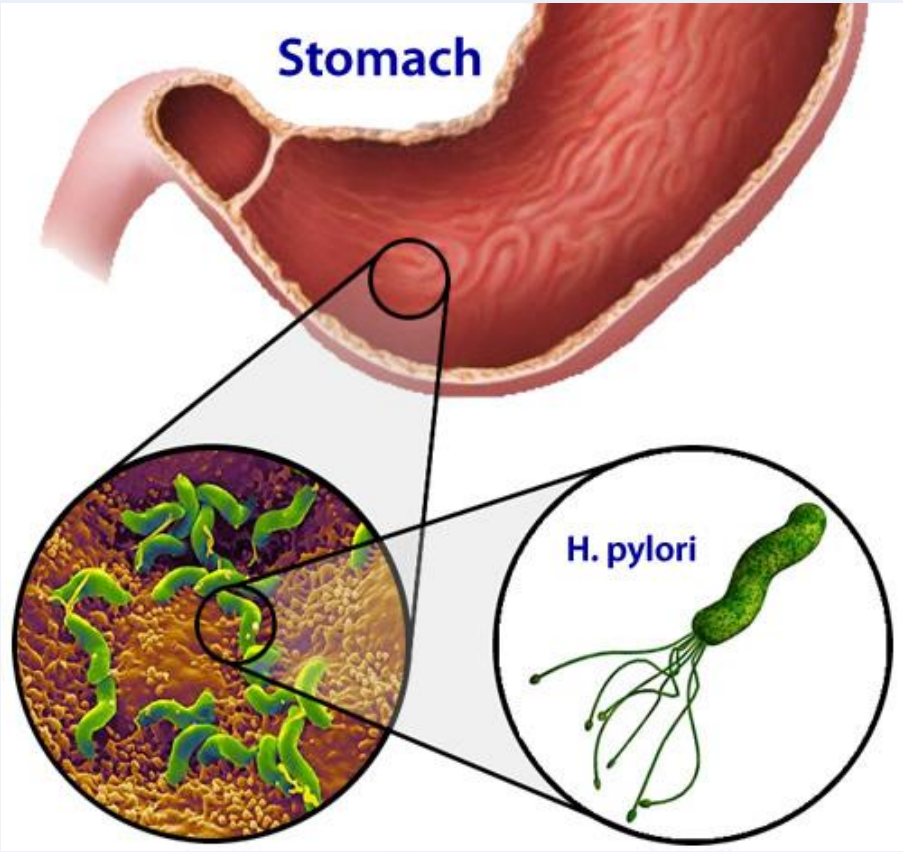

Types of chronic gastritis

Antral- type

The antrum is the main site affected

Pangastritis

Antrum and body are affected

Autoimmune

Mainly in the body

Both, antral type and pangastritis are mainly caused by H. pylori. But different mechanisms cause the autoimmune type.

- **H. pylori** is a noninvasive, non-spore-forming, S-shaped gram-negative rod measuring approximately 3.5 µm × 0.5 µm.
- **Luckily, it can be seen in biopsies under usual microscopic examination without the need of culture nor staining.**
- **H & E, as well as urase test through endoscopy, can reveal the presence of H. pylori.**

- After initial exposure to H. pylori, gastritis may develop in two patterns:

(1) an antral-type with high acid production and higher risk for the development of duodenal ulcer

(2) a pangastritis with multifocal mucosal atrophy with low acid secretion and **increased risk for adenocarcinoma.**

- Chronic gastritis due to *H. pylori* usually **improves symptomatically** when treated with antibiotics and proton pump inhibitors.
- Improvement in the underlying chronic gastritis may take much longer.
- Relapses are associated with reappearance of this organism.

(3) Autoimmune gastritis

- 10% of cases of chronic gastritis (not common)
- results from the **production of autoAbs to the gastric gland parietal cells, in particular to the acid-producing enzyme H+,K+-ATPase**.
- The autoimmune injury leads to gland destruction and mucosal atrophy with concomitant loss of acid and intrinsic factor production.
- The resultant deficiency of intrinsic factor leads to ***pernicious anemia***.

  Parietal cells produce HCL and intrinsic factor. They are mainly found in the body. When destroyed, we expect megaloplastic "pernicious" anemia due to B12 deficiency as well as gastritis.
- This form of gastritis is seen most often in Scandinavia in association with other autoimmune disorders such as *Hashimoto thyroiditis* and *Addison disease.*

Morphology of Chronic Gastritis

- The **inflammatory changes** consist of a **lymphocytic** and plasma cell infiltrate in the lamina propria
- Occasionally neutrophilic inflammation of the neck region of the mucosal pits.
- The inflammation may be accompanied by variable gland loss and mucosal **atrophy.**
- H. pylori organisms, when present, are found nestled within the mucus layer overlying the superficial mucosal epithelium.

H. Pylori organisms are not invasive, we don't expect them to invade epithelial cells. Usually, they are present on the surface of the mucosa within the mucus.

- In the autoimmune variant, **loss of parietal cells is particularly prominent.**

- **Intestinal metaplasia** refers to the replacement of gastric epithelium with columnar and goblet cells of intestinal variety.
- This is significant, because gastrointestinal-type carcinomas seem to arise from **dysplasia** of this metaplastic epithelium.

  → **H.pylori is related to Adenocarcinoma of the stomach.**
- *H. pylori*-induced proliferation of **lymphoid tissue** within the gastric mucosa has been implicated as a precursor of gastric lymphoma.

  → **H.pylori is related to Lymphoma of the stomach.**

Chronic gastritis

intestinal metaplasia (you can also see goblet cells)

inflammation of the lamina propria containing lymphocytes and plasma cells

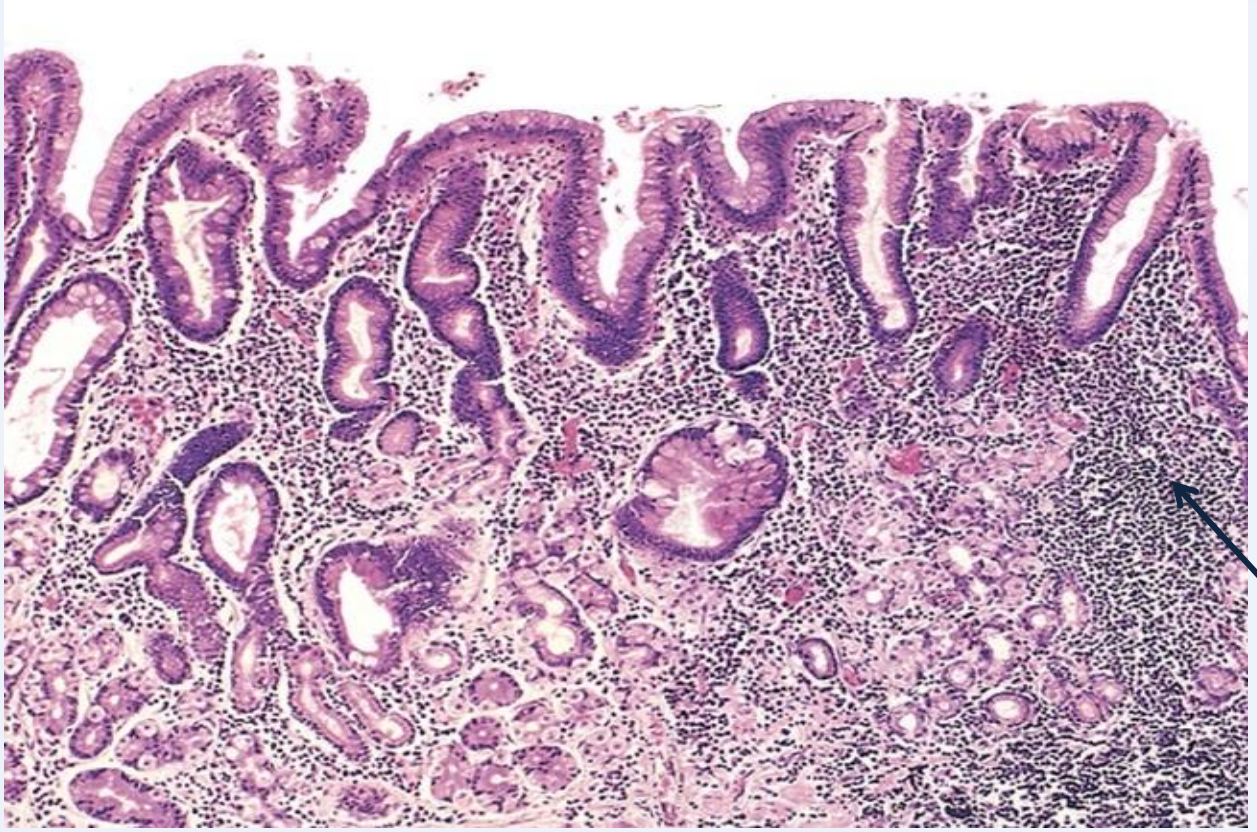

- **Lymphocytes are small cells compared to epithelial cells**
- **The nucleus occupies most of the cell and the cytoplasm appears as very thin rim around it.**
- **They appear as small black dots in the mucosa.**

CHRONIC GASTRITIS

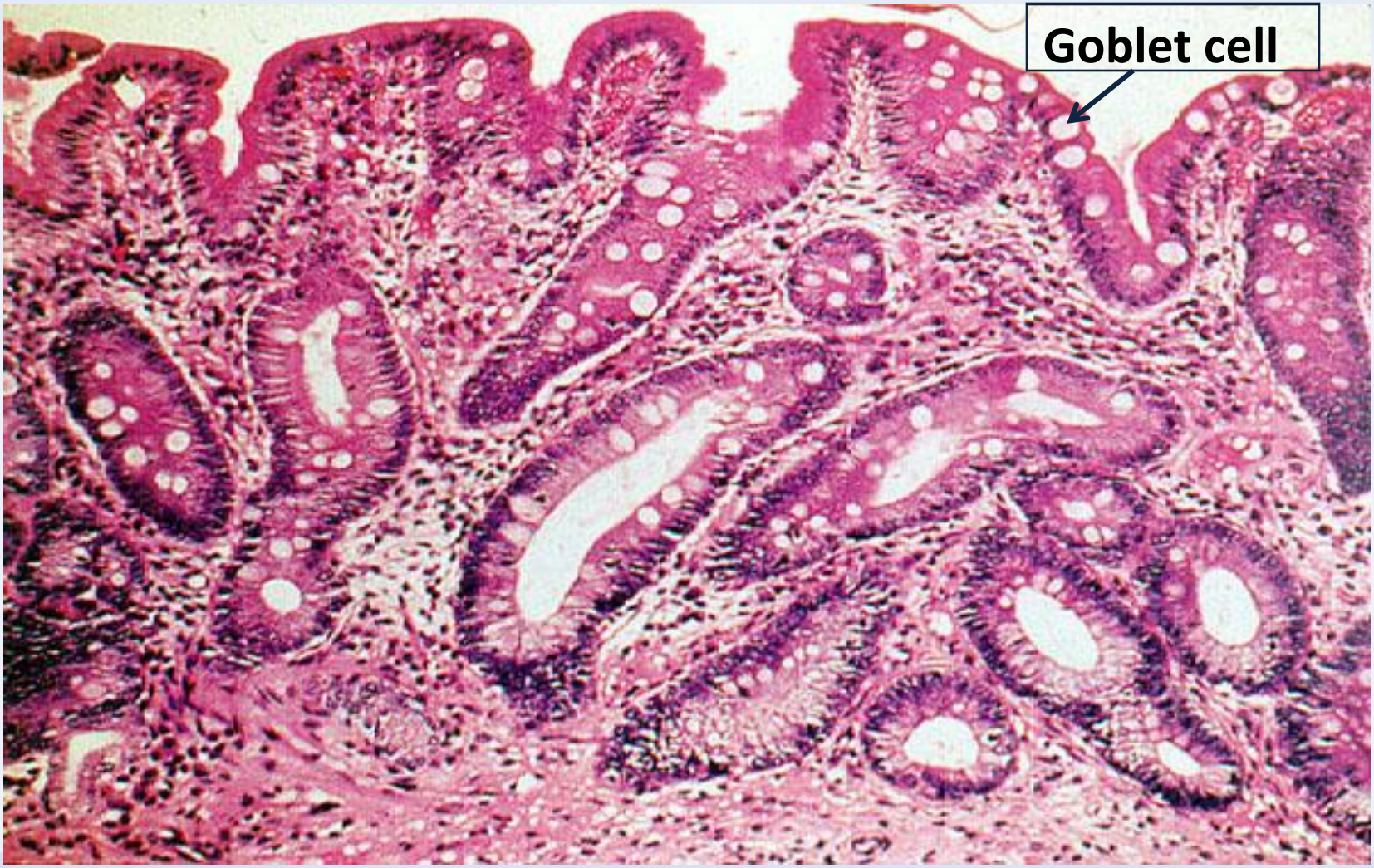

Helicobacter pylori gastritis.

numerous darkly stained *Helicobacter* organisms along the luminal surface of the gastric epithelial cells (silver stain)

<u>There is no tissue invasion by bacteria</u>

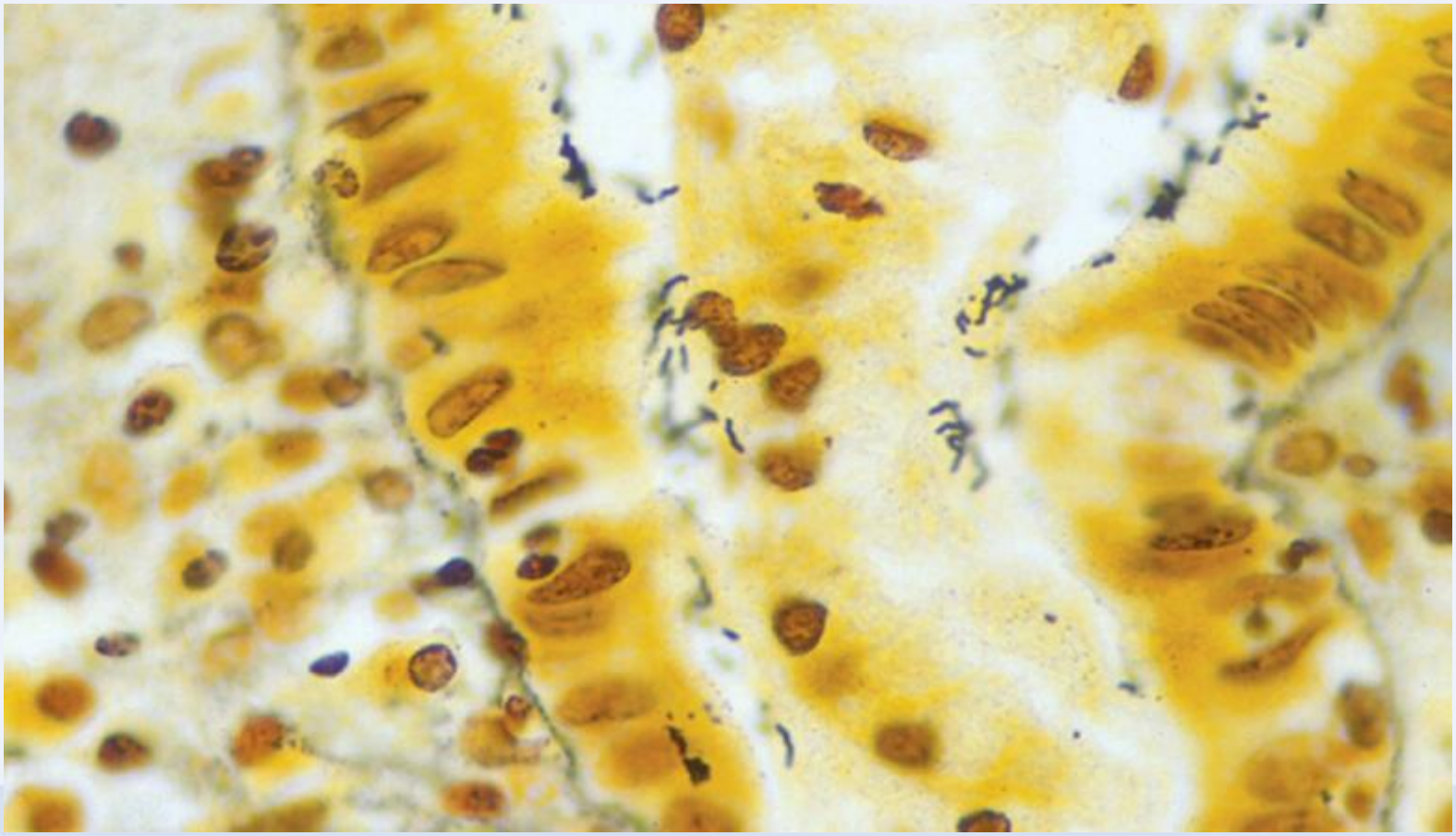

Clinical Features

- The patient may be Asymptomatic
- Upper abdominal discomfort and nausea and vomiting.
- Hypochlorhydria or achlorhydria
- Hypergastrinemia
- Individuals with chronic gastritis from H.pylori infection may be hypochlorhydric, but because parietal cells are never completely destroyed, these persons do not develop achlorhydria or pernicious anemia.
- Serum gastrin levels are either normal or only modestly elevated.

- Most important is the risk of the development of **peptic ulcer** and **gastric carcinoma**.
- Most individuals with a peptic ulcer whether duodenal or gastric have *H. pylori* infection.
- The long-term risk of gastric carcinoma for persons with *H. pylori*-associated chronic gastritis is increased about 5X.
- For autoimmune gastritis, the risk for cancer is in the range of 2-4% of affected individuals.

Clinical case #1...(Chronic Gastritis)

- A 35 yr old man presents with a month history of **burning epigastric pain** that occurs between meals.
- The pain can be relieved by food or antiacids.
- He denies taking aspirin or NSAID.
- Lab tests reveals **anemia**.
- Endoscopy shows **congested gastric antral mucosa**.
- Your diagnosis is ? **Chronic Gastritis**

2. Acute Gastritis

- *It is an acute mucosal inflammatory process, usually of a transient nature.*
- The inflammation may be accompanied by hemorrhage into the mucosa and in more severe circumstances by sloughing of the superficial mucosal epithelium (*erosion*).

  (acute gastritis may be associated with loss of epithelium leading to the formation of erosions which are superficial ulcers seen in acute gastritis, they develop due to loss of mucosa)
- This severe erosive form of the disease is an important cause of **acute GI bleeding**.

Pathogenesis

is frequently associated with: (الأسباب)

1. Heavy use of nonsteroidal anti-inflammatory drugs **(NSAIDs)**, particularly aspirin
2. Excessive **alcohol** consumption
3. Heavy **smoking**
4. Treatment with cancer **chemotherapeutic drugs**
   ---
5. Uremia
   ---
6. **S**ystemic infections (e.g., salmonellosis)
7. **S**evere **s**tress (e.g., trauma, burns, surgery)
8. I**s**chemia and shock
9. **S**uicide attempts with acids and alkali
   ---
10. Mechanical trauma (e.g., nasogastric intubation)
11. Reflux of bilious material after distal gastrectomy

Clinical Features

- **The patient might be Asymptomatic**
- **Variable epigastric pain with nausea and vomiting**
- **Overt hematemesis, melena, and potentially fatal blood loss.**
- **Hematemesis, *particularly in alcoholics.***
- **25% of persons who take daily aspirin for rheumatoid arthritis develop acute gastritis at some time in their course, many with occult or overt bleeding.**
- **The risk of gastric bleeding from NSAID-induced gastritis is dose related.**

3. Gastric Ulceration

nowadays, it's treated better and it's less common

- ***Ulcers*** of the alimentary tract are defined histologically as a breach in the mucosa that extends through the muscularis mucosae into the submucosa or deeper.
- ***Erosions*** is a breach in the epithelium of the mucosa only. **(superficial ulcers that involve the loss of superficial epithelium only)**
- Erosions may heal within days whereas healing of ulcers takes much longer.
- Ulcers may occur anywhere in the alimentary tract
- The most common sites of peptic ulcers are in the duodenum and stomach

Extra slide

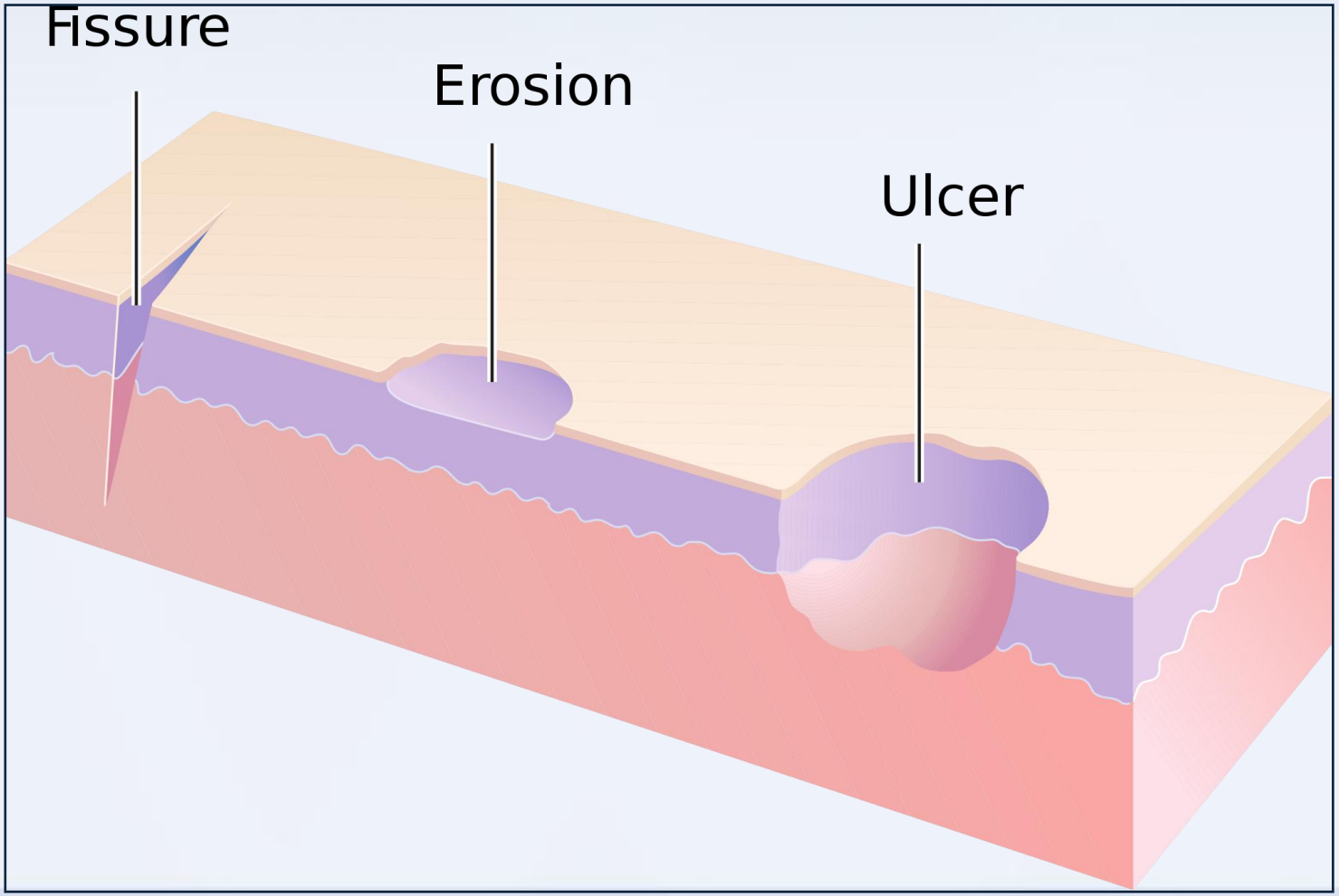

(A) Peptic Ulcers

- **chronic**, most often solitary, lesions that occur in any portion of the gastrointestinal tract exposed to the aggressive action of acidic peptic juices.
- 98% of peptic ulcers are either in the first portion of the duodenum or in the stomach (ratio of about 4:1).

  → **Peptic ulcer is more common to occur in the first part of the duodenum that in the stomach.**

Epidemiology

- In the American population 6-14% of males and 2- 6% of females have peptic ulcers.
- Middle-aged to older adults.
- They often appear without obvious precipitating influences and may then heal after a period of weeks to months of active disease.
- Even with healing peptic ulcers can recur because of recurrent infection with H. pylori

- The M:F ratio for duodenal ulcers is about 3:1.
- For both men and women in the United States the lifetime risk of developing peptic ulcer disease is about 10%.

- <u>Genetic or racial influences seem to have little or no role in the causation of peptic ulcers.</u>
- Duodenal ulcers are more frequent in persons with:

1. alcoholic cirrhosis
2. chronic obstructive pulmonary disease
3. chronic renal failure
4. hyperparathyroidism
5. Hypercalcemia → **increases acid secretion in stomach.**

Pathogenesis

- Two conditions are key for the development of peptic ulcers:

(1) *H. pylori* infection which has a strong causal relationship with peptic ulcer development

(2) mucosal exposure to gastric acid and pepsin, **which is influenced by two factors:**

A. **Acid hyper-secretion (increased acidity)**
B. **Loss of defense mechanisms of the gastric mucosa against gastric secretions**

Causes of peptic ulceration

1-H.pylori infection

2-NSAID

3-Gastric hyperacidity

4-Cigarette smoking

5-Corticosteroids in high dose

6-Personality and psychological stress

1-H.pylori infection

- ***H. pylori*** **infection is the most important condition in the pathogenesis of peptic ulcer.**
- **The infection is present in 70-90% of persons with duodenal ulcers and in about 70% of those with gastric ulcers.**
- **Antibiotic treatment of *H. pylori* infection promotes healing of ulcers and tends to prevent their recurrence.**

- Although *H. pylori* does not invade the tissues but **it induces an intense inflammatory and immune response.**

- There is increased production of proinflammatory cytokines such as **interleukin (IL)-1**, **IL-6**, **TNF** most notably, **IL-8**.
- IL-8 is produced by the mucosal epithelial cells, and it recruits and activates neutrophils.
- Several bacterial gene products are involved in causing epithelial cell injury and induction of inflammation.

- Epithelial injury is mostly caused by a **vacuolating toxin called VacA**, which is regulated by the **cytotoxin-associated gene A (*CagA*).**

  This toxin can produce inflammatory mediators in the mucosa to initiate inflammation.

- This gene is a component of the *Cag* pathogenicity island, a cluster of 29 genes, some of which encode pro-inflammatory proteins.

- H. pylori secretes an enzyme(**urease**) that breaks down urea to form toxic compounds such as ammonium chloride and monochloramine.

- The organisms also elaborate **phospholipases** that damage surface epithelial cells.
- Bacterial **proteases and phospholipases** break down the glycoprotein-lipid complexes in the gastric mucus thus weakening the first line of mucosal defense.
- ***H. pylori* enhances gastric acid secretion and impairs duodenal bicarbonate production thus reducing luminal pH in the duodenum**.
- Gastric metaplasia in the first part of the duodenum.
- Such metaplastic foci provide areas for *H. pylori* colonization.

H.Pylori and gastric lymphoma:

- Several *H. pylori* proteins are immunogenic, and they evoke a robust immune response in the mucosa.
- Both activated T cells and B cells can be seen in chronic gastritis caused by *H. pylori.*
- The B lymphocytes aggregate to form follicles.
- T-cell-driven activation of B cells may be involved in the pathogenesis of gastric lymphomas .

- Only 10-20% of individuals worldwide who are infected with *H.pylori* actually develop peptic ulcer.
- Perhaps there are interactions between *H. pylori* and the mucosa that occur only in some individuals.
- Strains producing VacA and CagA cause more intense tissue inflammation, more severe epithelial damage, and higher cytokine production.

2-NSAID -especially in elderly-

- **NSAIDs are the major cause of peptic ulcer disease in persons who do not have H. pylori infection.**
- **The gastroduodenal effects of NSAIDs <u>range</u> from acute erosive gastritis and acute gastric ulceration to peptic ulceration in 1-3% of users.**

- **Risk factors for NSAID-induced gastroduodenal toxicity are:**

1. **increasing age**
2. **higher dose**
3. **prolonged usage.**

Why can NSAIDs cause peptic ulcer?

- **Suppression of mucosal prostaglandin synthesis**, which increases secretion of hydrochloric acid and reduces bicarbonate and mucin production.
- **Loss of mucin** degrades the mucosal barrier that normally prevents acid from reaching the epithelium.
- **Synthesis of glutathione**(free-radical scavenger) **is reduced**.

3-Gastric hyperacidity

Excess production of gastric acid from a tumor in individuals with the ***Zollinger-Ellison syndrome*** causes multiple peptic ulcerations in the stomach, duodenum, and even the jejunum.

4-Cigarette smoking impairs mucosal blood flow and healing.

- Alcohol has not been proved to directly cause peptic ulceration, but alcoholic cirrhosis is associated with an increased incidence of peptic ulcers.

5-Corticosteroids in high dose and with repeated use promote ulcer formation.

6-Personality and psychological stress are important contributing variables.

Peptic ulcer of the duodenum

The ulcer is small with a sharply punched-out appearance

<u>The margins are not elevated. The ulcer base is clean</u>

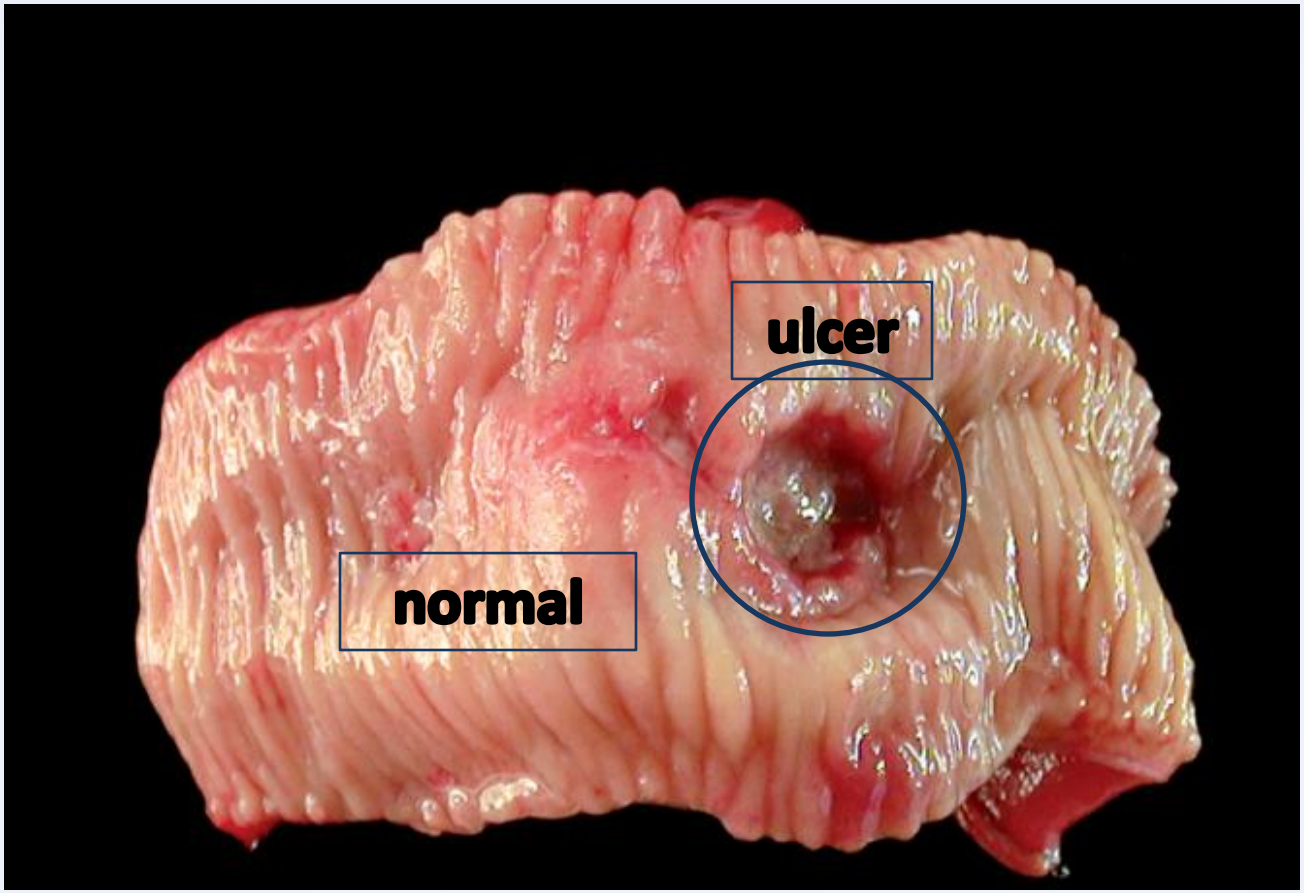

A biopsy should be taken to exclude malignancy.

the base of a non-perforated peptic ulcer, demonstrating the layers of <u>necrosis</u> (N), <u>inflammation</u> (I), <u>granulation tissue</u> (G), <u>scar</u> (S) moving from the luminal surface at the top to the muscle wall at the bottom.

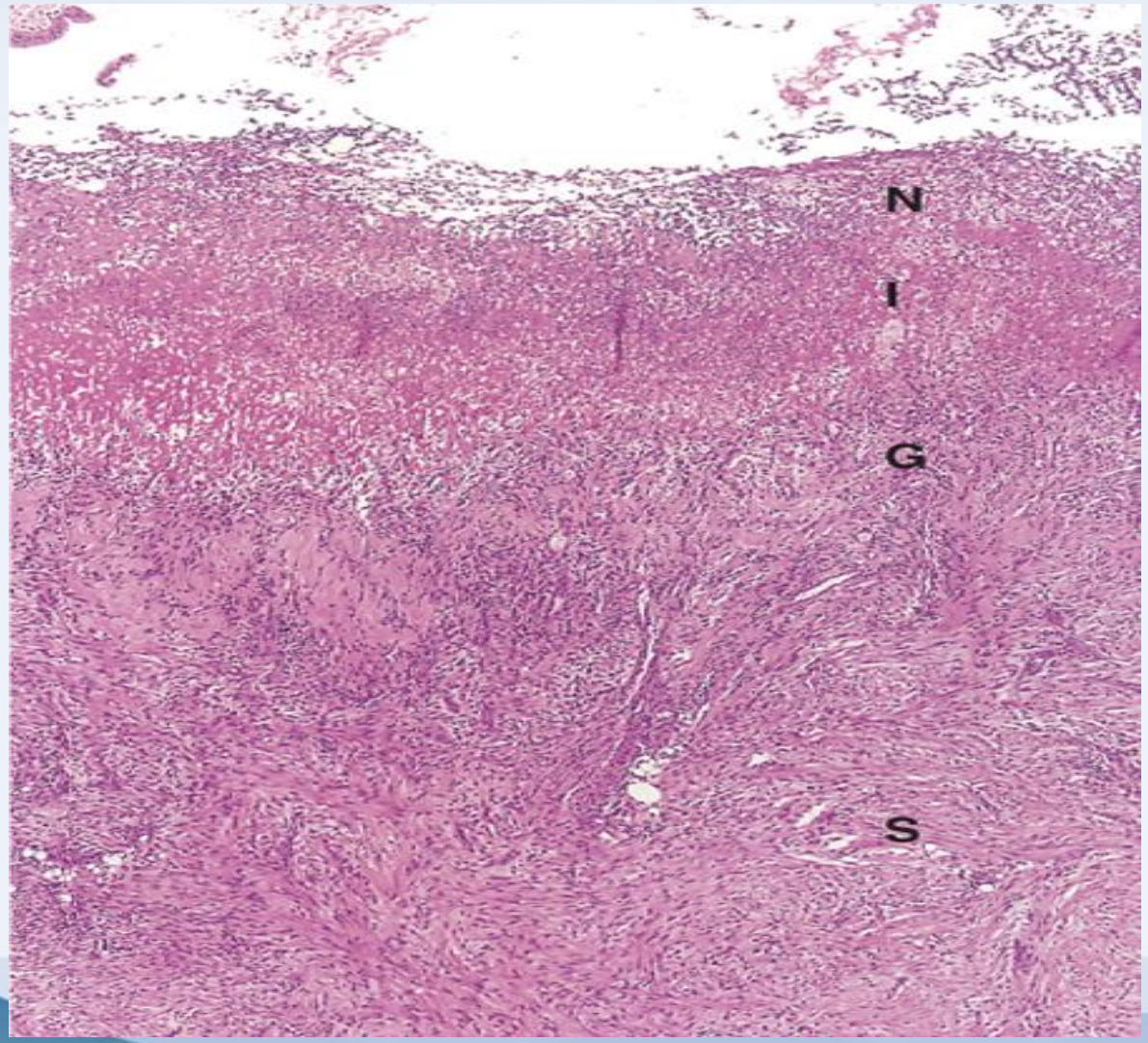

Nowadays, we don't see such severe cases due to the efficiency of treating H. pylori.

Clinical Features

- Epigastric pain.
- The pain tends to be worse at night.
- It occurs usually 1-3 hours after meals during the day.
- The pain is relieved by alkalis (e.g. milk) or food.
- Nausea, vomiting, bloating, belching… According to the degree or severity
- significant weight loss. Because The ulcer can cause decrease in appetite and because the patient might stop eating certain food that increases the pain.

Complications

1. **Bleeding** is the chief complication, occurring in 33%.
2. **Perforation** occurs in about 5% of patients but accounts for two-thirds of deaths from this disease in the United States.... **The perforated material my reach the pancreas causing pancreatitis.**
3. **Obstruction** of the pyloric channel is rare.
4. **Malignant transformation**
   - occurs in about 2% of patients
   - ulcers in the pyloric channel, and is very rare with gastric ulcers.

(B) Acute Gastric Ulceration

- Might be associated with acute gastritis.

- ***Stress ulcers***
- **Focal, acutely developing gastric mucosal defects that may appear after severe physiologic stress**
- **Multiple lesions located mainly in the stomach and occasionally in the duodenum.**

Causes :

- 1-Severe trauma, including major surgical procedures
- 2-sepsis
- 3-shock.... **Loss of body volume or blood, dehydration, vomiting → reflex: vasoconstriction in non vital organs like the GI tract**
- 4-grave illness of any type
- 5-chronic exposure to gastric irritant drugs, particularly NSAIDs and corticosteroids
- 6-extensive burns (**Curling ulcers**)
- 7-traumatic or surgical injury to the CNS or an intracerebral hemorrhage (**Cushing ulcers**).

Pathogenesis

- NSAID-induced ulcers are linked to decreased PG production.
- The systemic acidosis that can accompany severe trauma and burns may contribute to mucosal injury presumably by lowering the intracellular pH of mucosal cells already rendered hypoxic by impaired mucosal blood flow.
- With cranial lesions, direct stimulation of vagal nuclei by increased intracranial pressure may cause gastric acid hypersecretion which is common in these patients.

Multiple stress ulcers of the stomach showing dark digested blood in their bases

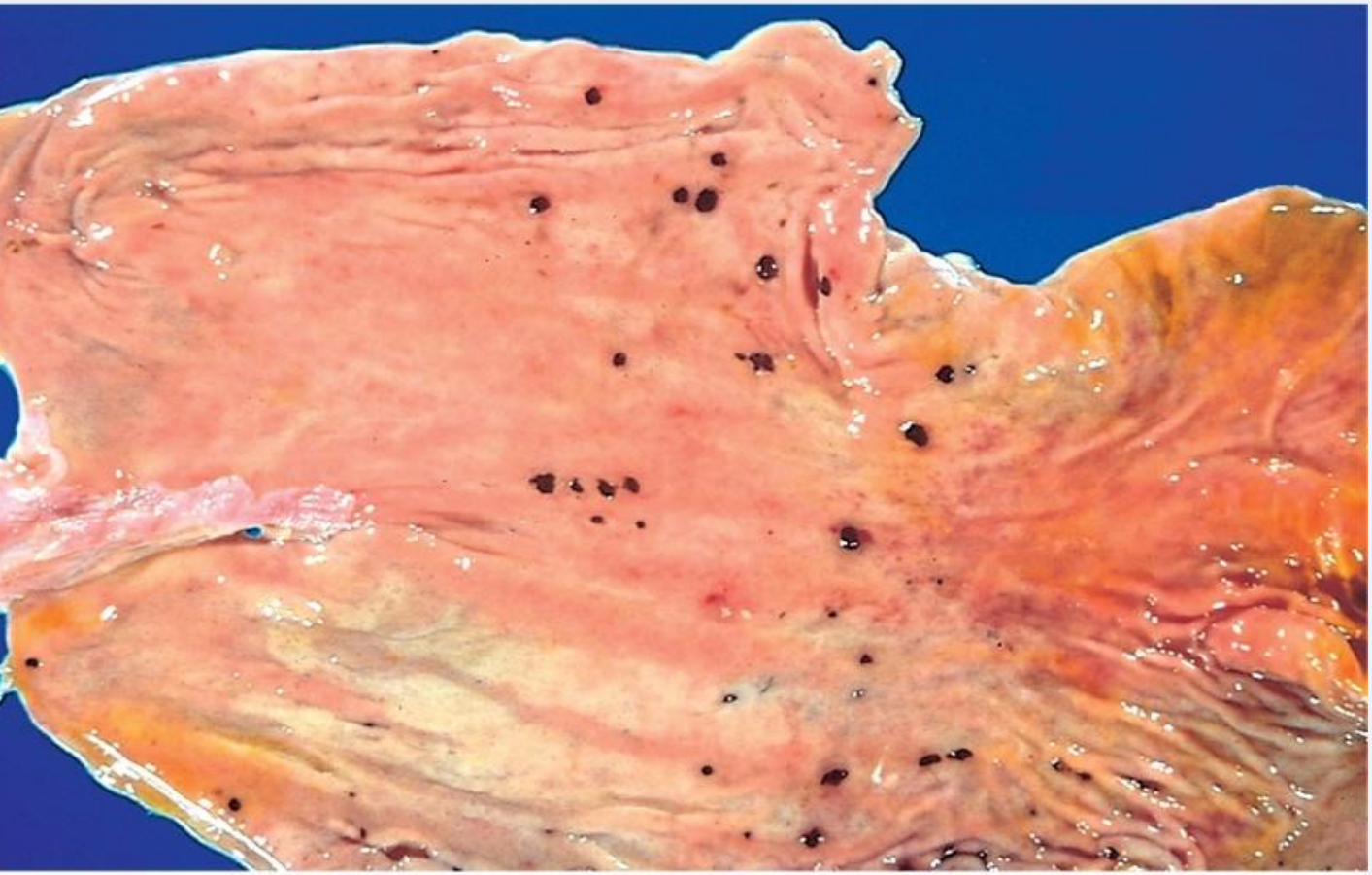

Multiple ulcers.

Small in size.

The base of the ulcer is dark because of hemorrhage (it's an acute insult associated with hemorrhage)

4. Gastric Tumors

A. **Gastric Polyps**
   1. hyperplastic polyps
   2. fundic gland polyps
   3. adenomatous polyps

B. **Gastric malignant tumors**
   1. Carcinoma
   2. lymphomas
   3. Carcinoids
   4. Stromal tumors

(A) Gastric Polyps

- *The term polyp is applied to any nodule or mass that projects above the level of the surrounding mucosa.*
- A lipoma or leiomyoma arising in the wall of the stomach may protrude from under the mucosa to produce an apparent polypoid lesion.
- *The term **polyp** in the gastrointestinal tract is generally restricted to mass lesions arising in the mucosa.*
- Gastric polyps are uncommon and are found in about 0.4% of adult autopsies

Polyps are common in the GI tract, but not common in the stomach as in the colon.

Extra slide:

- A polyp is a protrusion into the lumen.

- In general:
  - polyps can either be tumorous (neoplastic) or non-neoplastic.
  - Neoplastic polyps can either be benign or malignant.

Types of gastric polyps:

1. Hyperplastic polyps (80% to 85%) **.... The most common type**
2. Fundic gland polyps (~10%)**... Commonly seen in the fundus of the stomach**
3. Adenomatous polyps (~5%)**... These are the true neoplastic polyps. This type is the least common in the stomach but it's common in the colon.**

- All three types arise in the setting of chronic gastritis and so are seen in the same patient populations.
- **Note: if we look at polyps in the stomach, we find ulcers. That's why if we see an ulcer in the stomach, we should take a biopsy in order to find out if it's peptic ulcer or a tumor.**
- Hyperplastic and fundic gland polyps are essentially innocuous. **Both types are non-neoplastic**.
- There is a definite risk of an adenomatous polyp harboring adenocarcinoma, which increases with polyp size.

  The polyp size is a very important determinant of the risk of malignancy, among other things like the stage.

(B) Gastric malignant tumors

1. **Carcinoma** (more precisely, Adenocarcinoma) **(90% to 95%)....most common type**
2. **lymphomas (4%)**
3. **Carcinoids (3%)**.... Carcinoids actually range from benign to malignant.
4. **Stromal tumors (2%).**

- Lymphomas usually occur in lymph nodes.
- Lymphoma in a location other than lymph nodes is known as "extra nodal lymphoma".
- The most common site for extra nodal lymphomas in the GI tract is the stomach.

Gastric Carcinoma

- Gastric carcinoma is the **2nd leading cause of cancer-related deaths in the world.**

There is geographical variation:

- Japan and South Korea have the highest incidence 8-9X higher than in the United States and Western Europe .
- The incidence in China and Chile and Costa Rica is also high.

- The 5-year survival rate is < 20%. (low) → it's an aggressive type of malignancy.

- **<u>Morphological types :</u>**

1. ***intestinal***
2. ***diffuse*.**

Each type has different predisposing factors.

- **The incidence of <u>intestinal-type carcinoma</u> has progressively diminished in the United States.**

  This is because this type is related to (H.pylori , gastritis , and intestinal metaplasia). Nowadays, a patient who has H.pylori infection is usually treated before the development of malignancy.

- **The incidence of <u>diffuse gastric carcinoma</u> has not significantly changed in the past 60 years and now constitutes approximately half of gastric carcinomas in the United States.**

Summary Table (types)

	Intestinal type	Diffuse type
Pathogenesis	Arises from gastric mucous cells that have undergone intestinal metaplasia in the setting of chronic gastritis.	Arises de novo from native gastric mucous cells.
Is it related to chronic gastritis?	yes	No
Differentiation	**better differentiated**	**poorly differentiated**
Age at risk	Occurs primarily after age 50 years	Occurs at an earlier age
M:F (Ratio)	2 : 1 (affects males more than females)	F>M (affects females more than males)

(1) Intestinal type gastric carcinoma

- Arise from gastric mucous cells that have undergone intestinal metaplasia in the setting of chronic gastritis.

  Intestinal gastric carcinoma is the final step of chronic gastritis.

- This pattern of cancer tends to be **better differentiated** and is the more common type in high-risk populations.
- Occurs primarily after age 50 years
- M:F 2 : 1

RISK FACTORS

1. Chronic gastritis with intestinal metaplasia.
2. Infection with *Helicobacter pylori.*

   ---

3. Nitrites derived from nitrates (found in food and drinking water)
4. Preservatives in prepared meats which may undergo nitrosation to form nitrosamines and nitrosamides.
5. Diets containing foods that may generate nitrites as smoked fish.
6. Excessive salt intake.

6. **Decreased intake of fresh vegetables and fruits (antioxidants present in these foods may inhibit nitrosation).**

----

7. **Partial gastrectomy.**
8. **Pernicious anemia.**

----

9. **Amplification of *HER-2/NEU* and increased expression of β-catenin (in 20-30% of cases).**

(2) Diffuse variant gastric carcinoma

- **Arise de novo from native gastric mucous cells.**
- **Not related to chronic gastritis.**
- **Occurs at an earlier age.**
- **F>M**
- **It tends to be poorly differentiated.**

Risk factors

- undefined, except for rare Inherited mutation of **E-cadherin** (50%).
- *Infection with H. pylori and chronic gastritis often* ***absent.***
- Amplification of *HER-2/NEU* and increased expression of β-catenin are **absent.**
- **Mutations in *FGFR2* and increased expression of metalloproteinases are present in ~1/3 of cases (absent in intestinal type)** .

Clinical features

- **Location :**
- pylorus and antrum, 50- 60%.
- cardia, 25%.
- body and fundus 15-25 %
- Lesser curvature is involved in about 40%
- The greater curvature is involved in 12%.
- **The favored location is the lesser curvature of the antropyloric region.**
- An ulcerative lesion on the greater curvature is more likely to be malignant than benign.

- The morphologic feature having the greatest impact on clinical outcome is the **depth of invasion.**

- **Early gastric carcinoma** (carcinoma in situ) **is defined as a lesion confined to the mucosa and submucosa regardless of the presence or absence of perigastric lymph node metastases.**
- **Advanced gastric carcinoma is a neoplasm that has extended below the submucosa into the muscular wall** and has perhaps spread more widely.

- Gastric mucosal **dysplasia** is the presumed precursor lesion of early gastric cancer.

The macroscopic growth patterns

- Evident at both the early and advanced stages:

1. **exophytic**, with protrusion of a tumor mass into the lumen.
2. **flat or depressed**, in which there is no obvious tumor mass within the mucosa.
3. **excavated**, a shallow or deeply erosive crater is present in the wall of the stomach.

4. **linitis plastica** a broad region of the gastric wall, or the entire stomach, is extensively infiltrated by malignancy.

- The rigid and thickened stomach is termed a leather bottle stomach.

Note: very characteristic of poorly differentiated (diffuse type) gastric carcinoma is the infiltration within the wall of the stomach without having an obvious effect on the superficial mucosa which makes this type more difficult to identify since the infiltration is hidden within the wall, but the mucosa looks normal. We should take the biopsy from the wall and not from the mucosa.

- **Exophytic** tumors may contain portions of an adenoma.
- **Flat or depressed** malignancy presents only as regional effacement (محي) of the normal surface mucosal pattern.
- **Excavated** cancers may mimic in size and appearance chronic peptic ulcers but may show heaped-up margins

- Whatever the histologic variant, all gastric carcinomas eventually penetrate the wall to involve the serosa, spread to regional and more distant lymph nodes, and metastasize widely.
- The earliest lymph node metastasis may sometimes involve a **supraclavicular lymph node (Virchow node).**

  The involvement of this lymph node might be the first presentation of the tumor when the patient comes to the clinic.
- Intraperitoneal spread in females is to both the ovaries, giving rise to the so-called **Krukenberg tumor.** → **bilateral ovarian metastasis.**

Malignant gastric ulcer

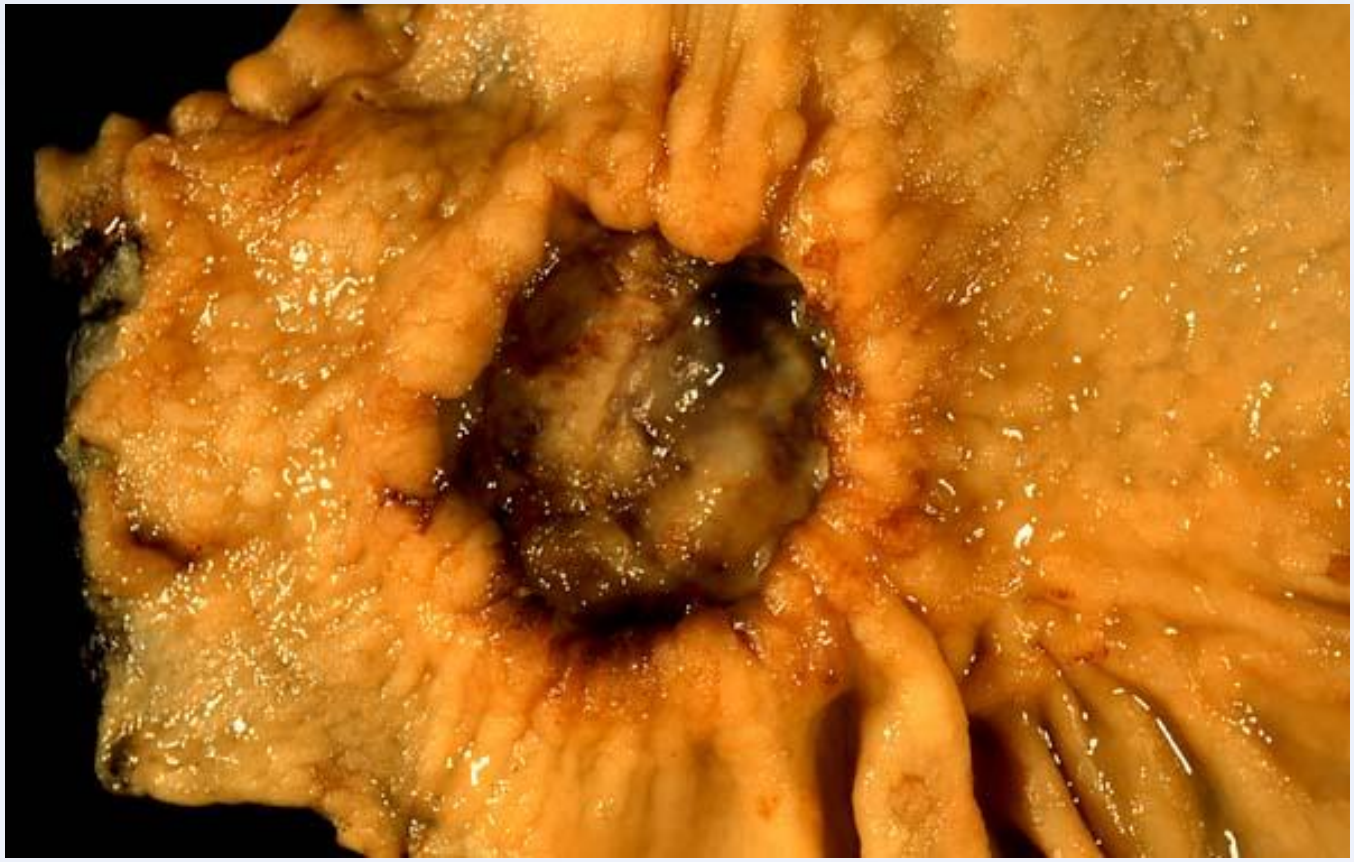

- **The base of malignant ulcer is necrotic.**
- The margins are elevated and irregular.
- The wall would be rigid and thickened.

Ulcerative gastric carcinoma.

The ulcer is large with irregular, heaped-up margins. There is extensive excavation of the gastric mucosa with a necrotic gray area in the deepest portion

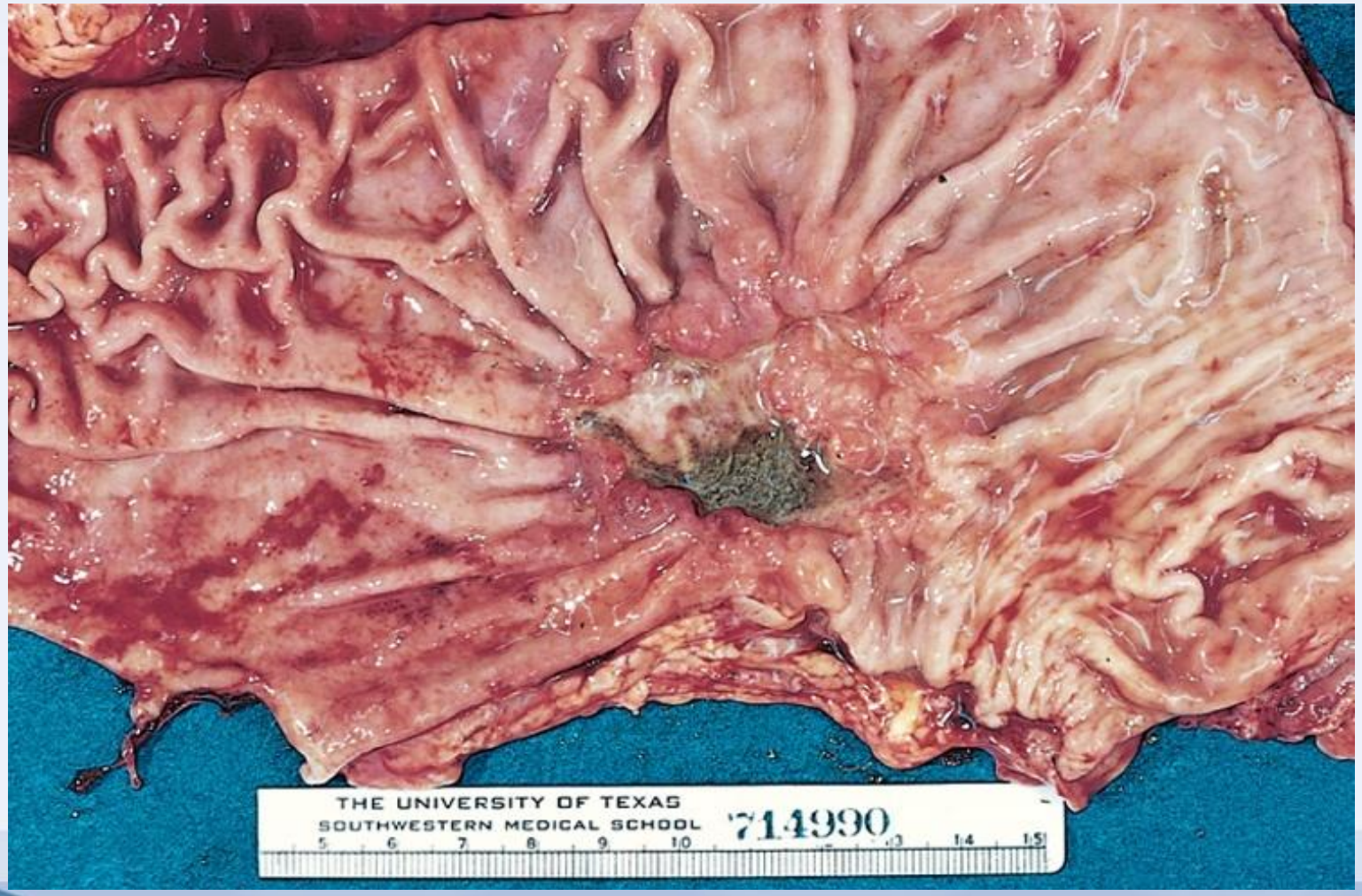

Intestinal type of gastric carcinoma with gland formation by malignant cells that are invading the muscular wall of the stomach

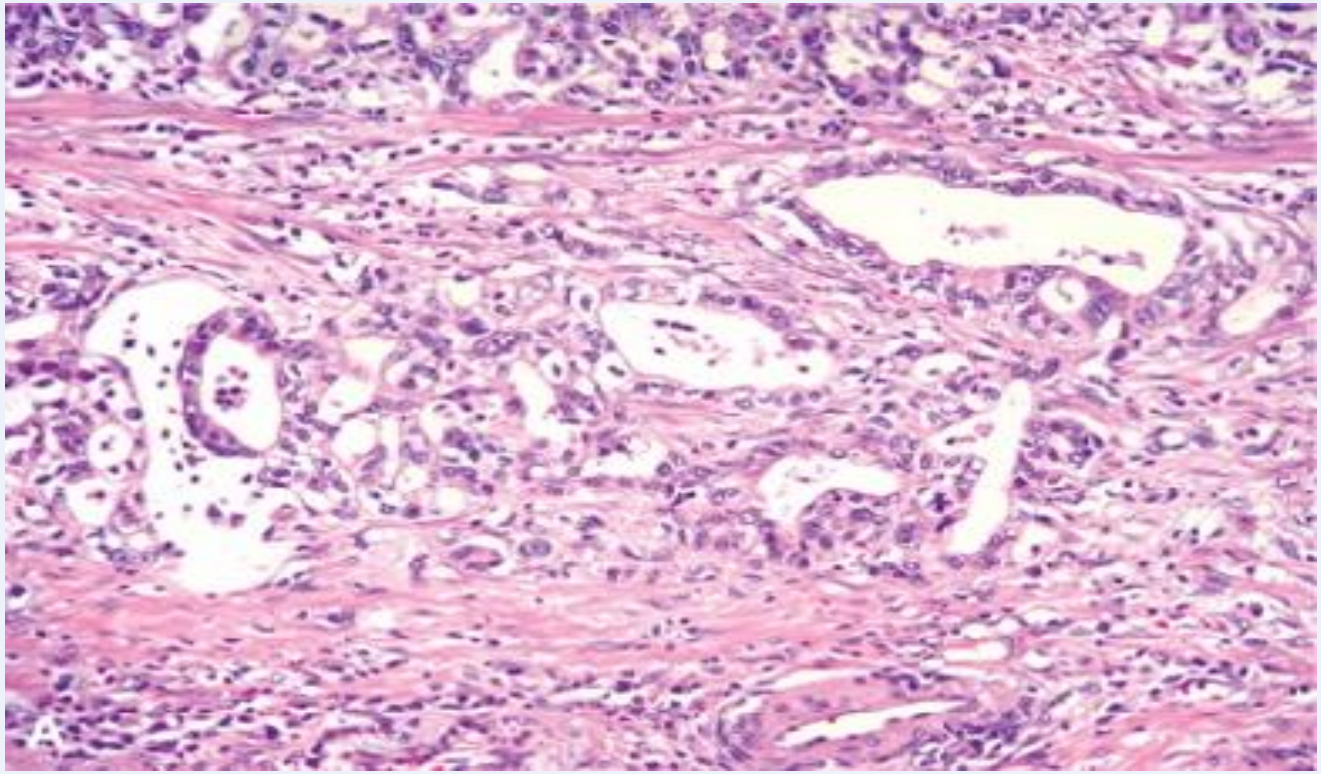

- Microscopically, it is **Adenocarcinoma** because it's formed from glands.
- We find Malignant cells with different shapes. And they infiltrate into the wall of the stomach.

Diffuse type of gastric carcinoma with signet-ring (مثل الخاتم) tumor cells (important slide)

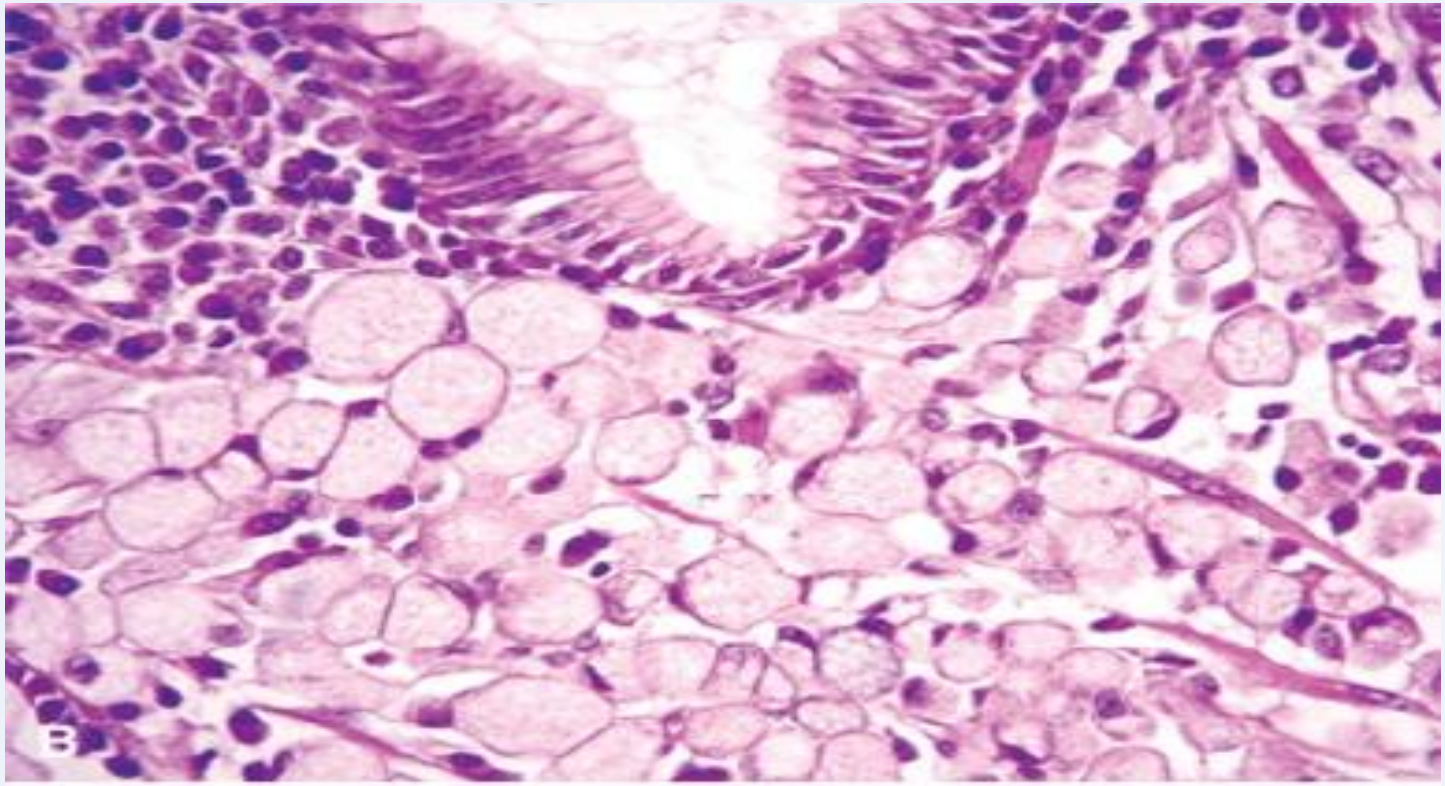

Intact surface epithelium (carcinoma is beneath it).
→ mucosa might appear normal.

Notice the shape of the cells (like a ring).



Clinical case #2...(Gastric Malignant Tumors)

- A 55 yr old lady presents with 2-month history of progressive weight loss, abdominal pain & dark stool.

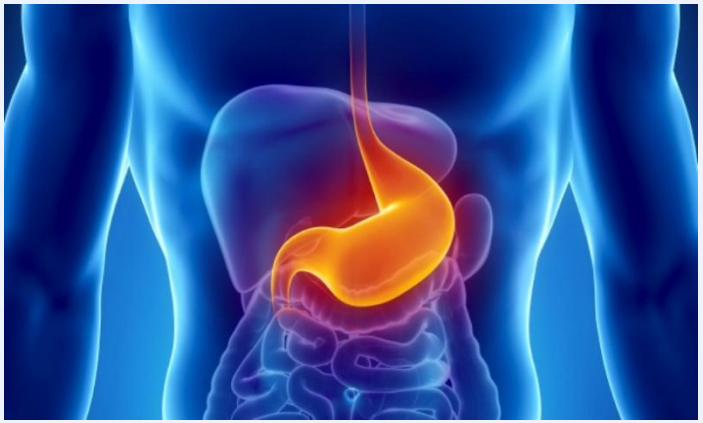

- The patient is pale and anemic.

- Gastroscopy reveals a an ulcerated lesion in the antrum with **raised, irregular, and indurated margins.**

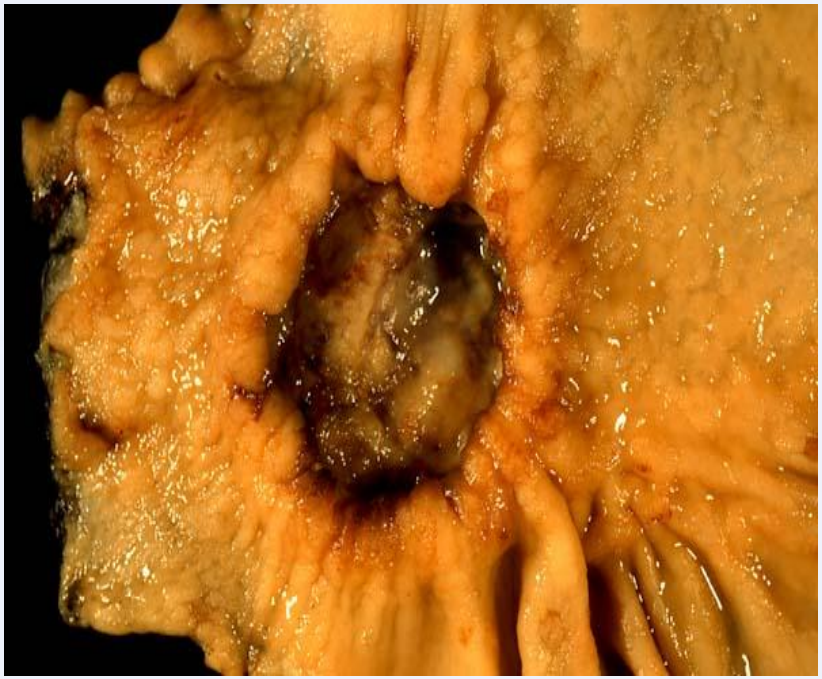

- This is most likely represents... **Gastric malignant tumor.**

Extra slide

Gastric Adeno Carcinoma:

Intestinal Type	Diffuse Type
• H.pylori Metaplasia	• Idiopathic/familial.
• C. gastritis / atrophy	• No precursor lesion
• HER-2/NEU mutation	• E-Cadherin mutations
• Well differentiated	• Poorly differentitated
• No Signet ring cells.	• Signet ring cells
• Gland formation.	• No gland formation,
• Better Prognosis	• Poor Prognosis

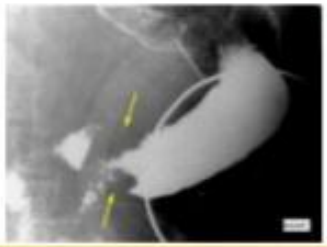
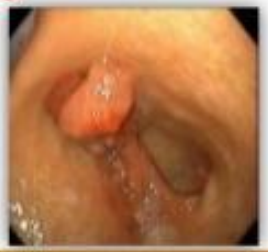
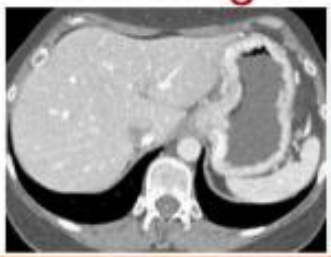
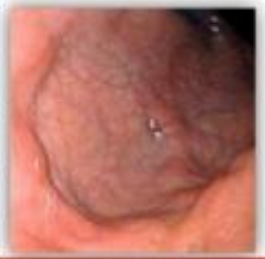

The End :’D