

Adductor canal (Subsartorial) or Hunter's canal

John **Hunter** described the exposure and ligation of the femoral artery in this canal for aneurysm of the popliteal artery; this method has the advantage that the artery at this site is healthy and will not tear when tied, as may happen if ligation is attempted immediately above the aneurysm.



Adductor (Subsartorial) Canal

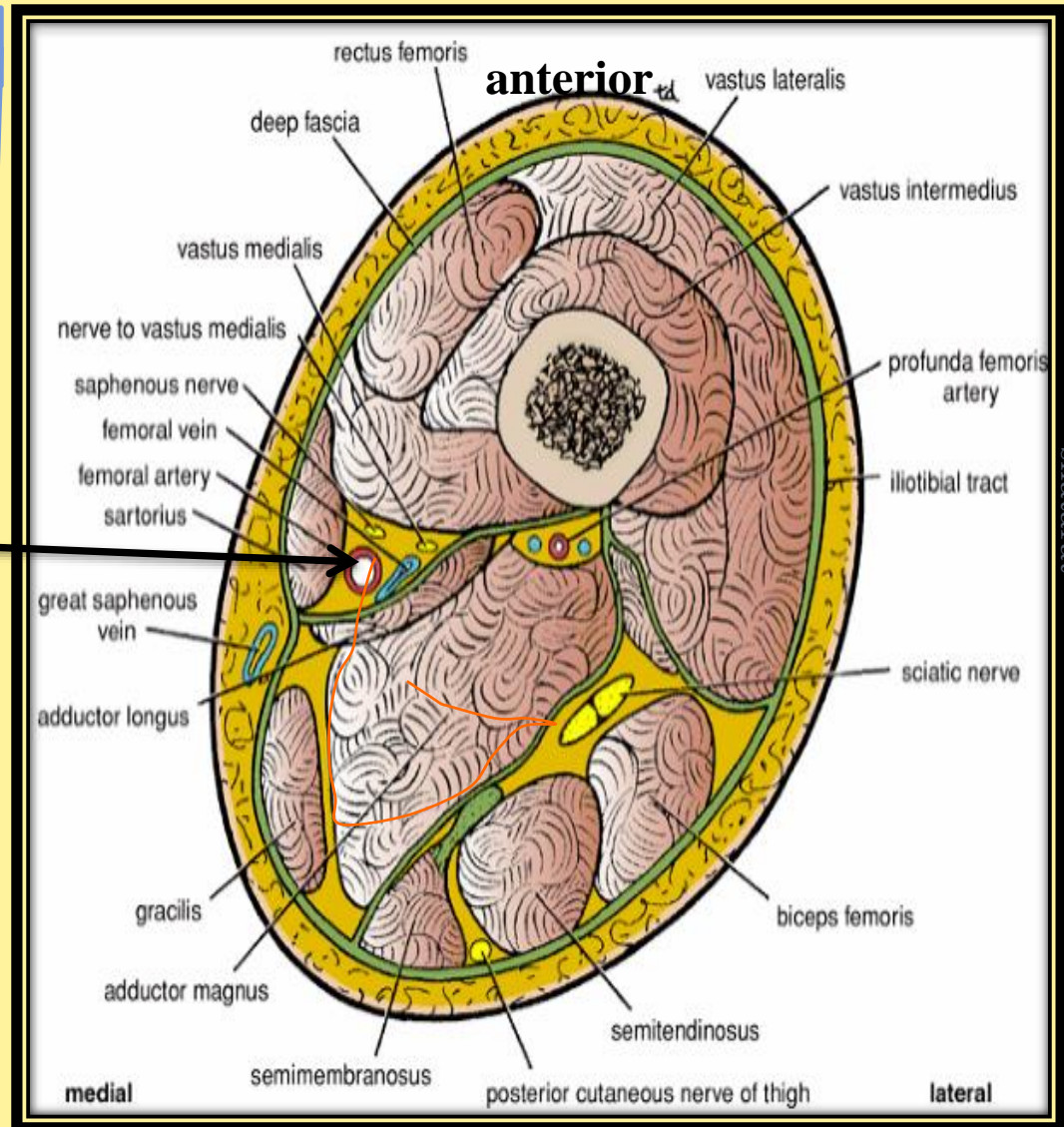
➤ is an intermuscular cleft situated on the medial aspect of the middle third of the thigh beneath the sartorius muscle

- It commences above at the apex of the femoral triangle and ends below at the opening in the adductor magnus.
- In cross section it is triangular, having

1-Anteromedial wall

2-Posterior wall

3-Lateral wall



Transverse section through the middle of the right thigh as seen from above

**The Anteromedial wall is
formed by:**

**The sartorius muscle
and fascia.**

anterior

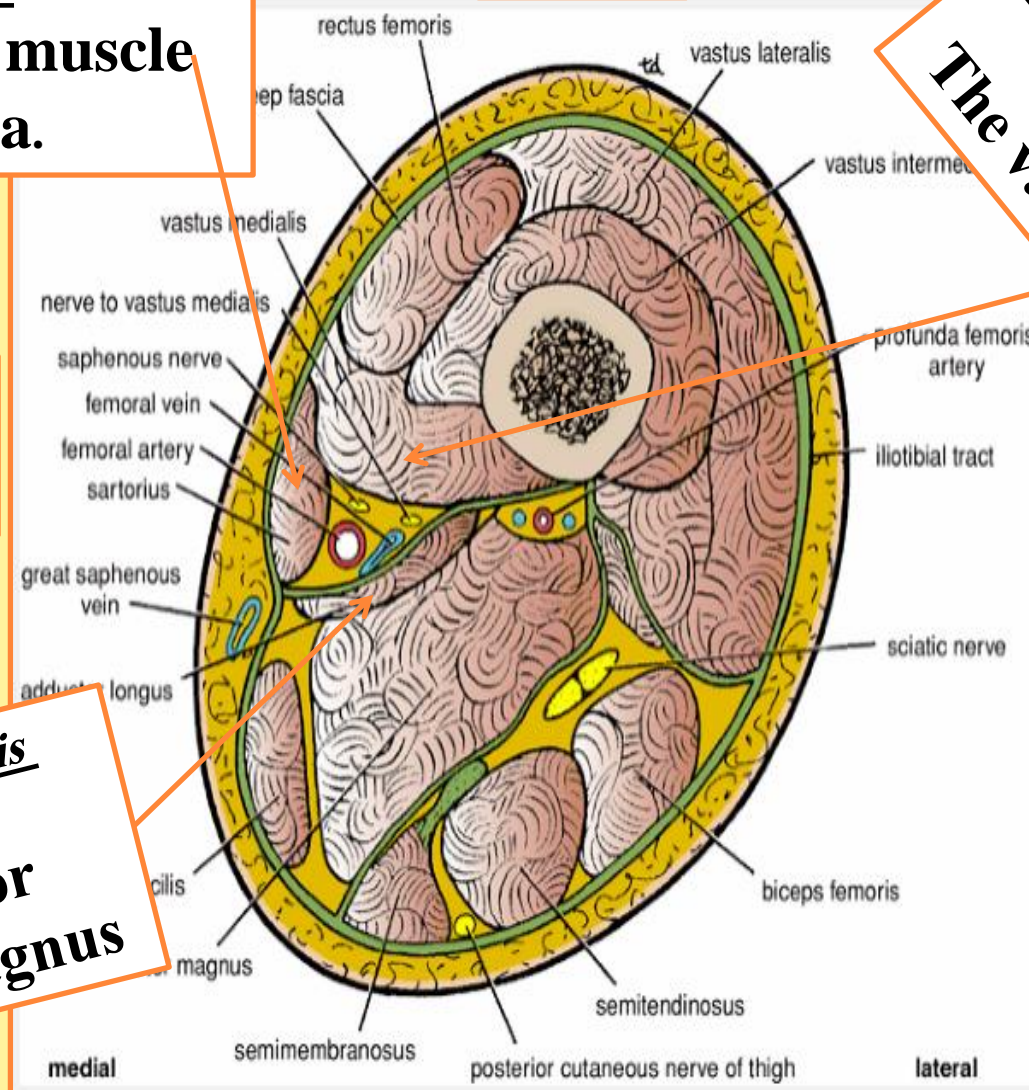
**The lateral wall is formed
by:**
The vastus medialis

medial

lateral

**The posterior wall is
formed by:**

**The adductor
longus and magnus**



posterior

The adductor canal contains

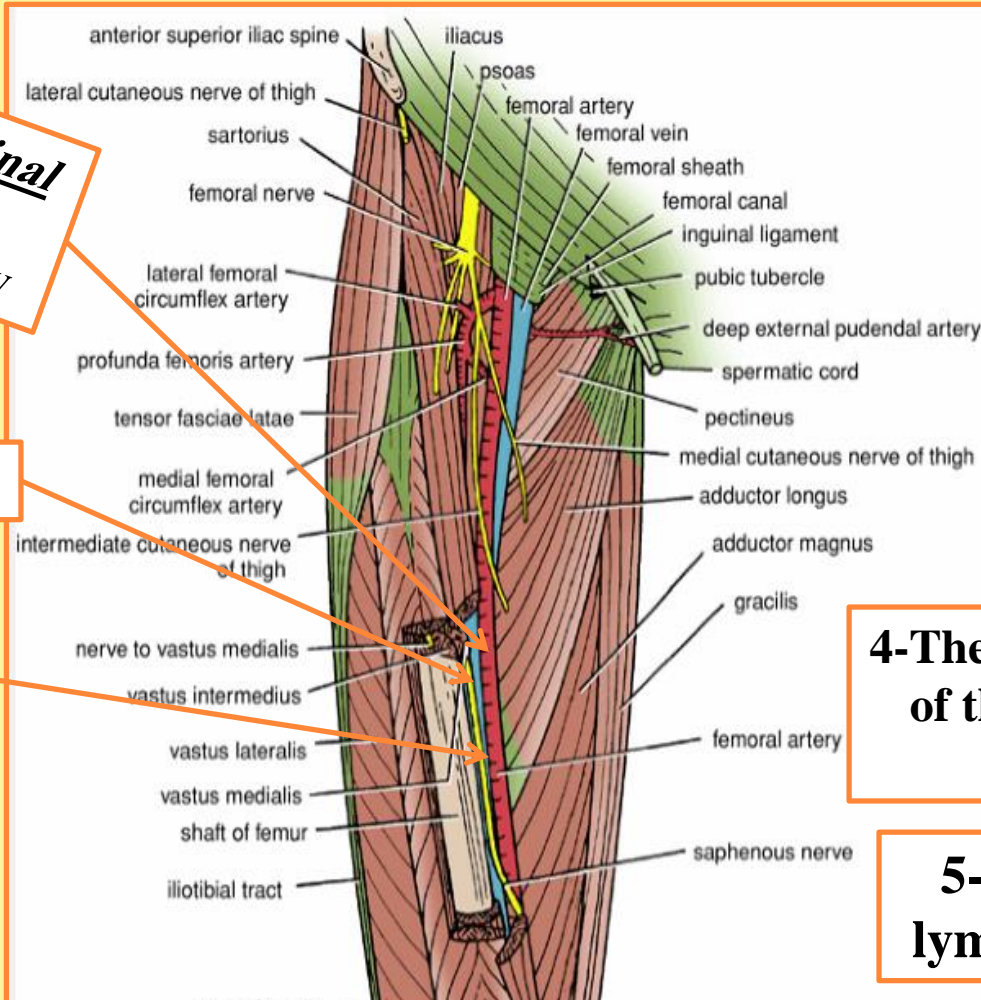
1-The terminal part of the femoral artery

2-The femoral vein

3-The saphenous nerve

4-The terminal part of the obturator nerve

5-The deep lymph vessels



Dr. Amjad shatarat

Subsartorial plexus of nerves:

➤ Located on the fascia under the sartorius muscle and is formed by branches from

1-Medial cutaneous nerve of the thigh, Saphenous nerve and The anterior division of obturator nerve

The femoral artery

1- It enters the thigh from behind the inguinal ligament as a continuation of the external iliac artery.

2- It lies midway between the anterior superior iliac spine and the symphysis pubis

Medial circumflex femoral artery

Lateral circumflex femoral artery

Perforating arteries

Anterior views

(midinguinal point)

3-As the femoral artery descends downwards,
its upper half lies

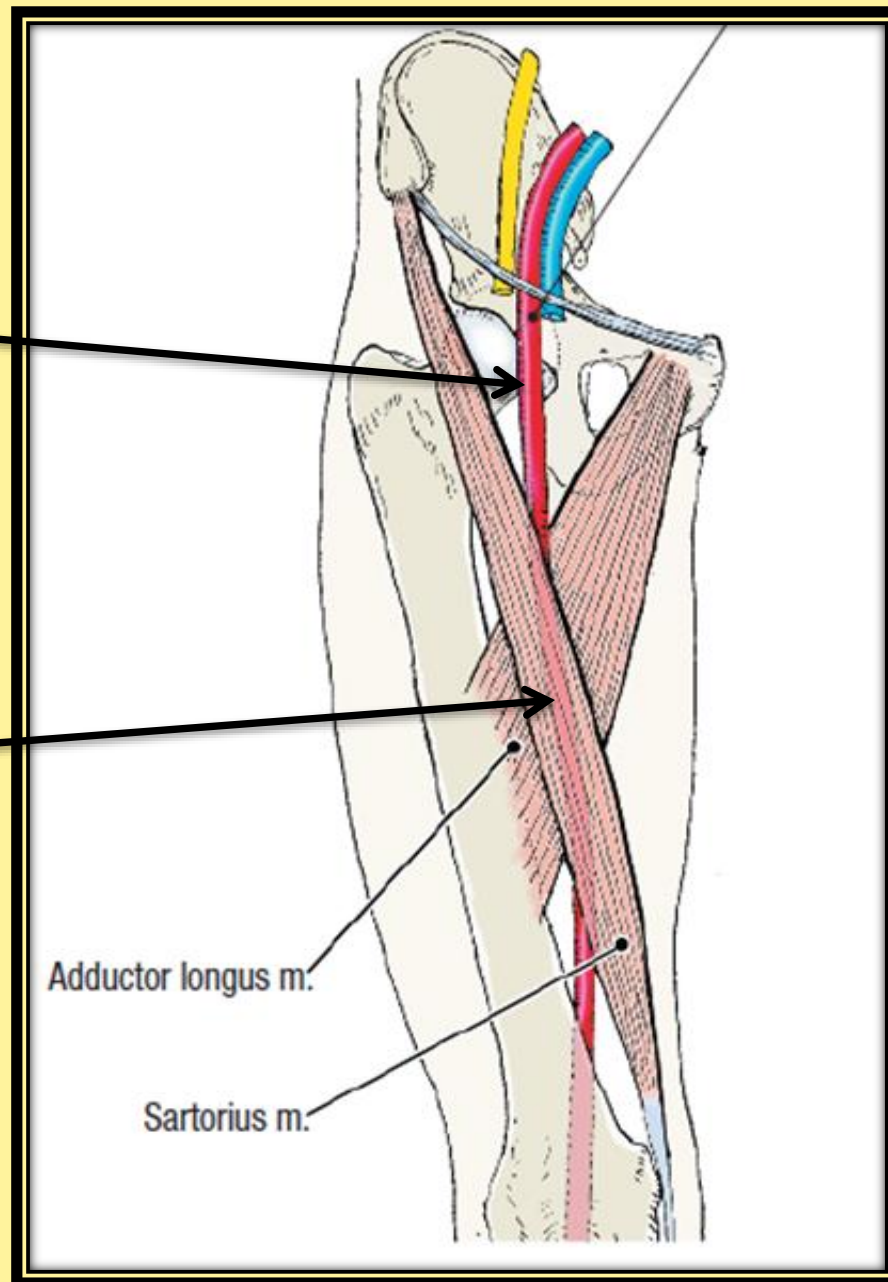
***superficial
in the femoral
triangle***

(what does this mean?)

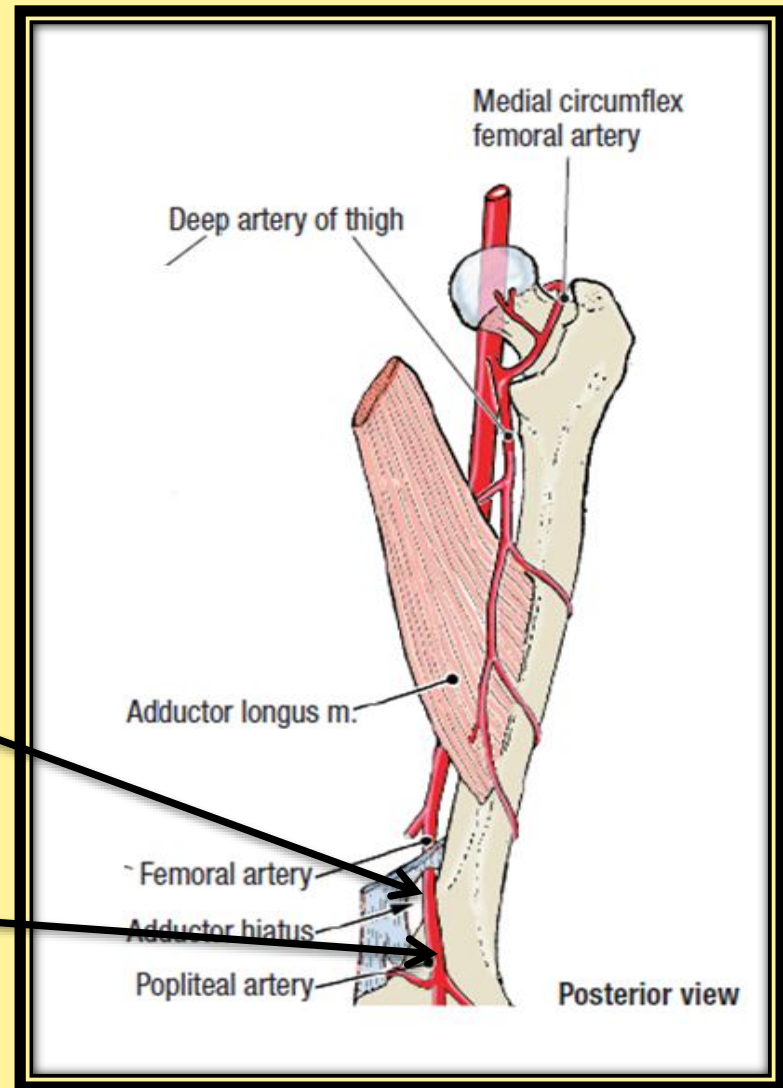
See next slides

while in the lower half

it lies ***deep in the
subsartorial
(adductor) canal***



4- The femoral artery then descends almost vertically toward the adductor tubercle of the femur and ends at the opening (Adductor hiatus) in the adductor magnus muscle by entering the popliteal space as THE POPLITEAL ARTERY



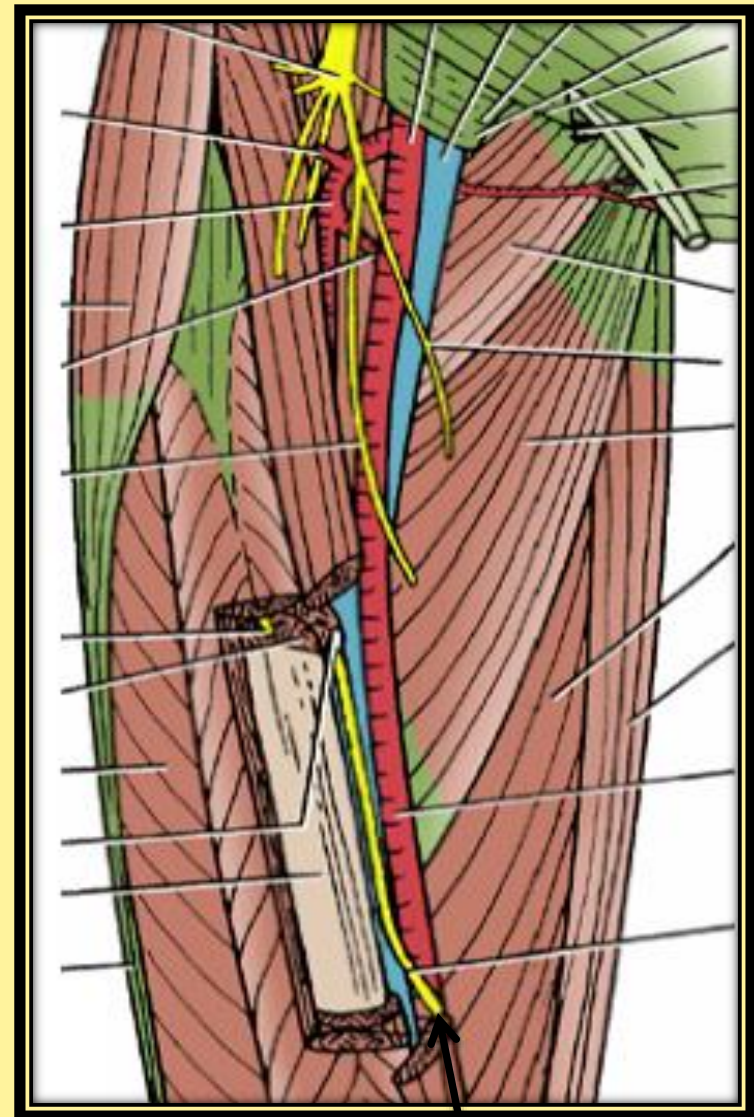
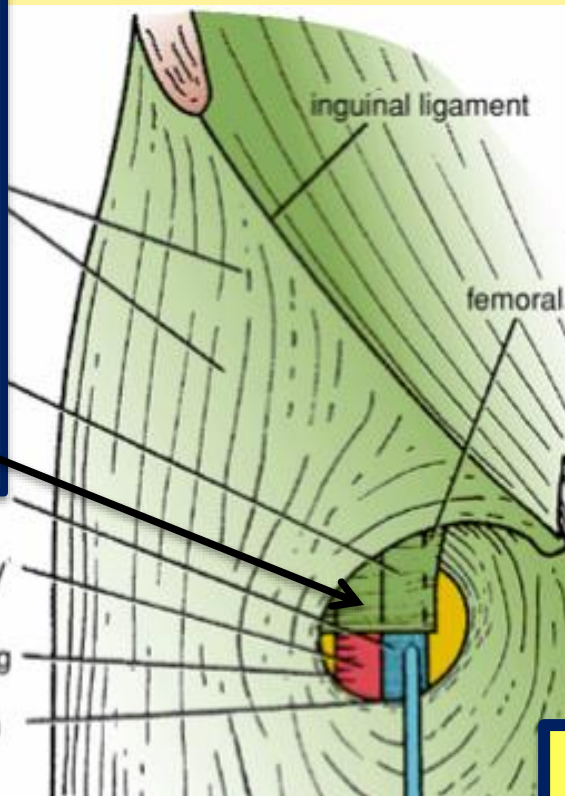
In the upper part of its course, femoral artery *lies in the femoral triangle* (superficial)

- 1- Exposed to injuries
- 2- Good approach for taking femoral pulse

Anteriorly : (in the femoral triangle)

The femoral artery is covered by skin and fascia

➤ Its upper part (1.5 inch) ***is covered by the anterior wall Of the femoral sheath and crossed by the femoral branch of genito-femoral nerve***



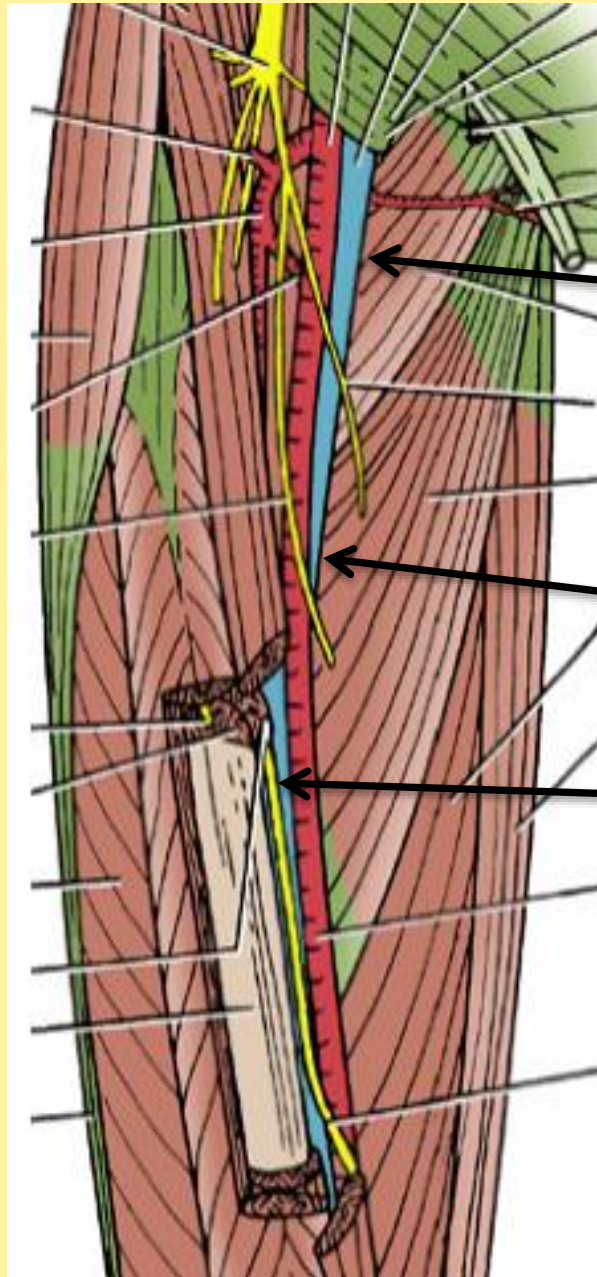
➤ Its lower part is crossed ***by the saphenous Nerve***

Laterally:

The femoral nerve and
Its branches.

Posteriorly:

***1-Psoas major
muscle, which
separates it from the
hip joint***



Medially: the
femoral vein lies
medial to the
artery in the
upper part of the
femoral triangle,
then it lies
posteromedial
and finally
posterior to the
artery at the
apex of the
femoral triangle

Because the femoral artery lies in the femoral triangle (superficial)

The following procedure can be done

Read only

Femoral Artery Catheterization

- 1-Fine catheter can be inserted into the femoral artery as it descends through the femoral triangle.
- 2-The catheter is guided under fluoroscopic view along the external and common iliac arteries into the aorta.
- 3-The catheter can then be passed into the inferior mesenteric, superior mesenteric, celiac, or renal arteries.
- 4-Contrast medium can then be injected into the artery under examination and a permanent record obtained by taking a radiograph.

Femoral Vein Catheterization

- 1-Femoral vein catheterization is used when rapid access to a large vein is needed.
- 2-The femoral vein has a constant relationship to the medial side of the femoral artery just below the inguinal ligament and is easily cannulated.
- 3- Because of the high incidence of thrombosis with the possibility of fatal pulmonary embolism, the catheter should be removed once the patient is stabilized.

Anatomy of the Procedure

- 1-The skin of the thigh below the inguinal ligament is supplied by the genitofemoral nerve; this nerve is blocked with a local anesthetic.
- 2-The femoral pulse is palpated midway between the anterior superior iliac spine and the symphysis pubis, and the femoral vein lies immediately medial to it.
- 3-At a site about two fingerbreadths below the inguinal ligament, the needle is inserted into the femoral vein.

6- Branches of the femoral artery

❖ In the femoral triangle

**THREE superficial branches and
TWO deep branch**

I-Superficial branches

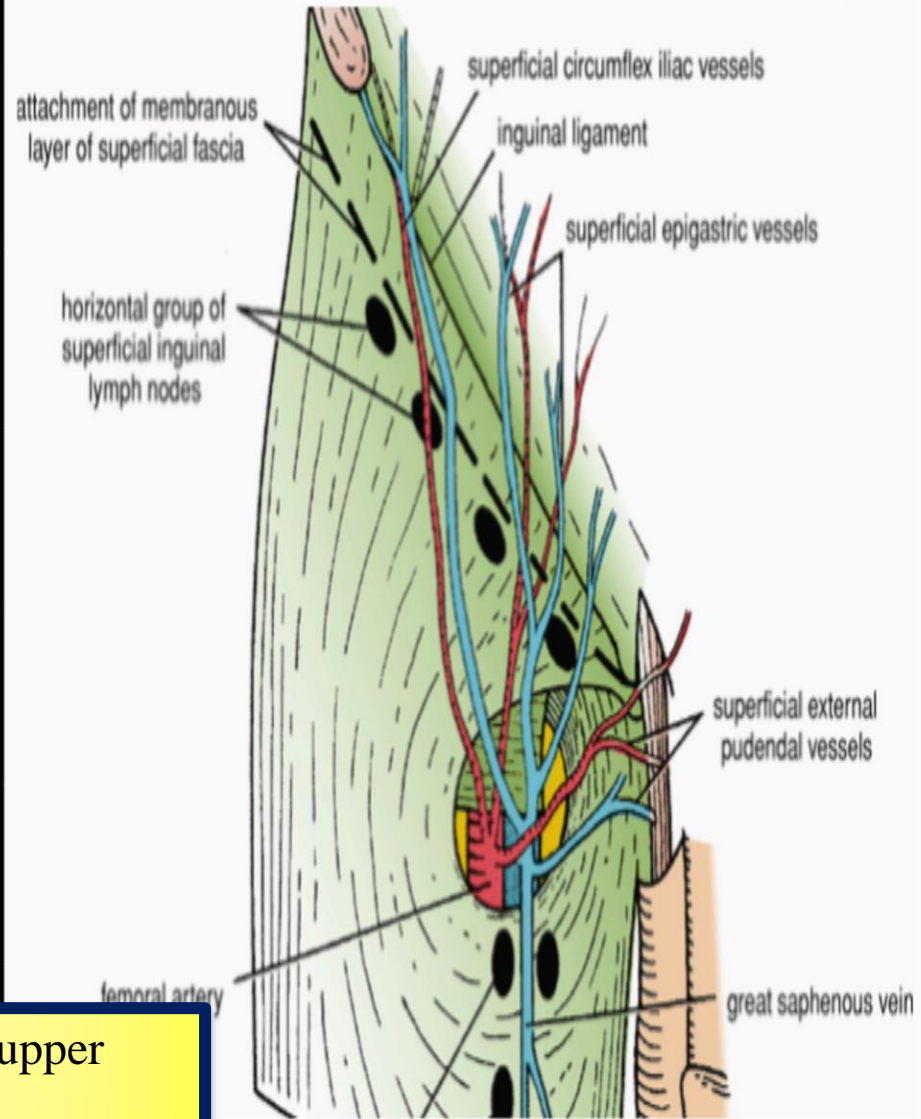
1-The superficial circumflex iliac artery

2-The superficial epigastric artery

3-The superficial external pudendal



They supply cutaneous regions of the upper thigh, lower abdomen, and perineum.





II- DEEP BRANCHES

1-The deep external pudendal artery

2-The profunda femoris artery (*Deep artery of thigh*)

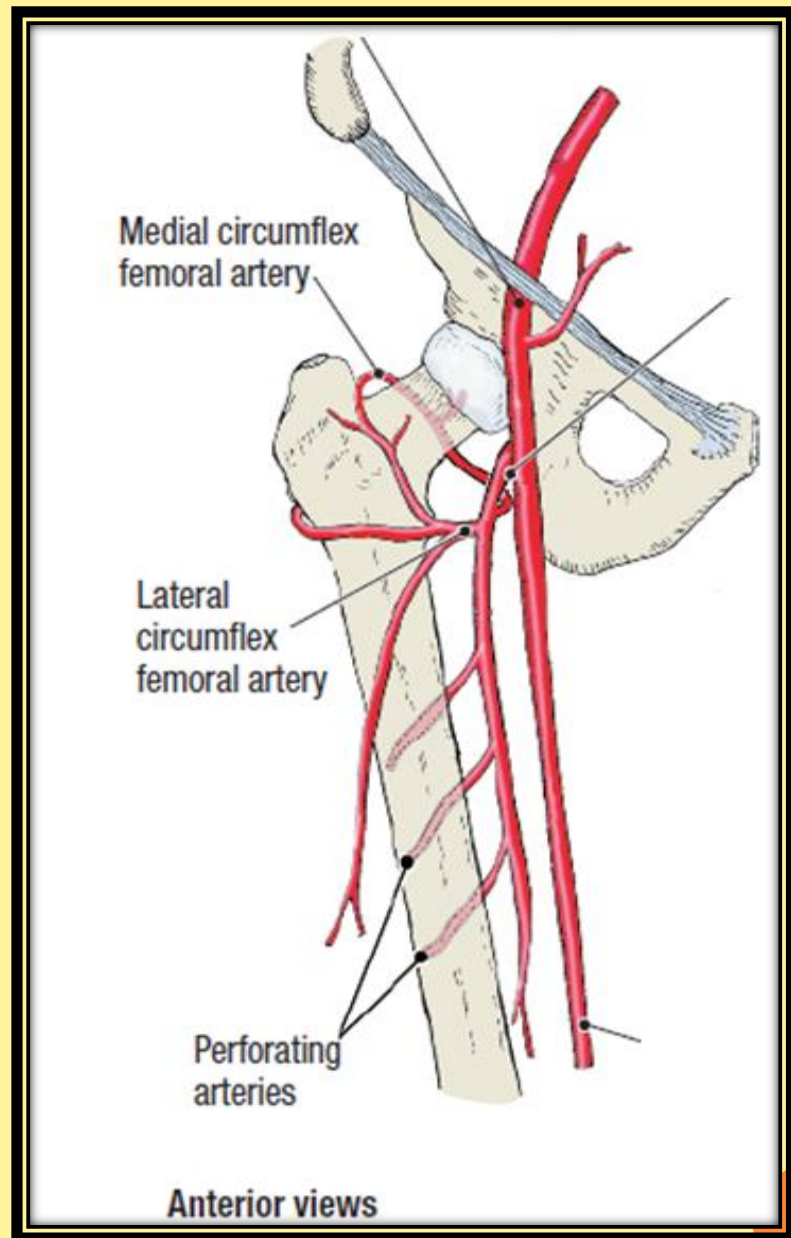
arises from the lateral side of the femoral artery about
(4 cm) below the inguinal ligament

it gives off:

A) lateral femoral circumflex artery

B) The medial femoral circumflex artery

C) Perforating arteries .



A) lateral femoral circumflex artery:

Normally originates proximally from the lateral side of the profunda femoris artery ,
but may arise directly from the femoral artery

Read only

It divides into three terminal branches:

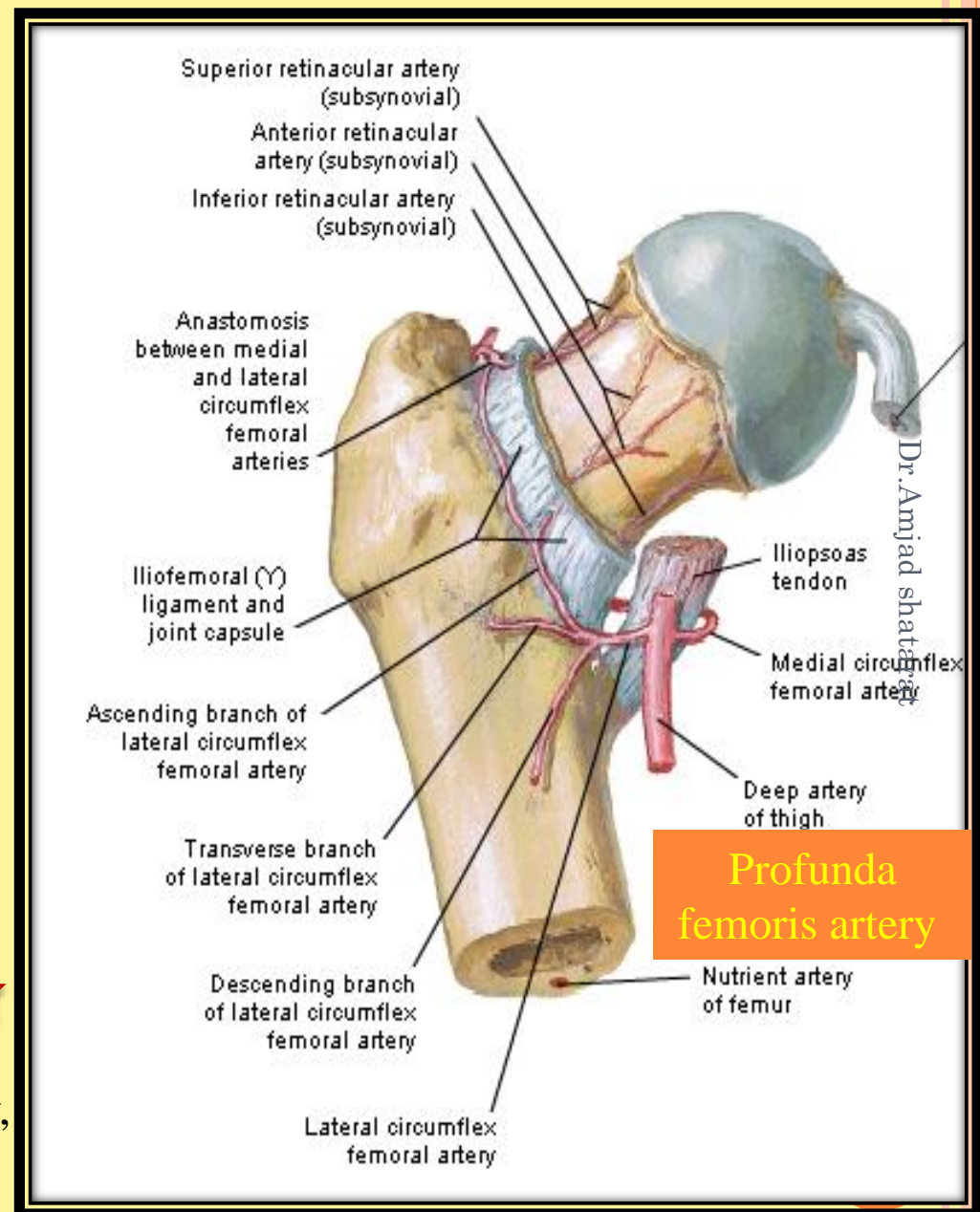
1-ascending branch, supplies *the neck and head of the femur*★

Read only

2-descending branch: connects with a★
branch of the popliteal artery near the knee

Read only

3-transverse branch: anastomoses with★
branches from the medial femoral
circumflex artery, the inferior gluteal artery,
and the first perforating artery to form the
cruciate anastomosis around the hip.



B) The medial circumflex femoral artery

normally originates proximally from the posteromedial aspect of the profunda femoris artery but may originate from the femoral artery

It gives off : **Read only**

a) **Acetabular branch**: which enters the hip joint through the acetabular notch and anastomoses with the acetabular branch of the obturator artery. **Read only**

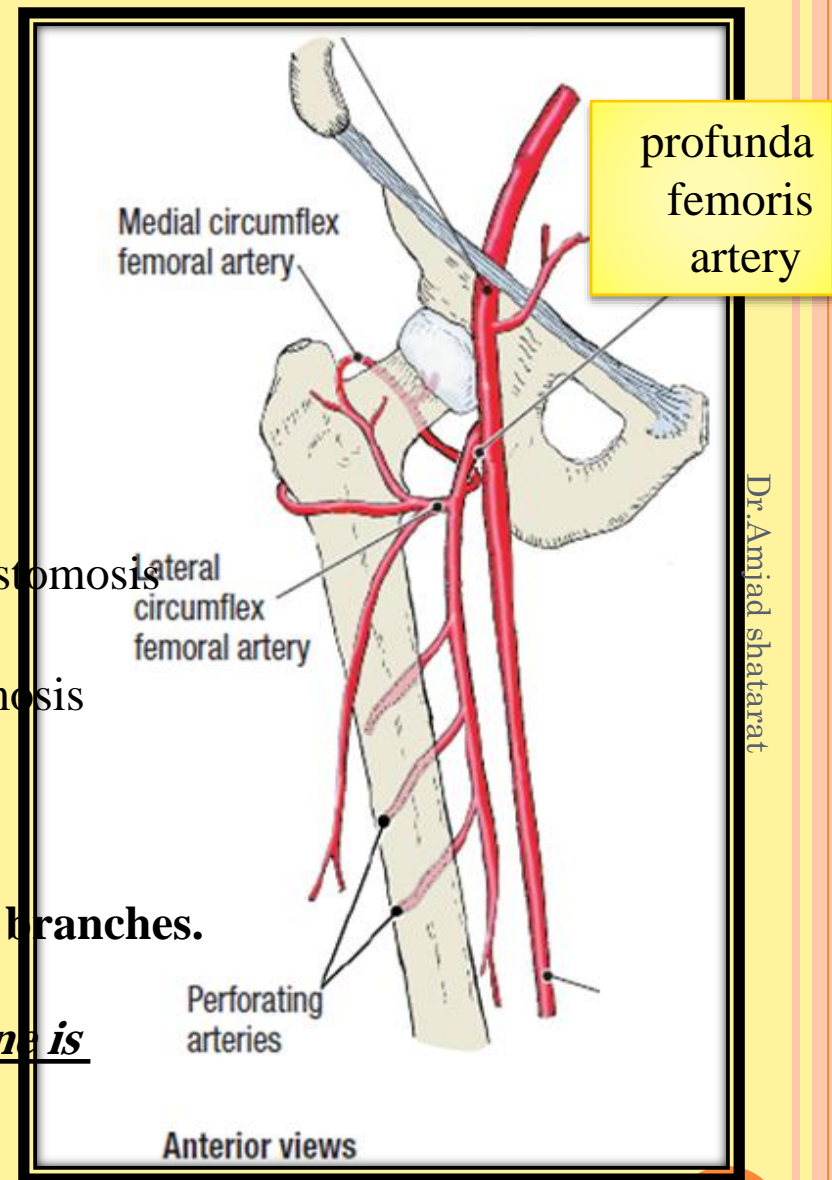
b) **Ascending branch**: shears in the trochanteric anastomosis

c) **Transverse branch**: shears in the cruciate anastomosis

C) Perforating arteries .

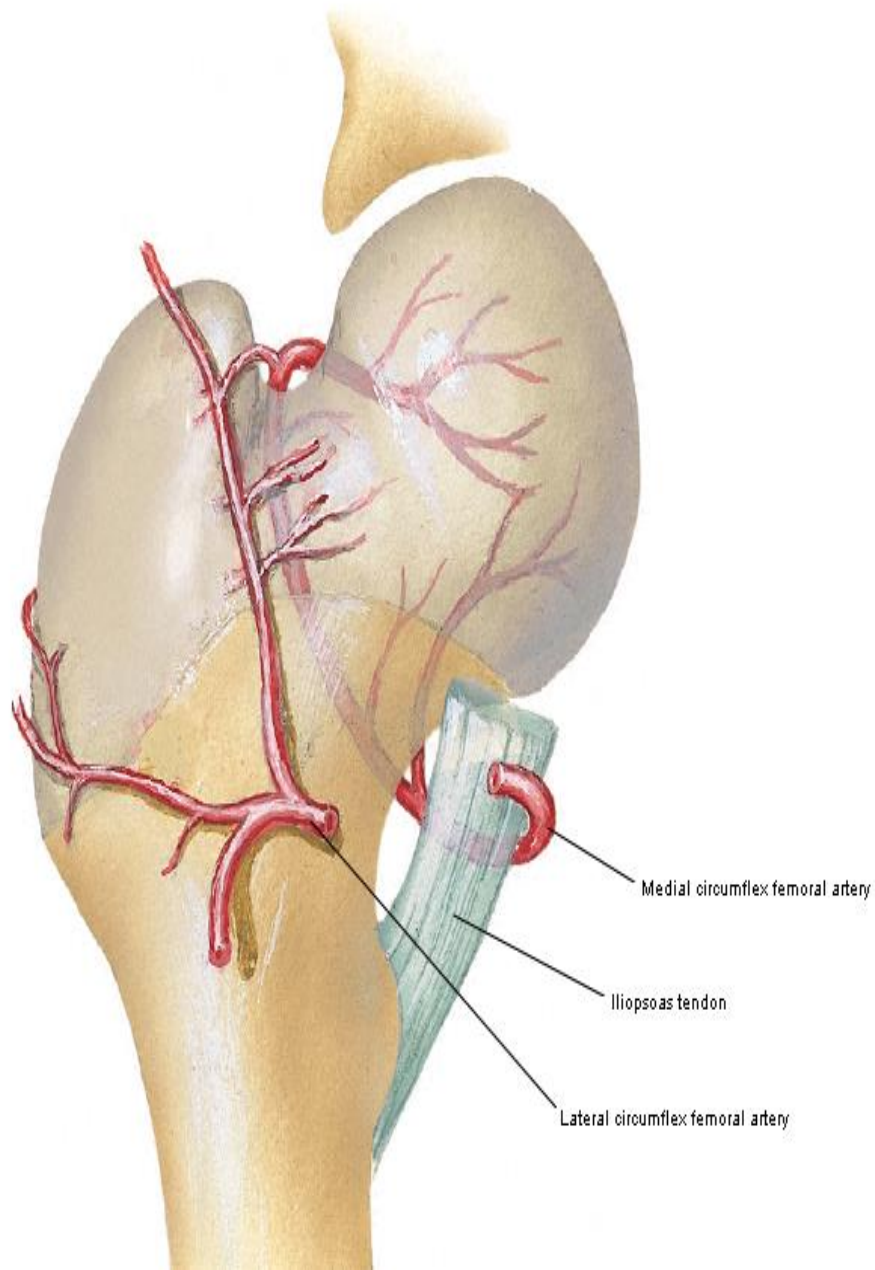
The profunda femoris artery gives off perforating branches.

The first three arteries arise as branches of the profunda femoris artery, while the fourth one is the termination of the profunda femoris artery



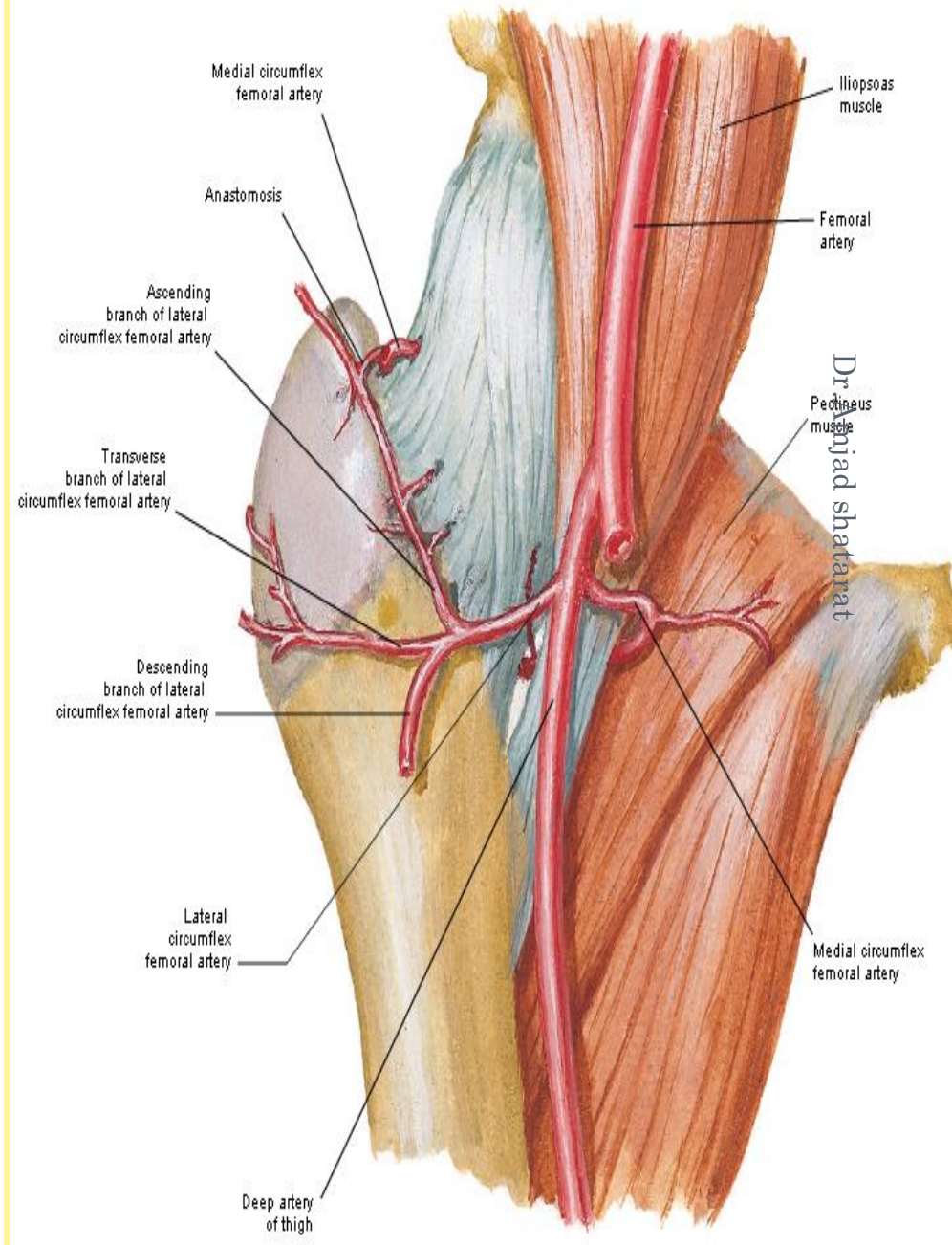
Arteries of Femoral Head and Neck

Femur of Child - Anterior View



Arteries of Femoral Head and Neck

Anterior View In Situ



Read only

In the lower part of its course, the femoral artery passes behind the **sartorius (deep)** muscle in the subsartorial canal (adductor canal).

**Relations of the femoral artery
In the subsartorial canal**

**Anteriomedially:
Skin and fascia**

**Sartorius muscle and fibrous roof
of the canal**

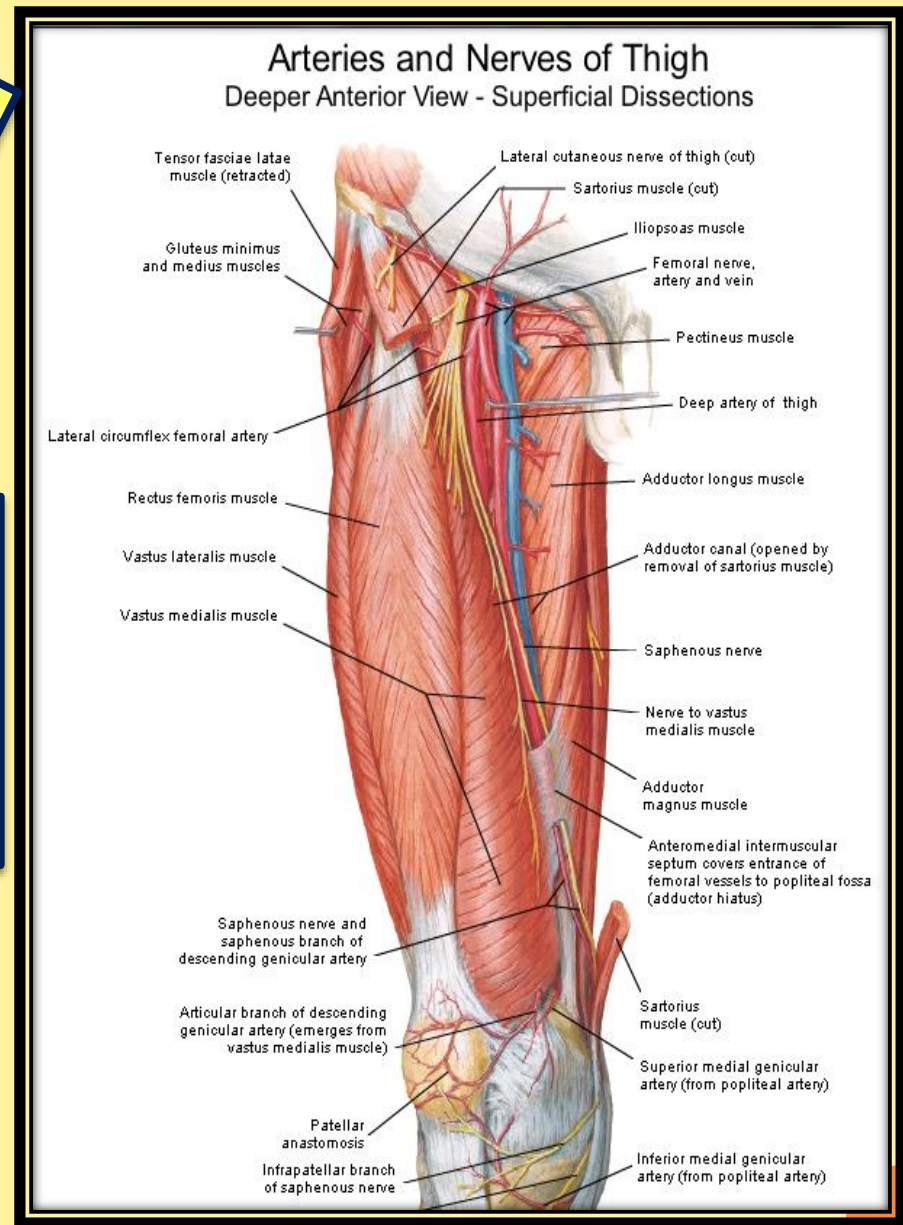
**Saphenous nerve which crosses from
lateral to medial**

Anterolaterally:

vastus medialis

Nerve to vastus medialis

**Posteriorly:
femoral vein**



❖ Branches of the femoral artery in the adductor canal

It gives off only one branch

The descending genicular artery

Other arteries that shear in the blood Supply of the lower limb

Obturator Artery

- The obturator artery is a branch of the internal iliac artery
- It passes forward on the lateral wall of the pelvis and accompanies the obturator nerve
- It gives off muscular branches and an articular branch to the hip joint

