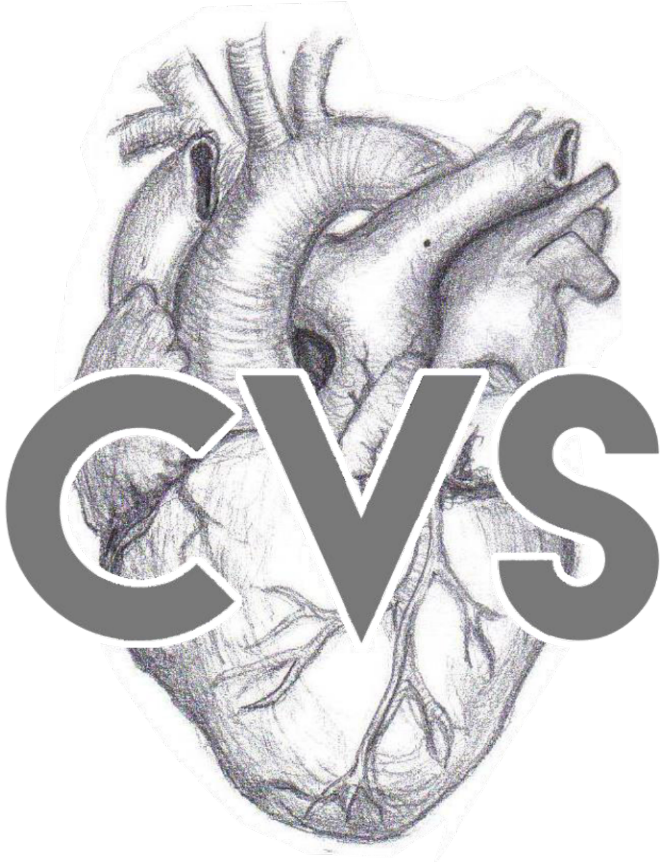

ANATOMY / HISTOLOGY

☑ Sheet ○ Slide ○ Handout

Number

5

Subject

Vessels around the heart

Done By

Lina Mansour

Corrected by

Mohammad Qussay Al-Sabbagh

Doctor

Dr. DBustami

Date: **00/00/2016**

Price:

In this lecture :

- ✓ Coronary arteries
- ✓ Venous drainage of the heart
- ✓ Vessels present at the chest wall
- ✓ Others (فراطة)

I have used the Dr's figures (those in the handout) I think they are fantastic (specially fig.3 :P), However referring to a good atlas is indicated .

Coronary Arteries

Figure1
There are two coronary arteries ;left and right. These arteries :

- ✓ arise from the **ascending** aorta. (in fact the coronary arteries are the only branches of the ascending aorta)
- ✓ Supply the heart itself.

Recall that at the beginning of the ascending aorta we have the aortic valve , the aortic valve is composed of two posterior cusp and one anterior cusp, opposite to each cusp the aorta wall is slightly dilated forming an areas called aortic sinuses.

Right coronary artery

- ✓ Origin : Anterior aortic sinus
- ✓ Course : on the surface of the ❤u can easily observe the course of the right c. artery: -indicated in fig1
    - From its origin, it emerges **between Rt. Auricle and the root of pulmonary trunk**.
    - Runs downward in the **coronary groove** (the groove between Rt. Atrium and Rt. Ventricle)

- At the lower border of the ❤it gives arise to the **marginal branch**.
- Runs backward at the posterior coronary groove where it meet and **anastomose** with the left coronary artery.
- Before its anastomosis it gives a posterior branch, posterior interventricular branch.

✓ Branches of Rt. Coronary :
- Marginal
- Posterior (or Inferior) interventricular
  - ➢ This supply the AV node and AV bundle in 90% of people.
- Nodal
  - ➢ The first branch of the Rt. Coronary , supply the SA node.
- Rt. Atrial
- Terminal

✓ Areas that it supply (areas of distribution) –Figure3
- Rt. Atrium
- Posterior part of the interventricular septum.
- Parts of the Ventricles (as indicated in fig3 – important to refer to)
- Conducting system (SA node , AV node and bundle)

Left coronary artery

✓ The left coronary artery is larger than the right coronary artery (maybe because the left part of the ❤is thicker –personal opinion :P)
✓ Origin: left posterior aortic sinus
✓ Corse : on the surface ,
- Between the **Lt. auricle and pulmonary trunk**.
- Once it emerges on the surface it divides into 2 branches: posteriorly, **circumflex branch** and anteriorly, **anterior interventricular branch** [clinicians call it LAD : Left anterior descending]
- The circumflex is considered as the continuation of the Lt. coronary artery, posteriorly it anastomose with the Rt. Coronary artery through the later posterior continuation.

- ✓ Branches of the Lt. coronary: (indicated at fig1+2)
    - Circumflex branch
        - ➢ Considered as the continuation of the Lt. coronary
        - ➢ Gives arise to obtuse marginal branch (indicated in Fig2)
    - Anterior interventricular branch:
        - ➢ Gives arise to diagonal branch (indicated in Fig2)
    - Branch to the diaphragmatic surface of Lt. ventricle
    - Branch to the Lt. atrium
    - Pulmonary branch
    - Terminal branch

- ✓ Areas of distribution :
    - Left atrium
    - Parts of the Ventricles (as indicated in fig 3)
    - Part of the left branch of the AV bundle

Remember (from sheet1) we stated that the coronary arteries are example on physiological end arteries , which means that there is anastomosis between the left and the right coronaries BUT this anastomosis is not sufficient. Which implies that if a thrombus occlude the posterior interventricular (branch of Rt. coronary artery) for example some of the cardiac muscle will infracts as the anastomosis that come from the circumflex (branch of Lt. coronary artery) is not sufficient.

by now we can conclude that:

- ✓ The main trunks of the Rt. And Lt. coronaries run in the coronary grooves, while their interventricular branches run in the interventricular groove (posterior and anterior)
- ✓ Please remember that the Posterior interventricular is branch of the Rt. Coronary artery and the Anterior IV coronary is a branch of the Lt.

Figure 1-3 are very important

Figure1: Coronary system

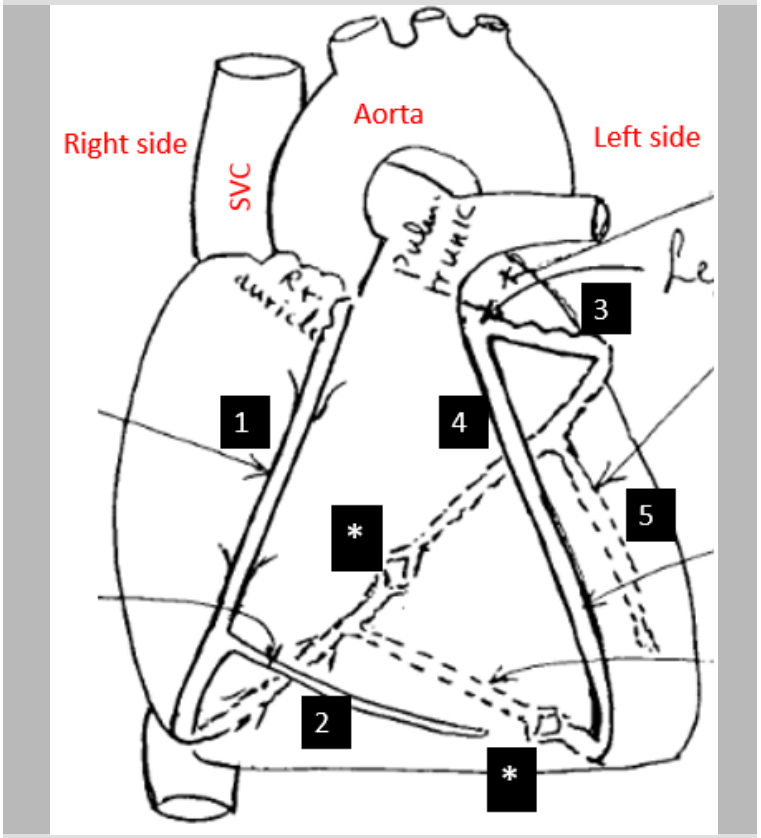

Coronary system is composed of Rt. And left coronary arteries. first , orient ur-self with Rt. And Lt. sides.

1: Rt. Coronary artery (notice how it emerges b/w Rt. Auricle and the pulmonary trunk

2: marginal branch of Rt. C.

* : posterior interventricular artery (anastomose with Lt. coronary branches)

now Lt. coronary branches (not indicated but from the figure u can till that it emerges b/w Lt. auricle and the pulmonary trunk.

3:circumflex branch

4: Anterior interventricular branch

5: Branch to the diaphragmatic surface of Lt. ventricle

Figure2: Lt. coronary branches

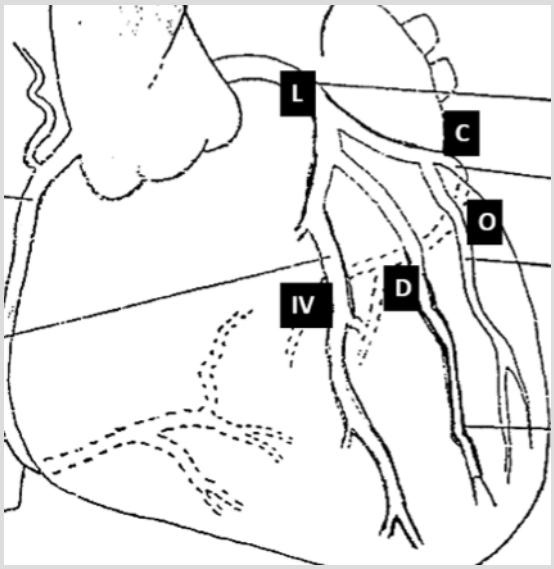

The Left coronary (L) gives rise to two main branches:

1. Circumflex branch (C) that give itself the Obtuse marginal branch (O)
2. Anterior Interventricular branch (IV) that give itself the Diagonal branch (D)

جماعة القلب ناس بحبوا الفيزياء و الرياضيات
الشريان الObtuse سمي هكذا لأنه بعمل زاوية منفرجة بس يطلع من "أصله" ـــيمكنك ملاحظتها من الشكل.

Figure3: ventricles blood supply

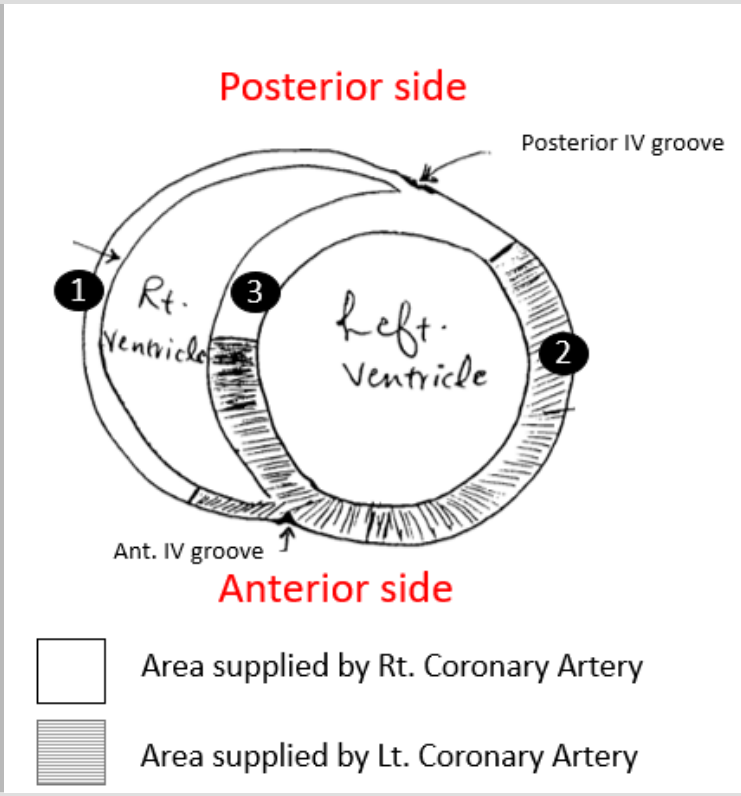

This is a cross section at the ventricles , it shows the blood supply for them:
first orient ur-self with post. And Ant. Sides , secondly read the key of the figure.
1: the right ventricle wall is supplied by the Rt. Coronary artery except for a small anterior part which is supplied by the Lt. coronary.
2: the Left ventricle is supplied by the Lt. coronary except for a small area posteriorly supplied by Rt. Coronary.
3: the Interventricular septum is supplied by the Rt. Coronary posteriorly and the Lt. coronary anteriorly.

Venous Drainage of the Heart

Figure4

As any muscle , the cardiac muscle has venous drainage. Most of this drainage is collected in the coronary sinus.

The coronary sinus is situated between the left atrium and ventricle posteriorly at the left posterior part of the coronary groove, when collecting blood it drain into the Rt. Atrium posterior wall.

Tributaries of the coronary sinus :

1. Great cardiac vein
    - This vein start anteriorly , accompanies first the anterior Interventricular and then the left coronary artery.
    - It winds posteriorly.
    - It enter the left end of the coronary sinus
2. Small cardiac vein
    - Runs anteriorly, Accompanies the Rt. Coronary artery.
    - Winds posteriorly.
    - Open at the Rt. End of the coronary sinus.
3. Middle cardiac vein
    - Runs with posterior interventricular branch
    - Opens at the Rt. End of the coronary sinus.
4. Posterior vein of left ventricle
    - Runs on the diaphragmatic surface of left ventricle
    - Opens at the middle of the coronary sinus
5. Oblique vein of left atrium (oblique vein of Marshall)
    - Small, Situated at the Posterior surface of the Lt atrium.
    - Drain into the Lt. end of the coronary sinus.
    - Clinically important :as it can get larger –embryonically- to form Left superior vena cava. Unlike the normal (Rt.) SVC this Lt. SVC does not open directly in the Rt. Atrium but rather it opens first in the coronary sinus then the later drain into the Rt. Atrium.

Notice We have said that most (not ALL) of venous blood drain into the coronary sinus through its tributaries, in fact some of venous blood drain into the cavity of the heart, How?

there are small veins impeded in the wall of the heart muscles called **venae cordis minimae** (old name: The besian veins) these –like the coronary sinus but to a lesser extant- collect venous blood from the wall of the heart and drain it directly to the heart cavity.

Figure4: venous drainage of the heart

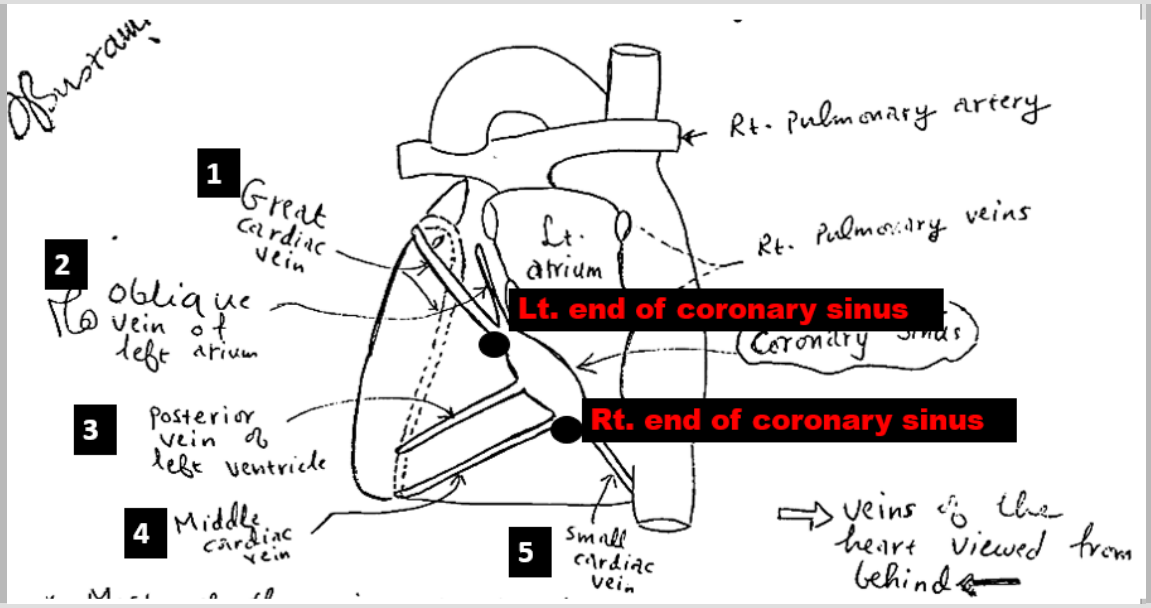

The tributaries are well indicated in this figure , make sure that you can identify them.

notice 1, 2 drain to the left end of the coronary sinus.

3 >> opens in the middle of the coronary sinus

4,5>> the Rt. End of coronary sinus.

Anastomosis between cardiac vessels :

The anastomosis can be of two types cardiac or extracardiac.

First. **Cardiac Anastomosis**

represented by the two coronary arteries anastomosis with each others, which could be superficial or deep in the myocardium.

put in mind when we talk about anastomosis of coronary arteries >> we are not talking about superficial anastomosis (this present at the surface of the heart but rather we are talking about the deep anastomosis (which present within the cardiac muscle) , because as we said the superficial anastomosis of the two coronaries is not adequate>> normally the deep anastomosis is present in less than 10% of anastomosis of a normal induvial . if the patient is anemic this percentage become 40% and if the person had a myocardial infraction (one of the coronaries has occluded) the percentage become 100%.

[I'm not sure but I think that the total percentage represent the superficial anastomosis plus the deep]

Second. Extracardiac anastomosis

this type of anastomosis occur far from the cardiac surface , and could be:

a. Between coronary arteries and vasa vasora of aorta and pulmonary trunk [rem. vasa vasora are vessels of the vessels –from sheet1]
b. Between coronary arteries and the internal thoracic artery (an important branch of the subclavian, it itself give anterior intercostal arteries when it branches]
c. Between the coronary arteries and the bronchial arteries
d. Between the coronary arteries and the phrenic arteries [phrenic arteries are branches of the descending aorta]

Notice

- ✓ (a) occur within the pericardium sac (as the root of the great vessels are still there) while (b-d) anastomosis occur out of the pericardium.
- ✓ All of these anastomosis are insufficient in case of MI emergency.

Question : **what determines the blood flow of the coronary arteries ?**

1) as branches of the ascending aorta, the coronary arteries are affected by the both the blood volume and pressure of the aorta.
2) also as some branches of the coronary arteries are within the myocardium a good blood flow within these branches is restricted to the diastolic phase, while in systolic phase the myocardium is contracted the vessels are squeezed and the blood flow get lesser.
3) Also during systole the ventricles intra-pressure increases which implies more constriction among these vessels.

To sum up we have one factor that enhance the blood flow within the coronary arteries which is the aortic pressure, and two factors that compromise the blood flow within these vessels which are the compression during systole phase and ventricles intra-pressure.

Question **which vessel has greater blood flow the Rt. Or Lt. coronary ?**
to answer such Q , recall that the Rt. Supply mainly the Rt. Ventricle which has a thinner wall and has 25 mm Hg intrapressure during systole . While the Lt. supply the Lt. ventricle mainly which has a thicker wall and has 120 intrapressure during systole.
we stated that the wall imply two inhibitory effects on the blood flow (more systole contraction and more ventricles intrapressure) >>then the Lt. ventricle must have a lower blood flow. In fact the Rt. Coronary is not that much affected (by the inhibitory effect of its wall) to the extant that it has a good flow during systole and diastole.

Vessels present at the chest wall

,note : chest wall and thoracic wall are interchangeable names

Azygous veins , figure5

Important vein that connect SVC and IVC >> this implies that if the SVC get occluded by a thrombus for example >> the blood of the SVC can still reach the Rt. Atrium through the IVC after passing through the azygous vein , it drains the thoracic wall and upper lumbar region. The azygous drain into SVC.

Intercostal vessels (arteries and veins)

- Generally speaking these vessels run with their correspond rib.

posterior Intercostal veins (please look at Fig5 while studying the following)

- The first intercostal vein (Rt. And Lt.) drain into Rt. And Lt. brachiocephalic vein , respectively.
- The second , third and forth intercostal veins unite and make **superior intercostal vein**>> on the Lt. side this vein will drain into the Lt. brachiocephalic , while on the Rt. Side it will drain into the Azygous vein.
- From fifth to 12th intercostal veins on the Rt. Side >> these also drain to the azygous vein
- On the left side 5th -8th intercostal veins unit to form **Accessory hemiazygos vein** , while the union of the 9th – 12th intercostal veins form **hemiazygos vein**.
  both hemiazygos and accessory hemiazygos drain into the azygos vein eventually.
  Notice the 12th intercostal vein is considered subcostal not intercostal

Posterior Intercostal arteries

- the anterior intercostal arteries are branches from the internal thoracic artery (we are not gana talk about these).
- The posterior Intercostal arteries are branches of the descending aorta except the 1st and 2nd these are branches of superior intercostal artery which is a branch of **costocervical trunk** which itself is a branch from the subclavian artery.
- Right posterior intercostal arteries are longer than the left posterior intercostal arteries , why?
  because as we said these are branches of the descending aorta which itself is deviated to the left.
- Important relation –indicated at Fig6
  the **Sympathetic chain** is ANTERIOR to RIGHT posterior intercostal arteries.
  also the azygous vein and the thoracic duct are anterior.
  Clinical correlation there is a group of diseases Known as occlusive diseases of the arteries of the lower limb in the past they tend to treat such condition by cutting the sympathetic chain >> NO MORE VASOCONSTRICTION >> in this "cutting" procedure there are always a risk of cutting the Rt. Posterior intercostal artery.>> cutting of this artery produce heavy bleeding.

Superior vena cava (SVC) figure7

- Collect venous blood from the upper half of the body
- Its lower part is inside the pericardium (with the company of the pulmonary trunk and ascending Aorta), while its upper part is out of it.
- formed by the union of Lt. and Rt. Brachiocephalic veins
- each brachiocephalic is formed by the union of the internal jugular (bring blood from head, neck and brain) and the subclavian (which bring blood from the upper limb) on each side.

- The SVC begins behind the lower border of the Rt. first costal cartilage (here the union of the two brachiocephalic veins occur)
- It pierces the pericardium opposite the 2nd Rt. Costal cartilage
- It receives the azygos vein just before it enter the pericardium
- Opposite the 3rd costal cartilage it opens into the Rt. Atrium (its upper part)
- Important relations :
  -Medial to the SVC is the ascending Aorta
  -lateral to the SVC is the phrenic nerve and the Rt. Pleura and lung.
- **Occlusion of the SVC:**
  what can occlude the SVC? A lot of things, like enlarged lymph node inside the thorax, remember that the SVC can easily be occluded as its wall is thin.
  Note the IVC is most commonly occluded by carcinoma of the liver (recall IVC hepatic groove, from GI)
  what will happen if the SVC is occluded –other than the azygous vein thing-? –look at fig8
  the azygous vein connect between SVC and IVC , DEEPLY.
  there is another deep connection (inside the rectus sheath) will be discussed soon.
  there is another "system" that can connect between the two cavas SUPERFECIALLY >> we care about this more to diagnose SVC occlusion , as it is VISIBLE.
  HOW? –look at fig8 please
  we want to connect SVC with IVC, so this connection must contain SVC-side and IVC side.
  The SVC side of the connection
  we have stated that the SVC is the union of the 2 brachiocephalic veins , each brachiocephalic vein is composed of internal jugular and subclavian vein.
  now this subclavian vein was axillary vein in the upper limb. The axillary vein has a branch called lateral thoracic vein , which itself have a branch called **thoraco-epigastric vein.**

The IVC side of the connection
the IVC is made of the union of the two common iliac veins , each common iliac vein is formed by the union of external and internal iliac veins , the external iliac vein was femoral vein in the lower limb. now this femoral vein has a branch called **superficial epigastric vein**.

thoraco-epigastric vein and superficial epigastric vein anastomose with each others.
when the SVC is occluded the blood will flow back to the axillary vein then until it reaches the thoraco-epigastric vein. From the prevous explained anastomosis the thoraco-epigastric shifts the blood to Sup. Epigastric then blood reach the IVC.
Note this "pathway" is also valid for the occlusion of IVC –but the other way around.
if this "pathway" get activated >> superficial tortuous veins will appear at the chest of the patient.
we can differentiate between SVC and IVC occlusion by observing the direction of the blood flow (if it was downstream then >> SVC is occluded , upstream IVC occlusion)

Another DEEP connection , inside the rectus sheath the superior epigastric vein anastomoses with the inferior epigastric vein.
the superior epigastric vein represent the SVC side of connection , as it's branch of the internal thoracic vein branch of subclavian.
the inferior epigastric vein represent the IVC side of connection it is a branch of interior epigastric vein branch of the external iliac >> common iliac >> IVC.
FIGURE 8 WILL MAKE UR LIFE EASYIER

Figure5: post. Intercostal veins and azygous system

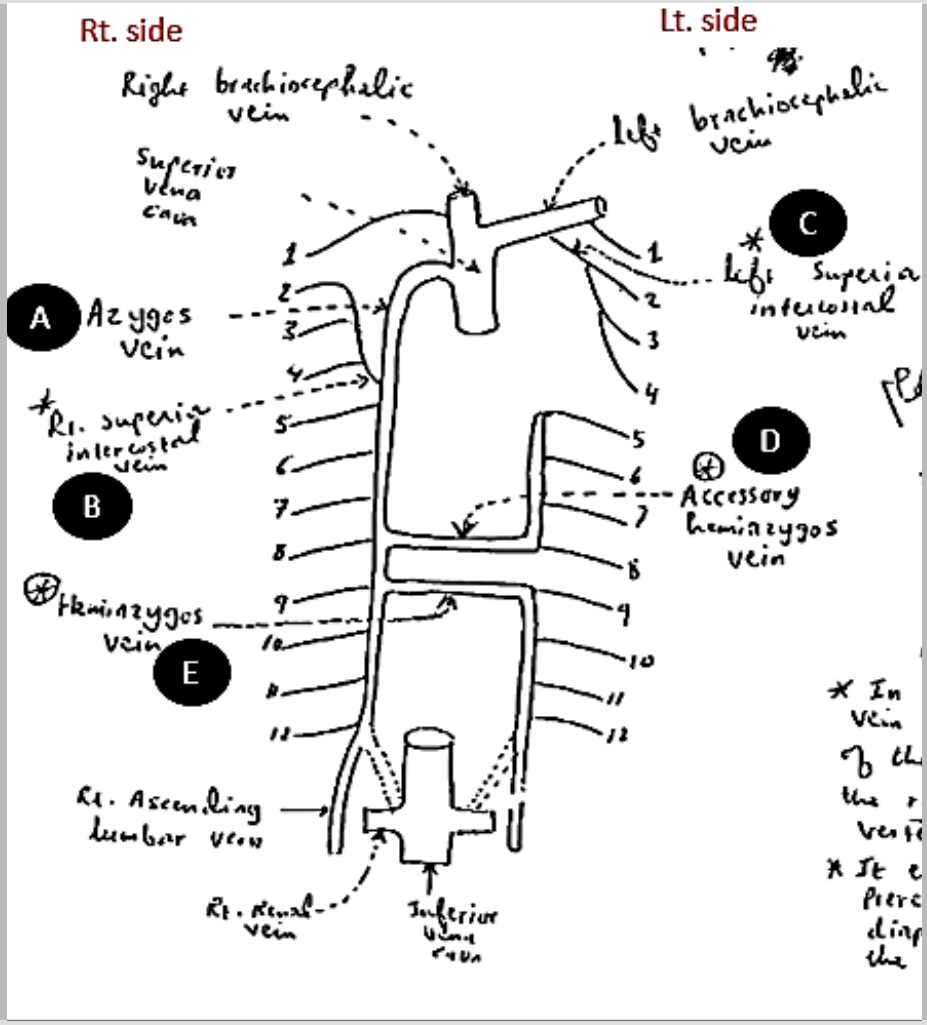

Well indicated -

Figure6 : the sympathetic chain (S) is anterior to the Rt. Post. Intercostal arteries (A)

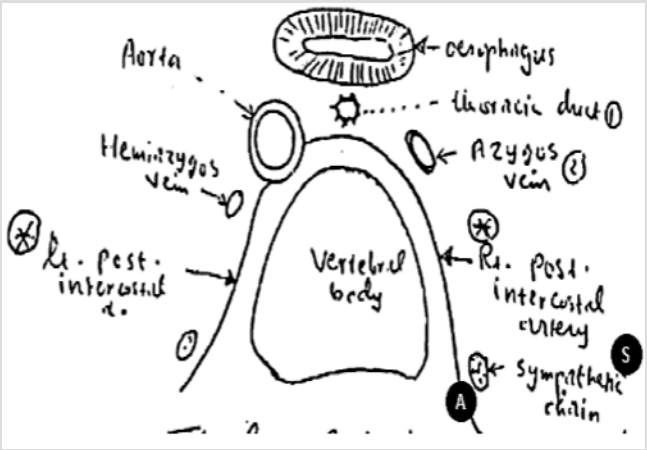

Figure7 : SVC

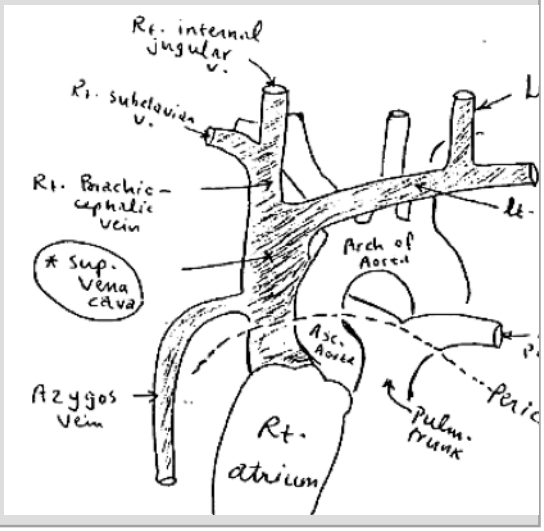

Figure8: Deep Vs Superficial anastomosis between SVC and IVC

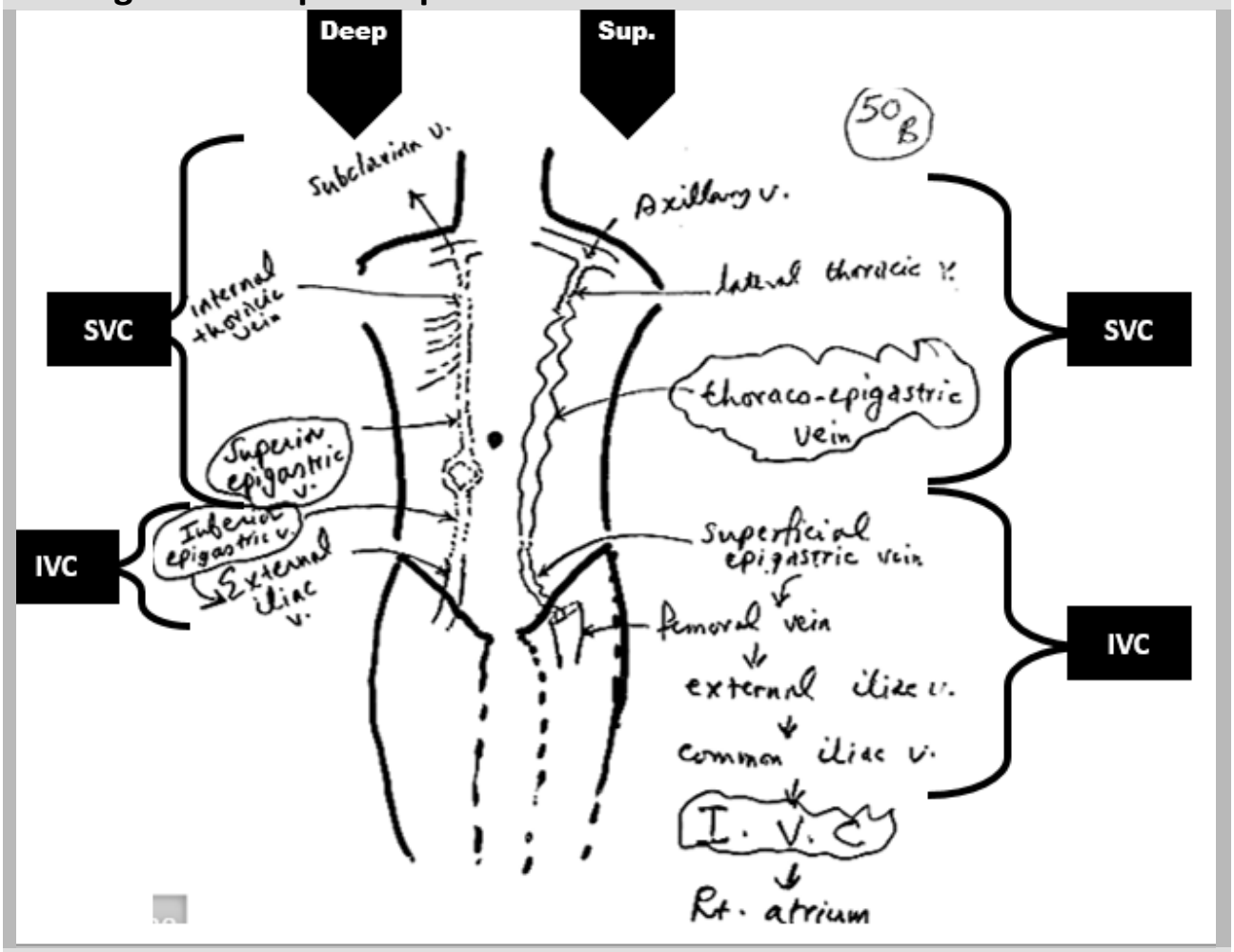

Well indicated -

Clinical correlation

there is a procedure called : **To Put a central venous line** we use it In case we want to measure the blood pressure of the Rt. Atrium (also called central venous pressure) **>>** this is indicated with a patient that present suddenly with extreme low blood pressure – we do this procedure to figure if his low BP is caused by hemorrhage (Internal or external) or weakening of the pumping activity of the heart (MI for example)

in case of hemorrhage the central venous blood >> LOW >> management : hydrate the patient or give him blood.

in case of weakening of the cardiac muscle the central venous pressure >>High >> stimulate the heart.

how to make this procedure ?
by inputting a needle in the Rt. Internal jugular>> from internal jugular the needle can reach the Rt. Atrium through the brachiocephalic then the SVC.
where is the internal jugular exactly ?
between the two heads of sternocleidomastoid muscle (this muscle have one origin from the sternum and another one from the clavicle , u may remember it from MSS)

Another approach

Input the needle into the subclavian (under the clavicle).

Aorta ,fig9

- **Ascending Aorta**
  present inside the pericardium, in the middle mediastinum. It starts in the aortic orifice (guarded by the aortic semilunar valve) at the Lt. ventricle , this orifice is opposite to Lt. 3rd costal cartilage.it runs upward and to the Rt. It eliminate opposite the 2nd costal cartilage in the pericardium. It gives two coronary branches only.
- **Arch of the Aorta**
  the Arch 'arches from anterior to posterior plane across the bifurcation of the trachea. It ends and start at the same level ; anteriorly at the level of the sternum angle and posteriorly at the level of the lower border of T4.
  surface anatomy : the arch is behind the lower half of the manubrium.
- **Descending Aorta**
  posterior to the heart (at the posterior mediastinum).
  Important relation to it : anterior to it is the Lt. Atrium BUT not directly related ; the Lt. atrium is separated from the descending aorta by the pericardium and its oblique sinus.
  it start at the level of T4 and terminate at T12.
  it gives a lot of branches : posterior intercostal arteries (except the 1st and the 2nd) also supply the middle third of the esophagus, also give

branches to the pericardium, superior phrenic arteries , two left bronchus arteries.

Note the lung have dual blood supply pulmonary (for gas exchange) and bronchial (this what supply the lung truly)

Relations of the Arch

- ✓ **Above the level of the arch , figure10**
  - 3 branches of the arch of the aorta (brachiocephalic trunk , Lt. common carotid and Lt. subclavian.
  - Lt. brachiocephalic vein >> this pass in front of all arch branches
  - Thymus gland
- ✓ **Inferior relations of the arch of the aorta , figure11**
  - Bifurcation of the pulmonary trunk (bifurcate into Lt. and Rt. Pulmonary arteries , the Lt. is short while the Rt. Is long and runs behind the ascending aorta and the SVC)
  - Left bronchus
  - Ligementum arteriosum (this runs from the Lt. pulmonary artery to the end of the arch , in the fetus it was 'ductus" and it used to transfer venous blood)
    its blood will go to the lower half of the body through the descending aorta.
    anterior to Ligementum arteriosum : superficial cardiac plexus (sympathetic , parasympathetic)
    posterior to Ligementum arteriosum : Left recurrent laryngeal n. (branch of Lt. vagus)
    recall from the lab : this n. is inferior to the arch , posterior to Ligementum arteriosum and when it winds posteriorly it winds between the esophagus and trachea.

note the Lt. bronchus lies directly on the esophagus narrowing it (congenitally – important info when u preform endoscopy) , which implies that any tumor of Lt. bronchus can affect the esophagus and vise verse.

(5 X 5) –figure12

- ✓ **Anterior and to the left (superficial relations)**
  - Left phrenic nerve
  - Lt vagus nerve
  - Lt. superior intercostal vein (deep to phrenic but superficial to vagus)
  - 2 cardiac nerves (sympathetic and parasympathetic) +superficial cardiac plexus
  - Lt. pleura and lung
- ✓ **Posterior and to the Rt. (deep) relations**
  - Trachea (with deep cardiac plexus)
  - Esophagus
  - Lt. recurrent laryngeal nerve (in the groove between trachea and esophagus
  - Thoracic duct (on the Lt. side of the esophagus)
  - Ventricle column

Recall the parasympathetic do not supply the ventricles.
figures 10-12 summarize relations of the arch.

Figure10 : sup. Relations to the arch

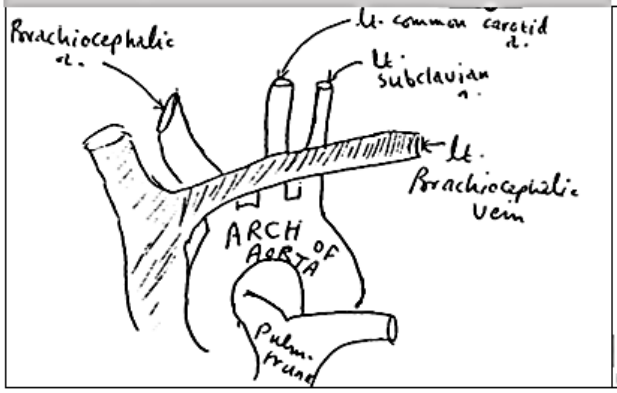

Figure11 : Inf. Relations to the arch

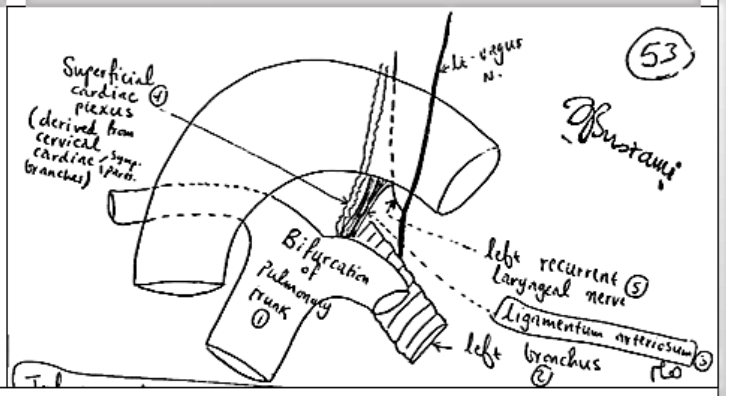

Figure11 : Inf. Relations to the arch

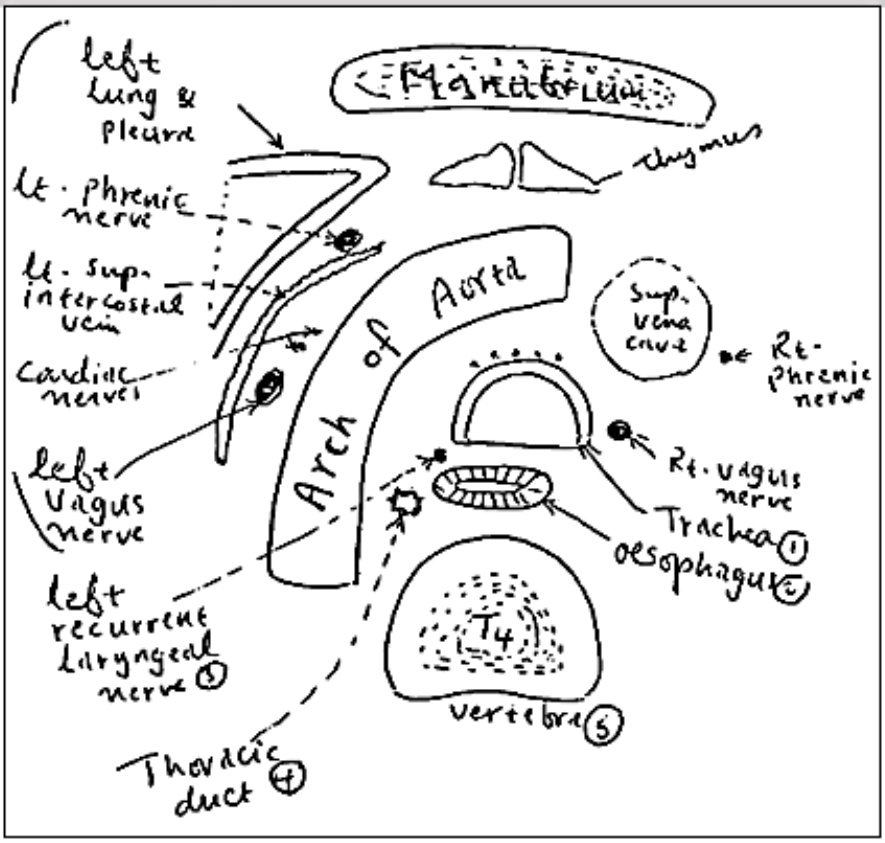

Heart auscultation

auscultation =Listening to the heart, when you want to physically examine the heart one of the things that u are going to do is putting ur stethoscope on the chest of the patient and hear his heart sound.

to do this u must know WHERE to put it.
recall : in a healthy induvial we hear sounds when the valve closes only.
so we must know where to hear these closure sounds.

Also some pathologies create abnormal heart sounds that can be detected (like in mitral stenosis)
the Dr. really just read this table and diagram so look at it and memorize it ☺

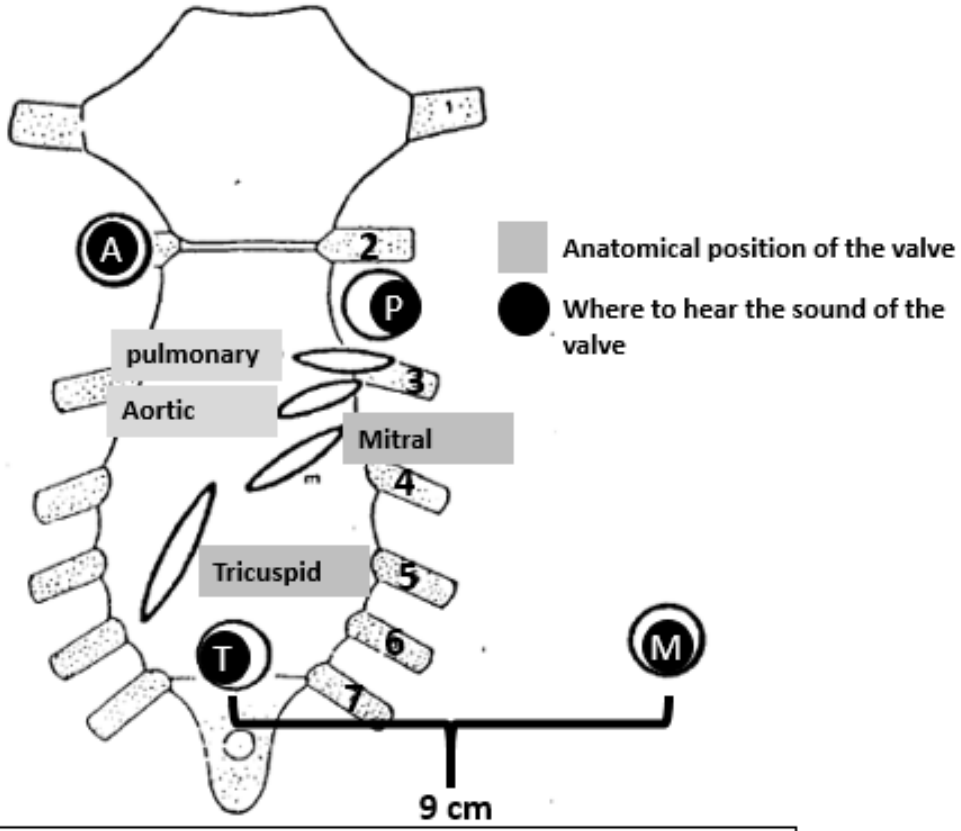

Fig. 173 Surface marking of the cardiac valves ; p = polumonary, a = aortic, m = mitral, andt = tricuspid. The position of the auscultatory areas is shown by circles and they are named by block letters.

Table 18. Surface marking of the cardiac valves, and the sites of the auscultatory areas

Valve	*Diameter of orifice*	*Surface marking*	*Auscultatory area*
1. Pulmonary	2.5 cm	A horizontal line, 2.5 cm long; behind the upper border of 3rd left costal cartilage and adjoining part of the sternum.	Second left interspace near the sternum.
2. Aortic	2.5 cm	A slightly oblique line, 2.5 cm long; behind the left 1/2 of the sternum at the level of the lower border of the 3rd costal cartilage.	Second right costal cartilage near the sternum,
3. Mitral	3 cm	An oblique line, 3 cm long; behind the left 1/2 of the sternum opposite the 4th costal cartilage.	Cardiac apex. 5th intercostal space, 9 cm to the Lt. from the middle line
4. Tricuspid	4 cm	Most oblique of all valves, being nearly vertical, 4 cm long: behind the right 1/2 of the sternum opposite to the 4th and 5th spaces.	Lower end of the sternum.

Surface anatomy of the heart

by knowing the surface anatomy of the heart we can know its size.
it's all about knowing how to draw the borders of the heart. (these are summarized in these upcoming figures)

The *upper border* is marked by a straight line joining (i) a point at the lower border of the 2nd left costal cartilage about 1/2 inch (1.3 cm) from the sternal margin to (ii) a point at the upper border of the 3rd right costal cartilage 1/2 inch (1.3 cm) from the sternal margin.

The *lower border* is marked by a straight line joining (i) a point at the lower border of 6th right costal cartilage 2 cm from the sternal margin to (ii) a point at the apex of the heart in the 5th intercostal space 3½ inches (9 cm) from the midsternal line.

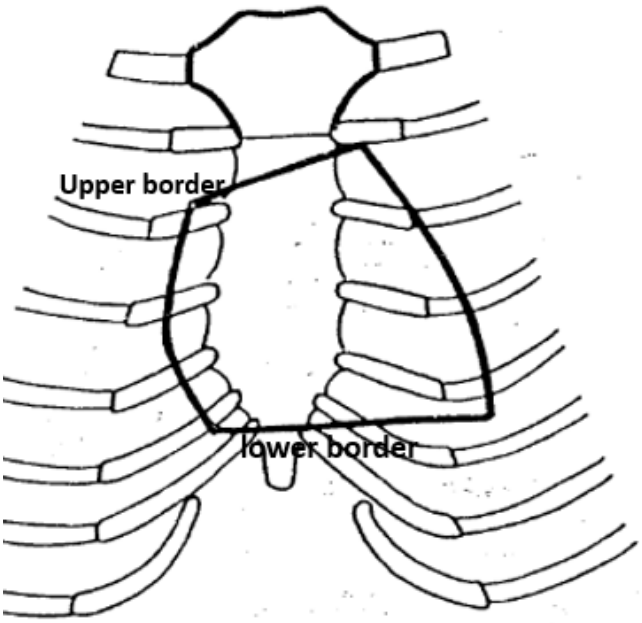

Note : ½ inch = 1.3 cm

Lt. sided heart failure :

- ✓ Weakening of the Lt. ventricle
- ✓ This have “backward effect “ which means that the blood will accumulate in the Lt. Atrium and “forward effect’ the blood flow from the heart is affected.(the cardiac output (CO) and the SV decrease)

backward effects:

- ✓ The end diastolic volume within the ventricle will increase (the blood that the ventricle receive but does not get pumped).
- ✓ Increase volume and pressure at the Lt. atrium.
- ✓ The blood get back to the pulmonary circulation.>> the lungs get congested.
- ✓ The pulmonary capillary bed pressure increase >> then the filtration increase>> pulmonary edema>> this affect oxygenation of blood.
  [if this come as attack “acute’ the patient may dye]

Forward effects :

- ✓ C.O (Cardiac output) decreases (the amount that the Lt. ventricle pump to the body)
- ✓ Systemic arteriolar blood pressure will decrease (as the CO decreases) >> the blood that reach Tissues is significantly reduced>> fatigue and dizziness.

The kidney will respond:
when the kidney feels that it is deprived of blood >> it secret Renin.
Renin-angiotensin-aldosterone system will induce vasoconstriction which will increase the blood pressure.
Aldosterone will induce retention of Na^+ and H_2O >> this also increase the BP.
eventually this compensatory effect will also fail.

END OF TEXT :3