# The Endocrine System

## Anatomy

☑ Sheet ☐ Slide ☐ Handout

| | |
|---|---|
| Number: | 1 |
| Subject: | Pituitary gland |
| Done By: | Omar Mahafza |
| Corrected by: | Mohammad Daas |
| Doctor: | Abdurrahman Shdeifat |

Date: **20/6/2016**

Price:

بسم الله الرحمن الرحيم

- **Endocrine system:** the collection of glands that produce hormones that regulate metabolism, growth and development, tissue function, sexual function, reproduction, sleep, and mood, among other things.

- A small comparison:- Endocrine system **vs** Exocrine system
  - Endocrine system: products are released directly to blood going to distant organs
  - Exocrine system: products are released to a cavity (e.g. intestine/gut & lacrimation)

- Paracrine system: product of cells affect adjacent cells

- Endocrine glands generally are:–
  - Pituitary gland
  - Thyroid gland
  - Parathyroid glands
  - Adrenal gland
  - Pancreas islets
  - Gonad system (Ovaries & Testicles)

- In general, endocrine cells are epithelial.

- Endocrine cells can have different embryological & anatomical structures.

- The relation between endocrine system & nervous system are intimate (correlated); some hormones that are product of endocrine system can be released by the nervous system, especially those of pituitary gland.

- A small comparison:-
  - **Endocrine cells** – release hormones → long-acting & distant effect.
  - **Neural cells** – release neurotransmitters → short-acting & local effect.
    (Both of them are secreted by specialized cells)

- Systemic circulation: Arterial supply – Capillary bed – Venous drainage.
- Portal circulation: Organs take their arterial supply from venous blood, because such organs can't tolerate high blood pressure from arterial blood. (Clinically, this is called **Plication**)

➔➔ Hormones have 2 forms:- Steroids **or** Proteins (amino acid-based)

Endocrine cells that secrete large amount of hormones/proteins have some features including:-

- Abundant **rER** (in case of protein hormones) or **sER** (in case of steroid hormones)
- Well-developed Golgi apparatus
- Abundant granules in cytoplasm

Glandular cells that are rich in steroidal hormones have **lost** the ability to be stained by H&E stain, unlike cells rich in protein/glycoprotein hormones that **can** be stained.

# Pituitary gland (الغدة النخامية)

- Latin name of pituitary gland is hypophysis cerebri (hypo=below, physis=growth)
- The reason behind naming it the pituitary gland is that the Greek anatomists thought that it produces the nasal mucus.
- Portal system is an important landmark in pituitary gland! (also in GI system)
- General structure of the pituitary gland; It contains:-
  - **Anterior lobe** *(Adenohypophysis)*
  - **Posterior lobe** *(Neurohypophysis)*
  - **Intermediate lobe** *(Pars Intermedia)*
  - **Infundibulum/Stalk** (connects it to the Hypothalamus) ~~~ (sometimes considered as part of the posterior lobe)

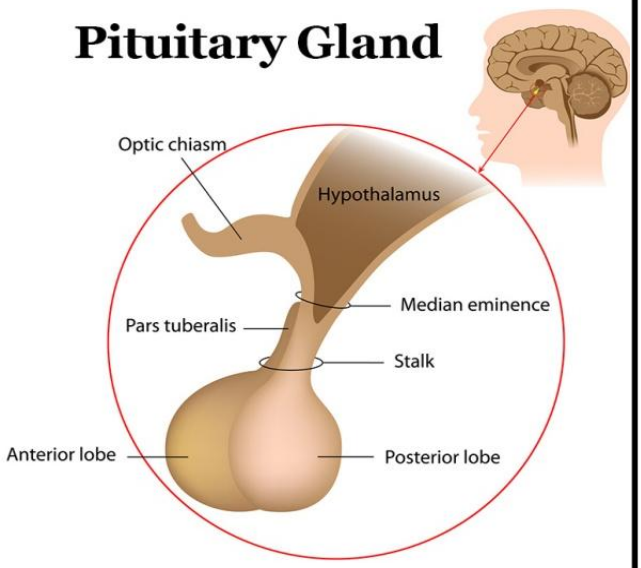

Important Note: **Histology** of endocrine cells (specifically, in Pituitary glands) is a two-dimensional study of a three-dimensional reality!

## ➢ Embryology of the pituitary gland:- (Origin from epithelial ectoderm)

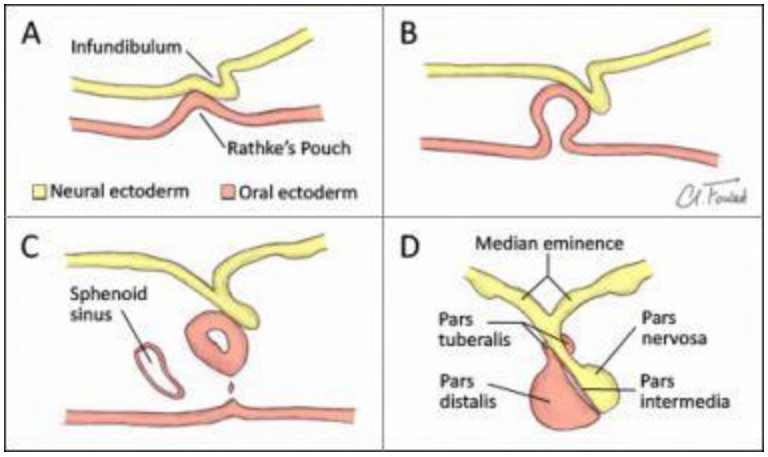


- Anterior lobe: adenohypophysis originates from <u>Rathke's pouch</u> in the hypopharynx (oral ectoderm) – The pouch invaginates superiorly from upper pharynx toward the base of skull, then segregation from the oral ectoderm occurs in step 3, forming the lobe.
- Posterior lobe: neurohypophysis is a protrusion that originates from the <u>medial eminence of hypothalamus</u> (neuro ectoderm) – The protrusion invaginates inferiorly toward the hypopharynx.

## Implications resulting from abnormal embryology:-

- **<u>Rathke's cleft cyst</u>** – An abnormality where remnants of the tract of the pouch between the oral cavity and cranial cavity is found.
- **<u>Congenital anomalies</u>**

## ➢ Anatomy of the pituitary gland:-

❖ The soft tissue of the pituitary gland lies on the "**sella turcica**" in the skull & it's well protected because of its important functions (e.g. Cortisol secretion).

Dimensions of the pituitary gland:

- 12 mm in transverse diameter
- 8 mm in anterior-posterior diameter
- 0.5 grams in adult

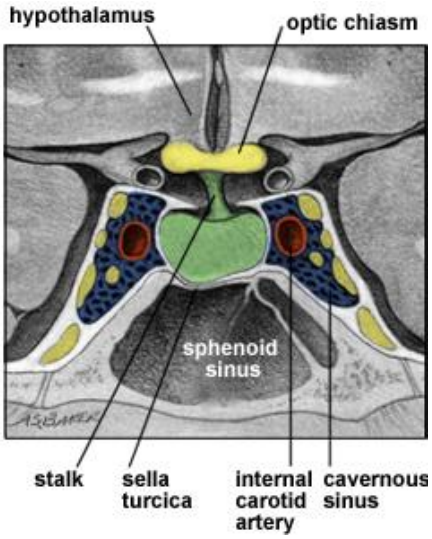


Structures lying around the pituitary gland:

- Optic chiasm
- Hypothalamus
- Cavernous sinus

*(Inside the cavernous sinus lies the Internal carotid artery & cranial nerves (III, IV, VI, V1, V2).*

*So, any abnormality in the pituitary gland could damage one of these nerves or any structure lying around it. for example: Pituitary macroadenoma)*

### ❖ Blood supply:

- **Superior hypophyseal artery –** direct branch from the internal carotid artery, it mainly supplies the infundibulum (stalk) & anterior part.
  (Major blood supply for the pituitary gland).

- **Inferior hypophyseal artery –** branch from meningeohypophyseal trunk of internal carotid artery, it mainly supplies the posterior & inferior parts.

  Note: These two arteries do not supply the gland directly; they supply other organs and give terminal branches that undergo venous outlet, giving venous supply to the gland. (Remember, we said the circulation in the pituitary gland is portal circulation).

- So, what is the major blood supply to the pituitary gland?

✓ Superior hypophyseal artery

- What is the main blood supply for adenohypophysis / infundibulum?

✓ Superior hypophyseal artery

- What is the main blood supply for neurohypophysis?

✓ Inferior hypophyseal artery

Note: Hypothalamus is related to the pituitary gland in terms of blood supply; some blood supply if cut, both the hypothalamus and the gland won't be functioning well (Common in surgeries).

## ❖ Circle of Willis:-

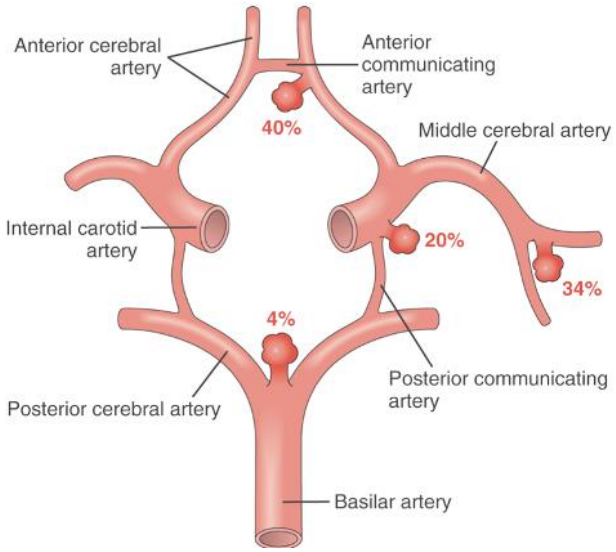


Consists of:

- Internal carotid artery
- Anterior cerebral artery
- Posterior cerebral artery
- Anterior communicating artery
- Posterior communicating artery

These arteries form an enclosed circle that lies superior to the pituitary gland.

❖ One example for the intimate relationship between the endocrine system & neural system is the relationship between the pituitary gland & hypothalamus;

Nuclei in the hypothalamus that could affect the pituitary gland are mainly supraoptic nucleus & paraventricular nucleus. They send a bulk of neurons in the hypothalamic pituitary tract through the infundibulum & control the neurohypophysis (posterior lobe) of the gland.

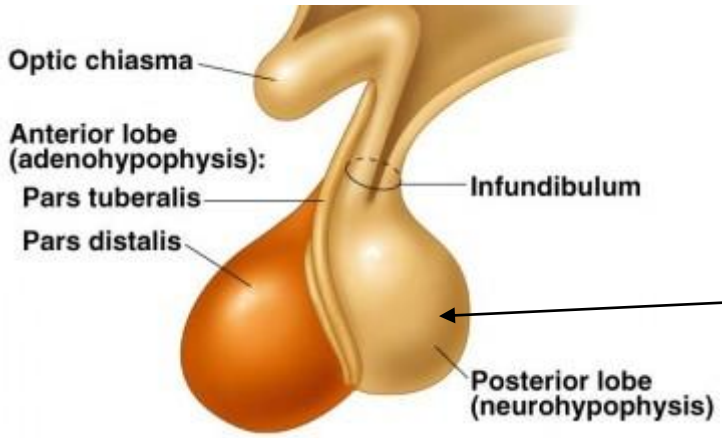


Anterior lobes consist of:
pars tuberalis & pars distalis

Posterior lobe consist of:
pars nervosa & infundibulum

❖ Venous drainage:

It drains into the cavernous sinus.

P.S.) There is a major connection between the 2 cavernous sinuses through the intercavernous sinuses that lies inferior to the pituitary gland.

## ❖ Classical histopathological staining classification:-

❖ (ADENOHYPOPHYSIS)

Adenohypophysis cells are divided into: chromophils and chromophobes.

- Chromophobes (according to function)
  - Poorly-stained
  - Mainly Stem cells
  - Large cells
  - Scattered & non-functioning
- Chromophils
  - Well-stained
  - Well-functioning
  - Divided to acidophils & basophils

Type of secretions from different chromophils:-

- Acidophils:

  a) **Somatotrophs** (Major; 50% of chromophils & occur in clumps) → Secretes growth hormone (GH); a protein hormone, so it's abundant in rER & is called insulin-like growth factor.

  b) **Mammotrophs** → Secretes prolactin.

- Basophils:

  a) **Gonadotrophs** → Secrete FSH & LH (important in both males & females).
  Importance in males: Indirectly stimulates spermatogenesis & increase libido (sexual desirability).

  b) **Thyrotrophs** (Only 5% of adenohypophysis) →Secrete thyroid-stimulating hormone (TSH).

  c) **Corticotrophs** →Secrete ACTH; allows the adrenal gland to secrete Cortisol.

❖ (NEUROHYPOPHYSIS) ➔ No epithelium, just axons! 2 major hormones.

Its cells can be distinguished by a special stain called "Synaptophysin".

- **ADH** (Antidiuritic hormone, also known as "Arginine Vasopressin" (AVP)) is usually produced by the supraoptic nucleus of neuronal hypothalamus.
  It is responsible for water retention, water secretion, Na+ resorption in distant tubules. So, any problem in ADH results in **diabetes insipidus**.

- **Oxytocin** is usually produced by the paraventricular nucleus of neuronal hypothalamus.
  For females, it helps in contraction of myoepithilial cells of smooth muscle mostly in the breast & uterus.

- Hypopituitarism: decreased secretion of one or more of the hormones produced normally by the pituitary gland.
- Hyperpituitarism: increased secretion of one or more of the hormones produced normally by the pituitary gland.

## Anomalies resulting from Hypopituitarism:-

- Hypogonadism (decrease FSH & LH)
- Dwarfism (decreased GH)
- Acromegaly (excess GH) – Occurs post-pubertal.
- Gigantism (excess GH) – Occurs pre-pubertal.

- Melanocyte-stimulating hormone (MSH): An important hormone secreted by "pars intermedia" of the pituitary gland but in negligible amounts.
- Surgically, to reach the pituitary gland you have to enter the endoscope through the nasal cavity → open the sphenoid sinus → open the floor of sella turcica → open the Dura.

  "Sealing material" is added to prevent CSF leak.

---

**Special thanks to Moe Daas**
**Good Luck <3**