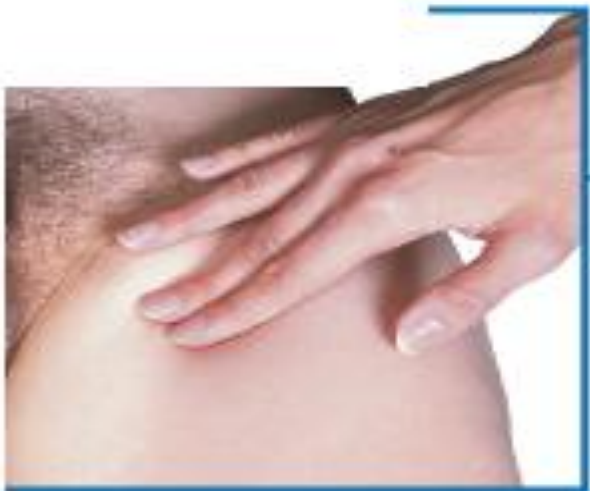

**Where should you palpate the pulse
of
different arteries in the lower limb?**

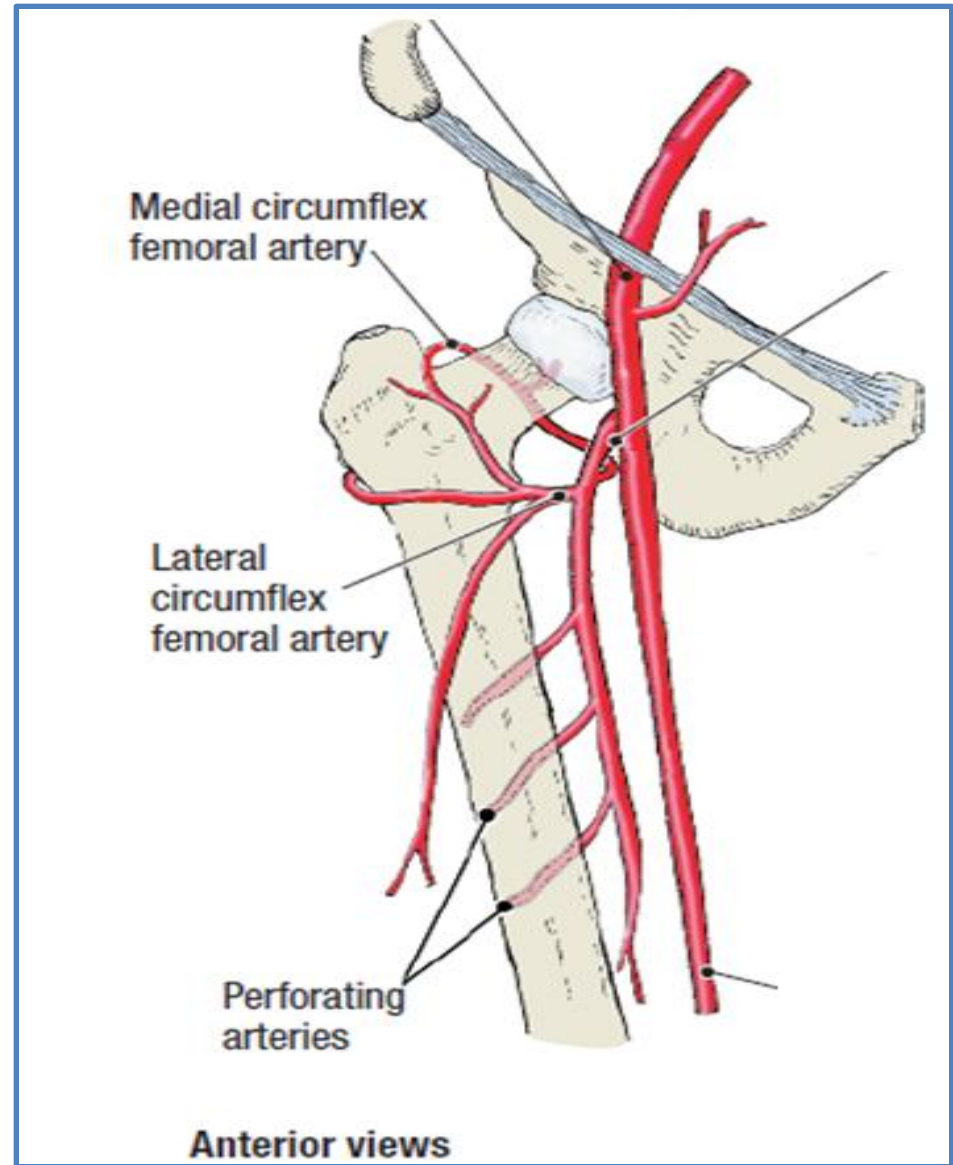
The femoral artery

In the femoral triangle, its pulse is easily felt just inferior to the inguinal ligament **midway** between the **pubic symphysis** and the **anterior superior iliac spine**.



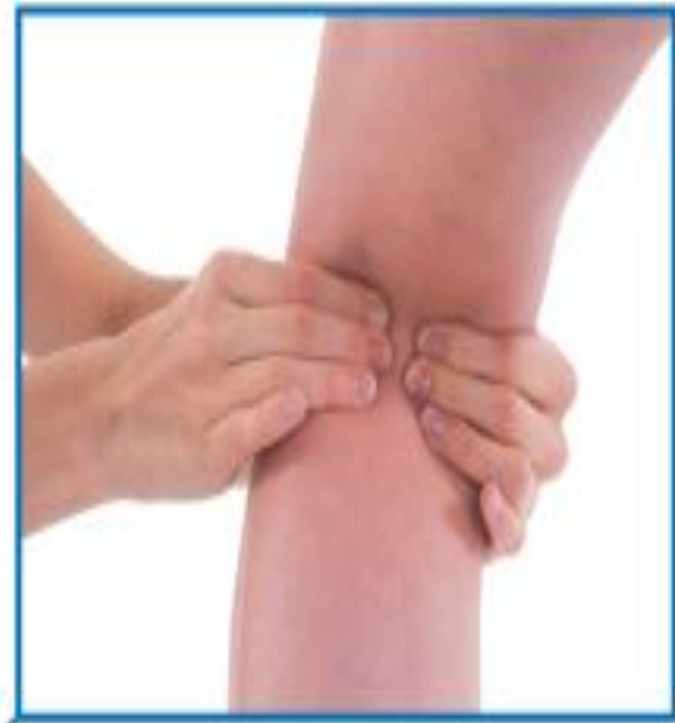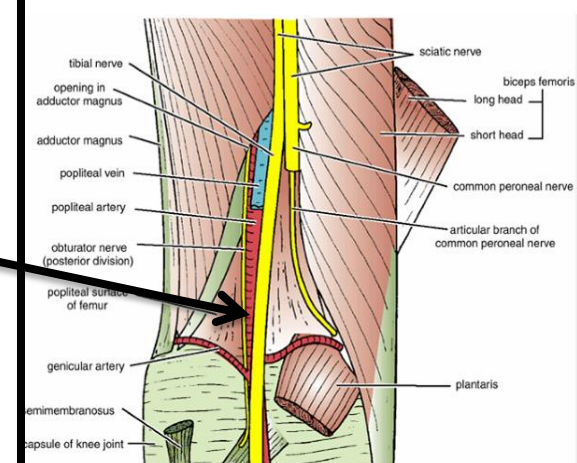
Femoral pulse

2/12/2016



The popliteal artery

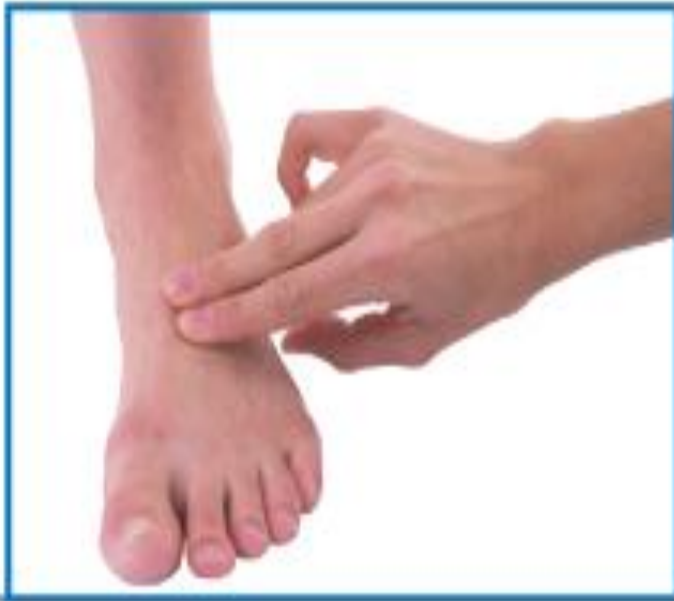The popliteal artery pulse is difficult to find, but usually can be detected on deep palpation just medial to the midline of the popliteal fossa.



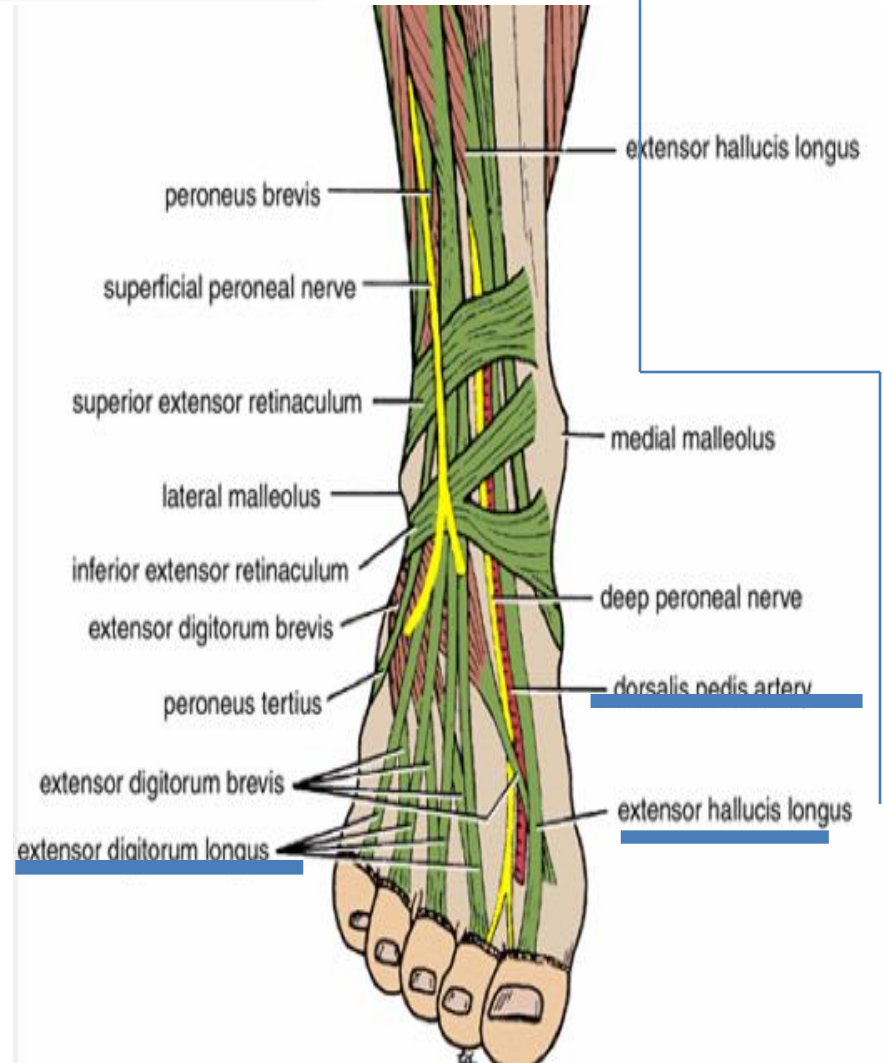
Popliteal pulse

The dorsalis pedis artery

Passes onto the dorsal aspect of the foot and anteriorly over the tarsal bones where it lies **between and is parallel** to the tendon of **extensor hallucis longus** and the tendon of **extensor digitorum longus** to the second toe.

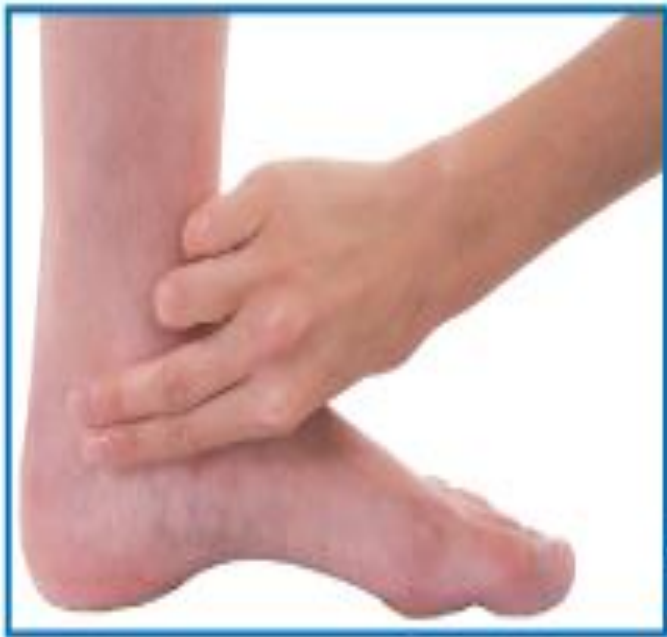

Dorsalis pedis pulse

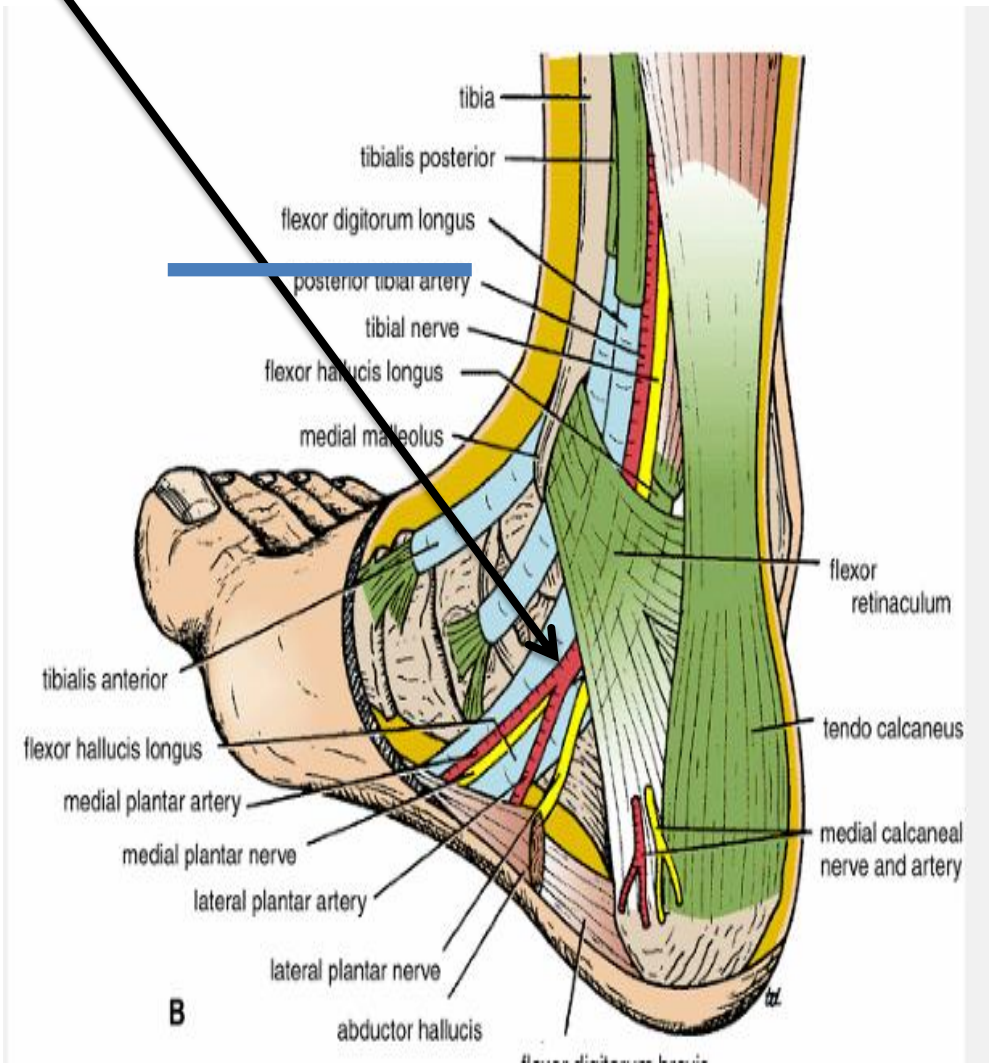


The artery may be absent in around 15% of people

Is palpable just
posteroinferior to the
medial malleolus
between the heel and
medial malleolus.



The posterior tibial artery



B

NERVE INJURIES

OF

LOWER LIMBS

Femoral Nerve Injury

The femoral nerve can be injured in:

Stab or gunshot wounds

a complete damage of the nerve is rare.

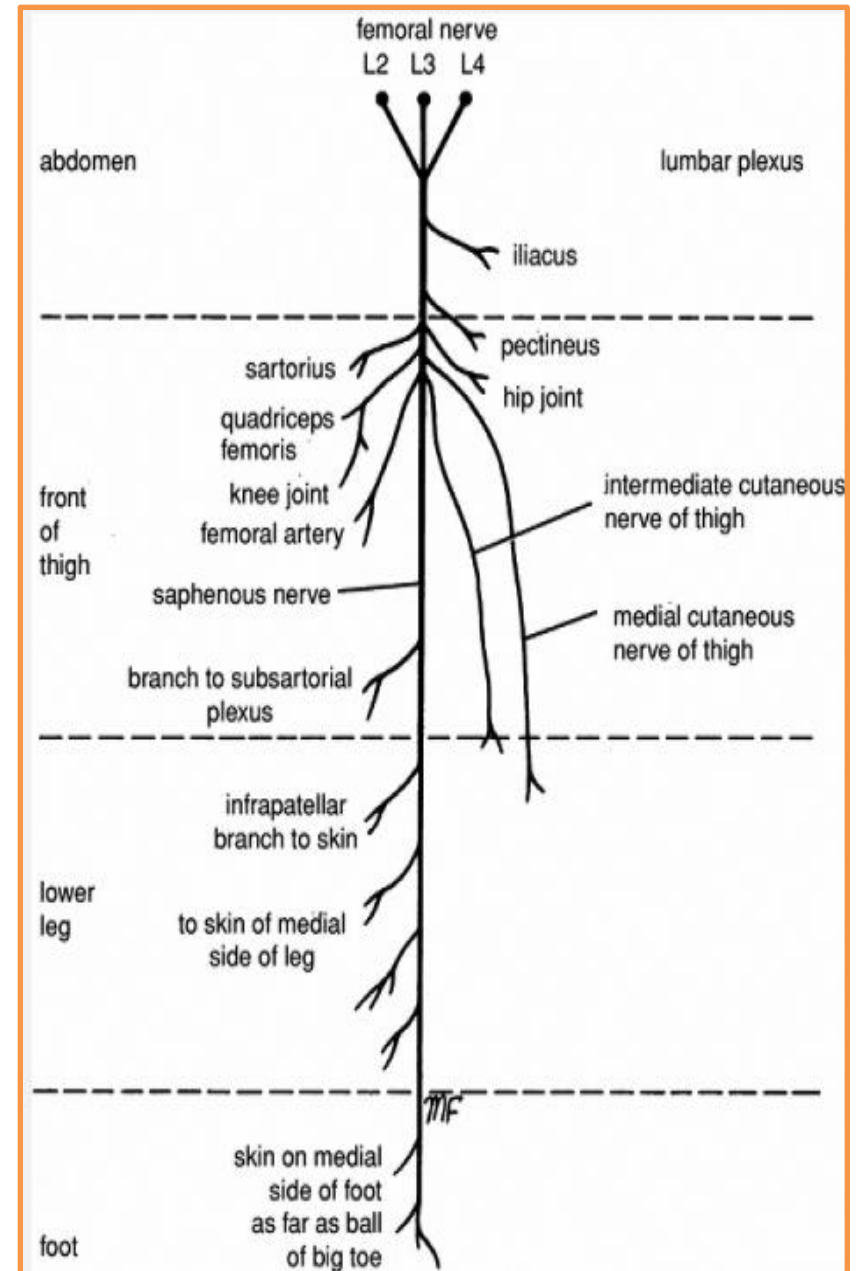
Clinical manifestations:

If The nerve is completely injured

Motor: The *quadriceps femoris muscle* is paralyzed, and the *knee cannot be extended*.

Sensory: Skin sensation is lost over

- 1-The anterior and medial sides of the thigh,
- 2-Over the medial side of the lower part of the leg



Sciatic Nerve Injury

The nerve is sometimes injured by:

- 1- penetrating wounds
- 2-fractures of the pelvis
- 3-dislocations of the hip joint. (posterior)
- 4-badly placed intramuscular injections in the gluteal region. (common).

The following clinical features are present:

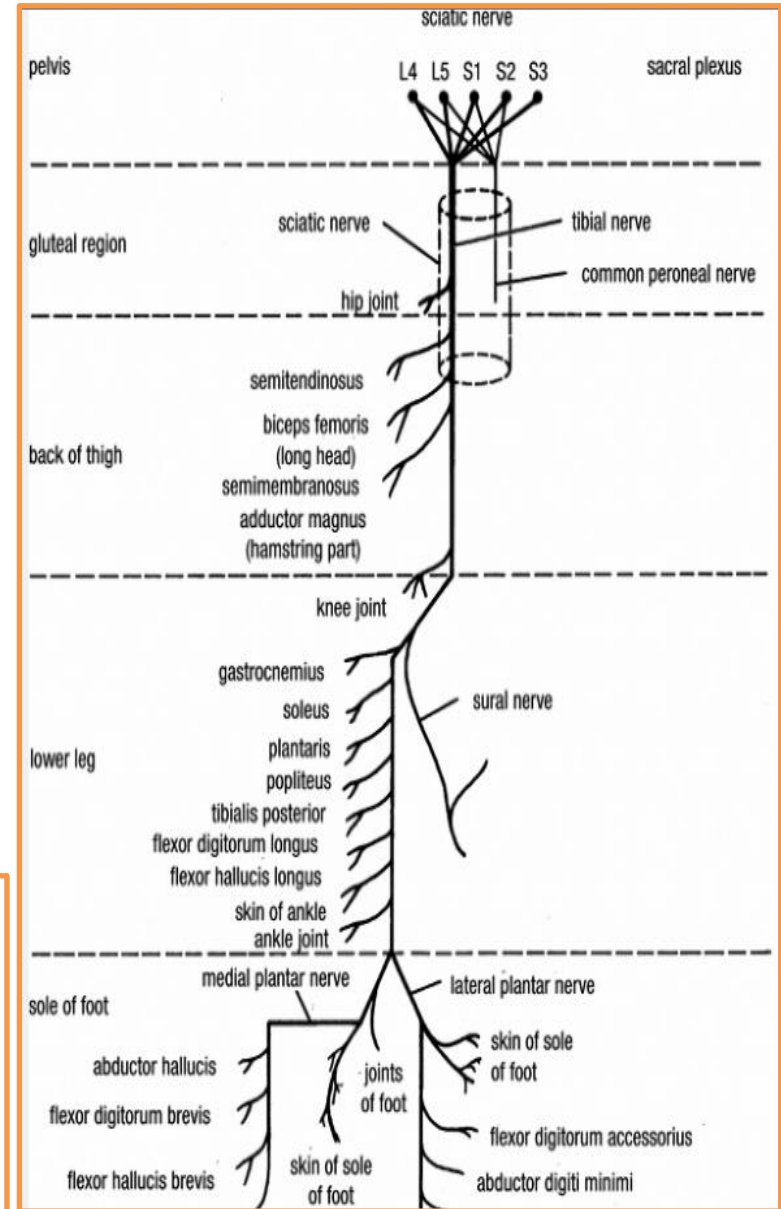
Motor: 1-The hamstring muscles are paralyzed, but weak flexion of the knee is possible because of the action of the sartorius (femoral nerve) and gracilis (obturator nerve)

2-All the muscles below the knee are paralyzed, the foot assume the plantar-flexed position, or

Foot drop

Sensory: Sensation is lost below the knee,

except for a narrow area down the medial side of the lower part of the leg and along the medial border of the foot as far as the ball of the big toe which is supplied by the saphenous nerve (femoral nerve).



common peroneal nerve is in an exposed position as it leaves the popliteal fossa and winds around the neck of the fibula to enter the peroneus longus muscle

Injury to common peroneal nerve

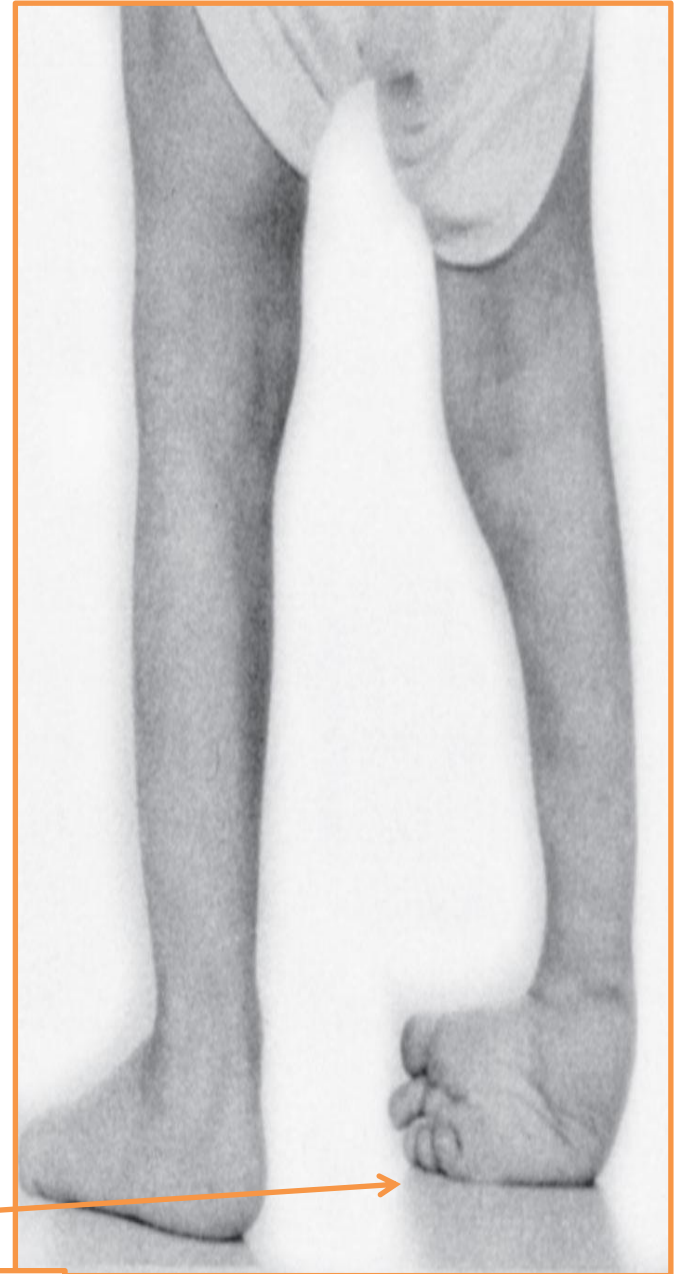Paralysis of extensor muscles (supplied by **deep peroneal nerve**) this means **loss of dorsiflexion of the foot**

Paralysis of peronei muscles (supplied by the **superficial peroneal nerve**) this means **loss of Eversion of the foot**

The antagonistic muscles (planter flexors and invertors) will take over
this leads to

Foot drop and inversion

Equino varus



Tibial Nerve Injury

Because of its deep and protected position, it is rarely injured.

Complete damage results in the following clinical features:

Motor: All the muscles in the back of the leg and the sole of the foot are paralyzed. The opposing muscles dorsiflex the foot at the ankle joint and evert the foot at the subtalar and transverse tarsal joints, an attitude referred to as

Calcaneovalgus

Sensory: Sensation is lost on the sole of the foot; later, trophic ulcers develop.

Obturator Nerve Injury

It is rarely injured in :

penetrating wounds,

in anterior dislocations of the hip joint,

or in abdominal herniae through the obturator foramen.

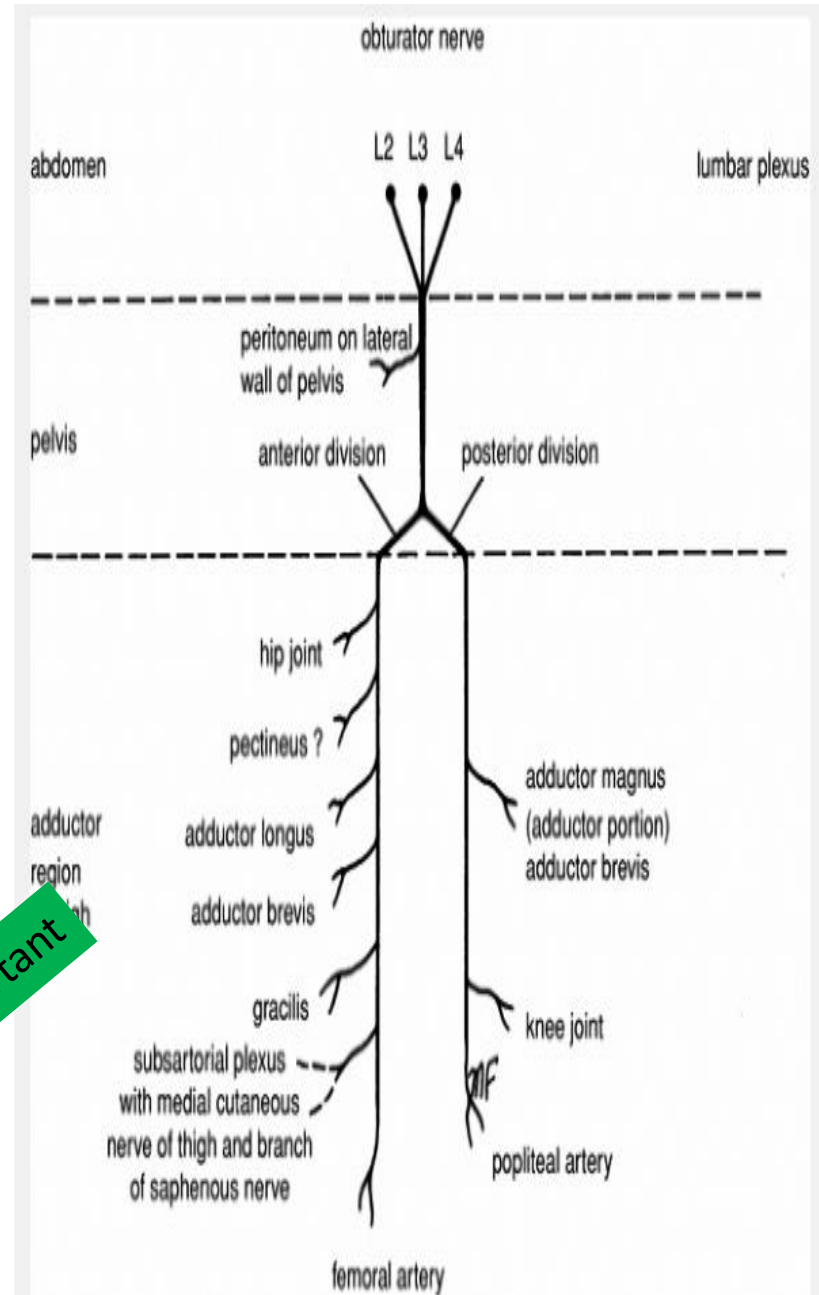
It may be pressed on by the fetal head during parturition.

The following clinical features occur:

Motor: All the adductor muscles are paralyzed except the hamstring part of the adductor magnus, which is supplied by the sciatic nerve.

Sensory: The cutaneous sensory loss is minimal on the medial aspect of the thigh.

important



Veins of the Lower Limb

The veins of the lower limb can be divided into three groups:

1-superficial, 2- deep , 3-perforating.

➤ The superficial veins consist of the great and small saphenous veins, which are situated beneath the skin in the superficial fascia.

➤ The deep veins are the **venae comitantes** to the anterior and posterior tibial arteries, the **popliteal vein**, and the **femoral veins** and their tributaries.

➤ The perforating veins are communicating vessels that run **between the superficial and deep veins.** Many of these veins are found particularly in the region of the ankle and the medial side of the lower part of the leg. They **possess valves that are arranged to prevent the flow of blood from the deep to the superficial veins.**

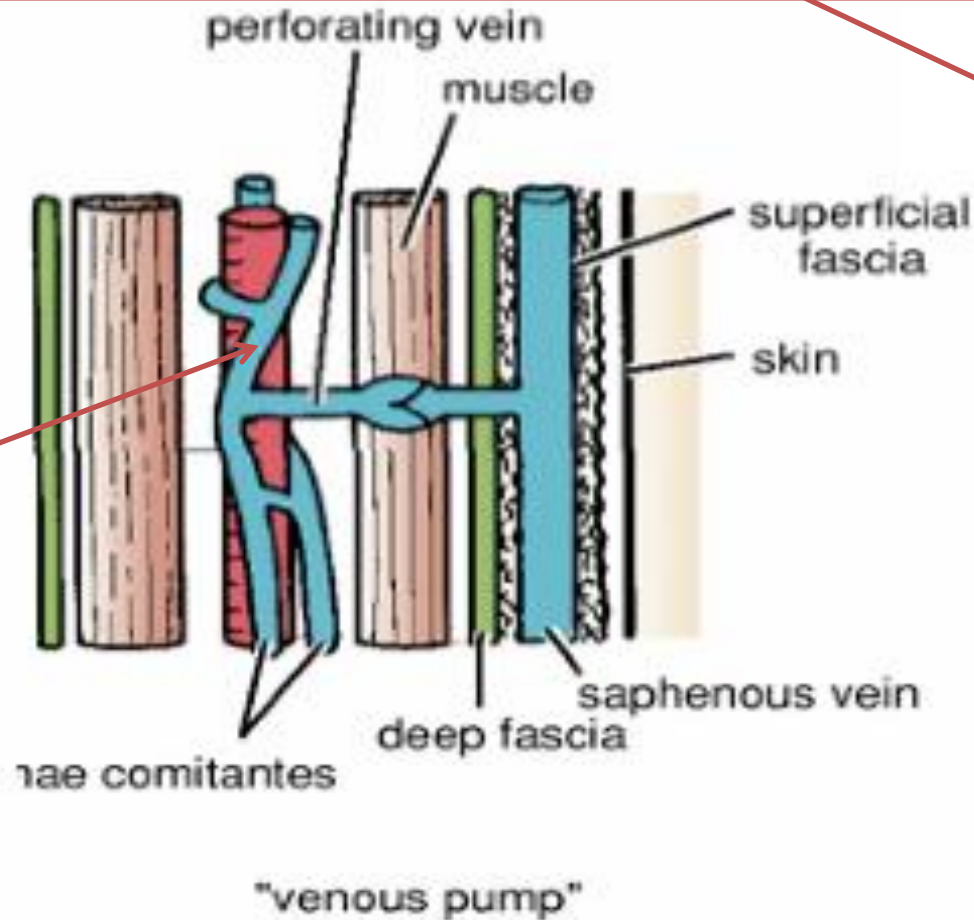
The valves in the perforating veins prevent the high-pressure venous blood from being forced outward into the low-pressure superficial veins.

High pressure

Low pressure

venae comitantes
are subjected to intermittent pressure at rest and during exercise

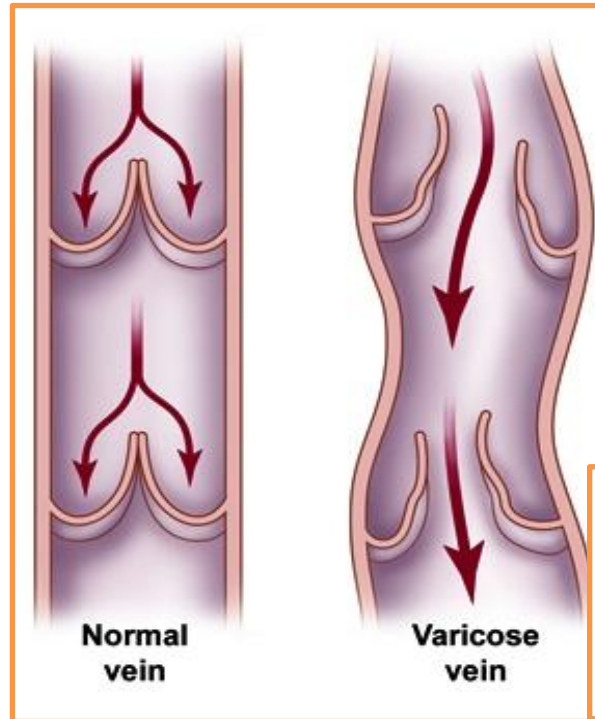
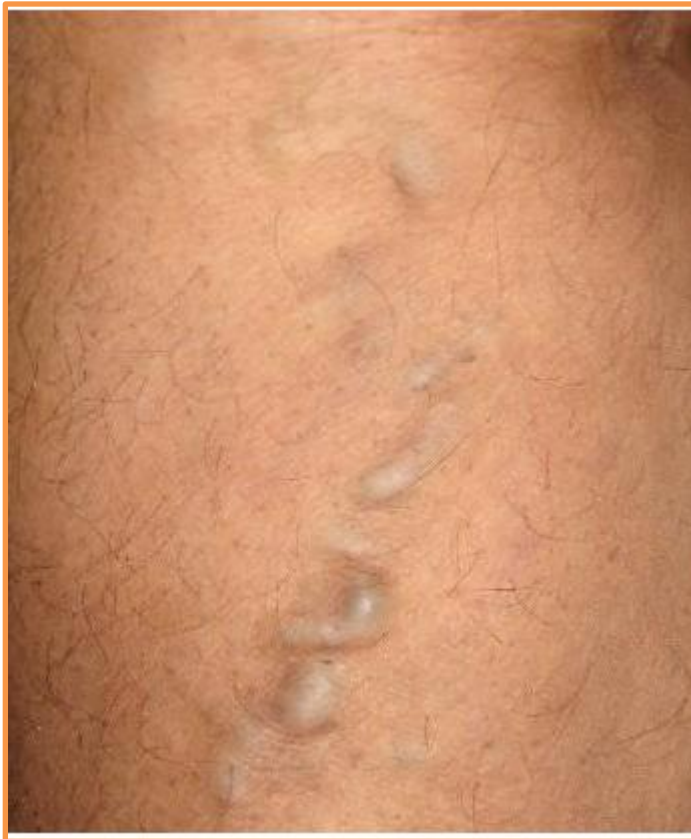The superficial saphenous veins lie within the superficial fascia and are not subject to compression forces



Varicose Veins

A varicose vein is one that has a larger diameter than normal and is elongated and tortuous.

This condition commonly occurs in the superficial veins of the lower limb



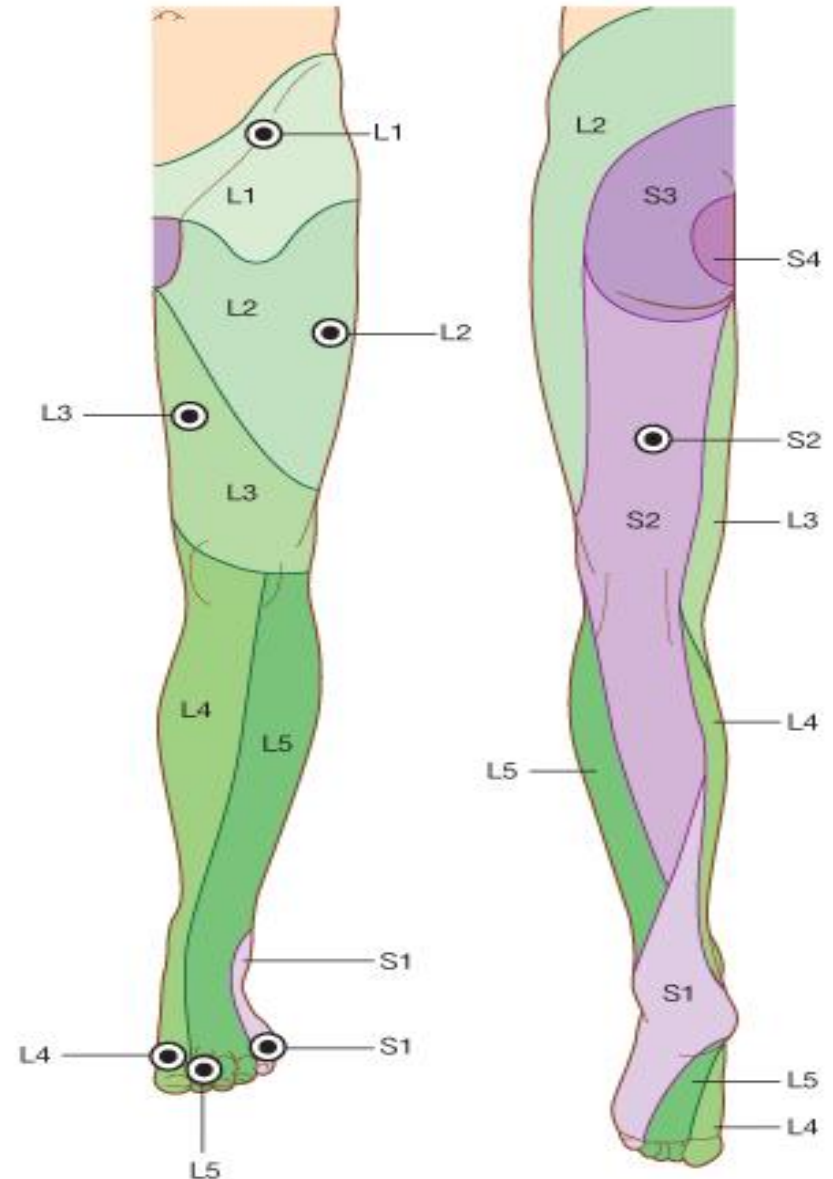
incompetence
of a valve in a
perforating
vein.`

Dermatomes in the lower limb

Regions that can be tested for sensation and are reasonably autonomous (have minimal overlap) are:

over

- 1-The inguinal ligament-L1
- 2-Lateral side of the thigh-L2;
- 3-Lower medial side of the thigh-L3
- 4-Medial side of the great toe (digit 1)-L4
- 5-Medial side of digit 2-L5
- 6-Little toe (digit 5)-S1
- 7-Back of the thigh-S2
- 8-Skin over the gluteal fold-S3

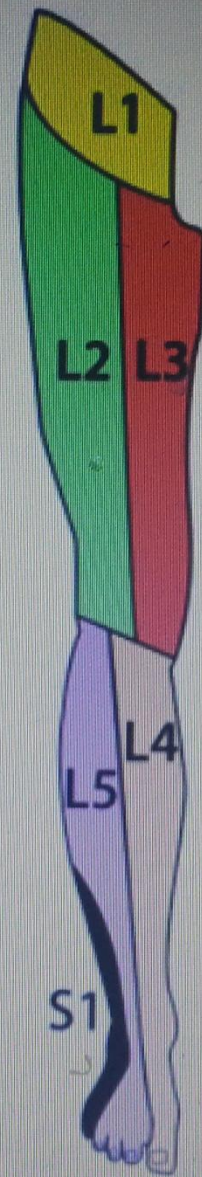


SIMPLIFIED DERMATOMES OF LOWER LIMB

These are approximate dermatomes that are perfectly adequate for most clinical practice and for testing, for instance, in lumbar disc lesions.

(See "dermatome dance" for an easy way of remembering and demonstrating them)

Across foot on both dorsal and plantar surfaces from medial to lateral is **L4 - L5 - S1**

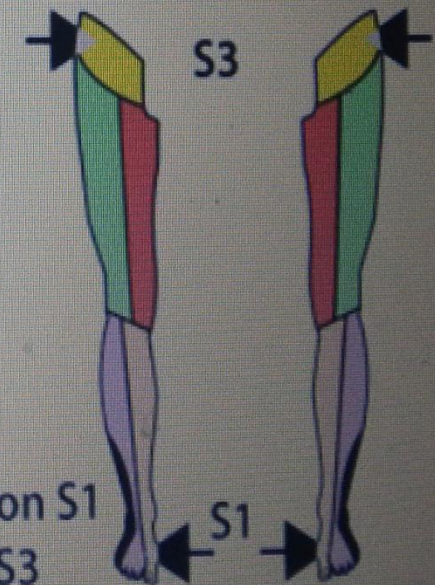
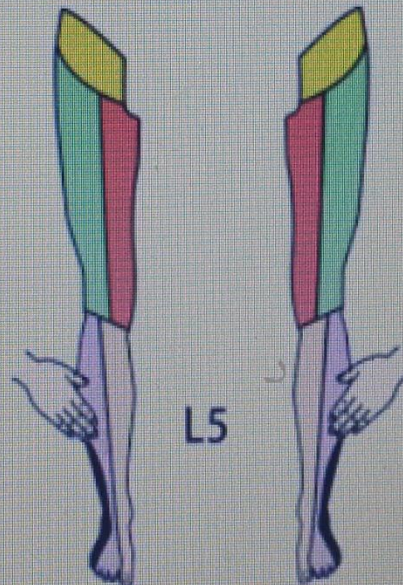
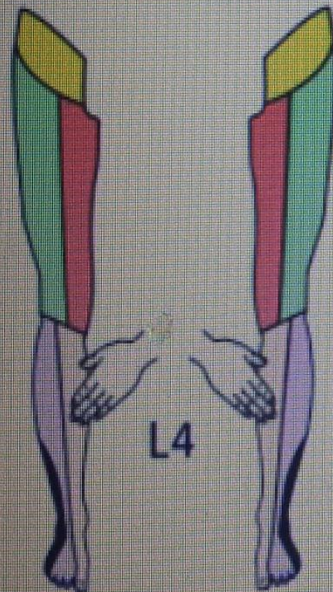
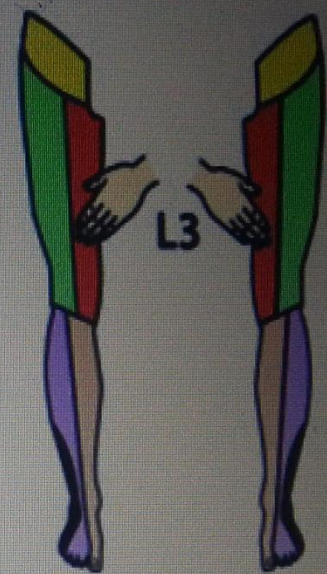
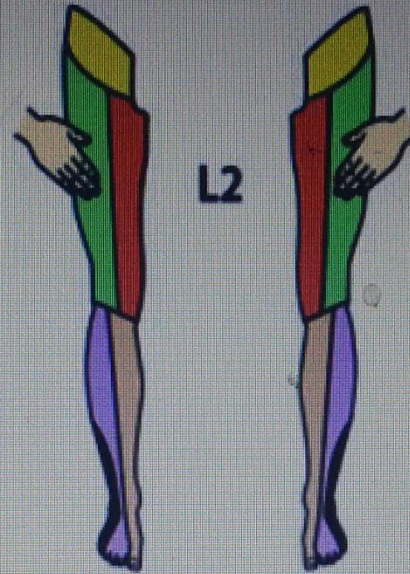
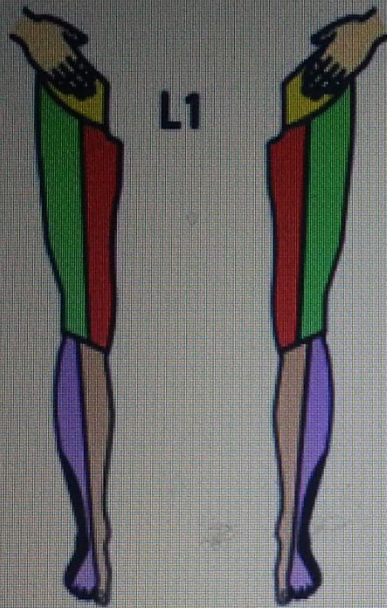


T12 Suprapubic area

L1 Hand's breadth below inguinal ligament, side of penis and scrotum

Stand on S1 - Sit on S3

"Dermatome Dance"



Stand on S1
Sit on S3

Segmental Innervation to Muscles of Lower Limb

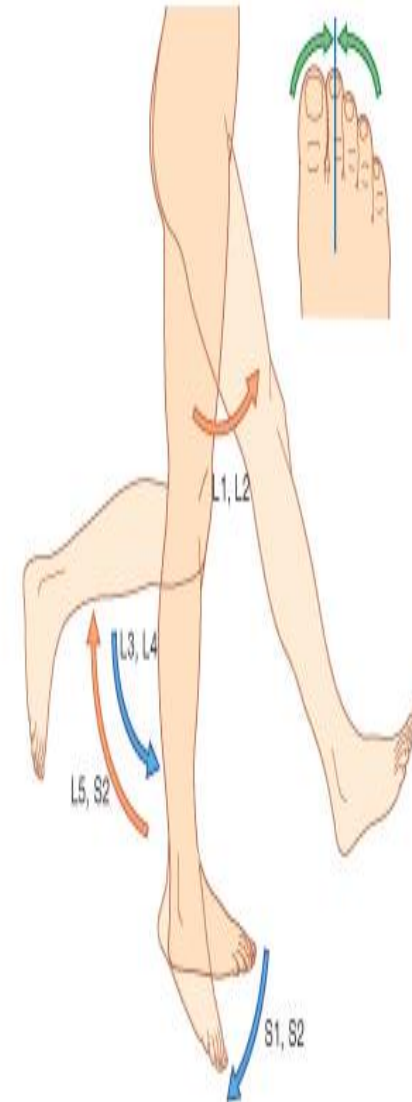
The **segmental innervation** to the muscles of the lower limb has a **proximal–distal gradient**, i.e., the more proximal muscles are innervated by the higher segments and the more distal muscles are innervated by the lower segments.

- The muscles that cross the **anterior side of the hip** are innervated by **L2 and L3**.
- The muscles that cross the **anterior side of the knee** are innervated by **L3 and L4**.
- The muscles that cross the **anterior side of the ankle** are innervated by **L4 and L5**.
- The muscles that cross the **posterior side of the hip** are innervated by **L4 and L5** (dorsi flexion).
- The muscles that cross the **posterior side of the knee** are innervated by **L5 and S1**.
- The muscles that cross the **posterior side of the ankle** are innervated by **S1 and S2** (plantar flexion).

In an unconscious patient, both somatic sensory and somatic motor functions of spinal cord levels can be tested using tendon reflexes:

1- a 'tap' on the patellar ligament at the knee *tests*
Patellar tendon reflex (knee jerk) L3, and 4
(extension of the knee joint on tapping the patellar tendon)

2-Achilles tendon reflex (ankle jerk) S1 and S2
(plantar flexion of the ankle joint on tapping the Achilles tendon)



Read only

In fractures of the upper third of the shaft of the femur

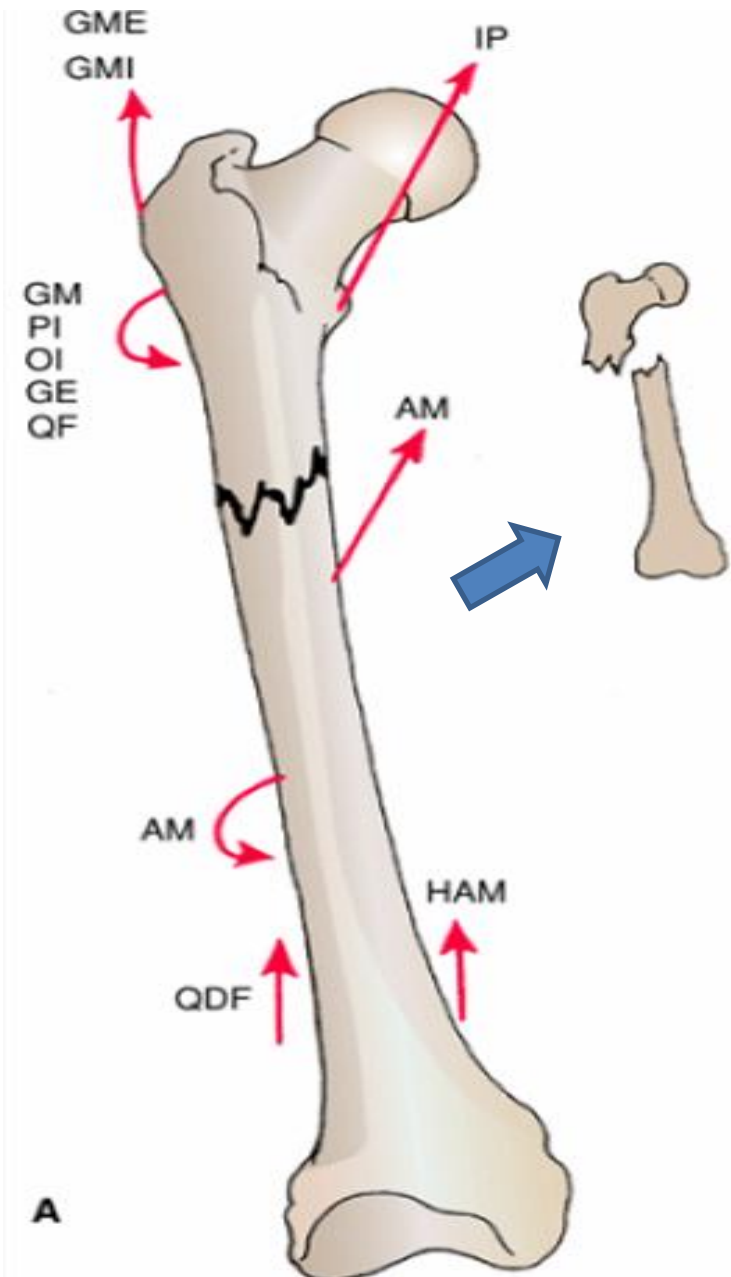
The proximal fragment is

flexed by the *iliopsoas*
abducted by the *gluteus medius and minimus*

laterally rotated by *the gluteus maximus, the piriformis, the obturator internus, the gemelli, and the quadratus femoris*

The lower fragment is adducted

by the adductor muscles,
pulled upward by the hamstrings and quadriceps, and laterally rotated by the adductors and the weight of the foot



A

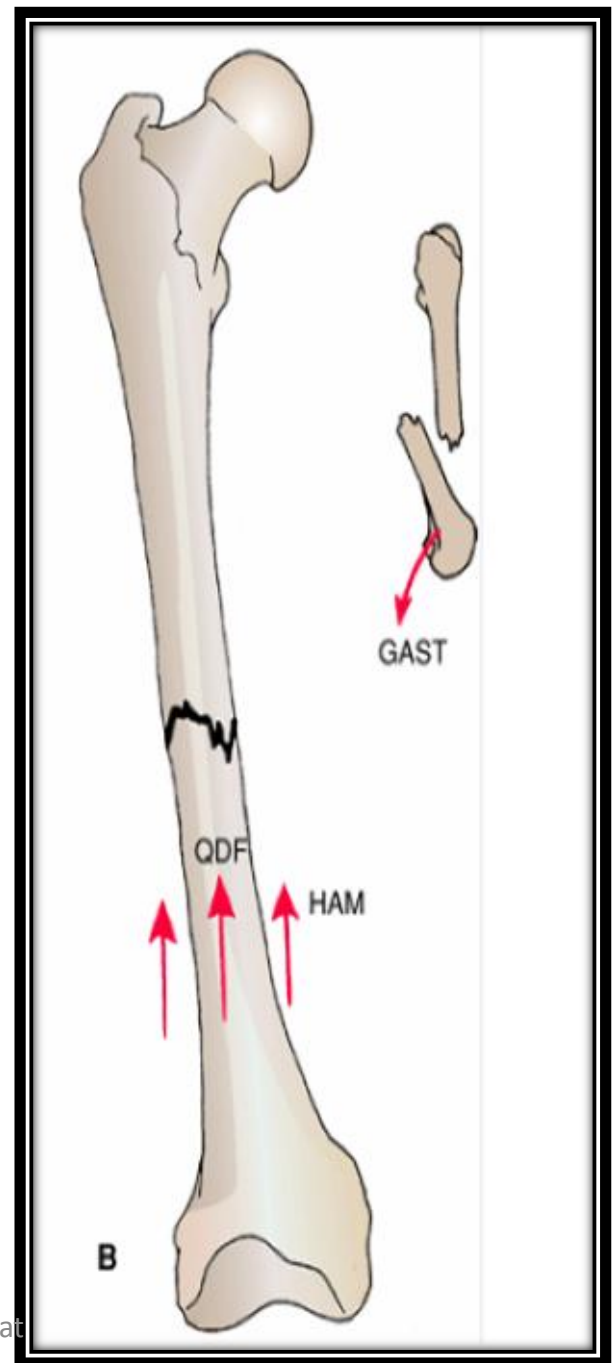
Read only

In fractures of the middle third of the shaft of the femur gastrocnemius

The distal fragment is pulled upward by the hamstrings and the quadriceps resulting in considerable shortening.

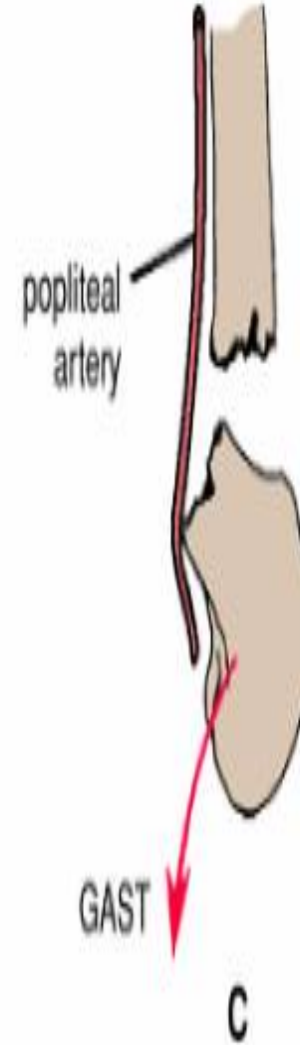The distal fragment is also rotated backward by the pull of the two heads of the

GASTROCNEMIUS



In fractures of the distal third of the shaft of the femur, the same displacement of the distal fragment occurs as seen in fractures of the middle third of the shaft..

However, the distal fragment is smaller and is rotated backward by the gastrocnemius muscle to a greater degree and may exert pressure on the **popliteal artery** and interfere with the blood flow through the leg and foot



Fibular collateral ligament extends from the lateral condyle of the femur inferiorly to attach to the head of the fibula and is not attached to the lateral meniscus. The fibular ligament prevents **medial displacement** (adduction) of the tibia under the femur.

Leave it until I talk to Dr.Hamdan

Tibial (medial) and fibular (lateral) collateral ligaments

Tibial collateral ligament extends from the medial epicondyle of the femur inferiorly to attach to the medial aspect of the tibia. It is firmly attached to the capsule and medial meniscus. The tibial ligament prevents **lateral displacement** (abduction) of the tibia under the femur.

Leave it until I talk to Dr.Hamdan

Clinical Correlate

The tests for the integrity of the anterior and posterior cruciate ligaments are the **anterior and posterior drawer signs**.

Tearing of the anterior cruciate ligaments allows the tibia to be easily pulled **forward** (anterior drawer sign). Tearing of the posterior cruciate ligament allows the tibial to be easily pulled **posteriorly** (posterior drawer sign).

Common Knee Injuries

Leave it until I talk to Dr.Hamdan

The 3 most commonly injured structures at the knee are the tibial collateral ligament, the medial meniscus, and the ACL (the terrible or unhappy triad)—usually results from a blow to the lateral aspect of the knee with the foot on the ground.

Leave it until I talk to Dr.Hamdan

Ankle Sprains

The ankle is the most frequently injured major joint in the body. *Ankle sprains (torn fibers of ligaments) are most common. A sprained ankle is nearly always an inversion injury, involving twisting of the weight-bearing plantarflexed foot. The anterior talofibular ligament (part of the lateral ligament) is most commonly torn during ankle sprains, either partially or completely, resulting in instability of the ankle joint. The calcaneofibular ligament may also be torn.*

Genu Varum and Genu Valgum

The femur is placed diagonally within the thigh, whereas the tibia is almost vertical within the leg, creating an angle,

The **Q angle**

Read only

at the knee between the long axes of the bones. The Q-angle is assessed by drawing a line from the ASIS to the middle of the patella and extrapolating a second (vertical) line through the middle of the patella and tibial tuberosity

The Q-angle is typically greater in adult females, owing to their wider pelvis.

A medial angulation of the leg in relation to the thigh, in which the femur is abnormally vertical and the Q-angle is small, is a deformity called ***genu varum*** that causes unequal weight distribution. Excess pressure is placed on the medial aspect of the knee joint, which results in *arthrosis (destruction of knee cartilage)*.

*A lateral angulation of the leg in relation to the thigh
(exaggeration of knee angle) is*
genu valgum (knock-knee). *Consequently, in genu
valgum, excess stress is placed on the lateral structures of the
knee*



The patella, normally pulled laterally by the tendon of the vastus lateralis, it is pulled even farther laterally when the leg is extended in the presence of **genu varum** so that its articulation with the femur is **abnormal**.

Leave it until I talk to Dr.Hamdan

Patellofemoral Syndrome

Pain deep to the patella often results from excessive running, especially downhill; hence, this type of pain is often called

“runner's knee.”

The pain results from repetitive microtrauma caused **by abnormal tracking of the patella relative to the patellar surface of the femur**, a condition known as the **patellofemoral syndrome**.

This syndrome may also result from a direct blow to the patella and from osteoarthritis of the patellofemoral compartment (degenerative wear and tear of articular cartilages).

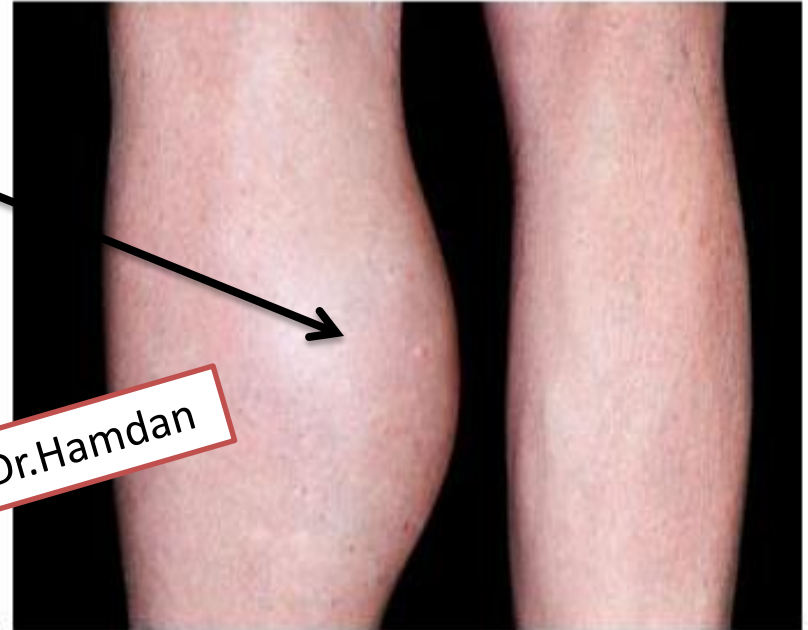In some cases, strengthening of the vastus medialis corrects patellofemoral dysfunction.

This muscle tends to prevent lateral dislocation of the patella resulting from the Q-angle because the vastus medialis attaches to and pulls on the medial border of the patella. Hence, weakness of the vastus medialis predisposes the individual to patellofemoral dysfunction and patellar dislocation.

Popliteal Cysts

Popliteal cysts (Baker cysts) are abnormal fluid-filled sacs of synovial membrane in the region of the popliteal fossa.. Popliteal cysts are common in children but seldom cause symptoms. In adults, popliteal cysts can be large, extending as far as the midcalf, and may interfere with knee movements.

Leave it until I talk to Dr.Hamdan



Read only

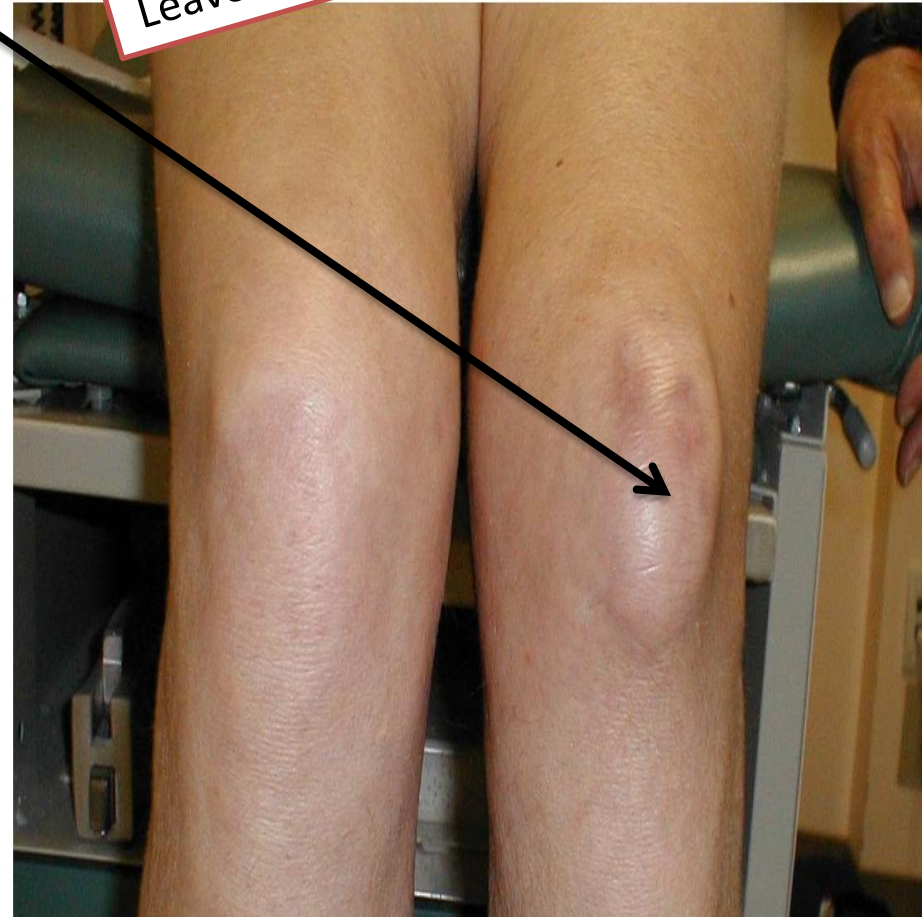A popliteal

yst is almost always a complication of chronic knee joint effusion. The cyst may be a herniation of the gastrocnemius or semimembranosus bursa through the fibrous layer of the joint capsule into the popliteal fossa, communicating with the synovial cavity of the knee joint by a narrow stalk. Synovial fluid may also escape from the knee joint (synovial effusion) or a bursa around the knee and collect in the popliteal fossa. Here it forms a new synovial-lined sac, or popliteal cyst

Bursitis in Knee Region

- *Prepatellar bursitis ("housemaid's knee") is usually a friction bursitis caused by friction between the skin and the patella.*
 - *Subcutaneous infrapatellar bursitis results from excessive friction between the skin and the tibial tuberosity*
 - *Deep infrapatellar bursitis results in edema between the patellar ligament and the tibia, superior to the tibial tuberosity.*
 - ❖ **The suprapatellar bursa communicates with the articular cavity of the knee joint;** consequently, abrasions or penetrating wounds (e.g., a stab wound) superior to the patella may result in *suprapatellar bursitis* caused by *bacteria entering the bursa from the torn skin.*
- The infection may spread to the knee joint.**

Leave it until I talk to Dr.Hamdan



Intraosseous Infusion of the Tibia in the Infant

The technique may be used for the infusion of fluids and blood when it has been found impossible to obtain an intravenous line.

The procedure is easy and rapid to perform, as follows:

With the distal leg adequately supported, the anterior subcutaneous surface of the tibia is palpated.

The skin is anesthetized about 1 in. (2.5 cm) distal to the tibial tuberosity, thus blocking the infrapatellar branch of the saphenous nerve.

The bone marrow needle is directed at right angles through the skin, superficial fascia, deep fascia, and tibial periosteum and the cortex of the tibia. Once the needle tip reaches the medulla and bone marrow, the operator senses a feeling of “give.” The position of the needle in the marrow can be confirmed by aspiration. The needle should be directed slightly caudad to avoid injury to the epiphyseal plate of the proximal end of the tibia. The transfusion may then commence

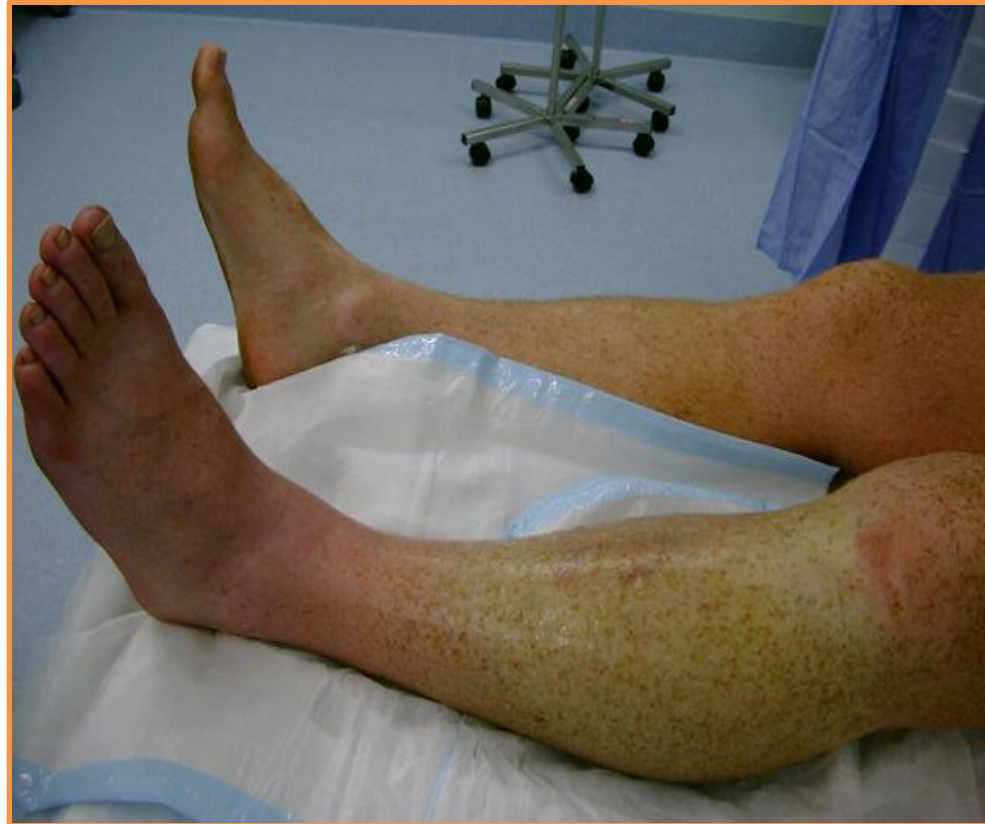Anterior Compartment of the Leg Syndrome.

- is produced by an increase in the intracompartmental pressure that results from an increased production of tissue fluid.
- Soft tissue injury associated with bone fractures is a common cause, and early diagnosis is critical.
- **The deep, aching pain** in the anterior compartment of the leg that is characteristic of this syndrome can become severe.

Dorsiflexion of the foot at the ankle joint increases the severity of the pain.

As the pressure rises, the venous return is diminished, thus producing a further rise in pressure.

- In severe cases, **the arterial supply is eventually cut off by compression**
- the ***dorsalis pedis arterial pulse disappears.***
- The tibialis anterior, the extensor digitorum longus, and the extensor hallucis longus muscles **are paralyzed.**
- Loss of sensation is limited to the area supplied by the deep peroneal nerve
that is, the skin cleft between the first and second toes.

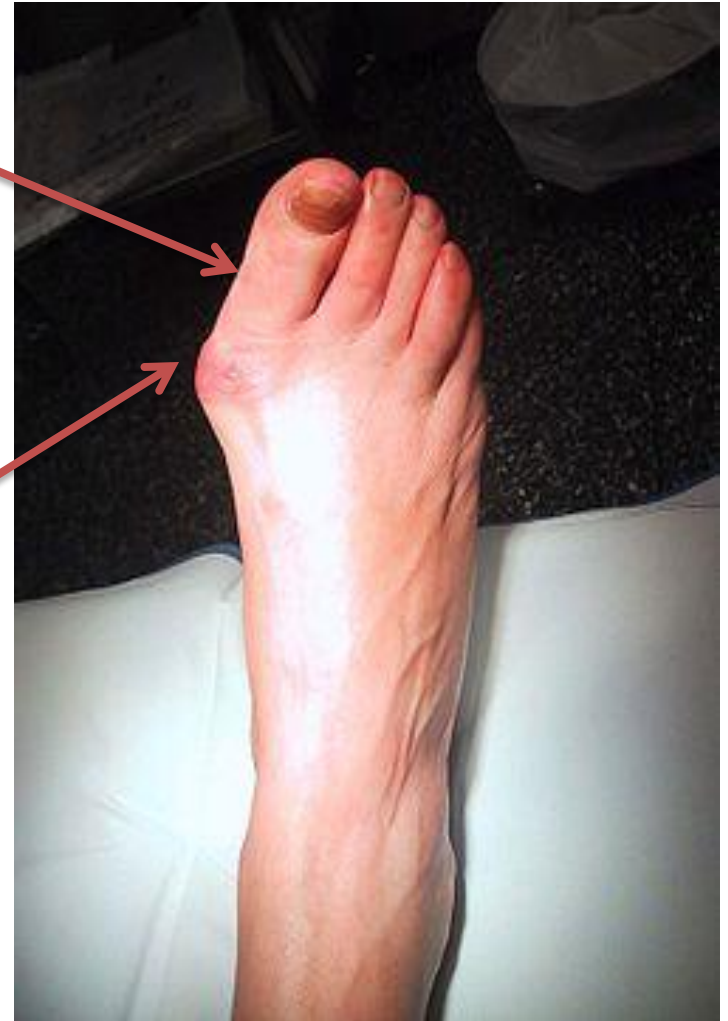

The surgeon can open the anterior compartment of the leg by making a longitudinal incision through the deep fascia and thus decompress the area and prevent anoxic necrosis of the muscles.

Hallux Valgus

Hallux valgus is a foot deformity caused by degenerative joint disease; it is characterized by lateral deviation of the *hallux*). *In some people, the deviation is so great that the first toe overlaps the second toe. These individuals are unable to move*

their first digit away from their second digit because the sesamoid bones under the head of the first metatarsal are displaced and lie in the space between the heads of the first and second metatarsals. In addition, a subcutaneous bursa may form owing to pressure and friction against the shoe. When tender and inflamed, the bursa is called a bunion great toe (L.



Patellar Dislocations

The patella is a sesamoid bone lying within the quadriceps tendon. ***The importance of the lower horizontal fibers of the vastus medialis and the large size of the lateral condyle of the femur in preventing lateral displacement of the patella has been emphasized.***

Congenital recurrent dislocations of the patella are caused by underdevelopment of the lateral femoral condyle. Traumatic dislocation of the patella results from direct trauma to the quadriceps attachments of the patella (especially the **vastus medialis**), with or without fracture of the patella