

PATHOLOGY

☐ Sheet

☒ Slide

☐ Handout

Number

Subject

CNS lab 2

Doctor

Heyam Awad

Date: 00/00/2016

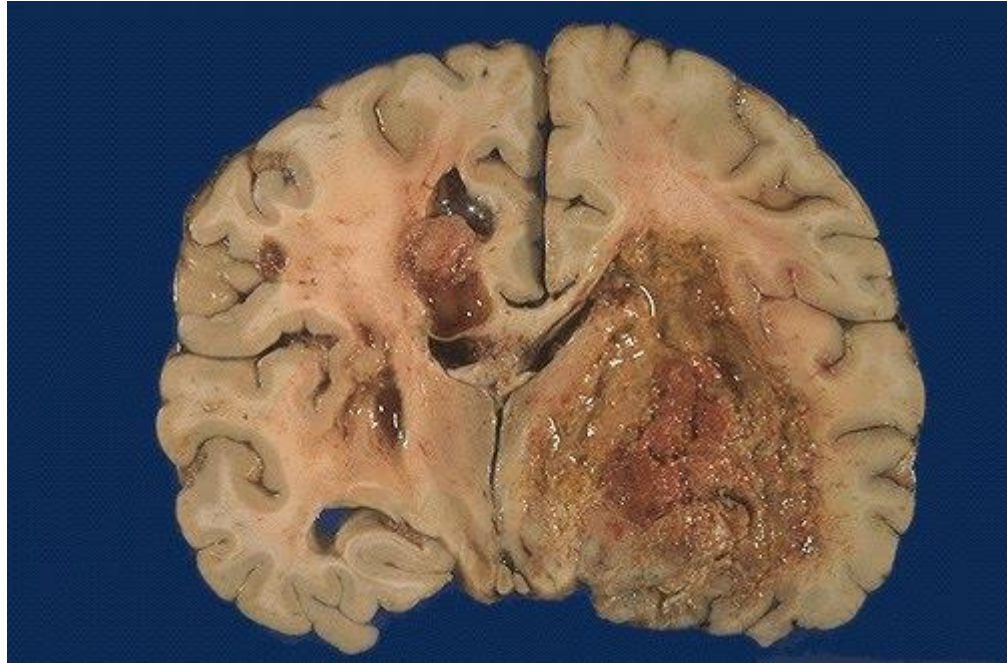
Price:

CNS lab 2

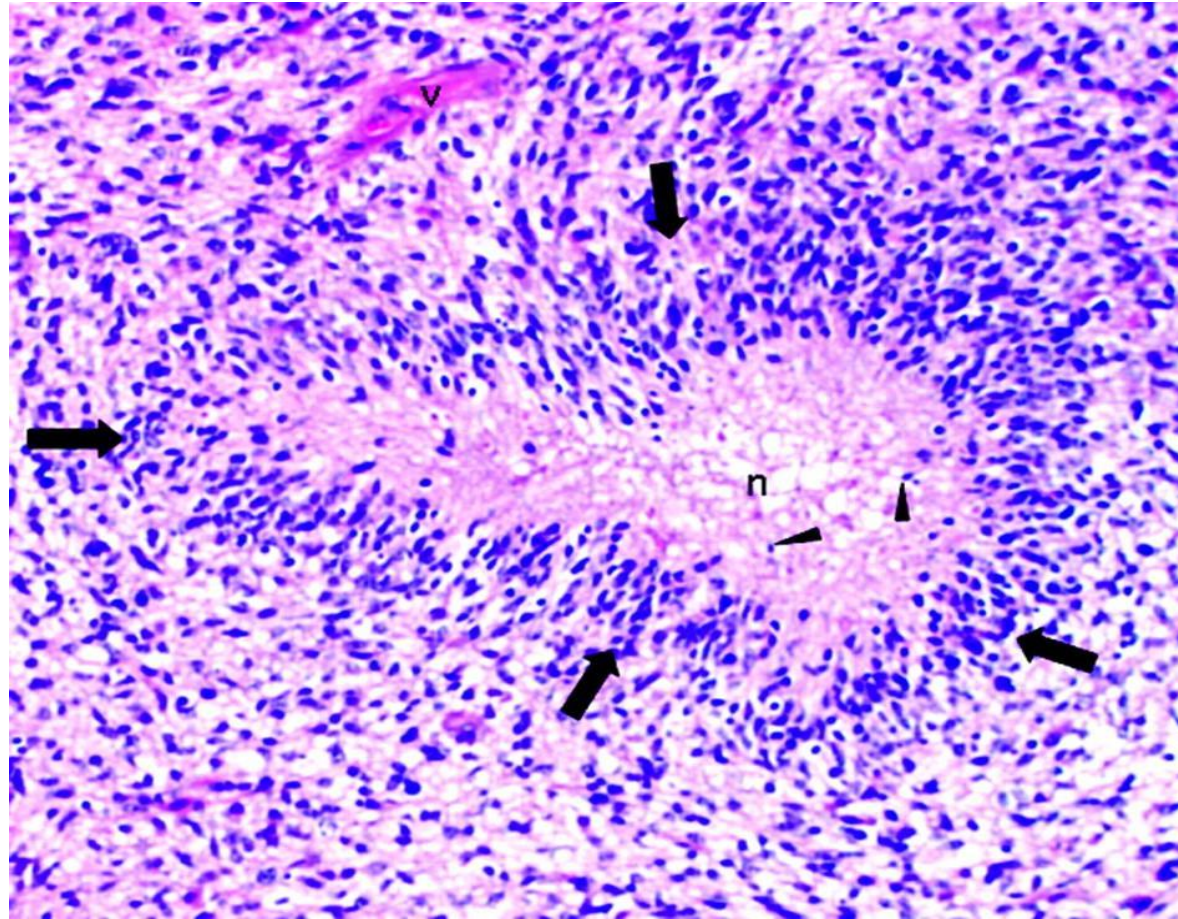
Dr H Awad

- THESE SLIDES ARE REQUIRED FOR THE FINAL EXAM
ONLY LAB 2 IS REQUIRED FOR THE FINAL.

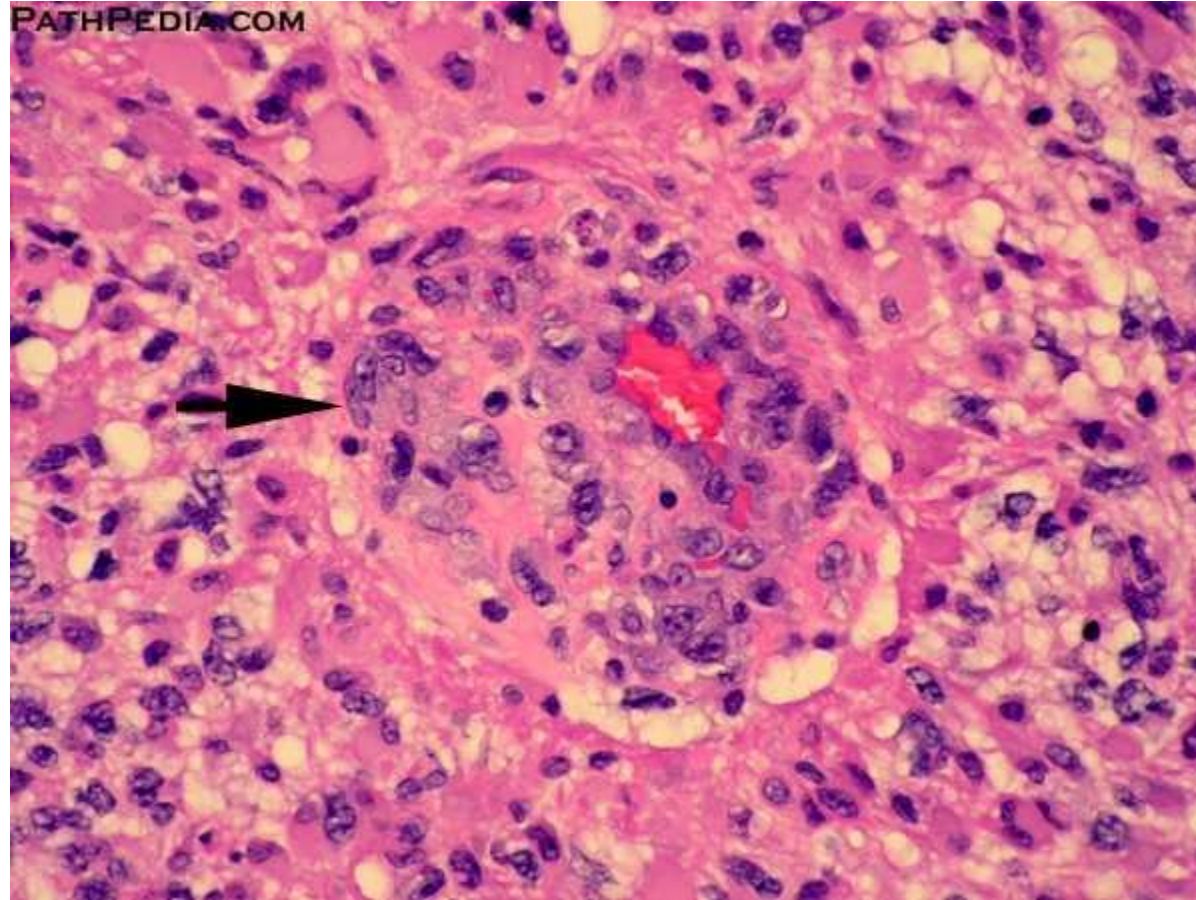
glioblastoma



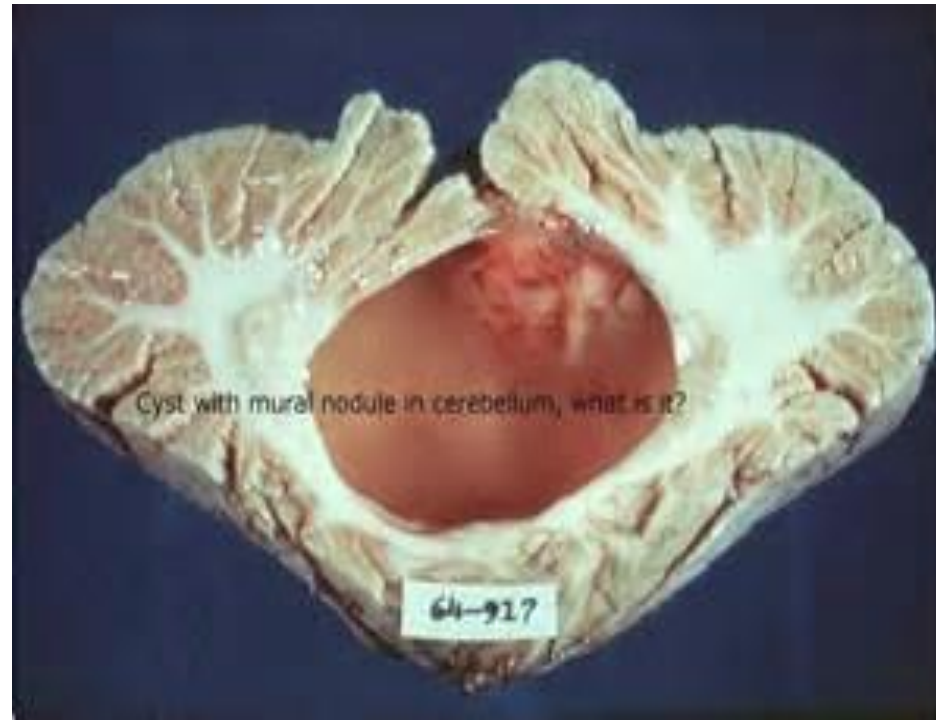Glioblastoma/ palisaded nuclei around necrotic area



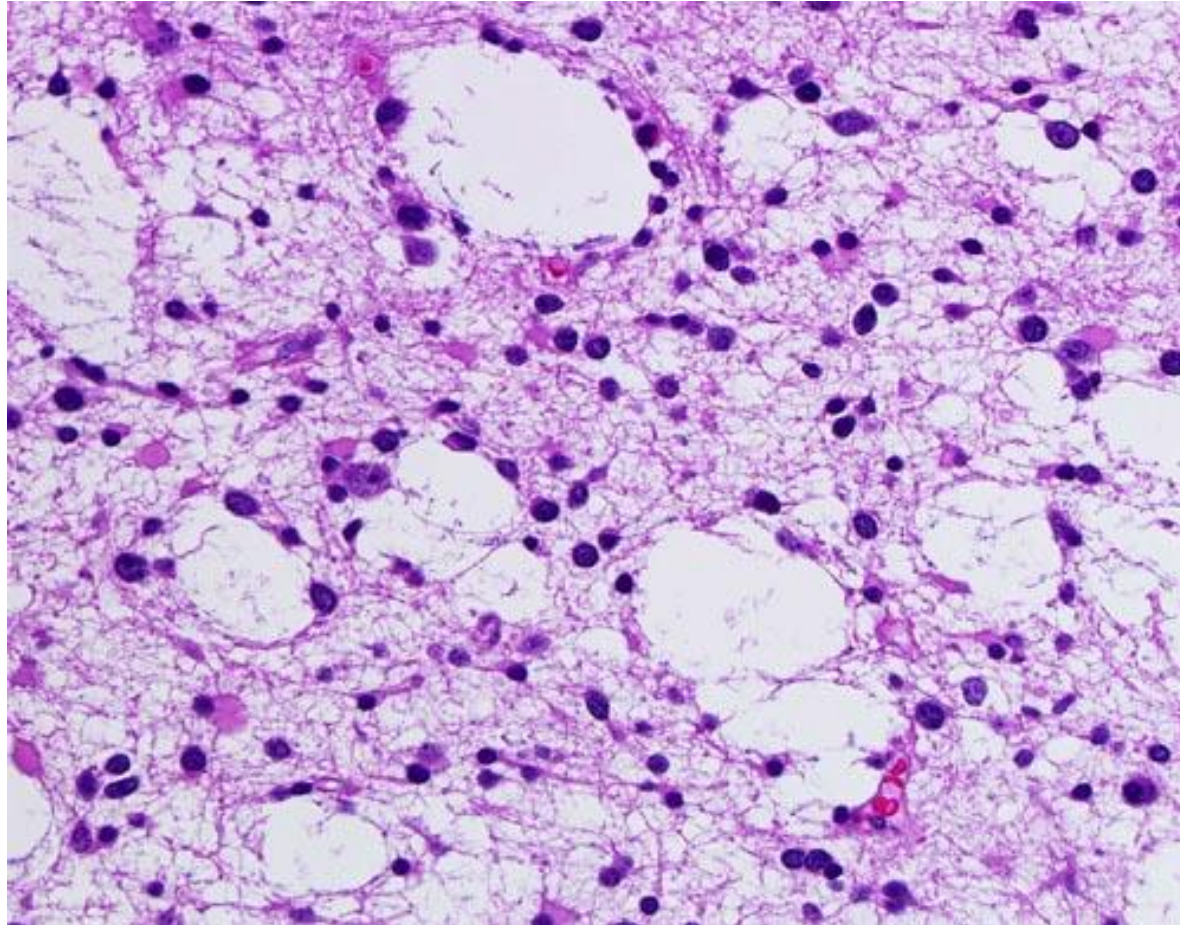
Glomeruloid body/ vascular proliferation in glioblastoma



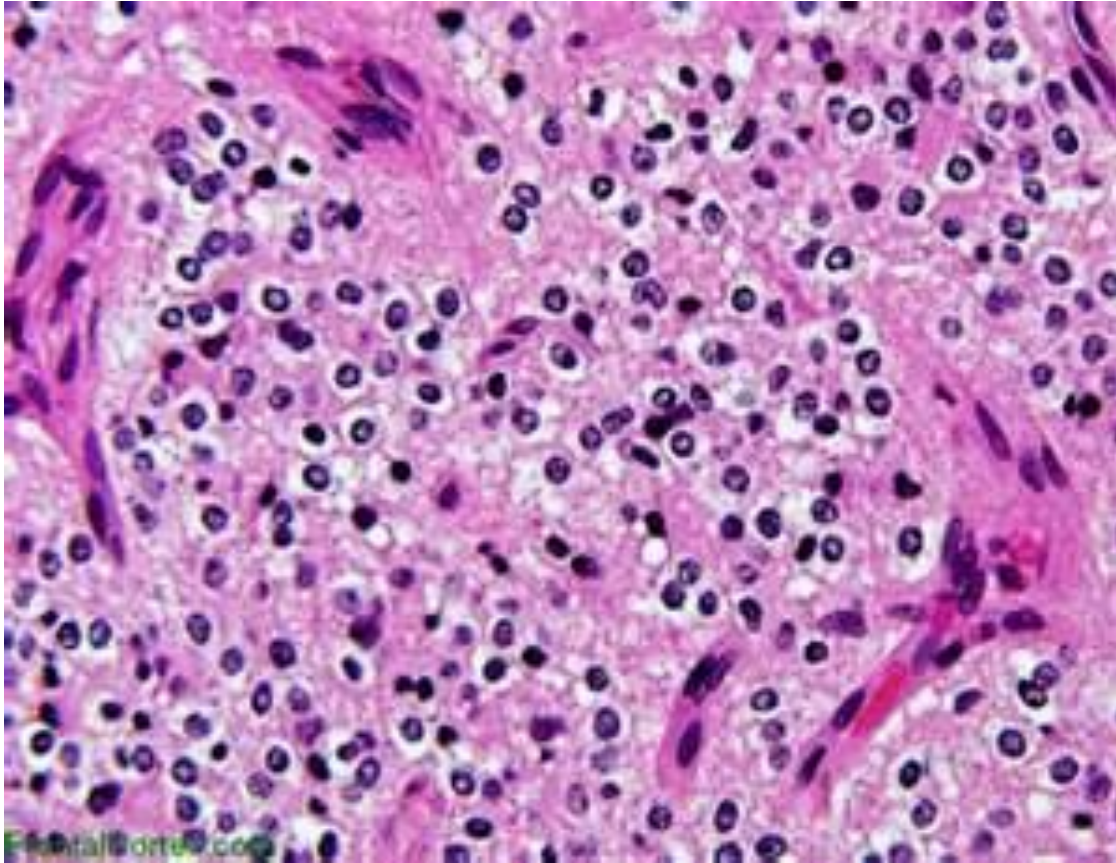
Pilocytic astro: this example is mainly cystic but has also a solid component



Pilocytic/ microcysts

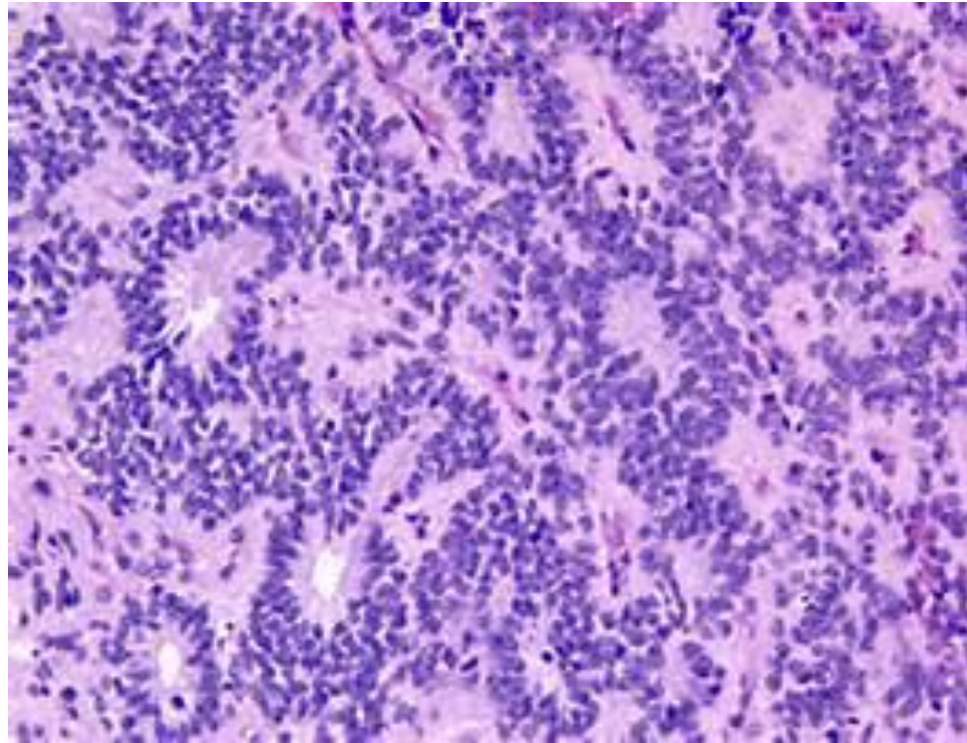


oligodendroglioma;/ note the white halo around the nuclei giving the fried egg appearance

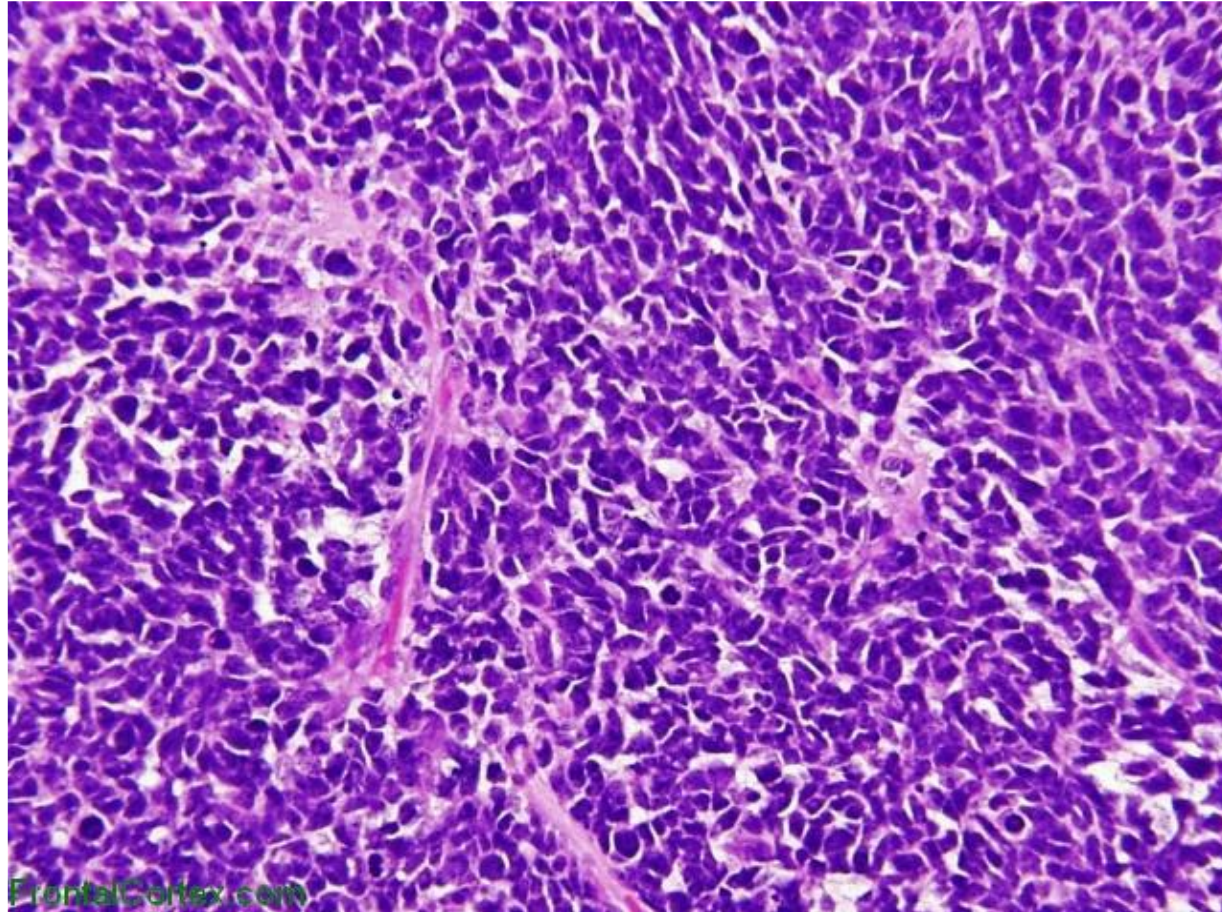


Ependymoma/ rosettes

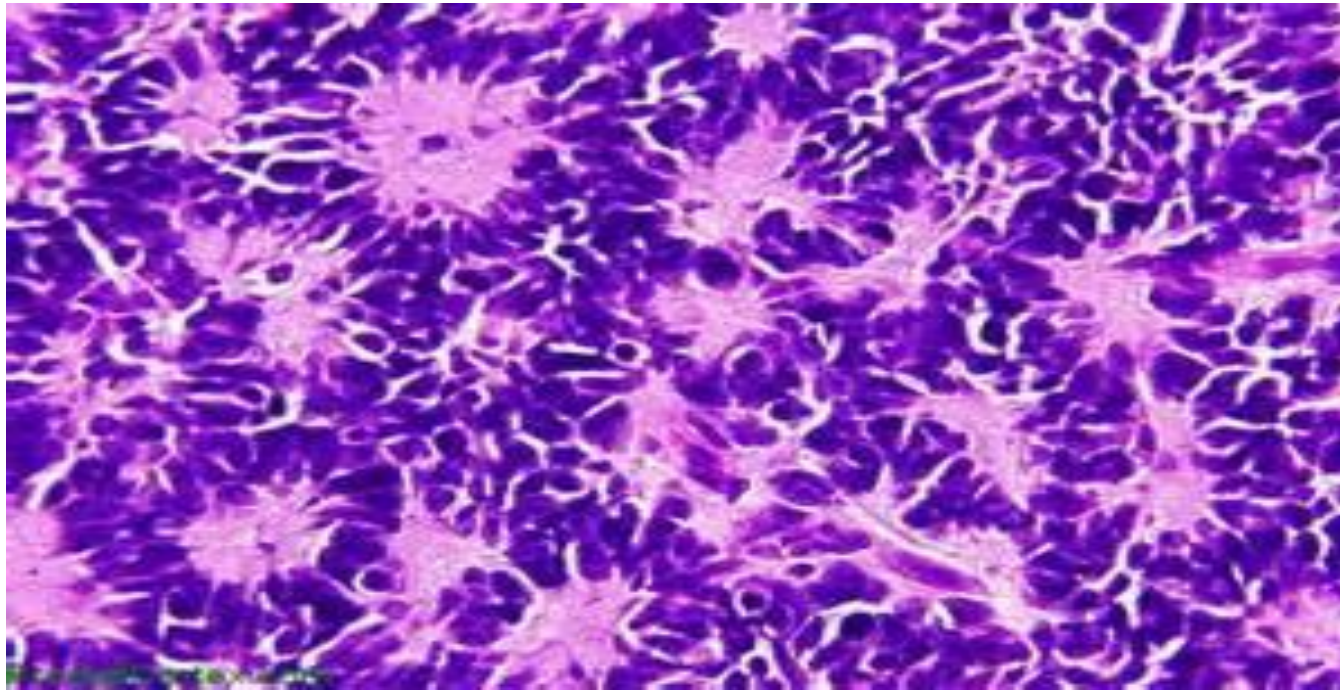
note: true rosettes arise around canals

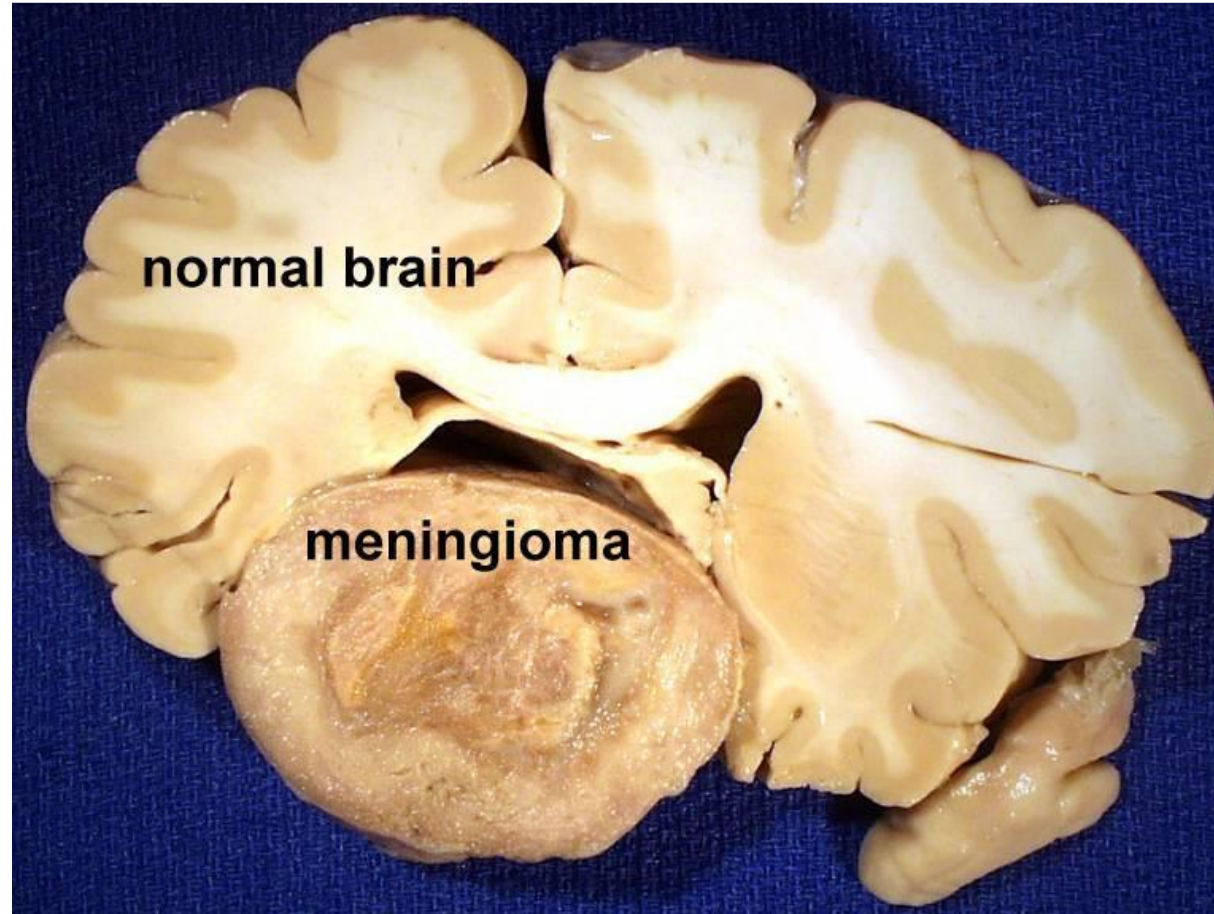


medulloblastoma

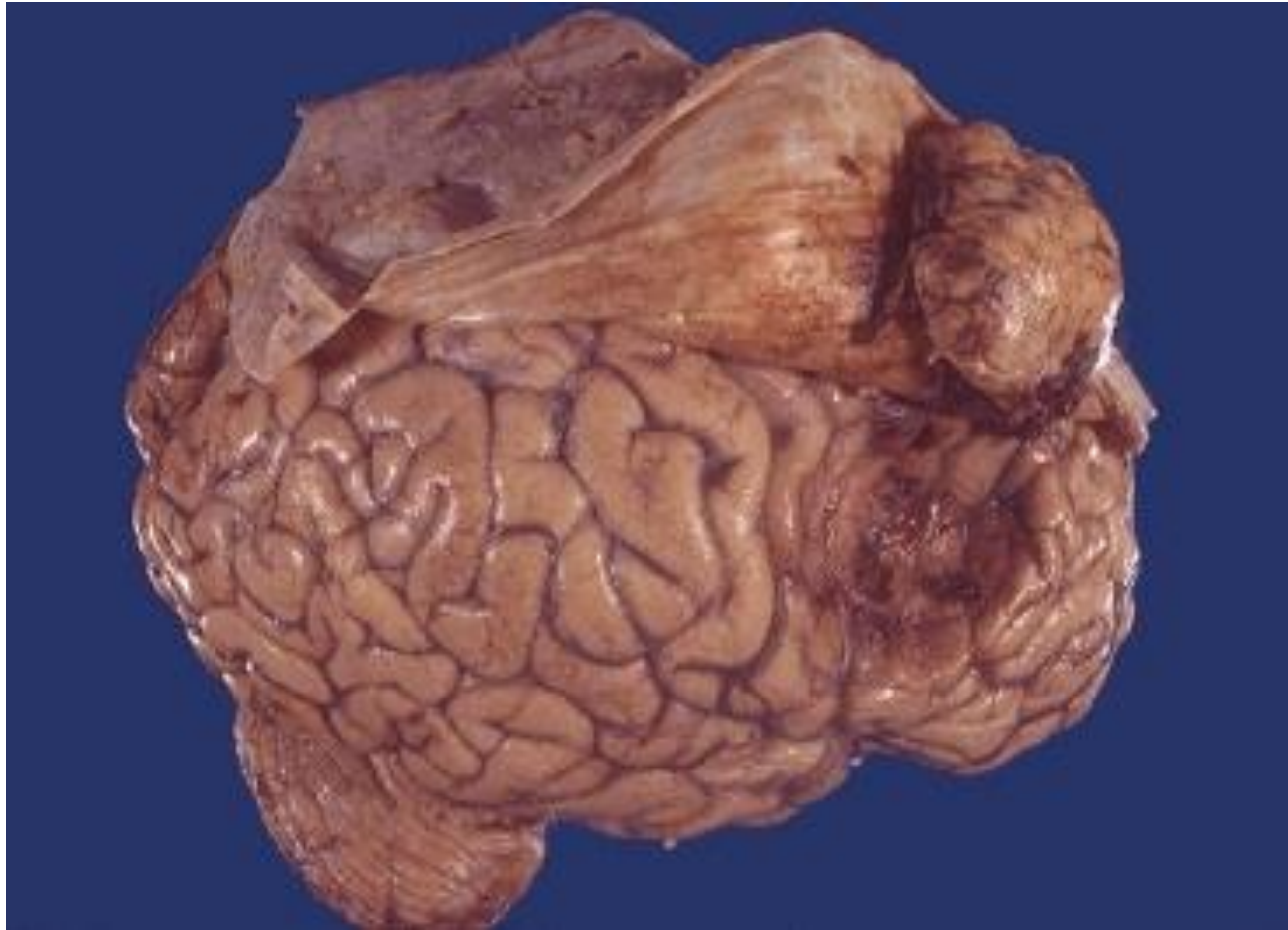

Homer Wright Rosettes

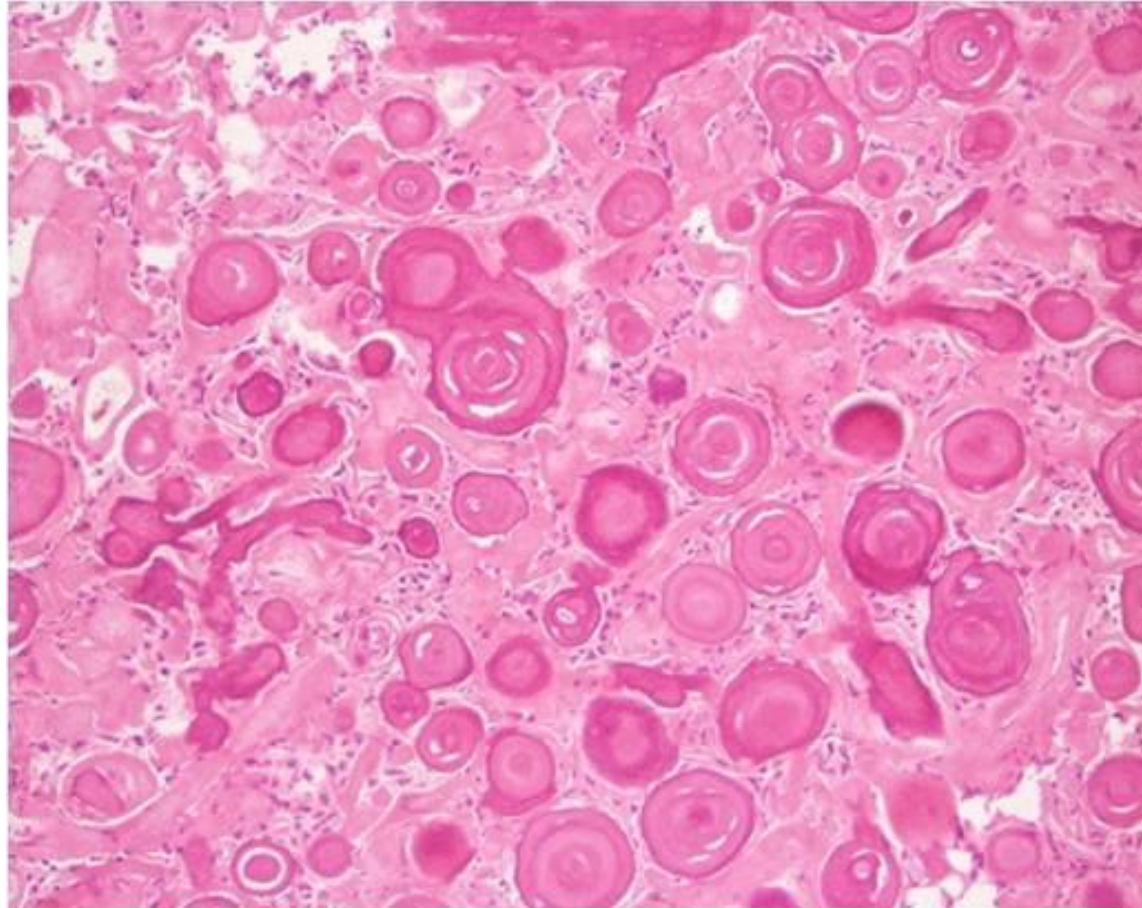




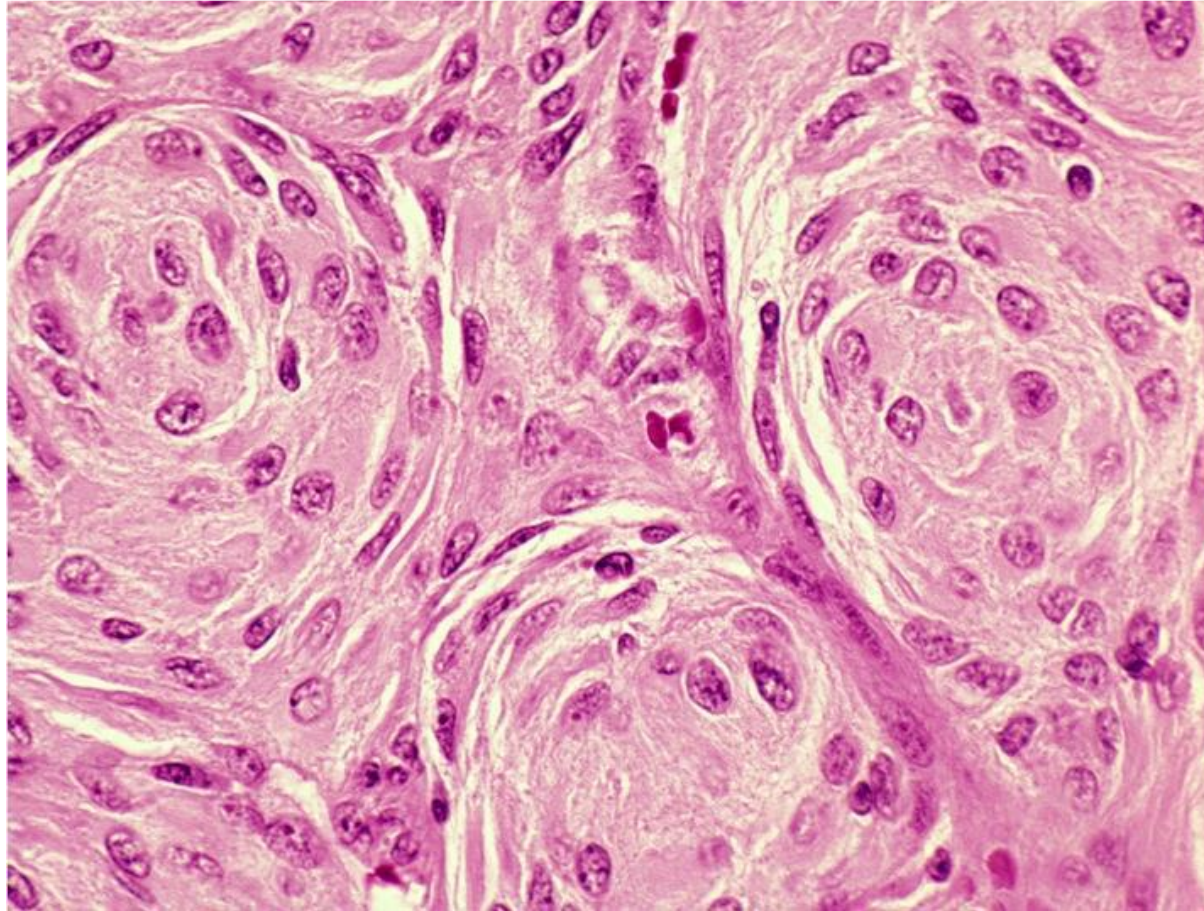
Meningioma.. Note that the mass is related to the dura, not the brain parenchyma



pasammomatous



syncytial



lymphoma

