# ANATOMY

## SHEET

Done By: Ayat M. Zghoul
Corrected By: Amer Sawalha
Subject: Vertebral Column
Doctor: Fadi Al-Hadidi

*This lecture is about the vertebral column (bones, muscles and clinical applications).*

## *Structure of the Vertebral Column*

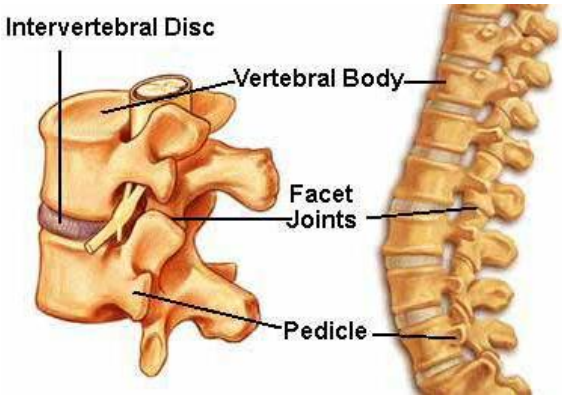


If we look at the vertebral column, we will notice that it is composed of multiple vertebrae and intervertebral discs between them.

- Why is the vertebral column composed of multiple vertebrae instead of being a single unit?
  Multiple segments give us a wide range of motion (flexion, extension, lateral flexion and rotation). In fact, this is why we can swim, move, dance, jump and so on.

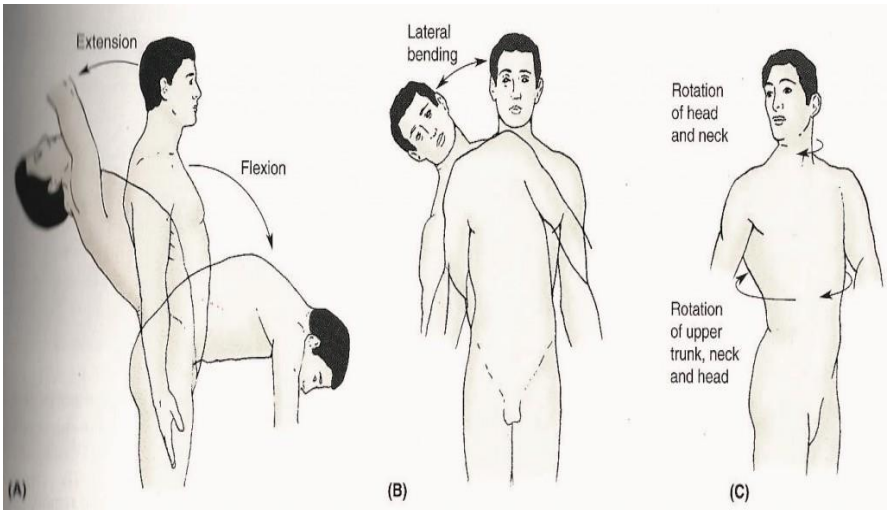


- If we look at the vertebral column in an anterior-posterior (AP) view (as shown in the figure on the right) we will notice that it is **straight**, but why is it straight?
  1. To give the body its shape
  2. To keep the head centered over the pelvis because the body is always trying to reach equilibrium.
  3. The most important reason is to keep the brain at the center of gravity.

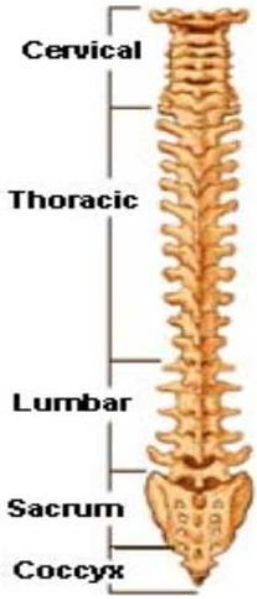

- If we look at it in the lateral view, we'll see **multiple curvatures** (as shown in the figure on the right). Why?

  We are always under the effect of gravity. Hypothetically, if there are no curvatures, <u>the center of gravity will be at the center of the body</u> (the center of the vertebral column). Therefore, the gravity will compress our bones over time so we'll end up becoming shorter. However, the curvatures allow the gravity line to pass anteriorly and posteriorly equally so the **distribution of weight is anterior and posterior**.

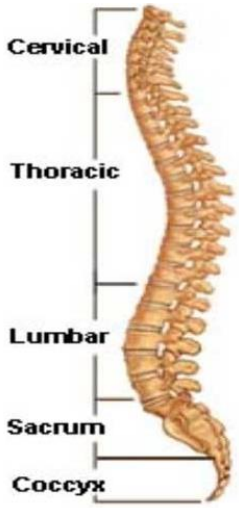


- The curvatures of the vertebral column are divided into:
  1. Primary Curves
  2. Secondary Curves

- What are primary curves? They are referred to as **kyphosis.** There are 2 kyphoses in the vertebral column: **thoracic kyphosis** (<u>concaved</u> anteriorly and spans from T2 to T12) and the **sacrococcygeal kyphosis** (<u>concaved</u> anteriorly and spans from the lumbosacral joint to the tip of the coccyx).

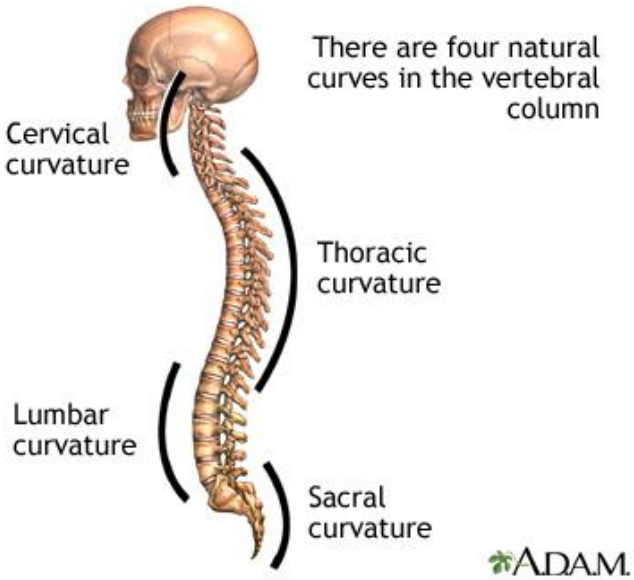


- What are secondary curves?

  They are referred to as **lordosis.** There are 2 lordoses in the vertebral column: **cervical lordosis** (<u>convexed</u> anteriorly and spans from C1 to T2) and **lumbar lordosis** (<u>convexed</u> anteriorly and spans from T12 to the lumbosacral joint). <u>Most patients complain of back pain in the regions of the secondary curves.</u>

- Why are kyphoses primary curves and lordoses secondary curves?

  Primary curves are formed during fetal development, while secondary curves develop after birth. If we observe the fetal position, we will notice **kyphosis** only (concaved). When the infant raises his/her head, he/she will develop **cervical lordosis**. The infant will develop **lumbar lordosis** as soon as he/she starts to sit down.

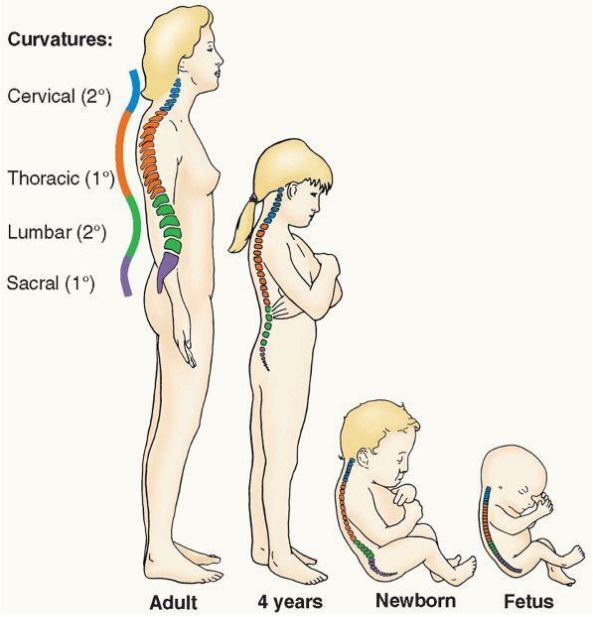


- The vertebral column is classified into regions according to their location:
  1. Cervical
  2. Thoracic
  3. Lumbar
  4. Sacral
  5. Coccygeal
- The basis of this classification is that some diseases affect certain regions more than others.

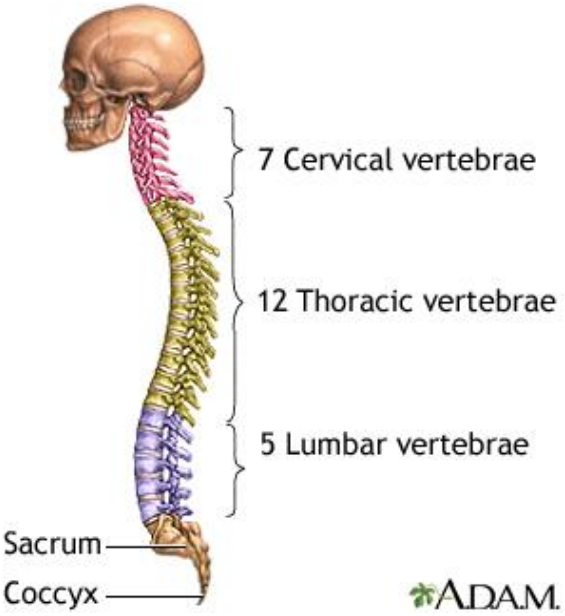


- For a correct classification, the vertebrae in each region should be categorized according to common properties such as <u>shape and function</u>. For instance, the cervical vertebrae are similar to each other. However, they are different from the thoracic vertebrae.

- The vertebral column is divided into **segments**, or **movement units**, and each segment (shown in the first figure in this sheet) consists of <u>2 vertebrae and the intervertebral disc</u> in between. Multiple segments permit a greater range of motion. In fact, multiple segments increase the flexibility of the body because, for instance, flexion of the cervical region can occur simultaneously with extension of the lumbar region.

## *Clinical Cases*

**CASE 1**

The patient shown on the right doesn't have a straight vertebral column in the AP view. In fact, the patient has lateral deviation of the spine. This is referred to as **Scoliosis**.

The x-ray also displays the deformity in the AP view.

**CASE 2**

The patient's x-ray shows that he/she has normal cervical lordosis, but there is **hyperkyphosis**, or **hunchback**, in the thoracic region of the vertebral column. Hyperkyphosis means that the kyphosis of the thoracic region is amplified.

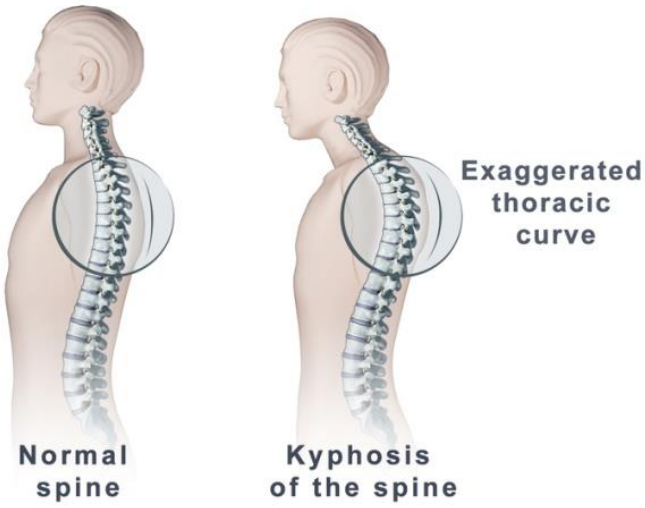


Osteoporosis and arthritis might cause such condition.

## *Classification of Vertebrae*

- Vertebrae can be classified according to shape into **typical** and **atypical** vertebrae. **Typical** vertebrae have a body on the anterior side and an arch on the posterior side.
  **Atypical** vertebrae have different structures that do not involve a body on the anterior side and an arch on the posterior side.
- To wrap up, there are 2 classification schemes:
  1. According to the site: cervical, thoracic, lumbar, sacral, & coccygeal.
  2. According to the shape: typical and atypical.
- The figure below shows different typical vertebrae including cervical, thoracic and lumbar respectively. Typical vertebrae have a **body** (anterior) which is the major part of the vertebra that bears weight. The **intervertebral disc** is inferior to the body and works as a shock absorber. Posteriorly, there is an arch which is composed of two **pedicles**, two **lamina**, a **spinous process**, two **transverse processes** and four **accessory processes** (**2 superior and 2 inferior articular processes** which produce the **facet joint** between the 2 vertebrae.

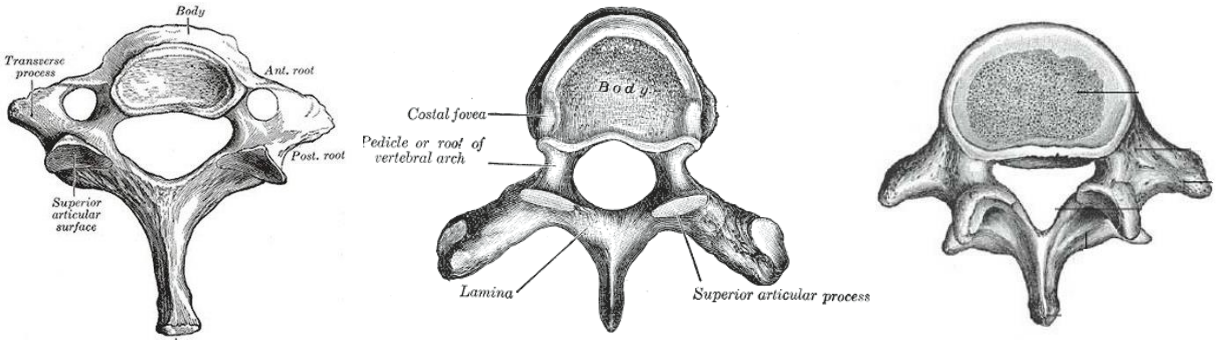


- The figure below shows different atypical vertebrae found in the vertebral column including: atlas, axis, fused sacral, and fused coccygeal vertebrae respectively.

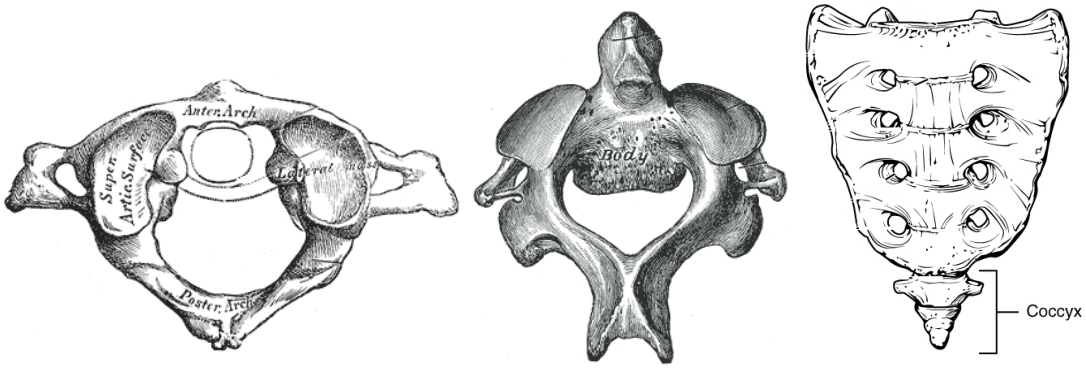

## *Typical Vertebrae*

1. **Cervical** Vertebrae

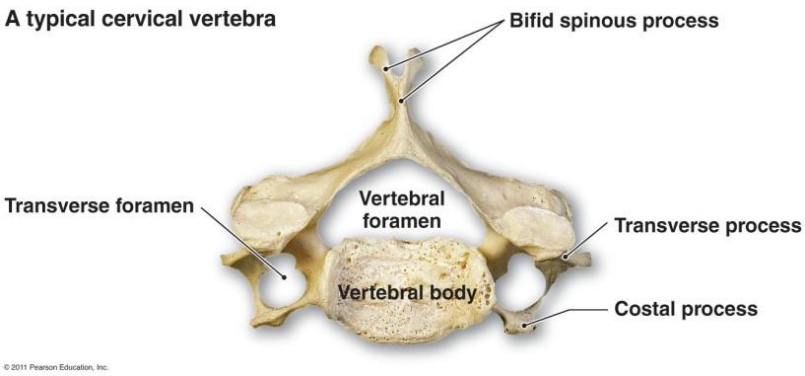


   Aside from the body and the arch which are distinct features of typical vertebrae, there are some special features for the cervical vertebrae:
   a. Wide vertebral foramen.
   b. Two extra foramina called the transverse foramina through which the vertebral arteries pass.
   c. Small body.
   d. Bifid spinous process (Bifid means divided into 2 equal parts).

- Why are the cervical vertebrae small?

  The function of the cervical vertebrae is to carry the head. The head is small, thus, larger vertebrae are not needed in this case.

2. **Thoracic** Vertebrae

   Special features of the thoracic vertebrae:
   a. The body is larger than the cervical vertebrae but smaller than the lumbar vertebrae.
   b. The body has a heart shape.
   c. The vertebral foramen is smaller than that of the cervical and has a circular shape.
   d. The spinous process is single and thinner.
   e. Overall it is longer than the cervical.

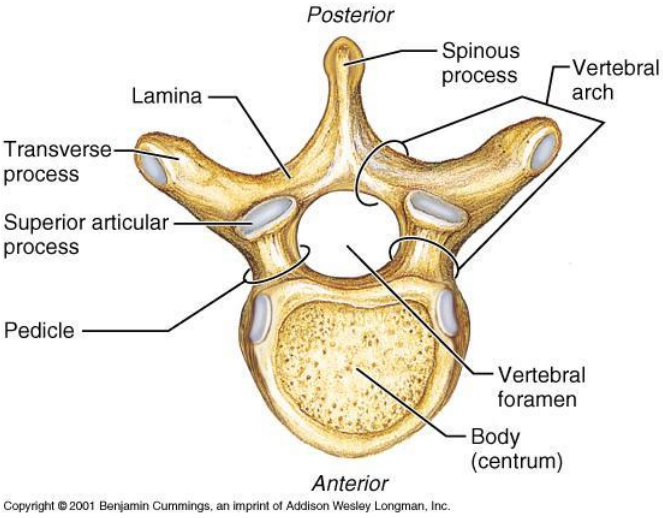

3. **Lumbar** Vertebrae
   Special features of the lumbar vertebrae:
   a. Largest body.
   b. The vertebral foramen is triangular (smaller than that of the thoracic).
   c. Body has a kidney shape.
   d. Spinous process is shorter and thicker.
   e. Transverse processes extend more laterally.

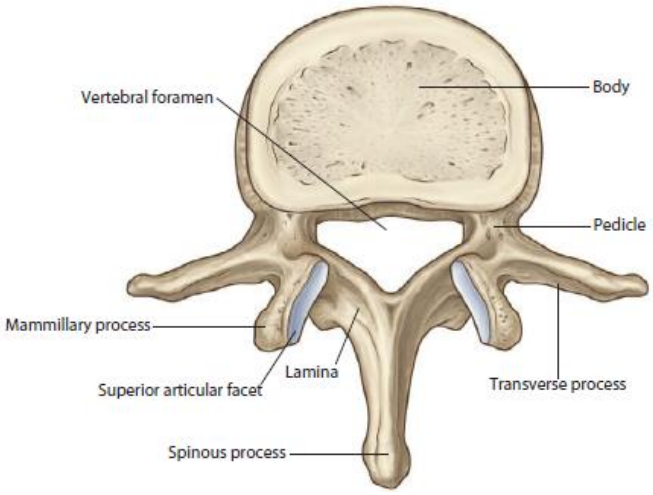


Note:

- Body of the lumbar vertebrae > Body of the thoracic vertebrae > Body of the cervical vertebrae
  This is due to the fact that vertebrae at the bottom of the column bear more weight than those at the top.
- In addition to the size variation of vertebrae between different regions of the vertebral column, there is a size variation within each region. For example, C4 > C3 > C2 > C1.

❖ Observe the x-ray on the right to understand its description below:
   1) This x-ray displays the vertebral column in the AP view.
   2) There is a variation in the size of the vertebrae going down the column.
   3) The spinous process is at the center.
   4) The pedicles look like 2 eyes on the periphery of each vertebra.
   5) The intervertebral disc is located in the spaces between vertebrae.
   6) Transverse processes extend laterally from both sides of the vertebrae.

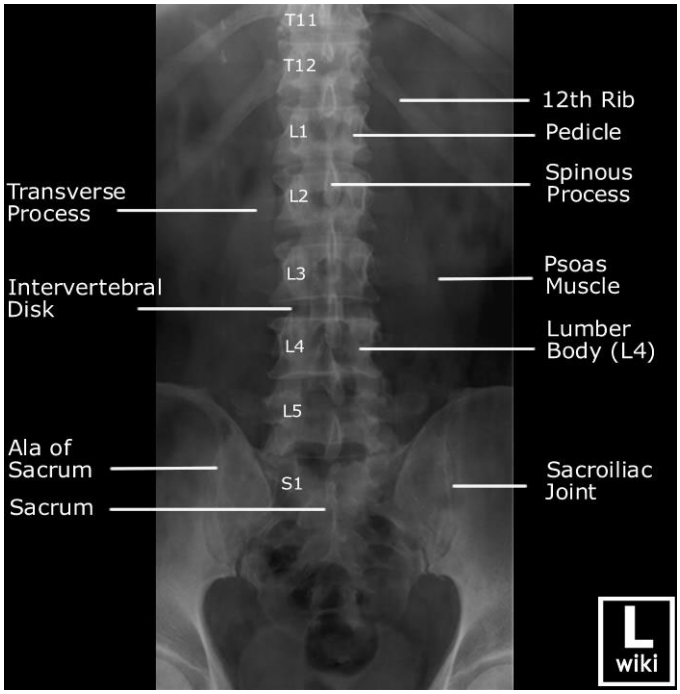

## ***Clinical Cases*** (cont.)

*The following are typical cases of vertebral column fractures.*

**CASE 3**

The x-ray on the right shows that the patient is suffering from a **fracture in the body** of one of the vertebrae. Assuming that the size of the vertebrae increases in the lower region of the column, it is clear that the fractured vertebra appears a bit smaller than the rest of the vertebrae.

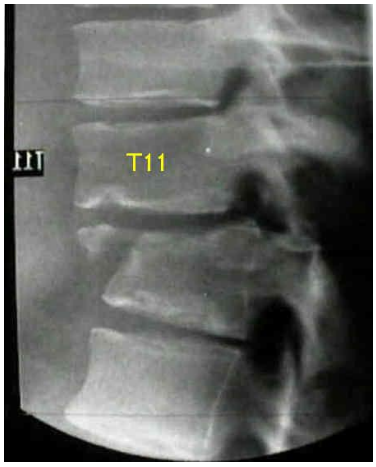


**CASE 4**

The x-ray on the right shows that the patient is suffering from a **compression fracture**. This is evident because the size of the compressed vertebra appears smaller than the adjacent vertebrae in the same region.

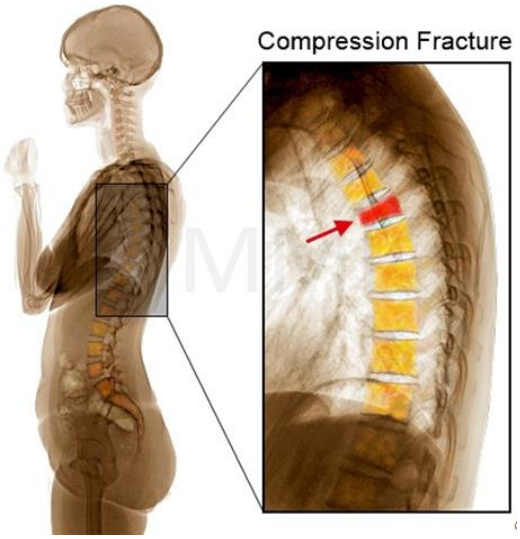


**CASE 5**

The CT scan shows that the patient is suffering from a **burst fracture** which could be the result of falling and landing on the feet from a significant height. A piece from the <u>fracture of the posterior aspect</u> of the vertebra might <u>compress the spinal cord</u>, thus causing <u>complete or incomplete paralysis</u>. The x-ray displays an AP view of the vertebral column after <u>stabilizing it using screws and rods</u>.


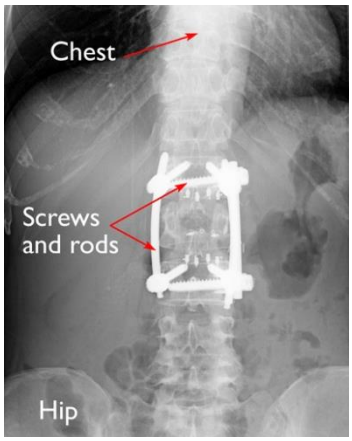

## *Facet Joints*

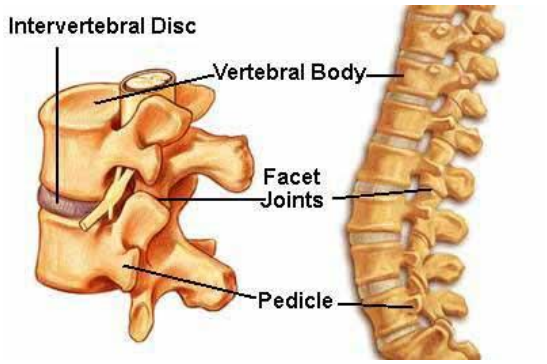


- A facet joint is a **synovial joint** that joins the superior articular process of the inferior vertebra with the inferior articular process of the superior vertebra.

- Diseases that can affect synovial joints:
  1. Gout
  2. Osteoarthritis (degenerative infection)
  3. Rheumatoid arthritis
  4. Dislocation because of a trauma

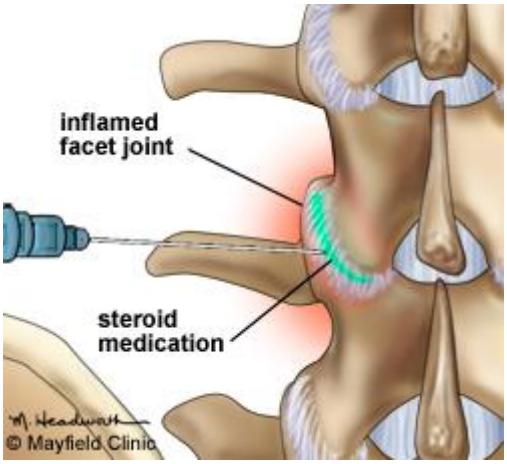


- The facet joints (and synovial joints in general) are essential for movement.

- If arthritis affects these joints, medications like steroids (anti-inflammatory) and anesthesia are given as a localized injection in the joint. To administer such medications in the facet joints, a dye is used to color the joint to determine the location of the joint.

Remember:

- ✓ A joint is the articulation of two or more bones for the purpose of motion of body parts.
- ✓ There are many types of joints including: synovial, fibrous, and cartilaginous joints.
- ✓ Joints are encapsulated for protection.
- ✓ Cartilage reduces friction and allows free and easy movement of the joint.
- ✓ Synovial fluid is the main component of synovial joints. Synovial fluid reduces friction.
- ✓ Nerve endings are present in joints. Some nerve endings transmit pain while other nerves are important for proprioception (ability to sense stimuli originating within the body regarding position and motion). Even if a person is blindfolded, proprioception allows the person to sense flexion or extension (motion) of any body part and determine the position of a certain body part (for example, if his/her hand is above his/her head).

## *Muscles of the Back*

- The muscles of the back are divided into 3 layers: superficial, intermediate and deep layers.

- What is the purpose of having more than one layer of muscles in the back? Protection of the vertebral column is not a valid reason. 1 layer of muscles would be enough for movement, but **3 layers are needed to stabilize the back** because certain muscles in some layers get tired after prolonged contraction (standing up for 4 hours or more). The 3 layers of muscles also increase the range of motion.

- Some muscles participate in the movement of other regions. Trapezius and latissimus dorsi participate in the movement of the shoulder joint. Serratus anterior and posterior (intermediate layer) participate in respiration.

- The primary function of the muscles of the back is to stabilize the vertebral column.

- The secondary functions of the muscles of the back are increasing the range of motion and participating in the movement of other regions.

| **Muscles of the Back** | | |
|---|---|---|
| **Superficial Layer** | **Intermediate Layer** | **Deep Layer (consists of 3 layers)** |
| Trapezius | Serratus Anterior | Splenius |
| Latissimus dorsi | Serratus Posterior Inferior | Erector Spinae:<br>1) Iliocostalis<br>2) Longissimus<br>3) Spinalis |
| Levator scapulae | Serratus Posterior Superior | Transversospinalis:<br>1) Semispinalis<br>2) Multifidus<br>3) Rotatores |
| Rhomboid minor | Levatores costarum | |
| Rhomboid major | | |

NOTE: THE NAMES, ORIGINS, AND INSERTIONS OF THESE MUSCLES ARE NOT REQUIRED.

- The main characteristic of the small muscles in the deep layer is resistance to fatigue. They work when all other layers of muscles get fatigue. They are also known as red muscle or slow muscles because their fibers are small, have extensive blood supply, and contain more mitochondria.

## ***Clinical Cases*** (cont.)

**CASE 6**

- The patient on the right has a normal straight back in the AP view.
- The patient on the left has a deviation of the trunk to the left side. This is evident because of the large space between the right arm and the right side of the back and the small space between the left arm and left side of the back.
- **Diagnosis**: Palpating the left side of the back will verify that there is a muscle spasm because of the thickened muscles which are abnormally contracted.
- **Reason**: The patient had this deviation in the back after carrying something really heavy.
- **Note**: there is no actual symmetry in the muscles of the back. This is the reason why each person stands up in a certain way, sleeps on a certain side, and uses right or left hand to write.