White blood cells disorders

Non-neoplastic

A-LAB 0004

Lab. Request Form

مستشفى الجامعة الأردنية
Jordan University Hospital

Surname : .....
Forname : .....
Sex : ..... Date of Birth : .....
Hospital No. : .....
Ward / Clinic : .....
Consultant : .....
Address : .....

Lab. Ref. No. : .....
Rec. Date : .....
Rec. Hr. : .....
Charges J. D. Fils
.....
.....

Nature of Specimen / s .....
Date .....
Hr .....
Dr. Sig. .....

Code No.				Result	
C B C 103001	103005	❑	WBC × 12^{12}/L		4.0 - 10
	103004	❑	RBC × 10^9/L		M 5.5 ± 1.0 F 4.8 ± 1.0
	103003	❑	Hemoglobin g/dl		M 16 ± 2 F 14 ± 2
	103003	❑	HCT		M 0.46 ± 0.05 F 0.42 ± 0.05
		❑	MCV fl		80 - 100
		❑	MCH pg / cell		26 - 34
		❑	MCHC g / dl		31 - 36
103006		❑	Platelet × 10^9/L		140 - 440
103011		❑	ESR mm / hr		M 0 - 15 F 0 - 20
103010		❑	Retic. Count		0.005 - 0.015
103009		❑	Eosin. Count t × 10^9/L		0.05 - 0.45
103020		❑	Sickle Cell		Nil
103007		❑	Blood Film		
103025		❑	Malaria Smear		
103031		❑	PT		
103032		❑	PTT		
103033		❑	E G T		

			Result	
103012	❑ Hb. Electrophoresis			
103008	❑ DIFFERENTIAL	Neut - Band %		0
		Neut - Sig. %		40 - 75
		Eosinophil %		1 - 6
		Basophil %		0 - 1
		Lymphocyte %		20 - 45
		Monocyte %		2 - 10

LAB COMMENTS

.....
.....
.....
.....
.....
.....
.....
.....
.....
.....

Date Reported Reported By

HEMATOLOGY I

Leukopenia

- Leukopenia: decrease in WBC count below average levels, results most commonly from a decrease in neutrophils

Neutropenia

- ANC < 1500 cell/ microliter
- Severe neutropenia: <500, spontaneous infection

Causes of neutropenia

1) Decreased production

- **Part of pancytopenia**: aplastic, myelophthisic, megaloblastic anemias, myelodysplastic syndrome, chemotherapy
- **Isolated neutropenia:**

Acquired: drugs (anti epileptic, anti psychotic, anti-hyperthyroidism), autoimmune

Congenital:

- **S**chwachman-**D**iamond **S**yndrome: AR, **S**B**DS** gene mutation, skeletal abnormalities, pancreatic exocrine deficiency
- Chediak- Higashi syndrome: AR, **LYS**T gene, abnormal **lys**osomal aggregation and dysfunction, platelet dysfunction, albinism

BM morphology: decreased myeloid cells (hypocellular)

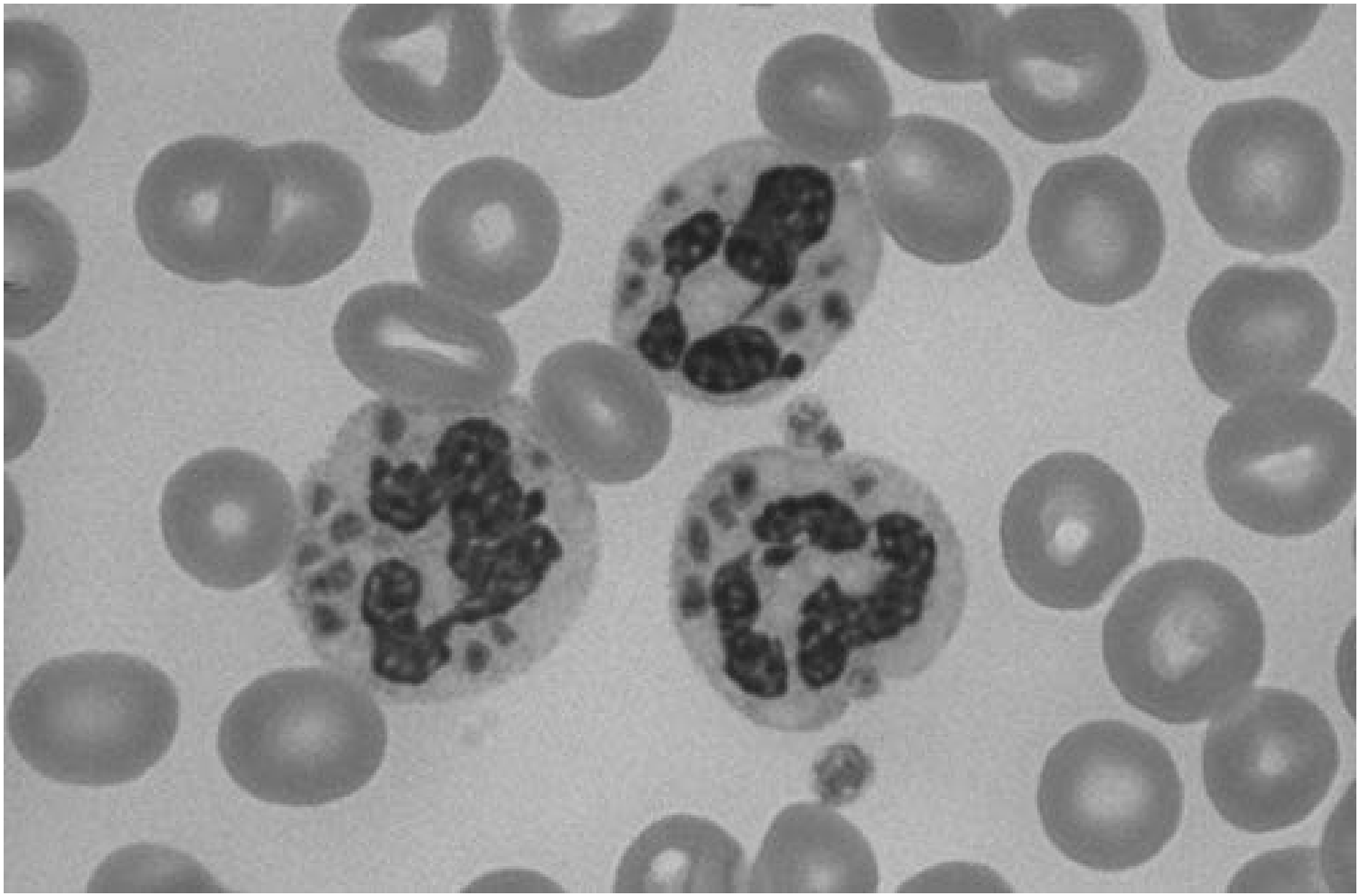

- Chediak-Higashi syndrome (CHS) is due to aberrant cellular handling of lysosomes. Giant granules are found in many cell types, including neutrophils. CHS patients may also be neutropenia

Causes

Increased destruction

- Special infection settings (severe sepsis, salmonella, brucella)
- Immune mediated
- Cyclic neutropenia (**ELA**NE gene mutation, abnormal **Ela**stase accumulation, apoptosis)
- Hypersplenism
- PNH

BM morphology: increased myeloid cells (hypercellular)

Lymphopenia

- Less common than neutropenia
- HIV infection (increased destruction)
- Corticosteroid therapy (inhibits migration)
- Congenital immunodeficiency (decreased production)

Reactive Leukocytosis

- An increase in the number of white cells in the blood is common in a variety of inflammatory states caused by microbial and nonmicrobial stimuli. Leukocytoses are relatively nonspecific and are classified according to the particular white cell series that is affected
- Leukemoid reaction: marked increase in WBC count with left-shifted granulpoiesis, mimicking chronic myelogenous leukemia. Occurs in severe stress, paraneoplastic syndrome

Neutrophilia

- Infection (bacterial)
- Burn
- Tissue necrosis (myocardial infarction)
- steroid
- Neutrophils show toxic granulation and cytoplasmic vacuoles

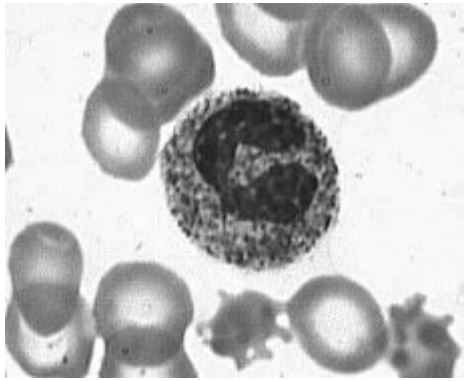

Eosinophilia

- Allergic reactions
- Parasitic infections
- Drug reactions
- Some malignancies (Hodgkin lymphoma)

Monocytosis

- Chronic infections
- Inflammatory bowel disease
- Rheumatologic diseases

Lymphocytosis

- Viral infections
- Tuberculosis
- Rheumatologic diseases

Reactive Lymphadenitis

- Lymphocyte response to antigen stimulus in the body (Infections, autoimmune)
- Leads to lymph node enlargement (lymphadenopathy)
- Acute is commonly painful, follows bacterial or viral infections

Chronic Reactive Lymphadenitis

- Follicular hyperplasia: proliferation of germinal center B-cells resulting in enlarged follicles, occur in HIV, Toxoplasmosis, Rheumatologic diseases
- Paracortical (diffuse) hyperplasia: proliferation of T-cells in the interfollicular areas, caused by viral infection, drug reaction, post vaccination



Normal Lymph Node

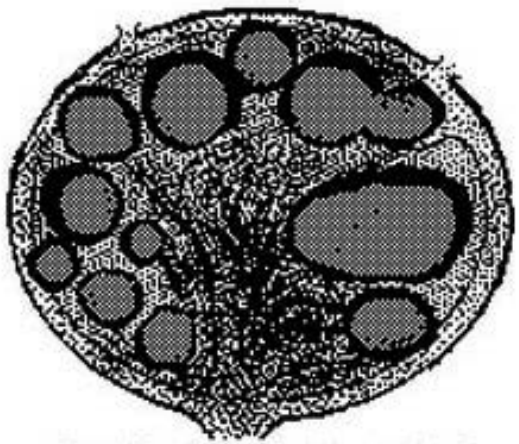

Reactive Follicular Hyperplasia



Diffuse Hyperplasia

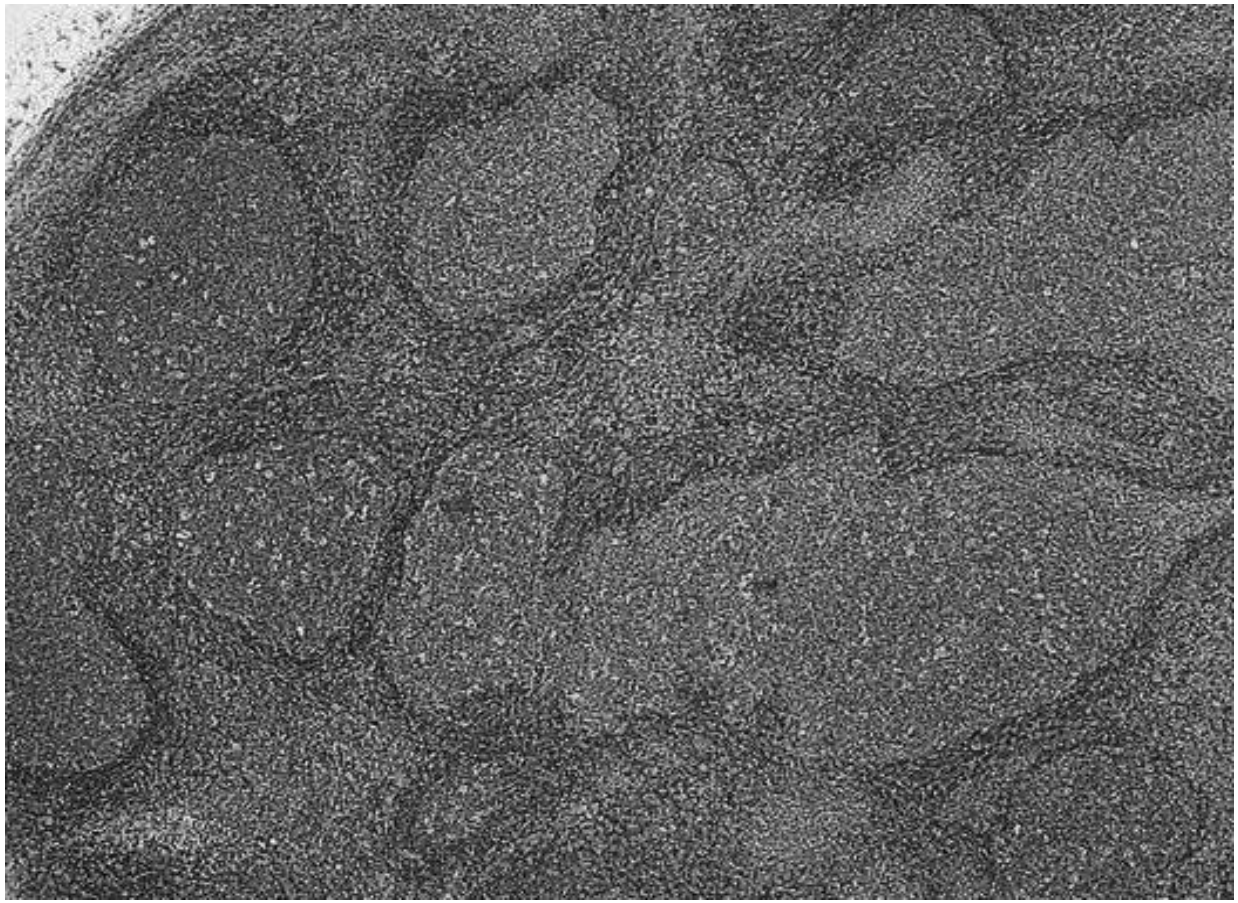

- Reactive follicular hyperplasia: note the enlarged follicles, variable sizes and shapes

Hematopoietic malignancies

- Myeloid
- Lymphoid
- Histiocytic

Myeloid neoplasms

- (1) Myeloproliferative neoplasms
- (2) Myelodysplastic syndromes
- (3) Acute myeloid leukemia

Features:

- Recurrent genetic mutations
- Increased bone marrow cellularity
- Tendency to progress to AML

Risk factors:

- Chemicals (benzen, pesticides), radiation, congenital diseases (Fanconi), smoking, PNH

- ***Normal Adult cell count in BM aspirate smear***
- Blasts: <5%
- Monocytes: <5%
- M:E 3-4
- Plasma cells: <3%

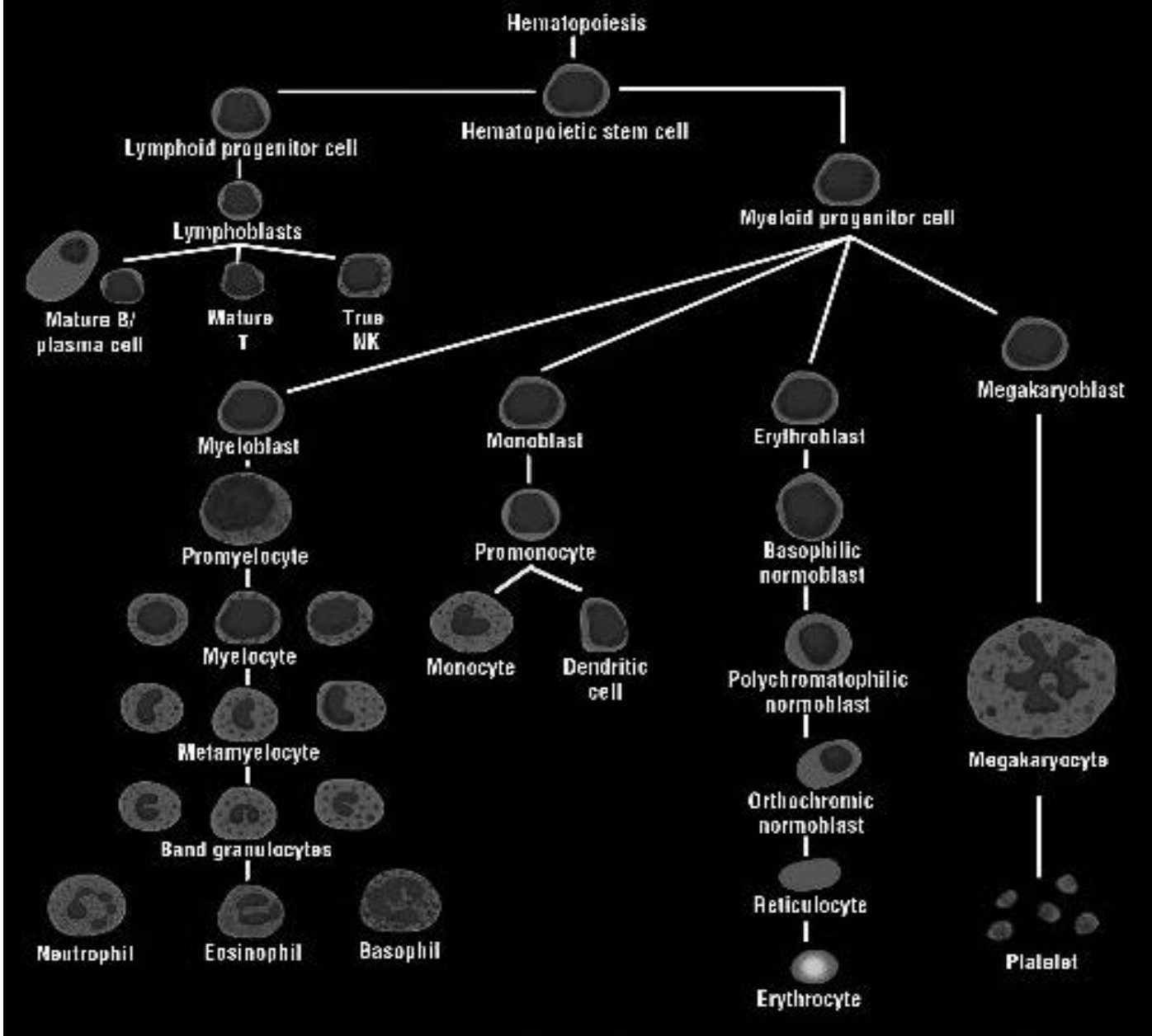

This simplified schematic illustrates general features of lymphoid and myeloid cell derivation from pluripotent stem cells. Thus both myeloid and lymphoid lineage cells are derived from a common precursor cell. The general maturation stages, from immature to fully differentiated hematopoietic, are listed.

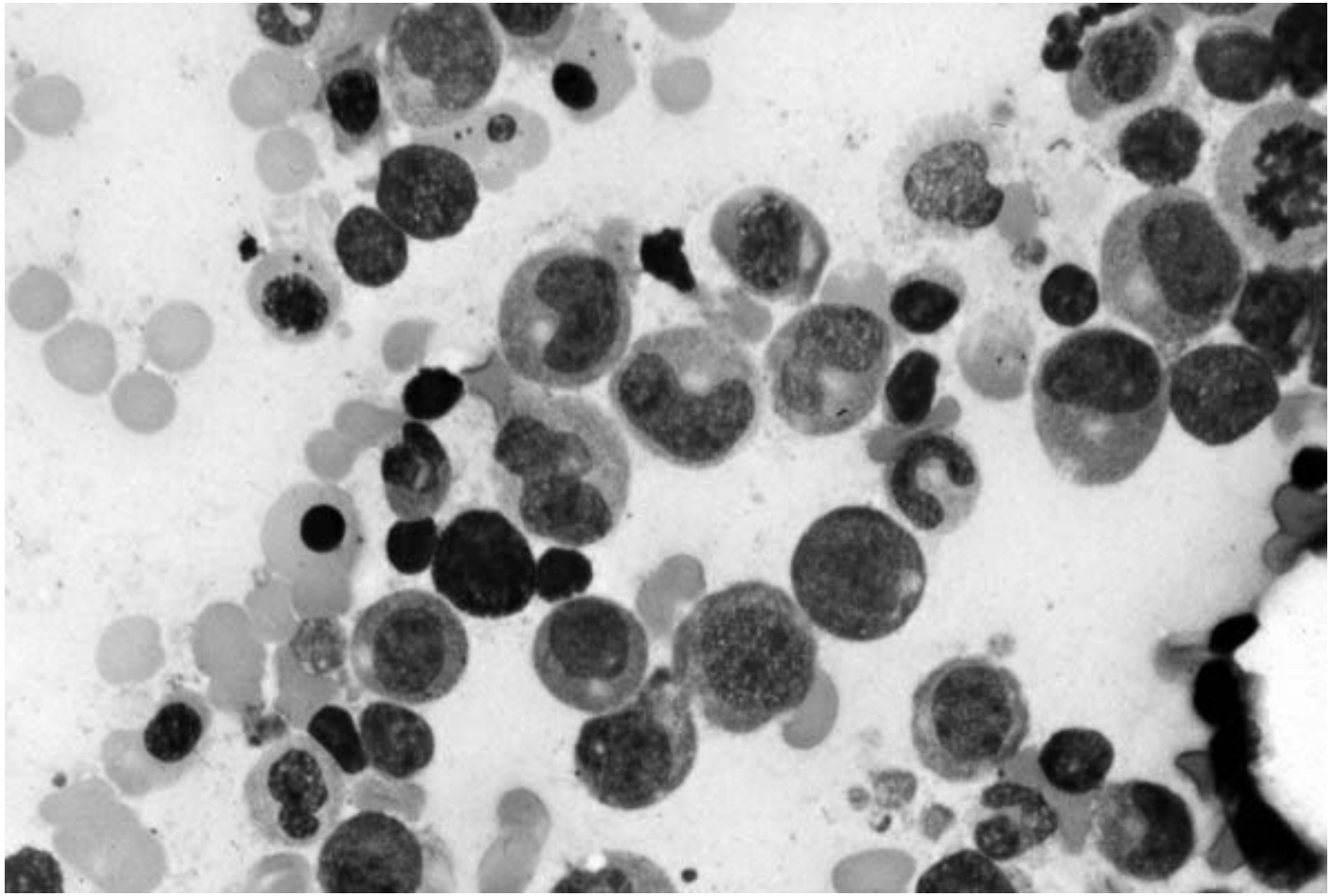

- Aspirate smear from bone marrow shows normal myelogenesis and erythropoiesis

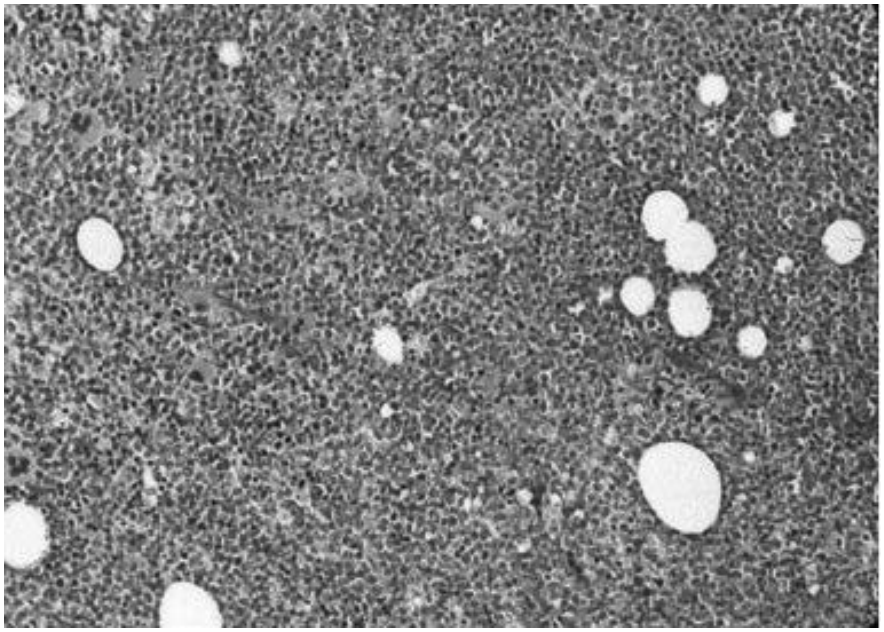

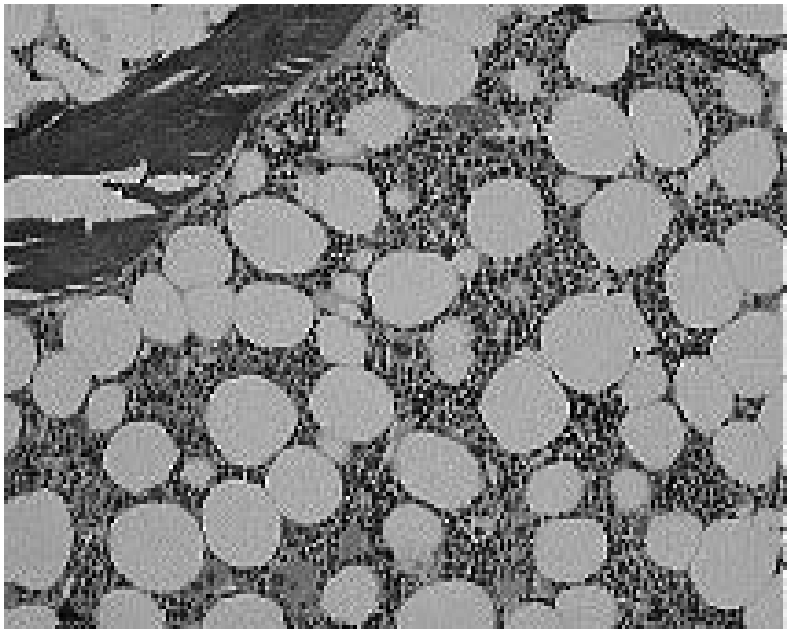

- Normal bone marrow cellularity depends on age (100-age)%

Myeloproliferative neoplasms

- Chronic disorders
- hyperproliferation of neoplastic myeloid progenitors that retain the capacity for terminal differentiation
- Mutation in tyrosine kinase proteins which results in permanent activation of growth factors
- Persistent peripheral blood cytosis (one or more lines)
- The neoplastic progenitors tend to seed secondary hematopoietic organs (the spleen, liver, and lymph nodes), resulting in hepatosplenomegaly (caused by neoplastic extramedullary hematopoiesis)

Chronic myelogenous leukemia

- a balanced (9;22) translocation that moves *ABL* from chromosome 9 to a position on chromosome 22 adjacent to *BCR*
- The new chr22 is known as Philadelphia chromosome
- The *BCR-ABL* fusion gene has a tyrosine kinase activity, stimulating the proliferation and prolonged survival of granulocytic and megakaryocytic cells

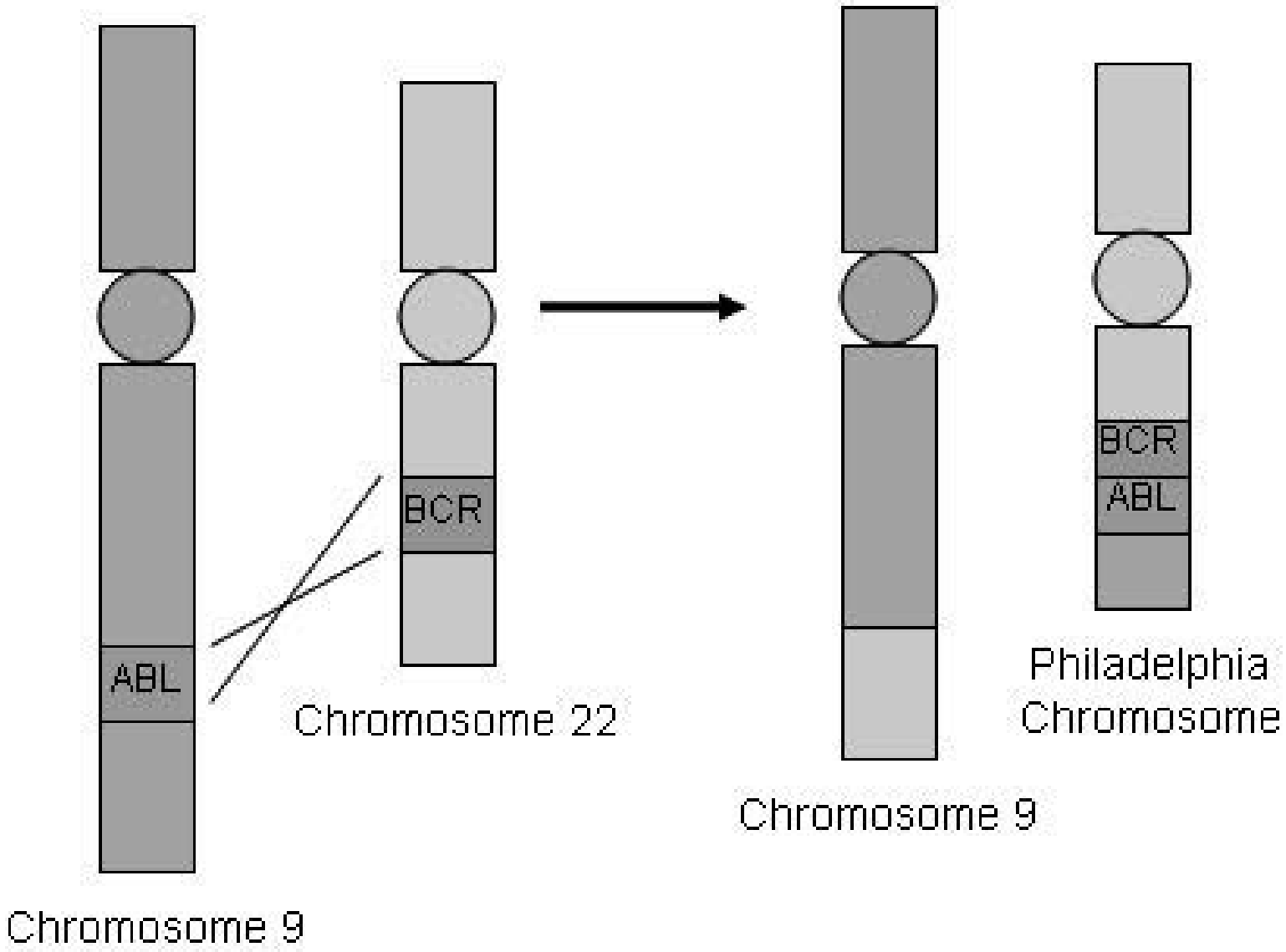
ABL
BCR
Chromosome 22
Chromosome 9
BCR
ABL
Philadelphia
Chromosome
Chromosome 9

manifestations

- Peripheral blood shows markedly increased WBC count, sometimes exceeding 100,000 cell/uL
- Most of the cells are neutrophils, metamyelocytes and myelocytes
- Basophils and eosinophils are also increased
- Thrombocytosis and anemia are common
- The bone marrow is hypercellular owing to increased numbers of granulocytic and megakaryocytic precursors
- Spleen is enlarged with extramedullary hematopoiesis

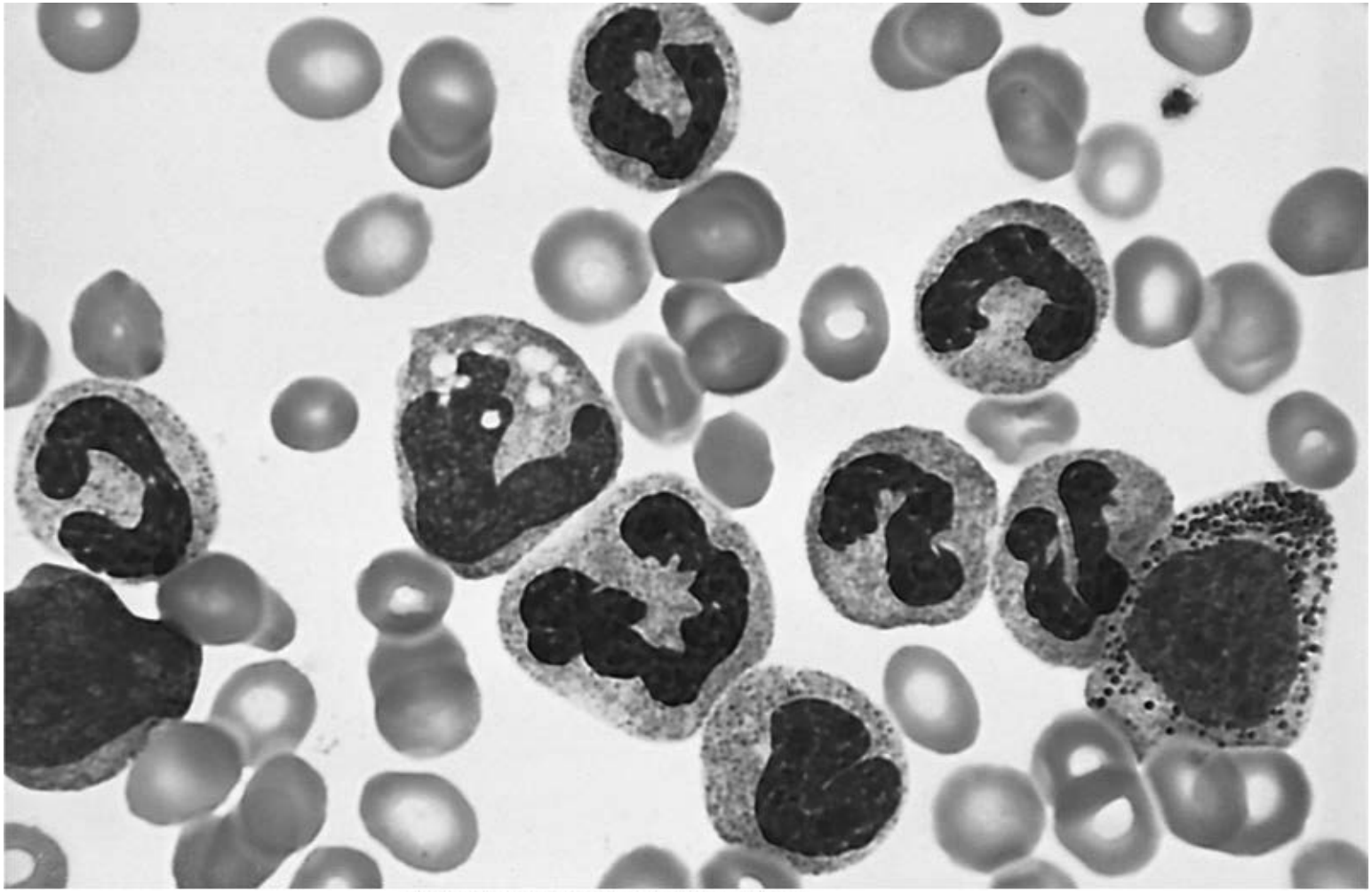

- Chronic myelogenous leukemia-peripheral blood smear. Granulocytic forms at various stages of differentiation are present

Primary Myelofibrosis

- Brief period of granulopoiesis and megakaryopoiesis, rapidly followed my BM fibrosis and elimination of hematopoietic elements
- The fibroblast proliferation is stimulated by platelet-derived growth factor and transforming growth factor β released from neoplastic megakaryocytes
- Hematopoiesis takes place in spleen and liver
- RBC's escaping the fibrotic stroma in BM are deformed and take the shape of "tear-drops"

Manifestations

- BM is initially hypercellular with increased atypical megakaryocytes
- PB: leukocytosis, shift to left, thrombocytosis, anemia, nucleated RBCs, tear drop cells
- Later in disease, become fibrotic and hypocellular, pancytopenia
- Spleen shows marked extramedullary hematopoiesis

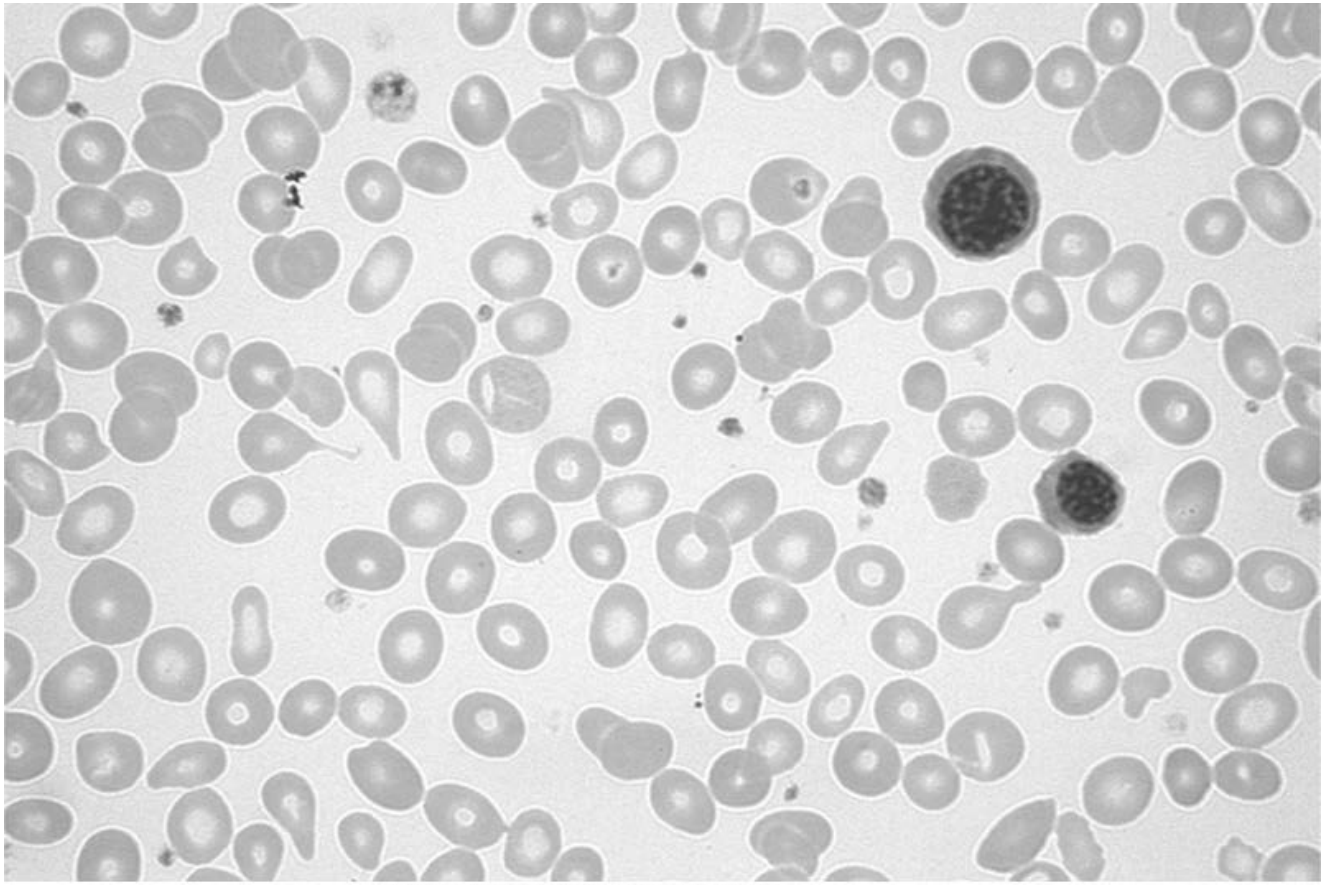

- Two nucleated erythroid precursors and several teardrop-shaped red cells are evident

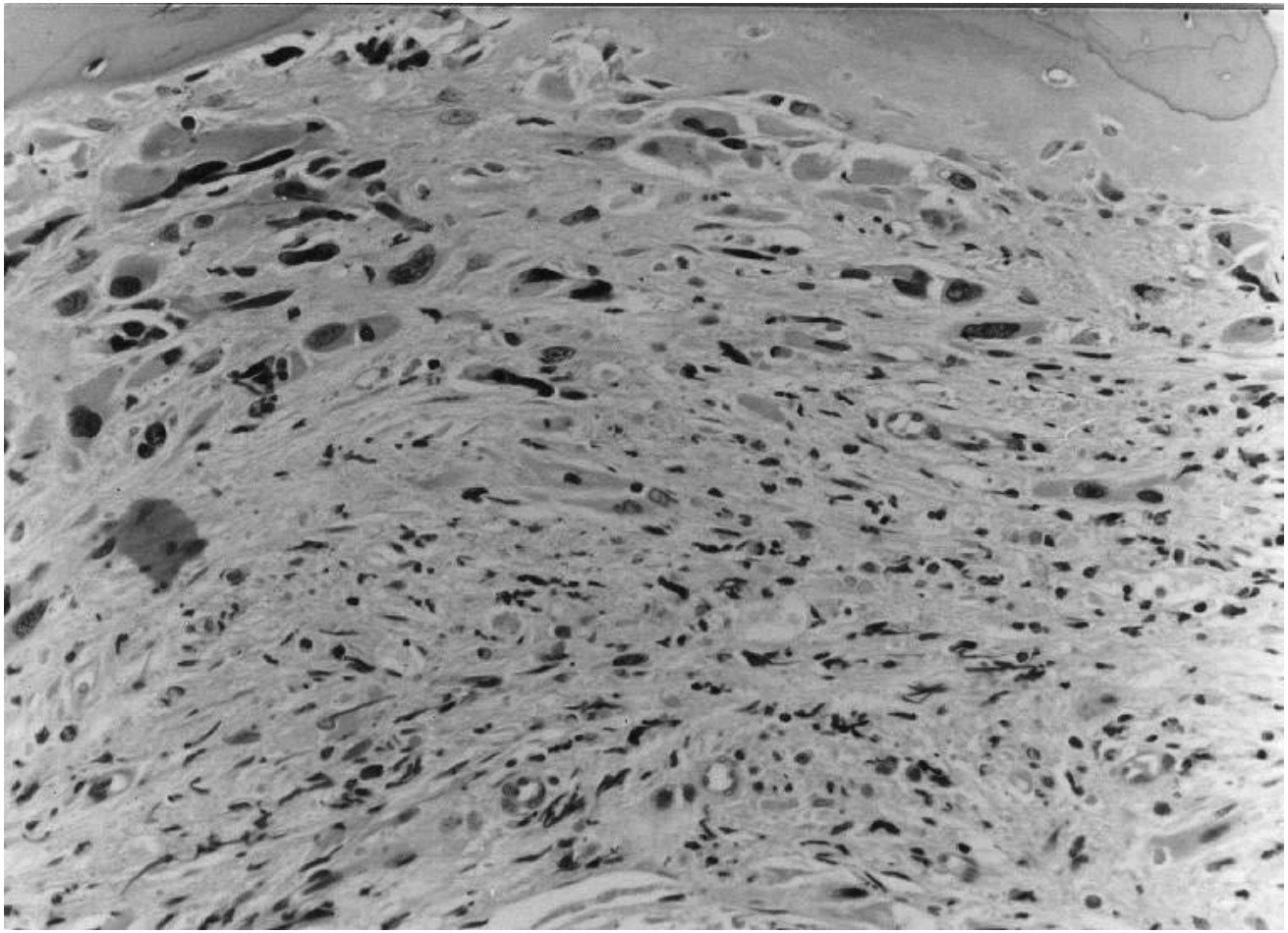

- BM biopsy shows hypocellular marrow, spindle shaped stroma and atypia of megakaryocytes

Essential Thrombocythemia

- Chronic MPN involves primarily megakaryocytes
- Sustained thrombocytosis (>450×10^9/L)
- Increased number of large mature megs
- Tendency for thrombosis and hemorrhage
- + Jak2 in 50%
- No BM fibrosis
- +/- splenomegaly

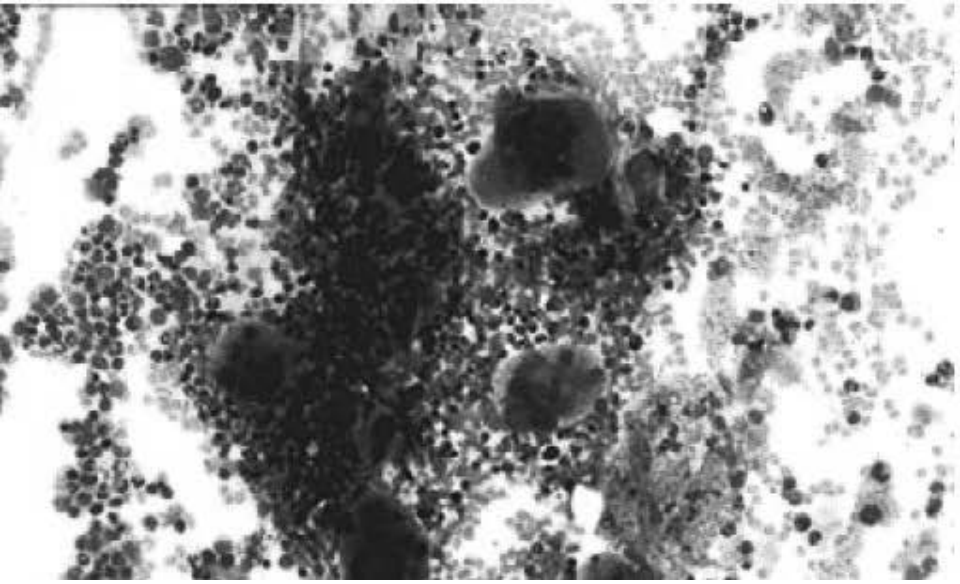

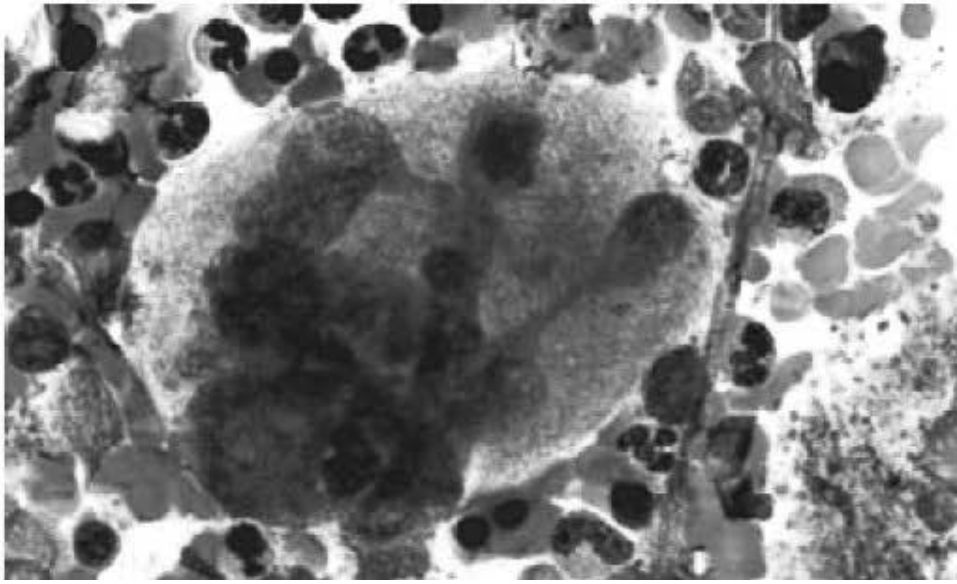

- ET: left: increased number of megakaryocytes. Right: megakaryocytes are large, mature with hyperlobated nuclei

Myelodysplastic syndromes

- Group of clonal stem cell disorders characterized by maturation defects that are associated with ineffective hematopoiesis
- Hematopoietic cells are morphologically abnormal, stay within the bone marrow and hence the patients have peripheral blood cytopenias
- The hallmark of MDS is persistent (refractory) peripheral cytopenia and BM morphologic dysplasia

Pathogenesis

- Cytogenetic analysis commonly reveals chromosomal aberrations
- Primary (idiopathic): more common, risk factors?
- Secondary (therapy related): History of chemotherapy or radiotherapy 2-8 years ago
- All forms of MDS can transform to AML, but transformation occurs with highest frequency and most rapidly in t-MDS

Findings

- Erythroid: megaloblastoid nuclei, nuclear/cytoplasmic asynchrony, multinucleation, ring sideroblasts
- Granulocytes: hyposegmented nuclei, hypogranular cytoplasm
- Megakaryocytes: small size, hypolobated nuclei
- Dysplasia can occur in a single or multiple lines
- With time, blast increases (5-19%), and can progress to acute leukemia

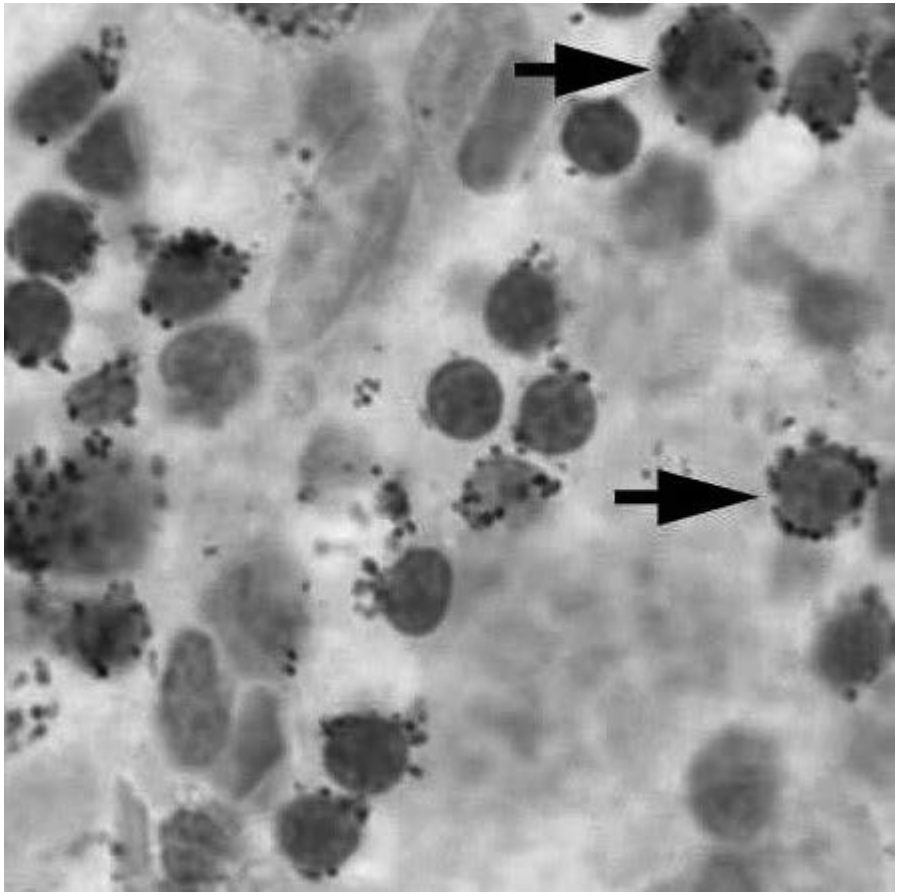

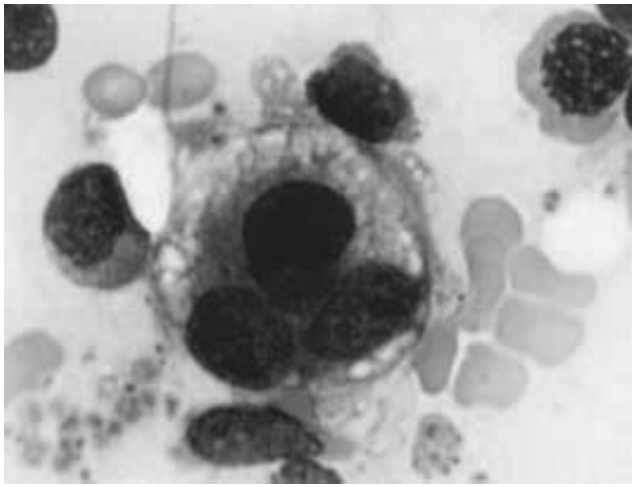

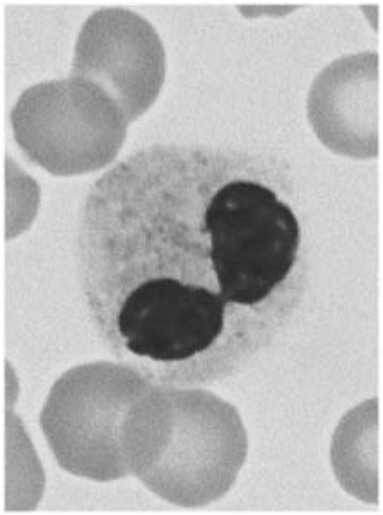

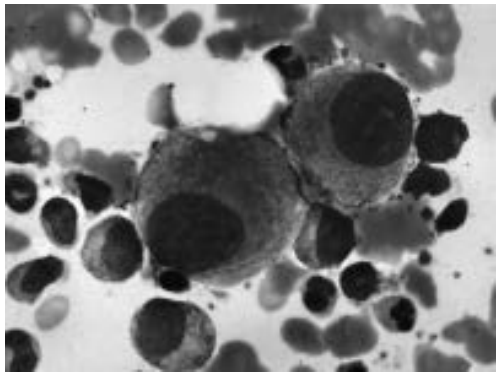

- Upper left: ring sideroblasts (iron stain), upper right: dysplastic erythroid precursor (multinucleation), lower right: dysplastic mega (small, hypolobated), middle: dysplastic neutrophil (hypogranulated cytoplasm, hyposegmented nucleus)

Acute myeloid leukemia

- mutations that impede myeloblast differentiation, and increases proliferation,
- Accumulated blasts leads to marrow failure (myelophthisic anemia)
- AML occurs at all ages, but the incidence rises throughout life
- Diagnosis of AML: blast count is ≥ 20% of bone marrow cells or peripheral blood

FAB-Classification

- M1: AML without maturation (blasts ≥ 80%)
- M2: AML with maturation (blasts 20-80%)
- M3: Acute promyelocytic leukemia
- M4: Acute myelomonocytic leukemia
- M5: Acute monocytic leukemia
- M6: Acute erythrocytic leukemia
- M7: Acute megakaryocytic leukemia

WHO-Classification

1) AML-recurrent cytogenetic abnormality: t(8:21), t(15:17), inversion11
2) AML-Myelodysplasia related changes (complicates MDS)
3) Therapy-related myeloid neoplasm
4) AML- not otherwise specified

Morphology

- **Myeloblasts** have delicate nuclear chromatin, two to four nucleoli, and abundant cytoplasm
- Auer rods: distinctive needle-like azurophilic granules (peroxidase), sometimes seen
- Blasts commonly appear in peripheral blood
- Myeloblasts express CD34 and myeloperoxidase

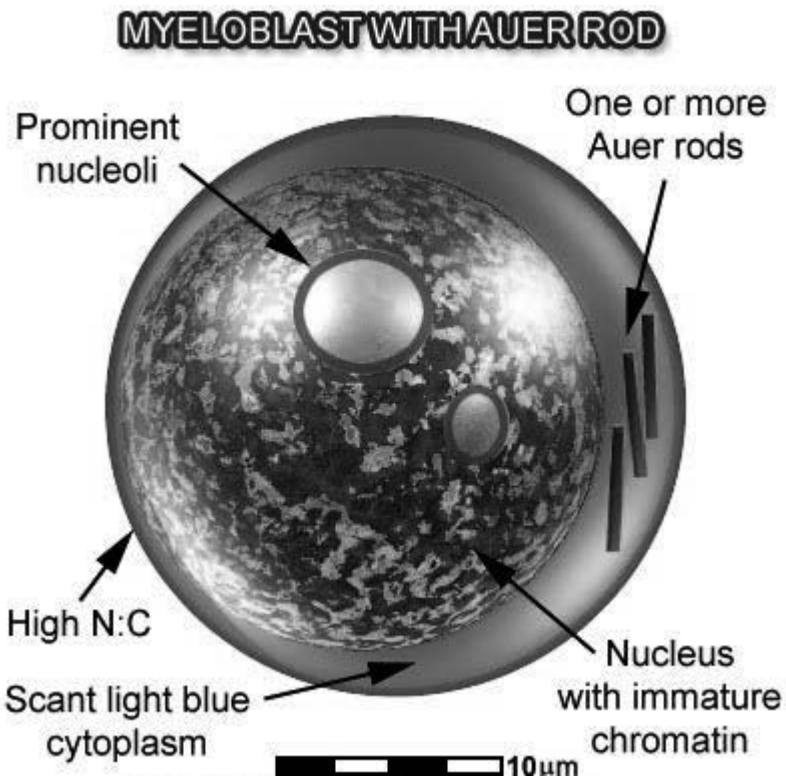

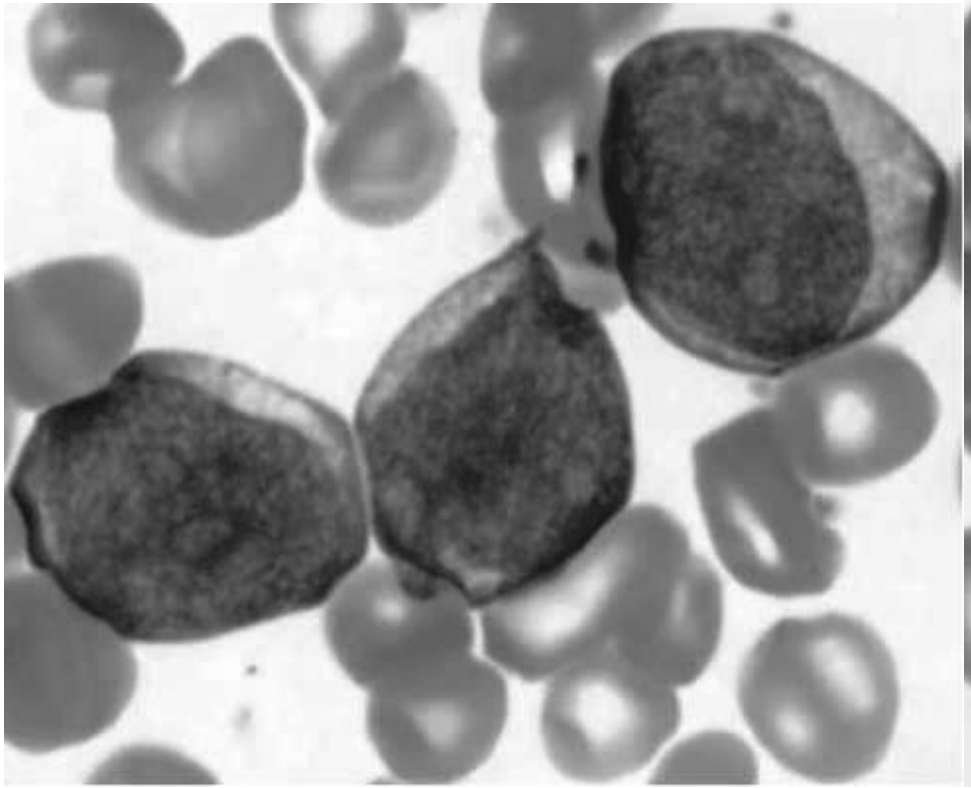

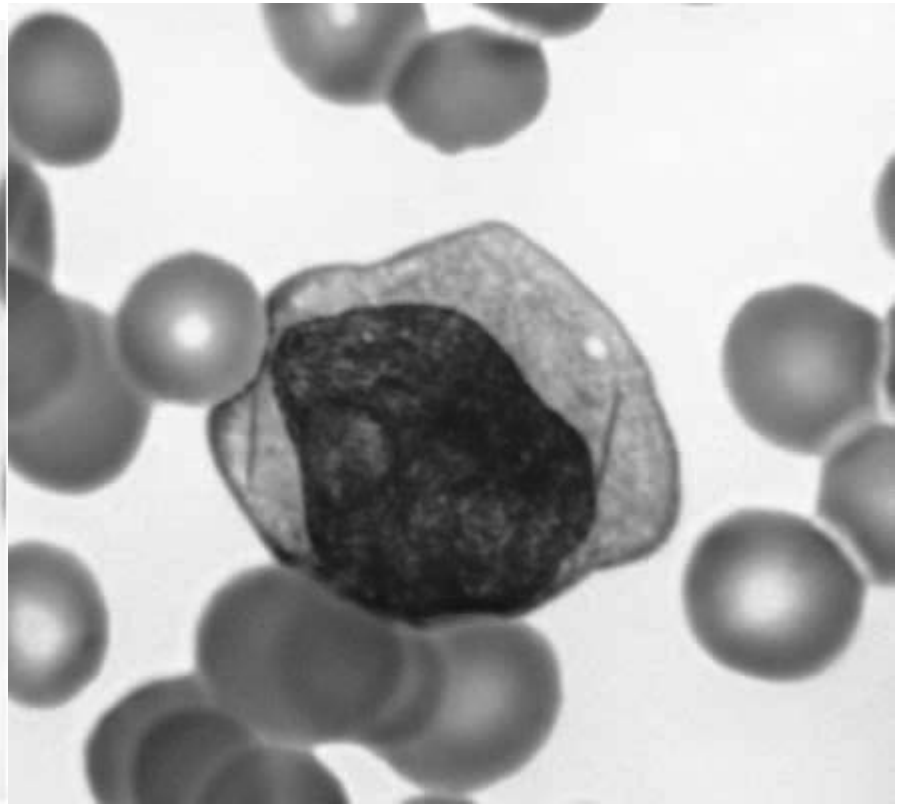

- AML: myeloblasts are large, high N/C ratio, prominent nucleoli

Acute promyelocytic leukemia

- FAB-M3
- WHO: AML-t(15:17), PML-RARA gene fusion
- Promyelocytic leukemia gene – retinoic acid receptor alpha
- New protein binds cell DNA, blocking maturation (reversed by vitamin A and arsenic)
- Cells are arrested at promyelocytic stage, showing prominent cytoplasmic granules and Auer rods
- Malignant promyelocytes secrete tissue factor, activating thrombin, initiating coagulation cascade (disseminated intravascular coagulation-DIC)

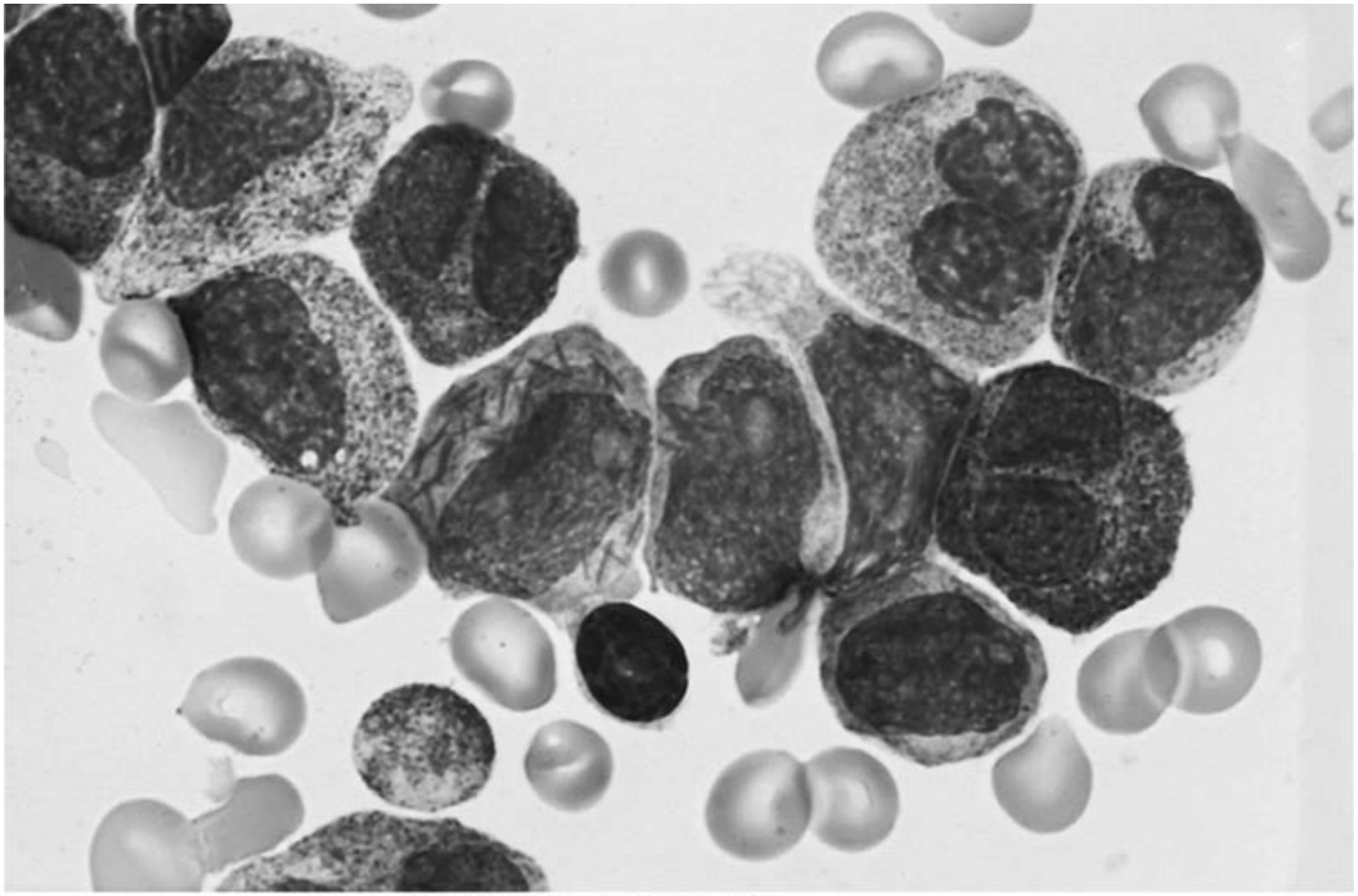

- Acute promyelocytic leukemia-bone marrow aspirate. The neoplastic promyelocytes have abnormally coarse and numerous azurophilic granules. Other characteristic findings include the presence of several cells with bilobed nuclei and a cell in the center of the field that contains multiple needle-like Auer rods

Acute monocytic leukemia

- FAB-M5
- Monocytes + promonocytes + monoblasts ≥80% of BM cells
- Extramedullary masses of leukemia are common (skin, gum, CNS)
- Monoblasts are large, with abundant and slightly basophilic cytoplasm, round central nuclei, prominent nucleoli, no granules of Auer rods

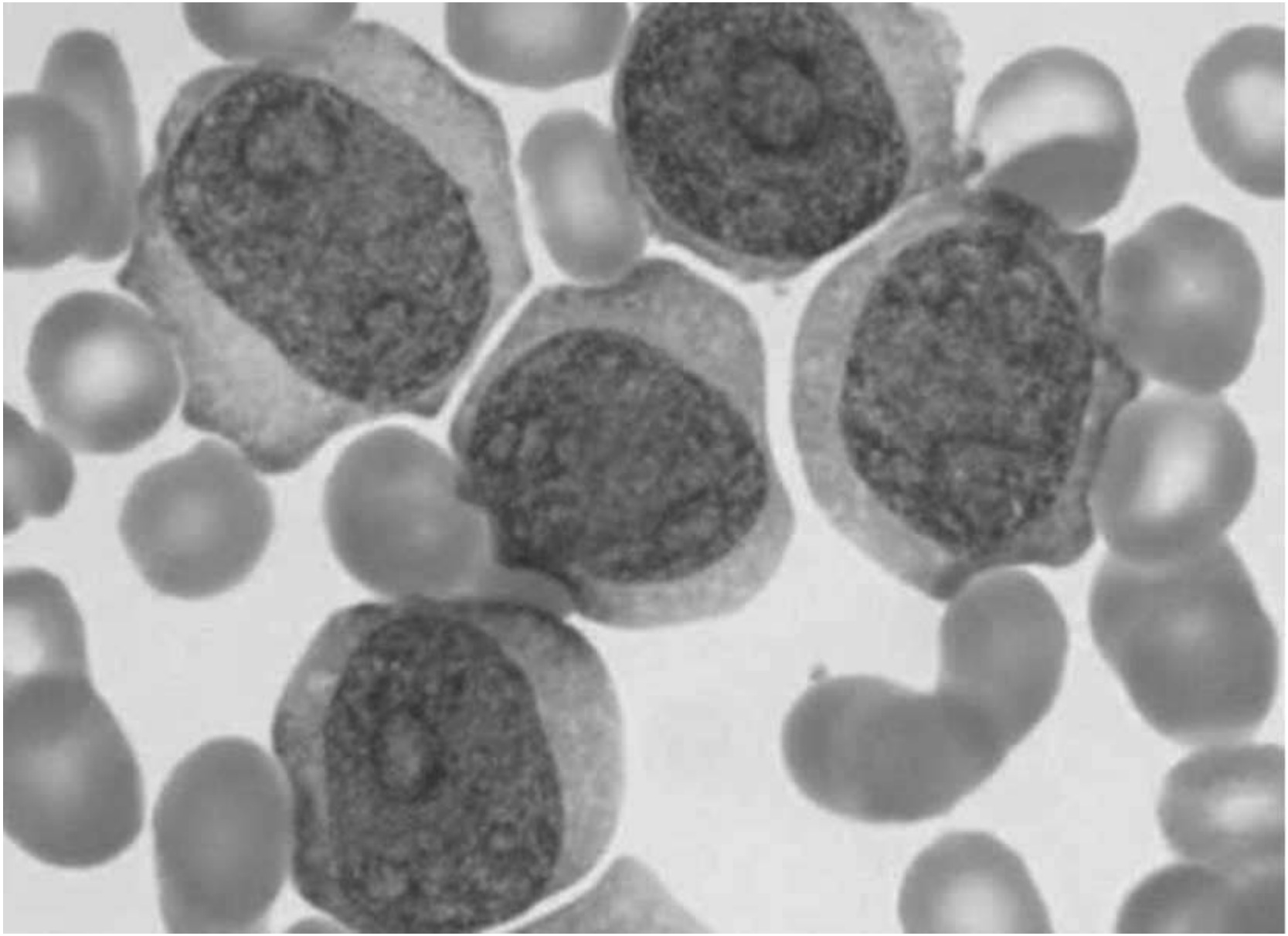

Clinical manifestations

- Bone pain
- Bleeding
- Anemia
- Infections
- Solid organ damage

Lymphoid neoplasms

Lymphoma

- Neoplastic disorders originate from B or T lymphocytes
- Most commonly arise in lymph nodes
- If circulates peripheral blood or bone marrow, it is called lymphoid leukemia
- They vary widely in their clinical presentation and behavior, low or high-grade lymphomas
- Generally classified as Hodgkin and non-Hodgkin lymphomas
- Risk factors: immune suppression, chronic inflammation, EBV, HHV8, HTLV1

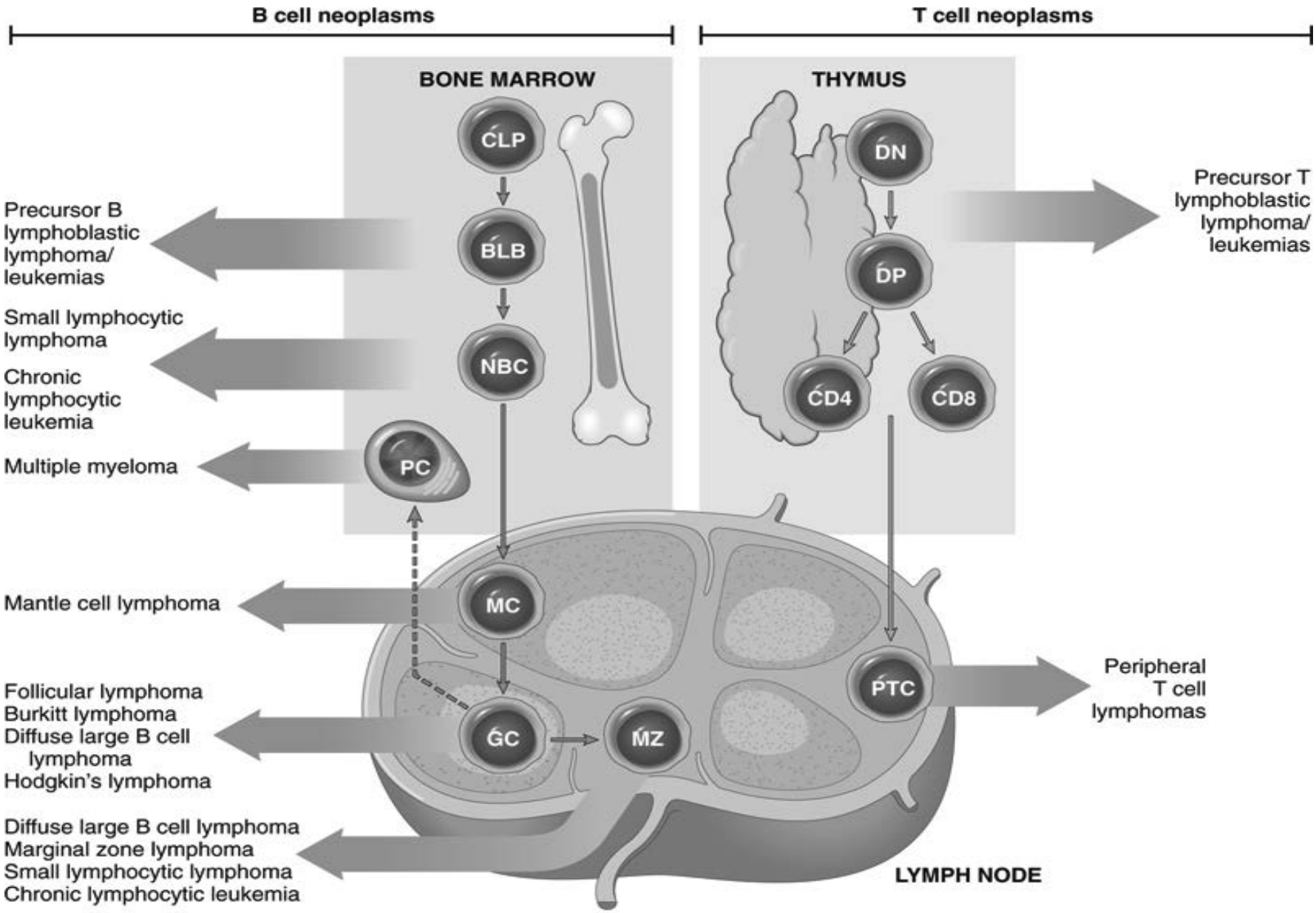

Kumar et al: Robbins Basic Pathology, 9e.

Diagnosis

- Large lymph nodes (>2 cm)
- Patients may have B-symptoms: fever, night sweating, weight loss, anorexia
- Immune suppression
- High LDH level
- Microscopic: Abnormal architecture
- Overgrowth of B or T-cells
- B-cells express CD19, CD20
- T-cells express CD2, CD3, CD5
- Lymphoblasts express Terminal deoxynucleotidyl transferase (TdT) enzyme

Acute Lymphoblastic Leukemia/ Lymphoma

- An aggressive, high-grade type of leukemia/lymphoma
- Arises from precursor lymphoid cells (lymphoblasts), B or T
- B-ALL is the most common cancer is children, arises from BM, affecting blood, and sometimes LNs
- T-ALL occurs mainly in male adolescents, arises from thymus, then affecting blood, BM and other tissues
- Lymphoblasts develop mutations in transcription genes which regulate both lymphocyte differentiation and proliferation
- Blasts express Terminal deoxynucleotidyl transferase (TdT)
- Lymphoblasts ≥ 20% BM cells, causing myelophthisic anemia
- When disease manifests in lymph nodes, called lymphoblastic lymphoma

Clinical features

- Abrupt, stormy onset of symptoms
- Patients have fever, anemia, bleeding, bone pain
- Lymphoblasts tend to disseminate into tissues: Generalized lymphadenopathy, splenomegaly, hepatomegaly, brain, testis (in contrast to AML)

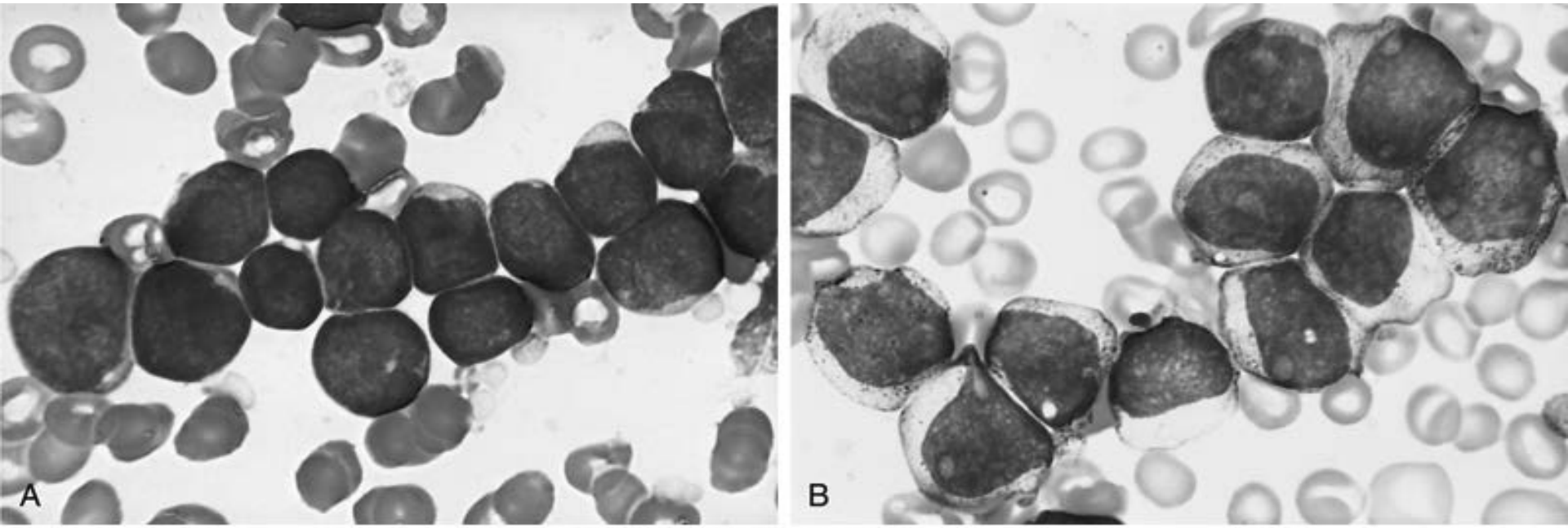

- Morphology: lymphoblasts have fine chromatin, minimal agranular cytoplasm

Chronic Lymphocytic Leukemia/Small Lymphocytic Lymphoma

- Low grade B-cell lymphoma
- Cells are small, round, mature looking similar to normal lymphocytes
- Affects BM and blood (CLL), or LN (SLL)
- Bcl2 (anti-apoptotic protein) is up-regulated
- Express CD5
- The most common leukemia in elderly
- Causes derangement in immune system (hypogammaglobulinemia), or auto AB-hemolytic anemia
- Indolent course, stays stable for years
- 10% transforms to high-grade lymphoma

- A: Low-power view shows diffuse effacement of nodal architecture.
- **B,** At high power, a majority of the tumor cells have the appearance of small, round lymphocytes, with scattered larger cells: "prolymphocyte," that have a central nucleolus

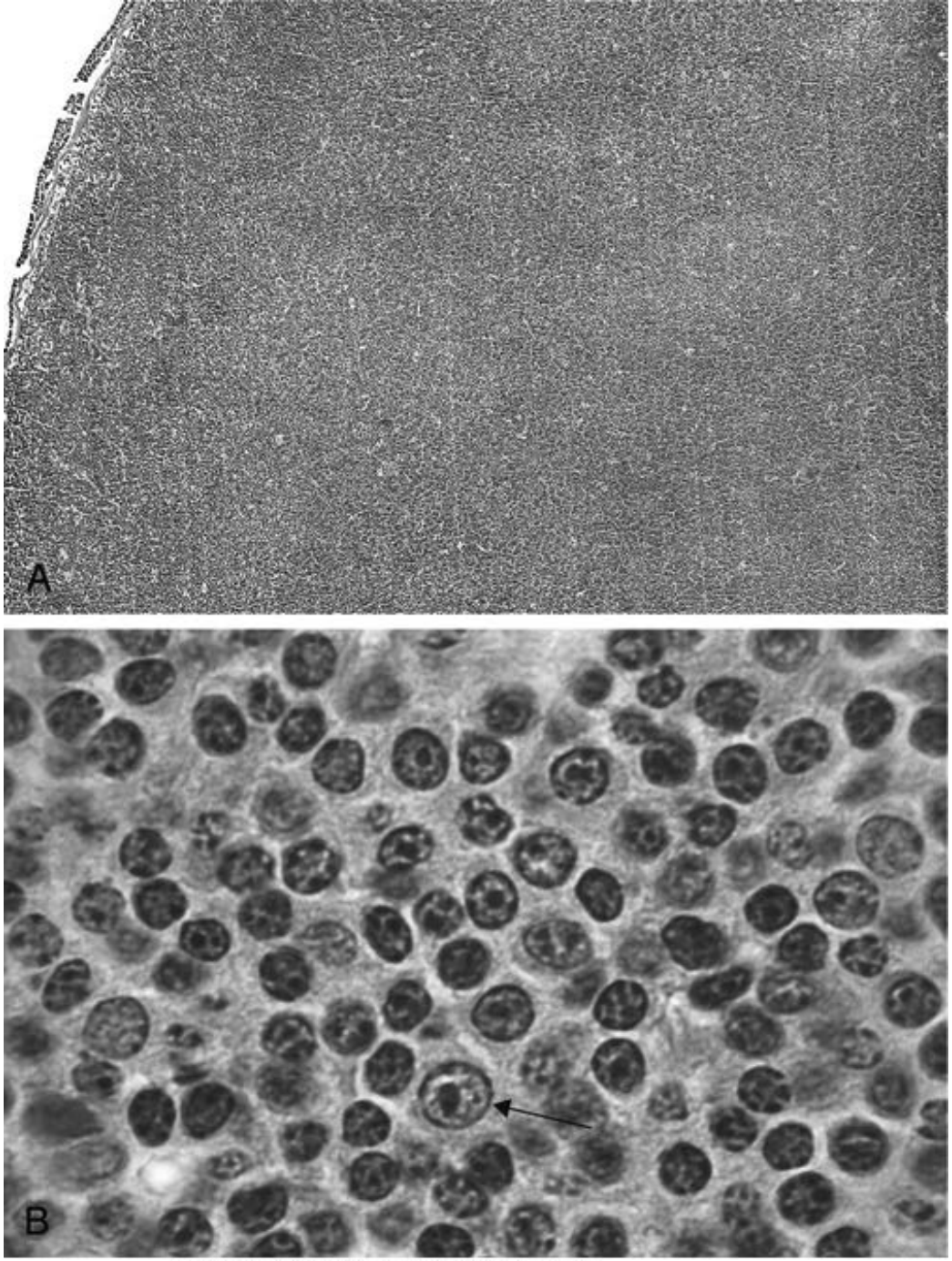

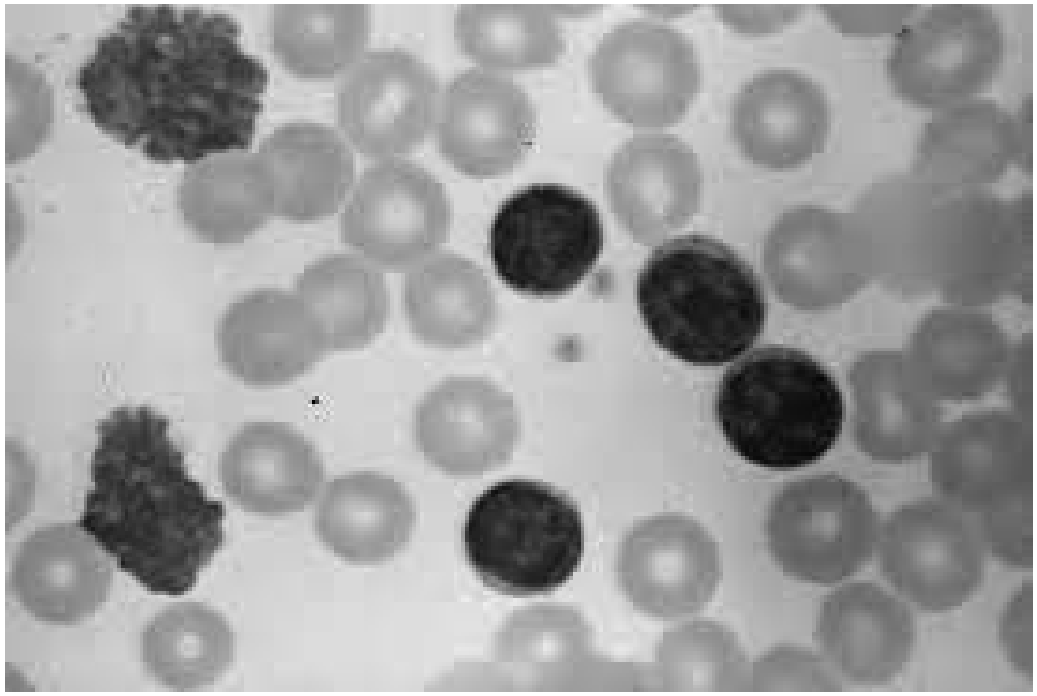

- CLL: leukemia cells are small in size, resemble normal lymphocytes. Burst “smudge” cells are commonly seen

Follicular Lymphoma

- Common (West), low-grade B-cell lymphoma
- Affects elderly
- Arises from germinal center B-cell
- Lymphoma cells have specific translocation t(14:18), in which Bcl2 gene on chr18 fuses with IgH gene on chr14, causing overexpression of Bcl2
- Patients has generalized lymphadenopathy
- Lymphoma cells proliferate to form abnormal, large, crowded follicles
- Patients have indolent course, transforms into high grade lymphoma in 40% of cases

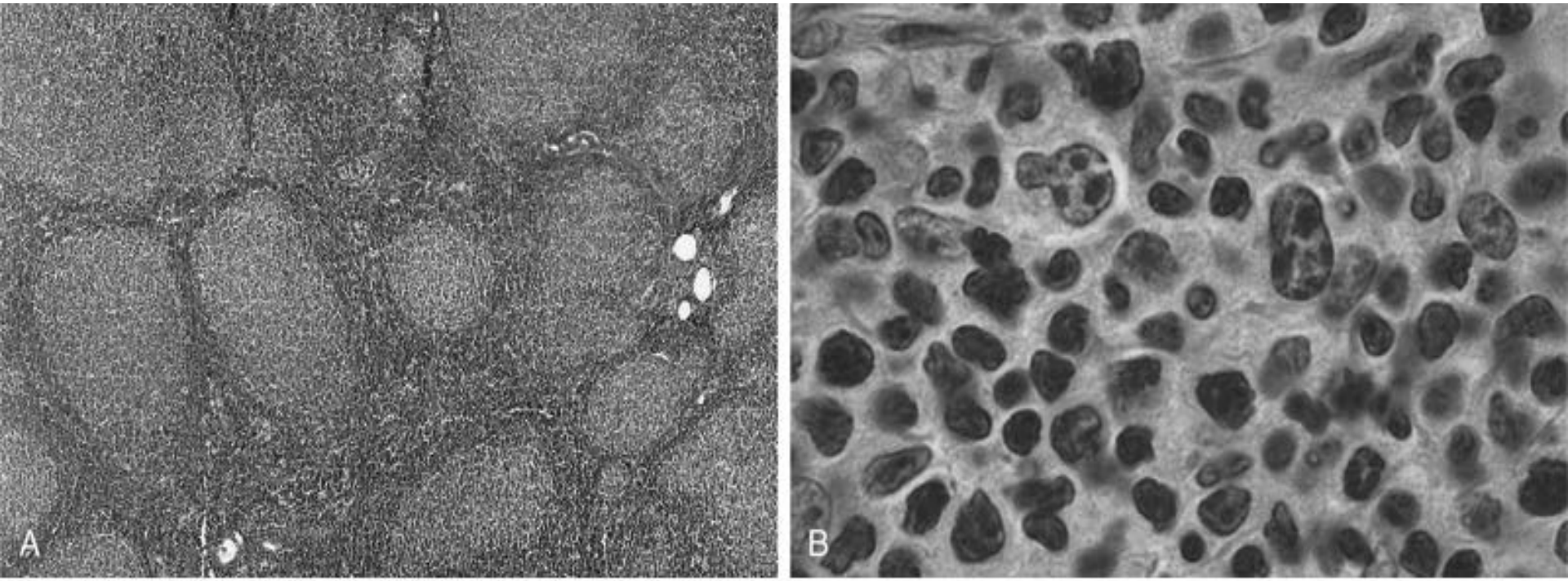

- **A,** Nodular aggregates of lymphoma cells are present throughout the lymph node. They are positive for Bcl2 staining.
- **B,** At high magnification, small lymphoid cells with condensed chromatin and irregular or cleaved nuclear outlines (centrocytes) are mixed with a population of larger cells with nucleoli (centroblasts).

Mantle cell lymphoma

- Rare
- Old age
- Disseminated, nodal and extranodal
- Morphology: diffuse pattern, small cleaved centrocytes
- Express CD5, cyclin D1

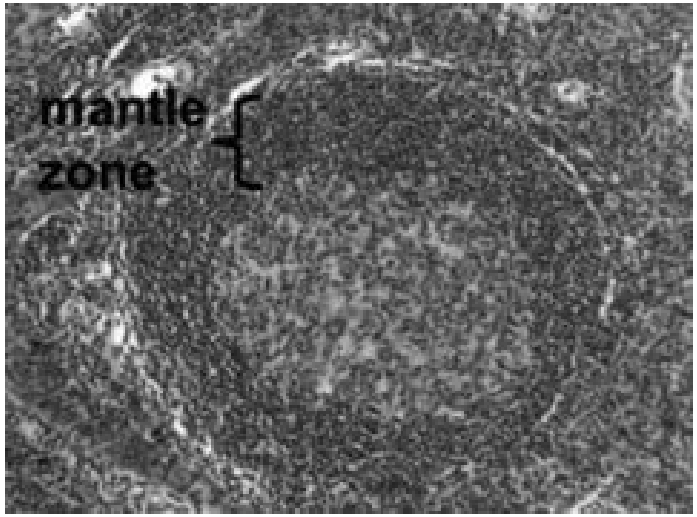

Diffuse Large B Cell Lymphoma

- most common type of lymphoma in adults, accounting for approximately 50% of adult NHLs, also arises in children
- Arises de novo, as a transformation from low grade B-cell lymphoma, in the setting of chronic immune stimulation, immune suppression (AIDS) or post transplant
- A subtype is caused by HHV8, arises in body cavities (pleural and peritoneal fluid), called primary effusion lymphoma
- High-grade lymphoma, progressive and fatal if not treated



- Tumor cells have large nuclei with open chromatin and prominent nucleoli.

Burkitt lymphoma

- High-grade B-cell lymphoma
- Endemic in Africa (high association with EBV), sporadic worldwide
- t(8:14), myc gene fuses with IgH gene, causing overexpression of myc, which activates other transcription factors and causes continuous cell proliferation
- Lymphoma commonly arises in extranodal sites (jaw, ileum)
- Lymphoma is rapidly growing and fatal if not treated

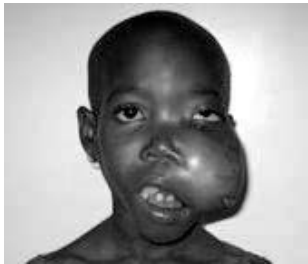

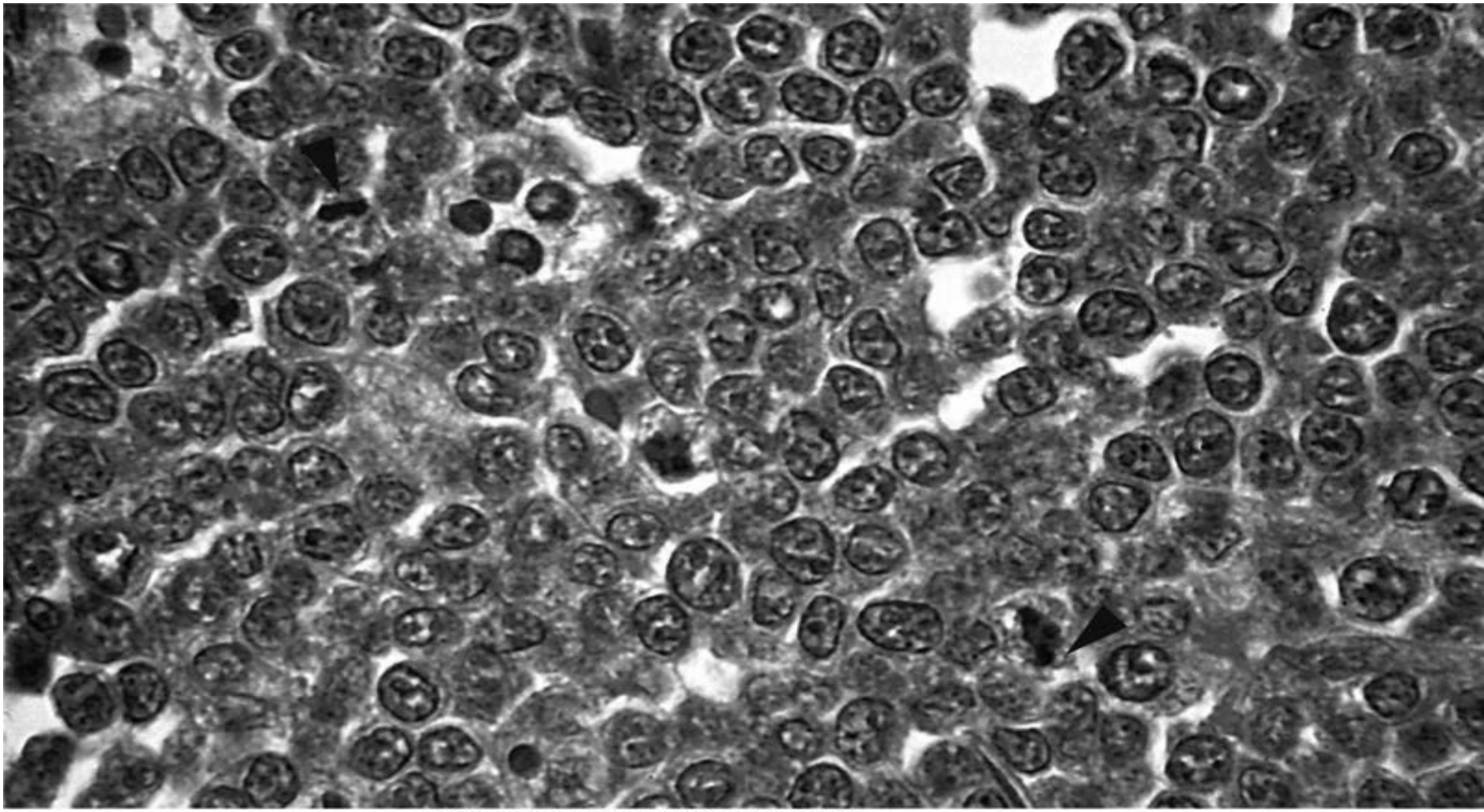

- The tumor cells and their nuclei are fairly uniform, giving a monotonous appearance
- high level of mitotic activity (*arrowheads*) and prominent nucleoli.



- The "starry sky" pattern produced by interspersed, lightly staining, normal macrophages

Mycosis Fungoides

- T-cell lymphoma
- Arises from CD4+ lymphocytes in skin
- Patients present with red patches
- With time evolves into tumorous masses
- A clinical variant (Sezary syndrome), patients have diffuse erythema in the body, and neoplastic lymphocytes circulate the blood
- Malignant lymphocytes show marked irregular nuclei (cerebriform)

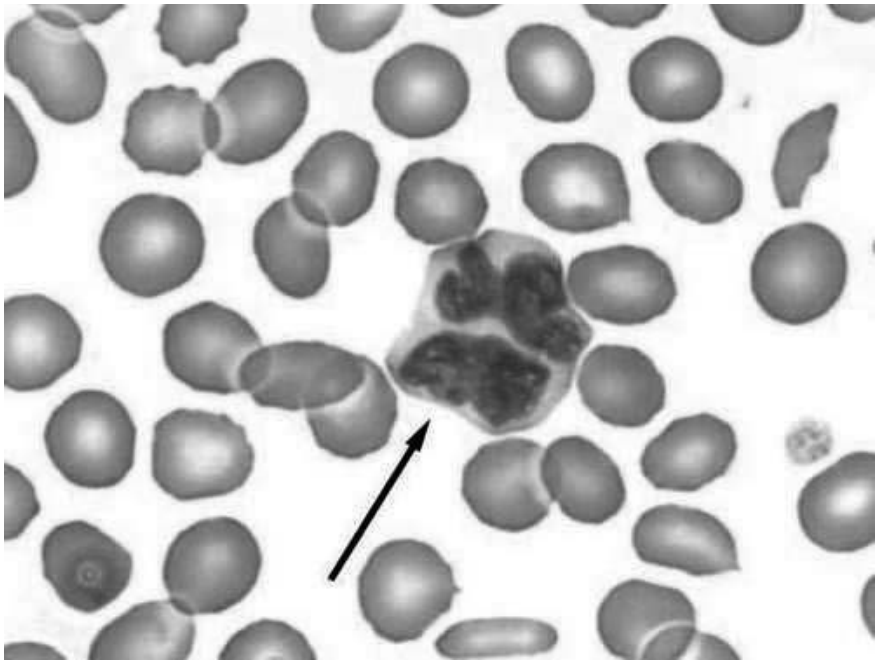

Adult T Cell Leukemia/Lymphoma

- CD4+ T cells that is caused by a retrovirus, human T cell leukemia virus type 1 (HTLV-1)
- Endemic in southern Japan, the Caribbean basin, and West Africa, and occurs sporadically elsewhere
- Lymphoma develops in 3-5% of infected persons, latent period 20-50 years
- Patients develop skin erythema, enlargement of liver and spleen
- Neoplastic cells express CD4, CD25
- Aggressive

Hodgkin Lymphoma

- a group of lymphoid neoplasms that differ from NHL in several respects
- Localized to a single axial group of nodes, most commonly in cervical, axillary and mediastinal LNs
- Orderly spread by contiguity
- Extra-nodal presentation rare

Hodgkin Lymphoma

- Presence of neoplastic giant cells called Reed-Sternberg cells
- RS cells constitute only a minority of tumor size, the rest is composed of reactive lymphocytes, histiocytes and granulocytes
- neoplastic RS cells are derived from crippled, germinal center, B cells
- Immunophenotype is very different from normal B-cells (negative for CD3, CD20, positive for CD30)
- EBV plays a role in the evolution of disease

Clinical features

- Bimodal age distribution: children + old age
- Presents as painless lymphadenopathy
- Constitutional symptoms (B-symptoms), such as fever, night sweats, and weight loss are common
- Spread: nodal disease first, then splenic disease, hepatic disease, and finally involvement of the marrow and other tissues

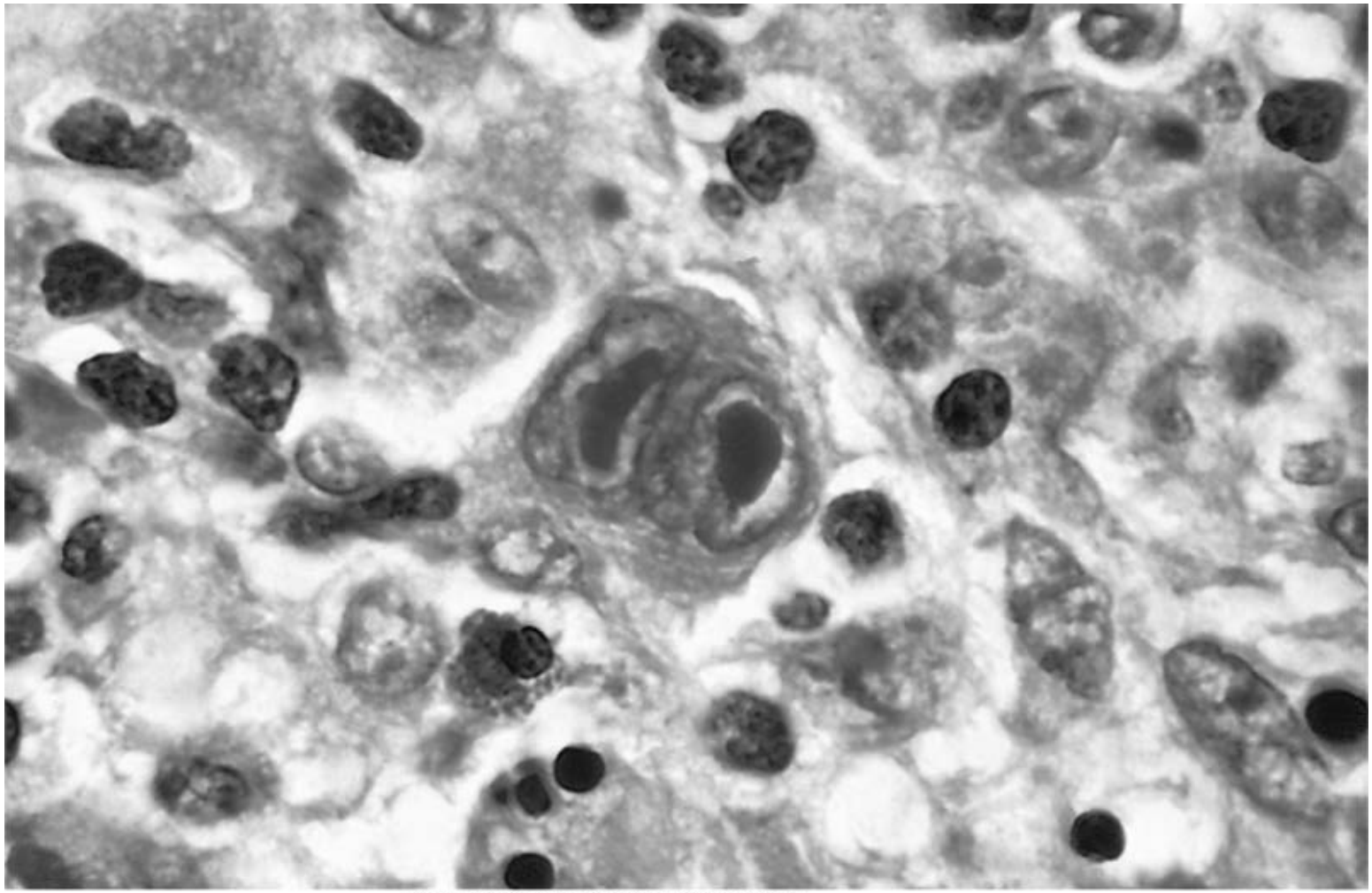

- Reed-Sternberg cell, with two nuclear lobes, large eosinophilic e nucleoli, and abundant cytoplasm, surrounded by lymphocytes, macrophages, and an eosinophil

Plasma cell myeloma

- Neoplasm of plasma cells that secrets monoclonal Immunoglobulin (M-protein)
- 10% of BM tumors
- Arises from long-lived plasma cells in the BM
- Aggressive tumor, difficult to control
- Affects elderly
- Clinically known as multiple myeloma

Pathogenesis

- Risk factors: older age, male, blacks, radiation, family history, obesity?
- Accumulation of genetic mutations and chromosomal aberrations
- Transformed plasma cells proliferate modestly, interact with stromal cells in BM (resistant to chemotherapy)
- Secrete IgG (>other Igs)
- Plasma cell count ≥ 10%

Clinical symptoms

- Hyper**C**alcemia
- **R**enal failure: protein cast (M-protein) blocks renal tubules
- **A**myloidosis
- **A**nemia: normochromic normocytic, decreased production (cytokines) + effacement
- **B**one pain/ fracture: activation of osteoclasts
- Recurrent infections: suppression of normal Ig
- Hyperviscosity: blurred vision, CNS symptoms,

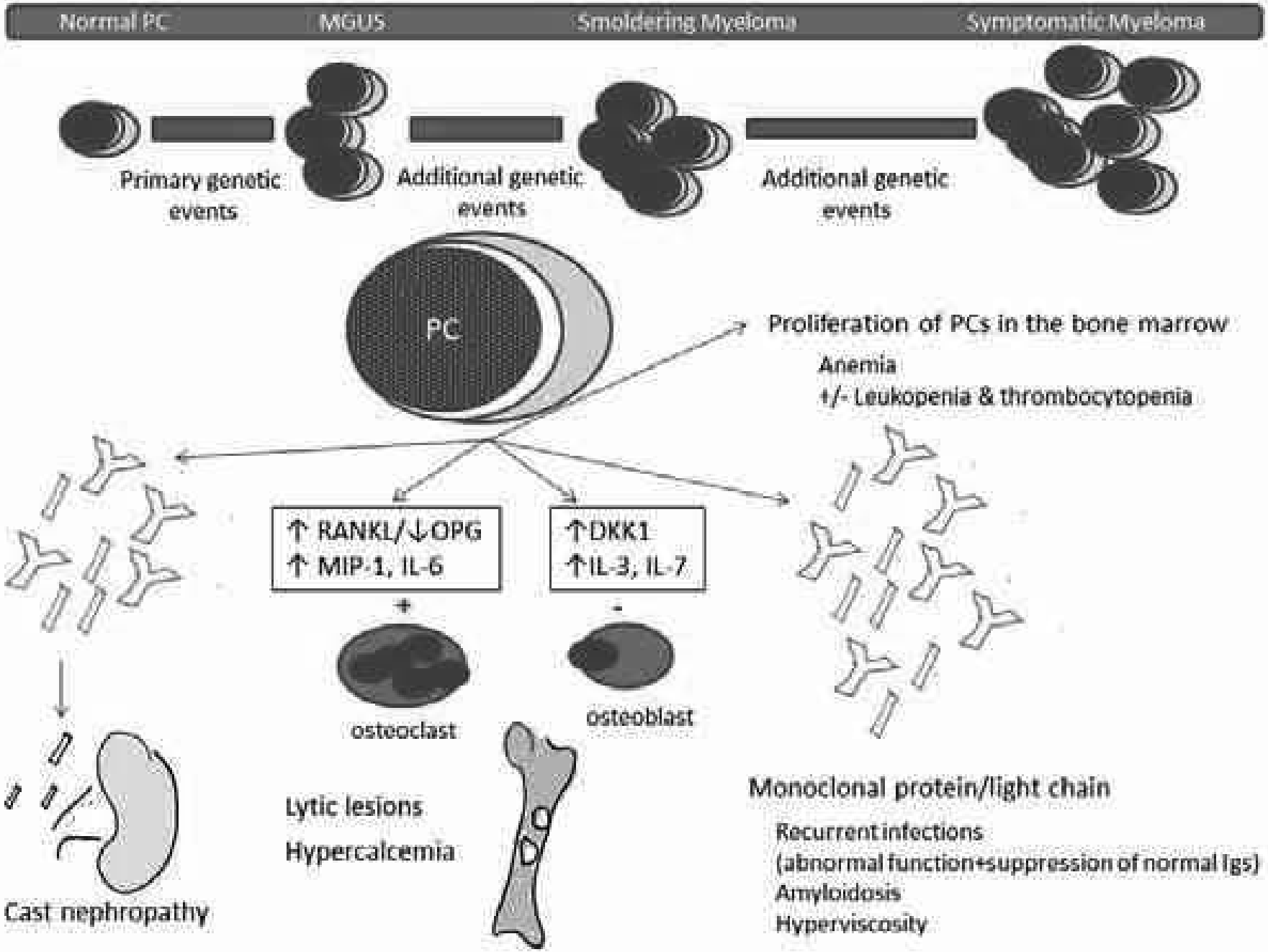
Normal PC
MGUS
Smoldering Myeloma
Symptomatic Myeloma
Primary genetic events
Additional genetic events
Additional genetic events
PC
Proliferation of PCs in the bone marrow
Anemia
+/- Leukopenia & thrombocytopenia
↑ RANKL/↓OPG
↑ MIP-1, IL-6
↑DKK1
↑IL-3, IL-7
+
-
osteoclast
osteoblast
Lytic lesions
Hypercalcemia
Cast nephropathy
Monoclonal protein/light chain
Recurrent infections
(abnormal function+suppression of normal Igs)
Amyloidosis
Hyperviscosity

Morphology

- Malignant plasma cells show large size, multinucleation, prominent nucleoli, ≥10%
- If 3-10%: called monoclonal gammopathy of undetermined significance (MGUS), usually asymptomatic, commonly progress to myeloma
- PB: RBS show rouleaux formation. Malignant plasma cells may circulate

- Normal marrow cells are largely replaced by plasma cells, including forms with multiple nuclei, prominent nucleoli, and cytoplasmic droplets containing Ig

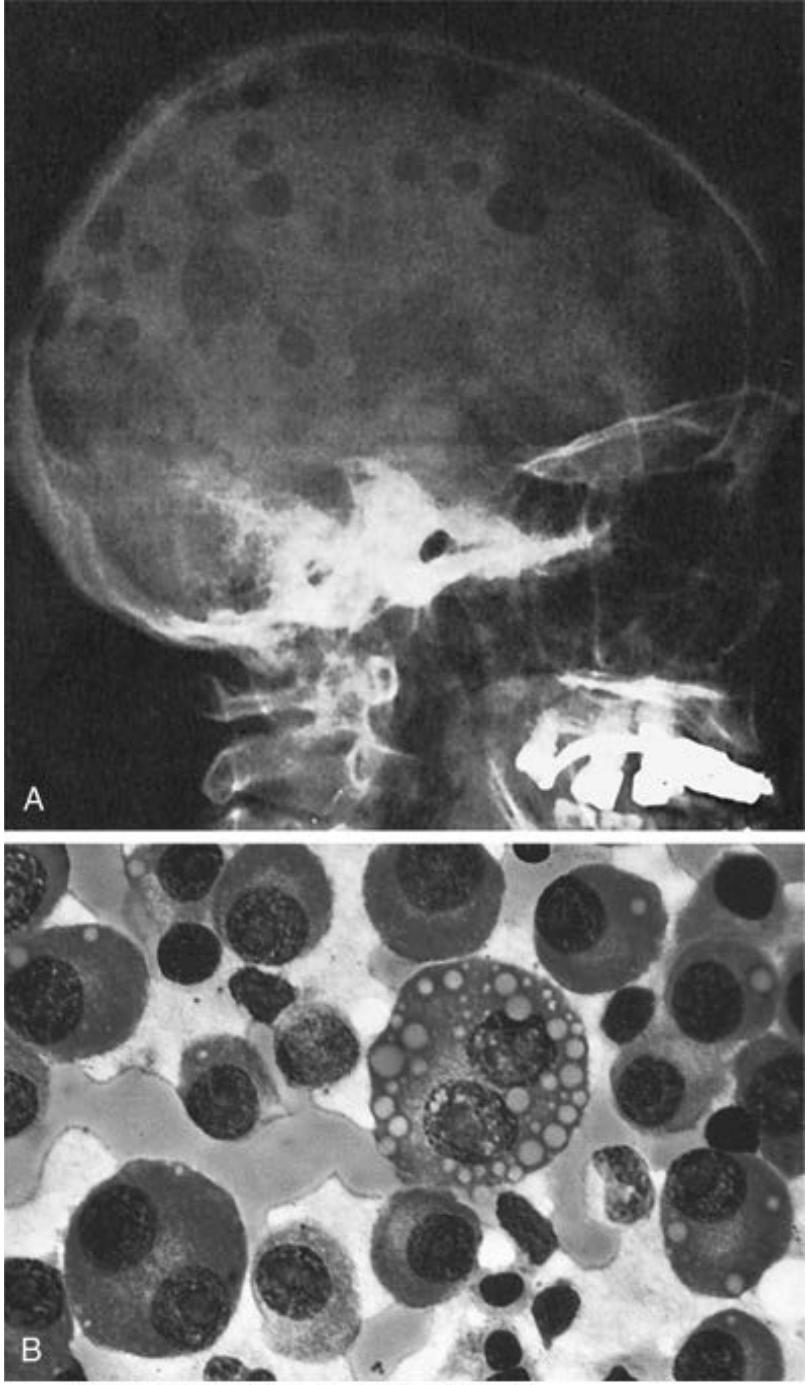

Kumar et al: Robbins Basic Pathology, 9e.

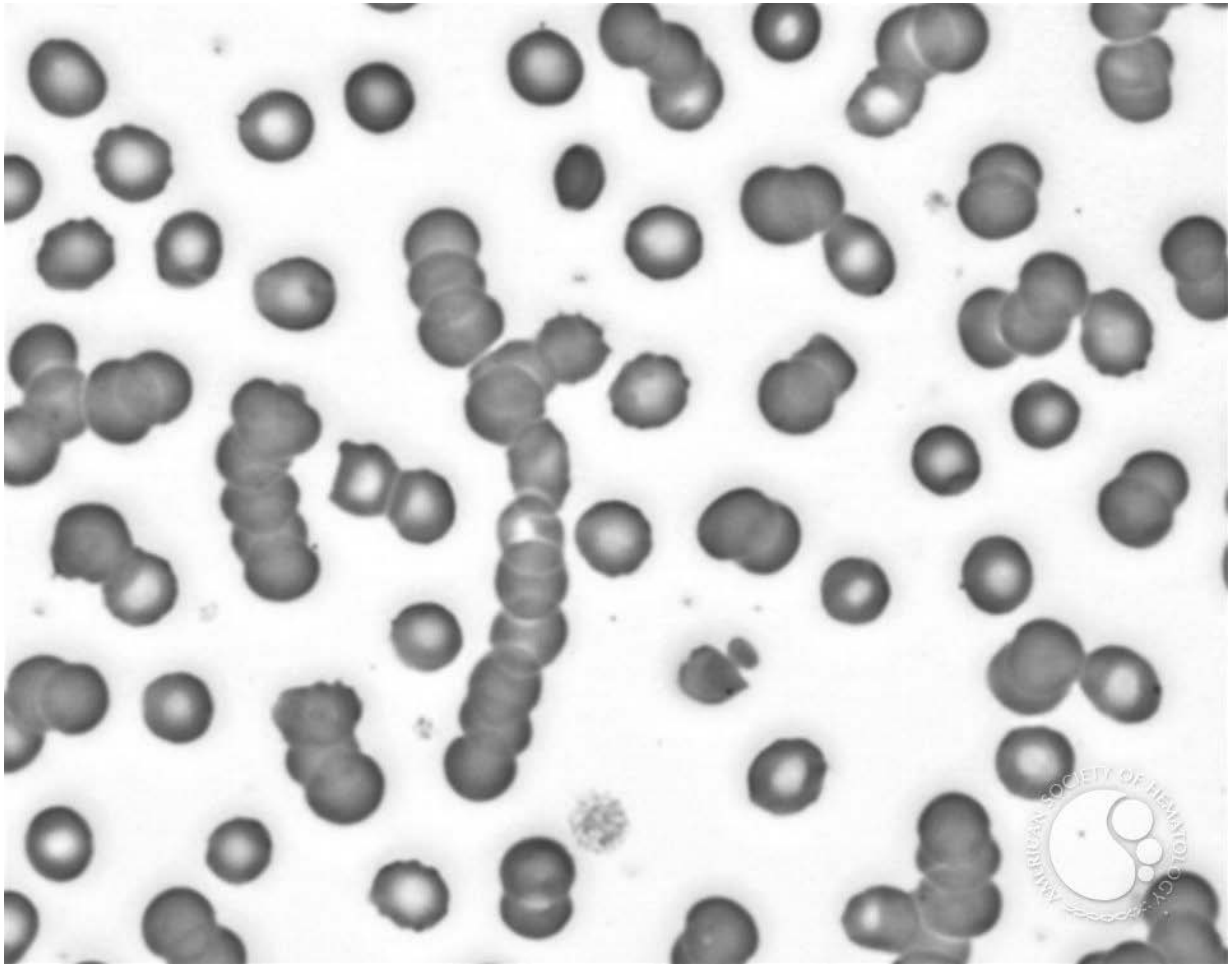

- Rouleax formation of RBCs secondary to M-protein in plasma cell myeloma

Disorders of the Spleen

Splenomegaly

Hypersplenism:

- Extravascular hemolytic anemia
- Chronic infection (TB, typhoid, IM)
- Autoimmune diseases

Infiltrative diseases:

- Benign: sarcoidosis, amyloidosis, storage diseases
- Malignant: lymphoma, metastasis, primary splenic tumor

Massive splenomegaly (>1 kg, >20 cm, crossing midline):

- Myelofibrosis, CML, CLL
- Leishmania, Malaria
- Gaucher disease
- Hairy cell leukemia

<u>Hypersplenism results in cytopenia, especially platelets</u>

Hairy cell leukemia

- Mature B-cell neoplasm (memory B-cells)
- Old age, M:F > 5
- Distinctive morphology: long cytoplasmic poles
- Very indolent disease
- Responds well to chemotherapy
- Patients always have splenomegaly, bone marrow infiltration, but very rarely lymph adenopathy
- Pancytopenia

B-RAF mutation

- Acquired mutation, present in all cases
- B-RAF is a member of MAP-kinase pathway growth signal transduction

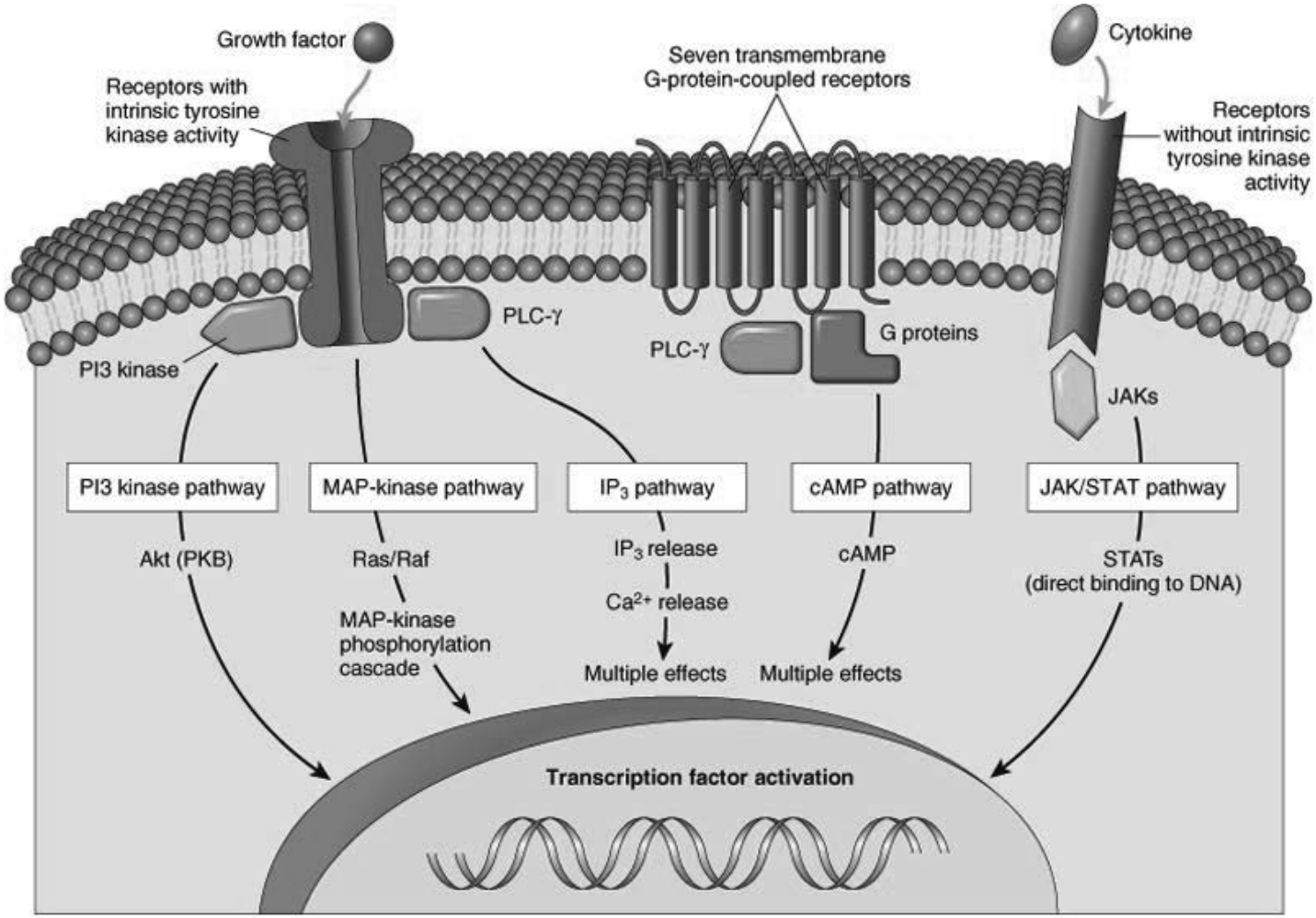

Morphology

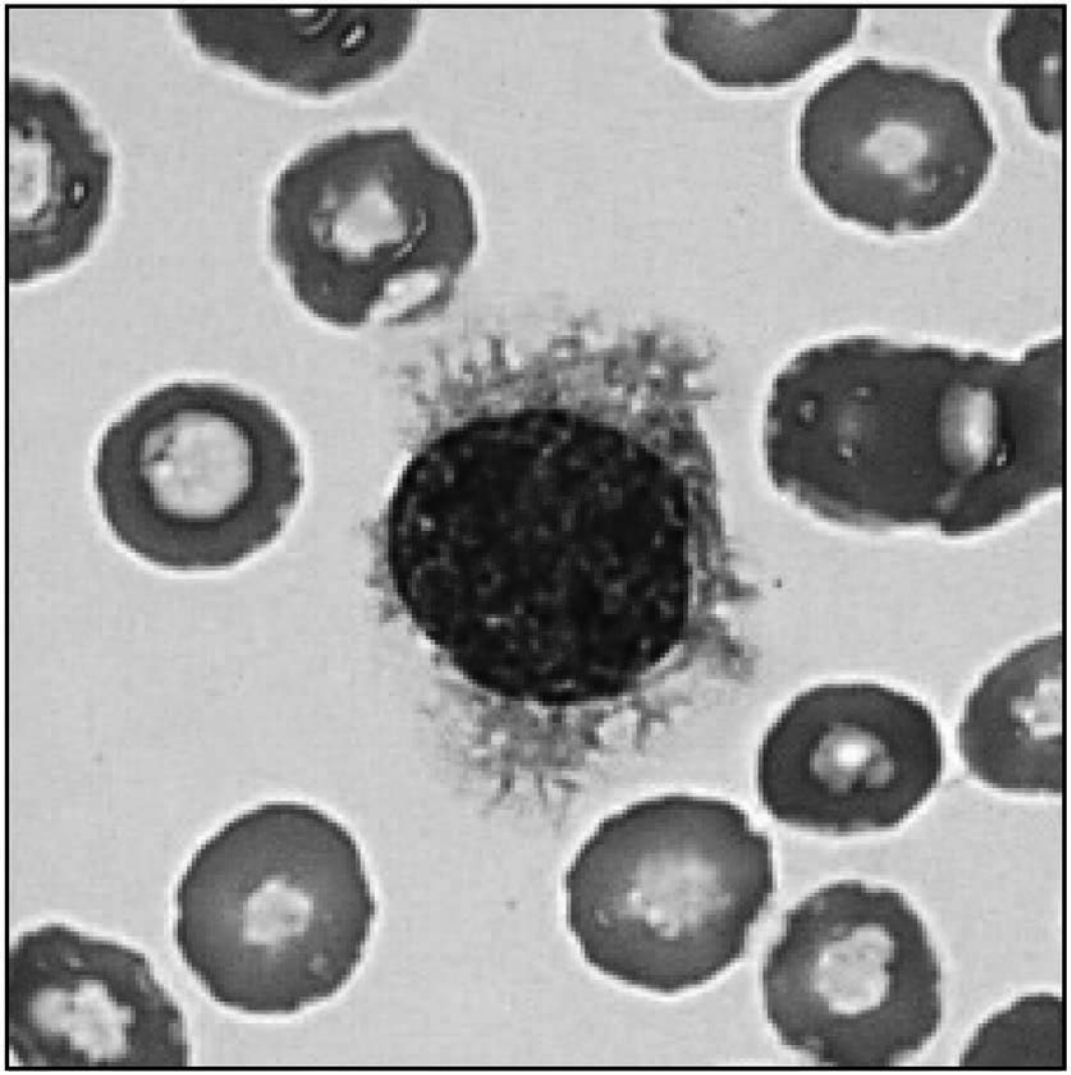

Circumferential cytoplasmic long projections

(abnormal cytoskeleton)

Other features

- Synthesis and binding to fibronectin by secreting fibroblast growth factor (stays in BM and spleen, few circulating cells)
- Secretes transforming growth β, causing BM fibrosis, decreased hematopoiesis (dry tap)
- Thus patients have pancytopenia, splenomegaly

Thymic disorders

- Thymic hyperplasia
- Thymoma

Thymic Hyperplasia

- Normally, few B-cells are present in the thymus
- In hyperplasia, or germinal centers appear within the medulla
- Occurs in Myasthenia Gravis, rheumatoid arthritis, systemic lupus erythematosus

Thymoma

- Can be benign or malignant
- Malignant is more common
- Mostly in middle aged people
- Presentation:
- 1/3 asymptomatic
- 1/3 anterosuperior mediastinal mass
- 1/3 myasthenia gravis
- Epithelial cell origin
- Morphology shows a mixture of epithelial calls and lymphocytes

Benign thymoma

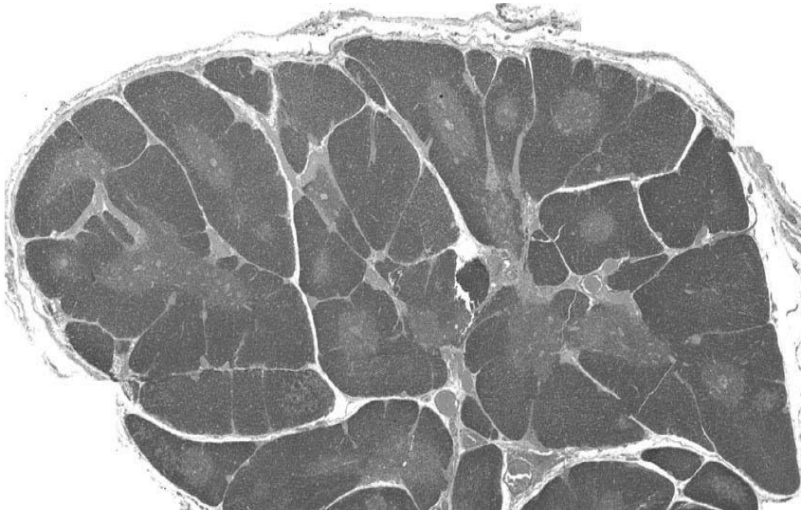

- Encapsulated
- Lobulated
- Epithelial cells are spindle

Resemble normal medullary

Epithelium (medullary thymoma)

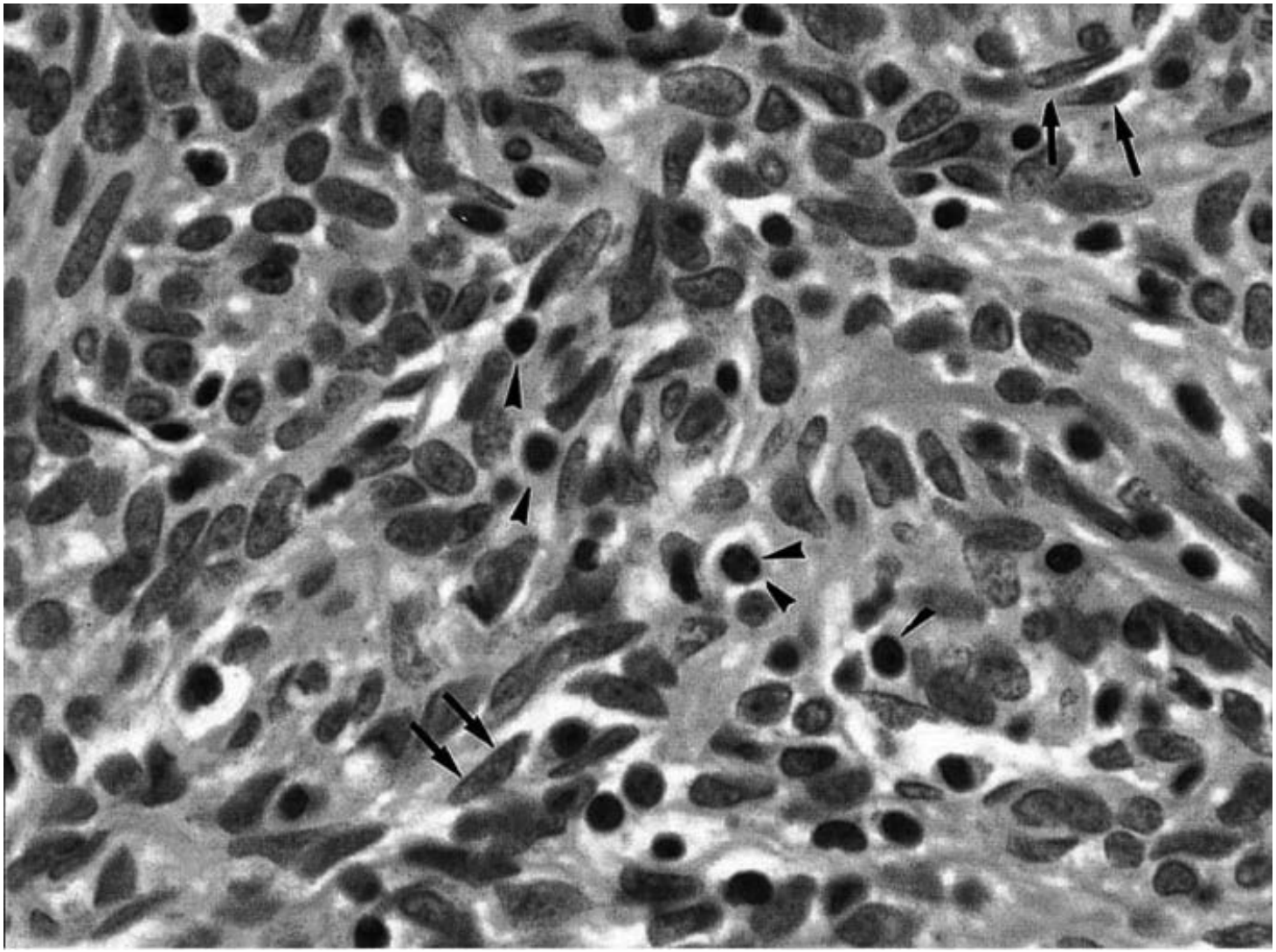

Malignant thymoma

- Type I: morphologically benign, but shows invasion and / or metastasis
- Type II: morphologically malignant (like squamous cell carcinoma)