The Eye

Nakhleh Abu-Yaghi, M.B.B.S
Ophthalmology Division


“The real voyage of discovery consists not in seeking new landscapes, but in having new eyes.”
– Marcel Proust

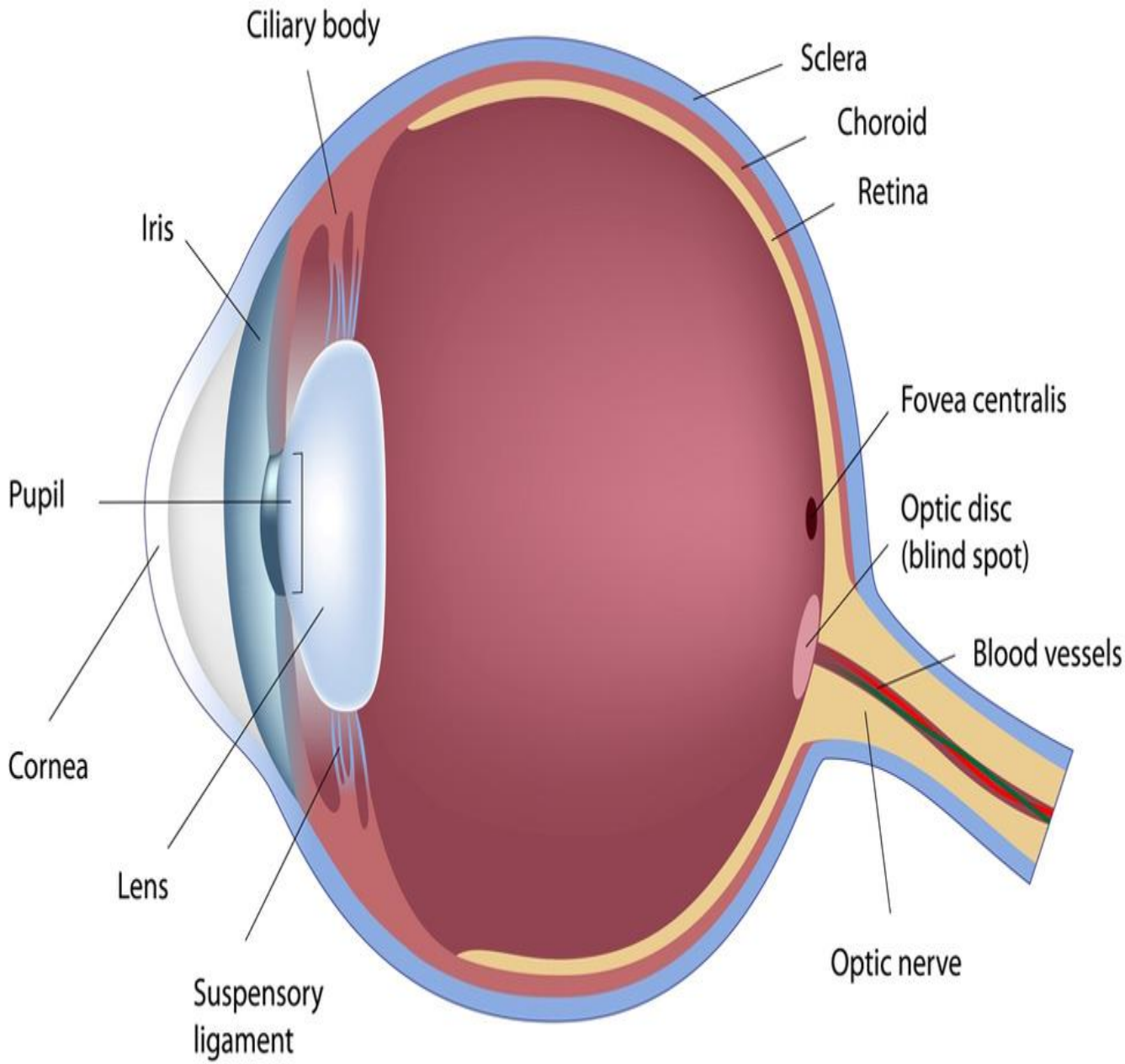
Ciliary body
Sclera
Choroid
Retina
Iris
Fovea centralis
Pupil
Optic disc
(blind spot)
Blood vessels
Cornea
Lens
Optic nerve
Suspensory
ligament

Coats of the Eyeball

1- OUTER FIBROUS COAT

is made up of :
Posterior opaque part

2-THE SCLERA

the dense white part

1- THE CORNEA

the anterior transparent part

The Sclera

- The sclera is composed of dense fibrous tissue and is white.
- Posteriorly, it is pierced by the optic nerve and is fused with the dural sheath of that nerve
- The sclera is also pierced by the ciliary arteries and nerves and their associated veins.

- The sclera is directly continuous in front with the cornea at the corneoscleral junction, or limbus

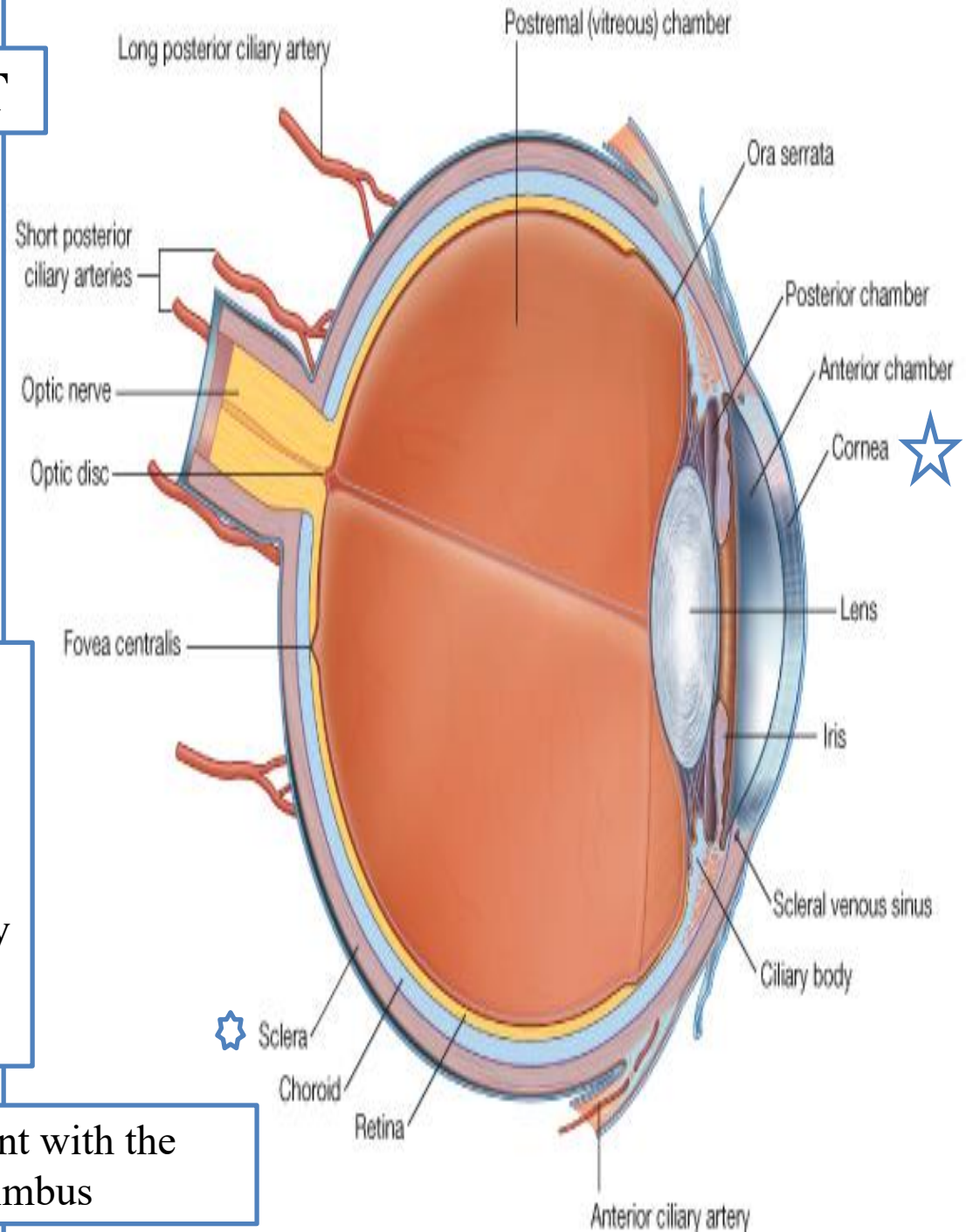

The Cornea

❖The transparent cornea is largely responsible for the refraction of the light entering the eye

❖It is in contact posteriorly with the aqueous humor.

Blood Supply

➢The cornea is avascular and devoid of lymphatic drainage

➢ It is nourished by diffusion from the aqueous humor and from the capillaries at its edge.

Nerve Supply

Long ciliary nerves from the ophthalmic division of the trigeminal nerve

Function of the Cornea

The cornea is the most important refractive medium of the eye.

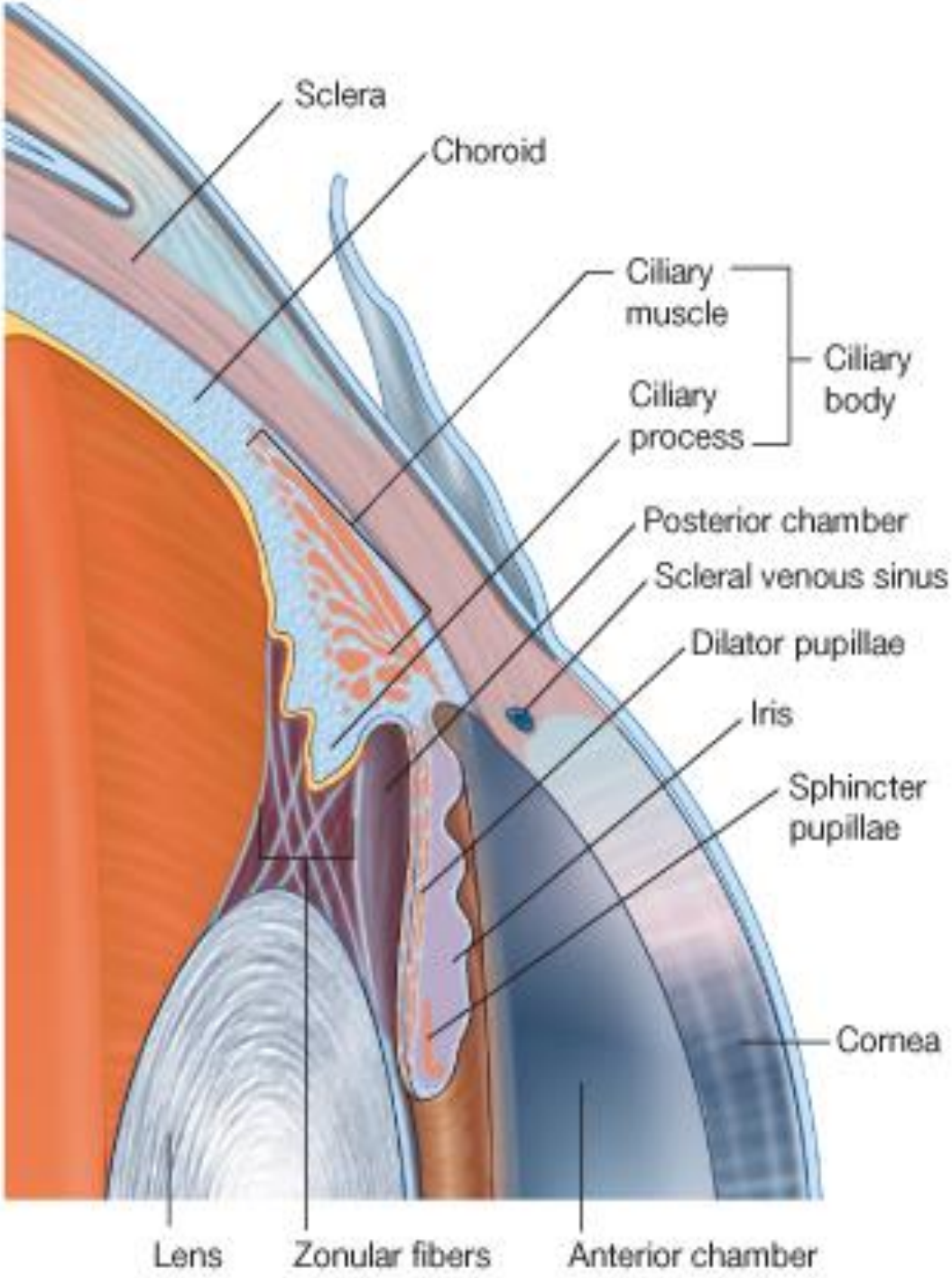

2-MIDDLE VASCULAR COAT

THE VASCULAR COAT CONSISTS OF:
FROM BEHIND FORWARD
1- THE CHOROID
2-THE CILIARY BODY
3-THE IRIS.

1-THE CHOROID

Choroid is a brown vascular membrane deep to the sclera

2-THE CILIARY BODY

The ciliary body is continuous posteriorly with the choroid, and anteriorly it lies behind the peripheral margin of the iris
Contains **the ciliary muscle (the main muscle of accomodation) which is** connected to the suspensory ligaments of the lens

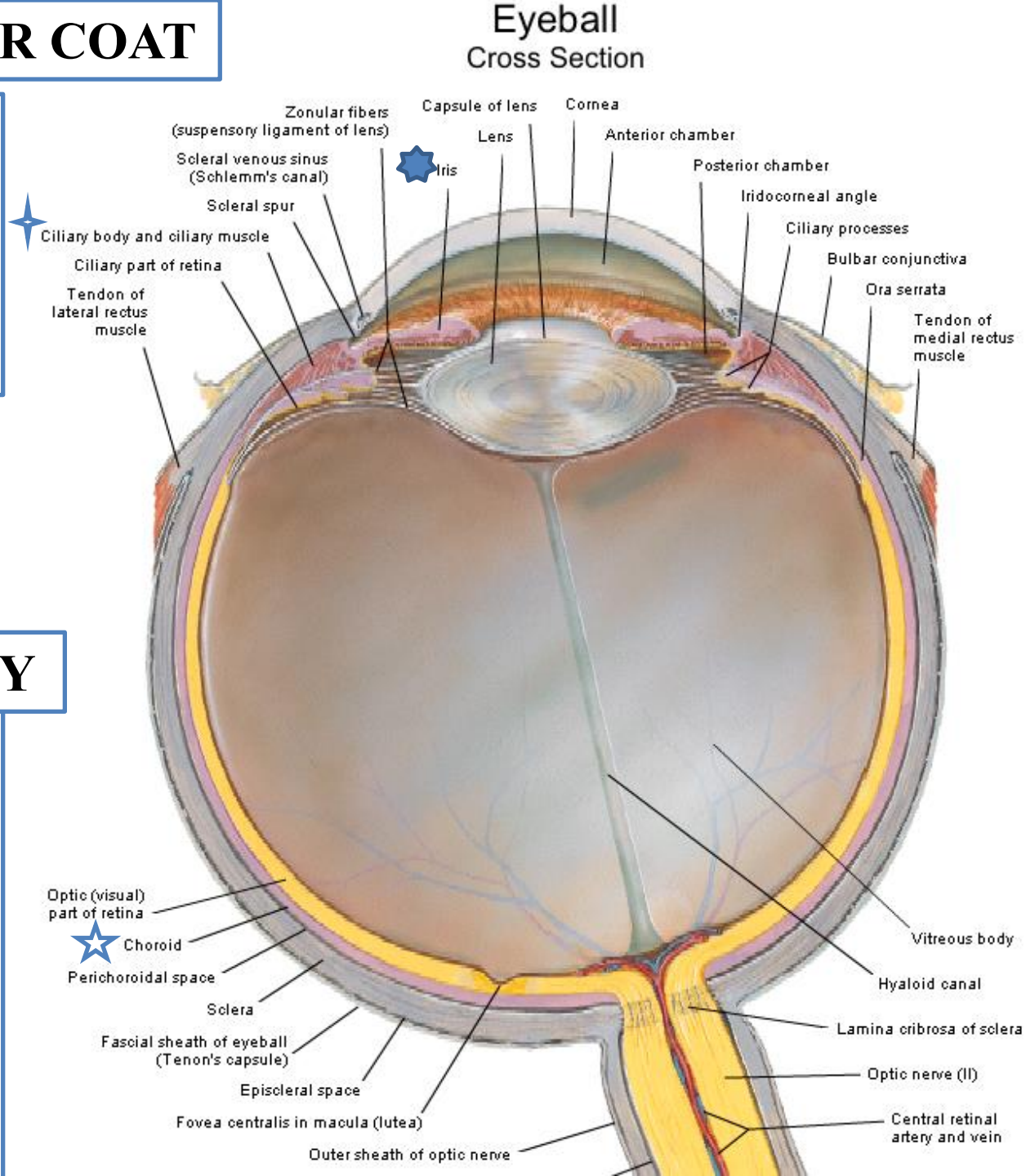

PRODUCTION OF AQUEOUS HUMOR AND INTRAOCULAR PRESSURE

1. Ciliary Process:
   Produces Aqueous Humor
2. Posterior Chamber:
   Aqueous Humor flows from
   this chamber through the
   pupil in Anterior Chamber
3. Canal of Schlemm
   Reabsorbs Aqueous Humor

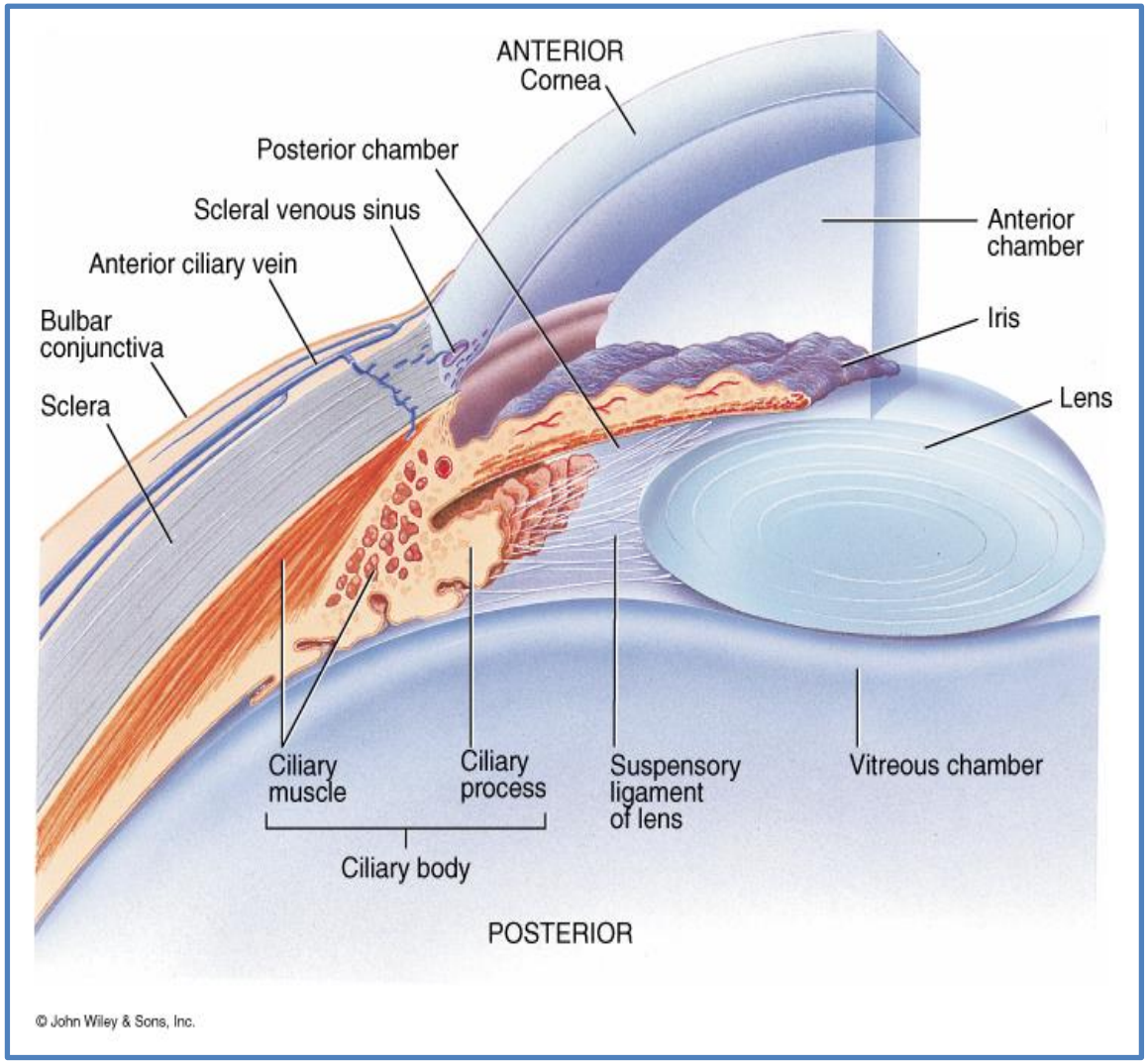

Glaucoma:

Optic neuropathy due to a relative increase in intraocular pressure in a susceptible eye

The ciliary muscle

Nerve supply:

The ciliary muscle is supplied by the parasympathetic fibers from the oculomotor nerve.
After synapsing in the ciliary ganglion, the postganglionic fibers pass forward to the eyeball in the short ciliary nerves.

Action: Contraction of the ciliary muscle, This relieves the tension in the suspensory ligament, and the elastic lens becomes more convex. This increases the refractive power of the lens.

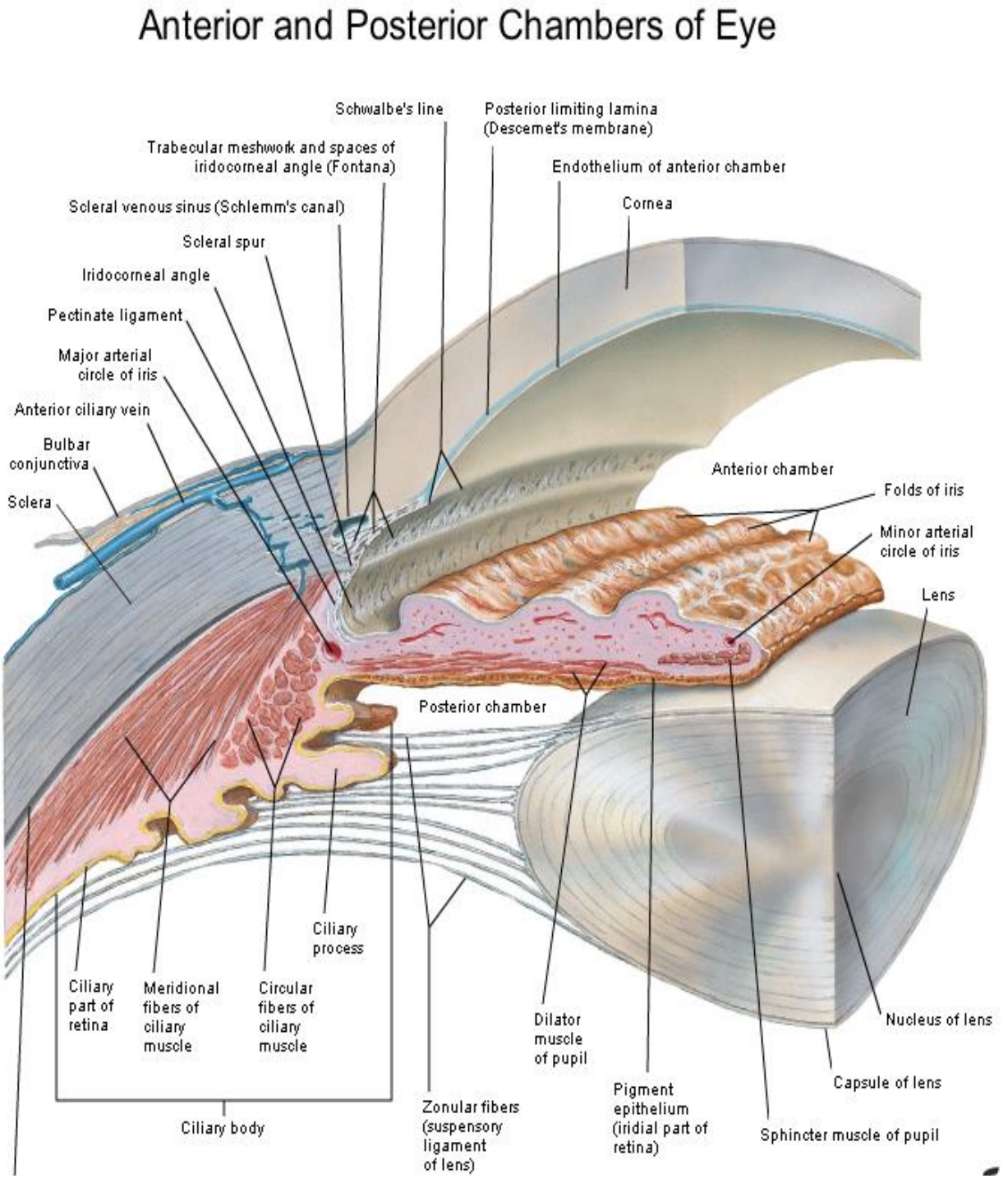

The Iris and Pupil

is a thin, contractile, pigmented diaphragm with a centre aperture **The pupil**

- It is suspended in the aqueous humor between the cornea and the lens.
- The periphery of the iris is attached to the anterior surface of the ciliary body.
- It divides the space between the lens and the cornea into an anterior and a posterior chamber.

- The muscle fibers of the iris are ***involuntary*** and consist of circular and radiating fibers.
- ***The circular fibers*** form **the sphincter pupillae**

Nerve supply: The sphincter pupillae is supplied by **parasympathetic** fibers from the oculomotor nerve. After synapsing in the ciliary ganglion, the postganglionic fibers pass forward to the eyeball in the short ciliary nerves.

- ***The radial fibers*** form **the dilator pupillae** is supplied by **sympathetic** fibers, which pass forward to the eyeball in the long ciliary nerves.

Action:
The sphincter pupillae constricts the pupil in the presence of bright light and during accommodation.

The dilator pupillae dilates the pupil in the presence of light of low intensity or in the presence of excessive sympathetic activity such as occurs in fright

Intrinsic Eye Muscles and their response to light

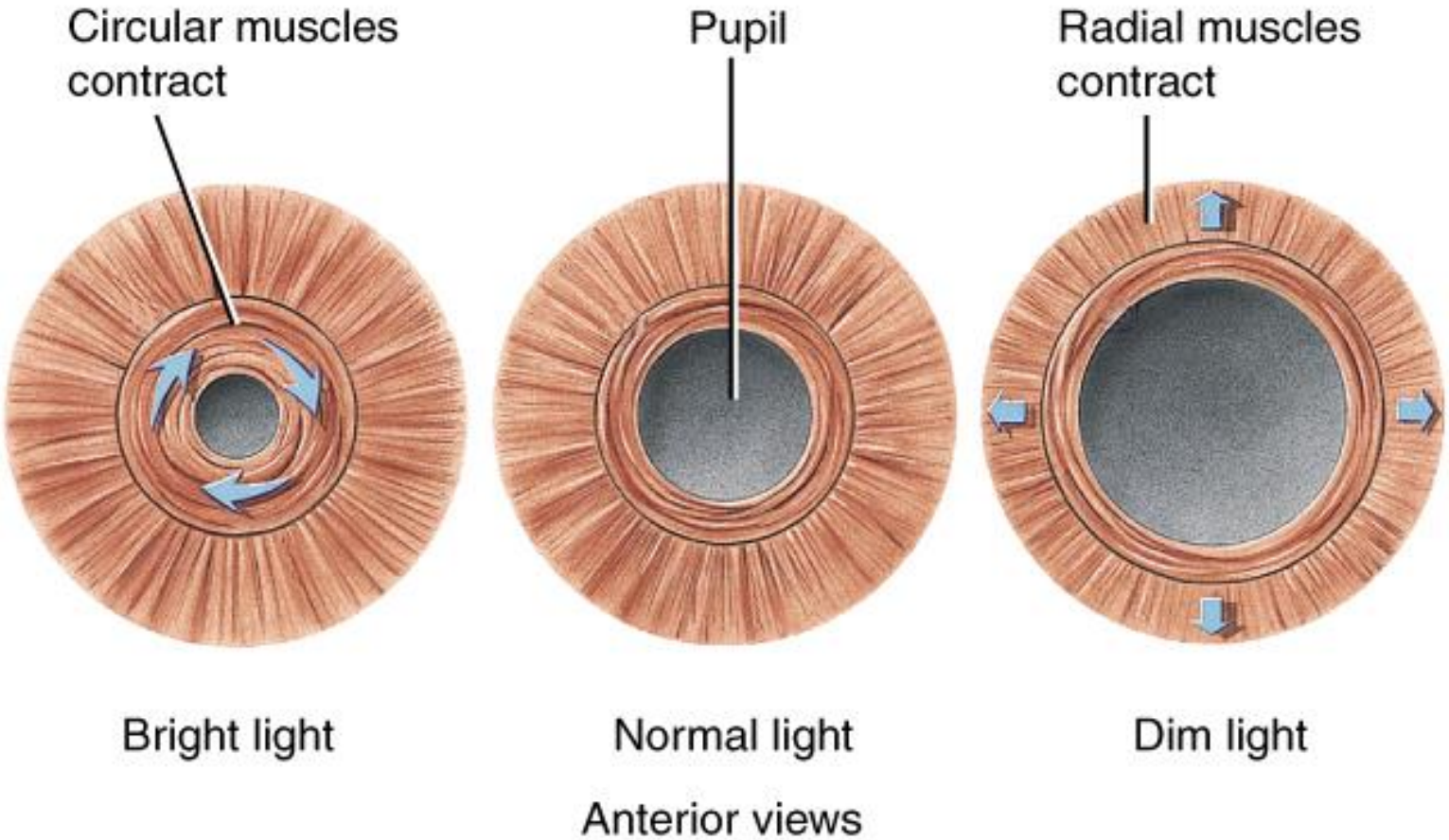

The Lens

The lens is a transparent, biconvex structure enclosed in a transparent capsule.
It is situated behind the iris and in front of the vitreous body and is encircled by the ciliary processes.

Accommodation of the Eye

To accommodate the eye for close objects, the ciliary muscle contracts and pulls the ciliary body forward and inward so that the radiating fibers of the suspensory ligament are relaxed. This allows the elastic lens to assume a more globular shape.
With advancing age, the lens becomes denser and less elastic, and, as a result, the ability to accommodate is lessened (presbyopia). This disability can be overcome by the use of an additional lens in the form of glasses to assist the eye in focusing on nearby objects.
The Near Triad: Constriction of the Pupil (Meiosis, Accommodation and Convergence)

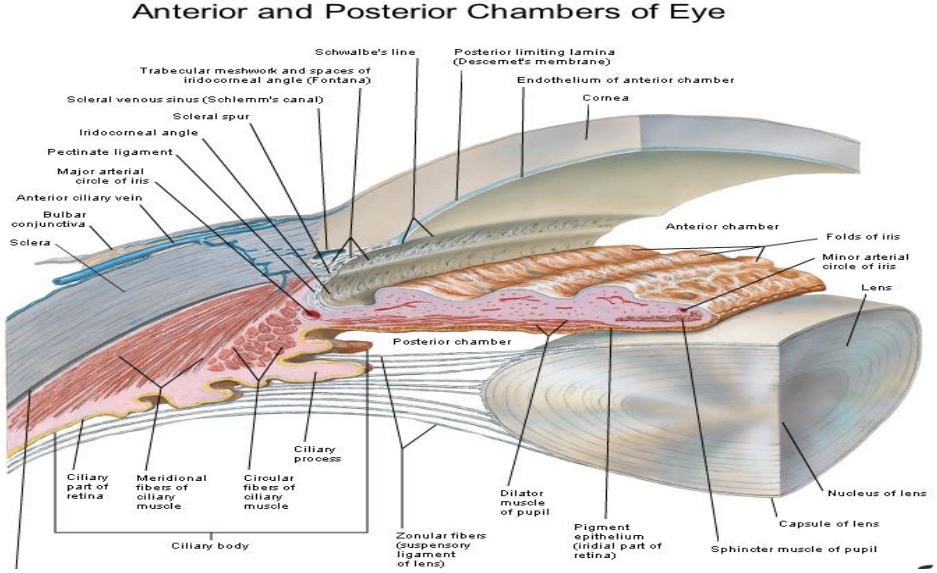

To ensure that the light rays pass through the central part of the lens so spherical aberration is diminished during accommodation for near objects, the sphincter pupillae muscle contracts so the pupil becomes smaller
Convergence of the Eyes During Accommodation of the Lens
In humans, the retinae of both eyes focus on only one set of objects (single binocular vision). When an object moves from a distance toward an individual, the eyes converge so that a single object, not two, is seen. Convergence of the eyes results from the coordinated contraction of the extra-ocular muscles

Light Refractory Pathway:

1. Cornea
2. Aqueous Humor
3. Lens
4. Vitreous Humor
5. Retina

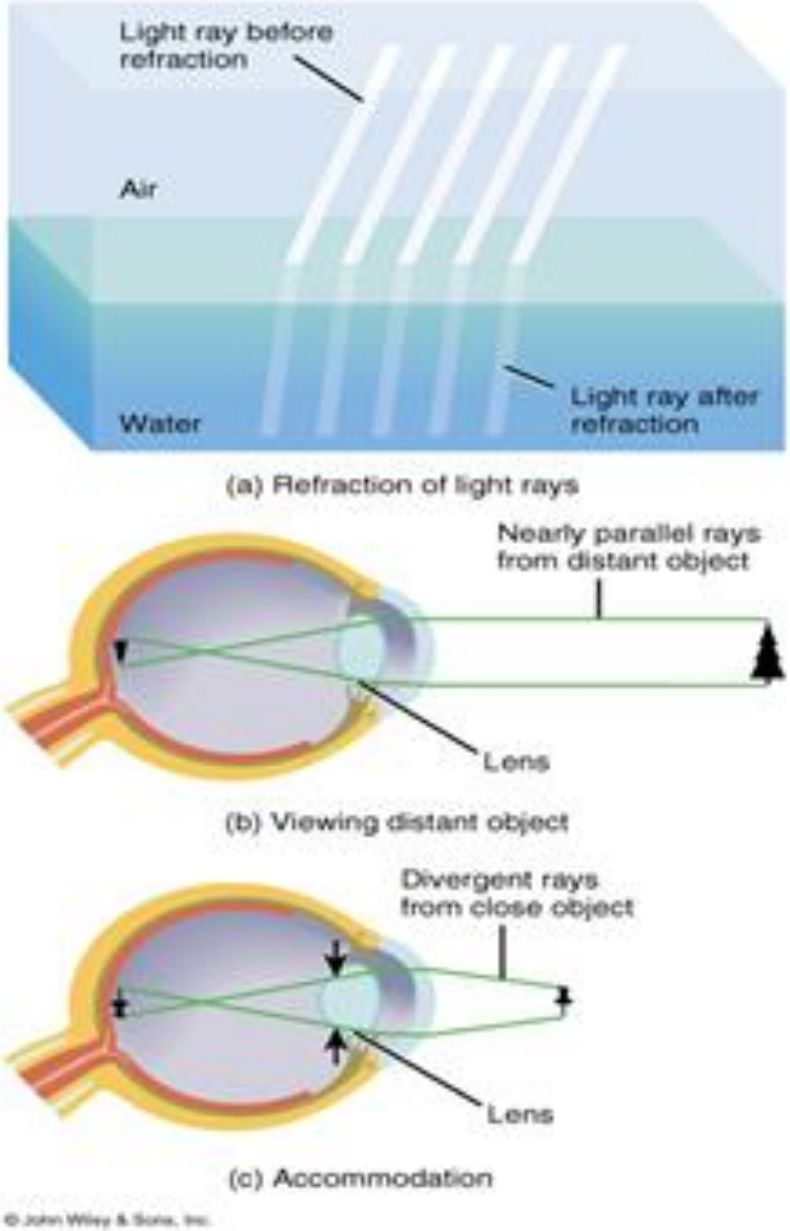

3-Nervous Coat: The Retina

The retina is an inner nervous layer that rests on an outer pigmented retinal pigment epithelium

➢Its outer surface is in contact with the choroid,
and its inner surface is in contact with the vitreous body

At the center of the posterior part of the retina is an oval, yellowish area,
the macula lutea,
which is the area of the retina for the most distinct vision.
It has a central depression, the fovea centralis

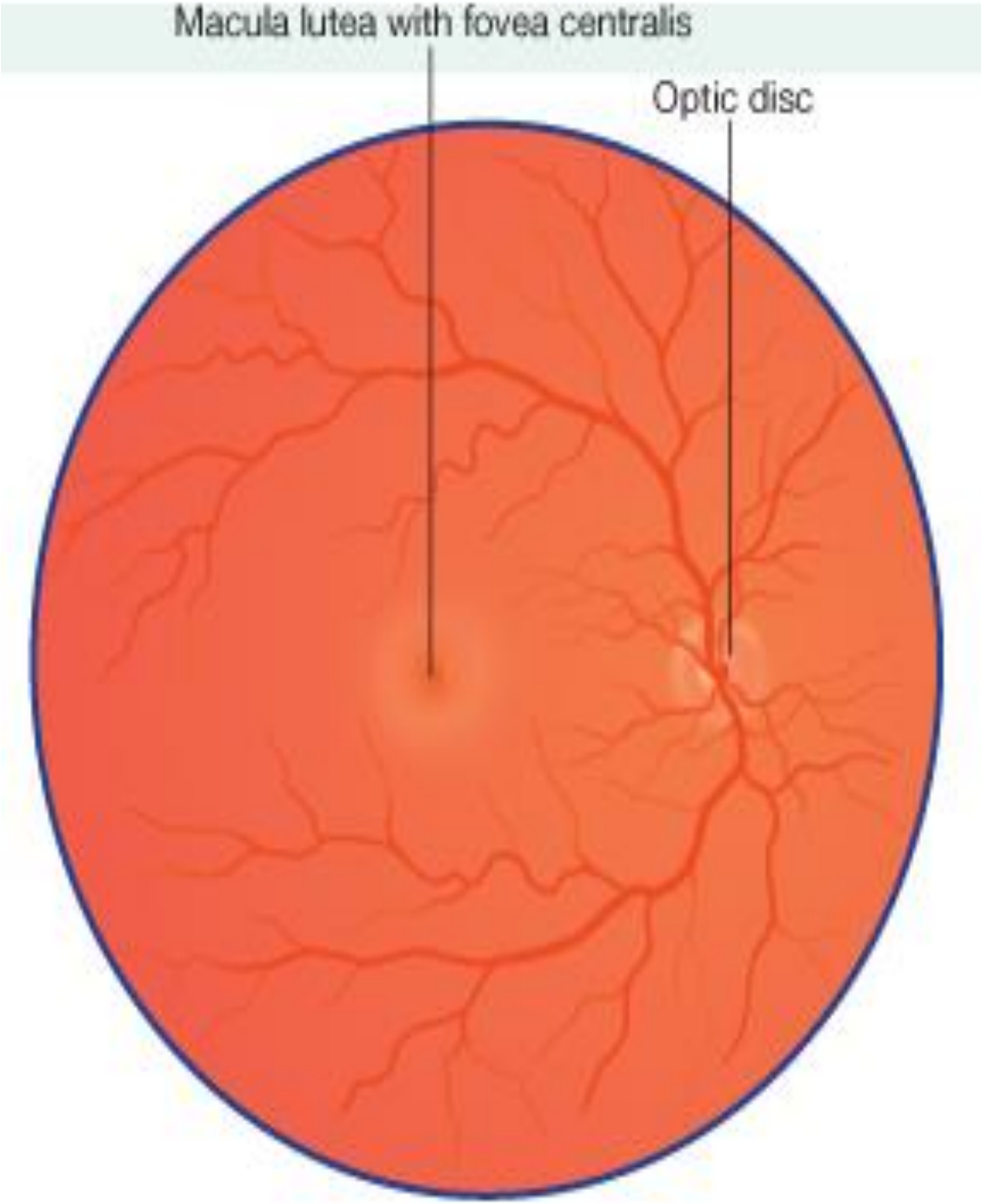

Contents of the Eyeball

The contents of the eyeball consist of:
1-THE AQUEOUS HUMOR
2-THE VITREOUS BODY
3-THE LENS

Aqueous Humor
is a clear fluid that fills the anterior and posterior chambers of the eyeball

Obstruction to the draining of the aqueous humor results in a rise in intraocular pressure, this may lead to optic neuropathy (glaucoma)

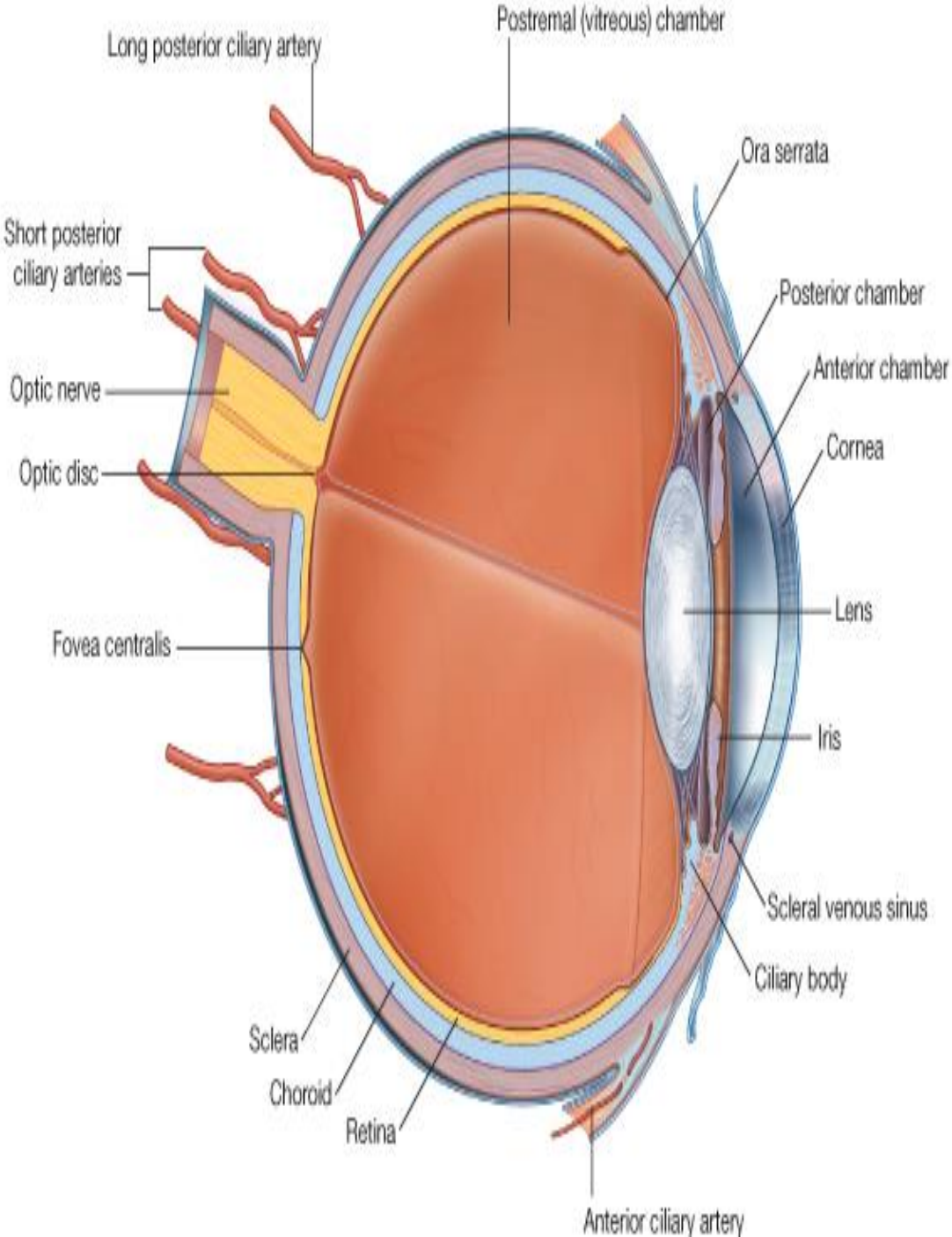

Vitreous Body

The vitreous body fills the eyeball behind the lens and is a transparent gel.
The hyaloid canal is a narrow channel that runs through the vitreous body from the optic disc to the posterior surface of the lens; in the fetus, it is filled by the hyaloid artery, which disappears before birth.
The function of the vitreous body is to contribute slightly to the magnifying power of the eye.
It supports the posterior surface of the lens and assists in holding the neural part of the retina against the retinal pigment epithelium (RPE).

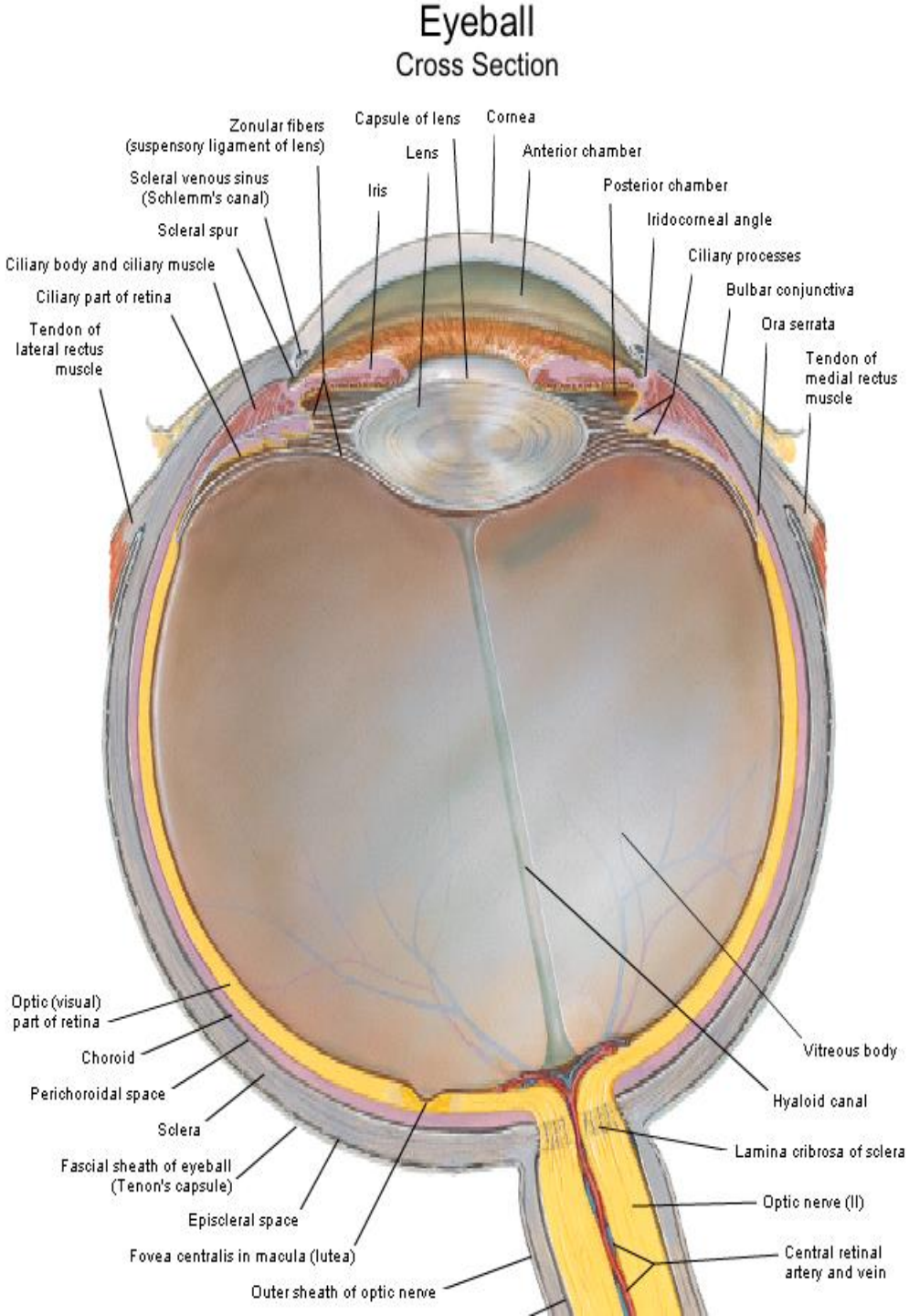

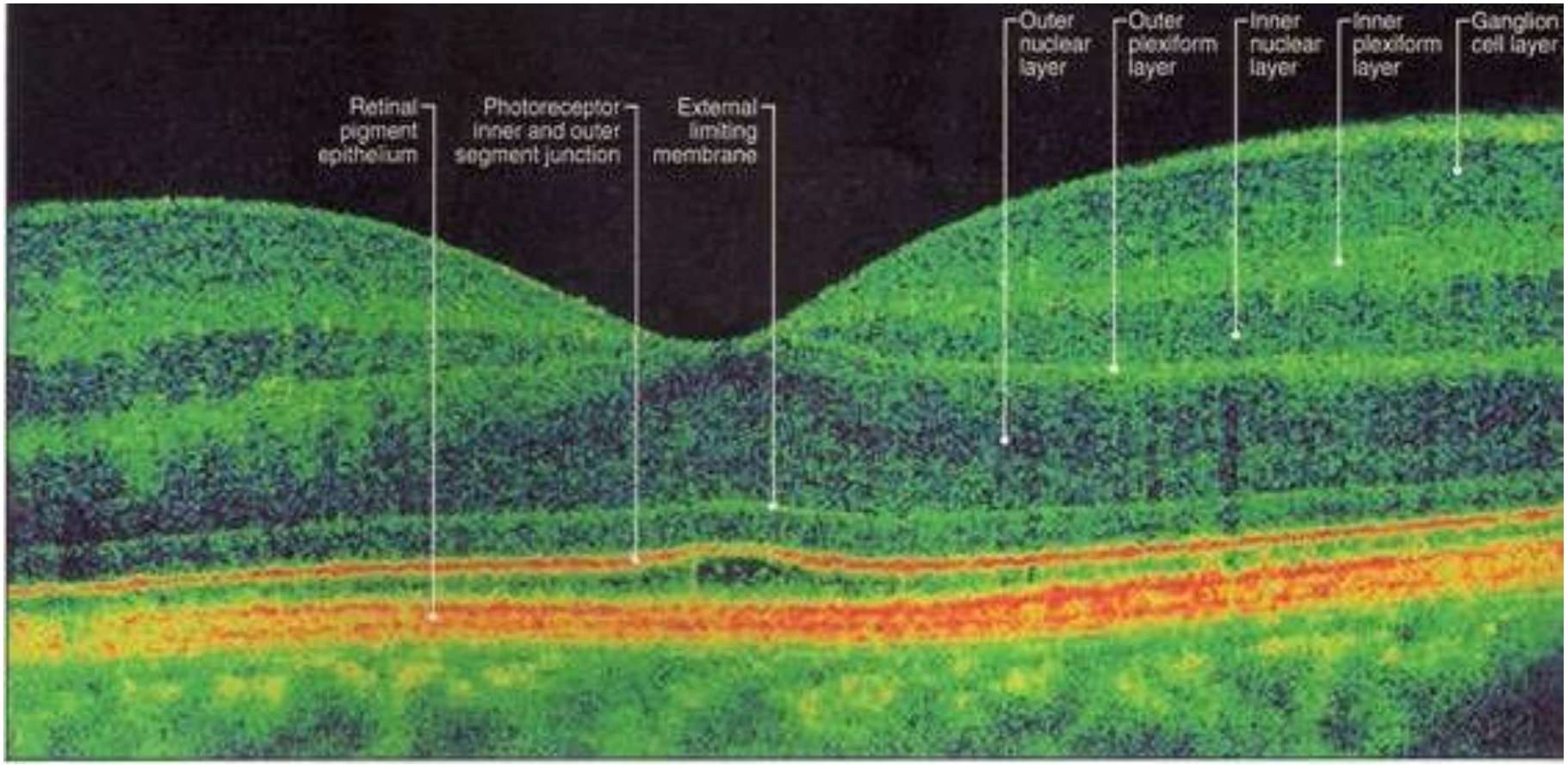
Retinal pigment epithelium
Photoreceptor inner and outer segment junction
External limiting membrane
Outer nuclear layer
Outer plexiform layer
Inner nuclear layer
Inner plexiform layer
Ganglion cell layer

Lacrimal Apparatus of the Eye

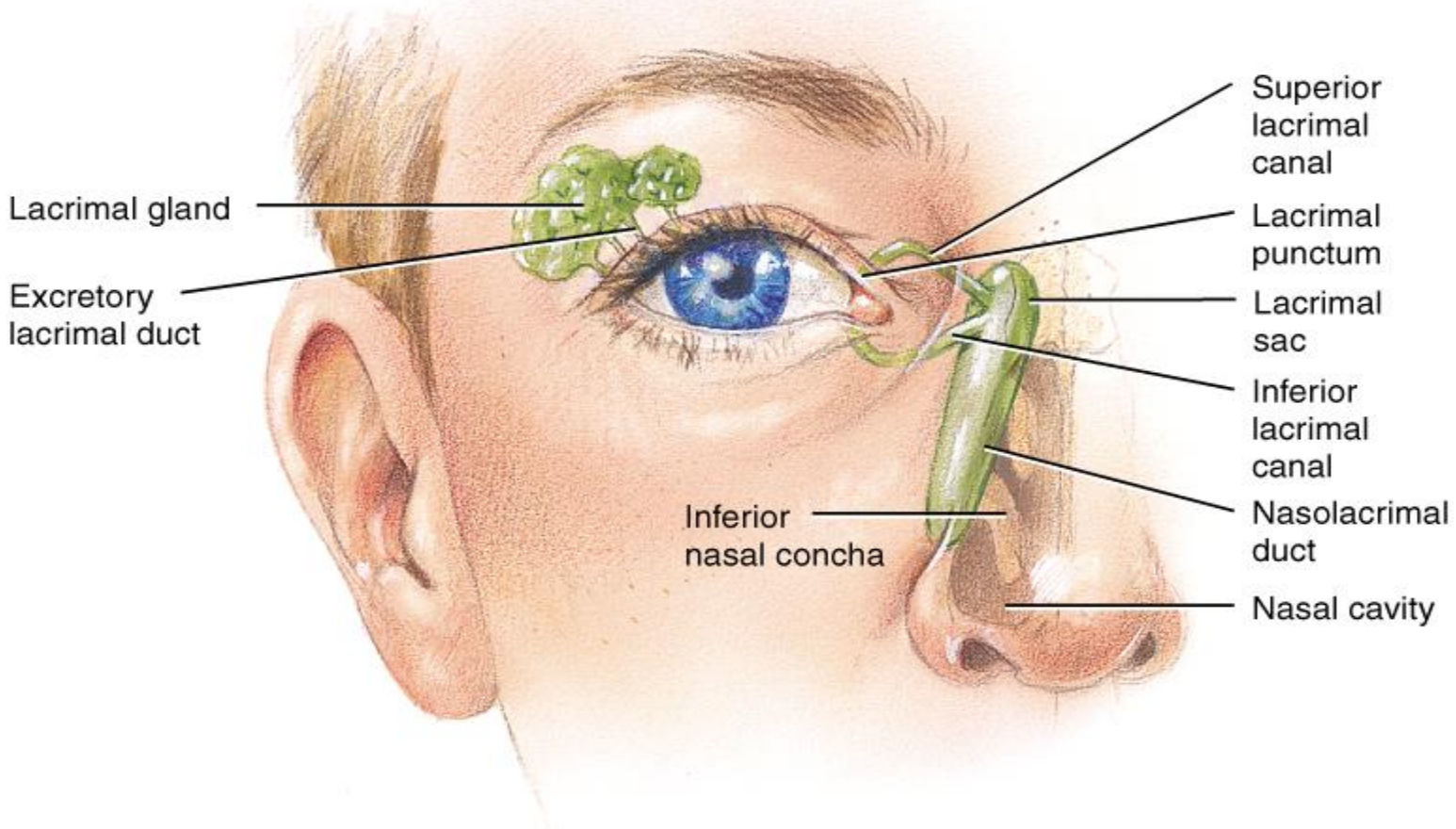

(b) Anterior view of the lacrimal apparatus


NEYMAR JR
11
ATAR
RWAYS

n.abuyaghi@ju.edu.jo