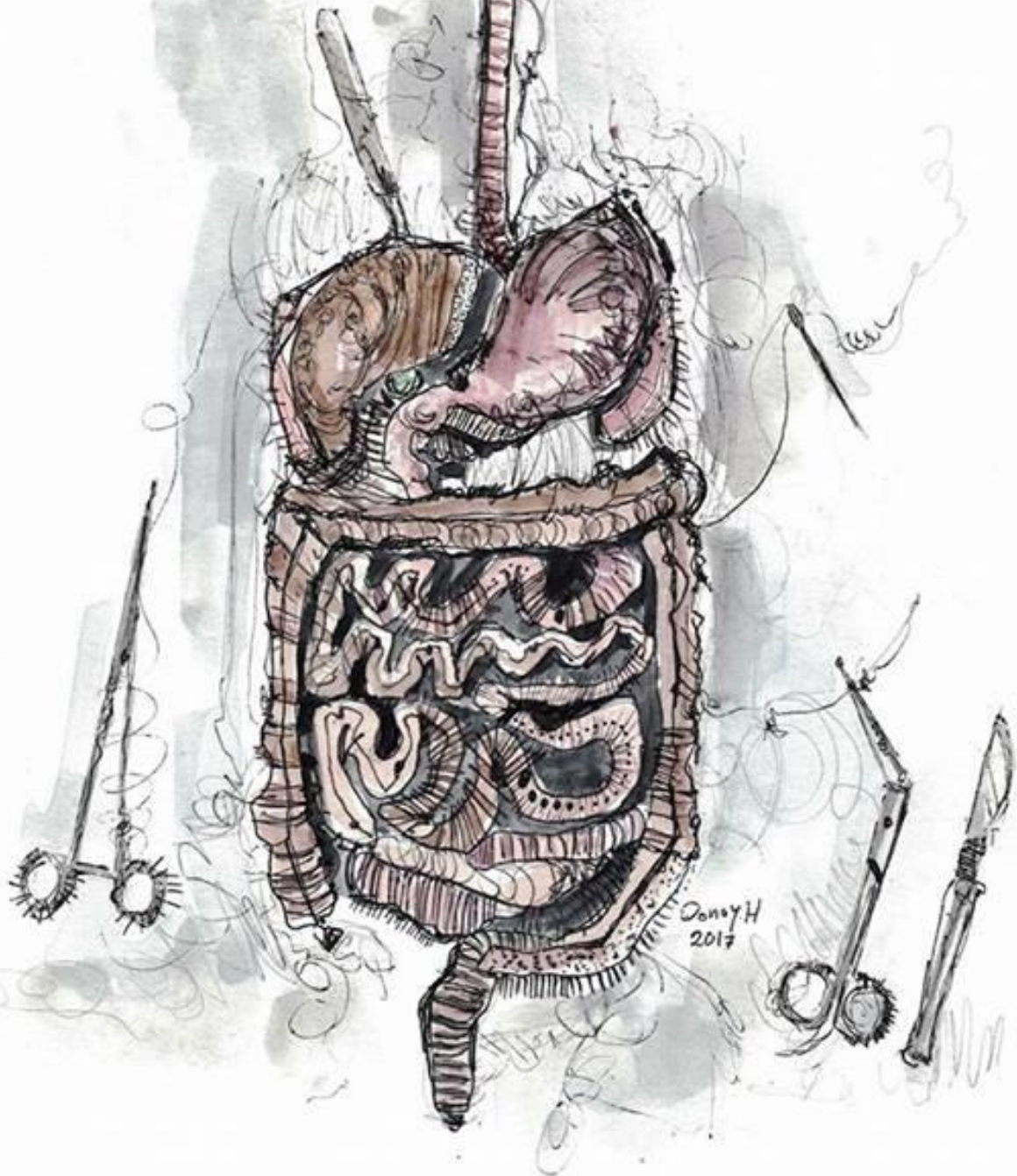


GI Surgery



Editors:

Alma Jarkas

Mohammad Daas

Mohammad Karajeh

Mohammad Qussay Al-sabbagh

Nada Hajjaj

Russole Emad

Yousef Al-As3d

Designed by:

Mohammad qussay al-Sabbagh

Yousef Al-As3d

Cover photo is done by:

Donay Habbak

TABLE OF CONTENTS

CHAPTER 1 (ESOPHAGUS & STOMACH)	3
ESOPHAGUS.....	4
STOMACH.....	28
CHAPTER 2 (PANCREAS & SPLEEN)	55
PANCREAS.....	56
SPLEEN.....	95
CHAPTER 3 (LIVER & BILIARY TREE)	107
LIVER	108
BILIARY TREE	142
CHAPTER 4 (ACUTE ABDOMEN, APPENDIX & SMALL INTESTINE)	179
ACUTE ABDOMEN.....	180
APPENDIX	187
SMALL INTESTINE.....	192
CHAPTER 5 (COLON, RECTUM & ANUS)	209
COLON.....	210
RECTUM & ANUS.....	234

Esophagus & Stomach

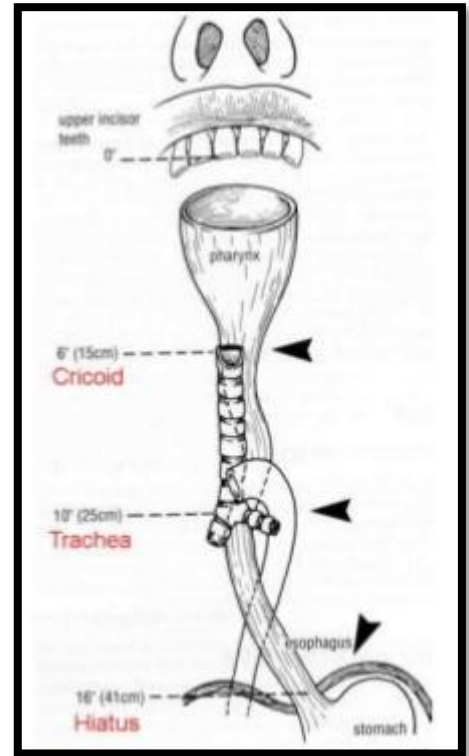
- Written by Mohammad Qussay Al-sabbagh
- Corrected by: Mohammad karajeh & Nada Hajjaj

- Esophagus : 4
 - Introduction: 4
 - Diseases of the esophagus : 6
 - Dysphagia : 19
 - GERD : 23
- Stomach: 28
 - Introduction : 28
 - PUD : 31
 - Gastric CA: 38
 - GIST: 43
 - GI lymphoma: 44
 - Bariatric surgery: 47
 - Gastric syndromes: 52

Esophagus

✦ **Anatomy:** The esophagus is a 25 cm- long muscular tube (40 cm from the mouth) that begins at the pharynx (lower border of C6) and ends at the opening of the stomach (cardia). The muscle type varies along the esophagus:

1. Upper 1/3 → skeletal muscle.
 2. Middle 1/3 → mixed (skeletal + smooth)
 3. Lower 1/3 → smooth muscle.
- There are 3 areas of Narrowing:
1. At the beginning of the esophagus (caused by the cricopharyngeus muscle). (C6)
 2. Where the left main bronchus and aorta cross. (T4)
 3. At the hiatus of diaphragm.
- It has 2 sphincters:
1. Upper esophageal sphincter (UES): anatomical sphincter, caused by actual thickening of the muscular wall, its main function is swallowing.
 2. Lower esophageal sphincter (LES): functional sphincter, so it's an area of high pressure, its main function is prevention of reflux.
- Blood supply:
1. Upper 1/3 → inferior thyroid + anterior intercostal arteries.
 2. Middle 1/3 → esophageal arteries + bronchial arteries.
 3. Lower 1/3 → left gastric + left inferior phrenic arteries.



#Note_1: the vagus nerve runs with the esophagus

#Note_2: the esophagus is at risk of perforation due to absence of serosa.

#Note_3: All GIT has serosa except esophagus and rectum.

✦ **Histology:** lining epithelium of the esophagus is stratified squamous epithelium.

✦ **Physiology:** esophagus is a connection canal through which the food pass, it transfers food by peristalsis.

➤ Types of peristalsis:

1. **Primary:** esophageal peristalsis accompanying swallowing.
2. **Secondary:** initiated by the esophageal musculature without the pharyngeal phase to clean the esophagus of any substance left behind Primary peristalsis.

➤ Phases of swallowing:

1. **Oral phase :** 1 sec. / voluntary
2. **Pharyngeal phase:** <1 Sec. / involuntary
3. **Esophageal phase:** 8-20 sec. / involuntary

➤ Anti-reflux mechanism:

1. Lower esophageal sphincter (LES)
2. Crura of diaphragm.
3. Cardiac angle (angle of His)
4. Peristaltic movement.
5. Saliva

✦ **Main signs and symptoms:** In esophageal disorders, we rely on History and investigations. Physical examination has low value here.

1. **Dysphagia:** the most important symptom, it means difficulty of swallowing, and almost all esophageal problems present with anatomical/functional dysphagia.
2. **Odynophagia:** may indicate esophageal problem as well.
3. **Wight loss:** as a consequence of Dysphagia and odynophagia.
4. **Regurgitation** of food or gastric content.
5. **Pain:**
 - A. **Heartburn:** a burning sensation in the central chest or upper central abdomen. The pain often rises in the chest and may radiate to the neck, throat, or angle of the jaw.
 - B. **Atypical chest pain:** may mimic MI.

Main Investigations:

- A. **Barium swallow:** a special type of X-ray, that uses barium sulfate to visualize upper GI, it's the first test (best initial) test performed in workup of dysphagia.

B. Upper endoscopy: follow Barium swallow (if needed).

#Note_1: Barium swallow is done before Upper endoscopy, as endoscopy carries the risk of perforation in case of diverticular diseases or obstruction. Moreover, Barium swallow could be diagnostic or it may give a big hint to direct other investigations.

#Note_2: Barium swallow and Upper endoscopy look for structural problems, while other investigations look for functional problems

C. Esophageal manometry: (dysphagia with -ve barium swallow and upper endoscopy → go for Manometry).

D. 24 hour esophageal monitoring

Achalasia



INTRODUCTION

✦ **Definition:** a failure of smooth muscle fibers to relax, which can cause a sphincter to remain closed and fail to open when needed.

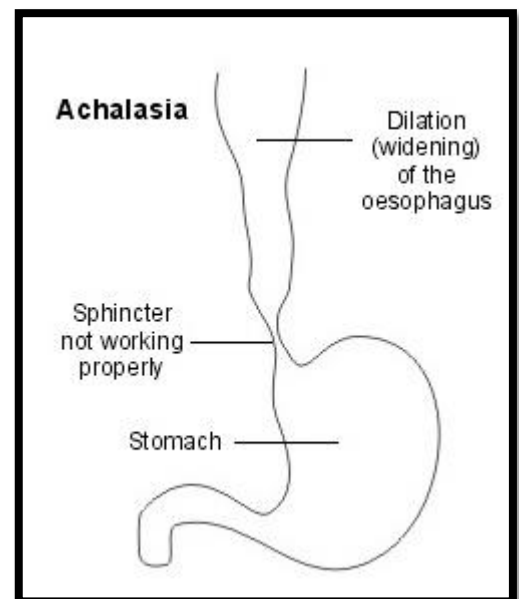


ETIOLOGY

✦ Of unknown etiology.

✦ pseudoachalasia/secondary achalasia:

1. Esophageal CA.
2. Lymphoma
3. Chagas disease (trypanosoma cruzi infection).
4. Eosinophilic esophagitis
5. Neurodegenerative diseases.



PATHOPHYSIOLOGY

✦ Loss of intraluminal neurons → inc. LES tone (failure of relaxation) → Dilation of the Distal esophagus.

✦ No esophageal peristalsis.

✦ inc. LES pressure

✦ LES does not relax with swallowing.



CLINICAL FEATURES

✦ **Signs and Symptoms:**

1- **Dysphagia**

- For solids and liquids.
- Progressive (become worse overtime)
- Longstanding, not associated with smoking and alcoholism, occur in younger group than CA (Vs CA).

2- **Regurgitation of food**

- especially at night.
- No reflux or difficulty in retching.
- Without bad smell

✦ **Complications:**

- Aspiration pneumonia.
- Wight loss.
- Esophageal carcinoma



DIAGNOSIS

✦ **Imaging:**

1. **Barium swallow:** (best initial test) → bird's beak appearance (narrow LES + dilated esophagus)
2. **Upper endoscopy+ biopsy:** to confirm diagnosis +role out CA
3. **Esophageal manometry:** (the definitive diagnosis) → absence of peristalsis+ non relaxing LES.



TREATMENT

✦ **pneumodilatation: (BEST initial therapy)**

- 3-4 diameter ballon is inflated in the LES→ produce higher pressure.
- Effective in 85% of patients.
- 5% risk of perforation.

✦ **Botox (botulinum toxin injection)**

- Effective in 65% of patients.
- Requires repeating therapy within 6-12 months.

✦ **Surgical myotomy.**

- "Heller" myotomy.
- Excision of circular muscle layer of LES.
- High risk of GERD

✦ **Medical treatment** (CCB and nitrates) is not that effective.

Diffuse esophageal spasm



INTRODUCTION

✦ **Diffuse esophageal spasm (DES):** Idiopathic abnormality in neuromuscular activity of the esophagus, resulting in non-peristaltic contractions with high amplitudes causing pain and dysphagia.

- **Nut-Cracker:** Similar to DES but it's peristaltic contractions.
- DES and Nut-cracker are the same disease, the only difference is manometry.
- Think about DES as Irritable bowel syndrome of the esophagus.



ETIOLOGY

✦ Idiopathic.



CLINICAL FEATURES

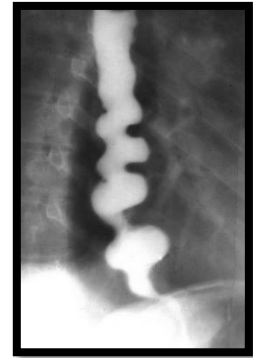
1. **Dysphagia:**
 - For both solids and liquids.
 - Intermittent.
2. **Atypical chest pain.**
 - May mimic MI.
 - Intermittent.
 - Not associated with swallowing (not odynophagia)
 - Not related with exercise.
 - Inc. With cold liquids.



DIAGNOSIS

Imaging :

- 1- ECG to rule out MI.
- 2- Barium swallow :
 - Corkscrew appearance (see picture).
 - Could be normal.
- 3- Manometry (most accurate test):
 - High intensity, intermittent, disorganized contractions.



TREATMENT

- 1- CCB (Diltiazem /Nifedipine)+nitrates → 1st line
- 2- Isosorbide or sildenafil → 2nd line
- 3- Botox injection → 3rd line

Lower esophageal ring (Schatzki ring)



INTRODUCTION

Definition: Lower esophageal ring, usually at the squamo-columnar junction.



ETIOLOGY

almost always associated with esophageal hiatal hernia.



CLINICAL FEATURES

- 1- Dysphagia:
 - Intermittent and not progressive.
 - For solids only, especially meat and fibers.
 - Not associated with pain.



DIAGNOSIS

✦ Imaging:

- 1- Barium swallow (the ring should be >13 mm to cause symptoms)
- 2- endoscopy



TREATMENT

✦ esophageal dilatation, using bougie or balloon dilators.

- The patients are placed on PPI after diltation.

Esophageal Webs



INTRODUCTION

✦ **Esophageal webs:** Thin protrusion of esophagus mucosa, most often in the upper esophagus (hypopharynx).



ETIOLOGY

✦ **Plummer-vinson syndrome**, due to iron deficiency anemia (IDA), it's characterized by:

- Esophageal webs
- Beefy-red tongue
- Koilonychia.
- Pica.



CLINICAL FEATURES

✦ Signs and Symptoms:

1. Dysphagia:

- Intermittent and not progressive.
- For solids only.
- Not associated with pain.

✦ **Complications:** slightly increased risk for esophageal CA.



DIAGNOSIS

⚡ Imaging:

- 1- Barium swallow.
- 2- endoscopy



TREATMENT

⚡ Treat IDA

⚡ or treat it like esophageal rings, by dilatation.

Esophageal stricture



INTRODUCTION

Definition: Narrowing of the esophagus.



ETIOLOGY

- Long history of incompletely treated reflux.
- Prolonged NG tube placement.
- Lye (bleaching agent) ingestion decades ago (alkali is worse than acids) → erosive esophagitis.



PATHOPHYSIOLOGY

⚡ Prolonged/severe Esophageal irritation → erosion of the mucosa → fibrosis (stricture)



CLINICAL FEATURES

⚡ Signs and Symptoms:

- 1- **Dysphagia:** (Vs CA)
 - Constant, slowly progressive.
 - For solids then liquids.



DIAGNOSIS

⚡ Barium swallow.



TREATMENT

⌘ Dilation



Esophageal CA



INTRODUCTION

⌘ Epidemiology:

- 99% of esophageal neoplasms are malignant.
- It's endemic In China, western Africa, central America and Iran.
- It's relatively rare in Jordan.

⌘ Types:

1- Adenocarcinoma.

- The most common type in USA (& Jordan).
- Associated with Barret's esophagus.
- distal 1/3.

2- Squamous cell CA. (SCC)

- Most common (90%) worldwide (and in endemic areas).
- Causes are environmental.
- Middle or upper thirds



ETIOLOGY

⌘ General risk factors:

- Male gender, age >50.
- Poor nutrition (low fruits and vegetables intake) .
- Hot beverages.
- Smoking and Alcohol (synergistic effect, especially in low incidence areas).
- History of Radiation to the mediastinum

⌘ Risk factors of SCC:

- **In general, Irritation of the mucosa.**
- Smoking and Hot beverages.
- Underlying esophageal disease (Achalasia, strictures, esophageal webs).
- Prior gastrectomy.
- Zinc oxide.

- Nitrosamines.
- Tylosis.

⚡ Risk factors of adenocarcinoma:

- GERD → Barret's esophagus → **most important risk factor.**
- Obesity.
- Smoking, and alcoholism.
- H. pylori
- EGF (epidermal growth factor) polymorphism.

PATHOPHYSIOLOGY

1- SCC:

- It occurs due to prolonged esophageal irritation, usually seen in upper or middle thirds.
- It grows as polypoid, white plaques, or scar like lesions, early stages could be missed by endoscopy. → biopsy any lesion seen in endoscopy.
- It invades the submucosa, and travels cranially and caudally.
- It invades regional lymph nodes (Cervical & mediastinal) early.
- The trachea and aorta could be invaded, leading to tracheoesophageal fistula and bleeding, respectively.
- 1/3 of cases shows metastasis to liver, bone and lungs

2- Adenocarcinoma:

- GERD → Barret's esophagus → dysplasia → CA
- It occurs in lower 1/3.
- In endoscopy, Lesions are similar to Barret's esophagus.
- Spread to lymphatics around the stomach, Porta hepatis, and celiac lymph nodes.

CLINICAL FEATURES

⚡ Most patients are asymptomatic till the tumor is advanced.

1- Dysphagia.

- The earliest sign.
- Dysphagia does not usually develop until >60% of esophageal lumen is obstructed.
- Constant, rapidly progressive.

➤ For solids then liquids.

➤ **Associated with reflux**

2- **Loss of appetite** and Weight loss, weakness and retrosternal discomfort.

3- **Achalasia-like symptoms.**

4- **Hoarseness** and Horner syndrome.

5- Tracheoesophageal fistula and bleeding.



DIAGNOSIS

⚡ Investigations:

1- **Barium study** → may show us changes in contour.

2- **Endoscopy** and multiple biopsies for any change seen in the mucosa of the esophagus.

3- Full metastasis work up (CT scan of abdomen and chest, endoscopic ultrasound, PET scan).

⚡ Staging (TNM):

1- **Endoscopic ultrasound** for T staging:

➤ T1 → mucosa/submucosa

➤ T2 → Muscularis propria

➤ T3 → Adventitia

➤ T4 → invasion of surrounding structures

• T4a → not adherent

• T4b → adherent

2- **CT, then PET scan for N staging:**

No → no lymphatic invasion N1 → 1-2

N3 → 3-6 N4 → 3-6

N5 → more than 6

3- **CT scan for lung and liver** for distant metastasis.

4- Final staging (briefly):

➤ Stage 1 and 2 → no lymph node invasion.

➤ Stage 3 → lymph node involvement or wall invasion (T3)

➤ Stage 4 → distant metz.

⚡ Ddx

1-Leiomyoma 2-Metz.

3-Lymphoma 4-Benign stricture.

5-Achalasia. 6-DES

7-GERD



TREATMENT

⚡ The only way to cure esophageal CA is surgery:

➤ Stage 1 and 2 → surgery.

➤ Stage 3 → neoadjuvant chemotherapy/radiotherapy to shrink the tumor → then surgery.

➤ Stage 4/or patients is unfit → chemotherapy/palliative surgery.

⚡ In surgery, we remove the esophagus, and we put a conduit (stomach or colon):

➤ Stwert 1 → if the tumor above LES → we remove esophagus only

➤ Stwert 2 → invades LES → we remove the esophagus + parts of the stomach with -ve margins.

➤ Stwert 3 → below LES → we remove the stomach with -ve margins.

➤ It's indicated to remove regional lymph nodes as well.

⚡ Palliative therapy:

➤ Stenting

➤ Palliative surgery.

➤ Laser therapy.

➤ Phototherapy.

Scleroderma esophagus



INTRODUCTION

⚡ **Scleroderma** (AKA systemic sclerosis): is a group of autoimmune diseases that may result in changes to the skin, blood vessels, muscles, and internal organs.

⚡ It's known as CREST syndrome:

1- calcinosis.

2- Raynaud's phenomenon.

3- esophageal dysmotility.

4- Sclerodactyly.

5- Telangiectasia

⚡ 85% of patients with scleroderma have esophageal disorders, so it's the most common Connective tissue disease affecting the esophagus.



PATHOPHYSIOLOGY

⚡ Atrophy of esophageal wall smooth muscles → absent/weak esophageal contractions + LES is wide open with no tone/pressure → reflux → fibrosis of the esophageal wall.

⚡ dysphagia due to Scleroderma is a neuromuscular problem, so it's for solids only. However, it may become mechanical eventually as a result of fibrosis of the smooth muscles.



CLINICAL FEATURES

⚡ Signs and Symptoms:

1- Dysphagia:

➤ Progressive, painless and for solids only (could progress into liquids in late stages)

2- Reflux



DIAGNOSIS

⚡ The clinical picture is clear, so need for further investigations.

⚡ Barium swallow and endoscopy?



TREATMENT

⚡ treat the reflux with PPI + follow up every 2-3 months.

Zenker's Diverticulum



INTRODUCTION

Definition: is a diverticulum (outpouching) of the mucosa of the pharynx, just above the cricopharyngeal muscle (i.e. above the upper sphincter of the esophagus). It is a pseudo diverticulum (not involving all layers of the esophageal wall).



PATHOPHYSIOLOGY

⚡ The upper esophageal sphincter has two parts, Upper Oblique (thyropharyngeus) and lower transverse (cricopharyngeus), between these muscles, there's a weak area.

✦ If swallowing is Uncoordinated so that the cricopharyngeus does not relax, the weak unsupported area above these fibers bulges out.



CLINICAL FEATURES

✦ **Signs and Symptoms:**

1- **Dysphagia:**

- Transfer dysphagia (difficulty initiating the swallowing)
- For solids Only.

2- Halitosis (bad smell)

3- Food reaggregation.

4- Posterior neck mass.



DIAGNOSIS

✦ Barium swallow.

✦ ~~Endoscopy~~ and NG tube are contraindicated (due to the risk of perforation)



TREATMENT

✦ **Surgical resection**

Other esophageal conditions

✦ These conditions are medical problems more than surgical, and usually don't present with dysphagia, we will mention them briefly:

1- Esophagitis

✦ **Definition:** It's a general term referring to either infection or inflammation of the esophagus, that results in a **painful swallowing (Odynophagia)**.

✦ We have 3 types:

- 1- Pill induced esophagitis.
- 2- Infective esophagitis.
- 3- Eosinophilic (allergic) esophagitis.

a) **Pill-induced esophagitis:**

✦ Inflammation due to direct effect of contact between the mucosa & pill, usually in patients who ingest pills without water.

✦ Examples of pills: NSAIDs, KCL, Iron sulfate, Doxycycline, Bisphosphonates, Alendronate etc....

✦ **Diagnosis** is based on history:

- **Odynophagia.**
- Pain ONLY with swallowing.
- History of taking pills with small amount or without water.

✦ **Treatment:**

- swallowing pills in upright posture & drinking enough water.

b) **Infective esophagitis**

✦ **Definition:** Opportunistic infection usually occur in immunocompromised patients (patients with HIV, DM, or using steroids, Chemotherapy etc..)

✦ It's caused by many organisms, but the most common are: Candida (may present with oral thrush), HSV and CMV.

✦ **Diagnosis and treatment:**

- We give **Fluconazole** empirically:
 1. If improved → Continue treatment, until the offending agent is gone (or CD4 improved)
 2. If not improved → Do endoscopy with biopsy.

c) **Eosinophilic (allergic) esophagitis**

✦ **Definition:** Immune mediated chronic esophageal inflammation:

- More common in males (20-40 years old)
- Strong association with other allergies: Involves IL-5, associated with peripheral eosinophilia, IgE is high in 20% of patients.

✦ Diagnosed by Endoscopy with biopsy:

- Classical finding of Scalloped off.
- Biopsy shows dense eosinophilic infiltration in the middle of esophagus.

✦ **Treatment:**

- Topical corticosteroids: (topical viscous budesonide or fluticasone).

➤ PPI maybe helpful.

2-Mallory weiss tear syndrome

⚡ Definition: Partial-thickness mucosal laceration at gastroesophageal junction due to severe vomiting, Usually found in alcoholics and bulimics.

⚡ Symptoms:

1. Painful Hematemesis, preceded by vomiting and retching.
2. Not a cause of dysphagia

⚡ Diagnosis:

1. History.
2. Direct visualization upper endoscopy.

⚡ Treatment: No need, is it resolves spontaneously.



HISTORY & PHYSICAL Of dysphagia

⚡ **Dysphagia:** it means difficulty of swallowing, there's 3 types of dysphagia:

1. **Neuromuscular dysphagia**, or esophageal dysmotility, is worse for solids and may be helped by liquids and sitting upright.
2. **'Mechanical' dysphagia**, or anatomical dysphagia, is for both solids and liquids.
3. **Neurological dysphagia** is worse for liquids than for solids, and may be accompanied by choking, spluttering and fluid regurgitating from the nose, It's not associated with esophageal abnormalities.

⚡ Differentials of dysphagia:

Ddx	Main problem	Time	Symptoms participated by
Schatzki ring	Anatomic	Intermittent	Solids only
Stricture	Anatomic	Slowly progressive	Solids, then liquids
Esophageal CA	Anatomic	rapidly progressive	Solids, then liquids
Achalasia	Neuromuscular	Long-standing	For solids and liquids -_-
DES	Neuromuscular	Intermittent	For solids and liquids

Scleroderma	Neuromuscular + anatomical	Slowly progressive	For solids and liquids
Neurological	Neurogenic	Various	For liquids.

History:

Patient Profile and Chief Complaint

History of Present Illness:

Dysphagia

- | | |
|--------------------------------------|---|
| ○ Duration | ○ Timing: |
| ○ Onset | - Is it worse over the course of the day? |
| ○ Solids, liquids or both? | (Myasthenia Gravis) |
| - Order them, which occurred first | ○ Progression of the symptoms |
| ○ At what level does the food stick? | ○ Alleviating or Exacerbating Factors |
| ○ Intermittent vs. Progressive | - Relieved by sitting forward? |
- What do you think caused this?

Associated With

- | | |
|--|--|
| ● Odynophagia | ● Heartburn, belching, waterbrash |
| - Site | ● Lump in the throat (Globus) |
| - Only on swallowing | ● Neck Bulge (Pouch) |
| ● Coughing or Choking on swallowing | ● Halitosis (Zencker) |
| - When? Is it nocturnal | ● Weight Loss |
| ● Chest Pain; SOB; Stridor | ● Appetite |
| ● Regurgitation: | ● General weakness or mental status change |
| - Undigested? Bad Smell? When? | ● Anemia Symptoms: |
| ● Symptoms of metastasis | - Tongue sores |
| ● Skin around the lips or fingers feels tight? (sclerosis) | - Tingling in the leg |
| | - SOB |
| | - Dizziness |
| | - Fatigue and Weakness |

Previous History and Risk Factors

- **Medical and Surgical History:**

- Previous esophageal disease
- Previous Stroke or Neurologic Disease
(Myasthenia Gravis, Bulbar Palsy)
- HIV

- **Family History:**

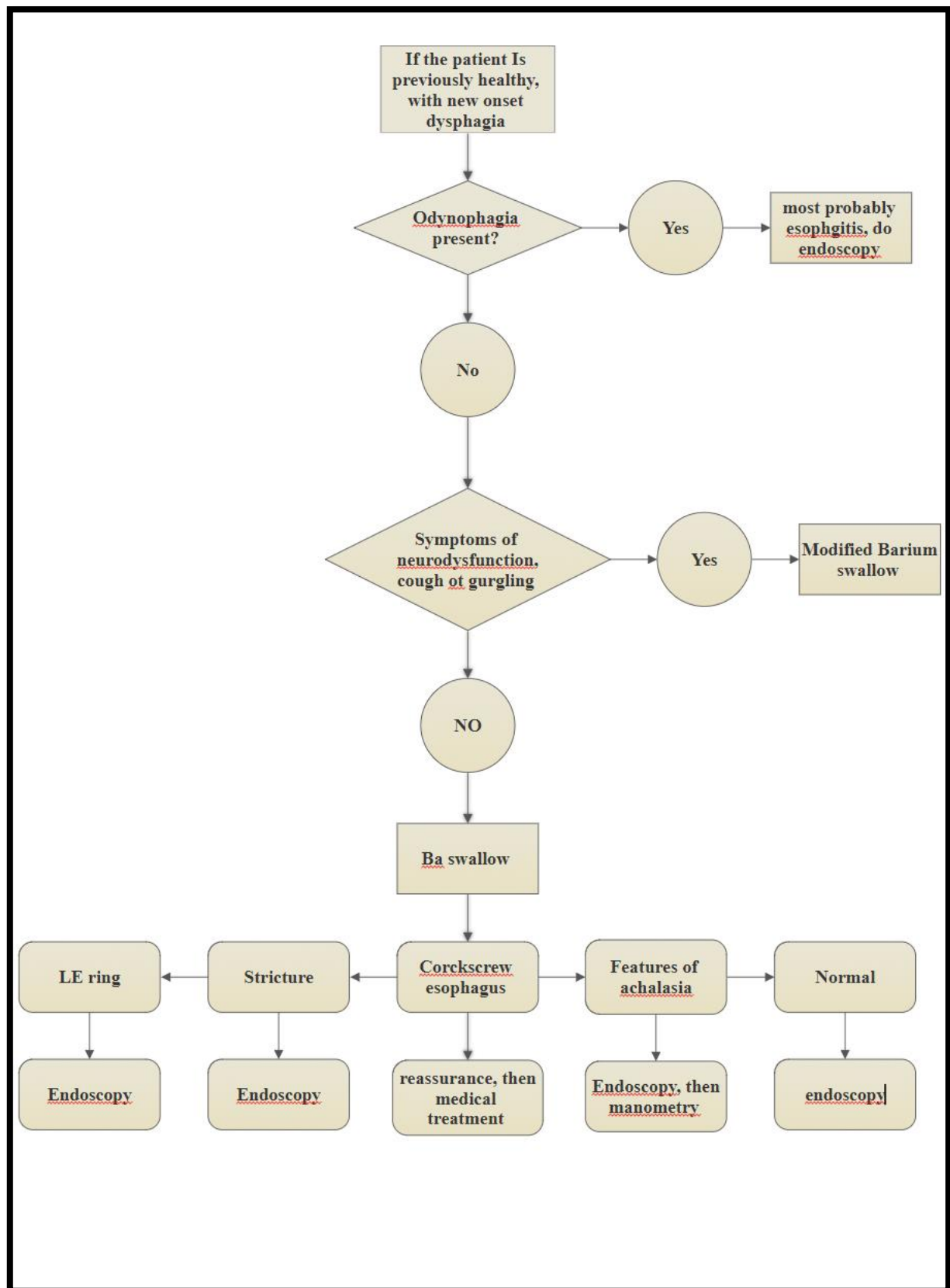
- Cancer

- **Medications:**

- NSAIDs
- Steroids
- Iron Tablets (Plummer Vinson)
- Pills taken without water

- **Social History:**

- Smoking
- Alcohol
- Diet



Gastroesophageal Reflux (GERD)

INTRODUCTION

✦ **Definition:** Gastroesophageal reflux disease (GERD), also known as acid reflux, is a long-term condition where stomach contents come back up into the esophagus resulting in either symptoms or complications

✦ **Epidemiology:** Very common disease.

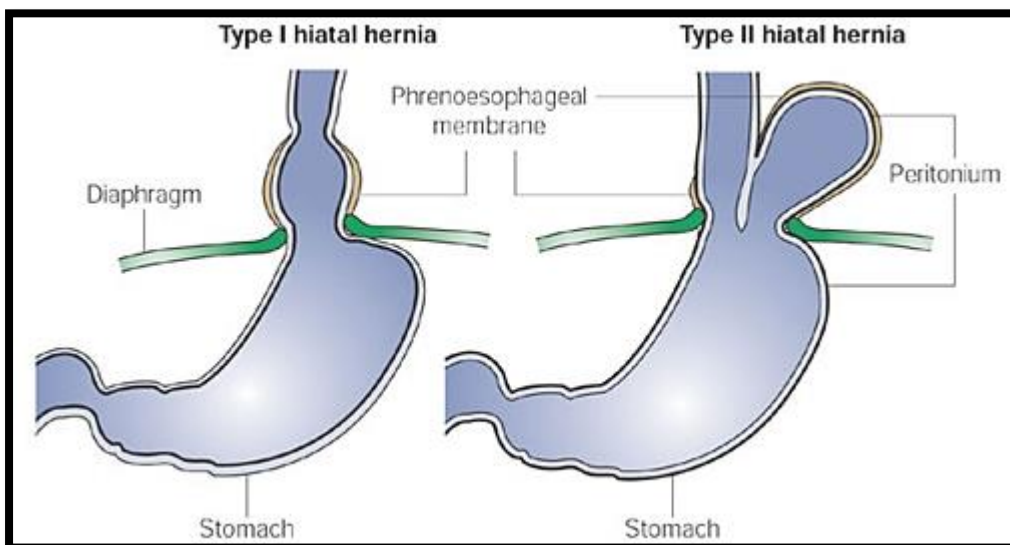
PATHOPHYSIOLOGY

✦ Loss of anti-reflux mechanisms:

1. **Loss of LES tone &/or peristalsis;** due to smoking, alcohol, peppermint, Chocolate, CCB & nitrates. Or **hiatal hernia (see below)**.
2. **Inc. Gastric volume;** due Diabetic gastroparesis or pyloric stenosis.
3. **Inc. Gastric pressure;** due to Ascites or pregnancy.

✦ **Hiatal hernia:**

- It is a type of hernia in which abdominal organs (typically the stomach) slip through the diaphragm into the middle compartment of the chest.
- It has two major subtypes, sliding (type I) and paraesophageal (Type II) :



1. Sliding hiatal hernia (Type I) :

- Both the stomach & GE junction herniate into the thorax via esophageal hiatus.
- It's the most common type of hiatal hernia. (>90% of cases)
- Mostly asymptomatic, but may present with GERD, esophagitis, dysphagia. And pulmonary problems.
- Diagnosed by UGI series, Manometry and endoscopy with biopsy.
- Treatment Is medical in 85% of cases, and surgical in 15% of cases.

2. Paraesophageal hiatal hernia (Type II):

- Herniation of all or part of the stomach through the esophageal hiatus into thorax without displacement of Gastroesophageal junction.
- It's rare (5% of cases)
- It causes mechanical obstruction → Dysphagia, stasis gastric ulcers & strangulation.
- However, most cases are asymptomatic (it's not associated with reflux, as the LES is normal)
- Complications: hemorrhage, obstruction, incarceration and strangulation.
- Treatment is surgical only.

3. Type III hiatal hernia → combined type I & II

4. Type IV hiatal hernia → Organ(colon/spleen) + stomach in chest cavity.



CLINICAL FEATURES

✦ Signs and Symptoms:

1. Heartburn/ sore throat.
2. Water brush.
3. Epigastric/substernal pain (the most common cause of non-cardiac chest pain is GERD).
4. Bad, metal-like taste in mouth.
5. Cough, wheezing or hoarseness (it may exacerbate asthma).

⚡Alarming signs:

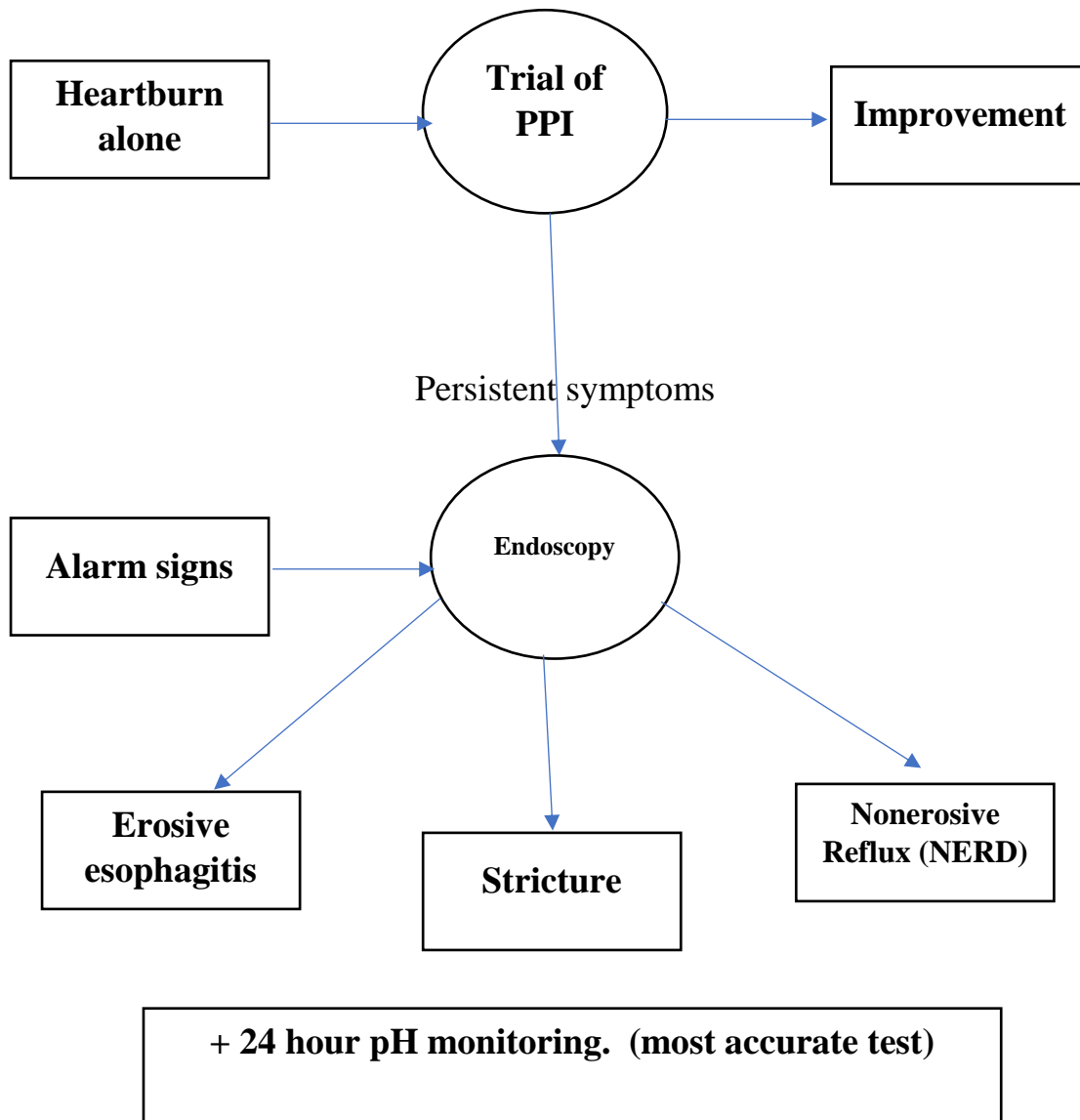
1. Nausea/emesis.
2. Dysphagia/odynophagia
3. Weight loss/ anorexia/ anemia/ blood in stool.
4. Abnormal physical exam.
5. Family history of peptic ulcer disease.
6. Failure to respond to PPI.
7. Long duration of symptoms.

⚡Complications:

1. Exacerbation of asthma.
2. Esophageal ulcers
3. Strictures,
4. bleeding
5. **Barrett esophagus**
 - It's an intestinal metaplasia of lower esophageal mucosa (change from stratified squamous epithelium into simple columnar epithelium with goblet cells).
 - Risk factors are smoking and GERD, but many cases lack these risk factors.
 - Diagnosed by endoscopy.
 - Management is by PPI and **follow up**:
 - i. No dysplasia → 3-5 years
 - ii. Low-grade dysplasia → 6-12 months
 - iii. High-grade dysplasia → 3 months



DIAGNOSIS



TREATMENT

Medical:

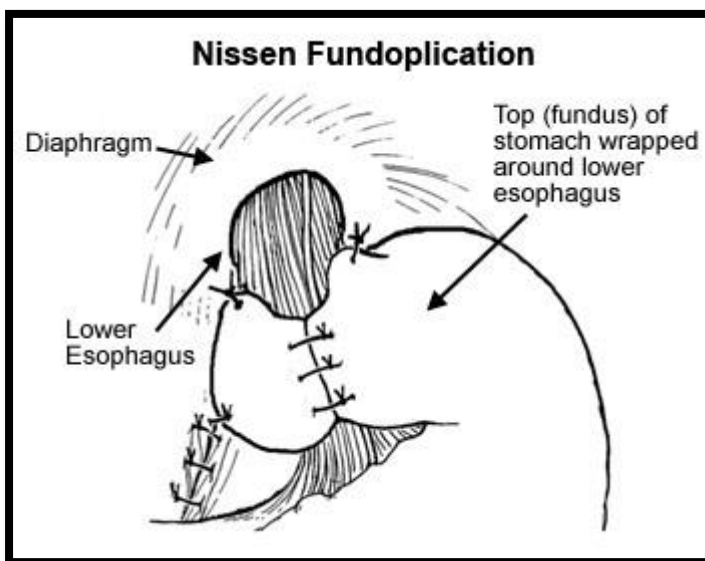
➤ Mild or intermediate:

1. Life style modification. (raise head in bed, weight loss, small not fatty or sweet meals, eat at least 3 hours before sleep, stop smoking and alcohol drinking)
2. Antacids
3. H2 blockers.

- Moderate or progressive:
 1. Life style modification.
 2. PPI

✚Surgical:

- Indications for surgery:
 1. Failure of medical treatment.
 2. Respiratory problems.
 3. Severe esophageal injury/
- Surgical options:
 1. **Lap Nissen**
 - It's 360 fundoplication – 2 cm Laparoscopically.

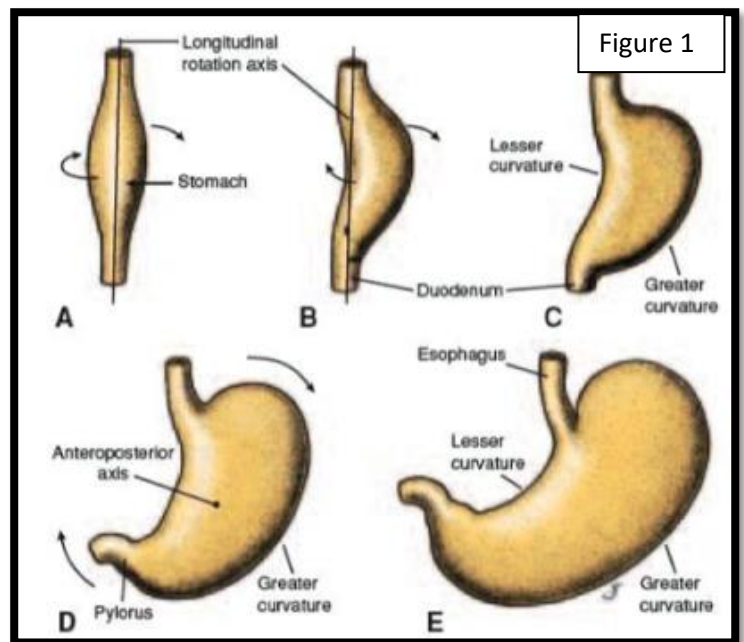


- It works through improving lower esophageal sphincter function; **Increasing LES tone, Elongates LES by 3 Cm, Returning LES into abdominal cavity.**
- Post-op complications:
 - i. Gas-bloating syndrome (Inability to vomit)
 - ii. Strictures
 - iii. Dysphagia.
 - iv. Spleen injury requiring splenectomy.
 - v. Esophageal perforation.
 - vi. Pneumothorax.
- 2. **Belsey Mark IV:** 240 to 270 fundoplication through thoracic approach.
- 3. **Hill:** Arcuate ligament repair (close large esophageal hiatus) + gastropexy (suture stomach to diaphragm).
- 4. **Toupet:** laparoscopic Incomplete Wrap (200)

The stomach

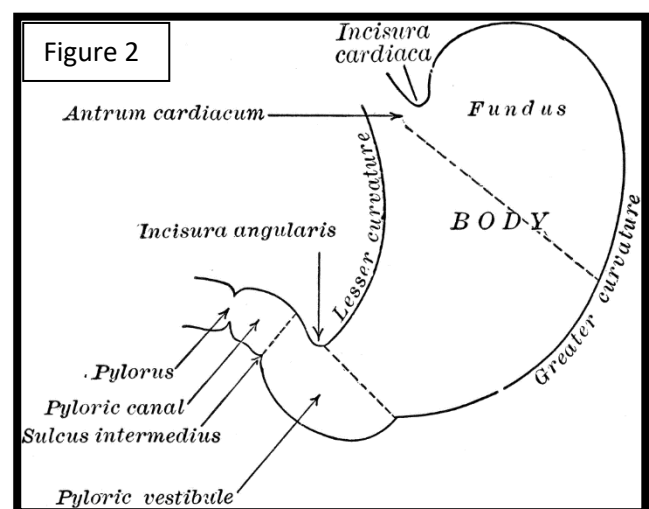
✦ **Embryology:** the stomach starts to grow as a part of the foregut, it grows like a cylinder, that has ventral and dorsal part. (figure 1)

- This cylinder is suspended to the body wall by the ventral embryonic mesentery and the dorsal embryonic mesentery.
- A fusiform dilation grows out of this tube, forming the stomach.
- The dorsal part grows more rapidly than the ventral part, forming the greater curvature.
- Meanwhile, the stomach rotates 90° clockwise, so the dorsal part becomes to the left, forming the greater curvature. and the ventral part becomes at the right side, forming the greater curvature.



✦ **Anatomy:** The stomach starts at the end of the LES, and ends at the pyloric sphincter: (figure 2)

- The main anatomical parts of the stomach are: the cardia, fundus, body, antrum, and pylorus.
- The left border of the stomach is called the greater curvature, and it's attached to the greater omentum. The right border of the stomach is called the lesser curvature and it's attached to the lesser omentum.



- The stomach and lesser omentum separate the abdomen into two sacks; the greater sac (most of the abdominal cavity, anterior to the stomach), and the lesser sac (behind the stomach).
- The only connection between these sacs is the foramen of Winslow.

⚡ **Blood supply:** All parts of the stomach are supplied by the branches of the celiac trunk. (figure 3)

- The celiac trunk gives 3 major arteries; left gastric, splenic and common hepatic.
- The **left gastric artery** supplies the lesser curvature (it gives also a branch to the esophagus).
- The splenic artery runs in a tortuous way behind the stomach, at the upper border of the pancreas, and before reaching the spleen, it gives one large artery, namely: the **left gastroepiploic artery**, to the greater curvature. Moreover, the spleen itself supplies the stomach from the terminal branches of the splenic artery with **the short gastric arteries** to the fundus of the stomach.
- The common hepatic artery gives two arteries before becoming the hepatic artery proper, these arteries are the **right gastric artery** (to the lesser curvature) and the gastroduodenal artery, respectively. The gastroduodenal artery descends posteromedial to the second part of the duodenum and terminates as **right gastroepiploic artery** (to the greater curvature) and the superior pancreaticoduodenal arteries.
- To sum up: blood supply to the greater curvature is from the right and left gastroepiploic arteries, and the blood supply to the lesser curvature is from the right and left gastric arteries.
- **Venous drainage** of the stomach:
 - Right and left gastric veins → Directly to the portal vein.
 - Left gastroepiploic vein → splenic vein.
 - Right gastroepiploic vein → SMV.

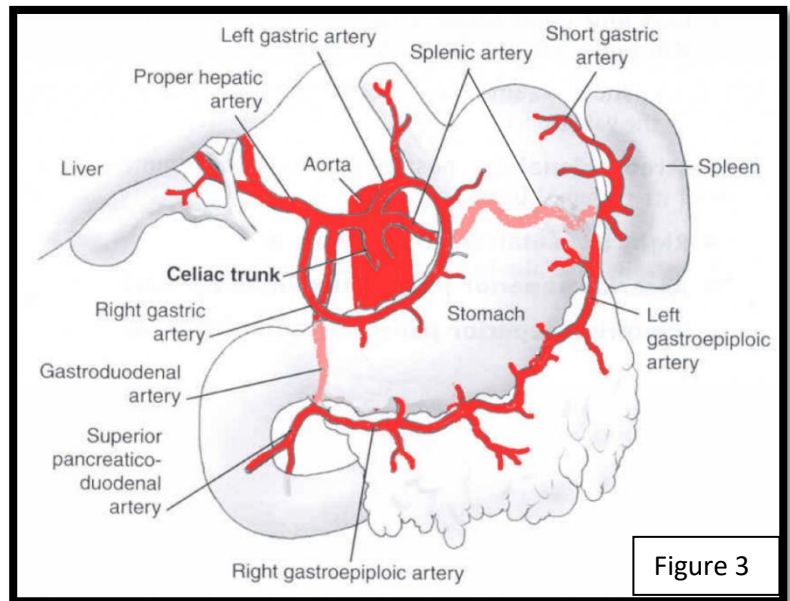


Figure 3

❖ Innervation

- Anterior gastric wall → left vagus nerve.
- Posterior gastric wall → right vagus nerve.
- Gastroduodenal pain is sensed via sympathetic afferents from T5 to T10

❖ **Physiology:** The major secretory cells of the stomach are Parietal cells, chief cells, mucus cells(found in the fundus, produces HCO_3^{2-} and mucus) and G-Cells (figure 4).

- Main factors that increase gastric acid secretion are gastrin, Acetylcholine and histamine.
- Somatostatin and prostaglandins decrease gastric acid secretion (figure 5).

Figure 4

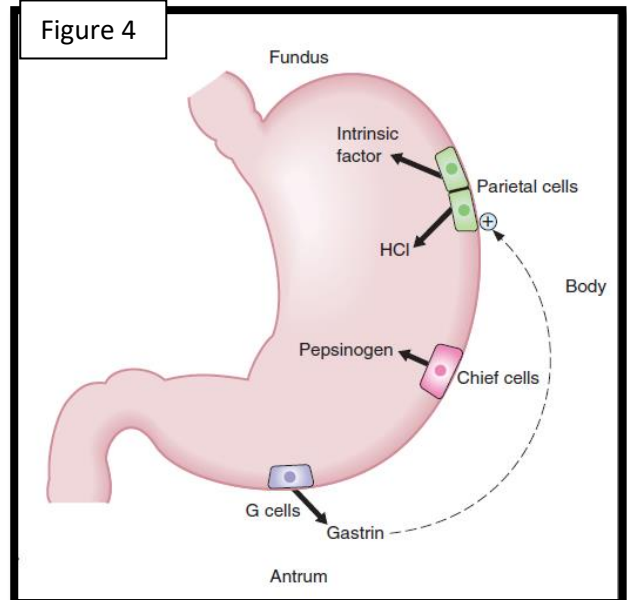
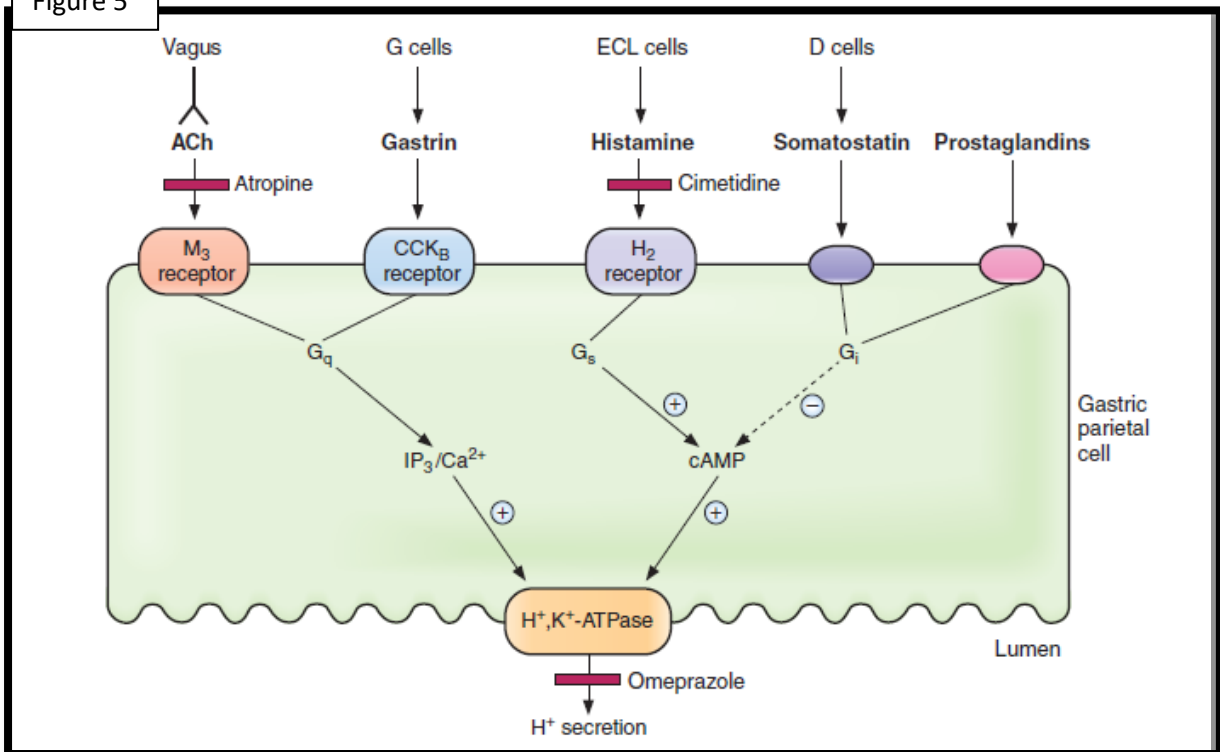


Figure 5



◆ Main signs and symptoms:

1. **Epigastric discomfort (dyspepsia):** Non-specific term that refers to recurrent upper abdominal pain or discomfort, it includes: epigastric fullness, burning, belching, bloating and heart burn.
 - It could be exacerbated or reduced by food, relieved by medications, or continuous.
2. Other serious or (ALARM Signs):
 - Anemia
 - Loss of weight
 - Anorexia
 - Recent onset of progressive symptoms.
 - Melena/Hematemesis.
 - Swallowing difficulty

◆ Main Investigations:

1. **Flexible upper endoscopy (FUE):** is the 'gold standard' investigation of the upper gastrointestinal tract.
2. **Barium Contrast studied** could be used, but these studies are less sensitive than FUE.
3. **Endoscopic/ laparoscopic Ultrasound.**
4. **CT, MRI, PET scan and laparoscopy** → for assessment of gastric CA.

Peptic ulcer disease



INTRODUCTION

◆ **Definition:** Peptic ulcer disease represents a spectrum of diseases characterized by ulceration of the stomach or proximal duodenum due to imbalance between acid secretion & mucosal defense mechanisms.

◆ **Epidemiology:** It's a very common disease.

- But the incidence is decreasing due to: discovery and eradication of H. pylori, better medical treatment, improvement in the quality of life, more sanitation and more precautions in the use of NSAIDs and aspirin.

⚡ Classification:

- **Duodenal:** at the antral-pyloric junction (more common).
- **Gastric:** (less, common, has 5 categories):

Type I → lesser curvature (near incisura angularis), it's associated with decreased mucosal production.

Type II → lesser curvature + duodenal, it's associated with increased acid production.

Type III → Prepyloric, it's associated with increased acid production.

Type IV → proximal stomach/ cardia, it's associated with decreased mucosal production.

Type V → anywhere in the stomach, it's medication induced.

? ETIOLOGY

1. **Helicobacter pylori** (the most common cause)
 - It causes both duodenal ulcers (90%) and Gastric ulcers (70-80%)
 - The infection causes chronic antral gastritis, and ulceration.
 - If eradicated, it has A very low reoccurrence rate.
2. **NSAIDs** (2nd most common cause)
 - It causes both duodenal ulcers (8%) and Gastric ulcers (40%).
 - It occurs due to decreased PGs production, so it's dose dependent.
 - IF NSAIDs are discontinued, it doesn't reoccur.
3. **Acid hypersecretion**
 - Associated with duodenal ulcers.
 - EX: Zollinger Ellison syndrome
4. **Smoking**

⚡ PATHOPHYSIOLOGY

⚡ PUD occurs when there is loss of the protective mucous barrier (of mucus and HCO_3^-) and/or excessive secretion of H^+ and pepsin.

- Protective factors are mucus, HCO_3^- , prostaglandins (that increases mucous production), mucosal blood flow, and growth factors.
- Damaging factors are H^+ , pepsin, Helicobacter pylori (H. pylori), nonsteroidal anti-inflammatory drugs (NSAIDs), stress, smoking, and alcohol.



CLINICAL FEATURES

◆ Signs and Symptoms:

- Usually asymptomatic.
- If symptomatic: it presents with **burning/Gnawing intermittent epigastric discomfort** that either relieved by food (duodenal ulcer) or exacerbated by food (peptic ulcer).
- It may present also with nausea, vomiting, Weight loss, upper GI bleeding or the complications.
- **ALARM** Symptoms may indicate malignancy.

◆ Complications:

- Bleeding.
- Perforation.
- Obstruction.



DIAGNOSIS

◆ History

◆ **Investigations: Flexible upper endoscopy** to confirm the diagnoses, once the diagnosis is confirmed, we have to look for the cause:

1. H. Pylori infection tests:

- Non-invasive: Serological antibody tests, Urea breath test, Fecal antigen test.
- Invasive: Biopsy (gold standard) → to rule out malignancy, Culture + Urase test.

2. Fasting serum Gastrin levels: to rule out ZES

- If there's no history of NSAIDs, with -ve h. pylori test.
- If a patient is experiencing recurrent ulcers despite medical treatment.
- If a patient has multiple ulcers or ulcers in unusual sites.

3. Endoscopic biopsy to rule out Gastric Ulcer.



TREATMENT

◆ Medical:

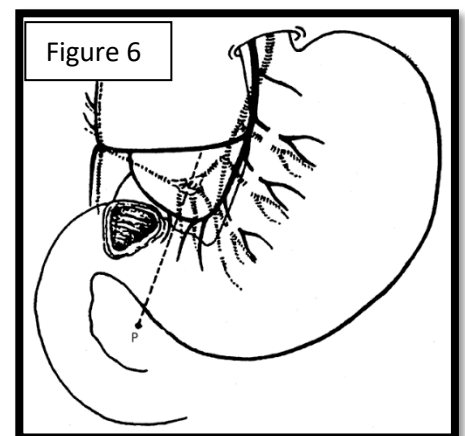
- **H. pylori eradication:** Triple therapy (1 PPI + 2 antibiotics), for 10-14 days
- NSAIDs -associated PUD → **Stop the drug**, then initiate anti-secretory Treatment.
- **Smoking cessation.**
- Follow up with endoscopy

◆ Surgical:

- Rarely done nowadays, unless PUD is complicated.
- Principles of Surgical treatment:
 1. In treating PUD, we are trying to reduce Gastric acid secretion by cutting the Parasympathetic stimulation (vagus nerve) through surgical vagotomy. Nowadays, the role of surgical vagotomy has decreased as we discovered a way to perform pharmacological vagotomy (PPI or H₂ blockers).
 2. In Vagotomy, the higher level you cut the vagus nerve, the more you paralyze the stomach (especially the antrum) and delay gastric emptying. So in Truncal Vagotomy, it's mandatory to perform a drainage procedure; pyloroplasty, antrectomy, or gastrojejunostomy.
- Surgical options for PUD:
 1. **Highly selective Vagotomy** (figure 6): transection of the vagal fibers to the body of the stomach without interruption of fibers to the pylorus.
 - Advantages: We don't remove any part of the stomach, We don't interfere with the process of emptying (no need for drainage procedure)
 - Disadvantages: high recurrence rate (15%) after 10 years.

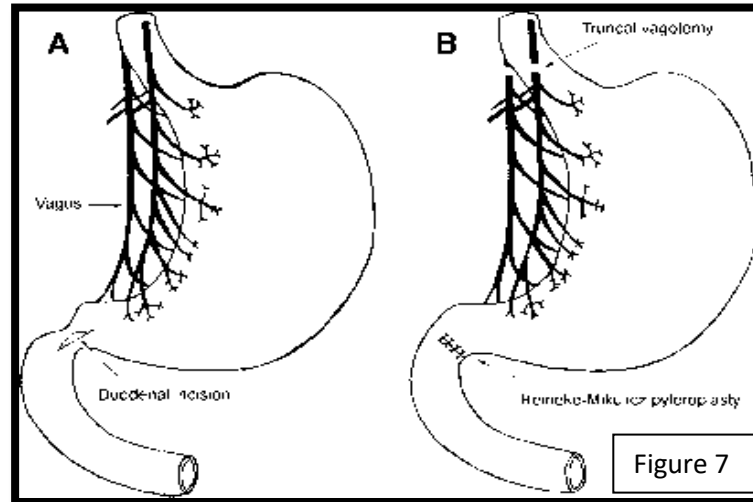
➤ Indications For surgery:

1. Non-healing ulcers.
2. Perforated Ulcers.
3. Bleeding Ulcers.
4. Gastric outlet obstruction.
5. Malignant Ulcers.

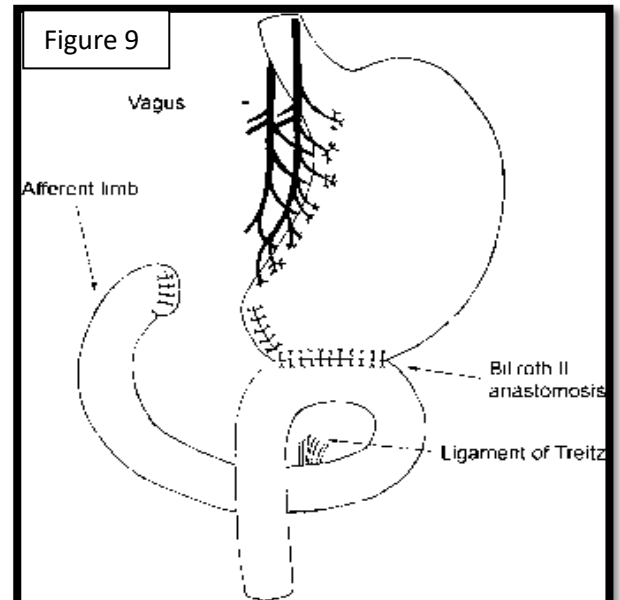
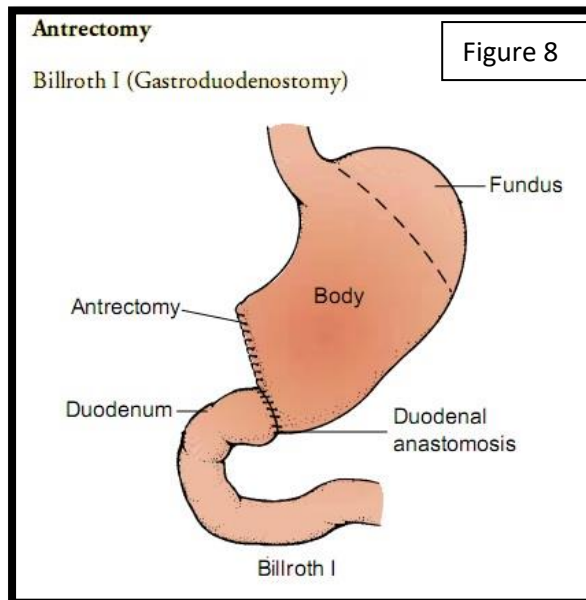


2. **Selective Vagotomy:** here We cut the nerve supply to the whole stomach, except the hepatobiliary and celiac branches.
3. **Truncal vagotomy:** The vagus in nerve is cut, It's mandatory here to perform a drainage procedure.

a) **Truncal vagotomy with pyloroplasty (figure 7):**



- b) **Truncal Vagotomy with antrectomy, and anastomosis:** transection of the vagus nerve trunk, then the distal 40% of the stomach is removed and anastomosed with the duodenum (Billroth I anastomosis- Figure 8) or Jejunum (Billroth II anastomosis- figure 9).



Complicated Peptic ulcer disease

1. Bleeding PUD



INTRODUCTION

✦ It's the leading cause of death due to PUD.

- Mortality rate is 5-10%
- The most common cause of UGI bleeding.

✦ The most common site of bleeding duodenal ulcer is the posterior wall, typically eroding the gastroduodenal artery.

✦ Signs and symptoms:

- 1- Fresh or coffee-ground hematemesis.
- 2- Melena.



TREATMENT

✦ Aggressive resuscitation & correction of any coagulopathy.

✦ Then we do endoscopy:

- We may need electrocautery or epinephrine.
- Spontaneous cessation is seen in 70% of cases.
- Findings indicating high risk of bleeding:
 - Large sized ulcer.
 - Visible vessels on a non-bleeding ulcer.
 - Visible clots.

✦ Surgical intervention if medical treatment is failed.

2. Perforated PUD

✦ Most commonly seen in the anterior duodenal wall.



DIAGNOSIS

⚡ History:

1. Sudden onset of severe abdominal pain (less dramatic in elderly/hospitalized and immunocompromised)
2. Peritonism (Fever/tachycardia and guarding).

⚡ investigations:

1. CBC → leukocytosis
2. Abdominal/chest X-ray → air under diaphragm.



TREATMENT

⚡ Stabilize the patient: Aggressive fluid resuscitation, analgesia, broad spectrum antibiotics.

⚡ Then we send the patient to the operation room, to do:

1. Graham patch.
2. Graham patch + HSV
3. Graham patch + truncal vagotomy + drainage procedure.

3. Gastric outlet obstruction



INTRODUCTION

⚡ It occurs due to:

1. Healing of a circumferential ulcer & fibrosis by scar tissue.
2. Edema & spasm
3. Antral tumors.



DIAGNOSIS

1. **History:**

- Recurrent vomiting of poorly digested food.
- Dehydration.
- Hypochloremic hypokalemic metabolic alkalosis.

2. **Physical examination:**

- Dilated full stomach.
- Visible peristaltic waves.

- +ve succession splash.

3. **NG tube** will expel a muddy fluid in large quantities



TREATMENT

✦ Stabilize the patient → insert NG tube, start IV hydration, Electrolytes correction and anti-secretory medications.

✦ When the patient is stable → Do endoscopy (to rule out CA_

✦ If the cause is scarring, it's usually refractory to medical treatment → surgical treatment.

4. Non-healing PUD:

- Rule out Cancer.
- Look for persistent H. pylori.
- Non-compliant patient.
- Use of NSAIDs.
- Motility disorder.
- ZES.

Gastric Cancer



INTRODUCTION

✦ **Types:**

- **Adenocarcinoma:** The most common type (95%), it's the type that will be discussed in this section, other types will be explained briefly later.
- **GIST**
- **Lymphoma.**
- **Carcinoid.** (Very rare)

✦ **Epidemiology:**

- It has a low incidence worldwide (10/100000 in USA), but very high incidence in Japan (78/100000).
- Incidence decreased dramatically due to the eradication of H. pylori.
- It's the disease of elderly (>60 years).

✦ **Subtypes of Gastric Adenocarcinoma:**

1. **Diffuse type:** (70%)

- Arise from lamina propria (no glands).
- More common in proximal parts of the stomach (Especially the Cardia), but could be found anywhere in the stomach.
- Associated with invasive growth pattern with rapid submucosal spread → if the entire stomach is involved, this results in thickening of the stomach “**Linitis plastica**”.
- Less association with the known risk factors.
- Occurs in younger age group.
- Worse prognosis than intestinal type.
- Metastasis are more common in this type, especially by invasion and seeding.

2. **Intestinal type:** (30%)

- Arise from gastric mucosa.
- In distal parts of the stomach.
- Associated with H. Pylori & other environmental risk factors.
- Well-Formed glandular structure.
- Spreads by lymphatics.

? **ETIOLOGY**

⚡ **Dietary risk factors:**

- Smoked meat.
- High nitrates contents.
- Low fruits and vegetables.
- Smoking.

⚡ **Demographic risk factors:**

- Male gender.
- Low socioeconomic state.
- Black race.
- Blood Group type A.
- Family history.

⚡ **Medical risk factors:**

- H. pylori infection.
- Atrophic gastritis.
- Previous partial gastrectomy.
- Ménétrier's disease.
- P53 mutation is found in 50% of cases

PATHOPHYSIOLOGY

⚡ As any other cancer, Carcinogenesis is a multi-step process, with increased rate of mutations with the persistence of the risk factors, this is mostly true in the case of intestinal type Gastric Adenocarcinoma:

- H. pylori infection → Chronic gastritis → intestinal metaplasia → Dysplasia → Carcinoma in situ → intestinal type Gastric Adenocarcinoma.
- It's important to mention that peptic ulcers don't transform into Gastric CA, but it's thought that Gastric CA present itself as an ulcer.
- Cancers are more common in the lesser curvature.

CLINICAL FEATURES

⚡ **Symptoms:** Gastric CA generally has non-specific signs & symptoms, so most of the patients present at late stage, remember the acronym "WEAPON":

- **W**ight loss (the most common presentation).
- **E**arly satiety/ **E**mesis.
- **A**norexia.
- **P**ain (epigastric discomfort) → Most common early symptom.
- **O**bstuction → seen in distal lesions, while in proximal ones, **dysphagia** could be seen.
- **N**ausea.

⚡ **Signs:**

- Signs of anemia, and chronic blood loss (Coffee-ground hematemesis, melena, heme-occult)
- Epigastric mass. (in advanced cases).

⚡ **Signs of distant metastases:**

- **Virchow's node:** enlarged supraclavicular lymph node.
- **Sister Mary Joseph's node:** infiltration of the Umbilicus.
- **Blumer's shelf:** fullness in the pelvic Cul-De-Sac (solid peritoneal deposit anterior to the rectum, forming a shelf palpated on PR).
- **Krukneberg's tumor:** enlarged ovaries on pelvic exam (metastases to the ovaries).
- **Hepatosplenomegaly** with ascites and jaundice.

- **Irish's node:** left axillary lymphadenopathy.
- **Cachexia**



DIAGNOSIS

⚡ **Screening:** endoscopy or contrast studies are only recommended in high risk groups:

- More than 20 years post-Gastrectomy.
- Patients with pernicious anemia or atrophic Gastritis.
- Endemic areas.

⚡ **Investigations:**

1. **Flexible upper endoscopy + Biopsy:**
 - It's the investigation of choice.
 - Take at least 7 biopsies from the edges of the ulcer.
2. ~~Double contrast barium enema~~ → not used anymore.

⚡ **Staging:** (TNM)

1. **Endoscopic Ultrasound:**
 - Used for T staging → Can't detect T1 & T3.
 - For N staging → regional lymph nodes.
 - Can't differentiate the tumor cells from fibrosis after neoadjuvant chemotherapy.
2. **CT-Scan**
 - It's complimentary to EUS in T staging.
 - Can't differentiate between T1 and T2.
 - Used also for Distant metastasis and lymph nodes.
 - Can't detect small metastasis (<5 cm).
 - Can't tell if an enlarged lymph node is involved or not → Use **PET** scan.
3. **Chest X-ray and LFT.**
4. **Laparoscopy** → To detect peritoneal implants → send peritoneal fluid for cytology → if +ve → it's stage IV .

⚡Staging:

⚡T staging:	⚡N staging:	⚡M staging:
<ul style="list-style-type: none"> ➤ T1→mucosa/submucos ➤ T2→Muscularis propria ➤ T3→Subserosa ➤ T4→ Whole wall invasion 	<ul style="list-style-type: none"> ➤ Nx→Couldn't be determined. ➤ N0→No lymph nodes ➤ N1→1-6 ➤ N2→7-15 ➤ N3→ >15 	<p>M1→ if there's metastases or peritoneal implants.</p>

- If T1/T2 → stage 1 → early stage
- If T3/T4→ stage 2 or 3 →late stage
- If there's distant metastases (M1) → it's stage 4

TREATMENT

⚡In early stages (stage 1) → we go for curative surgery.

⚡In late stages (stage 2 or 3) → we give neoadjuvant chemotherapy to down stage the tumor → then we go for curative surgery ± Adjuvant chemo or radio therapy.

⚡If the patient is in stage 4, or in stage but unfit for surgery→ we go for palliative therapy.

⚡ The curative surgery for gastric CA has two goals:

- Resect the tumor** with clear margins (at least 5cm):
 - If the tumor was proximal or midbody → Do total Gastrectomy.
 - If the tumor was distal → Do subtotal Gastrectomy.
 - Then re-anastomose the stomach; either by Billroth II (not I) or Roux-en-y anastomosis (see bariatric surgery section).
 - In cases of total gastrectomy, Roux-en-y limb is sewed to the esophagus.
 - Splenectomy is done if the tumor directly invades the spleen/splenic hilum/ or there's splenic hilar adenopathy.
- Lymph nodes dissection:** Usually D1 and D2 only
 - D1 → perigastric lymph nodes.
 - D2 → splenic artery LN/ Hepatic artery LN/ Left Gastric LN/Anterior mesocolonic LN/ Anterior pancreatic LN/ Crural LN.
 - D3 → Paraaortic

⚡ **Prognosis:** 25% of patients are alive 5 years in USA, while in Japan, 50% of people are alive after 5 years.

5. **MRI, PET scan and laparoscopy** → for assessment of gastric CA.

Other types of Gastric CA

1. Gastrointestinal stromal tumors (GIST)

INTRODUCTION

⚡ Gastrointestinal stromal tumors (GIST), previously known as leiomyosarcomas are rare GI tumors arising from mesenchymal component (interstitial cells of Cajal), these are only 3% of gastric tumors.

⚡ sites: GI tract, from esophagus to rectum:

- Most common site → The stomach (60%)
- The second most common sites → the small intestine (30%)
- Rectum (3%)
- Colon (2%)
- Esophagus (1%)

⚡ More common in males, >60 years.

⚡ Usually C-KIT (CD 117) +ve

- So it's the tumor marker for GIST.
- It's a target for chemotherapy.

DIAGNOSIS

⚡ **Signs and symptoms:**

- Vague abdominal pain.
- Abdominal mass.
- Nausea.
- Abdominal distention.

⚡ **Investigations:**

- Endoscopy + FNA biopsy.

⚡ **Staging:**

- CT abdomen/ pelvis.

- Chest x-ray.
- PET scan.



TREATMENT

✦ Treatment is surgical:

- Laparoscopic resection with 2cm -ve margins.
- No need for lymph node resection.
- Post-operative adjuvant chemotherapy by C-KIT inhibitor (imatinib).

2. GI lymphoma



INTRODUCTION

✦ Lymphomas are either **Hodgkin** or **non- Hodgkin**.

- Non- Hodgkin lymphomas are either **nodal** (from lymph nodes), 70%, or **extranodal** (30%).
- The most common site of Extranodal lymphoma is the GI tract (50%) of cases.

✦ **Characteristics of primary GI lymphomas:**

- No lymphadenopathy.
- Normal bone marrow.
- Normal blood smear.
- The disease is confined to a certain affected viscus.
- Absence of hepatic or splenic involvement unless direct extension of primary tumor.

✦ **Types of GI lymphoma:**

1. **Diffuse large B-Cell lymphoma:**

- Most common.
- Seen in the stomach, Ileocecum.
- BCL-2, BCL-6.

2. **MALToma:**

- Associated with H. pylori.
- Multifocal, distal, lymphoepithelial lesions.
- It has the best prognosis.

3. **Burkitt's lymphoma:**

- Younger patients.
- Aggressive.

- Involves the cardia, body and the terminal ileum.
- EBV infection is a risk factor.
- Starry sky appearance on LM.

4. Mantle Cell lymphoma:

- Polyposis in small bowel.
- Tends to compress rather than infiltrate.

5. Enteropathy T-Cell lymphoma:

- Celiac disease is a risk factor.
- Jejunum & ileum.
- Circumferential ulceration.
- Eosinophilic in histology.



CLINICAL FEATURES

◆ Gastric lymphomas:

- The stomach is the most common site of GI lymphoma.
- Most common site → distal stomach.
- Associated with H. Pylori infection.
- HIV infection is also a risk factor.
- Most common type → diffuse large B- Cell lymphoma.
- Symptoms are similar to Gastric adenocarcinoma.

◆ Small intestinal lymphoma:

- Second most common site.
- Bimodal age distribution.
- Presentation depends on the site, and may present as intestinal obstruction.
- Will be discussed later.



DIAGNOSIS

◆ **Endoscopy with biopsy** ± H. pylori test If MALToma.

◆ Staging:

- CT chest/ abdomen/ pelvis.
- Bone marrow biopsy.
- Biopsy of enlarged peripheral lymph nodes.

◆ Stages:

- **WHO classification:** low grade Vs High Grade.
- **TNM:** not useful, but could be used for some types of Gastric lymphoma.



TREATMENT

⌘ Treatment of gastric lymphoma is usually conservative:

- Low grade MALToma → H. pylori eradication.
- High grade MALToma → Chemotherapy/radiotherapy.
- Non- MALToma (Diffuse large B-Cell lymphoma, Burkitt's, etc ..) → Chemotherapy/radiotherapy.
- Indications for surgery: (1) failure of Chemotherapy, (2) emergency cases.

⌘ Treatment of intestinal lymphoma is surgical.

Obesity & bariatric surgery

INTRODUCTION

✦ Obesity is the 2nd most common cause of preventable death.

➤ It's a disease with many comorbidities.

✦ A **Comorbidity**: a condition that resolves with the treatment of the disease.

✦ Comorbidities that are associated with obesity:

➤ **Respiratory:**

1. Obstructive sleep apnea (OSA): is the most common comorbidity of the obesity, 70%-85% of cases can be cured with bariatric surgery.

➤ **GI:** GERD, Constipation colon CA.

➤ **CVS:** Hypertension, Diabetes mellitus, Heart failure, hyperlipidemia.

➤ **MSS:** osteoarthritis, Disc prolapse.

➤ **Urogenital:** PCOS, Urge/stress incontinence.

➤ **CNS:** pseudotumor cerebri, depression.

➤ **Reduction in all vital capacities.**

✦ Body mass index (BMI) (**figure 10**) is a good method for obesity staging, thus deciding the best method to lose weight. It equals body **mass (kg)/tall(M)²**

BMI (kgm ⁻²)	Definition
<18.5	Underweight
18.5-24.9	Ideal Weight
25-29.9	Overweight
30-39.9	Obese
40-49.9 or 35-49.9 with obesity-related comorbidity	Morbidly Obese
50-59.9	Super Obese
60-69.9	Super Super Obese
>70	Hyper Obese

Figure 10



TREATMENT

⚡ Methods of weight loss:

1- **conservative**: lifestyle modification.

- Once a patient reaches morbid obesity, the medical (conservative) failure rate is 100%.
- Bariatric surgery is the most effective, sustainable, method of weight loss, with a failure rate of 10%

2- **Surgical**, indications for bariatric surgery:

- Morbid obesity (BMI>40)
- Severe obesity (BMI>35) + comorbidities.
- Severe comorbidities.
- Social and psychological implications.

⚡ Types of bariatric surgeries:

- **Restrictive**: decreases the size of the stomach, ex: VBGT, LAGB. LSG.
- **Malabsorptive**: it's better to be called maldigestive, in these surgeries, we are diverting the food away from the duodenum → poor digestion → poor absorption, such surgeries are not done anymore nowadays.
- **Combined**: FOBI, BPD DS.

⚡ Bariatric surgery success rate is rate according to Excess weight loss (EWL), failure of surgery is if EWS <25%.

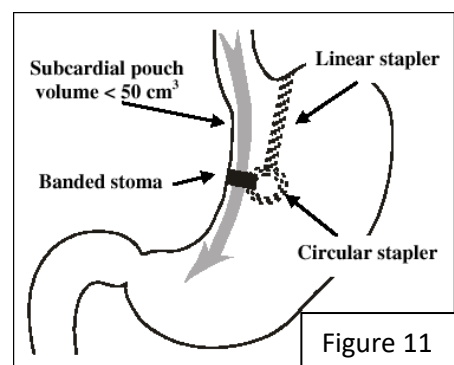
⚡ Points to be asked for surgical candidate:

- Sweet eater/salt eater.
- Family history.
- Maximum weight reached.
- Minimum weight reached.
- Trails of conservative treatment? Diet? Exercise?
- Symptoms of comorbidities.
- Motivation?

A. Restrictive surgery:

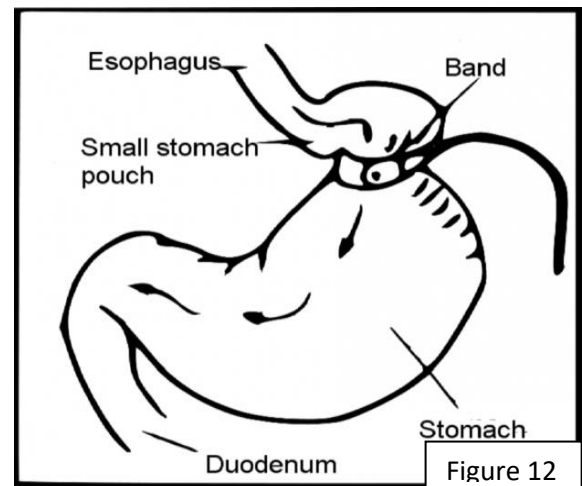
1- **Vertical Banded GasroPlasty (VBGP)** (figure 11)

- Not Used anymore.
- High failure rate (Dehiscence + Dilation of the gastric pouch)



2- Laparoscopic adjustable gastric band (LAGB) (figure 12)

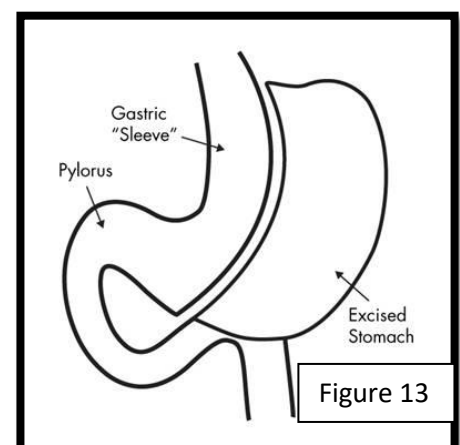
- Laparoscopic procedure, done by placing a silicone band with an inflatable balloon around the proximal part of the stomach, at the angle of His, connected to a port attached to the abdominal wall.
- It's **reversible** (no resection of the stomach) and **adjustable** (inflate the balloon to lose more weight, deflate the balloon to gain weight)



Advantages	Disadvantages
<ul style="list-style-type: none"> ➤ No resection of the stomach, less dangerous (no leak, peritonitis) ➤ Good for solid eaters, because they need time to pass the food. ➤ Reversible, adjustable. ➤ Can be used for borderline BMI. ➤ Few short-term complications. 	<ul style="list-style-type: none"> ➤ Not good for sweet eaters (sweet dissolves) ➤ Band may erode through the wall. ➤ Band slippage → it's an emergency. ➤ Port may reposition (should be fixed to the fascia of the abdominal wall). ➤ Side effects: reflux, regurgitation, Vomiting, esophageal dysmotility. ➤ The least effective In terms of EWL (50-60%) ➤ Relative CO in BMI >50 ➤ CO in hernia and reflux.

3- Laparoscopic Sleeve Gastrectomy (figure 13)

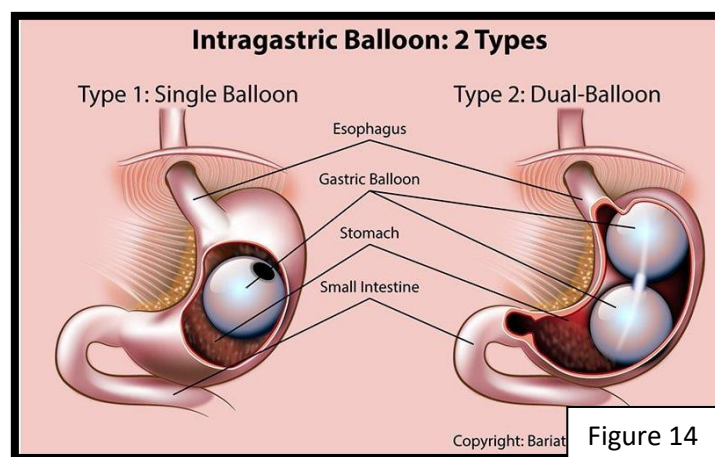
- 85% of the stomach is resected, from the pylorus to the angle of His along the greater curvature.
- By cutting the stomach, the size that's available for food is reduced, moreover, the Ghrelin hormone secretion is decreases → Less hunger.



Advantages	Disadvantages
<ul style="list-style-type: none"> ➤ Good EWL (80%) ➤ A re-sleeve procedure can be done or a bypass if the original surgery doesn't have satisfactory results. 	<ul style="list-style-type: none"> ➤ Not enough long term results. ➤ Morbidity is the same as the by-pass ➤ Fever is an ominous sign → could indicate leakage. ➤ Stenosis could be complication. ➤ Nutritional complications due to decreased food intake.

⚡ LSG could be used as a Bridge procedure for Biliopancreatic procedure.

- A bridge procedure can be done before the “real” surgery to lose weight & make the “real” surgery easier.
- Another bridging procedure is placing an intragastric balloon laparoscopically for very obese patients for 6 weeks preoperatively. (figure 14)



B. Combined Surgeries:

⚡ In these procedures, the stomach is converted to a small pouch (restrictive), then then the stomach is anastomosed to more distal part of the small intestine to by-pass it (malabsorptive). All these procedures have failure due to:

- Dilatation of the pouch.
- Vitamin for life.

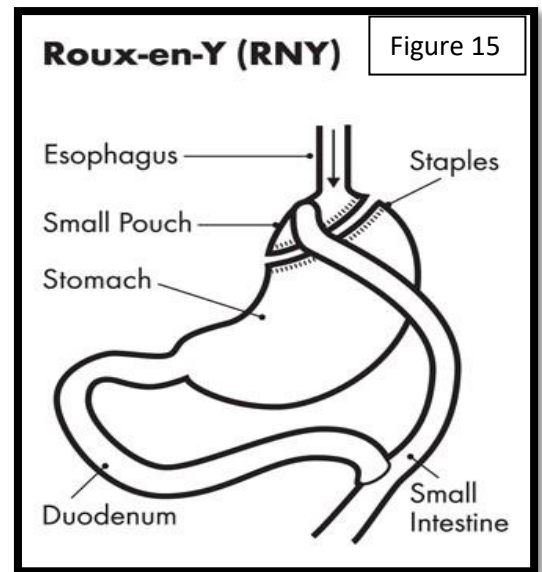
1- Roux-en-y gastric by-pass (figure 15)

⚡ It's the most popular surgery in U.S.A

⚡ 70% success rate

✦ Procedure:

- 1) The stomach is cut into small pouch (connected to the esophagus).
- 2) A 75-150 cm of the small intestine (that's connected to the remainder of the stomach) is cut.
- 3) The remaining small intestine is called Roux limb, the roux limb is anastomosed with the gastric pouch.
- 4) The cut small intestine (that's connected to the stomach) is anastomosed after 75 cm of the Roux limb.



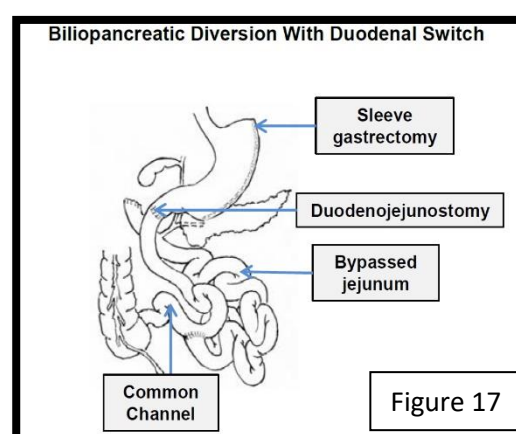
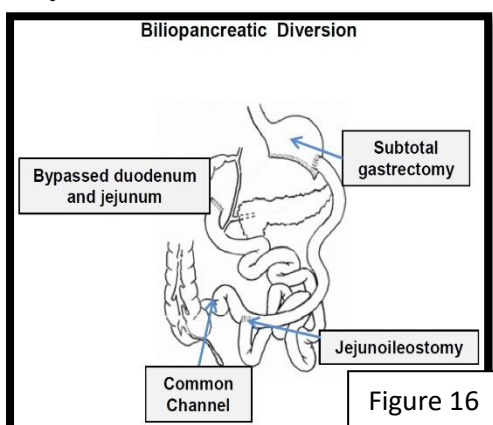
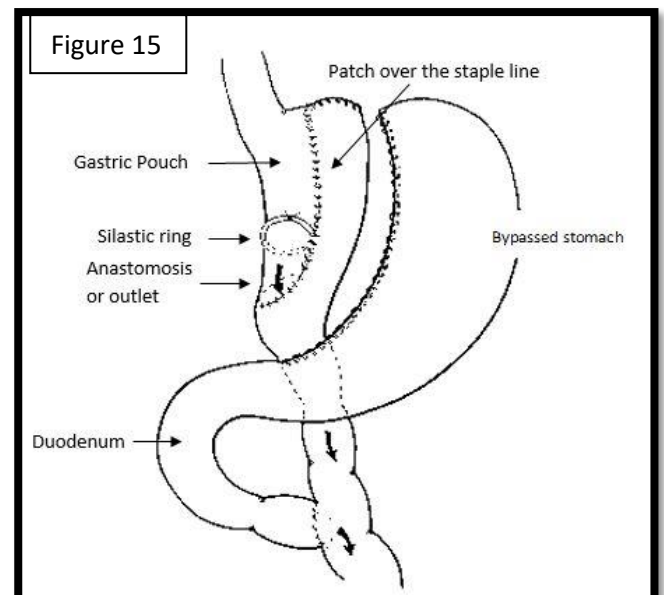
2- FOBI (banded Gastric bypass) (figure 16):

✦ FOBI Is a modification of RYGB, but rather than staples it uses silastic ring around the distal part of the pouch, to simulate pyloric valve, thus prevents stretching and dilation of the bowel under the pouch.

2- Biliopancreatic Diversion (± Duodenal switch) (BPD DS) (figures 16 and 17)

✦ It's combined, but more Malabsorptive.

✦ It has many complications (severe vitamin deficiency, anemia, dumping syndrome.. etc), Less commonly done.



Gastric syndromes

1- Post-Gastrectomy syndromes

⚡ **Dumping syndrome:**

- It occurs because the stomach “dumps” the food by fast emptying, this delivers hyperosmolar chyme to the intestine.
- Consists of postprandial vasomotor palpitation, sweating, lightheadedness.
- Types:
 - 1) Early: 30 minutes after eating.
 - 2) Late: >90 minutes after eating, due to hypoglycemia.
- Treatment: restrict sweets & lactose containing food, encourage frequent small meals.

⚡ **Blind loop syndrome:**

- Bacterial overgrowth in a loop.
- Usually seen in patients with previous gastrectomy with Billroth II anastomosis.
- Signs and symptoms of fat & vitamin B12 malabsorption.

⚡ **Afferent loop syndrome:**

- Seen in Gastrojejunostomy.
- Afferent loop is the portion that was by-passed.
- Signs & symptoms of Abdominal bloating & pain (20 minutes – 1 hour after eating), relieved by vomiting (bile stained)
- Etiology: might be due to incomplete draining afferent loop which fills with biliary & pancreatic secretions.

2- Gastroparesis in DM



INTRODUCTION

⚡ Highly variable gastric emptying patterns is seen in diabetic patients (slow, fast, or normal)

- But long-term DM tend to develop slow gastric emptying (gastroparesis).

PATHOPHYSIOLOGY

⚡ Blood glucose >200 mg/dl results in:

- 1) Decreased antral mortality.
- 2) Delayed gastric emptying.
- 3) May have direct -ve long term effects on gastric emptying.

⚡ Conversely, gastroparesis itself increases blood glucose (due to delay of insulinemic & glycemic response).

⚡ So it's a viscous cycle, we try to cut it or at least minimize it by tight glycemic control.



DIAGNOSIS

⚡ Symptoms:

- Nausea & vomiting.
- Early satiety.
- Predisposition for bezoars.

⚡ Investigations:

- Requires ruling out obstruction first.
- Then the diagnosis is confirmed by radioisotope-labeled solid meal.



TREATMENT

⚡ Good hydration.

⚡ low fat diet.

⚡ tight control of blood glucose.

⚡ **Metoclopramide** for long term use.

⚡ Or IV **erythromycin**

- Increase gastric motility (it's motilin analogue).
- It's used in acute sittings, less useful for long term use

⚡ Causes of Gastroparesis:

- Diabetic neuropathy.
- Autoimmune dysfunction (amyloid neuropathy).
- Infiltrative process (scleroderma)
- Viral infection.
- CNS disorders (MS, stress, Parkinson, tumor, cord injury).
- Post vagotomy.
- 1/3 to 1/2 of cases are idiopathic.

Pancreas & spleen

- Written by: Nada Hajjaj
- Corrected by: Mohammad Qussay Al-Sabbagh

- pancreas: 56
 - introduction: 56
 - Congenital Anomalies Of The Pancreas: 61
 - Acute Pancreatitis: 63
 - Pancreatic pseudocyst 73
 - Chronic Pancreatitis : 77
 - Pancreatic tumors: 81
 - Whipple procedure: 88
 - History & physical: 90
- Spleen 95
 - Introduction: 95
 - Splenectomy: 98
 - Splenic trauma: 105

Pancreas

❖ Embryology: [Figure 1]

- During the 4th week of gestation, the pancreas begins to develop from the duodenal endoderm.
- Two buds form (which then rotate and fuse by the 8th week):
VENTRAL BUD (from the convex part of the duodenum) → Uncinate process and part of the head
DORSAL BUD (from the concave part of the duodenum) → Remaining part of the head, neck, body and tail.
- The ventral bud rotates with the duodenum and then migrates posteriorly to fuse with the dorsal part.
- The ventral duct (the bud's duct) will take over and open into the duodenum at the ampulla of Vater → Wirsung duct.
- The dorsal duct may persist and opens into the the duodenum at a minor opening 2 cm medial and above the ampulla of Vater, BUT it usually disappears → Santorini duct.

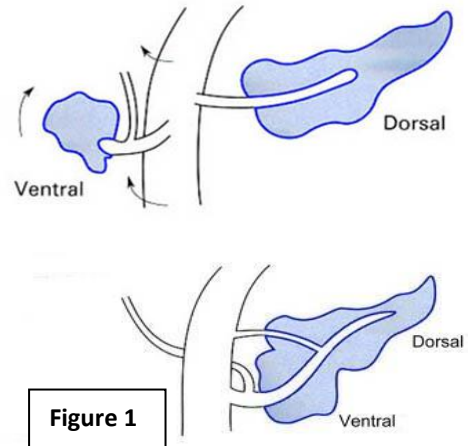


Figure 1

❖ Anatomy:

The pancreas is a J-shaped structure that weights approximately 85 g with a usual length of 12-15 cm and runs in an oblique transverse line [Figure 2].

- Site:
 Retroperitoneal structure **at the level of L1-L2**, lies posterior to the stomach, transverse mesocolon and lesser omentum and is covered anteriorly with the visceral peritoneum.

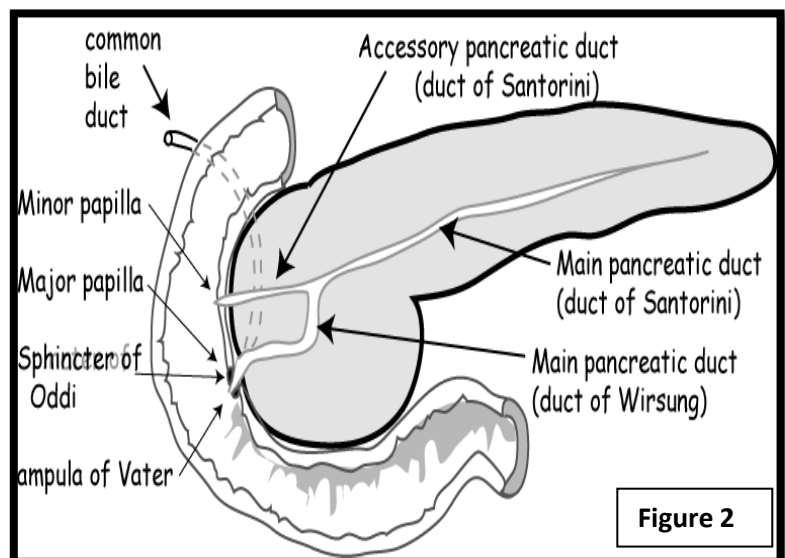


Figure 2

➤ Structures [Figure 2] and relations [Figure 3]:

1. Head
 - Bounded superiorly by the porta hepatus (bile duct, portal vein and proper hepatic artery) and by the pancreaticoduodenal artery.
 - The common bile duct runs superior then posterior and **partially within the head of the pancreas**.
2. Uncinate process
 - Small portion of it lies posteriorly to the superior mesenteric vein.
3. Neck
 - Lies over the SMV, which joins the splenic vein at the superior border of the pancreas to form the portal vein.
4. Body
 - Lies posterior to the stomach.
5. Tail
 - It has a close relation with the splenic hilum (Tickles the k2spleen).

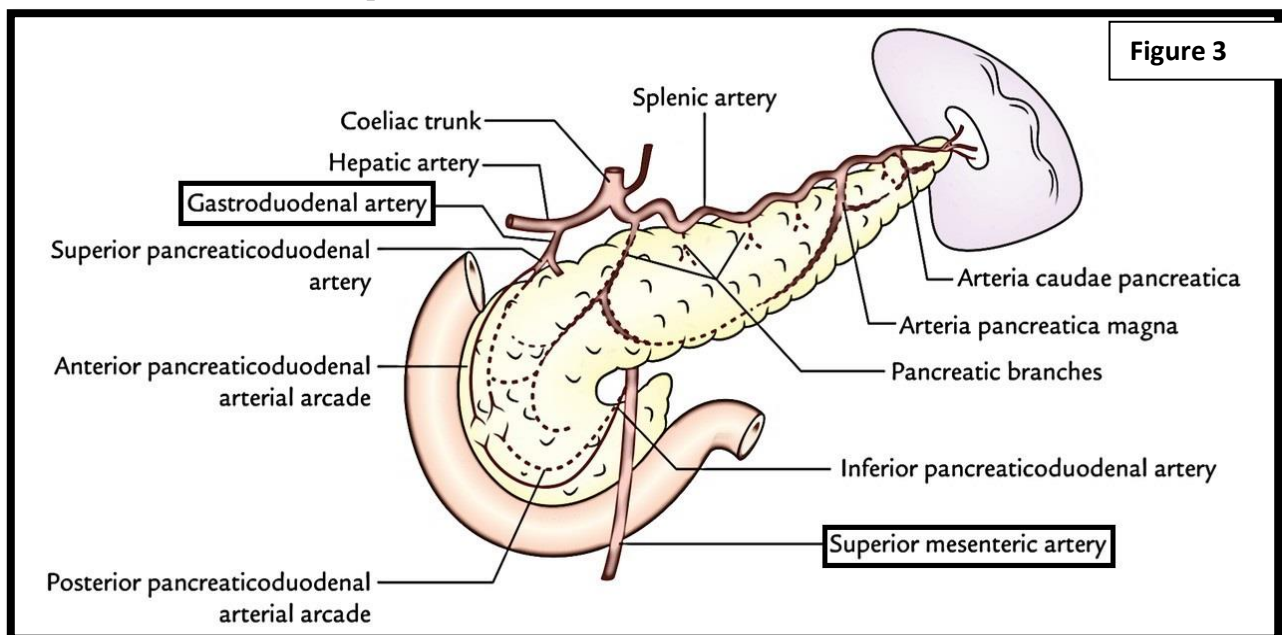


Figure 3

➤ Ducts:

1. Wirsung duct
2. Santorini duct (Small)

➤ Sphincter of oddi: smooth muscles surrounding the ampulla of Vater.

➤ Blood Supply:

Supplies the head.

- Celiac Trunk → gastroduodenal → Ant. Sup pancreaticoduodenal artery + Post. Sup. Pancreaticoduodenal artery.
- SMA → Ant. Inf. Pancreaticoduodenal artery + Post. Inf. Pancreaticoduodenal artery.

Supplies the neck, body and tail.

- Splenic artery → Dorsal pancreatic artery.

Note: The venous drainage follows the arterial supply.

Nerve Supply:

- **Sympathetic** : Pain sensation by the celiac plexus and the thoracic splanchnic nerves.
- **Parasympathetic**: for the glands (ducts) by the celiac branch of the vagus nerve.

❖ **Types of pancreatic cells: [Figure 4]**

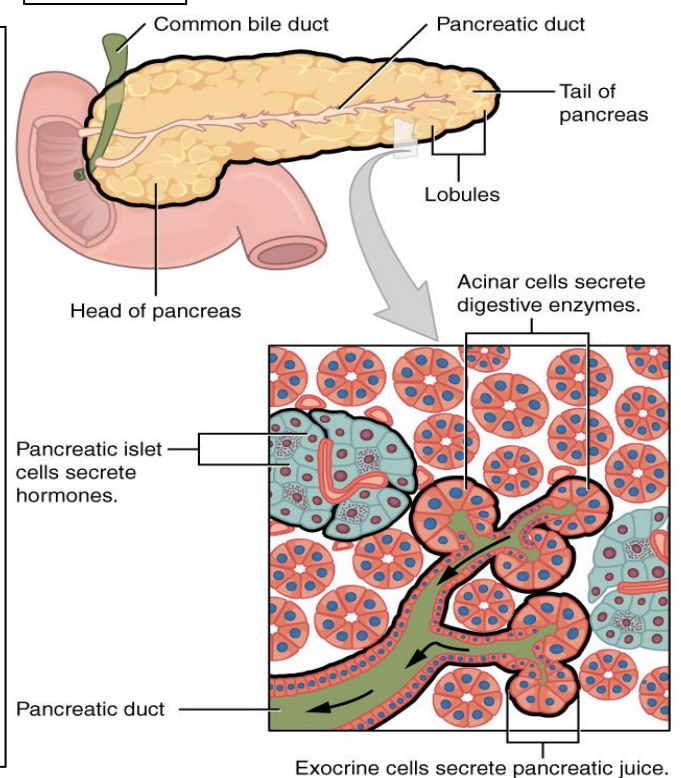
What is the pancreas made of?

The pancreas is composed of 85% exocrine tissue: which is organized into lobules. The main pancreatic duct branches into interlobular and intralobular ducts, ductules and, finally, acini. The main duct is lined by columnar epithelium, which becomes cuboidal in the ductules. Acinar cells are clumped around a central lumen, which communicates with the duct system.

And 2% endocrine tissue: which is made of Clusters of endocrine cells, known as islets of Langerhans, are distributed throughout the pancreas.

The rest is extracellular matrix and blood vessels.

Figure 4



1. **Endocrine cells** (islets of langerhans):

- α cells : Secrete glucagon which promotes the conversion of the hepatic glycogen → increases glucose level.
- β cells: Secrete Insulin which promotes glucose transport into the cells → decreases glucose level.

- D cells: secrete Somatostatin which inhibits the release of gastric hormones and gastric acid.
 - PP cells: Secrete polypeptides and vasoactive intestinal peptide (VIP).
2. **Exocrine cells** (Acinar, centroacinar and ductal cells):

- Acinar cells: Secrete enzymes {Trypsin, Chemotrypsin, Amylase, Lipase, Carboxypeptidase}.

The pancreatic enzymes (except for lipase and amylase) are secreted in an inactive form (Zymogens) until they're activated by **enterokinase** in the duodenum

- Centroacinar and ductal cells: Secrete water and electrolytes (Na^{+2} , K^{+} , HCO_3^{-} , Cl^{-}) in response to **Secretin** stimulation.

Secretin is secreted from the S cells in the duodenum; it is the most potent endogenous stimulant of bicarbonate secretion.

❖ Main Investigations:

- **Estimation of pancreatic enzymes in body fluids:** When the pancreas is damaged, enzymes such as amylase, lipase, trypsin, elastase and chymotrypsin are released into the serum.
- **Pancreatic function tests:** Pancreatic exocrine function can be assessed by directly measuring pancreatic secretion in response to a standardized stimulus.
- **Imaging investigations:**
 - **Ultrasound:** It may also define the presence or absence of a mass in the pancreas. However, obesity and overlying bowel gas often make interpretation of the pancreas itself unsatisfactory.
 - **CT scan:** A specific pancreatic protocol should be followed:
 1. An initial unenhanced CT scan is essential to determine the presence of calcification within the pancreas and gall bladder.

2. Following rapid injection of intravenous contrast, scanning is performed in the arterial and venous phases.

- **Endoscopic retrograde cholangiopancreatography (ERCP) [Figure 5]:** ERCP is performed using a side-viewing fiberoptic duodenoscope. The ampulla of Vater is intubated, and contrast is injected into the biliary and pancreatic ducts to display the anatomy radiologically.
- **Endoscopic ultrasound (EUS) [Figure 6]:** when the endoscope is in the lumen of the stomach or duodenum, the pancreas and its surrounding vasculature and lymph nodes can be assessed. This is particularly useful in identifying small tumors that may not show up well on CT or MRI.

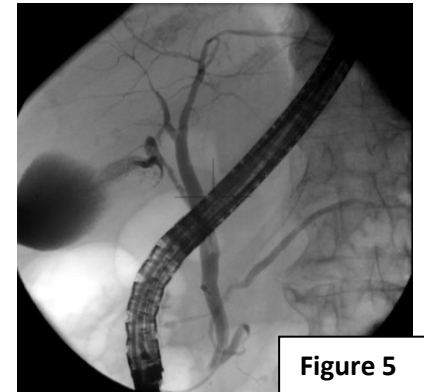
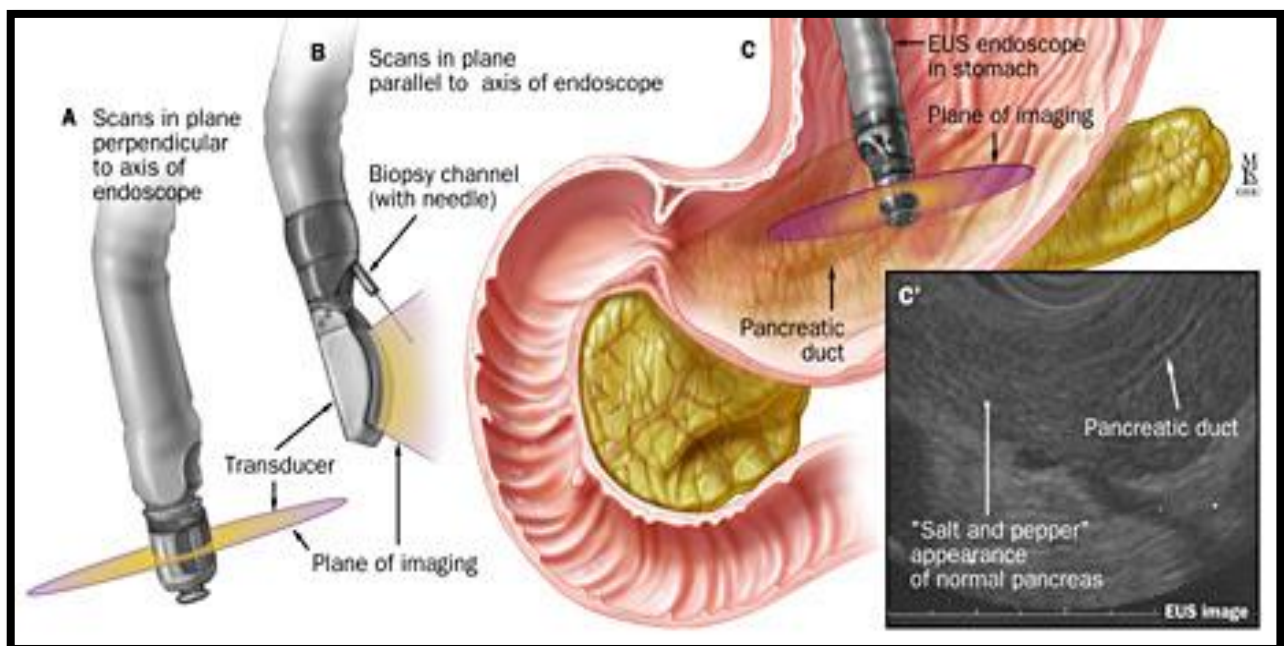


Figure 6



Congenital Anomalies Of The Pancreas

INTRODUCTION

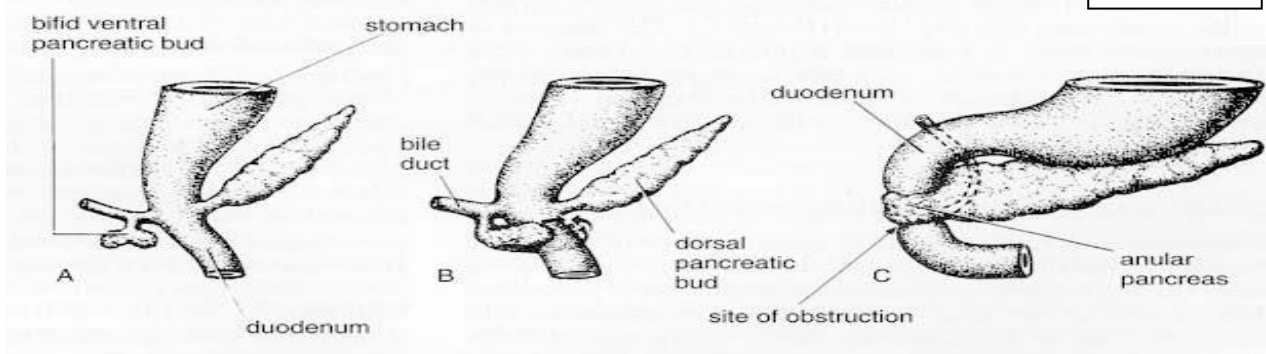
❖ Pancreatic divisum: → the most common

- Embryological failure of the two pancreatic ducts to fuse (the dorsal and ventral).
- The dorsal pancreatic duct becomes the main pancreatic duct and drains most of the pancreas through the minor or accessory papilla.

❖ Annular Pancreas: [Figure 7]

- During rotation and migration of the pancreatic tissue, some tissue may be left around the duodenum.
- Although it's congenital → 50% presents in adulthood.

Figure 7



❖ Heterotropic Pancreas:

- Islands of ectopic pancreatic tissue can be found in the submucosa in parts of the stomach, duodenum or small intestine (including Meckel's diverticulum), the gall bladder, in the hilum of the spleen and within the liver.

CLINICAL FEATURES

❖ Pancreatic divisum :

- A large volume of secretions flowing through a narrow papilla probably leads to incomplete drainage, which may then cause obstructive pain or

pancreatitis [in patients with idiopathic recurrent pancreatitis, pancreatic divisum should be excluded].

❖ **Annular Pancreas:**

- Duodenal obstruction typically causes vomiting in neonates.
- The disease may occur in later life as one of the causes of pancreatitis.



DIAGNOSIS

❖ **Pancreatic divisum :**

- ERCP and MRCP.

❖ **Annular Pancreas:**

- Abdominal ultrasound and CT scan.



TREATMENT

❖ **Pancreatic divisum :**

- Endoscopic sphincterotomy and stenting of the minor papilla may relieve the symptoms.
- Surgical intervention can take the form of sphincteroplasty, pancreatojejunostomy or even resection of the pancreatic head.

❖ **Annular Pancreas:**

- Duodenojejunal bypass, we need to bypass the obstruction.

We do not do resection of the pancreatic tissue because it's almost impossible and we may end up by causing a fistula or pancreatitis.

READ:

We can't go through congenital anomalies of the pancreas without quickly discussing **Cystic Fibrosis**:

- It's a genetic disease affecting **CFTR gene**, and diagnosed by **increased Cl^- and Ca^{+2} levels in the sweat** ($>90\text{mmol/L}$).
- Cystic fibrosis is a multisystem disorder of exocrine glands that affects the lungs, intestines, pancreas and liver. Most of the organ damage is due to blockage of narrow passages by thickened secretions.
- **Chronic pulmonary disease** arises from plugging of bronchi and bronchioles and at birth. The meconium may set in a sticky mass and produce **intestinal obstruction** (meconium ileus).
- Secretions precipitate in the lumen of the pancreatic duct causing blockage, which results in duct ectasia and fatty replacement of exocrine acinar tissue. Pancreatic **exocrine insufficiency** leads to **fat malabsorption**.
- Treatment is aimed at control of the secondary consequences of the disease; antibiotics for pulmonary infection and pancreatic enzymes oral supplements.

Acute Pancreatitis



INTRODUCTION

Definition: it's a reversible inflammation of the pancreas as a result of autodigestion by its own enzymes.



ETIOLOGY

Remember its causes as **I GET SMASHED**:

Idiopathic

Gallstones

Ethanol (alcohol)

Trauma (usually a penetrating one)

Steroids (it could happen from the first exposure)

Mumps

Autoimmune disease (ex: polyarteritis nodosa [PAN])

Scorpion bite (Rare)

Hyperlipidemia/ Hypercalcemia

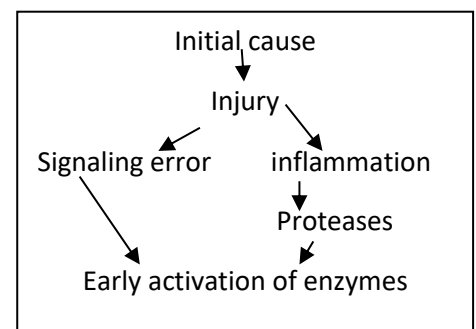
ERCP [endoscopic retrograde cholangio-pancreatography] → Iatrogenic

Drugs (diuretics, Isoniazid {INH}, reverse transcriptase inhibitors and Metronidazole).



PATHOPHYSIOLOGY

- An initial cause causes injury to the pancreatic ductal cells which results in cell membrane trafficking problem (signaling error) that causes the early activation of pancreatic enzymes and thus, destruction of the pancreatic tissue. Also cell



injury causes the release of activated neutrophils which produces proteolytic enzymes and activation of zymogens.

Remember that: the inflammatory process includes the production of inflammatory mediators from the macrophages (IL-6, IL-8, TNF α) which act locally (local inflammation) and systematically (SIRS → hemodynamic instability).

- Cells injury may take place as a result of any cause the was already mentioned (I GET SMASHED), the most common causes is an obstruction by a **gallbladder stone**, and chronic alcohol abuse that causes cell injury by its direct toxicity and alteration of the pancreatic secretion resulting in an actual obstruction. Among patsients who undergo **ERCP**, 1-3% develop pancreatitis as a consequence of duct distrupction and the reflux of duodenal enzymes(enterokinase) to the pancreas. **Idiopathic** pancreatitis should not exceed 20% and it may be caused by biliary microlithiasis (stones that are not found) or genes effect which are not yet detected.



CLINICAL FEATURES

- **Symptoms:**
 1. **Pain:** rapid onset, epigastric pain radiating to the back, progressive and reaching maximum intensity within minutes, continuous persisting hours or days, increases when lying supine and decreases when leaning forward refractory to analgesia.
 2. **Nausea and vomiting.**
 3. **Fever**
- **Signs:**
 1. **Epigastric tenderness**
 2. **Diffuse abdominal tenderness**
 3. **Decrease in bowel sounds (Adynamic ileus)**
 4. **Abdominal distention (due to ileus)**
 5. **Fever**
 6. **Dehydration and shock (due to fluid sequestration)**
 7. **Signs of hemorrhagic pancreatitis (if damage to the blood vessels caused retroperitoneal hemorrhage):**
 - **Cullen's sign** [Umbilical hemoperitoneum]

Deferential diagnosis (DDX):

1. **Biliary colic/Cholecystitis.**
2. **Gastritis/PUD.**
3. **Perforated viscus.**
4. **SBO.**
5. **Mesenteric ischemia/infarction.**
6. **Inferior MI/ inferior lobe pneumonia.**
7. **Ruptured AAA.**

- **Grey-Turner sign** [Flank hemoperitoneum]
- **Fox's sign** [bluish discoloration of the inguinal ligament]

- **Complications:**

- **Early:**

1. **Shock and Renal failure**
2. **Pancreatic ascites and pleural effusion**
3. **ARDS and Sepsis**
4. **Severe HYPOcalcemia** (due to fat saponification, in which fat necrotic tissue binds to calcium)
5. **Superior mesenteric/ Splenic/Portal vein rupture or thrombosis.**

Remember that: Inflammation and hemodynamic instability cause a systemic effect in all over the body (Lungs, kidneys ...).

Note: Splenic vein thrombosis is a complication of both acute and chronic pancreatitis.

- **Late**

1. **Pancreatic necrosis**
2. **Pancreatic Abscess**
3. **Hemorrhagic pancreatitis**
4. **Infection**
5. **Fistula**
6. **Pseudocyst**
7. **Diabetes.**

Most of these late complications will be explained as separate conditions as we move forward.



DIAGNOSIS

- **History and Physical exam** (as previously mentioned in the signs and symptoms).
- **Labs:**
 - **Amylase and lipase levels:** this is the typical way to diagnose pancreatitis, amylase level increases then decreases after a few days (So if the patient presented after a few days and amylase level where normal, check for lipase.)
 - **CBC** (increase in WBC : 10,000-30,000)
 - **LFT**

Amylase is more sensitive.

Lipase is more specific.

The increase in amylase level is not proportional to the severity of the pancreatitis.

- If Alkaline phosphatase was high → think biliary stones.
- If AST > ALT → Think alcohol.
- You should also ask for **Ca²⁺** and **lipid** levels.
- **Imaging:**
 - **Abdominal X-ray (AXR):**
 - Gallstones (only 10% are radiopaque)
 - Sentinal loop: Air-filled small bowel in LUQ. → m.c sign on X-ray.
 - Colon cutoff: Abrupt ending of transverse colon.
 - **RUQ ultrasound (U/S):**
 - Swollen pancreas (collection of pus “phlegum” and fluid) may be seen.
 - Gallstones or dilated biliary duct may be detected.
 - Pseudocysts and ascites can be detected in severe cases.
 - **CT scan:**
 - It's not necessary for all patients, it's used to determine prognosis.
 - It should be done in severe acute cases to diagnose necrotizing pancreatitis.
 - It's used when a localized complication is suspected (Fluid collection or pseudocyst).
 - **EUS and MRCP:**
 - It's not widely available.
 - Can detect stones in the CBD along with assessing the pancreatic parenchyma.
 - **ERCP:**
 - Is not routinely indicated for the evaluation of patients during an attack of acute pancreatitis. It has four indications:
 1. Patients with jaundice, suspected biliary pancreatitis, and possible cholangitis who are not clinically improving by 24 hours after admission should undergo endoscopic sphincterotomy and stone extraction.

Sentinal loop and colon cutoff
result from localized paralysis of the small and large intestines respectively which resulted from a nearby inflammation.

Ultra sound has a major limitation in that it cannot be performed when excessive bowel gas is present, as occurs with an ileus.

KEEP IN MIND:

Pancreatic necrosis has two parts:

Parenchymal liquafactive necrosis and **fat** necrosis.

2. Patients with no identifiable cause to rule out occult common bile duct stones, strictures, or neoplasms.
3. Suspected pancreatic ductal disruption, such as with traumatic pancreatitis.

- **Assessing severity:**

- Skin findings:

- Most common finding is erythema of flanks (as a result of focal fat necrosis).
- Cullen's sign, Grey-Turner's sign and Fox's sign.

- CT severity index (CTSI):

- (A) → Normal.
- (B) → Enlargement.
- (C) → Peripancreatic inflammation.
- (D) → Single peripancreatic fluid collection.
- (E) → Multiple peripancreatic fluid collection.

- Severity scoring system:

- **Ranson's criteria:** [not specific nor sensitive]

****Within 24 hours (GA LAW): [Point for each]**

Glu >200 mg, Age >55, LDH >350 U/L, AST >250 U/L, WBC >16,000

**** After 48 hours (C HOBBS): [Point for each]**

Ca⁺² <8mg/dl, Hct decreased > 10%, O₂ (Arterial PO₂) < 60mmHg,
Base deficit >4meq/L, BUN increased > 5mg/dl, Sequestered fluid >6 L

Mortality risks:

- Point/s → risk
- 0-2 → 1%
- 3-4 → 16%
- 5-6 → 40%
- 7-8 → 100%

- **APACHE II** [good specificity and sensitivity]:

Needs a calculator → If ≥ 8 → SEVERE

- **BISAP:** it can be done on bedside with No need for a calculator as APACHE II. [Point for each]:

1) BUN >25 2) Impaired mental status 3) SIRS

4) Age >60 5) pleural effusion.

Mortality risks:

- Point/s → risk
- 0-2 → <2%
- 3-5 → >15 %



TREATMENT

- **Conservative management:** (90% of cases resolve spontaneously)

- NPO

- NG suction may be needed.
- IV hydration
- Analgesia and antiemetic are the only drugs needed, though Somatostatin analogues may help in
- Broad spectrum antibiotics are used **ONLY** if infection is established

Remember that: Pancreatitis is a sterile inflammation unless complicated by infection

- PO2 monitoring.
- **Cholecystectomy** should be required in patients with gallstone pancreatitis.
- **Percutaneous aspiration** of fluid or necrotic collection guided by CT or EUS need to be done only if it has a pressure effect or if complicated with infection (or suspicion of infection).
- **Resection** in acute pancreatitis is very dangerous, but removing the necrotic tissue may be required in patients with deteriorating sepsis. (The surgery has a high mortality rate).

Once pancreatic necrosis with infection is diagnosed, CT guided aspiration should be tried before resection by surgery is done.

Biliary Pancreatitis



INTRODUCTION

Definition: Acute pancreatitis from a gallstone in or passing through the ampulla of vater and it's the most common cause for acute relapsing pancreatitis.

The stones which cause biliary pancreatitis are small stones (2mm), because the pancreatic duct is small in diameter (1-3.5 mm).



DIAGNOSIS

- Acute pancreatitis with cholelithiasis or choledolithiasis + NO OTHER CAUSE for pancreatitis (alcohol abuse).
- U/S to look for gallstones.
- CT to look at the pancreatic changes if the symptoms where severe.
- MRCP to look for small stones obstructing the pancreatic duct.



TREATMENT

- Conservative management until the patient is stable then early interval cholecystectomy (in the same admission) should be done with intraop cholangiogram (IOC) which is needed to rule out persistent choledocholithiasis.
- ERCP should be done if the patient is not fit to surgery, with cholangitis took place or in case of refractory choledocholithiasis to do sphincterectomy with stone extraction.

Early interval cholecystectomy is important to prevent relapsing episodes of acute pancreatitis.

Pancreatic Necrosis



INTRODUCTION

Definition: Dead pancreatic tissue usually following acute pancreatitis, it has two components; parenchymal liquefactive necrosis plus fat necrosis.



DIAGNOSIS

- Abdominal CT with contrast. {Dead pancreatic tissue does **NOT** take up the IV contrast and is **NOT** enhanced on CT scan “does not light up”}



TREATMENT

- If sterile → Medical management.
- If suspicious of infection → CT-guided FNA.
- If hypotension/ sepsis → Operative debridement.

Pancreatic Abscess



INTRODUCTION

Definition: Infected peripancreatic purulent fluid collection.

Pathogens:

- Gram -ve : (m.c): E-coli, KLebsiella and pseudomonas.
- Gram +ve: S.aureus
- Fungal: Candida



CLINICAL FEATURES

- Fever.
- Unresolving pancreatitis.
- Epigasrtic mass



DIAGNOSIS

- **Imaging:** Abdominal CT with needle aspiration → Send to gram stain/ culture.
- **Labs:** Gram stain / culture for bacteria.



TREATMENT

- **Medical:** Antibiotics with percutaneous drain placement.
- **Surgical:** Operative debridement and placement of drains → maybe needed in very rare situations.

Hemorrhagic Pancreatitis



INTRODUCTION

Definition: Bleeding into the parenchyma and retroperitoneal structures with extensive pancreatic NECROSIS.

So: if the necrosis was severe to the extent of causing damage to the blood vessels, hemorrhagic pancreatitis takes place.



CLINICAL FEATURES

- Abdominal pain and tenderness.
- Shock/ ARDS.
- Cullen's sign.
- Grey-Turner's sign.
- Fox's sign.



DIAGNOSIS

- **Labs:**
 - Decreased Hct.

- high amylase and lipase levels with low Ca^{+2} level (as in acute pancreatitis).

- **Imaging:**

- CT scan with contrast.



TREATMENT

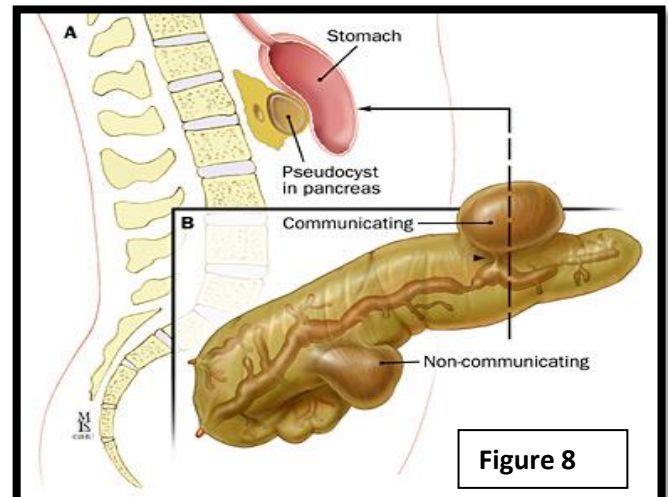
- ❖ Treatment involves embolization of the affected vessel or surgery.
-

Pancreatic Pseudocyst

INTRODUCTION

❖ Definition:

- Encapsulated collection of pancreatic fluid in the lesser sac.
- Pseudocyst's wall consists only of the inflammatory response of the neighboring organs (granulation tissue or fibrosis) and not epithelium (That's why it's called PSEUDOcyst).
- Types [Figure 8]: Communicating (more common) and non-communicating.



? ETIOLOGY

❖ Risk factors:

- Acute pancreatitis → most common cause.
- Chronic pancreatitis.
- Pancreatic trauma.

⚡ PATHOPHYSIOLOGY

- Pseudocyst forms as a result of fibrosis, thickening and organization of the organs bordering the collection.
- It's not lined by epithelium.
- Formation of a pseudocyst requires 4 weeks or more from the onset of acute pancreatitis in order to become mature.

By definition, a fluid collection appearing in the first 4 weeks after the onset of pancreatitis is an acute fluid collection; after 4 weeks, it becomes an acute pseudocyst.

- Small pseudocysts may resolve; large pseudocysts with mature organized walls generally do not resolve.
- They are often single but, occasionally, patients will develop multiple pseudocysts.

Pseudocysts that are thick-walled or large (over 6 cm in diameter), have lasted for a long time (over 12 weeks) or have arisen in the context of chronic pancreatitis are less likely to resolve spontaneously.



CLINICAL FEATURES

- **Symptoms:**

1. Recurrent or persistent upper abdominal pain.
2. Nausea and vomiting.
3. Mild fever.
4. Weight loss.

Suspect it in a patient with acute pancreatitis with unresolved pain.

- **Signs:**

1. Palpable epigastric mass
2. Tender epigastrium.
3. Ileus.

DDX: Cystadenoma and cystadenocarcinoma

- **Complications:**

- Infection in 5-20% of the cases.
- Enteric fistula can occur spontaneously and usually results in resolution of the cyst.
- Bleeding into the cyst resulting from erosion into surrounding visceral vessels.
- Pancreatic ascites.
- Obstruction: gastric outlet, duodenal or biliary obstruction.
- Rupture occurs in fewer than 3% of cases.



DIAGNOSIS

- **History and physical examination** (as mentioned earlier).

- **Labs:**

- CBC (leukocytosis).
- Increased Amylase and Lipase levels.
- Increased LFT (if biliary obstruction took place).
- Cystic fluid analysis: low CEA, high amylase level and cytology reveals inflammatory cells in pseudocyst fluid.

- **Imaging:**

- Ultrasound: Fluid-filled mass
- CT scan: It's the diagnostic imaging of choice; it gives information about the wall thickness, calcifications and number of pseudocysts which affect the prognosis.
- ERCP: Radiopaque contrast material fills the cyst if communicating (to differentiate between communicating and non-communicating) as well as it allows for the determination of pancreatic duct abnormalities
- EUS: it's important if sample is needed, in order to differentiate it neoplasm if there was suspicion.

If there's no access to EUS, FNA is acceptable (Only aspiration without insertion of a drain).



TREATMENT

Therapeutic interventions are advised if the pseudocyst doesn't resolve spontaneously within 6 weeks. You wait 6 weeks for the pseudocyst's wall becomes mature and firm enough to hold sutures. Approximately 50% resolve within 6 weeks.

Indications for treatment:

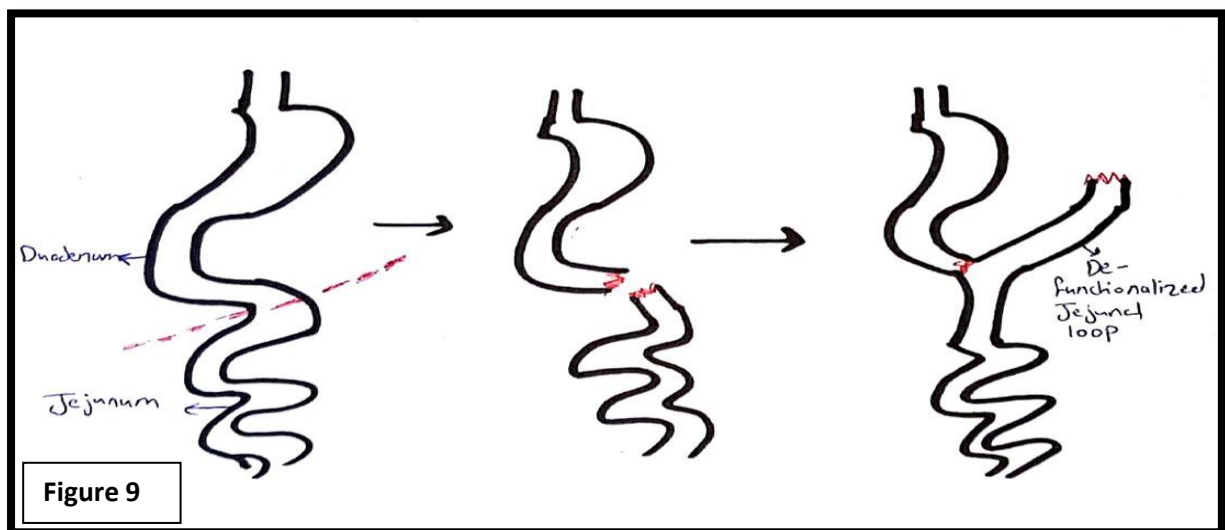
1. Size > 5cm (because it has higher chance of complications and is less likely to resolve spontaneously).
2. Calcified cyst wall.
3. Thick wall cyst.

- **Percutaneous drainage under radiological guidance:** should be avoided. It carries a very high likelihood of recurrence. Moreover, it is not advisable unless one is absolutely certain that the cyst is not neoplastic and that it has no communication with the pancreatic duct (or else a pancreaticocutaneous fistula will develop).
- **Endoscopic drainage:** usually involves puncture of the cyst through the stomach or duodenal wall under EUS guidance, and placement of a tube drain with one end in the cyst cavity and the other end in the gastric lumen.
- **ERCP and placement of a pancreatic stent across the ampulla (Transpapillary stent):** It may help to drain a pseudocyst that is in communication with the duct.

- **Operative drainage:**

- Internal drainage: If the the cyst is adherent to the stomach, cystogastrostomy (drainage into the stomach) is done. If the cyst is adherent to the duodenum, cystduodenostomy (drainage into the duodenom) is done. Drainage into a defunctionalized (Roux-en-Y) loop jejunum [Figure 9]: If the cyst isn't adherent to any organ.

This is conventionally done through an open incision, but laparoscopic cystgastrostomy is also feasible.



- External drainage: Used if the pseudocyst is not found to be mature and the pseudocyst wall is not safe. The external drainage results in a pancreatic fistula, which usually heals with continued TPN.
- Excision: rare; however, may be indicated if the pseudocyst is small and is located distally in the tail of the pancreas. Resection of the tail of the pancreas maybe done.

Chronic Pancreatitis

INTRODUCTION

- **Definition:** Persistent inflammation of the pancreas with **IRREVERSIBLE** histological changes (fibrosis, atrophy or calcification), recurrent abdominal pain and loss of exocrine & endocrine function.
- **Has two subtypes:** 1) Chronic calcific pancreatitis 2) chronic obstructive pancreatitis.

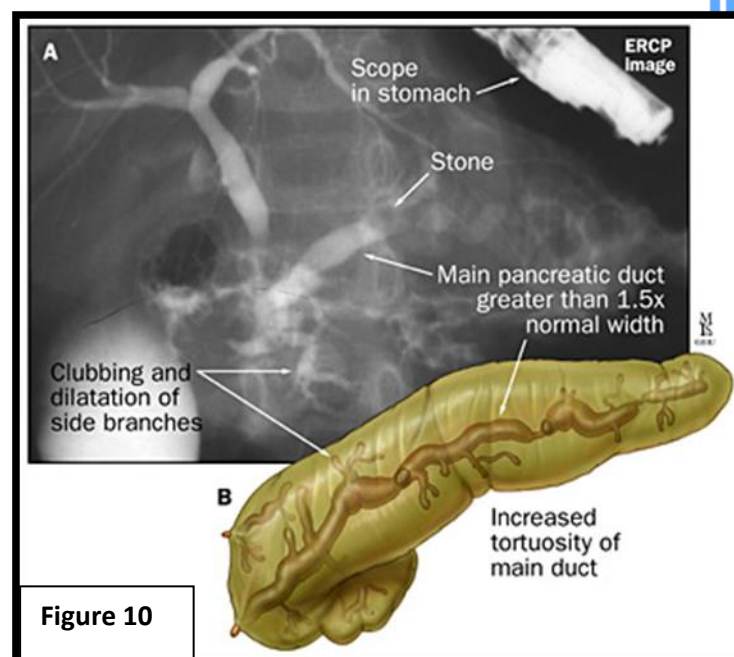
? ETIOLOGY

- **Alcohol** (chronic >10 years) → 60-70% {most common in developed countries}
- **Idiopathic** → 30%
- **Obstructive** → Pancreas divisum, sphincter of oddi dysfunction/mass.
- **Metabolic** → Malnutrition, Hyperlipidemia and hypercalcemia (hyperparathyroidism).
- **Familial.**
- **Trauma.**
- **Iatrogenic.**
- **Gallstones.**

⚡ PATHOPHYSIOLOGY

Can be summarized in 4 steps:

1. Early changes: plugging of small ducts with proteins and eosinophils.
2. With disease progression: multiple calcification and multiple areas of ductal dilatations.
3. End stage of ductal dilatations → Chain of lakes appearance [Figure 10].



Note: Common bile duct obstruction and duodenal obstruction: can occur in advanced cases as a result of inflammation in surrounding areas.

- **Symptoms:**

- Epigastric pain: Unrelenting (continuous, doesn't stop) and radiating to the back.

The site of pain depends to some extent on the main focus of the disease. (It's not always epigastric).

- Weight loss.

- Steatorrhea → Stool floats in the water.

Malabsorption

- **Signs:**

- Signs of exocrine insufficiency; malnutrition, steatorrhea (fat malabsorption "Lipase is insufficient")

- **Complications:**

- Severe, prolonged and refractory pain.

- Insulin-dependent DM.

- Steatorrhea and malnutrition especially lipid soluble vitamins deficiency (K, E, D, A).

- Splenic vein thrombosis → short gastric veins hypertension → gastric varices (in the fundus).

- Biliary obstruction (from pancreatic inflammation and edema or from stricture of the intrapancreatic CBD)

- Duodenal obstruction.

- Pancreaticocenteric fistulas.

- Pancreatic pseudocyst → becomes an abscess if infected.

- Splenic artery pseudoaneurysm [differs from a true aneurysm in that its wall does not contain the components of an artery but instead consists of fibrous tissue].

- Pancreatic CA (if > 20 years) → 2-4 % risk.



DIAGNOSIS

- **Labs:**

- Amylase and Lipase.

- Pancreatic secretin stimulation test: high sensitivity and specificity.

Amylase and Lipase are only elevated in the beginning of the disease after that their level will be normal, as a result of extensive pancreatic tissue loss "Burred-out pancreas".

- A 72-hour fecal collection for estimation of daily fecal fat (it doesn't play a huge role in the definitive diagnosis for chronic pancreatitis).
- Glucose tolerance test.
- **Imaging:**
 - Abdominal X-ray → Pancreatic calcification may be seen.
 - CT and MRI show the outline of the pancreas and the main area of the damage, calcification, masses or pseudocysts may be seen.
 - MRCP and ERCP will identify the presence of biliary obstruction and the state of the pancreatic duct (chain of lakes, pseudocysts or stenosis) but as it 3-7% risk of causing acute pancreatitis.
 - EUS has come to play a more important role in the diagnosis of biliary obstruction, but it needs a very skilled doctor.



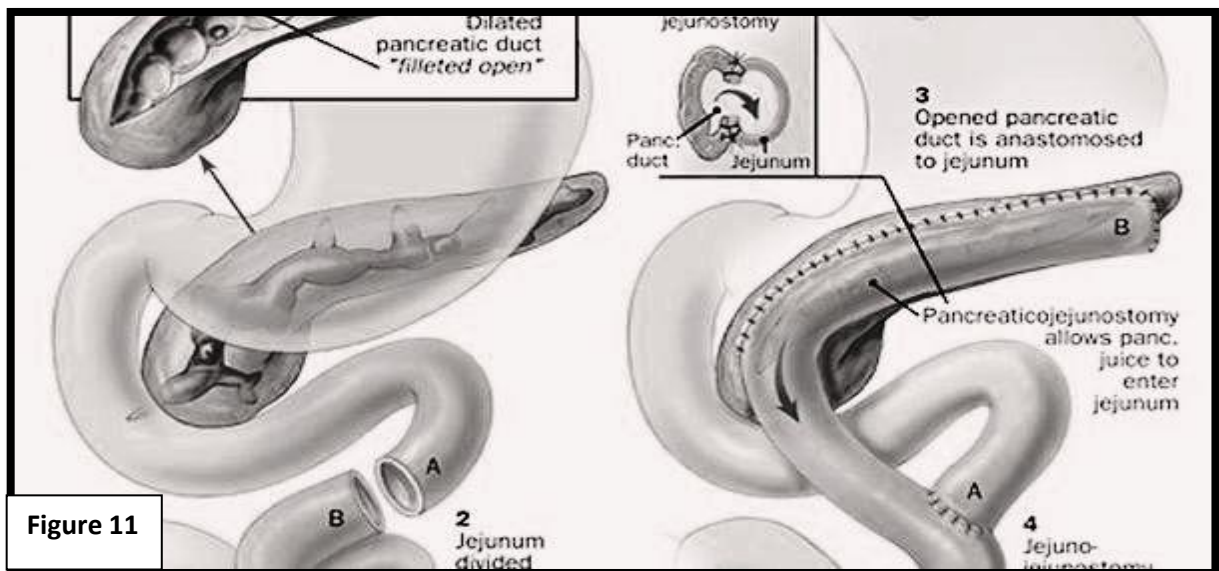
TREATMENT

- **Life style changes:**
 - Stopping alcohol intake and avoiding smoking.
 - Decreasing fat intake and adding medium chain triglyceride (MCT).
- **Medical:**
 - Analgesia and endocrine supplements when needed.
 - Exocrine replacement with pancreatic enzymes(Creon).
 - Vitamins K, E, D and A supplements.
 - Diabetes initially is responsive to good nutrition and dietary control; however, use of oral hypoglycemic agents or insulin therapy often is required.
 - Tube thoracostomy or repeated paracentesis may be required for pancreatic pleural effusions or pancreatic ascites.
- **Endoscopy:**
 - Endoscopic sphincterotomy, stenting and stone retrieval have all been used with moderate success in the management of patients with ductal complications from chronic pancreatitis.
 - Endoscopic celiac plexus block may improve symptoms in patients with severe pain.

Creon (pancrelipase): is a combination of three enzymes: lipase, protease, and amylase.

- **Surgical:**

- **Puestow operation [Figure 11]** (longitudinal pancreaticojejunostomy): pancreatic duct must be dilated to do this surgery. After draining the pancreatic duct it is anastomosed with a defunctionalized jejunal loop (Roux-en-y loop).



- **Frey procedure:** longitudinal pancreaticojejunostomy with the resection of the affected parts in the pancreatic head. It's considered better than Puestow operation because the proximal pancreatic duct is also cleared by extensive coring of the head of the gland.

Puestow has often failed because the pancreatic duct in the head of the gland was not drained adequately.

- **The Beger procedure:** Duodenum-sparing pancreatic head resection, it has shown excellent long-term results.

- **Pancreatectomy:**

- **Pancreaticoduodenectomy (whipple):** is indicated in cases in which the pancreatitis involves the head of the pancreas, the pancreatic duct is of small diameter, or cancer cannot be ruled out in the head of the pancreas.
- **Distal subtotal pancreatectomy:** used to treat a distal ductal obstruction.
- **Total pancreatectomy:** is performed only as a last resort in patients whose previous operations have failed

Pancreatic tumors (in general)



INTRODUCTION

- Classified into endocrine tumors (from islets of langerhans) and exocrine tumors, only exocrine tumors will be discussed in this section.
- Majority of pancreatic tumors are malignancies arising from the ductal system.
- Exocrine tumors are classified into benign, borderline (intermediate), and malignant.

➤ Benign:

- Serous cystadenoma (15%)
- Mucinous cystadenoma (40%)
- Intraductal papillary mucinous adenoma (30%)
- Mature cyst teratoma

➤ Borderline

- Mucinous cystadenoma with moderate dysplasia.
- Intraductal papillary mucinous tumors.
- Solid pseudopapillary tumors.

➤ Malignant:

- Ductal adenocarcinoma
- Mucinous adenocarcinoma.
- Intraductal papillary mucinous tumors.

If they gain malignant characteristics.

Read if you didn't understand half of the things you've just read:

- ❖ **Mature cell teratoma** (dermoid cyst) is a benign, well-differentiated, extremely rare germ cell neoplasm.
- ❖ **Solid pseudopapillary tumor** is a low-grade malignant neoplasm of the pancreas of papillary architecture with special histopathological (part-solid, part-cystic) features that typically affect young women.
- ❖ Cystic tumors of the pancreas may be serous or mucinous.
- ❖ **Serous cystadenomas** are typically found in older women, and are large aggregations of multiple small cysts, almost like bubblewrap. They are benign.
- ❖ **Mucinous tumors** have the potential for malignant transformation. They include mucinous cystic neoplasms (MCNs) and intraductal papillary mucinous neoplasms (IPMNs). MCNs are seen in perimenopausal women, show up as thick-walled cysts in the pancreatic body or tail and they can be confused with pseudocysts. IPMNs are more common in the pancreatic head and in older men.
- ❖ **Ductal adenocarcinoma** comprises 85% of total pancreatic tumors and they are solid tumors, characterized by neoplastic tubular glands within a markedly desmoplastic fibrous stroma.

**** Pancreatic adenocarcinoma will be discussed in details in a separate section.**



TREATMENT

- Serous cystadenoma should be resected if they cause symptoms, become large in size or is suspected to be mucinous.
- Mucinous cystadenoma should be resected because they have the potential to become malignant.
- Solid pseudopapillary tumors should also be resected.

Mucinous= Malignant

Pancreatic Adenocarcinoma

INTRODUCTION

- **Definition:** It is tumor arising from the pancreatic cells (majority of tumors arise from the ductal cells) and forming a granular-like shape.
- **Types:** Ductal adenocarcinoma (>80%), Cystadenocarcinoma and Acinar cell carcinoma.
- **Classified into:** periampullary tumors, Head of pancreas tumors (66%) and Body and tail tumors (33%)
- **Epidemiology:** it's the fourth leading cause of death in the US, and constitutes 2-3% of all cancers there [75% of the patients die within the first year after diagnosis].

Remember that: in order to name a tumor "adenocarcinoma", it should either originate from glandular cells or from any cells that form histological glandular appearance.

? ETIOLOGY

Risk factors:

1. Male gender (males:females, 2:1).
2. Black gender (black:white, 2:1).
3. **Smoking (increases the chance by 3 times).**
4. Heavy alcohol intake.
5. Chronic pancreatitis (>20 years) especially in familial pancreatitis.
6. Diabetes.
7. Age (>60).
8. Diet [low fiber diet].
9. Familial history of cancer and FAP (familial adenomatous polyposis).

Mutations in Pancreatic CA: 10% familial genetic mutations (P53), 80-90% sporadic mutations (Kras, P53). Most of pancreatic CA patients have 3 or more mutated genes

****Pancreatic CA has precancerous stage (carcinoma in situ) named: Pancreatic intraepithelial neoplasia; it has grades (grade I, II and III) and can end up transforming into cancer. As it progresses it gains several mutations providing it with malignancy potentials.**



CLINICAL FEATURES

1. Periapillary tumors:

- Tumors arising from the ampulla or from the distal common bile duct can present as a mass in the head of the pancreas, and constitute around a third of all tumors in that area.
- Have 4 types; from the ampulla itself, from the duodenum around the ampulla, from the terminal part of the common bile duct near the ampulla and from the head of the pancreas near the ampulla.
- Present as a triad:
 1. Obstructive jaundice (intermittent).
 2. Fluctuating in severity.
 3. Stool +ve occult blood test.

Patients with familial adenomatous polyposis (FAP) can present with multiple duodenal polyps. Malignant transformation in a duodenal polyp is a significant cause of mortality in these patients.

Why intermittent jaundice?

Due to central necrosis and sloughing of cells (thus relieving the obstruction).

2. Head of pancreas tumors:

Present as:

- Painless jaundice (as a result of CBD obstruction).
- Pruritis.
- Pale stool and dark urine.
- Weight loss and anorexia.
- Although the jaundice is commonly painless, epigastric discomfort with back pain may be present.
- Nausea and vomiting.
- Steatorrhea.
- Diabetes.
- Chronic pancreatitis may be seen due to pancreatic duct obstruction.

Pruritis results from the precipitation of **bile salts** in the subcutaneous fat. (Salts are water soluble).

Stool features:

1. **Pale** → obstructive jaundice
2. **Fatty (Steatorrhea)** → Malabsorption

An important sign in pancreatic head CA: **Courvoisier's sign** (in 25% of cases) → palpable painless gallbladder.

3. Body and tail tumors:

Present as:

- Weight loss and anorexia (90%).
- Migratory thrombophlebitis (**Trousseau's sign**) (10%): Blood clots felt as small lumps under the skin.
- Jaundice (<10%).

- Nausea and vomiting.
- Fatigue.
- Usually present with back pain due to invasion of neural endings.



DIAGNOSIS

• Labs:

- Direct bilirubin and Alkaline phosphatase (increased due to biliary obstruction).
- Liver function tests.
- Pancreatic tumor markers (CA19-9, CEA) are used only to confirm diagnosis after imaging studies (neither sensitive nor specific).

Pancreatic tumor markers: 1) **CA 19-9** (carbohydrate antigen 19-9) 2) **CEA** (Carcinoembryonic antigen)

• Imaging:

- Ultrasound → reveals CBD dilatation in periampullary or pancreatic head tumor.
- CT scan with contrast → is the preferred test for diagnosis.
- Endoscopic ultrasound (EUS) is done:
 1. If CT fails to find a tumor, because it can detect very small tumors which CT cannot.
 2. If tissue biopsy is needed {tissue biopsy is needed if we diagnosed an unresectable tumor, or the tumor is resectable but the patient can't undergo a major surgery and we need to confirm the diagnosis before starting chemotherapy}.
 3. For staging after diagnosis with CT, as it does a better job in assessing the resectability.
- Diagnostic laparoscopy should be done to evaluate distant metastasis; because even after doing CT and EUS, their prediction for resectability is only 80%, so to avoid doing laparotomy to find unresectable tumor, we do diagnostic laparoscopy to increase the prediction to 98%.
- ERCP with stenting and cell biopsy is carried out if the patient is suffering from cholangitis and needs immediate intervention.

IF CT scan or EUS confirmed a resectable tumor, a diagnostic laparoscopy can be done, but tissue biopsy is **NOT** needed.

****The type of biopsy taken in the ERCP is brush biopsy in order not to cause perforation of the duct.**

- **Staging:** It's important in order to determine the following management; it's done by CT, EUS and laparoscopy. It's classified as following:

EUS does a better job than CT in assessing the resectability of the tumor. (lymph nodes or major vessels involvement).

Stage:	Tumor (T):	Lymph nodes involvement (N):	Metastasis
I A	T1: tumor < 2cm and is confined to the pancreas.	No: no regional lymph nodes involvement)	Mo: No distant mets.
I B	T2: tumor > 2cm and is confined to the pancreas.	No	Mo
II A	T3: tumor extending outside the pancreas without the involvement of the celiac axis or SMA	No	Mo
II B	T1, T2, T3	N1 (regional lymph nodes involvement).	Mo
III	T4 (tumor involves celiac axis or SMA)	No, N1	Mo
IV	Any T	Any N	M1 (distant mets)

- **Unresectable tumors are: (Stages III and IV)**

1. Liver metastasis.
2. Celiac or hepatic hilar lymph nodes involvement (outside of resection area)
3. Peritoneal implants.
4. Invasion of major vessels (Portal, celiac and SMA).

Tumors that:

- 1) Invade of duodenum and distal stomach.
- 2) Involve peripancreatic lymph nodes.

Are resectable tumors



TREATMENT

- **SURGICAL (if resectable):**

- Periapillary or pancreatic head CA → Whipple procedure (pylorus-preserving).

Whipple procedure will be discussed in details in the next section.

1. Body or tail CA → Distal resection (Near-total pancreatectomy).

- **Palliative (if unresectable or if the patient can't undergo surgery):**

- For pain → Narcotics or celiac axis block (sometimes severe pain results from the involvement of nerves in retroperitoneal area).
- For jaundice → Pancreatic stent or choledochojejunostomy.
- For duodenal obstruction (in 20% of cases) → gastrojejunostomy.
- Palliative chemotherapy.

- **Prognosis:**

- Unresectable tumor → 5-year survival is < 5% (they live about 4-6 months).
 - After successful resection → 5-year survival 15-20% (they live about 12-19 months).
-
-

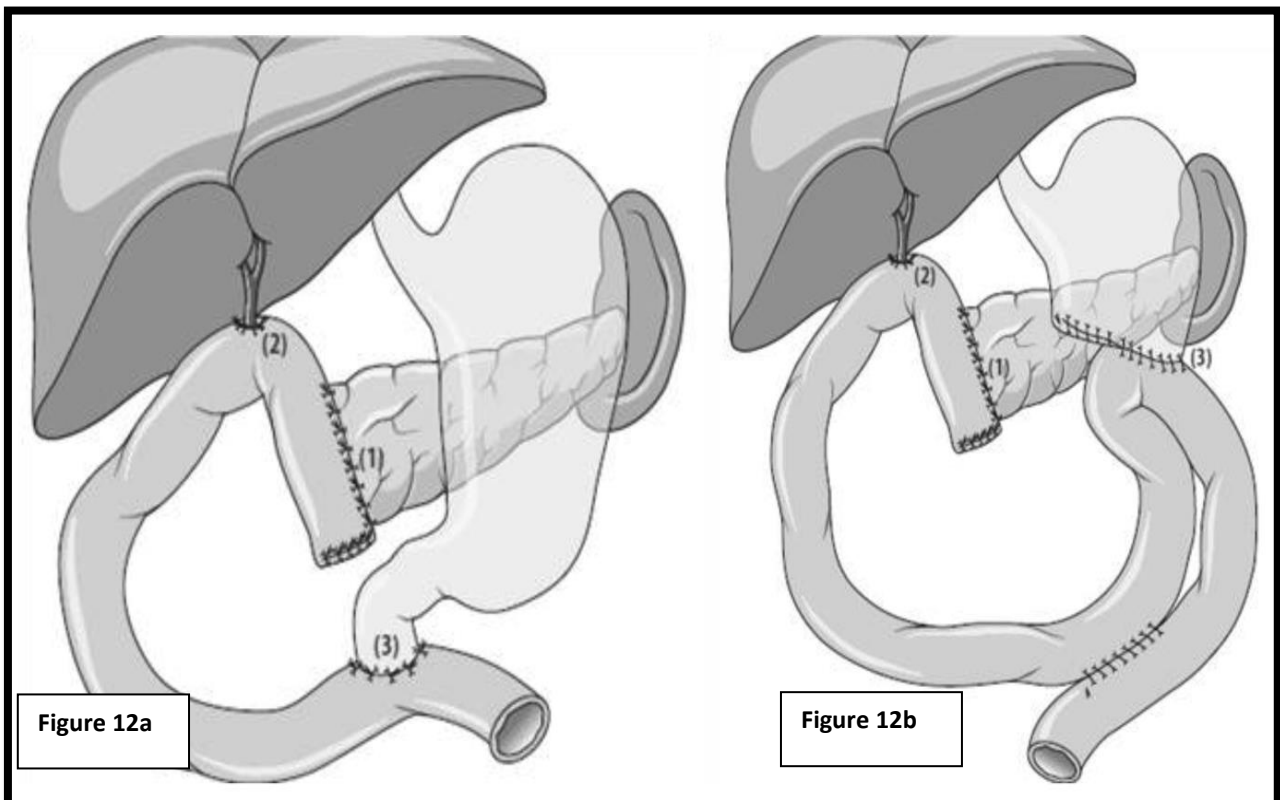
Whipple Procedure (Pancreaticoduodenectomy)

INTRODUCTION

❖ Definition:

- Cholecystectomy.
- Truncal vagotomy.
- Antrectomy.
- **Pancreaticoduodenectomy** (removal of the head of pancreas + the duodenum).
- Choledochojejunostomy (anastomosis of the CBD to the jejunum).
- Gastrojejunostomy (anastomosis of the stomach to the jejunum).
- Pancreaticojejunostomy (anastomosis of the pancreas to the jejunum).

“Pylorus-preserving whipple (Figure 12a)”: **NO antrectomy** as in the conventional whipple (Figure 12b), involves anastomosis of small part of duodenum with the jejunum.



❖ Indications:

- Carcinoma (Periampullary):
 1. CA of the head of the pancreas.
 2. CA of the duodenum.
 3. CA of bile duct (distal part).
 4. CA of the ampulla of vater.
- Benign cases (sometimes):
 1. In case of chronic pancreatitis (refractory to medical treatment).
 2. Benign tumors in the head of pancreas.

❖ Complications:

- Anastomotic leak (from the bile duct or pancreatic anastomosis).
- Delayed gastric emptying (if antrectomy is performed).
- Pancreatic/ biliary fistula.
- Wound infection.
- Postgastrectomy syndromes.
- Sepsis.
- Pancreatitis.

❖ **Mortality rate** associated with whipple is <5% which is considered very high.

❖ Why must we remove the duodenum be removed if the head of the pancreas is resected? * Because they share the same blood supply (Gastroduodenal artery).

FOR YOUR OSCE



HISTORY & PHYSICAL

- ❖ This part will be your guide during the OSCE exam, we will be discussing pancreatitis as a specific condition but symptoms of other conditions will be discussed as we move forward.

This section was taken from the new OSCE dossier and it was written by Yasmin Khundakji.

- ❖ **History:**

- Patient's Profile: Age is usually 40-50.
- Chief Complaint: Epigastric Pain that radiates to the back.
- History of Present Illness:
 - ✓ **Pain:**

Site, Character and Severity:	<ul style="list-style-type: none">• Epigastric (in the upper abdomen). It is severe, dull, gnawing and persistently aching.• Gallstone pancreatitis: pain is well localized and the onset of pain is rapid (reaches maximum intensity in 10-20 minutes).• Pancreatitis due to hereditary or metabolic causes or alcohol: The onset of pain may be less abrupt and the pain may be poorly localized.
Onset, duration and offset:	<ul style="list-style-type: none">• Sudden onset with severity gradually increasing.• The pain lasts days. Its onset is rapid, but not as abrupt as that with a perforated viscus.
Radiation:	<ul style="list-style-type: none">• Band-like radiation to mid back.• <u>Pancreatic cancer: radiation to the LH (tumor at the head) or RH (tumor at the tail).</u>
Timing:	<ul style="list-style-type: none">• What do you think may have initiated the pain? Eating a large meal or drinking alcohol?
Exacerbating and relieving factors:	<ul style="list-style-type: none">• Does it increase at night (cancer)? Do movement and lying supine increase it?• Usually there are no alleviating factors but bending forward while sitting may relieve it slightly.
Associated with:	<ul style="list-style-type: none">• Vomiting: Frequency, color, smell, amount and content. Any involuntary efforts to

	<ul style="list-style-type: none"> • Vomit without fruitful vomiting? • Nausea: persistent between vomiting attacks • Dizziness • Restlessness and agitation • Patients with fulminant attacks may present in shock or coma • Jaundice: Cancer or Chronic pancreatitis • Inability to take full breaths and dyspnea? (diaphragmatic inflammation secondary to pancreatitis, pleural effusions, or ARDS) • Steatorrhea: Fatty and frothy stool that doesn't flush (chronic, cancer) Muscle cramps or spasms (hypocalcemia), in severe cases only • Weight loss: Cancer or Chronic
--	---

✓ **Other Symptoms and DDx:**

- Gallbladder Disease:
 - -Flatulence, dyspepsia and jaundice.
 - Past History of biliary tree disease: previous attack of upper indigestion like abdominal pain with flatulence and belching or jaundice?
- Other GI Symptoms.
- Urinary Symptoms.
- Gynecologic Symptoms.
- Pancreatic cancer:
 - The pain is incessant and boring, accompanied by gastric discomfort, anorexia and weight loss.
 - Steatorrhea, epigastric bloating, flatulence, altered bowel habits.
 - Vomiting.
 - Obstructive Jaundice: Pale stools, dark urine, itching.
 - Respiratory Symptoms (metastasis).

✓ **Past Medical and Surgical History:**

- Previous attacks? Frequency? (2-3 times a year indicate chronic pancreatitis).
- Surgeries: Pancreas, stomach, heart?
- Previous Procedures: Recent ERCP?

- Chronic Diseases: DM; Hyperparathyroidism; Hyperlipidemia (increased LDH).
- ✓ **Medications:**
 - OCPs.
 - Diuretics.
 - Corticosteroids.
 - Antibiotics (tetracycline).
 - Chemotherapy.
 - Opiate analgesics.
- ✓ **Social History:**
 - Alcohol.
 - Smoking.
 - Scorpion sting (very rare).
 - Contact with a person that has Mumps.
- ✓ **Family History:**
 - Of the same condition.

❖ **Physical Examination:**

➤ **General Appearance:**

- Distress
- Pattern of breathing: Shallow
- If respiration is impaired: the patient appears apprehensive, dyspnic and cyanosed
- Pale and Sweating (indicate hypovolemia)
- Movement: the patient lies still
- Jaundice: if the cause is a stone lodged in the lower end of the bile duct or if edema in the head of the pancreas compresses it.

➤ **Vital Signs:**

- Temperature: not usually elevated .
- Heart rate: Tachycardia.
- Blood pressure: if the patient has become hypovolemic, the JVP and blood pressure may be low.

➤ **Inspection of Abdomen:**

- Comment on abdominal movement with respiration (usually none as pain is severe and the tone of the muscles increases).

- Cough tenderness.
- Distention may be present.
- Grey Turner and Cullen's Signs: bruising or discoloration in the left flank or periumbilical region respectively. Those are late and rare signs that indicate extensive destruction of the gland due to retroperitoneal hemorrhage (very severe hemorrhagic pancreatitis).
- **Palpation:**
 - Tenderness and Guarding in the upper abdomen.
 - Pseudocyst: A collection of inflammatory exudates that develops in the lesser sac and This is initially suggested by fullness in the epigastrium, which may become a more prominent mass if a pseudocyst or abscess develops.
- **Percussion:**
 - May cause pain.
 - Dullness may be found over a developing pseudocyst.
- **Auscultation:**
 - Bowel sounds present in the first 12-24 hrs but fade away if a paralytic ileus develops.
- **Mention that you'd like to perform:**
 - Gynecological and pelvic exams, PR, Check pulses and LN.
- **Notes:**
 - You may find: Hepatomegaly in patients with alcoholic pancreatitis, xanthomas in hyperlipidemic pancreatitis, and parotid swelling in patients with mumps.
 - Any patient with severe pain but minimal abdominal signs may have acute pancreatitis.
 - Carcinoma of the head of the pancreas: Obstructive jaundice, a palpable gallbladder and an enlarged liver. In the early stages there are barely any physical signs.
 - Chronic pancreatitis can cause thrombosis of the portal vein (signs of portal HTN will be present). There are often few physical signs, patients often look distraught and disheveled and it's associated with DM.

➤ **Investigations (acute pancreatitis):**

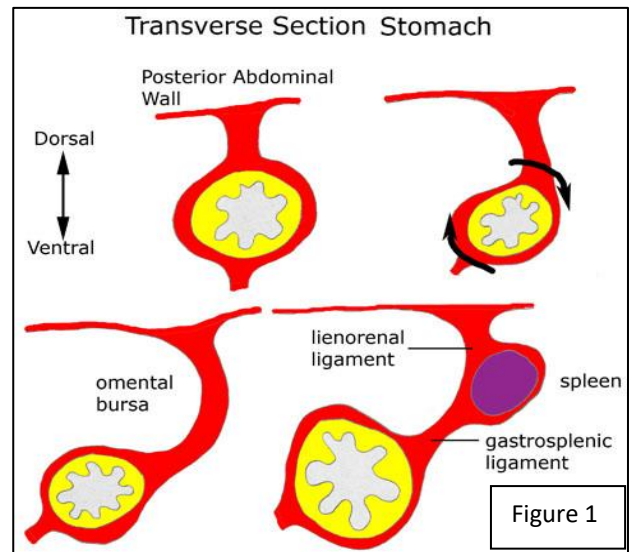
- Serum amylase and lipase: elevated.
 - ALT: >3x (gallstone pancreatitis).
 - CRP: elevated.
 - CBC: leukocytosis.
 - Hematocrit: Elevated.
 - LFT: increased bilirubin.
 - Abdominal X Ray: unremarkable findings in mild.
 - Abdominal US: appears diffusely enlarged and hypoechoic.
 - Abdominal CT.
 - MRI: higher sensitivity than CT.
 - MRCP or ERCP: choledocholithiasis.
-

THE END

Spleen

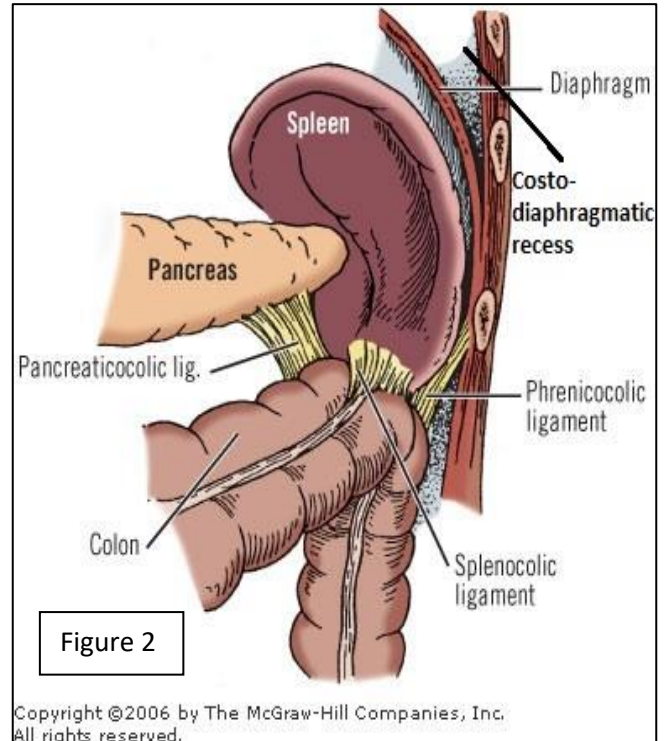
❖ Embryology: [Figure 1]

- Spleen develops from condensations of mesoderm in dorsal mesogastrium of the foregut. (The foregut is the only part of GI tracts which attached by dorsal and ventral mesentery which later form lesser and greater omentum respectively).
- As rotation of the foregut takes place, it becomes located in the upper quadrant of the abdomen.



❖ Anatomy:

- It's an intraperitoneal structure (except the hilum), separated from the stomach by the greater sac.
- It's located in the LUQ (left hypochondrium) between 9th and 11th ribs.
- 12-13 cm long, 7-8 cm wide and 2.5-3.5 cm thick.
- Weights about 75-250 grams.
- **Boundaries:**[Figure 2]
 - Costodiaphragmatic recess of the left pleural cavity extends to the inferior border of a normal spleen.
 - Superiorly: left diaphragmatic leaf.
 - Inferiorly: splenic flexure of the colon and phrenocolic ligament.
 - Medially: greater curvature of the stomach and tail of the pancreas.
 - Laterally: 9-11 Ribs
 - Anteriorly: Stomach.



- Posteriorly: Left kidney.
- **Peritoneal reflections (ligaments):**
 - Splenocolic ligament.
 - Splenorenal ligament.
 - Gastrosplenic ligament.
 - Splenophrenic ligament.
- **Arterial supply:**
 - Splenic artery (branch of the celiac trunk) which is tortuous artery to allow the increase in the spleen size, it runs along the upper border of the body and tail of the pancreas
- **Venous drainage:**
 - Splenic vein and left gastroepiploic vein → to the portal vein.
- **Lymphatic drainage:**
 - Nodes at the hilum → retropancreatic lymph nodes → Celiac lymph nodes.
- **Nerve supply:**
 - Sympathetic supply from the celiac plexus supplies the splenic arterial branches.

Note: 10-20% of population has accessory spleen, most common site is **the splenic hilum (80% of cases)**, it could also be found in gastrosplenic omentum, along the tail of pancreas or in the retroperitoneum.

Splenic artery gives small branches to the stomach called short gastric arteries.

❖ **Physiology and Histology:** [Figure 3]

- The tissue inside the spleen is called the splenic pulp or parenchyma, it's divided into white pulp and red pulp. It's surrounded by a capsule of dense connective tissue.
- **White pulp (20%):** composed of periaarterial lymphatic sheath (T-cells), splenic follicles (B-cells) and marginal zone (macrophages and dendrites). It is a lymphatic tissue concerned with fighting infections and controlling immune response.
- **Red pulp (80%):** composed of splenic cords and sinusoids which are highly vascular structures (RBCs)

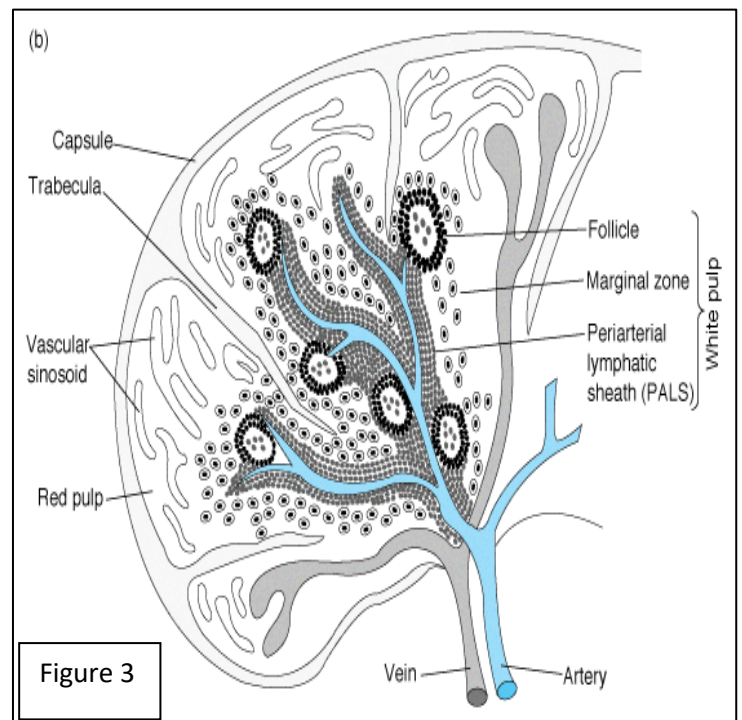


Figure 3

with macrophages, lymphocytes and plasma cells. It is concerned with the destruction of worn-out red blood cells.

❖ **Functions:**

- Filtration of RBCs (NOT storage) → by the red pulp.
- Storage of platelets → 33% of the platelets is stored in the spleen.
- Immunity → by the white pulp. (It produces tuftsin, properdin and antibodies, and it's also site of phagocytosis).

Properdin and tuftsin are non-specific opsonins.

Extra pieces of information for the love of our spleen: [Figure 3]

- The capsule sends extensions to the spleen called trabeculae.
- The splenic artery gives branches called trabecular arteries which follow the course of trabeculae, as each trabecular artery enters the white pulp it becomes the central artery.
- Periarterial lymphatic sheath (T-cells) surrounds each central artery, with follicles filled with B-cells scattered around them.
- Marginal zone located between white pulp and red pulp and is filled with macrophages and dendritic cells.
- Splenic cords contains all types of cells (lymphocytes, macrophages..) with RBCs and Sinusoids are blood filled spaces with large lumen and large pores within their endothelial cells.
- As the blood enters the spleen via central arteries it's being filtered from foreign antigens using immune cells in the white pulp.
- Central arteries give end-arteries that open to the splenic cords, and then it's translocated to the sinusoids through the endothelial pores. As this happen, damaged RBCs are forbidden from entering through the pores and left to be destructed by the cells in splenic cords.

❖ **Main Investigations:**

- History and physical exam: very important in the diagnosis of splenomegaly (we look for signs of anemia or portal hypertension).
- Laboratory investigations: important in diagnosis of hemolytic anemia or liver dysfunction.
- Endoscopy: used in the diagnosis of esophageal varices associated with portal hypertension.
- Lymph node biopsy may be required as many diseases that cause splenomegaly are associated with lymphadenopathy.
- Imaging:
 - Plain radiography is rarely done (may reveal calcifications).
 - Ultrasound can determine the size and consistency of the spleen.

- CT scan with contrast is **more commonly** done to reveal any splenic pathology.
- Radioisotope scanning is used occasionally to provide information about the spleen.
- The use of technetium-99m (^{99m}Tc)-labelled colloid is normally restricted to determining whether the spleen is a significant site of destruction of red blood cells.

Splenectomy



INTRODUCTION

- **Definition:** It's the surgical removal of the spleen.
- It can be done via **laparoscopy** or **open** surgery.
- **Contraindications for laparoscopic splenectomy:**
 - **Absolute:**
 1. Portal hypertension
 2. Splenic trauma with an unstable patient.
 3. Massive splenomegaly (>30 cm long).
 - **Relative:**
 1. Morbid obesity.
 2. Splenic vein thrombosis.
 3. Moderate splenomegaly (>20-25 cm long).
 4. Splenic trauma with a stable patient.
 5. Marked uncorrectable cytopenia.
- **Open splenectomy incisions:**
 1. Midline (preferred).
 2. Left subcostal incision.
- **Preoperative consideration:**
 - Vaccinations for encapsulated bacteria two weeks prior to surgery:
 1. Strep Pneumonia.
 2. Haemophilus influenzae type B.
 3. Neisseria meningitides.

Remember that: by losing the spleen we are losing its immunogenic role in detecting foreign antigens.

- Antibiotic prophylaxis appropriate to the operative procedure should be given.
- Transfusion consideration, especially in patients with a hematological disease; cross match should be done, and fresh-frozen plasma, cryoprecipitate or platelets may be needed.
- Imaging; Ultrasound and CT scan to determine the spleen size. Nuclear imaging can be done to reveal the presence of an accessory spleen.
- Embolization of the splenic artery preoperatively in order to decrease spleen size.

- **Postoperative considerations:**

- Complete response if platelets count more than $100 \times 10^9/L$.
- Partial response if platelets count more than $30 \times 10^9/L$.
- If platelets failed to increase → look for accessory spleen.
- Abnormal findings on peripheral smear post-splenectomy (these are normal in a person without a spleen):
 - Pappenheimer bodies.
 - Howell-Jolly bodies.
 - Heinz bodies.
- Abnormal lab tests post-splenectomy (bad signs):
 - Increase in WBC >50%.
 - Marked thrombocytopenia.

Why does the platelets' level increase post-splenectomy?

*Because spleen used to store those platelets (33%).

- **Complications:**

- **Intra-op:**
 - Hemorrhage (due to hilar distention, capsular tear or injury to a blood vessel).
 - Pancreatic injury (especially the tail).
 - Small bowel, colon or stomach injury.
 - Diaphragmatic injury.
 - Pancreatic gastric dilation. (rare)

Note: if suspected injury to the pancreatic tail during surgery, a drain should be placed.

- **Early:**
 - Left basal pulmonary atelectasis (with pleural effusion) → most common complication.
 - Subphrenic abscess which is usually accompanied with left pleural effusion (treated by percutaneous drainage and IV antibiotics).
 - Wound problems (Hematoma, seroma or wound infection).

- Thrombocytosis (If > 1 million Aspirin should be given) which can cause splenic or portal vein thrombosis.
- Postoperative ileus.

➤ **Late:**

- Overwhelming postsplenectomy sepsis (OPSS):
 - Increased susceptibility to fulminant bacteremia, meningitis or pneumonia as a result of losing splenic immunogenic role.
 - Incidence < 1% in adults.
 - Increased risk in young patients (< 4 years).
 - Most septic episodes occur within 2 years after splenectomy.
 - Clinical presentation: Fever, lethargy, common cold, sore throat and URTI followed by confusion, coma and death within 24 hours in 50% of patients.
 - Organisms: S.Pneumonia, H.influenzae and N.meningitides.
 - Prevention: daily prophylactic antibiotics (especially for children and immunocompromised) and vaccinations.
- Splenosis:
 - It's the presence of disseminated intraabdominal splenic tissue.
 - It's not common after laparoscopic splenectomy, but care should be taken during the procedure to avoid bag rupture and spillage of splenic tissue.

? ETIOLOGY

Indications for splenectomy:

- Before starting discussing the indications for splenectomy, we have to differentiate between two terms; Hypersplenism and splenomegaly:

Splenomegaly: Enlargement of the spleen.

Hypersplenism: is an indefinite clinical syndrome that is characterized by splenic enlargement with any combination of anemia, leukopenia or thrombocytopenia, compensatory bone marrow hyperplasia and improvement after splenectomy.

- Few conditions that cause splenomegaly will require splenectomy as part of treatment.
- In hypersplenism, Careful clinical judgement is required to balance the long- and short-term risks of splenectomy against continued conservative management.

1. **Trauma:** Resulting from an accident (blunt) or during a surgical procedure (iatrogenic).

Splenic trauma will be discussed in details in the next section.

2. **Thrombocytopenia:**

➤ **Idiopathic thrombocytopenic purpura (ITP):**

- Results from the development of antibodies (IgG) to specific platelet membrane glycoproteins that damage the patient's own platelets.
- Acute ITP in children often follows an acute infection and has a spontaneous resolution within months.
- Chronic ITP in adults and women persists longer than six months without a specific cause being identified.
- Treatment: First line is corticosteroids [only 20% have a sustained response]. If refractory to medical treatment or in patients with intracranial hemorrhage **splenectomy** is indicated (sustained remission in 75% of patients).

ITP is the most common cause for elective splenectomy.

Splenectomy eliminates the primary source of antibodies plus the site of platelets destruction.

➤ **Thrombotic thrombocytopenia purpura (TTP):**

- RARE!
- Rapidly progressive and usually fatal.
- Platelets are consumed in the formation of microthrombi and RBCs are sheared as they cross microthrombi causing resulting in hemolytic anemia.
- Diagnostic pentad: **FAT RN**
 - ✓ **F**ever, **A**nemia, **T**hrombocytopenia, **R**enal dysfunction and **N**eurological dysfunction.
- Treatment: First line is plasmapheresis (plasma exchange). **Splenectomy** reserved for patients with relapse or requiring multiple plasma exchanges as a last resort.

Microthrombi formation results from the lack of VHL degradation caused by ADAMTS13 enzyme deficiency.

Transfusion platelets in TTP is thought to “fuel the fire” and exacerbate consumption of platelets and clotting factors resulting in more thrombi in microvasculature. That’s why plasmapheresis is the treatment of choice and not transfusion.

3. **Anemias:**

➤ **Hereditary spherocytosis:**

- It is an autosomal dominant hereditary disorder characterized by the presence of spherocytic red cells.

- spherocytic red cells are going to be filtered by the spleen resulting in anemia.
- **Splenectomy** is curative but should be delayed until the age of 4 to minimize the risk of post-splenectomy infection.
- **Autoimmune hemolytic anemia:**
 - Caused by autoantibody (IgG and IgM) formation against RBC membrane proteins.
 - Antibody coated RBCs (especially with IgG) are destructured in the spleen resulting in anemia.
 - Treatment: first line is medical treatment with corticosteroids (response in 75%). **Splenectomy** can be done in cases refractory to medical treatment (response in 80%).
- **Sickle cell anemia:**
 - Sickle cell disease is an autosomal recessive hemolytic anemia in which the normal haemoglobin A is replaced by haemoglobin S (HbS).
 - The HbS molecule crystallizes when the blood oxygen tension is reduced, thus distorting and elongating RBCs.
 - The resulting increased blood viscosity may obstruct the flow of blood in the spleen.
 - **Splenectomy** is of benefit in a few patients in whom excessive splenic sequestration of red cells aggravates the anemia.
 - Autosplenectomy usually occurs secondary to repeated vaso-occlusive events and splenectomy is rarely required.
- **Thalassemia (especially β major “Coleey’s anemia”):**
 - Autosomal dominant inheritance characterized by defective hemoglobin(α or β) synthesis.
 - Causes severe anemia and hepatosplenomegaly.
 - Blood transfusion may be required to correct profound anaemia.
 - **Splenectomy** is of benefit in patients who require frequent blood transfusion.
- **Myelofibrosis and myeloid metaplasia:**
 - They are incurable myeloproliferative disorders that usually present in patients older than 60 years.

HbS results from change of glutamic acid to valine in the sixth amino acid position on the beta chain in hemoglobin.

- The condition is characterized by bone marrow fibrosis, leucoerythroblastic anemia, and extramedullary hematopoiesis, which can result in massive splenomegaly.
- Indications for **splenectomy** include symptomatic splenomegaly and transfusion dependent anemias.

4. Malignancies:

- **Hodgkin lymphoma:** **Splenectomy** used to be part o the staging but is now rarely indicated because the additional information does not alter therapy.
- **Leukemias or non-Hodgkin lymphoma:** they result in hypersplenism and **splenectomy** may be indicated in select patients to treat hypersplenism and thrombocytopenia.
- **Splenic tumors:** primary, metastasis (isolated splenic mets are rare) or locally invasive tumors.
 - **Splenectomy** indicated for indeterminate or suspicious lesions (to confirm or exclude malignancy).
 - **Splenectomy** for splenic cysts if larger than 5 cm is indicated.
 - Benign, stable hemangiomas contrast enhanced CT do not necessarily require **splenectomy**.

Splenic tumors:

- Benign: Hemangioma/ lymphoma/ hamartoma/ primary cyst, pseudocyst or echinococcal cyst (hydatid cyst).
- Malignant: lymphoma/myeloproliferative disorder or metastasis.

5. Miscellaneous indications:

- Bleeding esophagogastric varices associated with **splenic vein thrombosis**. **Splenectomy** is curative.
- **Gaucher's disease:** It's a lipid storage disease characterized by storage of glucocerebroside in the reticuloendothelial system and in the spleen. **Splenectomy** is indicated only for severe symptoms related to the splenomegaly.
- **Splenic abscess:**
 - Caused by splenic seeding (most commonly from endocarditis), Infection from adjacent structure, hematoma or IV drug abuse.
 - Presented with fever, chills, LUQ tenderness, guarding and splenic mass(not always palpable).
 - Diagnosed by U/S and CT scan.
 - Can be complicated to peritonitis or sepsis if rupture took place.

*Most common cause of isolated gastric varices is splenic vein thrombosis

*Most common cause for splenic vein thrombosis is pancreatitis.

- Treatment: treating the underlying cause and percutaneous drainage under radiological guidance. **Splenectomy** only for refractory cases.
 - **Felty's syndrome:** It's the triad of rheumatoid arthritis, leukopenia and splenomegaly. **Splenectomy** produces only a transient improvement in the blood picture, but rheumatoid arthritis may respond to steroid therapy.
 - **Splenic artery aneurysm:** should be repaired if symptomatic, >2 cm or any size in a women in child bearing age (or pregnant female) by either endovascular treatment or open surgery. For aneurysms located in distal splenic artery, **splenectomy** is performed.
 - **Hypersplenism as a result of portal hypertension:** **Splenectomy** would only be required in those patients whose portal hypertension has resulted in symptomatic esophagogastric varices.
 - **Primary hypersplenism:** As a result of a primary disease of the spleen, very rare and a diagnosis of exclusion.
-

Splenic Trauma



INTRODUCTION

- **Definition:** Blunt trauma causing injury to the splenic tissue.
- It's graded from grade I-V according to specific grading system (Hematoma, laceration, rupture...). And according to the grade the management can be decided.
- Previously the first line management of any splenic trauma was splenectomy; nowadays, many cases of traumatic splenic injury can be managed nonoperatively.

But it's still one of the most common causes of splenectomy.

Most common causes for splenectomy: 1) ITP 2) Trauma



ETIOLOGY

- Blunt trauma.
- Iatrogenic trauma (during mobilization of the esophagus, stomach, distal pancreas or splenic flexure of the colon).



CLINICAL FEATURES

- **Major symptom:** LUQ pain.
- **Signs:**
 - Signs of peritoneal irritation.
 - External signs of injury.
 - Kehr's sign (Left shoulder pain from diaphragmatic irritation especially when a person is lying down and the legs are elevated).
 - Ballance's sign (LUQ dullness to percussion).
 - Seagesser's sign (Phrenic nerve compression causing neck tenderness).
 - Hemoperitoneum.
 - Shock.
 - Left sided lower rib fracture.
- **Late Complications:**

- Missed splenic injury: those with delay in diagnosis of splenic trauma have a ten-fold increase in mortality. It is therefore important to have a high index of suspicion for this diagnosis when evaluating patients with blunt trauma.
- Delayed splenic rupture: subscapular hematoma or pseudoaneurysm two weeks after rupture after splenic. Results as shock (Abdominal pain). Signs and symptoms are similar to those of any splenic injury mentioned before).
- Splenic pseudocyst.



DIAGNOSIS

- If stable patient → DPL or FAST exam.
- If unstable patient → CT.

DPL= Diagnostic peritoneal lavage (aspiration).

FAST= Focused assessment with sonography for trauma is a rapid bedside ultrasound examination.



TREATMENT

- If stable patient with an isolated splenic injury without hilar involvement nor complete rupture → Non-operative treatment.
- If unstable patient → Laparotomy with splenorrhaphy or splenectomy.
- Embolization of the splenic artery can be done pre-op in selected patients.

Splenorrhaphy= Splenic salvage operation= Wrapping visceral mesh and adding topical hemostatic agents. partial splenectomy maybe done then suturing of the spleen is persumed.

Liver & biliary tree

- Written by: Alma Jarkas & Russole Emad

- Liver: 108
 - Introduction: 108
 - Abscesses of the liver: 119
 - Hydatid disease 122
 - Tumors of the liver: 128
 - Haemobilia: 134
 - Portal HTN: 136
- Biliary tree: 142
 - Introduction: 142
 - Gallstones : 149
 - Acute cholecystitis: 157
 - Choledochal cyst: 162
 - Choledocholithiasis: 164
 - Cholangitis: 167
 - Gallstone ileus: 172 .
 - Biliary system tumors: 174

Liver

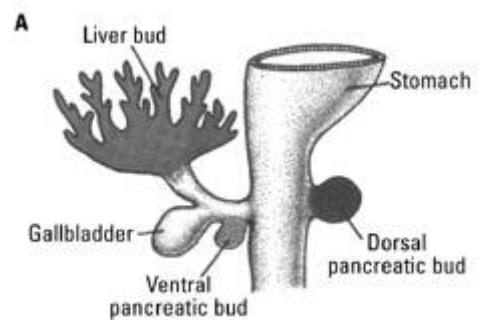
Embryology:

-It starts as a hepatic duct/diverticulum just proximal to the ampulla of Vater, at the same area where the pancreatic duct arises.

The hepatic duct arises at the ventral aspect and rotates 90 degrees clockwise, and that's why the liver is on the right.

The diverticulum divides into:

1. Cranial part>>>> gives rise to CBD, right and left hepatic duct & the liver.
2. Caudal part (smaller)>>>> gives rise to the cystic duct and gallbladder.

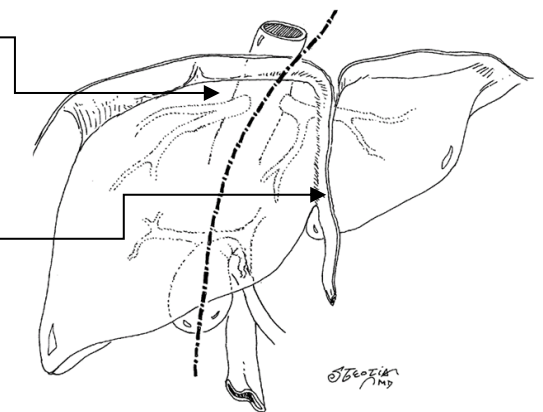


The liver grows very rapidly, especially during the 5th to 10th weeks of gestation because the blood is produced from the liver and spleen during this period.

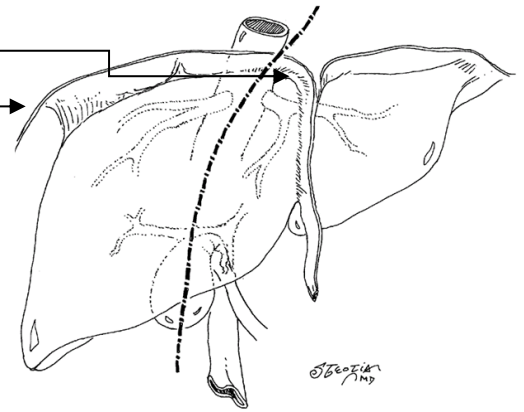
The liver is relatively very huge, leaving no space in the peritoneal cavity, this will push the small bowel outside, a process called physiologic herniation.

Anatomy:

- **The Bare area of the liver:** the posterior section of the liver against the diaphragm that's "bare" without a peritoneal coverage.
- **Glisson's capsule:** the capsule of the liver.
- **Cantle's line:** line drawn from the gallbladder to a point just to the left of the IVC, which transects the liver into left and right lobes.
- **Falciform ligament:** a ligament that goes from the anterior abdominal wall to the liver and contains ligamentum teres-obligated umbilical vein.

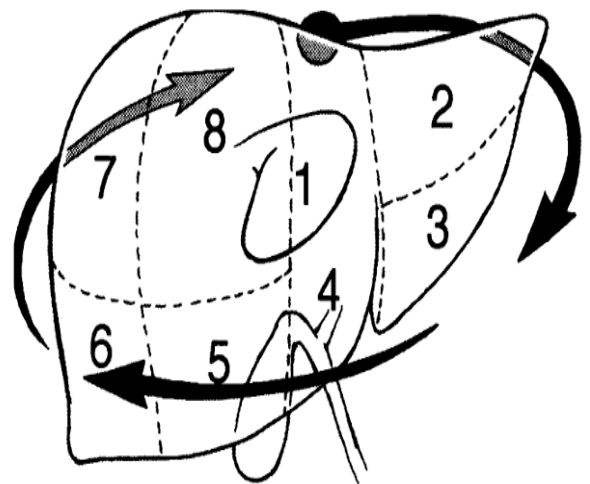
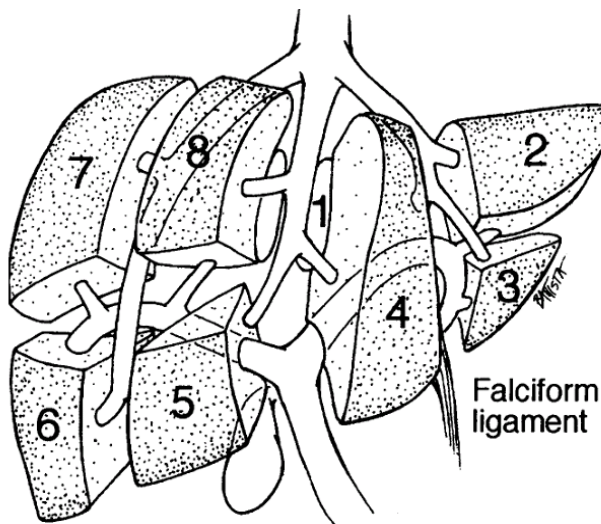


- **Coronary ligament:** peritoneal reflection on the top of the liver that crowns the liver and attaches it to the diaphragm.
- **Triangular ligament:** right and left lateral extensions of the coronary ligament (which form triangles).



Segments of the liver: the liver is divided into functional Rt and Lt lobes by a line passing from the left of the gall bladder fossa to the left of IVC, this line is known as Cantlies' line

- Clockwise starting from segment 1



- French system.
- Notice the relation of the gallbladder to the 4th and 5th segments.

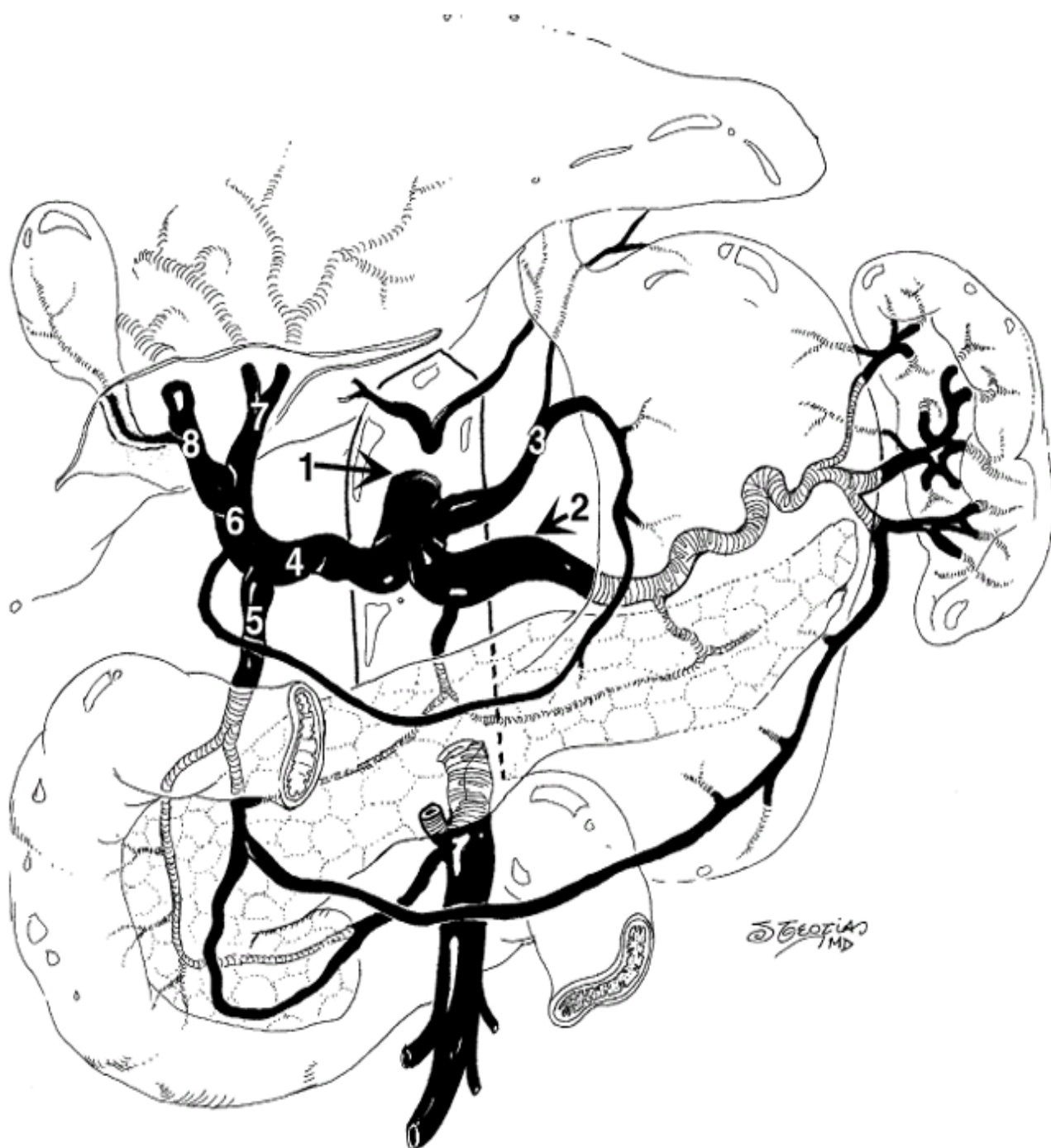
Blood supply:

- Celiac trunk from the aorta.

Branches of the celiac trunk:

- The left gastric artery.
- Splenic artery.
- Common hepatic artery.

Observe the celiac trunk and its branches in the figure in the next page



1. Celiac trunk
2. Splenic artery
3. Left gastric artery
4. Common hepatic artery
5. Gastroduodenal artery
6. Proper hepatic artery
7. Left hepatic artery
8. Right hepatic artery

Venous drainage:

- Portal vein that's formed by the union of the Superior mesenteric vein (SMV) and splenic vein.
- Hepatic venous drainage via the hepatic veins (3 veins: left, middle and right) >>> drain into IVC.

Notes:

- Sources that provide oxygen to the liver are the portal vein (50%) and the hepatic arterial blood (50%).
- Sources from which the liver receives blood are the portal system (75%) and the hepatic artery (25%).
- The maximum amount of the liver that can be resected while retaining adequate liver function is more than 80%, i.e. if given adequate recovery it will regenerate
- **Child's classification:**

-A classification that estimates hepatic reserve in patients with hepatic failure and mortality rates.

	Ascites	Bilirubin	Encephalopathy	Albumin	PT
A	None	<2	None	>3.5	1.7
B	Mild	2-3	Minimal	2.8-3.5	1.7-2.2
C	Marked	>3	Severe	<2.8	>2.2

Interpretation:

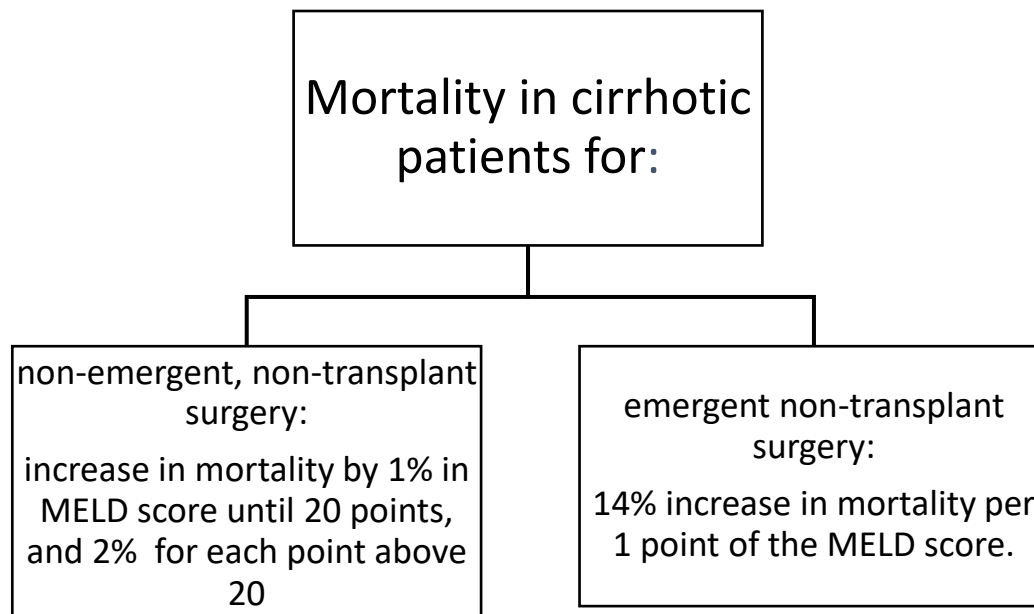
class	Overall mortality
A	10%
B	30%
C	75%

MELD Score (Model for End-stage Liver Disease):

-Used more than child's.

-it's the formula currently used to assign points for prioritizing position on the waiting list for deceased donor liver transplant, based on INR, bilirubin and creatinine, with extra points given for the presence of liver Ca. You can find a good calculator online.

Measurements are : INR, total bilirubin, Serum creatinine .



Physiology:

Liver function tests:

Full work up:

- 1- Transaminases (ALT,AST)
- 2- Alkaline phosphatase
- 3- PT/INR
- 4- Bilirubin
- 5- Albumin
- 6- GGT
- 7- CBC

AST and ALT:

- They don't really test liver function BUT they are a reflection of hepatocellular injury as they reflect hepatocytes function
- **ALT** is more specific to the **Liver** than AST
- AST also increases in MI, skeletal damage and hemolysis.

	AST	ALT	AST:ALT	MCV
Alcoholic liver disease	↑↑	↑	AST>ALT 3:1 (>2)	↑↑
Viral hepatitis	↑	↑↑	AST<ALT <1	↔
NAFLD	↑	↑↑	AST<ALT	↑ or ↔

*NAFLD: non alcoholic fatty liver disease.

➤ Albumin:

- Decreases in liver disease.

➤ Alkaline phosphatase:

- Found in liver, bone, GI, kidneys and placenta.
- It increases in cholestasis.
- It varies with age (It's higher in males) and gender (in children, it's 3 times higher because it correlates with bone growth). And it's two times higher in pregnancy because it's produced by the placenta.

➤ Gamma Glutamyl Transpeptidase GGT:

- Rises in parallel with alkaline phosphatase from the liver.
- It should be checked in cases of **raised alkaline phosphatase** with normal bilirubin and transaminases.
- If both alkaline phosphatase and GGT are elevated, then we should perform an abdominal ultrasound to look for dilated bile ducts.
- If only GGT is elevated, then we should investigate the usage of the following drugs:
 - ♣ Barbiturates(CNS depressants used for anesthesia, anxiolysis, hypnosis and anti-convulsants), Carbamazepine(epilepsy), phenytoin(anti-seizure drug)

- ♣ Ethanol
- ♣ Steroids
- ♣ INH (isoniazid is a TB medication) , rifampicin(antibiotic).

➤ **PT:**

- Detects the Severity of hepatocellular injury, it's the most sensitive test for severity because it's only affected by severe liver diseases not moderate ones.
- PT and serum ammonia reflect the metabolic function of the hepatocytes.

➤ **Bilirubin:**

- It's either:

- ♣ Conjugated: direct.
- ♣ Unconjugated: Indirect (without bilirubinuria).

- Bilirubinuria is an indication of cholestasis.

Overall:

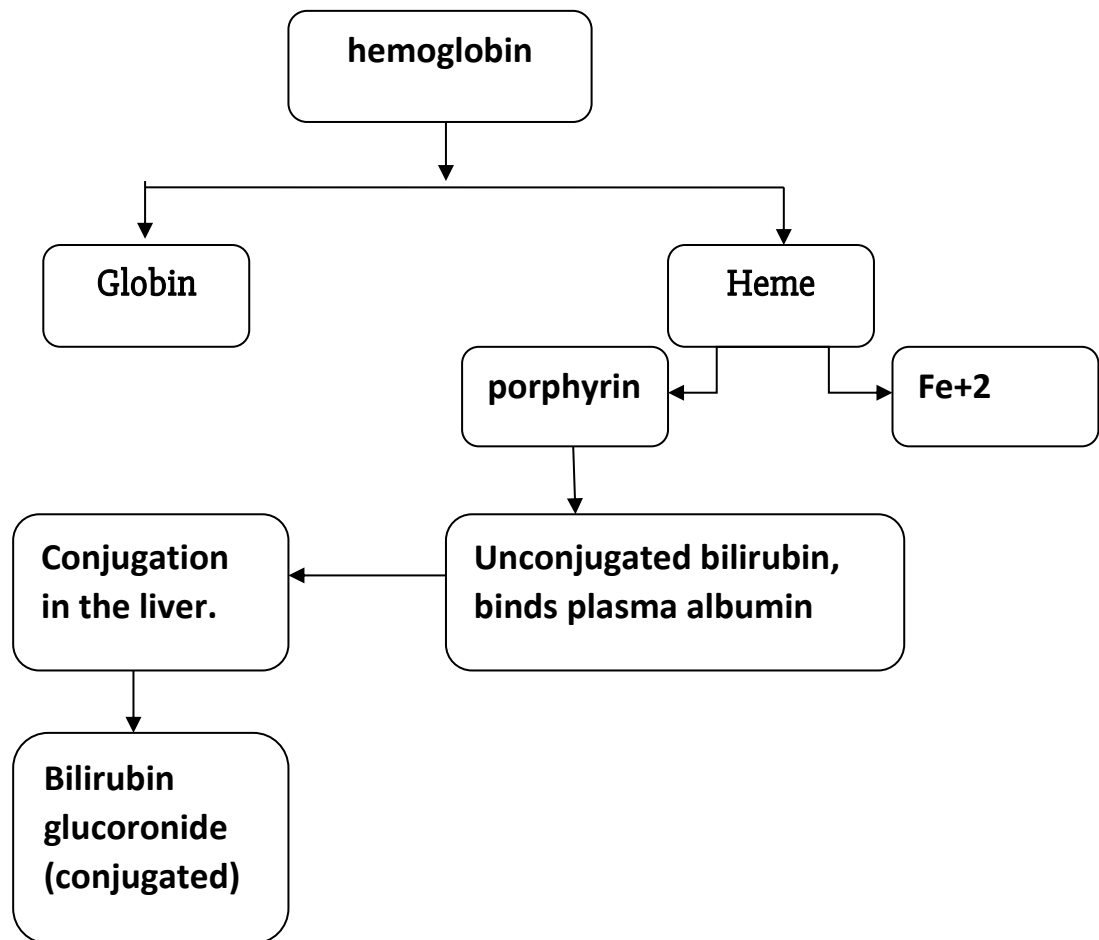
Hepatocytes function	AT, ALT
Synthetic function and metabolism	PT/INR, factor V & VII, albumin, bilirubin
Biliary canalicular function	ALP, 5 Nucleotide, GGT, bilirubin

Main signs and symptoms of liver disease:

1-Jaundice:

- **Definition:** Yellowish discoloration of the skin and mucus membranes, caused by an excess of bile pigments in the plasma.
- Jaundice is clinically detected when [Bilirubin] >2.5-3 g/dL.
- The appearance of jaundice depends on the type of bilirubin elevated and the duration.

Metabolism of hemoglobin:



In the small bowel, Bilirubin glucoronide is converted to stercobilinogen, by intestinal bacteria, and then into stercobilin, that gives the brown color of stool, and stercobilinogen is also converted in the kidneys into urobilinogen and then into urobilin that gives the urine its color.

➤ Causes of increased bilirubin:

- Overproduction by reticuloendothelial system.
- Failure of conjugation or excretion.
- Obstruction of biliary excretion into intestines.

Hyperbilirubinemia

Unconjugated/pre-hepatic and hepatic:

Due to:

- ↑RBC destruction
- ↓hepatic bilirubin conjugation

Conjugated/mostly due to post-hepatic:

Due to obstruction(surgical jaundice).

1-Prehepatic jaundice:

➤ Could be due to:

- Excessive production of bilirubin.
- ability of liver to conjugate is overcome.
- increased plasma unconjugated bilirubin.

➤ Differential diagnosis:

1-hemolysis, hematoma resorption or multiple blood transfusions.

2-Gilbert syndrome.

3-Criglar-Najjar syndrome.

Lab tests indicating hemolysis:

↑LDH.

↓ serum haptoglobin.

Evidence of hemolysis on blood film.

2-Hepatic jaundice:

➤ The defect could be in one of the following processes:

1-uptake. 2-conjugation. 3-secretion.

➤ It reflects liver dysfunction (↑ alkaline phosphatase, ↑↑↑AST/ALT)

➤ Differential diagnosis:

1-Viral hepatitis.

2-Medications: erythromycin/INH/phenytoin/valproate/OCP

3-Alcohol abuse.

4-cirrhosis.

♣ Gilbert syndrome:

- An inborn error in liver bilirubin uptake and glucuronyl transferase resulting hyperbilirubinemia (Think **Gilbert=Glucuronyl**), leading to intermittent asymptomatic jaundice in the 2nd or 3rd decade of life.
 - It's a benign condition affecting up to 7% of the population.
 - Affected people may have jaundice after stress or infection.
- So, the cause of unconjugated hyperbilirubinemia in Gilbert syndrome is both \uparrow RBC production and \downarrow hepatic conjugation.

3-Post-hepatic jaundice:

➤ Characterized by:

- \uparrow conjugated bilirubin
- $\uparrow\uparrow$ alkaline phosphatase & GGT.
- \pm AST, ALT.

➤ Effects of obstructive jaundice:

- In liver: enlarged green bile stained liver (hydrohepatitis) and dilated intrahepatic biliary tracts. Once intraductal CBD pressure increases the bile secretion from the liver is reduced causing the formation of "white bile" in CBD. Biliary cirrhosis may develop later.
- In the biliary tree: recurrent inflammation from cholangitis for example causes the fibrosis of biliary tracts.
- In bowel: absence of bile from bowel impairs digestion, reduces fat absorption making feces bulky and fatty. In addition, vit K absorption is reduced causing fall in prothrombin levels and raising PT/INR.
- Altered coagulation profile and as result hepato renal syndrome and renal failure.

Cholestatic syndrome:

Characteristics:

- Conjugated hyperbilirubinemia (dark urine, pale stool & pruritis)
- Chronic malabsorption of lipid-soluble vitamins.

➤ **Causes:**

- Secondary to biliary obstruction (post-hepatic/ surgical).
- Hepatic jaundice (AKA: non-obstructive/medical jaundice).

➤ **Clinical presentation:**

- jaundice
- pale color stool (due to absence of fecal bilirubin)
- Dark urine (↑conjugated bilirubin)
- Itching.

Differential diagnosis for proximal bile

Differential diagnosis for proximal bile obstruction:

- 1-Gallbladder stones.
- 2-Gallbladder cancer.
- 3-Cholangiocarcinoma.
- 4-Benign bile duct tumor.
- 5-Primary sclerosing cholangitis.
- 6-Parasites.
- 7-Metastatic tumor.
- 8-Metastatic tumor.
- 9-Lymphadenopathy.

Differential diagnosis for distal bile

Differential diagnosis for distal bile obstruction:

- 1-Choledocholithiasis
- 2-Benign bile duct tumor
- 3-Ampullary cancer
- 4-Pancreatic cancer or pancreatitis
- 5-Pseudocyst
- 6-Lymphadenopathy or lymphoma
- 7-Post-operative stricture.
- 8-Parasite.

➤ **Diagnostic test of choice is ultrasound.**

Abscesses of the liver



INTRODUCTION

- **Definition:** a collection of pus in the liver parenchyma.
- **Types:**
 - Pyogenic (bacterial)
 - Parasitic (amebic)
 - Fungal.
- Most common site is the right lobe.



ETIOLOGY

- **Sources:**
 - 1- Direct spread from biliary tract infection.
 - 2- Portal spread from GI infection (example: appendicitis, diverticulitis).
 - 3- Systemic source (bacteria).
 - 4- Liver trauma (example: liver gunshot wound).
 - 5- Cryptogenic (unknown source)
- **the two most common types are :**
 - ♣ bacterial (most common in USA).
 - ♣ amoebic (most common worldwide).
- **Bacterial liver abscess:**
 - The most common pathogens are gram negative bacteria: E.coli, Klebsiella and proteus.
 - **Causes:**
 - ♣ Cholangitis
 - ♣ Diverticulitis
 - ♣ Liver Ca/ metastasis



CLINICAL FEATURES

Signs and symptoms:

- Fever and chills
- -RUQ (right upper quadrant) pain
- Jaundice
- weight loss
- ↑WBC
- ↑LFT
- sepsis



TREATMENT

Medical: IV antibiotics (triple antibiotics with metronidazole)

Surgical: percutaneous drainage with CT or U/S guidance.

Indications for operative drainage:

- Multiple/loculated abscesses
- When multiple percutaneous attempts have failed.

Amebic liver abscess:

➤ **Pathogens :**

Entameba Histolytica (typically reaches the liver via portal vein from intestinal amebiasis).

➤ **Spread:** feco-oral transmission.

➤ **Risk factors :**

- Patients from south American borders.
- Institutionalized patients.
- Homosexual men.
- Alcoholic patients.



CLINICAL FEATURES

➤ Signs and symptoms:

- RUQ pain.
- Fever (chills are much less common with amebic abscess than pyogenic).
- Diarrhea.
- Hepatomegaly.

➤ Most common site is the right lobe.

➤ Diagnosis:

- Labs (Indirect hemagglutinin titers for entameba antibodies in 95% of patients and ↑ LFTs).
- U/S and CT.



TREATMENT

➤ Medical:

- Metronidazole.

➤ Surgical:

- Percutaneous drainage is done in the following cases:
 - ♣ refractory to metronidazole.
 - ♣ bacterial co-infection.
 - ♣ peritoneal rupture.
- Possible complication of large left lobe abscess : Erosion of pericardial sac (potentially fatal).

Hydatid disease of the liver

also known as echinococcosis or echinococcal disease

INTRODUCTION

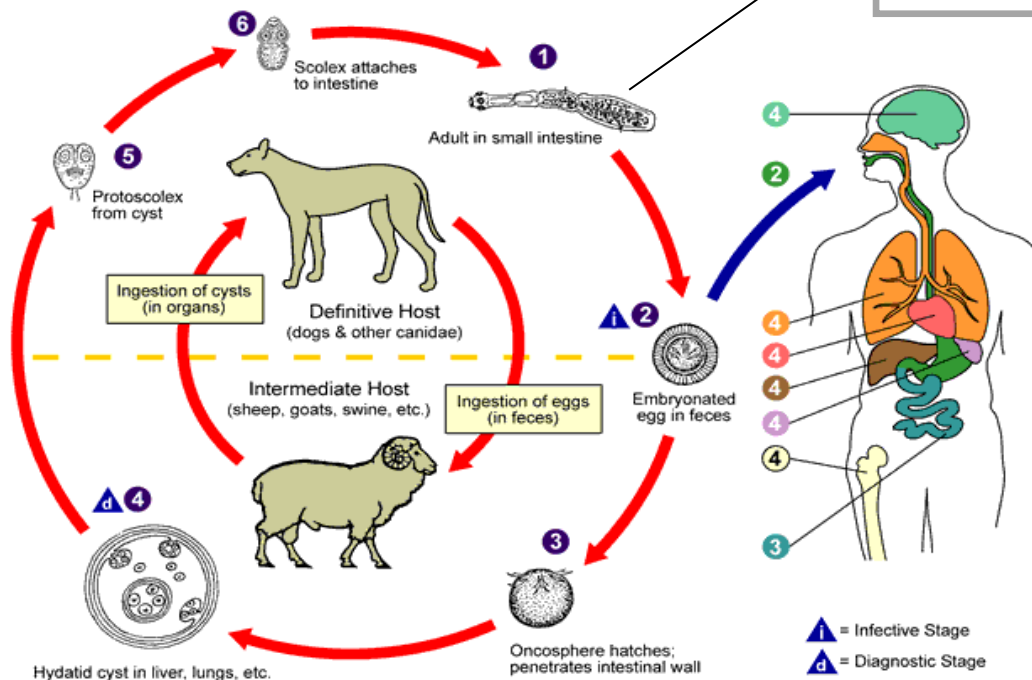
- ✓ It is a parasite disease of dog tape worm (Echinococcus), which affects humans in 2 forms depending on the larval stage:
 - I. Cystic Echinococcus : most common caused by Echinococcus granulosus
 - II. Alveolar Echinococcus : caused by Echinococcus multilocularis
- ✓ The disease affects both humans and animals like: dogs, pigs, camels, sheep, rodents, and horses.
- ✓ Life cycle:

A year after the infection of dogs protoscolices are produced.

Morphology:

Head (scolex) → 2 rows of hooks, 4 suckers.

Body → 2-6 proglotid.



Notes:

- The major (most common) intermediate host is the sheep (also pigs, horses, and camels).
- The major definitive host is the DOG (also foxes, and wolves)
- Infection of the intermediate host occurs after the ingestion of food contaminated with eggs containing embryos (oncospheres) passed from feces of the definitive host.
- Humans are infected via 2 ways: 1) direct contact with dogs 2) eating products contaminated by the feces of the definitive host, but never by eating infected intermediated host!!
- Humans are intermediate host if the dog ate human infected organs however this is not common so humans are considered end hosts.

✓ distribution of the disease:

- I. Endemic areas are: Mediterranean countries, middle east, Asia, turkey, south America, Newzeland, and Africa.
- II. Uncommon in USA and most of central Europe.

? ETIOLOGY

-The intermediate host (human) ingests the embryonated egg → the eggs which contain embryos (onchspheres) hatch and penetrate the wall of the intestines → the embryos reach the liver via the blood stream → the embryos may pass via the blood to other organs (mostly the lungs)

Once the embryos settle in an organ they form cysts.

Notes:

- I. The liver is affected (diseased) in 60% of the cases while the lungs are affected in 30% of the cases. In 90% of the cases there is single organ involvement.
- II. The Right lobe of the liver is mostly affected in 80% of the cases when the liver is affected, and in third of the cases the cysts are multiple.

➤ Components of the cyst:

- The cavity is filled with Hydatid fluid.
- The cyst has got 3 layers covering it from outside to inside →
 - I. Outer adventitial layer (pseudocyst) is an inseperable fibrous tissue due to reaction of the liver to the parasite. (coming from the host)
 - II.2 inner layers coming from the parasite:
 - ♣ Outer laminated membrane (ectocyst) contains Hydatid fluid and can be readily peeled from the adventitia.
 - ♣ Inner germinal epithelium (endocyst) the only living part lining the cyst, this layer :synthesizes the laminated layer which is a mucopoly sacccharide –protein –lipid complex, and secretes the Hydatid fluid which is clear and similar to interstitial fluid .
- Sometimes a small cyst within the cyst exists, if this cyst was attached to the germinal layer it is called brood capsule, but if it was floating in the Hydatid fluid it is called daughter cyst.
- The Hydatid fluid or the rood capsule or the daughter cyst contain scolices which are heads of future worms.

Notes:

- The time required of *Echinococcus granulosus* to become mature (ready to infect humans or dogs) varies from 10 to 20 minutes
- Daughter cyst: also known as degenerated or secondary cyst have fragment of germinal layer and can develop by 2 ways:
 1. Develop within the primary cyst (as above)
 2. Develops separately
- Commonly the cysts in the liver after 5-10 years begin calcifying , the complete calcification indicates an old cyst but not necessarily a dead cyst .

➤ Risk factors of infection:

- I. Travel.
- II. Exposure to dogs, and (sheep & cattle: although that we mentioned above that they are not infective).



CLINICAL FEATURES

➤ Signs and symptoms:

- Most of the times the cyst remain uncomplicated and the symptoms they induce are related to the pressure or mass size (when the size is > 10cm) they exert on the liver, so the signs and symptoms are:
 1. RUQ pain: most common symptom.
 2. Liver enlargement or palpable mass : 1-5 cm increase in size per year
 3. Jaundice and pressure symptoms.
 4. Sometimes the cyst rupture or leaks some of its contents (suppuration) which may cause anaphylactic reactions which can be fatal or subclinical manifestations.
- The rupture or suppuration may occur into:
 1. Biliary tree
 2. Thorax
 3. Peritoneum
 4. Vascular structure
 5. GI tract

➤ **Diagnosis:**

1. Blood tests:

- ♣ Most cases have limited eosinophilia due to the chronic presence of the parasite, or absent eosinophilia.
- ♣ If there was biliary communication: increased liver function tests.



2. Serology:

- ♣ for detection of anti Echinococcus antibodies (AKA indirect hemagglutination test).
- ♣ Antibodies detection is more sensitive than detecting serum antigens (IHA detection by ELISA)
- ♣ More informative in Echinococcus multilocularis than granulosis
- ♣ PCR technology is used in this test.

3. Imaging:

- ♣ Plain X ray.
- ♣ Ultra sound: shows➔
 1. Simple pyogenic cyst vs paracystic cyst.
 2. Abscess , neoplastic masses vs parasitic cyst: by detecting the membranes of the cyst.
 3. Detects Hydatid sand sign (scolices appear as sand) : this sign is diagnostic in most cases
 4. Active vs. inactive: water lily sign.
 5. Eggshell appearance in calcified cyst.

Classification upon ultra sound findings

<u>Hassan Gharbi classification:</u>		<u>WHO classification:</u> depends on ➔
type I.	Cyst with pure fluid collection	 Final state of the parasite: active / inactive/ transitional  Size: small <5cm / medium 5-10 cm/ large>10 cm
type II.	Cyst with variable morphology, detached membrane or split wall (water lily sign)	
type III.	Multiple septa and/ or daughter cyst	
type IV.	High internal heterogenous echos	

♣ **CT :**

- Sensitivity reaches 100%.
- Determines size, location, number, and presence of intrahepatic lesions.
- More sensitive in detecting minimal calcifications.
- BUT !! U/S is more informative regarding wall cyst changes.

♣ **MRI**

♣ **MRCP/ ERCP**



TREATMENT

1. Chemotherapy:

- Alone is not useful, so it should be combined with other modalities of treatment.
- Albendazole (ABZ) and ABZ sulfoxide (the active metabolite) are the most effective adjuvant chemotherapy.

ABZ alone can cure 10-30% of cases, and causes degeneration of the cyst in up to 92% of the cases, so it should be combined with percutaneous drainage or surgery)

- Indications of medical treatment:

- ♣ Inoperable or unfit patient.
- ♣ patients with multiple cysts in more than 2 organs
- ♣ Multiple small liver cyst or cysts deep in the liver.
- ♣ Peritoneal cyst.
- ♣ Patients following incomplete surgery or relapses.
- ♣ Prevention of secondary of echinococcal infection following percutaneous rupture or aspiration of the cyst.

2. Percutaneous drainage:

- Some studies show that percutaneous drainage in combination with chemotherapy is SAFE and EFFICIENT / LOWER COMPLICATIONS/ and BETTER POST OP RECOVERY.

BUT!! In surgical recall , it is mentioned that you should never do percutaneous drainage due to the risk of leakage into the peritoneal cavity (anaphylaxis).

3. surgery: the mainstay of treatment

- Principles or characteristics:
 1. Eradicates the parasite in > 90% of cases.
 2. Avoids spillage.
 3. Obliterates the residual cavity.
- Indications:
 1. Superficial cyst with risk of rupture
 2. Large cyst >10 cm with many daughter cysts
 3. Cystobiliary communication
 4. Mass effect on vital organs
 5. Infected cyst
 6. Any extrahepatic localized cyst
- Surgical options:

Radical approach:
includes➔

- ♣ Cystectomy
- ♣ Pericystectomy
- ♣ Liver resection

*Less recurrence

Conservative approach:
includes➔

- ♣ External drainage.
- ♣ Wide roof excision.
- ♣ Evacuation and sterilization of the cavity.
- ♣ Capitannage.
- ♣ Marsipulization.
- ♣ Partial cystopericestectomy.
- ♣ Near total pericystectomy.

In conservative approach consider: if there was a wide communication
➔ do: biliary bypass / sphincteroplasty/ ERCP & endoscopic sphincteroplasty/ CBD exploration and T- tube insertion.

➤ The surgery can be laparoscopic or open:

During surgery there is toxic irrigation with scoliocidal agents before cyst removal to prevent recurrence, the agents used are➔

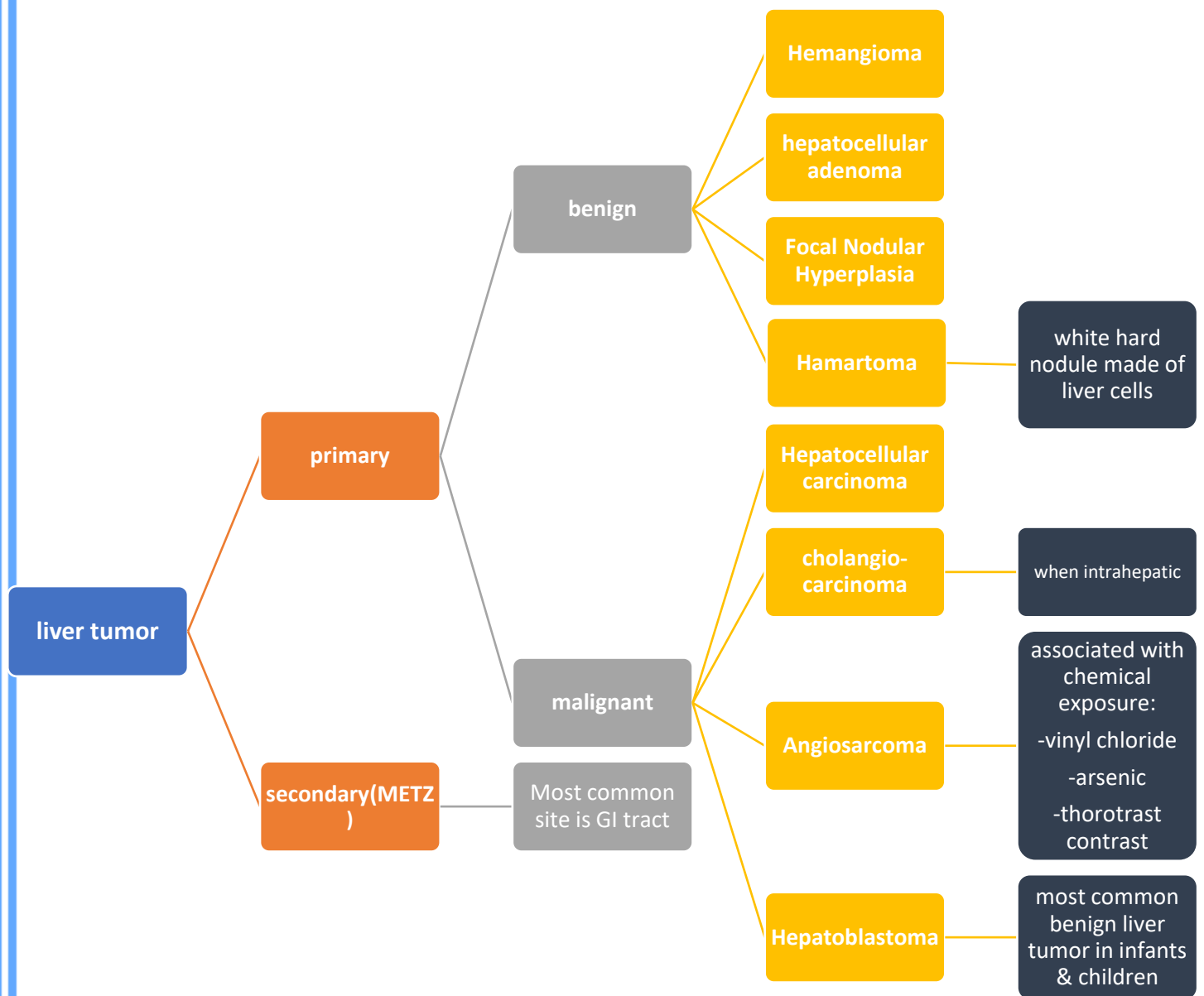
1. Hypertonic saline 10-20% for 5-10 minutes.
2. Peroxide solution 10%.
3. Chlorhexidine.
4. cetrimide

➤ Contraindications of laparoscopic surgery:

1. Cholangitis due to communication.
 2. Liver cirrhosis
 3. Recurrent cyst
 4. Complicated cyst with rupture or infection
 5. Deep intraperitoneal cyst
 6. Cyst in the posterior segment
 7. Cyst close to major vessel
 8. >3 cysts
 9. Thick calcified wall cyst
- Post op complications:
1. Infection of the residual cavity.
 2. Intra abdominal abscess.
 3. Anaphylactic reactions.
 4. Spillage of parasite material → 2ry echinococcosis.
 5. Biliary fistulation.
 6. Sclerosing cholangitis.

Tumors of the liver

- Most common liver CA is METZ (it is way more common than primary tumors of the liver 20:1 and the primary of metz site is usually the GI tract)
- Most common primary malignant liver tumor is hepatocellular CA (also called hepatoma or HCC)
- Most common primary benign liver tumor is hemangioma
- Right hepatic lobectomy: removal of the right lobe of the liver , i.e.: removal of all liver tissue to the right cantles line.
- Lt hepatic lobectomy: removal of left lobe of the liver , i.e.: removal of all liver tissue to the left of cantles line.
 - Trisegmentectomy: removal of all liver tissue to the Right of the falciform ligament.



Primary benign tumors

1. Hemangioma



INTRODUCTION

- The most common primary benign liver tumor (up to 7% of the population)
- It is a benign vascular tumor of the liver.



CLINICAL FEATURES

➤ Signs & symptoms:

1. Asymptomatic in 85%.

1. RUQ pain/ mass.
2. bruits.

➤ Complications:

1. -Pain.
2. -Congestive heart failure due to AV shunt.
3. -coagulopathy due to sequestration of platelets.
4. -Gastric outlet obstruction due to compression over gastroduodenum
5. -Kasabach-Meritt syndrome:
hemangioma+thrombocytopenia+fibrinogenopenia+
disseminated intravascular coagulation ??
6. -hemorrhage

➤ Diagnosis:

1. -CT scan with IV contrast
2. -tagged red blood scan
3. -MRI
4. -Ultra Sound

Note: biopsy shouldn't be performed due to risk of hemorrhage with biopsy.



TREATMENT

- Observation in >90% of cases.
- Resection if:
 - Symptomatic.
 - Hemorrhage.
 - Can not be diagnosed depending on the previous investigations.

2. Adenoma



INTRODUCTION

- This tumor histologically consists of normal hepatocytes without bile duct or kupffer cells
- Risk factors:
 1. -female : male ratio = 9:1
 2. -birth control pills (think ABC = Adenoma Birth Control)
 3. -anabolic steroids.
 4. -glycogen storage disease .



CLINICAL FEATURES

- signs & symptoms:
 1. -RUQ pain/ mass/ fullness
 2. -bleeding
- complications:
 1. Rupture with bleeding.
 2. Necrosis.
 3. Pain.
 4. Risk of hepatocellular carcinoma.
- Diagnosis:
 1. CT.
 2. Ultra Sound.
 3. -±biopsy but rule out hemangioma with tagged red blood cells scan first.



TREATMENT

- If small → stop pills → it may regress
→ if didn't regress → surgical resection is necessary.
 - If large (>5 cm)/ bleeding/ painful/ rupture → surgical resection.
- ❖ Note: average age: 30-35 years of age.

3.Follicular Nodular Hyperplasia (FNH):



INTRODUCTION

- It is hyperplasia of liver containing all components of liver in disorganized pattern so histologically the tumor consist of normal functioning liver tissue with bile ducts.
- Second most common benign liver tumor.
- **Risk factors:**
 1. Female
 2. Birth control pills, however they are more associated with adenomas than with FNH.



CLINICAL FEATURES

- **Diagnosis:**
 1. Nuclear Technetium -99 study.
 2. Ultra Sound.
 3. CT scan, the findings are: liver mass with central scar.
 4. Angiogram.
 5. Biopsy.
- **Complications:**
 1. Pain.
 2. Hemorrhage ,very rare.
 3. No risk of CA , unlike adenoma.



TREATMENT

- If symptomatic→ resection or embolization.
 - Why does embolization work with FNH?

Because this tumor is usually fed by one major artery.

- If asymptomatic→ follow up if diagnosis is confirmed + stop birth control pills.
 - ❖ Note: average age is around 40 years of age.

Primary malignant liver tumors:

1. Hepatocellular carcinoma HCC, AKA: hepatoma.



INTRODUCTION

- Most common malignant primary liver tumor, the incidence is 80% of all primary malignant liver tumors.
- **High risk areas: Africa & Asia.**
- **Risk factors:**

Most
important risk
factors

1. Hepatitis B
2. Cirrhosis : 5% of patients with cirrhosis will develop HCC.
3. Aflatoxin (fungi toxin of *Aspergillus Flavus*).
4. α 1 –antitrypsin deficiency
5. Hemochromatosis.
6. Liver fluke.
7. Anabolic steroids.
8. Polyvinyl chloride.
9. Glycogen storage disease.



CLINICAL FEATURES

- **Signs & Symptoms:**

1. -Dull RUQ pain
2. -Hepatomegaly
3. -Abdominal mass
4. -Weight loss
5. -Paraneoplastic syndrome
6. -Signs of portal hypertension
7. -Ascites
8. -Jaundice
9. -Fever
10. -Anemia
11. -splenomegaly

Classic presentation: painful hepatomegaly

➤ **Investigation:**

1. Tumor marker: increase in α -feto protein.
2. Ultra Sound.
3. CT.
4. Angiogram.
5. tissue biopsy with CT / Ultra Sound/ or laproscopic guidance
: the most common way to diagnose HCC



TREATMENT

- Surgical resection: if possible , ex: lobectomy.
- Liver transplant, the indications are listed in the box.

Indications for liver transplant:

- *Cirrhosis and no resection candidacy as well as no distant lymph node metz and no vascular invasion.*
- *The tumor must be single and less than 5 cm or have three nodules with none larger than 3 cm.*

Hemobilia



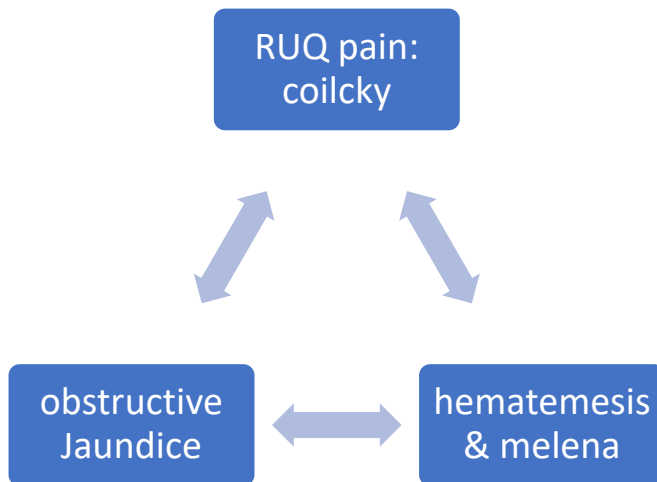
INTRODUCTION

- Bleeding commonly from the liver or occasionally from the gallbladder into the Biliary tract, it indicates abnormal communication between a blood vessel and a bile duct or any part of the Biliary tree. This blood is drained via CBD into the duodenum.
- **Causes:**
- Trauma with liver laceration
 - Percutaneous transhepatic cholangiography
 - Vascular disease of the hepatic artery
 - Tumors: malignant ones being more common in causing hemobilia than benign.



CLINICAL FEATURES

- **Signs and symptoms** : Sandblom/ Quincke's triad:



All three symptoms of triad are seen only in 20% of cases but:

- RUQ pain occurs in 70% of cases
- Obstructive jaundice occurs in 60% of cases
- hematemesis occurs in 60% of cases, & melena occurs in 90% of cases.

*just understand the idea; don't memorize the percentages of symptoms.

- **Diagnosis:**

- Based on signs & symptoms.
- Investigations ,which are:
 - endoscopy (upper GI scopy) : finding of blood out of the ampulla of vater
 - Angiogram : test of choice in detecting bleeding site.



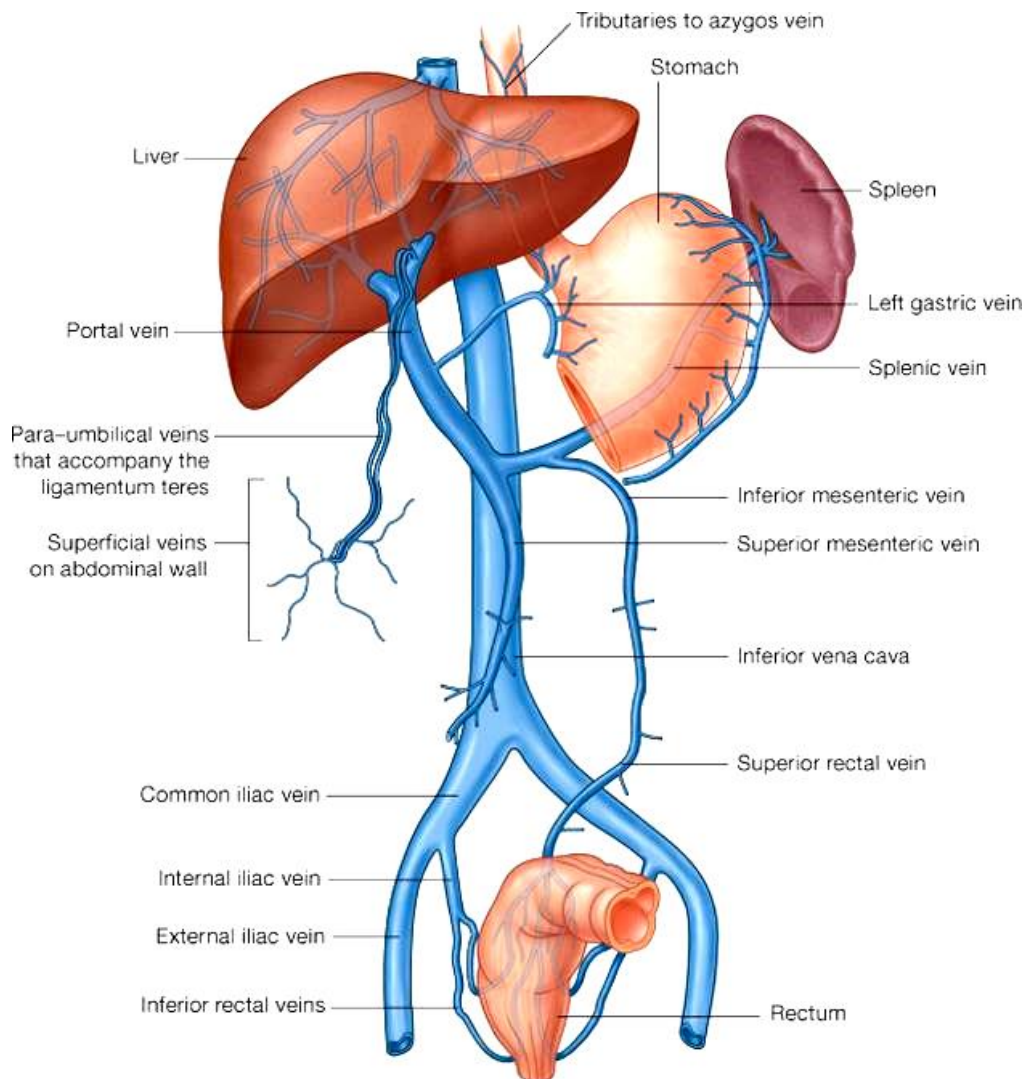
TREATMENT

- The aim is to stop bleeding and to relieve Biliary obstruction and the best intervention is ➔ Angiogram with embolization of the bleeding vessel also called : Trans Arterial Embolization (TAE).

Portal hypertension

INTRODUCTION

- It is a sustained elevation of venous portal pressure more than 10 mmHg.
- Note: the normal portal pressure is < 10 mmHg.
- Anatomy of the portal vein :
 - Inferior Mesenteric Vein (IMV) drains in the splenic vein → the splenic veins unite with the Superior Mesenteric Vein (SMV) to form → the portal vein.



Drake: Gray's Anatomy for Students, 2nd Edition.
Copyright © 2009 by Churchill Livingstone, an imprint of Elsevier, Inc. All rights reserved.

- there are 6 potential routes of portal –systemic collateral blood flow (ares of communication):
 1. Umbilicus: between paraumbulical vein and anterior abdominal vein.
 2. Lower end of esophagus: between (left gastric and short gastric) with azygos vein.
 3. Retroperitoneal veins (veins of Retzius) which communicate with the systemic venous circulation via the lumber vein
 4. Diaphragm veins (veins of sappey).
 5. Lower end of rectum: between superior hemorrhoidal vein and (middle and inferior hemorrhoidal veins and then to the iliac vein).
 6. Splenic vein to the short gastric vein.

PATHOPHYSIOLOGY

➤ Pathophysiology of portal hypertension:

Increased resistance to portal flow ➔ results in increased portal venous pressure, this increased resistance may be:

- I. Prehepatic: due to blockage of the portal vein before the liver can be due to ➔ portal vein thrombosis , splenic vein thrombosis, or atresia of portal vein
- II. Hepatic: due to distortion of the liver architecture which can be caused by ➔ cirrhosis (distortion of normal liver paranchyma by degenerating hepatic nodules), Hepatocellular Carcinoma, or hepatic fibrosis
 - ♠ Note: 2/3 of patient with cirrhosis develop portal hypertension.
- III. Post-hepatic: due to venous blockage outside the liver (rare). caused by ➔ prolonged severe right heart failure with tricuspid incompetence , constrictive pericarditis, veno occlusive disease (like :Budd-Chiari syndrome: see the box below)

Budd-Chiari syndrome: a syndrome due to obstruction to the venous outflow of the liver owing to occlusion of the hepatic vein. In one third of the cases the cause is unknown, but specific causes include hypercoagulability states , thrombophilia, tumors like: renal or adrenal tumors.



CLINICAL FEATURES

➤ signs & symptoms:

1. splenomegaly: the most common physical finding in patients with portal hypertension.
2. esophageal varices: engorgement of the esophageal venous plexus due to backing up of blood (increased collateral blood flow) from left gastric vein (also called coronary vein) and short gastric vein into the systemic venous system via the Azygos vein.
3. Caput medusa: due to backing up of blood from the paraumbilical vein via the falciform ligament into the epigastric veins (also called anterior abdominal veins).
4. Hemorrhoids: due to blood backing up from the superior hemorrhoidal vein which drains into the inferior mesenteric vein into the systemic venous system via the middle and inferior hemorrhoidal veins.
5. Signs and symptoms of liver cell failure or chronic liver disease: spider angioma, palmer erythema, ascitis, truncal obesity and, confusion and drowsiness due to neuropsychiatric complications (portosystemic encephalopathy), asterix (hepatic flap).

Portosystemic encephalopathy:

Pathophysiology: accumulation of toxic metabolites which should have been metabolized by the liver in the brain

2 types :

➔ chronic neuropsychiatric syndrome secondary to : cirrhosis

➔ acute which is secondary to acute hepatic failure, in patients with portal hypertension due to spontaneous shunting or in those with surgical or TIPS shunts (TIPS & surgical shunts are discussed below)

6. Jaundice.

- ❖ Note: retroperitoneal varices may appear as a result of blood backing up into the systemic venous system via the lumbar vein.

In addition to the symptoms mentioned above (drowsiness & confusions), signs may include:

- feto hepaticus
- asterixes

➤ **Complications:**

- The most feared complication is bleeding from esophageal varices, the mortality rate from acute esophageal variceal bleeding is 50%.
- The diagnosis of esophageal varices is based on: signs and symptoms + confirmed by endoscopy



TREATMENT

- Treatment of esophageal varices :
 - ♠ Management can be divided into the active bleeding episode, the prevention of rebleeding, and prophylactic measures to prevent the first hemorrhage.
 - ♣ Initial management of active bleeding episode:
 - I. Resuscitation:
 - IV line insertion (2 large bore cannulas)
 - IV fluid
 - Foleys catheter
 - Obtain blood for grouping and crossmatching
 - Send labs: liver biochemistry and blood cultures
 - Correct coagulopathy: use vit K and fresh frozen plasma
 - ±intubation to protect from aspiration
 - II. Urgent endoscopy: both diagnostic and therapeutic

Diagnostic: to confirm the diagnosis of varices, it also excludes other causes of bleeding such as bleeding gastric ulcer

Therapeutic: used in 2 ways to stop the bleeding:

Injection sclerotherapy: a needle is passed down the biopsy channel of the endoscope and a sclerosing agent is injected into the varices , this may arrest bleeding by producing vessel thrombosis.

Variceal banding: the varices can be banded by mounting a band on the tip of the endoscope, sucking the varix just into the tip of the scope and dislodging the band over the varix using a tip wire mechanism.

III. Other measures available:

- Medical treatment: Vasoconstrictor therapy, the main use of this is for emergency control of bleeding while waiting for endoscopy and in

combination with endoscopic techniques. Vasoconstrictors reduce bleeding by restricting portal blood flow by splanchnic (mesenteric) arterial constriction.

Agents used: somatostatin (octreotide) / IV vasopressin called Terlipressin which should be given with nitroglycerine in patients with ischemic heart disease as a result of the generalized vasoconstriction it causes.

- Balloon tamponade: if bleeding continues

IV. Additional management of acute episodes:

-If sclerotherapy and conservative methods failed to stop the variceal bleeding or bleeding recurs:

- Repeat sclerotherapy/ banding & treat conservatively
- Transjugular intrahepatic portocaval shunt (TIPS):

Used when bleeding cannot be stopped after 2 sessions of endoscopic therapy within 5 days.

A guidewire is passed from the jugular vein into the liver and an expandable covered metal shunt is placed over it to form a channel between the systemic (hepatic vein) and the portal circulation (portal vein).

Advantages: it reduces the portal vein pressure by creating a total shunt and doesn't have the risk of general anesthesia and surgery.

Disadvantages: increased risk of portosystemic encephalopathy.

- Surgical shunt:

Used when other methods fail or if TIPS is not available and particularly when the bleeding is from gastric fundal varices.

Types:

1. Partial shunt: shunt that directly decompress the portal vein but only partially
2. Selective shunt (Warren): distal splenorenal shunt with ligation of the coronary vein (left gastric vein). It is associated with decreased incidence of portosystemic encephalopathy, however it is contraindicated in patients with ascitis.

Notes:

1. The most common perioperative cause of death following shunt procedure is hepatic failure secondary to reduced blood flow
2. Major postop morbidity after shunt procedure is :increased incidence of hepatic encephalopathy (portosystemic encephalopathy) because

of reduced portal blood flow to the liver and decreased clearance of toxins / metabolites from the blood.

3. What lab value roughly correlates with the degree of encephalopathy?
Serum ammonia level , note that it is thought to correlate with encephalopathy but not as a cause of encephalopathy.
4. Treatment of hepatic encephalopathy (portosystemic encephalopathy) :
 - a) Lactulose (oral): an osmotic purgative that reduces the colonic pH and limits ammonia absorption. Please note that we said that ammonia is not a cause of encephalopathy.
 - b) \pm neomycin (oral): **the latest recommendations recommends avoiding neomycin and giving Rifaximin or metronidazole → the source is Kumer and Clarke's clinical medicine 7th edition**

♣ **Prevention of rebleeding:**

Using a combination of medical measures (e.g. no selective beta blockers) , endoscopic measures (e.g. variceal banding at 2 weekly interval which leads to obliteration of the varices) , and surgical measures (e.g. surgical shunts).

♣ **Prophylactic measures to prevent the first bleed:**

Patients with cirrhosis and varices that have not bled should be prescribed non selective beta blockers, this reduces the chances of upper GI bleeding , may increase survival , and is cost effective.

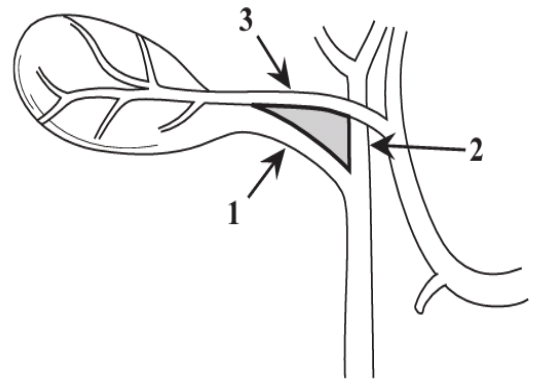
Gall bladder & biliary tree



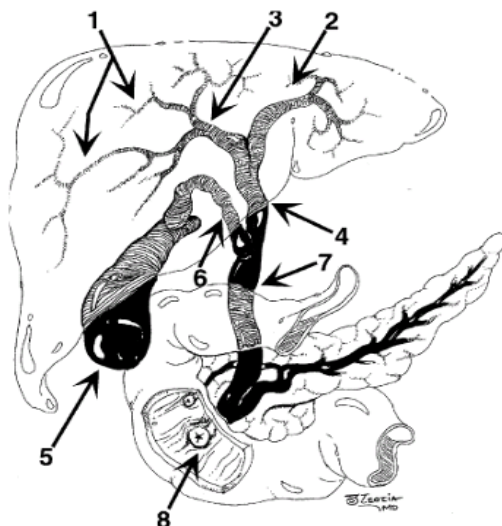INTRODUCTION

➤ Anatomy:

- It is a pear shaped reservoir located in a fossa in the inferior surface of the liver
- The ampulla of Vater opens in the 2nd part of the duodenum.
- Both gall bladder neck and cystic duct contain mucosal folds called valves of Heister.
- Ducts of Luschka: small ducts that drain bile directly into the gallbladder from the liver.
- 10% of people have accessory cystic artery.



Name structures 1 through 8 (below) of the biliary tract:



1. Intrahepatic ducts
2. Left hepatic duct
3. Right hepatic duct
4. Common hepatic duct
5. Gallbladder
6. Cystic duct
7. Common bile duct
8. Ampulla of Vater

381

➤ Callot's triangle:

♣ Boundaries (3 C's)

1-Cystic duct

2-Common hepatic duct

3-Cystic artery

♣ **Contents:** calot's node

♣

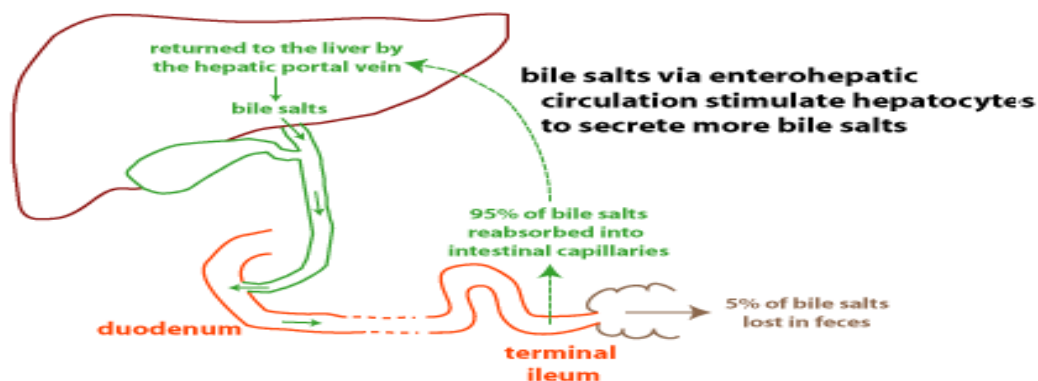
➤ **Physiology:**

• **Function:**

- ♣ Storage of bile and secreting bile in response to CCK(cholecystokinin) and vagal response.
- ♣ Bile = cholesterol + leicithin +bile acid+ bilirubin
- ♣ Bile emulsifies fat.
- ♣ Mainly produced by the liver.it's secreted to the intestines (from the 2nd part of the duodenum) and reabsorbed mainly to the terminal ileum
- ♣ CCK is screted from duodenal mucosla cells as a response to fat (mainly), amino acids, proteins and HCl.
- ♣ CCK is inhibited by Trypsin and Chemotrypsin, which are secreted from the pancreas.
- ♣ Functions of CCK
 1. GB emptying
 2. Opening of ampulla of vater
 3. Slowing gastric emptying
 4. Pancreatic acinar cell growth and release of exocrine pancreatic products.

• **Enterohepatic circulation:**

-Circulation of the bile acids from the liver to the intestines and back to the liver.



- When total bilirubin > 2.5 >>>> clinical detection of jaundice.
- The 1st anatomic location where jaundice appears is under the tongue.
- The bile duct epithelium is the source of alkaline phosphatase so we expect it to be raised in the case of bile duct obstruction.

➤ **Definitions:**

- Cholelithiasis: gallstones in GB.
- Choledocholithiasis: stones in the CBD.
- Cholecystitis: inflammation of GB.
- Cholangitis: infection of the biliary tract.
- Cholangiocarcinoma: adenocarcinoma of the bile duct.
- Klatskin's tumor: cholangiocarcinoma at the site of junction of the right and left hepatic ducts.
- Biloma: intraperitoneal bile fluid collection.
- Choledochojejunostomy: anastomosing the CBD and the jejunum.
- Hepaticojejunostomy: anastomosing the hepatic ducts or CBD to jejunum.
- Biliary colic: pain from gallstones (usually from stone in the cystic duct), located in the RUQ/epigastrium or right subscapular region of the back. Lasts minutes to hours but eventually goes away, and it's often postprandial (after meals, esp. Fatty food).
- Hydrops GB: Complete obstruction of the cystic duct by gallstones with filling of GB with fluid from GB mucosa.
- Mucocele: sterile collection of secretions.
- Biliary sludge: viscous mixture of mucin glycoproteins, calcium bilirubinate and cholesterol crystals inside the GB or the biliary tree. (can produce the same symptoms produced by the stone).
- Nucleation: the precipitation of cholesterol crystals from saturated bile.



DIAGNOSIS

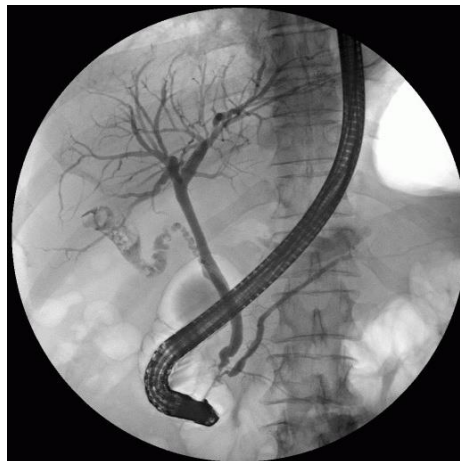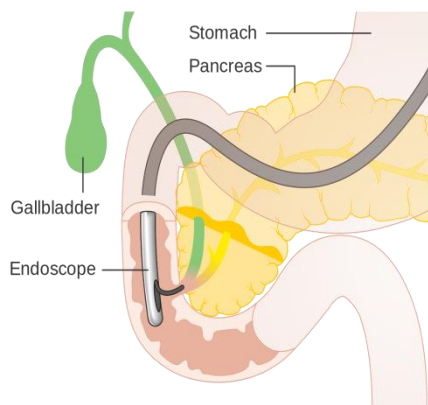
- **Signs and symptoms of obstructive jaundice :**

- 1) Jaundice.
- 2) Tea-colored urine.
- 3) Clay-colored stool.
- 4) Pruritis(i.e. itching, due to deposition of bile salts (not bilirubin) in the dermis).
- 5) Loss of appetite.
- 6) Nausea.

- **Diagnostic studies:**

- I. **Endoscopic Retrograde Cholangio-Pancreaticography (ERCP):**

Through a side viewing gastro duodenoscope, sphincter of Oddi is cannulated, and dye is injected. Biliary and pancreatic trees are visualized.



- **Indications:**

- a. Malignancy: appears as irregular filling defect.
 - b. Chronic pancreatitis: chain of lakes appearance.
 - c. Congenital anomalies.
 - d. Stones.
 - e. Stricture of biliary tree.
 - f. Choledocal cyst.
 - g. For sampling of biliary and pancreatic juices for analysis and cytology.
 - h. Brush biopsy from tumor site.
- ERCP can be therapeutic and used in the following cases:

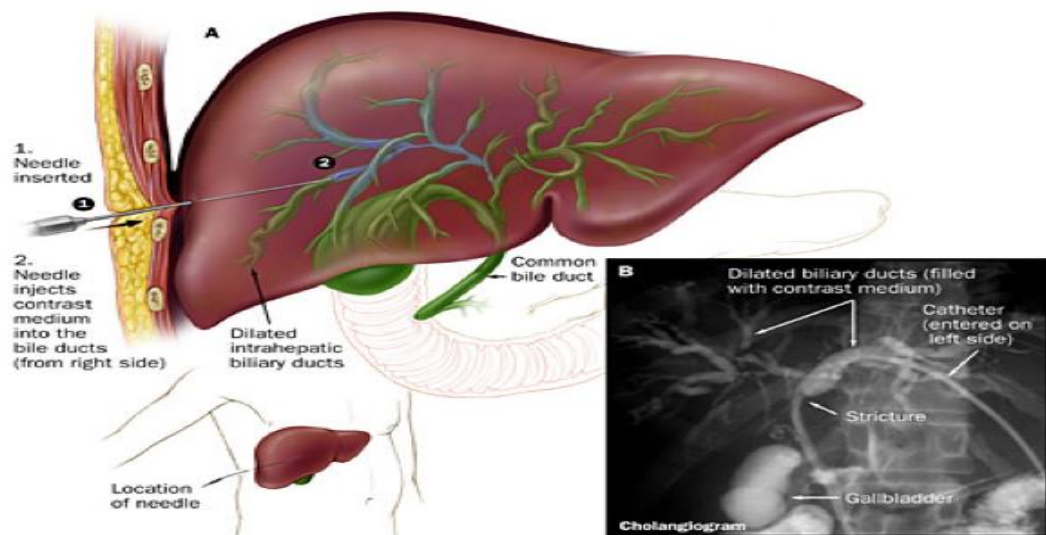
- a. Extraction of stone from biliary tree.
- b. Nasobiliary drainage.
- c. Stenting of tumor in the CBD or in the pancreas.
- d. Dilatation of the biliary stricture.
- e. Endoscopic papilotomy.
- **Complications:**
 - a. Pancreatitis
 - b. Duodenal injury, perforation.
 - c. Cholangitis.
 - d. Bleeding from pancreaticoduodenal artery.
 - e. Sphincter stenosis.
- **Relative contraindications:**
 - a. Acute pancreatitis
 - b. Previous gastrectomy.
 - c.

II. Percutaneous Transhepatic Cholangiography (PTC):

With the help of fluoroscopy (c-arm)/ US/ CT a long, flexible, thin, blunt needle is passed into the liver through right 8th intercostal space in midaxillary line, once the needle is in the dilated biliary tree, bile is aspirated and sent for culture, cytology, and analysis. Then a water soluble dye is injected so as to visualize the biliary tree.

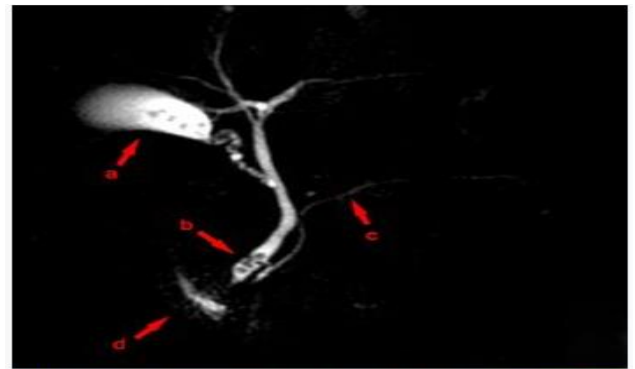
PTC can be therapeutic when used to stent the biliary tree.

- **Indications:**
 - a. Failure of ERCP
 - b. High biliary strictures
 - c. Klatskin tumor
 - d. Stenting in high tumors



III. **Magnetic Resonance Cholangio-Pncreaticography (MRCP):**

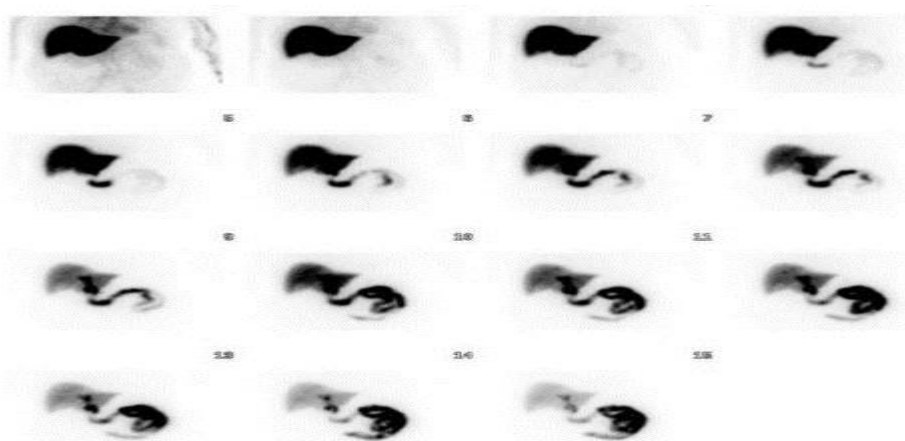
It is a non contrast non invasive imaging method, better than ERCP as diagnostic tool in biliary and pancreatic diseases.



MRCP image showing stones in the distal common bile duct: (a) Gallbladder with stones, (b) Stones in bile duct, (c) Pancreatic duct, (d) Duodenum.

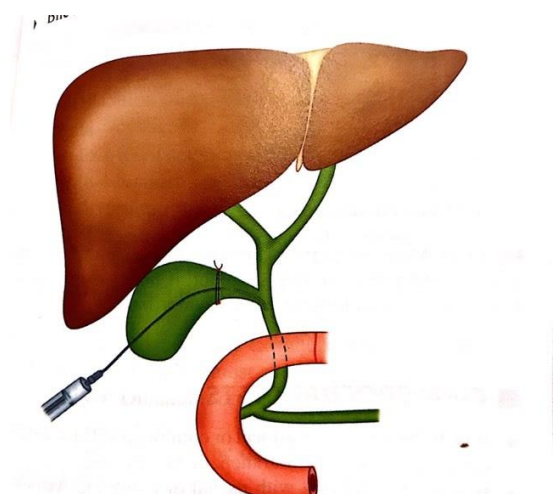
IV. **Radioisotope scan study (HIDA & PIPIDA):**

Very useful in diagnosing acute cholecystitis and other biliary disorders like biliary atresia.



V. **Peroperative Cholangiogram:**

fine catheter is passed through cystic duct into the CBD and dye is injected. Under C- arm image intensifier any block or stricture can be identified. Complications: infection & bile leak. Precautions: air should not be present in the syringe, as it may mimic stones.



VI. Postoperative T-Tube Cholangiogram:

After choledochotomy, T-tube is inserted in CBD for 14 days and then water soluble dye is injected into the tube and X-ray is taken. Complete free flow of dye into the duodenum indicates that there is no blockage by stones. T-tube can then be removed safely.

➤ **Biliary surgery:**

- Cholecystectomy: removal of the GB, whether laparoscopically or open.
- Lap Chole: laparoscopic cholecystectomy.
 - 1-Complications of lapchole:
 - 2-CBD injury
 - 3-Rt hepatic duct or artery injury
 - 4-Cystic duct leak
 - 5-Biloma
 - 6-Bowel injury
 - ♣ One of the complications of laparoscopic cholecystectomy is biloma, which is intraperitoneal bile fluid collection.
 - ♣ Treatment of post op biloma:
 - ♠ 1-Percutaneous drainage of bile collection.
 - ♠ 2-ERCP with placement of a biliary stent past leak (usually cystic duct remnant leak).
 - ♣ Another complication is major CBD injury after lapchole, which is treated by: choledochojejunostomy.
- Kocher incision: right subcostal incision.
- Sphincterectomy: (AKA: papillotomy) a cut through the sphincter of oddi to allow the passage of gallstones from CBD (most often done in ERCP).

Gallbladder stones (Cholelithiasis)



INTRODUCTION

- Incidence : 10% of USA population will develop gallstones.
- Types of stones:
 - Mixed (80% of stones):
 - ♣ The most common type of gallstones.
 - ♣ Content: cholesterol content 50-80%
 - ♣ Various shapes and sizes.
 - ♣ Usually small, multiple stones of faceted surface.
 - ♣ Radiolucent.
 - Pure cholesterol (10% of stones):
 - ♣ Content: cholesterol 100%.
 - ♣ Pale yellow.
 - ♣ Usually large and solitary.
 - ♣ Radiolucent.
 - Pigmented (10% of stones)
 - ♣ Cholesterol content less than 20% of their weight.
 - ♠ Black stones:
 - ♠ Causes: hemolysis (any haemolytic disease is a risk factor) and cirrhosis.
 - ♠ Content mainly Calcium-bilirubinate.
 - ♠ Homogenous, brittle.
 - ♠ Small multiple stones.
 - ♠ Radiopaque 75%.
 - ♣ Brown stones:
 - ♠ Causes: after biliary infection (most common causative organism is Klebsiella).
 - ♠ Content: mainly calcium palmitate.

- ♠ Small, multiple, soft stones.
- ♠ Radiolucent.

? ETIOLOGY

➤ Risk factors:

4 F's:

1-female (twice the risk). (due to hormonal effect).

2-Fat (three times the risk in obese, and increases with fatty diet)

3-Forty.

4-Fertile (multiparity and usage of OCP).

➤ Less common risk factors:

1-Advanced age.

2-Infection

3-Bile stasis

4-Cirrhosis

5-IBD

6-Chronic hemolysis

7-OCPs, somatostatin treatment

8-TPN (the effect of the CCK is put off to rest since there's no food in the duodenum, so no contraction of the gallbladder or the biliary tree).

9-Hyperlipidemia (but hypercholesterolemia is not a risk factor)

Hyperlipidemia could be familial or acquired.

10-Obesity

11-Rapid weight loss

12-Bypass surgery / terminal ileal resection(due to interruption of enterohepatic circulation which leads to suprasaturated bile).

13-Vagotomy.

14-Native Americans.

15- spinal cord injury due to denervation and biliary stasis.

16-Medications, examples are:

a-antipyretics (rocephin) which is widely used by in paediatrics patients, long term use might lead to formation of gallstones.

b- Somatostatin analogue(octreotide), somatostatin is a universal anti-secretory hormone, so it suppresses the secretion of all hormones. In surgery it's used to treat gastrointestinal fistulae (duodenal, pancreatic, biliary fistulae) by suppressing the secretions from the biliary tree and the pancreas, so prolonged use might lead to gallstones formation.

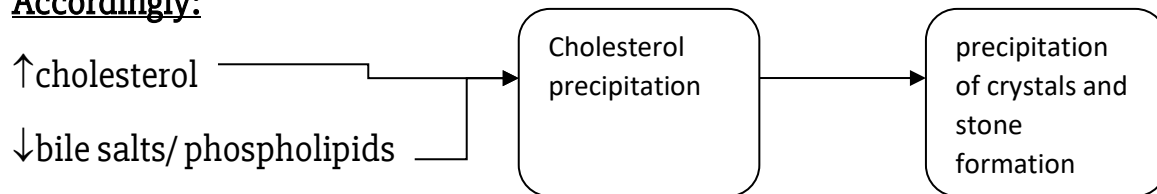
PATHOPHYSIOLOGY

1st.Metabolic causes (disturbed cholesterol: bile salts or lecithin ratio)

- Exogenous cholesterol represents about 30% of cholesterol in our body.
Cholesterol is mainly produced by the liver, with little contribution of the dietary sources.
- Chylomicrons and LDL, are taken up by receptors, converted to cholesterol esters, then by the enzyme hydrolase are converted to free cholesterol, this free cholesterol is either re-esterified or hydrolised to bile salts or excreted in the hepatic biliary canaliculi.
- 10-20% of adult population in USA have gallstones.
- They are 3 times more in females than males because of hormonal effect, estrogen and progesterone affect the saturation of cholesterol in bile.
- As age increases, the incidence of gallstones also increases.
- Most lipid lowering enzymes increase the excretion of cholesterol in bile, and that's why these people might develop gallstones.
- At the level of hepatocytes, what comes from food is chylomicrons.
- Major organic solute in the bile are bilirubin, bile salts, phospholipids and cholesterol.

- The way to keep cholesterol from precipitation is the complexes (micelles and vesicles), so the aim of complexes is solubilisation of cholesterol, micelles are carriers of cholesterol. Micelles can be simple, mixed, multilamellar or vesical.

Accordingly:



➤ **Pathogenesis of gallstones :**

1-Supersaturation of bile with cholesterol:

- ♣ ↑↑ secretion of cholesterol.
- ♣ ↓bile salts and lecithin.

2-Nucleation:

- ♣ Formation of solid crystals from bile saturated with cholesterol.
- ♣ Nidus (calcium-bilirubinate) is another mechanism.
- ♣ Promoters of nucleation (mucus glycoproteins) are important risk factors.

3-Growth:

- ♣ Individual growth of each crystal.
- ♣ Promoters (calcium and mucus glycoproteins) act as frameworks for crystal formation.
- ♣ 1-2 mm per year (so they increase in size and don't go away)

2nd. Bile stasis:

Occurs due to estrogen therapy, pregnancy, vagotomy, and in patients who are on long term IV fluids or TPN.

3rd. Infections and infestations (pathogenesis of pigmented brown stones):

Bacteria like E.coli and Salmonella and parasites like Ascaris act as a nidus for stone formation.

The stones are typically found in the bile duct as primary stones

Bacteria that have the enzyme glucuronidase will cause the hydrolysis of soluble conjugated bilirubin into unconjugated bilirubin that precipitates with calcium. Another bacterial enzyme is phospholipase which hydrolyzes lecithin into palmitate.

"A gall stone is a tomb stone erected to the memory of the organism within it"

Differential diagnosis of biliary colic:

- 1-Cholelithiasis.
- 2-Acute cholangitis.
- 3-Liver diseases.
- 4-PUD (peptic ulcer disease).
- 5-Renal colic
- 6-GERD.
- 7-Inferior wall MI.
- 8-Right lower lobe pneumonia.
- 9-IBS.

4th. Increased bilirubin production (Pathogenesis of pigmented black gallstones):

- ↑load of unconjugated bilirubin>>>>precipitate with calcium.
- Not associated with infected bile.
- Almost exclusively in the gallbladder.



CLINICAL FEATURES

Signs and symptoms :

1st. In the gall bladder

80% of patients are asymptomatic.

If symptomatic:

- ♣ Biliary colic (misnomer; not really a colic); usually last for hours and is characterized by:
 1. RUQ pain that radiates to the back/epigastrium/LUQ, the pain worsens after eating especially fatty meals
 2. ±Nausea and vomiting the body trying to prevent fatty food from reaching the duodenum.
 3. No jaundice.
- ♣ Acute cholecystitis.

Boas' sign:
referred right
subscapular pain

- ♣ Chronic cholecystitis.
- ♣ Empyema gall bladder:
A type of acute cholecystitis wherein the gall bladder is filled with pus.
- ♣ Perforation causing biliary peritonitis or pericholecystic abscess.
- ♣ Mucocele of gall bladder.
- ♣ Gall bladder carcinoma.

2nd. In the CBD:

- ♣ Choledocolithiasis: The stone may move from the gall bladder and get obstructed in the CBD (secondary CBD stone): explained later
 - ♣ Cholangitis : explained later
 - ♣ Oriental cholangiohepatitis.(Oriental cholangiohepatitis, an endemic disease in Southeast Asia, is characterized by recurrent attacks of abdominal pain, fever, and jaundice. Pathologically, the intra- and extrahepatic ducts are dilated and contain soft, pigmented stone and pus.)
 - ♣ Gall stone Pancreatitis
 - ♣ Mirizzi syndrome : explained later
- 3rd. In the intestines:
- ♣ Gall stone ileus: explained late



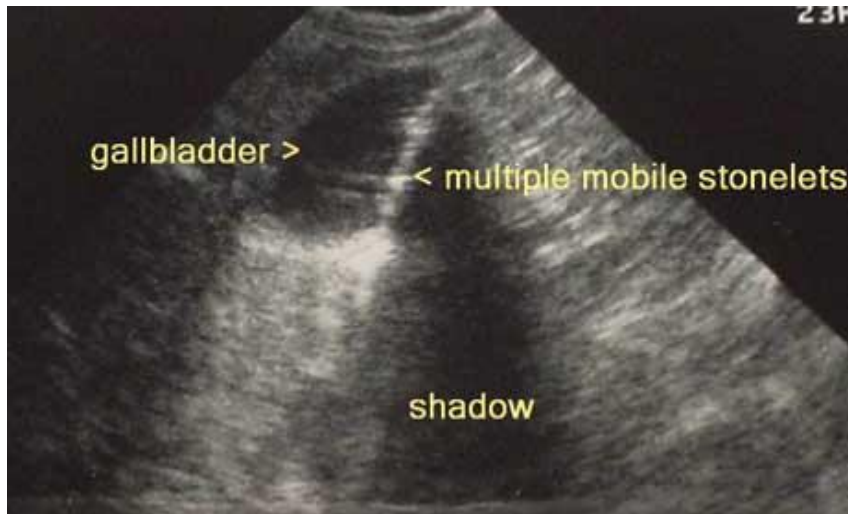
DIAGNOSIS

- History and physical exam.
- Ultrasound (detects stones in >98% of cases in gallstones, while it only detects 33% in choledocholithiasis, so it's not a very good diagnostic tool for choledocholithiasis).
- **Findings:** acoustic shadow.

Differential diagnosis for

Differential diagnosis for pain radiating to the back:

- 1-Cholelithiasis.
- 2-Acute cholecystitis.
- 3-pancreatitis.
- 4-penetrating PUD (not perforating).
- 5-ruptured aneurysm disk prolapsed.



- Abdominal x-ray detects only 15% of gallstones.



TREATMENT

- If symptomatic or complicated stones>>>cholecystectomy (surgical or lapchole).

Does the gallbladder have a role in stone formation?

Yes, when we remove the gallbladder rarely stones reoccur, so the removal is a symptomatic treatment, we are removing the site where most stones are formed.

The epithelium of the gallbladder has an absorptive and a secretory capacity(mucin), so once there is alteration in either capacities or increase/decrease motility of the gallbladder, stones are formed.

Dysmotility of the gallbladder could develop spontaneously, postoperative or due to a disease. (denervation of the gallbladder).

Hypermotility of the gallbladder leads to shrinkage of the pool of bile acid.

- Medical treatment: ursodeoxycholic acid.
- For pain management we give pethidine not morphine because morphine causes contraction of the sphincter of oddi.
- If asymptomatic > no treatment except: in the following cases:

- Porcelain GB (due to risk of CA).
- Pediatric pts (relative indx).
- Sick cell disease.
- Imunosuppression.
- DM.
- Others: females predicting pregnancy.
- Incidental finding intraoperatively.
- GB polyp(increased risk of CA).

Acute cholecystitis:

♠ Types:

- a) Calculous cholecystitis.
- b) Acalculous cholecystitis.
- c) Emphysematous cholecystitis.
- d) Xanthogranulomatous cholecystitis.



PATHOPHYSIOLOGY

- Obstruction of cystic duct leads to inflammation of the gallbladder, 95% due to stone and 5% is acalculous, so pain is continuous (more than 3 hours).
- Risk factors: gallstones.



CLINICAL FEATURES

Signs and Symptoms:

- more continuous and severe symptoms than Cholelithiasis, unrelenting RUQ pain or tenderness
- Fever
- Nausea , vomiting and anorexia
- Positive Murphy's sign: arrest of inspiration during deep palpation of the RUQ
- Painful palpable GB in 33% of patients.
- Mild jaundice(if severe, you should think of CBD stone)
- Right subscapular pain/ epigastric discomfort. (referred pain)

Difference between acute cholecystitis and biliary colic:

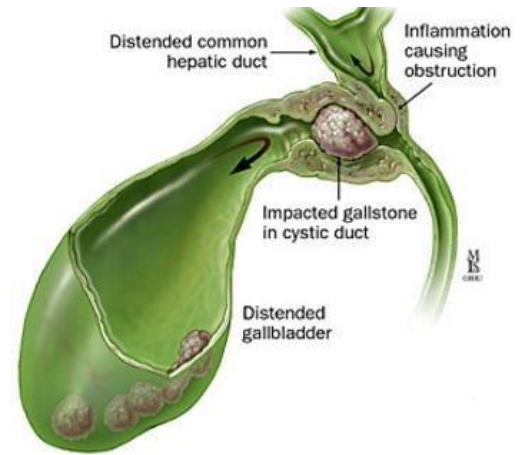
Biliary colic has temporary pain, while acute cholecystitis has a pain that doesn't resolve.

Cholecystitis has elevated WBC, fever and signs of acute inflammation on

Complications:

- 1- Empyema.
- 2- Abscess formation.
- 3- Perforation.

- 4- Gangrene.
- 5- Cholecystenteric fistula.
- 6- Choledocholithiasis.
- 7- Gallstones ileus.
- 8- Mirizzi syndrome. (Defined as common hepatic duct obstruction caused by an extrinsic compression of an impacted stone in the cystic duct or Hartmann's pouch of the gallbladder).



DIAGNOSIS

- **Investigations:**

- ♣ **Labs:**

- a. CBC:

1. WBC (but could be normal)
2. Alkaline phosphatase ↑ LFTs, ↑ total bilirubin.
3. Slightly ↑ amylase.

- b. **Imaging:**

- The diagnostic tool of choice is ultrasound.

- ♣ Findings on ultrasound:

- 1- Thickened gallbladder wall > than 3 mm.
- 2- Pericholecystic fluid.
- 3- Distended gallbladder
- 4- Gallstones or cystic stones.
- 5- Sonographic Murphy's sign.

- HIDA scan is the most accurate.
 - CT scan, less sensitive.



TREATMENT

- 1-admit the patient
- 2- IV fluids
- 3- IV antibiotics (piperacillin/ Tazobactam).

Acute cholecystitis is classified into mild, moderate and severe according to Tokyo guidelines:

1-Mild (grade 1):

- a. Mild inflammation.
- b. No organ dysfunction.

2-Moderate (grade 2):

- a. Leukocytosis.
- b. Palpable tender mass.
- c. Duration >72 hours.
- d. Marked inflammation.

- *In Acute cholecystitis>>>palpable painful mass.*
- *In GB cancer>>>palpable painless mass.*

3-Severe (grade 3):

- a. Multi-organ failure MOF
- b. Hypotension.
- c. Respiratory failure.
- d. Renal failure.
- e. Altered mental status.
- If mild>>>> early cholecystectomy within 24-48 hours
- If moderate>>early vs. delayed cholecystectomy after 6 months, but recent studies showed that early is better regardless of the degree.
- If severe (or the patient has a severe medical illness/ very old or can't tolerate general anaesthesia)>>>> percutaneous cholecystectomy.

Acalculous cholecystitis:



INTRODUCTION

- It's acute cholecystitis without the evidence of stones.
- Mortality rate is 30%.
- You can think of it as a deterioration that happens to ICU patients.



PATHOPHYSIOLOGY

- It's believed to be due to biliary sludge, GB diseases and biliary stasis(secondary to absence of cholecystokinin stimulation which leads to decreased function of GB).

Theories of pathophysiology:

1. *Sludge*
2. *Thickening of mucosa*
3. *Ischemis, as in ICU ptients*

- Risk factors:
 1. Prolonged fasting
 2. TPN
 3. Trau,a
 4. Multiple transfusions
 5. Dehydration
 6. Prolonged postop. Setting or ICU patients (critically ill), especially with history of hypotension.
 7. Sepsis or MOF.
 8. Burns.



DIAGNOSIS

Investigations:

- Labs:
 - ↑WBC, ↑amylase, abnormal LFTs.
- Imaging:
 - a. U/S
 - b. HIDA scan is the most accurate, we find non-filling of GB
 - c. CT(has the same sensitivity as U/S).

Limitations to ultrasound:

- Overlying bowel gas
- Concomitant abdominal wounds or dressings.



TREATMENT

- If the patient is stable>>>do cholecystectomy.
- If unstable, we decompress the GB percutaneously via cholecystectomy tube then we do cholecystectomy.

Emphysematous cholecystitis

- By gas-forming bacteria (E.coli)
- Usually n diabetic patients, males and elderly and has a high morbidity and mortality rate.
- Often results in perforation of gallbladder.
- If gas is present in:
 - ♠ Biliary tree>>>Think of fistula.

- ♠ In gallbladder wall>>>think of emphysematous GB.

Xanthogranulomatous cholecystitis

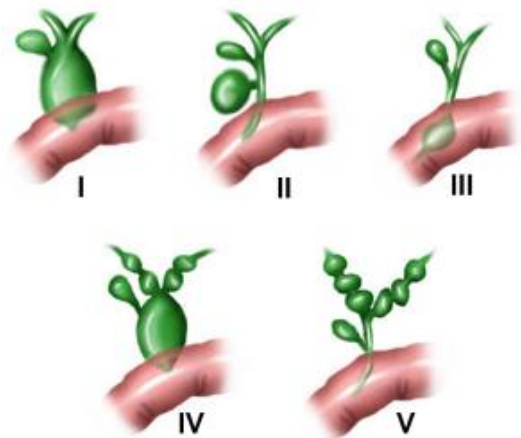
- A rare inflammatory disease of the gallbladder characterized by a focal or diffuse destructive inflammatory process.
- A foreign body-giant cell reaction that leads to formation and accumulation of xanthoma cells.
- Its importance lies in the fact that it is a benign condition that may be confused with carcinoma of the gallbladder.

Choledocal cyst

INTRODUCTION

- **Definition:** a congenital dilatation of extra or intrahepatic Biliary tree, usually in CBD.
- **Causes:** there are more than one theory about its cause, the most common 2 are➔

- pancreaticobiliary maljunction (there is along common channel more than 2 cm) , Babbit theory suggests that : reflux of pancreatic juice into the bile duct which causes enzymatic destruction of the bile duct wall , ductal wall weakening and dilatation.



- During embryogenesis ,there is abnormal early canalization of the bile duct with distal obstruction causing increased proximal pressure, weakening and ductal dilatation.

- **Types:**

- type I. Fusiform/ diffuse dilatation ,represents 75% of cases.
- type II. Isolated sacular diverticulum
- type III. Choledocoele/ cyst: localized dilatation with intradudenal part of CBD
- type IV. Multiple cystic dilatation inside and outside liver.
- type V. Single/ multiple lesions only intrahepatic (e.g.: caroli's disease, read the box below)

Caroli's disease: it is a congenital non familial multiple, irregular dilatations of the intrahepatic ducts with stenotic segments in between, it is associated with congenital liver fibrosis and medullary sponge kidney. It is considered a subtype of type 5 choledocal cyst .

➤ Notes:

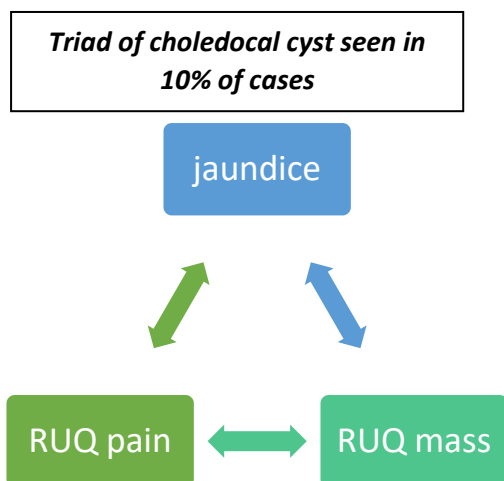
- I. 60% of cases present before the age of 10 years.
- II. 3 times more common in females.



CLINICAL FEATURES

➤ Signs & symptoms:

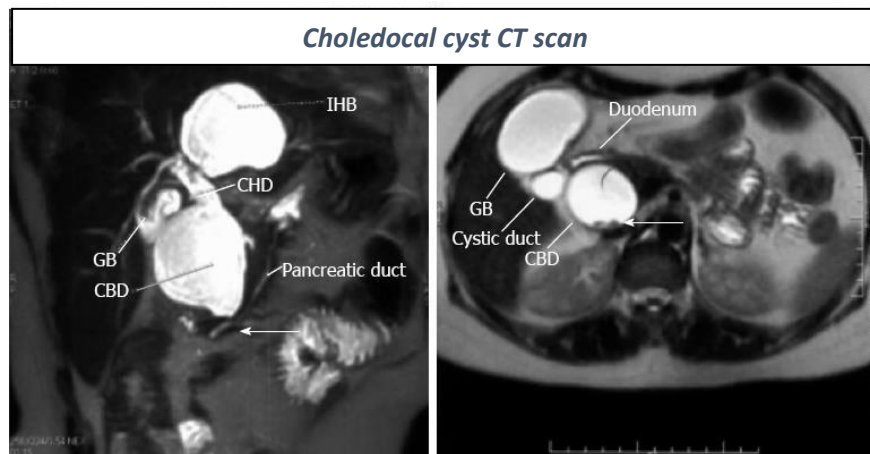
1. Obstructive jaundice in 80% of cases
2. RUQ pain
3. Cholangitis
4. Abdominal mass: RUQ mass, soft, not moving with respiration, not mobile and resonant.
5. Failure to thrive in children



➤ Complications:

1. Choledocolithiasis: stones in CBD.
2. Cholangitis.
3. Portal hypertension secondary to biliary cirrhosis which results from prolonged obstruction of ducts.
4. Cholangiocarcinoma: the risk is 30%, and usually develops in the 4th decade of life.
5. Rupture of cyst and peritonitis.
6. Diagnosis:

7. History and physical examination.
8. Ultra Sound or CT.



TREATMENT

- **Treatment:** according to the type→

Type I & IV: hepatojejunostomy.

Type II: cyst excision.

Type III: cyst varroofing and sphincteroplasty.

Type V: hemihepatectomy.

Complete excision of the cyst is important due to the increased risk of Cholangiocarcinoma!

Choledocolithiasis



INTRODUCTION

- it is stones in the CBD
- classification:
 - I. **Primary:** rare, they are formed in CBD and biliary tree itself ,causes of its formation are:
 - biliary stasis, biliary dyskinesia, benign biliary stricture, sclerosing Cholangitis
 - choledocal cyst
 - Infections and infestations like ascariasis

The stones are brown pigment stones .

Note: after cholecystectomy the stones formed in the biliary tract are cholesterol stones mostly.

- II. **Secondary**: common, the stones are formed in the gall bladder (gall stones) , these stones pass through the cystic duct to the CBD and get impacted in the CBD most commonly in the supraduodenal portion of CBD , here CBD is otherwise normal.

The stones are either black pigment stones in 15% of cases or cholesterol stones in 75% of cases.

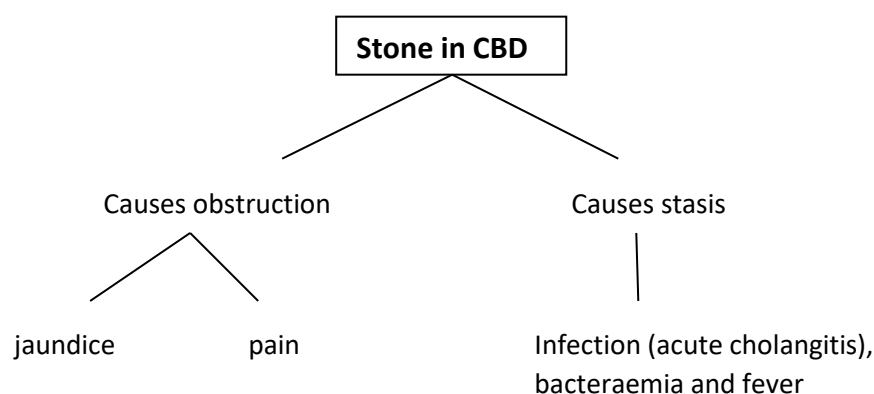
➤ **Notes:**

The incidence of Choledocolithiasis is found to be in 5-15% of patients with acute calculus cholecystitis and in 1-2% of patients with acalculus cholecystitis.



CLINICAL FEATURES

- Signs & symptoms: the pathophysiology behind the signs and symptoms of Choledocolithiasis is demonstrated by the following diagram→



So the signs and symptoms are;

1. Jaundice (if bilirubin > 2.5), with icterus (yellowish a. discoloration of the sclera).
2. Epigastric /RUQ pain: it may be biliary colic pain a. , non specific abdominal pain, pain of ascending b. Cholangitis, pain of pancreatitis.

Charcot's triad of acute cholangitis

3. Fever with chills and rigors.

The stone may move proximally and floats on the bile, so obstruction is relieved and symptoms subside (intermittent features), but when there is pus production in the biliary tree these previous signs will be persistent and will be associated with toxic shock and altered mental status (Reynolds pentad of acute Cholangitis).

4. Steatorrhoea and darkening of urine.

5. Pruritus.

➤ **Complications:**

1. Liver dysfunction and biliary cirrhosis with resulting portal hypertension
2. White bile formation : it is a misnomer ; it is neither white nor bile but rather it contains mucous , it signifies severe obstructive jaundice due to which secretion of bile from liver is stopped. The mucous is derived from biliary tree lining.
3. Pancreatitis: if CBD stone is near sphincter of Oddi which blocks the drainage of bile and pancreatic duct



DIAGNOSIS

1. Labs: raised alkaline phosphatase / raised LFT/ raised total bilirubin and direct bilirubin
2. ERCP: the gold standard for diagnosis , it is also therapeutic.
3. PTC (Percutaneous Transhepatic Cholangiography): done when ERCP fails, it is also therapeutic.



TREATMENT

- ERCP (85-90% successful): involves endoscopic sphincterotomy with extraction of the CBD stones with a basket.
- If ERCP fails then the CBD is opened surgically and stones are removed. A T-tube is placed so bile can be drained externally; this tube is removed 2-3 weeks later on an outpatient department basis.

- Other treatment options: lap chole and intraoperative cholangiogram (IOC) / blind passage of balloon catheter or stone basket.

Cholangitis

Overview:

- It is inflammation of the biliary tree.
- 2 types:
 - I. ascending Cholangitis
 - II. suppurative cholangitis : severe inflammation with sepsis (pus under pressure), it will be discussed with ascending cholangitis.
 - III. sclerosing Cholangitis

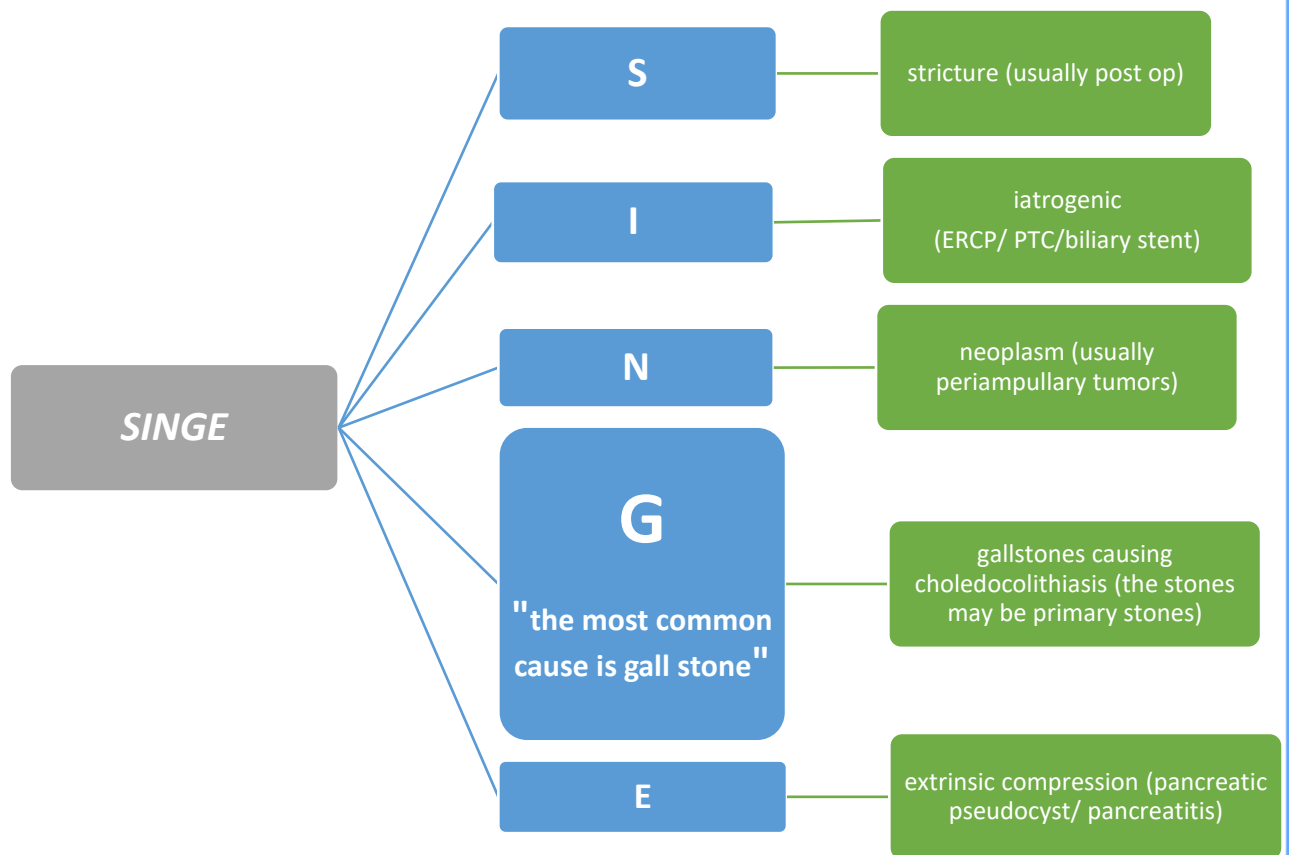
Ascending Cholangitis:

? ETIOLOGY

- Biliary infection of the biliary tract caused by complete /partial obstruction. It is potentially life threatening!! Causes: any cause of obstruction➔

The pathogens which will cause the infection as a result of the obstruction are:

- ✚ Commonly: bacterial ➔
 - I. Gram negative: E-Coli/ Klesbsiella/ Pseudomonas/ Enterobacter.
 - II. Gram positive: Enterococci .
- ✚ Less common:
 - I. Anaerobes : B-Fragills.
 - II. Fungi: Candida (the least common).



CLINICAL FEATURES

➤ Signs & symptoms:

- Charcot's triad in 50-70% of cases of ascending cholangitis (non –suppurative cholangitis):
 - I. Fever/ chills
 - II. RUQ pain
 - III. Jaundice
- If there was pus production (causing severe infection with sepsis) → suppurative cholangitis which is more common in elderly, the signs and symptoms are the following (when all of them are present they are called **Reynolds pentad**):
 - I. Charcot's triad.
 - II. Altered mental status.
 - III. shock .



DIAGNOSIS

- Labs: ↑WBC, ↑alkaline phosphatase, abnormal LFT, ↑ bilirubin.
- Ultra Sound:
 - I. Should be the initial study
 - II. Findings: dilatation of common bile duct and intrahepatic ducts along with gall stone and thickened edematous gall bladder wall.
- ERCP / PTC (percutaneous Transhepatic cholangiogram): provides definitive diagnosis and can also be therapeutic.
- Bile cultures.



TREATMENT

- If non suppurative: IV fluid + IV antibiotics+ definitive treatment later which is: lap cholecystectomy ± ERCP
- If suppurative:
 - I. IV fluids+ IV antibiotics
 - II. Decompression by: ➔ ERCP with sphincterotomy.
 - ➔ or PTC with catheter drainage.
 - ➔ or laparotomy with T- tube placement.

Primary sclerosing cholangitis (PSC):



INTRODUCTION

- Autoimmune progressive fibrous obliteration of the bile duct (multiple inflammatory fibrous thickening of the bile duct walls resulting in biliary stricture).
- **Complications:**
 - I. progressive obstruction possibly leading to cirrhosis and liver failure
 - II. 10% will develop cholangiocarcinoma
 - III. Cholangitis

IV. Obstructive jaundice

✓ **Risk factors:**

- I. IBD : 60% of ulcerative colitis patients develop PSC.
- II. Young and middle aged male.



CLINICAL FEATURES

➤ **Signs and symptoms:**

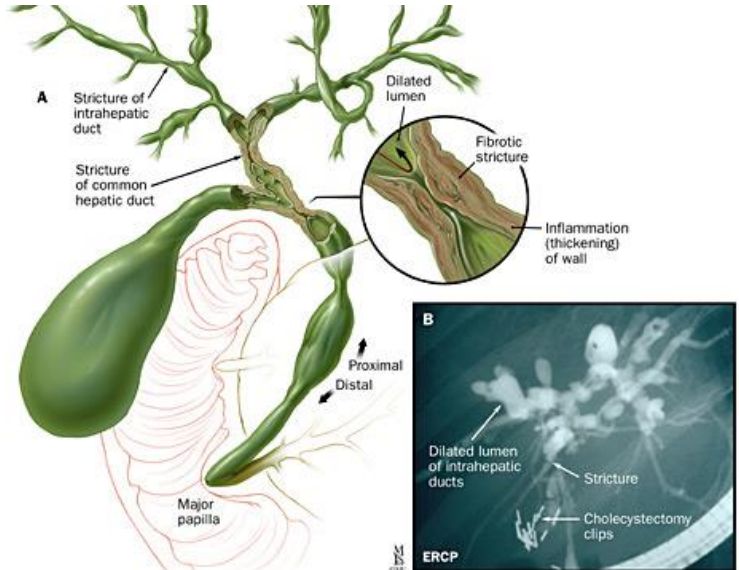
- Usually asymptomatic for years (up to 15 years !)
- Symptomatic: the symptoms include: RUQ pain/ jaundice/ hepatosplenomegaly/ itching (pruritis) /dark urine/ clay colored stool/ malaise/ weight loss.



DIAGNOSIS

Diagnosis:

- ERCP or PTC: shows beads on a string which is characteristic of PSC, the beads on a string represents diffuse irregular narrowing of the entire biliary tree and annular strictures.
- **Labs:** ↑alkaline phosphatase, +ve PANCA in 80% of the cases.
- If liver biopsy was taken it will show: periductal concentric fibrosis around the macroscopic bile duct, if the hepatic ducts were viewed it will show that the hepatic ducts bifurcation is most severely involved.





TREATMENT

- Endoscopic balloon dilatation for strictures and stent placement after dilatation
- Liver transplant: the definitive treatment; especially if PSC was primarily intrahepatic or if there was cirrhosis.
- If primarily extrahepatic ducts are involved: hepatoenteric anastomosis and resection of extrahepatic ducts due to risk of cholangiocarcinoma.

Prognosis: 10-12 years

Notes:

- ✚ Close follow ups are important due to risk of cholangiocarcinoma.
- ✚ ↑ Ca 19-9 suggests carcinoma.

Oriental cholangiohepatitis (also known as recurrent pyogenic hepatitis):

Overview:

- it is a result of infestation with parasites (ascaris) that cause: bacterial overgrowth and infection of the hepatic ducts / stricture of the ducts and stasis of bile/ brown stone formation in the intra hepatic and extrahepatic ducts
- it is one of the complications of cholelithiasis
- more common in the far east
- the Lt hepatic duct is more affected than the Rt.

Treatment: dilation of biliary stricture by stents and biliary drainage.

Gall stone ileus



INTRODUCTION

- A small bowel obstruction from a large gall stone (>2.5 cm) that has eroded through the gall bladder into the duodenum/ small bowel, gall stone ileus accounts for 1% of cases of SMALL bowel obstruction.
- Site of obstruction :
 - I. Just proximal to the ileocecal valve: the classical site of obstruction
 - II. Duodenum
 - III. Sigmoid colon
- Risk factors: female >70 years.



CLINICAL FEATURES

- Signs and symptoms:
 1. Signs and symptoms of small bowel obstruction:
RUQ pain, distention, vomiting, hypovolemia.



DIAGNOSIS

1. Clinical features
2. Abdominal x ray: shows➔
 - I. Reveals radio opaque gall stone in the bowel (most commonly near ileocecal valve)
 - II. 40% of patient show AIR in the biliary system (air in the hepatic ducts)
 - III. Small bowel distention
 - IV. Air –fluid levels secondary to ileus
3. Upper GI series
4. Abdominal CT : shows➔
 - I. Reveals air in the biliary system
 - II. Features of small bowel obstruction
 - III. ±gall stone in the bowel.



TREATMENT

- Surgical → enterotomy with removal of stone ± interval (delayed) cholecystectomy.

Biliary system tumors

“gall bladder carcinoma & bile duct tumors”

Gall bladder carcinoma:



INTRODUCTION

- Malignant neoplasm arising in the gall bladder, It is a very aggressive tumor.
- Incidence: 1% of all gallbladder specimens (rare!)
- Risk factors are:
 - I. Common in females (female: male= 3:1) and elderly.
 - II. Gall stones: 90% of carcinoma of gallbladder is associated with gallstones, however only 3% of gallstones with cholecystitis will develop carcinoma of the gall bladder.
 - III. Porcelain gallbladder: it is a calcified gall bladder seen on abdominal X-ray, results from chronic cholelithiasis/ cholecystitis with calcified scar tissue in gallbladder wall. 50% of patients with porcelain gallbladder will develop gallbladder carcinoma.

It is indicated to perform cholecystectomy when there is porcelain gall bladder.

- IV. Cholecystenteric fistula: a communication between the gallbladder and the GI tract most commonly the small intestines specifically the duodenum.
- **Site:** most common in the fundus of the gallbladder (60%).
 - **Types:**
 - I. Types according to the gross view:
 - a. Polypoid/papillary: better prognosis
 - b. Scirrhus/ nodular.
 - c. Proliferative/ infiltrative.
 - II. Types according to the histology:
 - a. Adenocarcinoma: 90%
 - b. Squamous cell carcinoma.
 - c. Adenosquamous.

d. Carcinoid tumor.

- **Prognosis:** 5% is the 5 year survival , due to the fact the most of the cases are unresectable at the time of diagnosis. However, cases detected at T1 (the tumor invaded lamina propria or muscular layer) has a 5 year survival rate of 95%.
- **Route of spread:** contiguous spread to the liver is the most common route.

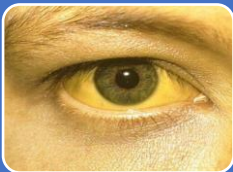

CLINICAL FEATURES

- **Signs & symptoms:**
 - Most patients are asymptomatic with: late biliary colic / weight loss / anorexia.
 - Some patients might present with acute cholecystitis.
 - Jaundice: as a result from invasion of the common bile duct or compression by involved choledocal lymph node.
 - RUQ mass.
 - Courvoisier's sign or law: " in a patient with jaundice, if there is a palpable gall bladder it is not due to stones".
 - In malignancy, like carcinoma of the head of the pancreas or periampullary carcinoma, gall bladder will be distended, palpable and non tender.

Clinically, patients present with one of the following three scenarios:

Overall;



clinically obvious type with pain, obstructive jaundice, and mass.



early gallbladder carcinoma mimics gall bladder stone disease.



atypical as unusual features.



DIAGNOSIS

1. Ultra Sound.
2. Abdominal CT.
3. ERCP.



TREATMENT

- Depends on the extent of tumor involvement.
- Tumor confined to gall bladder mucosa → cholecystectomy
- Tumor reached muscular layer or serosal layer → radical cholecystectomy: cholecystectomy+ wedge resection of overlying liver+ lymph node dissection+ chemo/radio therapy

The main complication of lap cholecystectomy for gall bladder carcinoma is trocar site tumor implants; so if gall bladder carcinoma is suspected preoperatively open cholecystectomy is indicated.

Tumors of the biliary tree:



INTRODUCTION

- 2 types:

- I. Benign: most commonly they are adenomas which are rare neoplasms, arise from ductal glandular epithelium, Polypoid (polyps) and < 2 cm in diameter.

The most common sites are:

- ⇒ Ampulla (first most common site)
- ⇒ CBD (second most common site)

Signs and symptoms: intermittent obstructive jaundice + RUQ pain

the signs and symptoms can be confused with Choledocolithiasis

Treatment: complete resection of the tumor with a margin, if only simple curettage of the polyp was done there is a high recurrence rate.

- II. Malignant (also known as Cholangiocarcinoma): it is a malignancy of the intrahepatic or extrahepatic ducts, note that we are explaining primary bile duct cancer.
- b. Almost all of cholangiocarcinomas are adenocarcinomas when studied histologically.
 - c. Average age of presentation: 65 year old
 - d. Female: male = 1:1
 - e. Most common site: proximal bile duct specifically at the junction of the Lt and Rt hepatic ducts.

Klatskin tumor: cholangiocarcinoma arising at the junction of the Rt and Lt hepatic ducts.

f. **Risk factors:**

- 1. Choledocal cyst
 - 2. Primary sclerosing cholangitis
 - 3. Ulcerative colitis
 - 4. Radiation exposure
 - 5. Toxin exposure
 - 6. Parasitic infection
- g. Cholangiocarcinomas have been classified according to the site into:
- 1) Intrahepatic : 20% of the cases
 - 2) Upper extrahepatic (klatskin): 40% of the cases
 - 3) Lower extrahepatic : 40% of the cases

h. **Diagnosis:**

- 1) Ultra Sound
- 2) CT scan
- 3) ERCP/ PTC with biopsy or brushing for cytology
- 4) MRCP

i. **Treatment:** depends on the site:

- A. Proximal → resection with Roux-en-Y hepaticojejunostomy ± unilateral hepatic lobectomy.
- B. Distal → whipple procedure.

j. **Prognosis:** depends on :

- a) Location and extent

- b) Portal vein invasion
- c) Hepatic lobar atrophy

5 year survival rate is 15-20%.

Acute abdomen, Appendix & small intestine

- Written by: Mohammad Daas
- Corrected by: Mohammad Qussay Al-Sabbagh

- Acute abdomen: 180
- Appendix: 186
- Small intestine: 192
 - Introduction: 192
 - Small intestinal obstruction: 195
 - Small intestinal tumors: 200
 - Fistulae: 205

Acute Abdomen



INTRODUCTION

Definition:

→ A sudden, severe abdominal pain, it's in many cases a medical emergency, requiring urgent and specific diagnosis or surgical treatment.

→ Causes range from self-limiting to severe life-threatening diseases.



ETIOLOGY

8.42 Common non-traumatic causes of the acute abdomen		
Pathology	Organ	Disease
Inflammation	Appendix	Acute appendicitis
	Gallbladder	Acute cholecystitis
	Colon	Diverticulitis
	Fallopian tube	Salpingitis
	Pancreas	Acute pancreatitis
Obstruction	Intestine	Intestinal obstruction
	Gallbladder/bile duct	Biliary obstruction
	Ureter	Ureteric obstruction
	Urethra/bladder	Urinary retention
Ischaemia	Intestine	Strangulated hernia
		Volvulus
		Thromboembolism
	Ovary	Torsion of ovarian cyst
Perforation	Duodenum	Perforated peptic ulcer
	Stomach	Perforated ulcer/cancer
	Colon	Perforated diverticulum
		Perforated cancer
	Gallbladder	Biliary peritonitis
Rupture	Fallopian tube	Ruptured ectopic pregnancy
	Abdominal aorta	Ruptured aneurysm



8.43 Typical clinical features in patients with an 'acute abdomen'

Condition	History	Examination
Acute appendicitis	Nausea, vomiting, central abdominal pain which later shifts to the right iliac fossa	Fever, tenderness, guarding or palpable mass in the right iliac fossa, pelvic peritonitis on rectal examination
Perforated peptic ulcer with acute peritonitis	Vomiting at onset associated with severe acute onset abdominal pain, previous history of dyspepsia, ulcer disease, NSAIDs or corticosteroid therapy	Shallow breathing with minimal abdominal wall movement, abdominal tenderness and guarding, board-like rigidity, abdominal distension and absent bowel sounds
Acute pancreatitis	Anorexia, nausea, vomiting, constant severe epigastric pain, previous alcohol abuse/cholelithiasis	Fever, periumbilical or loin bruising, epigastric tenderness, variable guarding, reduced or absent bowel sounds
Ruptured aortic aneurysm	Sudden onset of severe, tearing back/loin/abdominal pain, hypotension and past history of vascular disease and/or high blood pressure	Shock and hypotension, pulsatile, tender, abdominal mass, asymmetrical femoral pulses
Acute mesenteric ischaemia	Anorexia, nausea, vomiting, bloody diarrhoea, constant, abdominal pain, previous history of vascular disease and/or high blood pressure	Atrial fibrillation, heart failure, asymmetrical peripheral pulses, absent bowel sounds, variable tenderness and guarding
Intestinal obstruction	Colicky central abdominal pain, nausea, vomiting and constipation	Surgical scars, hernias, mass, distension, visible peristalsis, increased bowel sounds
Ruptured ectopic pregnancy	Premenopausal; delayed or missed menstrual period, hypotension, unilateral iliac fossa pain, pleuritic shoulder tip pain, 'prune juice'-like vaginal discharge	Suprapubic tenderness, periumbilical bruising, pain and tenderness on vaginal examination (cervical excitation), swelling/fullness in the fornix on vaginal examination
Pelvic inflammatory disease	Sexually active young female, previous history of sexually transmitted infection, recent gynaecological procedure, pregnancy or use of intrauterine contraceptive device, irregular menstruation, dyspareunia, lower or central abdominal pain, backache, pleuritic right upper quadrant pain (Fitz-Hugh–Curtis syndrome)	Fever, vaginal discharge, pelvic peritonitis causing tenderness on rectal examination, right upper quadrant tenderness (perihepatitis), pain/tenderness on vaginal examination (cervical excitation), swelling/fullness in the fornix on vaginal examination



8.44 Clinical signs in the 'acute abdomen'

Sign	Disease associations	Examination
Murphy's	Acute cholecystitis Sensitivity 50–97% Specificity 50–80%	As the patient takes a deep breath in, gently palpate in the right upper quadrant of the abdomen; the acutely inflamed gallbladder contacts the examining fingers, evoking pain with the arrest of inspiration
Rovsing's	Acute appendicitis Sensitivity 20–70% Specificity 40–96%	Palpation in the left iliac fossa produces pain in the right iliac fossa
Iliopsoas	Retroileal appendicitis, iliopsoas abscess, perinephric abscess	Ask the patient to flex the thigh against the resistance of your hand; a painful response indicates an inflammatory process involving the right psoas muscle
Grey–Turner's and Cullen's	Haemorrhagic pancreatitis, aortic rupture and ruptured ectopic pregnancy (see Fig. 8.28)	Bleeding into the falciform ligament; bruising develops around the umbilicus (Cullen) or in the loins (Grey–Turner)



DIAGNOSIS

***** You can skip Hx & PE if you want / but better to read them *****

History:

- **Demographic** details, occupation, recent travel, hx of recent abdominal trauma.
- **Pain:** (SOCRATES)
- **Associated symptoms:**
 - * Vomiting and the nature of vomitus (undigested food or bile suggests → upper GI pathology or obstruction; faeculent vomiting suggests lower GI obstruction).
 - * Haematemesis or melaena.
 - * Stool/urine colour.
 - * New lumps in the abdominal region/groins.
 - * Eating and drinking - including when the patient's last meal occurred.
 - * Bowels - including presence of diarrhoea, constipation and ability to pass flatus.
 - * Fainting, dizziness or palpitations.
 - * Fever/rigors.
 - * Rash or itching.
 - * Urinary symptoms.
 - * Recent weight loss.
- **Past medical and surgical** history/medication.
- **Gynecological and obstetric** history:
 - * Contraception (including intrauterine contraceptive device (IUCD) use).
 - * Last menstrual period.
 - * History of sexually transmitted infections/pelvic inflammatory disease.
 - * Previous gynecological or tubal surgery.
 - * Previous ectopic pregnancy.
 - * Vaginal bleeding.
 - * Drug history and allergies - including any complementary medication.

*****مهم جداً*****

Abdominal signs may be masked in patients :

- steroids
- immunosuppressant
- anti-inflammatory drugs
- alcohol intoxication
- altered states of consciousness

Physical Examination:

- Pulse, temperature and blood pressure (**vital signs**)
- Assess respiratory rate and pattern. Patients with **peritonitis** may take shallow, rapid breaths to reduce pain.
- If there is an altered consciousness, check **Glasgow Coma Scale** (GCS) or **AVPU** (Alert, Voice response, Pain response, Unconscious) scale.

- **Inspection:**

- * Look for evidence of anaemia/jaundice.
- * Look for visible peristalsis or abdominal distension.
- * Look for signs of bruising around the umbilicus (Cullen's sign- this can be present in haemorrhagic pancreatitis and ectopic pregnancy) or flanks (Grey Turner's sign this can be present in retroperitoneal haematoma).
- * Assess whether the patient is dehydrated (skin turgor/dry mucous membranes).

- **Auscultation:**

- * Auscultate the abdomen in all four quadrants.
- * Absent bowel sounds suggest paralytic ileus, generalized peritonitis or intestinal obstruction. High-pitched and tinkling bowel sounds suggest subacute intestinal obstruction.
- * Intestinal obstruction can also present with normal bowel sounds.
- * If there is reason to suspect aortic aneurysm, listen carefully for abdominal and iliac bruits.

- **Percussion:**

- * The abdomen to assess swelling/distension might be due to bowel gas or ascites.
- * Patients who display tenderness to percussion are likely to have generalized peritonitis and this should act as a **red flag** for serious pathology.
- * Shifting dullness and fluid thrill.
- * Size of an abdominal mass/extent of organomegaly.

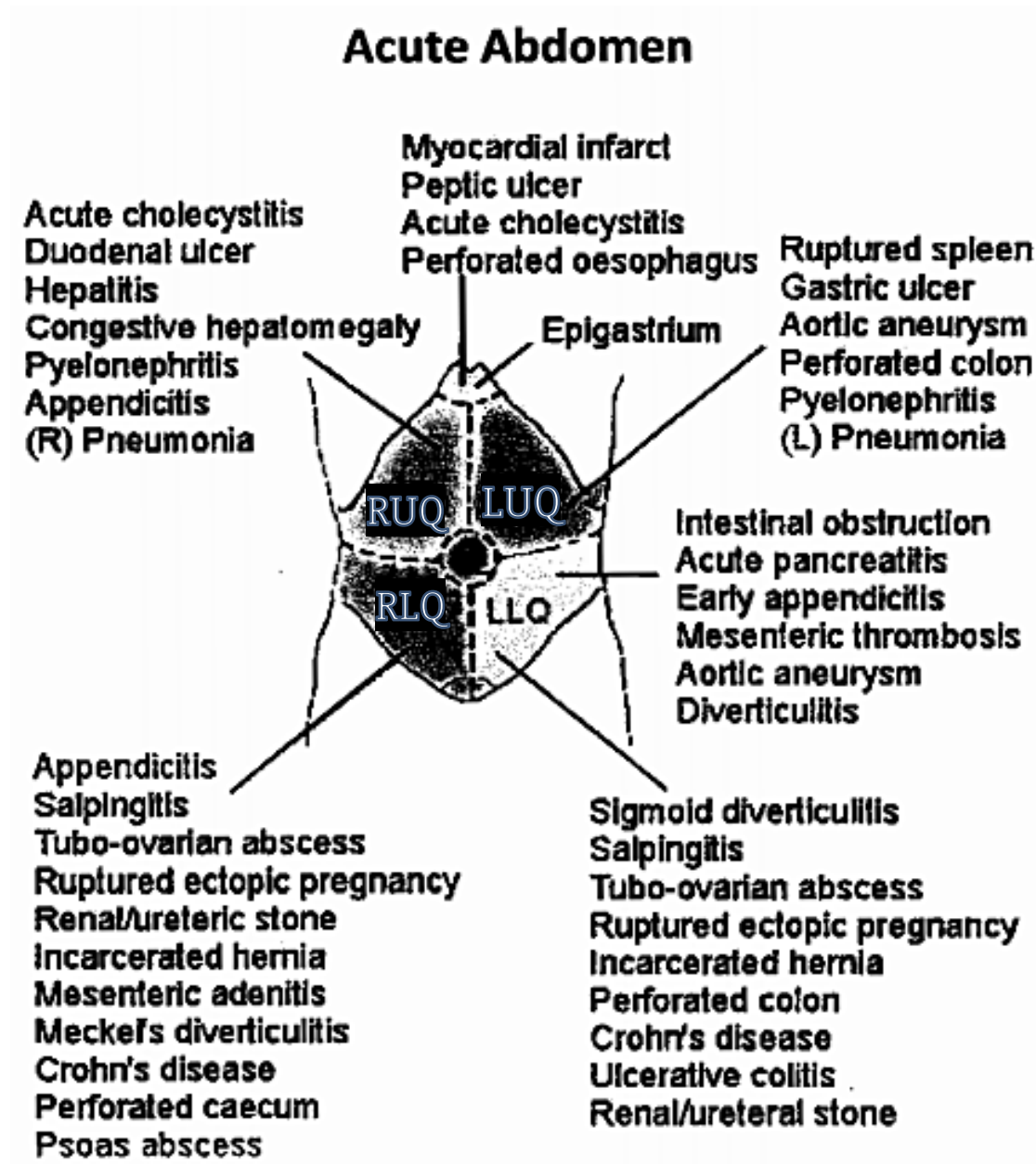
- **Palpation:**

- * superficial & deep palpation starting away from the pain moving towards it.
- * Feel for masses, tenderness, involuntary guarding and organomegaly (including - the **bladder**).
- * Rebound tenderness / Murphy's sign.
- * Examine the groins for evidence of herniae.
- * Scrotum in men as pain may be referred from unrecognized testicular pathology.
- * Check **supraclavicular** and **groin lymph nodes**.

- **Further examination:**

- * PR / pelvic examination
- * Check lower limb pulses if there could be an abdominal aortic aneurysm.
- * Dipstick urine and send for culture if appropriate.
- * **In a woman of childbearing age, assume that she is pregnant until proven otherwise - perform a pregnancy test.**
- * Examine any other system that might be relevant, eg respiratory, and CVS

Differential Dx:





TREATMENT

Assessment:

1) Initial impression/ observation:

- Does the patient look ill, septic or shocked?
- lying still (peritonitis)? /rolling around in agony (intestinal, biliary or renal colic)?
- Assess and manage **Airway, Breathing and Circulation** as a **priority**.
- In an emergency department setting: if there are signs that the patient is **shocked** or **acutely unwell** assess quickly but carefully and arrange any early investigations.

2) Hx & PE

Prehospital/Emergency department care of suspected acute abdomen:

- Keep patient nil by mouth **NPO**
- Apply **oxygen** as appropriate.
- **Intravenous (IV) fluids**: set up immediately if the patient is shocked and the equipment is available. Send blood for group and save/crossmatch and other blood tests as appropriate.
 - Consider passing a nasogastric (**NG**) tube if there is severe vomiting, signs of intestinal obstruction or the patient is extremely unwell and there is danger of aspiration.
- **Analgesia**: "فلسفة تأيم" → the previous practice was to withhold analgesia until surgical review, but a surgical abdomen is very painful and is likely only to be adequately relieved by parenteral opioids, eg morphine. One recent review showed that opioid administration may alter physical examination findings, but these changes result in no significant increase in management errors. Another study showed that morphine safely provides analgesia without impairing diagnostic accuracy. A Cochrane review also supported the use of analgesia before assessment by a surgeon.
- **Antiemetic**: avoid using this as a symptomatic treatment without considering a diagnosis in a community setting.
- **Antibiotics**: if systemic sepsis, or peritonitis, or severe urinary tract infection (UTI) is suspected. IV cephalosporin plus metronidazole are commonly used in acutely unwell patients in whom peritonitis is suspected.
- Arrange **urgent surgical/gynaecological review** as appropriate.
- Arrange **investigations** such as **ECG** if a medical cause is likely.
- **Admit**: if surgery is considered likely, if the patient is unable to tolerate oral fluids, for pain control, if a medical cause is possible or if IV antibiotics are required.

Appendix

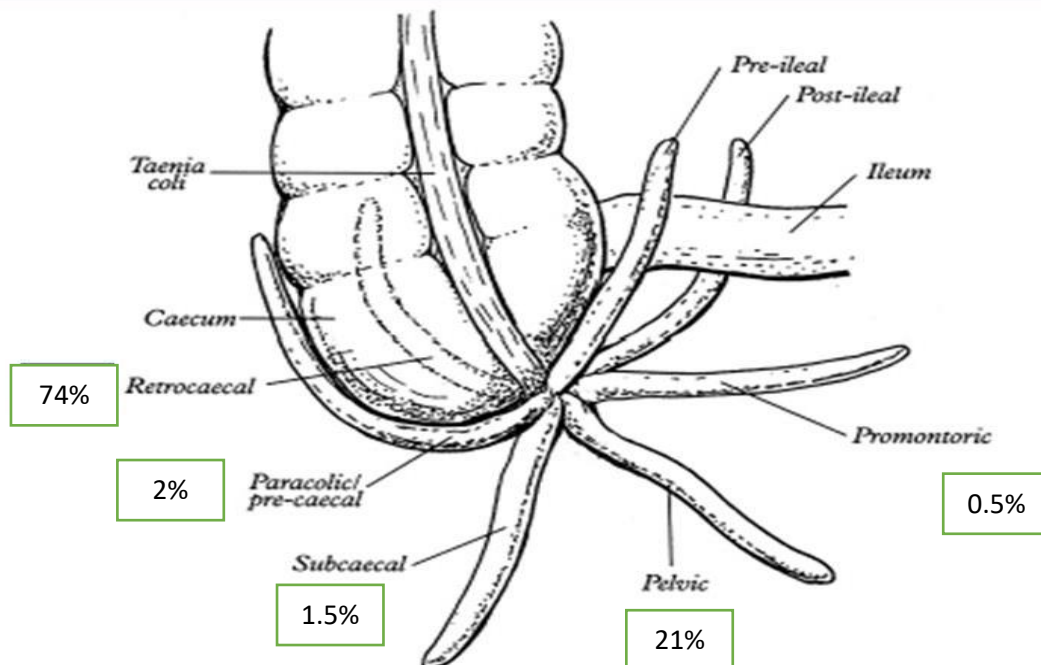
Embryology: "intra-peritoneal structure"

begins as a (bud off) from the cecum at around the 6th week of embryological development. **The base of the appendix remains in a fixed position** with respect to the cecum, whereas **the tip can end up in a various positions**

Anatomy: <https://www.youtube.com/watch?v=40WYeNMiVas>

- It's length range from 2 to 3 cm (avg. 6-9)
- Anatomical variation in the position of the appendix:

Variations in position Vermiform Appendix



- the base of the appendix is **fixed in position** while its tip is in various position.
- Most common site → **Retrocecal** (~ 74%)
- 2nd m.c site → **Pelvic** (~21%)
- Appendix lumen capacity = 1 ml.
- To locate the appendix → locate the cecum → follow the 3 taenia coli until they converge at the base of the appendix
- Blood supply → appendicular artery "end artery" (a terminal branch of the ileocolic artery that pass behind the terminal ileum and through the mesoappendix "the mesentery of the appendix")

Physiology: An immunological organ that secretes IgA

"not essential organ & can be removed"

Acute Appendicitis



INTRODUCTION

Definition: inflammation of the appendix caused by obstruction of the appendiceal lumen, producing a closed loop with resultant inflammation that can lead to necrosis & perforation

Epidemiology:

- life-time Incidence → 7% of population
- Avg age → 20 – 30 years



ETIOLOGY

Causes:

- Fecalith → 40% "most common"
- Hypertrophy of lymphoid tissue
- Tumor e.x. (carcinoid)
- Vegetable / fruits seeds
- Intestinal parasites / worms
- Inspissated barium from previous X-ray

Most common pathogens:

- Ecoli
- bacteroids fragilis

- ** Acute appendicitis is usually misdiagnosed in females & elderly
- ** Rare in extreme of age (if it happens → life threatening due to uncontrolled sepsis)



PATHOPHYSIOLOGY

Obstruction → distention (increased intraluminal pressure) → venous congestion → impaired blood supply → bacterial accumulation → inflammation → Necrosis & perforation



CLINICAL FEATURES

Symptoms: "بالترتيب"

- 1) -Diffused pain (periumbilical area) "referred pain"
- intermittent of cramps
- 2) Nausea / vomiting (After pain)
due to Neural stimulation + presence of ileus
- 3) Anorexia
- 4) pain that migrates to RLQ
(constant & intense pain) usually <24 hours
due to peritoneal irritation

Signs:

- 1) usually normal V/S
- 2) signs of peritoneal irritation :
 - Guarding / muscle spasm
 - Rebound tenderness
 - Obturator of psoas sign
 - Low-grade fever (high grade → if perforated)
 - RLQ Hyperesthesia

** McBurney's Point :

point 1/3 from the ASIS to the umbilicus
(often point of maximal tenderness)

Complications:

A) Of Appendicitis:

- * Pelvic / liver abscess
- * perforation & peritonitis
- * Portal pylethrombophlebitis
- * Gangrene

B) Of Appendectomy:

- * Small bowel obstruction (X4 more with perforation)
- * Enterocutaneous fistula
- * Wound infection
- * increase incidence of Rt inguinal hernia
- * Stump abscess
- * Infertility with perforation in females

Appendicitis in Pregnancy:

- Incidence → 1/1500
- chief complain → RUQ pain
- Risk of Fetal loss → 4%
- Risk of preterm labor → 7%
- ** it's the most common procedure done during pregnancy
- ** the only Abnormal finding is → Left shift

Obturator sign

pain upon internal rotation of the leg to the hip & knee flexed (seen in pts with pelvic appendix)

Rovsing's sign

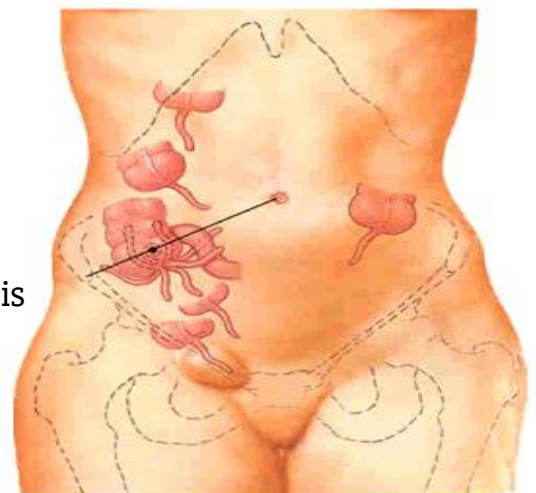
palpation / rebound pressure of LLQ resulting in pain in the RLQ (seen in appendicitis)

Psoas sign

pain elicited by extending the hip with knee extended on by flexing the hip against resistance (seen in retro cecal app.)

Valentino's sign

RLQ pain (peritonitis) from succus draining down to RLQ from a perforated gastric or duodenal ulcer





DIAGNOSIS

History & physical : refer to the OSCE Dossier

Investigations :

LAB

A) CBC : increased WBC (> 10,000 in 90%) most often with a **left shift**

B) U/A "urine analysis" : To rule out UTI (if +ve you can't rule out appendicitis)

** you may have abnormal U/A with appendicitis → **Pyuria & mild hematuria** are common in "appendicitis with pelvic inflammation" → resulting in inflammation of the ureter

** also do β -hCG / BUN / Cr / electrolytes

Imaging

A) X-ray → to rule out other pathologies.

- CXR → to rule out pneumonia & free air

- AXR → calcified Fecalith present in 5% of appendicitis cases "non-specific" findings on AXR :

1- Fecalith (5% of cases)

3- Scoliosis away from the right (due to pain)

5- Loss of psoas shadow

7- free air (if perforated) "rare"

2- Sentinel loops

4- mass effect (abscess)

6- Loss of preperitoneal fat stripe

B) CT findings:

- periappendiceal fat stranding

- appendiceal diameter <6 mm

- periappendiceal fluid

- Fecalith

C)MRI (we use it in pregnant females)

D) Graded compression sonography (U/S)

→ most sensitive

Differential diagnoses:

1) Acute Abdomen :

Meckel's diverticulum , Peptic ulcer disease, crohns, Urological causes , Gastroenteritis

2)Acute Mesentric Adenitis : (in children), M.C organism → **Yersinia enterocolitica**

3) Gyne: PID, Ruptured ovarian cyst/ graafian follicle, Ectopic pregnancy

ALVERADO SCORE :

used to assess the probability

mnemonic (**MANTRELS**)

M: migration of pain to RLQ (1)

A: Anorexia (1)

N: Nausea & Vomiting (1)

**** T**: Tenderness in RLQ (2)

R: Rebound tenderness (1)

E: Elevated Temperature (1)

**** L**: Leukocytosis (>10,000) (2)

S: Shift to the left (1)

**** 2 points for T & L ** 1 point for others**

SCORE :

<4 → unlikely

5-6 → possible

7-8 → Probable

9-10 → V. probable



TREATMENT

A) PRE-OP :

- Rehydration with IV fluid (Ringer lactate)
- Pre-op antibiotics with anaerobic coverage
(cefoxitin / cefotetan / ciprofloxacin / flagyl)

B) OP :

** If not perforated:

- prompt appendectomy → to prevent perforation
- 24 hours of antibiotics "anaerobic coverage"
- discharge home usually on postop day 1

** If perforated (Ruptured) : " 25% of rupture → after 24 h, 75% → after 48 h.

- IV fluid resuscitation & prompt appendectomy
- All pus is drained
- postop antibiotics (broad spectrum) for 3-7 days
- wound is left open in most cases of perforation after closing the fascia
- " 2ry intention or delayed 1ry closure

** If appendiceal abscess:

- percutaneous drainage of abscess
- antibiotics to fight possible peritonitis
- Elective appendectomy → 6 weeks later

Notes:

1_ If normal appendix is found upon exploration → (take it out, even in crohns UNLESS the base is involved)

2_ Dx of ruptured appendix:

- Fever (>39) - increased WBC -Rebound tenderness
- U/S → periappendiceal fluid collection.

3_ Appendectomy is the most common cause of **emergent** abdominal surgery

4_ Open vs. laparoscopic appendectomy :

** Open is more cost effective & time saving , less pain , less risk of wound infection & better anesthesia

** contraindication of laparoscopic:

- extensive adhesions - severe portal tension - coagulopathies -1st trimester preg.

5_Atypical presentations of appendicitis are not uncommon, and they depend on the location of the appendix, So pelvic appendix may present with UTI symptoms, pre-ileual & post- ileual may present with Intestinal obstruction, etc

** McBurney's vs. Rocky Davis incision:

-McBurney's → angled down "oblique"

- Rocky Davis incision → Straight across, "transvers"

** during surgery electrocautery is used → to avoid Mucocele

** Layers Cut during surgery:

Skin → Subcutaneous fat → Scarpa's fascia → Ext. oblique → Int. oblique →

transversus abdominis → Transversalis fascia → Preperitoneal fat → peritoneum

Tumors of the Appendix:

CARCINOID: "Most common"

- <5% malignant

- treatment:

If <1.5 cm → Appendectomy

If >1.5 cm → Right hemecolecotomy

- DDx:

* Carcinoid * Adenocarcinoma

* Malignant Muroid Adenocarcinoma

Small Intestines

- ➔ The longest part of the GIT and extends from the pyloric orifice of the stomach to the ileocecal fold. This hollow tube which is 6-7 meters in long consists of the Duodenum, Jejunum and the ileum. Its function is (Digestion + Absorption)

Embryology:

Foregut → esophagus to upper duodenum

Midgut → lower duodenum to proximal 2/3rd of transverse colon

** the junction b/w the foregut & Midgut is immediately distal to the opening of CBD.

Hindgut → distal 1/3rd of transverse colon to anal canal above pectinate line

Anatomy:

Ligament of trietz → marks the end of duodenum & the beginning of the jejunum.

❖ Duodenum:

- Extends from pylorus to the duodenojejunal junction.

- It's Retroperitoneal except the 1st 2cm

- Parts:

1) 1st part (Superior) → 5cm , Duodenal bulb "site of most ulcers"

2) 2nd Part (Descending) → 10 cm, curves around the head of pancreas.

3) 3rd Part (Transverse) → 10 cm, crosses anteriorly to the aorta & IVC & posteriorly to SMA & SMV

4) 4th Part (Ascending) → 5 cm, ascends past left side of aorta then curves anteriorly to meet DJ

Junction suspended by ligament of trietz.

- Blood Supply:

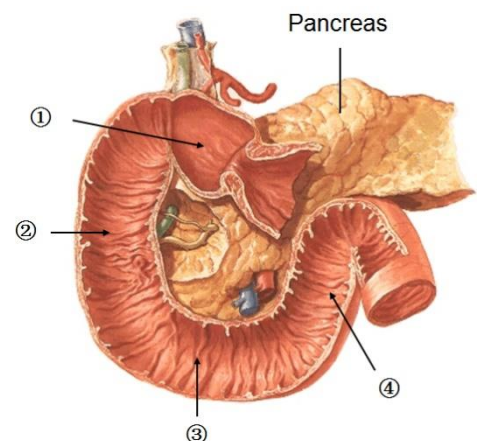
- **Proximal** part (up to ampulla of vater) → **Gastro duodenal art.** "br of proper hepatic art" it bifurcates into ant. & Post. Superior pancreatic duodenal art.

- **Distal** Part (beyond the ampulla of vater) → **inf. Pancreatic duodenal art** "br. Of SMA" also bifurcates into Ant & Post art.

- Venous Drainage:

- Ant & Post pancreatic duodenal vein, drain into → SMV (which joins splenic v. to form portal vein.)

- Prepyloric vein of mayo → it's a landmark for pylorus.



❖ Jejunum & Ileum:

- No anatomic boundaries b/w them
- Jejunum is the proximal (40% of small intestines) → "distal to ligament of trietz"
- Ileum is the distal (60% of SI).
- Mesentery tethers the jejunum & ileum to post. Abd. Wall
- Difference b/w them:
 - Jejunum →
Long vasa recta + Large plica circularis + Thicker wall
 - Ileum →
Short vasa recta + Smaller plica circularis + Thinner wall
- Terminal ileum absorbs → **B12**, fatty acids and bile salts.
- Blood supply:
branches of SMA (which runs in the mesentery)
arteries loop to form **arcades** that give rise to straight arteries → **vasa recta**.
- Venous Drainage → SMV

Plica circularis:

the circular folds of mucosa in small intestines lumen

AKA (valvulae conniventes)

plica = folds

❖ Lymphatics:

- Bowel wall → mesenteric nodes → lymphatic vessels → Cisterna chili → thoracic duct → Lt subclavian vein

❖ Innervation:

- Parasympathetic → originates from Vagus & celiac trunk + motility
- Sympathetic → originates from ganglion cells that reside at the base of SMA + motility
- Enteric Nervous system → Meissner plexus

Physiology:

90% of digestion & Absorption

Digestion in duodenum → food is mixed with (bile from liver, pancreatic juice + intestinal juice "Succus entericus")

Investigations:

⚡ It is difficult to examine the whole small bowel because of its length so we need different tests and investigations to get the whole picture:

- **Contrast study**: the patient swallows barium or the contrast material then we follow the contrast with series of X-rays until the contrast reach the colon.

- **Enteroclysis:** is mostly the same procedure but the difference here is that we inject the contrast material through a tube in the stomach.
- **Endoscopy:** classically we do upper GI endoscopy for the stomach and duodenum but there is certain techniques which help in examining the whole intestines such as:
 1. **Double balloon enteroscopy (DBE)** (also known as "push-pull enteroscopy) or the "double-bubble": is a new endoscopic technique that allows pan-enteric (complete) examination of the small bowel.
 2. **Push endoscopy** (also referred to as push enteroscopy): is a procedure that allows diagnosis and treatment of diseases in the upper small intestine. Push endoscopy reaches further into the small intestine than the standard upper gastrointestinal endoscopy.
- **MRI/CT enterography:** uses CT imagery and a contrast material for a better view of small intestine by examining it loop by loop (most commonly used).
- **Angiography:** to examine the blood supply for a tumor as an example.
- **Capsule endoscopy:** is a camera that images the entire GI tract down to the colon and look for any lesion, it is an expensive test and we have to make sure that there is no narrowing in the intestines before doing it. It is done to certain patients whose signs and symptoms are not clear.

Small Bowel Obstruction

INTRODUCTION

Definition:

Interruption in the normal flow of intestinal contents along the intestinal tract
SBO accounts for **20%** of all acute surgical admissions

** Ileus → when the obstruction is functional "it mimics the SBO"

ETIOLOGY

Risk factors: check the table.

Causes:

- **Intraluminal:**
- Fecal impaction "immobile bulk"
- Foreign bodies
- Bezoars "solid mass of indigestible materials"
 - Trichobezoars** → a hair bolus occurring in young females with long hair & psychiatric disorder
- Gall stone ileus "usually due to fistula"
- **Intramural:**
- Strictures → they are due to :
ischemia, inflammation " such as crohn's",
RTX, Surgical "iatrogenic or trauma".
- CA
- Diverticulosis
- **Extramural:**
- Hernia (internal / external) → **m.c.c world wide**
- Adhesions → fibrinous or fibrous
- Volvulus
- Intussusception

Common causes of alimentary tract obstruction, by age

Neonates

Atresia (duodenum, ileum)
Meconium obstruction
Volvulus neonatorum

3 weeks

Congenital hypertrophic pyloric stenosis

6-9 months

Intussusception

Teenage

Inflammatory masses (appendicitis)
Intussusception of Meckel's diverticulum or polyp

Young adult

Hernia
Adhesions

Adult

Hernia
Adhesions
Inflammation (appendicitis, Crohn's disease)
Carcinoma

Elderly

Carcinoma
Inflammation (diverticulitis)
Sigmoid volvulus

The most prominent Gas found in SBO → is **N₂** because it's an absorbable gas

The M.C.C of colonic obstruction:
1st Colon CA
2nd Volvulus
3rd Diverticulosis

- **Causes of functional obstruction:**
- Postop Ileus → Normally resolves in 3-5 days
- Electrolyte abnormalities → hypokalemia
- Peritonitis, sepsis, shock
- Drugs (opiates/ anticholinergic)
- Hemoperitoneal/ Retroperitoneal hemorrhage

acronym “**GIVES BAD CRAMPS**”:

Gallstone ileus

Intussusception

Volvulus

External compression

SMA syndrome

Bezoars, **B**owel wall hematoma

Abscesses

Diverticulitis

Crohn's disease

Radiation enteritis

Annular pancreas

Meckel's diverticulum

Peritoneal adhesions

Stricture

PATHOPHYSIOLOGY

Mechanism

- **Increased peristalsis** → Abd colic, increased bowel sounds, & borborygmi
- **Proximal bowel distension** → third space losses, electrolyte imbalance, air-fluid levels:
 - Increased secretion and decreases absorption → fluid accumulation
 - Swallowed air accumulation
- **Bacterial overgrowth and translocation**
- **Increased wall tension compromise of circulation**

Classifications:

- Mechanical vs. Functional (pseudo-obstruction, Adynamic, Paralytic ileus)
- Complete vs. partial

Complete vs. partial

Complete → usually no passage of stool & flatus (obstipation) + increased risk of strangulation

Partial: some passage of flatus.

****** We differentiate using CT with oral contrast + small bowel follow through

- Simple vs. complicated (strangulated)
- Small bowel (distal / proximal) vs. Large bowel obstruction
- Acute vs. chronic
- Closed loop vs. open loop
- Gangrenous vs. non-gangrenous



CLINICAL FEATURES

Signs and Symptoms:

- Colicky **pain** → if proximal then time b/w attacks is LESS than distal obst.
- **Vomiting** → Proximal > Distal
its color → watery/ bile stained "green"/ feculent if distal "brown + smelly"
- **Constipation** → Distal > Proximal
**in distal there is no passage of flatus while in early proximal there can be.
- **Distention** → Distal > Proximal
**in distal we might see visible peristalsis + visible right iliac fossa bulge "caecum" if there was a competent ileocecal valve.
- Diarrhea → in certain cases like partial obst, colon CA, GB obstruction
- Increased bowel sounds + visible peristalsis.

Signs of strangulated bowel with SBO:

- **Fever/** Severe & continuous pain
- **Tachycardia**
- Hematemesis
- **Shock/ Acidosis/ Peritoneal signs**
- Gas in the bowel wall or portal vein /Abdominal free gas

Complications:

- Bowel ischemia → necrosis
- Perforation.
- Sepsis
- Intra-abdominal abscess
- Wound dehiscence
- Aspiration
- Short-bowel syndrome (as a result of multiple surgeries)
- Death (secondary to delayed treatment)



DIAGNOSIS

History:

- 1) **Abdominal pain** → Central, Crampy and intermittent.
- 2) Nausea
- 3) **Vomiting**
- 4) **constipation** or **obstipation**
- 5) Diarrhea
- 6) **Fever & tachycardia** - Occur late and may be associated with strangulation
- 7) Hx of abdominal or pelvic surgery, previous radiation therapy, or both
- 8) Hx of **malignancy** - Particularly ovarian and colonic malignancy

**** Changes in the character of the pain may indicate the development of a more serious complication (i.e., constant pain of a strangulated or ischemic bowel).**

Physical Examination:

- Abdominal **distention**
- **Hyperactive bowel sounds** → occur early as GI contents attempt to overcome the obstruction
- **Visible peristalsis**
- Borborygmi
- Abdominal scars
- Abdominal hernias
- **Rectal examination:**
 - Gross or occult blood → suggests late strangulation or malignancy
 - Masses → suggest Obturator hernia

Labs:

CBC / Electrolytes / Creatinin/ BUN/ Urine analysis

Imaging:

- **Plain AXR:**
 - Erect → multiple air-fluid level (non-specific)
 - Supine → Distended Bowel
 - Duodenum → hollow tube
 - Jejunum → Plica circularis "coins like"
 - Colon → Haustration
 - Gas in intramural space → infarction
 - Gas under diaphragm → Perforation
- **Enteroclysis / CT / Ultrasound.**

By Supine abd X-ray:

- *Confirm Dx
- *Detect if proximal or distal
- *Detect type of intestine involved

**** Presence of any gas in Small intestine is indicative of obstruction.**

UNLIKE colon, which normally contain gas



TREATMENT

Management:

Initially

- NPO
- NG tube
- IV fluid
- Foley catheter

Then

- If complete obstruction:
 - lysis of adhesions (adhesiolysis)
- If partial obstruction:
 - initial management + conservative treatment + close observation + NGT decompression

Medically:

→ Non-operative treatment "dr. qudah slide 29"

Surgical:

Open surgery is frequently used for patients with

- strangulating adhesive SBO
- after failed conservative management
- in appropriate patients, a laparoscopic approach using an open access technique is recommended

Small Bowel Tumors



INTRODUCTION

✦ It is only about 1-2% of the GI tumors, Same in males and females.

- Benign lesions are more common distal, while carcinomas are more common proximal.



ETIOLOGY

✦ **Risk factors:**

- Familial adenomatous polyposis.
- HNPCC.
- Peutz-Jeghers syndrome.
- Crohn's disease.
- Celiac disease.
- Biliary diversion



CLINICAL FEATURES

✦ **Clinical presentation:**

- Age: 6th/7th decades of life.
- Found incidentally.
- Vague symptoms (nausea, dyspepsia, epigastric discomfort, weight loss, hemorrhage).
- Other presentations: Mass, fistula, perforation, intraperitoneal hemorrhage.



DIAGNOSIS

✦ Contrast studies, special types of upper endoscopy, angiography, CT/MR enterography ..

✚ The tumors are classified into a benign, malignant and a carcinoid which we can't tell if the tumor is definitely benign or definitely malignant:

1- Adenoma (benign tumors)

✚ The benign are adenomas which are polyps, 20% are in duodenum 30% are in jejunum and 50% are in ileum, and as more distal the polyp is the more benign it is, villous adenomas are more common in duodenum and as more villous structure there the more potential to be pre-Malignant.

- Because it is benign, it's commonly asymptomatic, may present with obstruction, bleeding (mainly upper GI bleeding that due to a polyp in the jejunum).
- Malignant changes increase with increased size, site (Adenomas involving the ampulla transform to malignancy more often than do lesions found elsewhere in the duodenum and small intestine).
- Patient's with FAP have increased risk to develop duodenal polyps, and polyps elsewhere in the GI tract. The interesting thing that developing polyps in the colon has a 100% risk to develop cancer, but that of the small bowel, the risk of developing cancer is 2-12%.
- It is treated by surgical excision and follow up

✚ Other benign tumors:

- fibromyoma, lipoma, leiomyomas and other vascular tumors.

2- Malignant tumors:

✚ Always produce symptoms, the most common presentation is weight loss and pain, other presentations are obstruction, bleeding, adhesions and diarrhea.

a) Carcinoid tumor

✚ It originates from the enterochromaffin cells.

- It may present in the foregut, midgut and the hindgut.
- It is the most common cancer of the appendix and it is found accidentally (after appendectomy) so it is painless.
- The most common site of the Carcinoid is the terminal ileum.
- Carcinoid increases the risk of developing adenocarcinoma of the colon by 10-20% causing obstruction, fibrosis, and ischemia.
- It is a slow growing, yellow tumor that can metastasize to the nearby LN which they are around vessels, fibrosis may occur there so it will cause ischemia in a segment of the small bowel, and that is what we found during surgery; a yellow tumor and an ischemic segment of the small bowel.

✦ So, the Carcinoid may metastasize to nearby lymph nodes and to the liver, where it will cause ulceration, obstruction and jaundice.

- Carcinoid of the Terminal ileum seems to be more aggressive than that of the appendix.
- The risk of metastasis increases with increasing size, so if the tumor size is more than 2 cm, the risk of metastasize more and more. If the metastasis happens toward the liver this increases the risk of developing the Carcinoid syndrome, where serotonin (secreted by the tumor) can bypass the liver and cause diarrhea and flushing.
- By logic, the prognosis becomes more and more dismal if the metastasis occurs.
- There is a correlation between Carcinoid and increasing levels of acetic acid; Since 5-HIAA is a metabolite of serotonin, testing is most frequently performed for the diagnosis of carcinoid tumors of the enterochromaffin (Kultschitzky) cells of the small intestine, which release large amounts of serotonin. Values greater than 25mg per 24 hours (higher if the patient has malabsorption) are strong evidence for carcinoid. (The normal range is 2 to 6 mg per 24 hours)
- About 30% of Forgut Carcinoid patient lack the enzyme that convert L-5 hydroxytryptophan to serotonin, so we check it if we suspect the patient to have forgut Carcinoid.

✦ Treatment of carcinoid:

- **Surgical resection** with the involved lymph node if we cannot resect all tumor we do **tumor debulking “cytoreduction”** (remove part of tumor+ give Cryotherapy).
- Radiofrequency ablation: Two probes is placed inside the tumor, the radiofrequency waves passing through the probe increase the temperature within tumor tissue and results in destruction of the tumor and stop the tumor.
- Embolization of hepatic artery.
- Chemotherapy.
- Chemoembolization.
- Somatostatin or its analog (systemic therapy).
- No Chemotherapy in Carcinoid.

b) Adenocarcinoma:

✦ More common in proximal small bowel, Usually in older people

⌘ Present with nonspecific symptoms.

⌘ Treatment: Resection with involved lymph node.

⌘ Notes:

- The more proximal the tumor in small bowel the more malignant, and adenocarcinoma is more common in proximal small bowel.
- In proximal small bowel tumors, we can't do major resection in the upper small bowel because wherever we get proximal in small bowel we get closer to the root of mesentery which is superior mesenteric artery that we cannot resect because it's the main supply to the small bowel.
- So we do wedge resection with the involve lymph node.
- The 5-year survival is worse if we have lymph node involvement.
- **Exception:** Crohn's disease and adenocarcinoma:
 - Patients with Crohn's which occurs mostly in terminal ileum have increased risk of adenocarcinoma in terminal ileum.
 - Usually in younger patients.
 - More in males.
 - Prognosis is poor because there is other disease (there are two diseases; Crohn's and the cancer).
 - We diagnose Crohn's disease by biopsy. But in some situations we treat patients based on our clinical findings, Always be careful in diagnosis because in Crohn's disease you will give the patient immunosuppressant → if the patient had a tumor → it will grow faster.

c) Gastrointestinal lymphoma

⌘ We talked about GI lymphomas in Chapter 1, here we'll concentrate on the small intestine.

- The 2nd most common site for GI lymphoma is the small intestine.
- It can present with obstructing, bleeding, anorexia or weight loss.
- Usually seen in older people.
- More common in ileum because it contains more lymph nodes.
- Associated with celiac disease and immunosuppression (AIDS).
- Treatment is medical unless complicated.
- Complications are perforation, hemorrhage, obstruction, and intussusception.

d) Gastrointestinal stromal tumors (GIST):

- Usually arise from connective tissue cells

- Could be benign or malignant.
- The risk of malignancy is related to the size of the tumor.
- More common in stomach compared to small bowel and usually in older people.
- There is no lymphatic spread but it can metastasize to peritoneum and liver.
- Prognosis depends on tumor size and mitotic figures on pathology.
- Treatment: surgery with clean margins.

Fistulas



INTRODUCTION

Definition:



Abnormal communication between 2 epithelized organs



ETIOLOGY

Causes

Mnemonic



HIS FRIEND

High output fistula (> 500 cc/day)

Intestinal destruction (> 50% of circumference)

Short segment fistula (< 2.5 cm)

Foreign body (e.g., G-tube)

Radiation

Infection

Epithelization (e.g., colostomy)

Neoplasm

Distal obstruction



PATHOPHYSIOLOGY

Classification

- External "m.c" vs. Internal
 - ** external = to the skin

- Proximal vs. Distal

- Proximal:

→ usually high output

→ associated with dehydration/ malnutrition/ electrolytes disturbances.

LOW OUTPUT = < 200

MODERATE OUTPUT = 200-500

HIGH OUTPUT = > 500

Types

❖ **Enterocutaneous Fistula** → from GIT to skin
(entero – cutaneous = bowel to skin)

- Causes
 - Anastomotic leak.
 - Trauma/ iatrogenic.
 - Infections → Abscess/ TB/ Amebiasis.
 - Crohn's disease.
 - Diverticulitis (m.c.c of colovesical fistula).
 - Inflammation.
 - Inadvertent suture into the bowel.
 - Vascular compromise.
- Complications
 - High output fistula
 - Malnutrition
 - Skin breakdown
- Investigations
 - CT scan → to rule out abscess/ inflammation
 - Fistulogram
 - Endoscopy
- Management
 - NPO/ TPN
 - Drain the abscess
 - Rule out or correct the underlying cause
- Treatment
 - 50% → resolves spontaneously after 4 weeks of sepsis & adequate nutrition support.
 - 50% → Need surgery (considered dirty surgery)
 - Long fistulas heals faster
 - Resection & primary anastomosis
 - Vacuum assisted closure device

Cholecystenteric Fistula:

- ➔ Connection b/w GB & duodenum or other loop
due to large erosion, often result in SBO as the gallstone lodges the ileocecal valve (gallstone ileus)

Gastrocolic Fistula:

- ➔ Causes by penetrating ulcers, gastric or colonic cancer, crohn's
- ➔ Complications are malnutrition & severe enteritis

Factors increase rate of closure:

- Decrease output
- Long tract > 2 cm
- Small orifice < 1 cm

❖ Colonic Fistula

Colovesical (m.c) → presents with recurrent UTI

Colocutaneous / Colovaginal / Coloenteric

- Causes

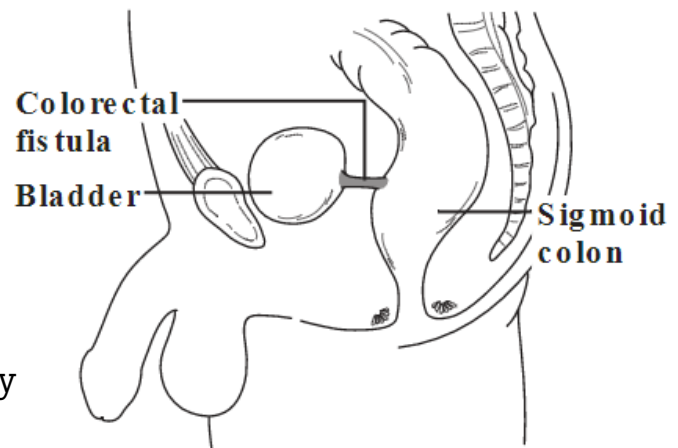
- Diverticulitis (m.c)
- Foreign body
- Cancer
- IBD
- RTX "irradiation"

- Diagnosing

- Barium enema or Cystoscopy

- Treatment

- Surgery → segmental resection & primary anastomosis & repair/resection of the involved organ



❖ Pancreatic Enteric Fistula

→ Decompression of a pseudocyst or abscess into adjacent organ, (usually done surgically or endoscopically to treat a pancreatic pseudocyst).

→ External Pancreatic Fistula

Pancreatico-cutaneous fistula → drainage of pancreatic exocrine secretions into skin (usually through drain/tract/wound).

- Diagnosing → ERCP

- Management & Treatment

- NPO/TPN/Skin protection
- Octreotide → somatostatin (decrease the output of the fistula)
- If refractory "doesn't resolve with conservative medical Mgt"
 - ** if in the **tail** = tail resection,
 - **if in the **head** = pancreaticojejunostomy.

→ Bladder Fistula

- Types

- Vesicoenteric → 50% to sigmoid diverticulitis
signs: Pneumaturia/ Fecaluria
- Vesicovaginal → secondary to gynecological procedures
Signs: Urinary leak through vagina

→ Fistula In Ano → from rectum to anal skin

- Causes → Anal crypt infx / Perianal abscess
- S&S → Perianal drainage/ perianal abscess/ diaper rash/ itching.

Colon, Rectum & anus

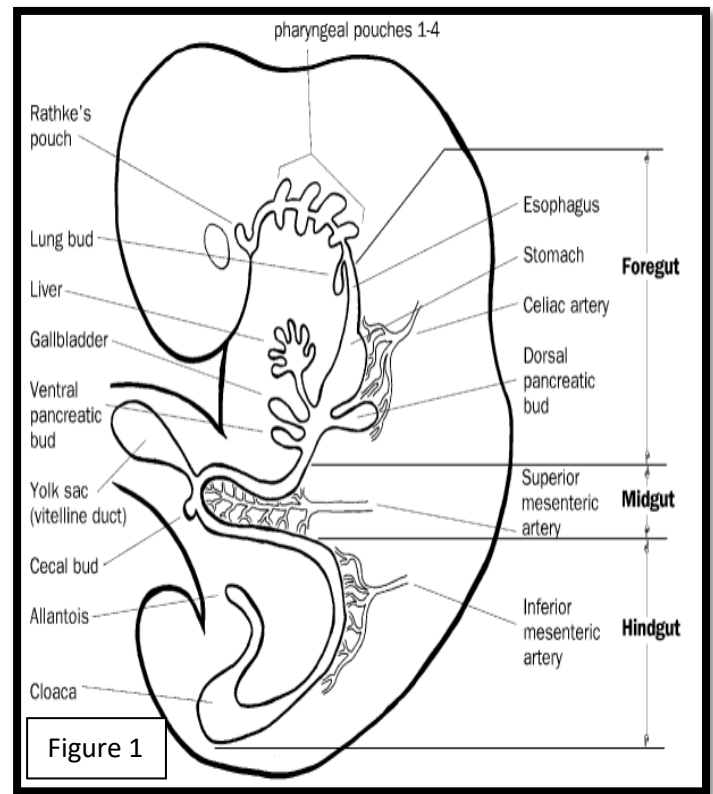
- Written by: Mohammad Karajeh & Yousef Al-As3d
- Corrected by: Mohammad Qussay Al-Sabbagh & Nada Hajjaj

- Colon: 210
 - Introduction: 210
 - Colonic polyps: 214
 - Colorectal CA: 217
 - Surgical management of colorectal cancer: 222.
 - Diverticular disease: 225
 - Volvulus: 230
- Anorectum: 234
 - Introduction: 234
 - Hemorrhoidal diseases: 239
 - Anal fissure: 244
 - Perianal suppuration: 247
 - Other anaorectal conditions: 253.
 - Anal CA: 256

The Colon

❖ Embryology: [Figure 1]

- The embryonic midgut (Endoderm) gives rise to the ascending colon and 2/3 of the transverse colon.
- The embryonic hindgut (Endoderm) gives rise to the rest of the colon, rectum and the proximal anus.
- In the development of the midgut loop, it rotates 270° counterclockwise around the axis of SMA. (Development anomalies include malrotation or failure of the right colon to elongate).
- The ectoderm gives rise to the distal anus.
- The dentate line (in the anal canal) marks the transition between the hindgut and the ectoderm.



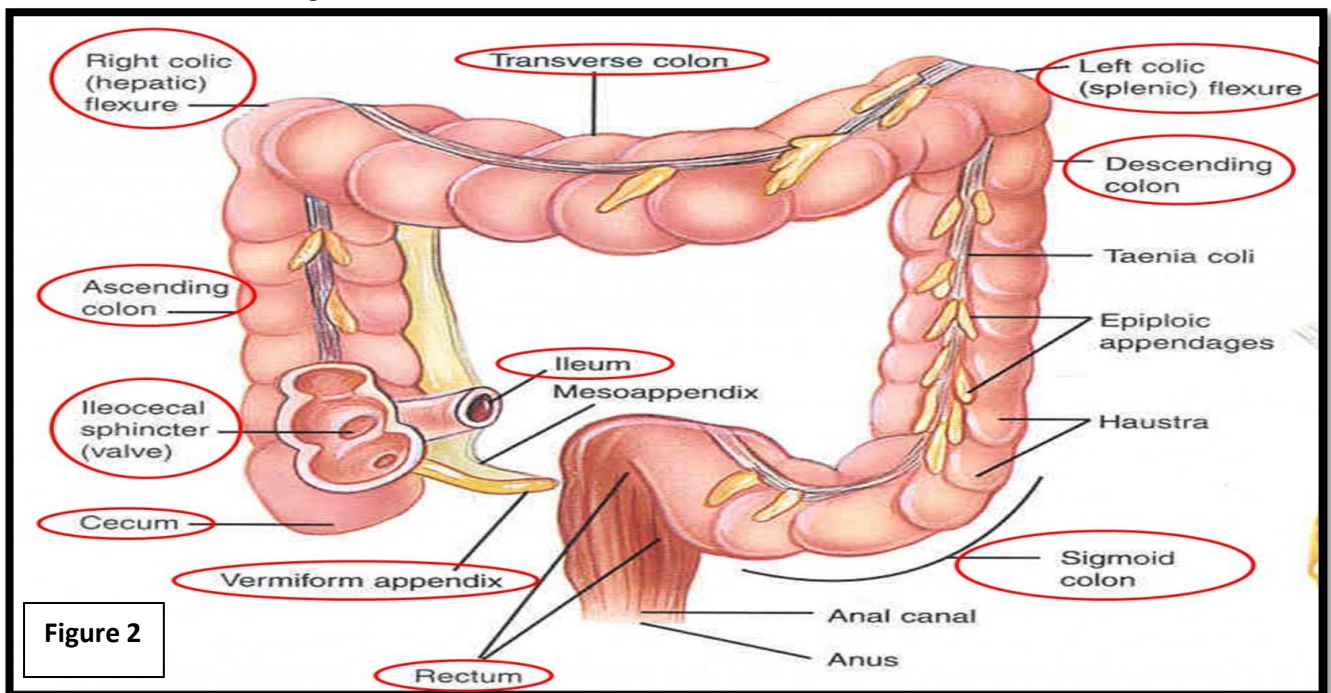
❖ Anatomy: [Figure 2]

- The colon is approximately **1.5 m long**.
- The colon begins at the ileocaecal valve and extends to the rectum.
- It includes: **Cecum** [7 cm], right (**ascending**) colon [20 cm], **transverse** colon [45 cm], left (**descending**) colon [30 cm] and **sigmoid** colon [40 cm].
- Between the ileum and the cecum there's an ileocecal valve which prevent the reflux of bowel content from the cecum back to the ileum.
- The cecum is the widest, the colon progressively narrows distally.
- The colon has **taenia coli**, **haustra** and **appendices epiploicae** (fat appendages that hang off antimesenteric side of the colon).

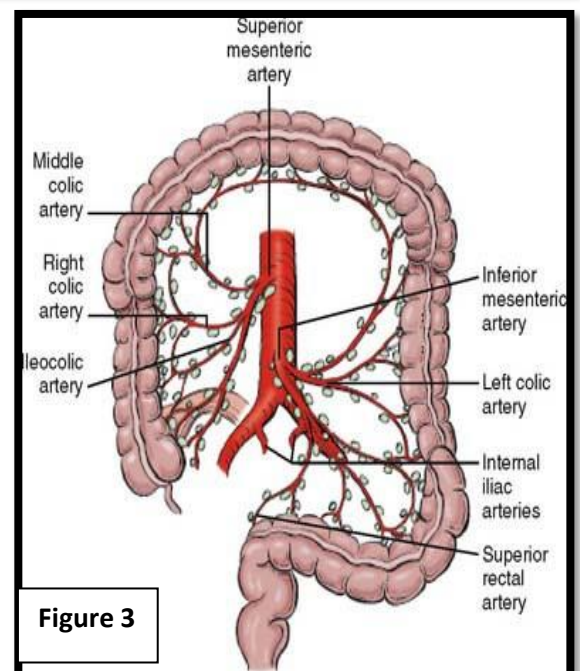
Despite the length of the colon, the cecum can be reached with as little as 70 cm of colonoscope.

- **Taenia coli** are three distinct bands of longitudinal muscle which converge at the appendix and spread out to form the longitudinal muscle layer at the proximal rectum.
- **Haustra** are sac-like segments which appear after contractions of the colon.
- Retroperitoneal structures: Ascending colon and descending colon.
- Intraperitoneal structures: Cecum, Transverse colon and sigmoid colon.

Note: the only parts of the GI tract which are not covered by serosa are: the esophagus, middle rectum and distal rectum.



- **Blood supply:** [Figure 3] Superior mesenteric artery gives three branches:
 1. Ileocolic artery → Supplies the cecum.
 2. Right colic artery → Supplies the ascending colon.
 3. Middle colic artery → Supplies the proximal 2/3 of the transverse colon.
- Inferior mesenteric artery gives three branches:



1. Left colic artery → Supplies the distal 1/3 of the transverse colon.
 2. Sigmoidal artery → Supplies the sigmoid.
 3. Superior rectal artery → Supplies the superior third of the rectum.
- The anastomosis between the terminal branches of the SMA and IMA forms a continuous arterial circle or arcade along the inner border of the colon called **“the marginal artery of the colon”**.
 - **The splenic flexure** represents a **“watershed” area** between areas that are supplied by SMA and IMA, and it's particularly **susceptible to ischemic injuries** as seen in ischemic colitis.
 - The venous drainage of the colon is through the SMV (drains the cecum, ascending and descending colon) and IMV (drains the descending, sigmoid and proximal rectum).
- Both SMV and IMV drain the colon before joining the splenic vein.**
- **Lymphatic drainage:** It follows the arterial supply.
 - **Histology:**
 - Mucosa → Submucosa → innercircular muscular layer → outer longitudinal muscular layer (forming taenia coli).
 - The mucosal layer consists of epithelium, lamina propria and muscularis mucosa.
 - The submucosal layer contains the **Meissener plexus** (submucosal plexus) which is part of the enteric nervous system (ENS) and it controls colon secretions.
 - Between the circular and longitudinal muscular layers there's the **Myenteric plexus** (Auerbach plexus) which is part of the enteric nervous system (ENS) and it controls colon motility.
 - **Innervation:**
 - Derived mainly from the autonomic nervous system (ANS):
 1. Sympathatic → inhibits peristalsis and secretion.
 2. Parasympathatic → stimulates peristalsis and secretion.
- The ANS can control the GI tract independently and through the enteric nervous system**

❖ Microbiology:

- The colon is sterile at birth.
- Normal flora is established shortly after birth.
- Normal flora includes:
 - 99% Anaerobic (Predominantly Bacteroides fragilis).

- 1% Aerobic (Predominantly E.coli).

❖ Physiology:

The main physiological functions of the colon are:

- Absorptions and Secretions:

- The principal function of the colon is absorption of water.
- Sodium and chloride absorption also take place in the colon.
- Active excretion of Potassium takes place.

- Motility:

- Colonic motility is variable.
- Two types of contractions take place:
 1. Segmentation → Mixing contractions which are responsible for the appearance of haustra.

Note: Constipation is the inability to pass stool with the ability to pass flatus, while obstipation is the inability to pass stool and flatus.

2. Contractions resulting in mass movement → 1-3 times/day.

- Storage of feces.

Colonic polyps



INTRODUCTION

✦ polyps are classified into 4 types:

- **Inflammatory:** associated with inflammatory bowel disease; Crohn and Ulcerative colitis.
- **Metaplastic or Hyperplastic:** Hyperplasia of the epithelium.
- **Hamartomatous:** related to certain syndromes example is *Peutz Jegher syndrome* which is very rare and is associated with perioral pigmentation (macules and melanosis) with benign hamartomatous polyps. Another example is *Juvenile Polyposis Syndrome*.
- **Neoplastic:** The one which we are concerned with mostly, results from abnormality in the glands. Examples including adenoma, carcinoma and carcinoid.

✦ Colonic polyps can be benign or malignant, and as we mentioned they result from gland abnormality.

- Neoplastic colonic polys are also known as adenomas and have different growth patterns therefore they have been classified into:
 1. *Tubular adenomas*
 2. *Tubulovillous adenomas*
 3. *Villous adenomas*
- Also, polyps can vary in morphology; they can either be sessile or pedunculated.



PATHOPHYSIOLOGY

✦ Most of colon cancer develops from polyps (adenoma-carcinoma sequence) so the removal of the polyps reduces the risk of cancer.

- If you discover a polyp in a patient, you need to complete your colonoscopy because there are probably much more polyps and could be on the other side.

⚡ Factors that determine the risk of malignancy:

- **Degree of dysplasia**; the more the dysplastic the polyp, the higher the grade, and the higher risk of malignancy.
- **Size of the polyp**; the larger the polyp (>1cm), the higher the risk of malignancy.
- **Histological type**: Villous has a higher risk for cancer than tubular.
- **The location of the polyps**; if it's proximal, it has higher risk of malignancy.
- **Number of polyps**.

⚡ Guidelines for screening adenoma:

<u>findings</u>	<u>colonoscopy</u>
1 or 2 small tubular adenoma with low grade dysplasia	Repeat colonoscopy 5-10 years after polypectomy
3-10 adenomas or 1 adenoma > 1 cm or any villous feature or high grade dysplasia	Repeat colonoscopy in 3 years
>10 adenoma	Repeat in <3 years
Patients with sessile adenomas that are removed	Repeat in 2-6 months to verify complete removal

- **Note**: hyperplastic polyps if <1 cm (except those with hyperplastic polyposis) have the same follow up as no polyps

⚡ Malignant potential related to the size of the polyp:

	<u><1 cm</u>	<u>1-2 cm</u>	<u>>2 cm</u>
<u>Tubular</u>	1%	10%	35%
<u>Mixed</u>	5%	10%	45%
<u>villous</u>	10%	20%	55%

? ETIOLOGY

✚ Most of the colonic polyps are sporadic, however, there are some familial syndromes.

1- **Familial Adenomatous polyposis:**

- **Familial adenomatous polyposis (FAP):** It is an autosomal dominant inherited disorder.
- There is a mutation on APC gene on chromosome 5.
- Hundreds of colonic polyps are found (100 or more polyps for diagnosis), and also polyps may be found in other parts of the GIT (Eg. Duodenal polyps). This disorder is associated with 100% risk of colon cancer. There are many extra-colonic manifestations most commonly:
 1. Upper GI adenoma (95%): duodenal polyps, and fundic gland polyps.
 2. Connective tissue: Desmoid, Osteomas, and Epidermoid cyst (80%); it's called **Gardner syndrome** in these cases.
 3. CNS: CHRPE (75%).
 4. Endocrine: papillary thyroid cancer.
 5. Hepatobiliary: biliary tract carcinoma, hepatoblastoma.
- APC gene mutations in 80% of cases, 20% will have new mutations; in milder forms we will have attenuated FAP.
- **Screening:** If the patient has a family history of FAP, we do clinical surveillance starting at 13-15 years of age if no polyps are present we start at 20 (by endoscopy), or we do genetic testing.
- **Prophylactic treatment:** total colectomy + restorative surgery, upper GI surveillance at age of 30 and looking for duodenal polyps every 2 years. **Sulindac and Celecoxib** causes regression of polyp but require frequent examination.

2- **Juvenile Polyps:** another syndrome, the patient develops multiple hamartomatous polyps (50-200) at the age of 4 years in various sites (rectum, colon, stomach), autosomal dominant but it's rare with 30-50% risk of cancer.

3- **Peutz-Jeghers syndrome:** Multiple hamartomatous polyps and melanotic pigmentations on lips and buccal mucosa

- increase risk of cancer (the risk is 50% by age of 60).
- Most common symptom is abdominal pain due to intussusception or bowel obstruction by large polyp.

4- Turcot syndrome:

- Autosomal recessive
- Polyps + cerebellarmeduloblastoma and glioblastoma.

Colon cancer



INTRODUCTION

- 2nd most common cancer in Jordan, more common in sigmoid.
- There is screening for colon cancer since more people are being affected.
- The overall survival is 45% and this number is improving.
- It's a major problem in the Western World.
- Males and females are affected equally.
- Sigmoid more common than cecum, but rectum is more common than sigmoid.



ETIOLOGY

⌘ Environmental & dietary risk factors:

- Smoking.
- Alcohol.
- Lack of fiber in diet
- Excess fat in the diet
- Lack of exercise.
- Bile acids (as carcinogens after cholecystectomy, so calcium is protective since it binds free bile acids.)

⌘ Predisposing conditions:

1. Age >50
2. Adenomatous polyps
3. longstanding IBD.
4. gastrectomy, vagotomy and uretero- sigmoidostomy.
5. Inflammatory bowel disease
6. Obesity

7. Acromegaly
8. BRCA 1 mutation.

PATHOPHYSIOLOGY

⚡ Most GI cancers arise from adenomas, the change from benign to malignant cancer involves 2 stages, mutations that convert normal mucosa into adenoma, then, mutations that convert a benign tumor to a cancer.

- The series of this mutations is called Adenoma carcinoma sequence.
- APC → K-RAS → DCC → P53.

⚡ Aspirin and colon cancer:

- COX enzyme is thought to be related to the pathogenesis of colon CA.
- Low dose (81mg) causes mild decrease risk of recurrent adenomas but no decrease risk of colon cancer.
- Full dose aspirin decrease the risk of colon cancer
- Protective effect of aspirin is related to:
 1. dose of ASA.
 2. frequency of use.
 3. duration of use

⚡ Inherited colon cancer:

1. **Polyposis**; FAP, Gardner syndrome, Tarcot syndrome, peutz-jeghers syndrome, discussed earlier.
2. **Non polyposis** ; hereditary non polyposis colon cancer (lynch syndrome)
 - Patients don't have familial polyps
 - **Diagnostic criteria (Amsterdam Criteria)**: It's the occurrence of colon cancer in at least 3 1st degree relatives over at least 2 generations with at least 1 person diagnosed < age of 50.
 - Females with HNPCC have increased risk of ovarian and endometrial cancers (also renal/ureteral , stomach and pancreas)
 - Start screening at age 25.

⚡ Pattern of spread :

- **Direct**: circumferentially bowel wall – abdomen
- **Hematogenous**: portal system to liver / systemic to the lung
- **Lymphatic**: transepithelial and intraluminal

- Metastasize always to the liver first via portal circulation but if it invades only the rectum it will bypass portal circulation



CLINICAL FEATURES

⚡ General symptoms:

High risk:

1. Rectal bleeding with change in bowel habits especially in older age.
2. Persistent bleeding without anal symptoms.
3. Palpable right sided abdominal mass.
4. Palpable rectal mass (not pelvic).
5. Unexplained iron deficiency anemia.
6. Change in bowel habit without bleeding (>6 weeks, especially with old age).

Low risk:

1. Rectal bleeding with anal symptoms such as pain, prolapsed hemorrhoid.
2. Rectal bleeding with obvious external cause e.g. anal fissure
3. Change in bowel habit in young people.
4. Abdominal pain.

⚡ Despite the fact that most Colorectal cancers have the same biology, they differ in their presentation according to the site of the tumor:

- **Right sided tumors:** right side of the bowel has a large diameter, so a tumor may attain a large size before causing problems, so it presents with IDA, occult melena, hematochezia, postprandial discomfort & fatigue.
- **Left sided tumors:** left side of the bowel has smaller diameter with semisolid content, so it presents with change in bowel habits, colicky pain & signs of obstruction.
- **Rectal tumors:** presents usually with hematochezia, mucus discharge, tenesmus & feeling of rectal mass.

⚡ Note: endocarditis caused by strep bovis or C.septicum is often associated with colon cancer so do GI workup in these patients



DIAGNOSIS

⚡ **History:** diagnostic flags:

- Weight loss / anorexia.
- Fever
- Positive heme stool
- Anemia
- Change in bowel habits esp nocturnal stool
- Onset of sx after age 45.

⚡ **Colonoscopy:** it is a diagnostic test that could be therapeutic by removing polyps, but carries risk of bleeding and perforation.

- If we find a tumor on one side there is a 3-5% probability to have another one on the other side (synchronous tumors), so we need to do colonoscopy to the whole colon.

⚡ **Barium enema:** it is only diagnostic using X-Ray imaging.

⚡ **CT colonography:** it requires exposure to radiation, and contrasts that may damage the kidneys. It is only diagnostic.

⚡ **Fecal occult blood test:** looking for blood in the stools, used for screening purposes. So we don't use it for patients with obvious rectal bleeding.

⚡ **Staging of colon cancer: (TNM)**

- Stage I T1(submucosa) or T2 (muscularis) / No / Mo
- Stage II T3 (to the tissue) or T4 (visceral peritoneum) / No / Mo
- Stage III T1-4 (any) / N1 / Mo
- Stage IV any T / any N / M1

Index for colonoscopy:

- 1)Occult blood
- 2)Abnormal barium enema
- 3)Adenomatous polyp
- 4)FP syndrome / HNPCC
- 5)History of colon cancer
- 6)1st degree relative with colon cancer
- 7)Unexplained IDA
- 8)Gross lower GI bleeding (except if bright red in young patient)
- 9)IBD
- 10)Strept.bovis or C. septicum bacteremia
- 11)4-8 weeks after new onset diverticulitis (to rule out cancer)
- 12)Persistent diarrhea with negative blood test and not meeting the criteria for diagnosis of IBS

✦ Screening for colon cancer :

- Fecal occult blood testing (fobt)
- **Colonoscopy** (or flex sigmoidoscopy + barium enema)
- CEA

Tests that detect adenomatous polyps and cancer:

- 1) Colonoscopy / 10 years
- 2) Or flexible sigmoidoscopy / 5 years
- 3) Or double contrast barium enema / 5 years
- 4) CT colonography / 5 years

Tests that detect cancer :

- 1) Annual rectal immunochemical test
- 2) Annual guaiac based fecal occult blood
- 3) Stool DNA test

- If the polyp is benign repeat every 3 years.
- Any positive test (other than colonoscopy) should be followed up by colonoscopy with biopsy of any polyp / adenomatous.

✦ FOBT: annually

- Positive in about 2% (varies with age ; >5% after age of 60) and about 2% of these have colon cancer.
- Poor screening test but quick and cheap also least invasive ; negative in up to 66% of patients with colon cancer !! it can miss 1/3 of advanced colon cancer !
- Full FOBT series use 6 hemoccult , even if only one FOBT is positive do colonoscopy (or flex sigmoidoscopy + barium enema but is less desirable)

✦ Colonoscopy:

- Have the highest yield of finding polyps and cancer
- It is the screening procedure of choice

✦ CEA (carcinoembryonic antigen) :

- Good only in checking for recurrence of cancer
- CEA also increase in smokers , patients with benign biliary disease , PSC or IBD .

✦ The 10 years rule :

- **High risk patients:** colonoscopy should be at age 40 years or 10 years before age at which index case is diagnosis



TREATMENT

✦ **surgical resection:**

- 1st option.
- Surgeries could be curative or palliative (after the staging always remember to discuss options with the patient and to assess the patient's status before doing surgeries, to prevent death during the operation).
- recurrence happens due to micrometastases.
- Hepatic resection increase survival with solid liver metastasis

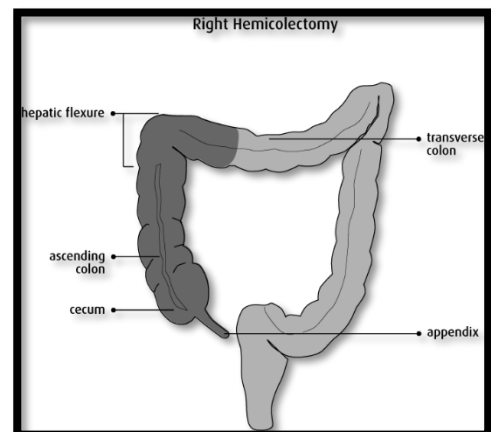
✦ **Adjuvant chemotherapy:** 5-FU effective only stage III or locally advanced stage II

✦ RTX (prior to surgery) is helpful for rectal lesion only.

Surgical management of colorectal cancer

✦ **Right hemicolectomy:**

- resected material: terminal ileum + cecum + ascending colon + proximal transverse colon
- Plus, resection of right colic artery + ileocecal artery +/- middle colic artery
- Plus, removal of fat and lymph node
- indications: right colon cancer / cecum cancer

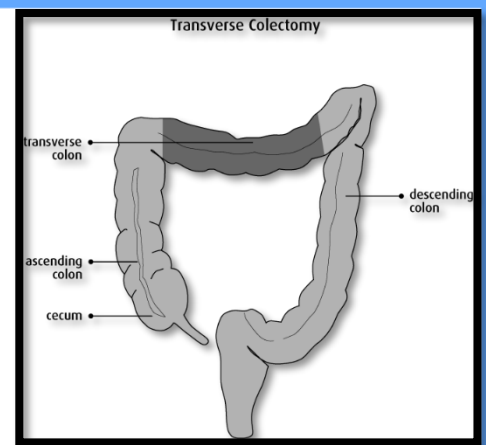


✦ **Extended right hemicolectomy:**

- resected material: same as right hemicolectomy + remainder of transverse colon and splenic flexure + resection of right colic artery, ileocecal artery and middle colic artery
- indications: hepatic flexure cancer / transverse colon cancer (proximal mid)

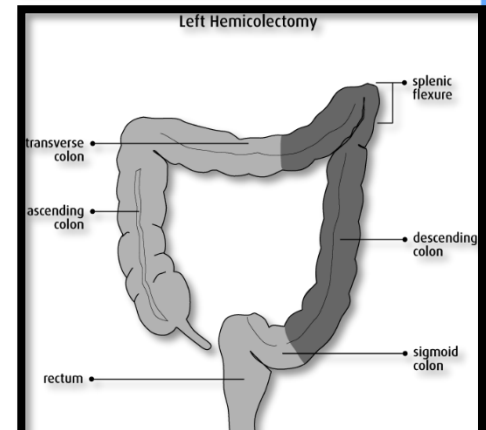
◆ **Transverse colectomy:**

- Resected material: transverse colon + middle colic artery
- indication: transverse colon cancer



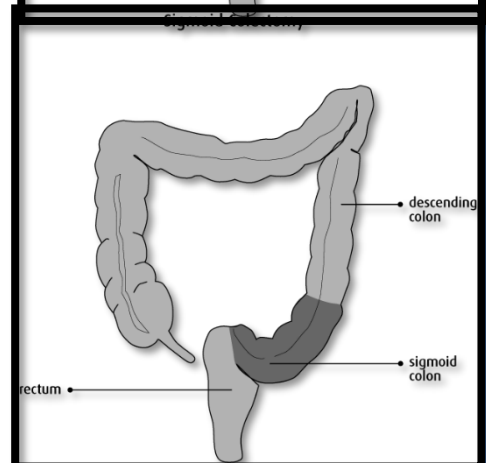
◆ **left hemicolectomy:**

- Resected material: descending colon + left colic artery
- indications: splenic flexure cancer / left colon cancer



◆ **Sigmoid colectomy:**

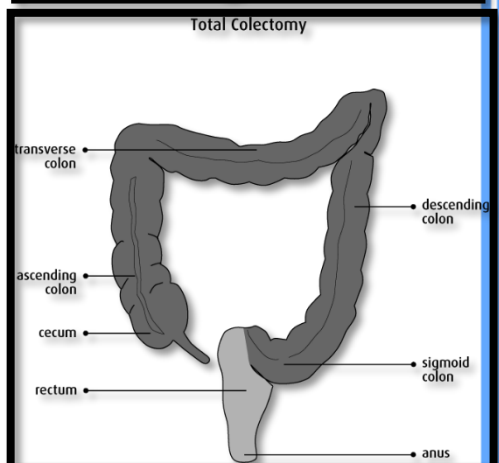
- Resected material: sigmoid colon + sigmoid artery.
- indications: sigmoid / rectosigmoid cancer.



◆ **Total colectomy:** removal of the entire colon without the rectum

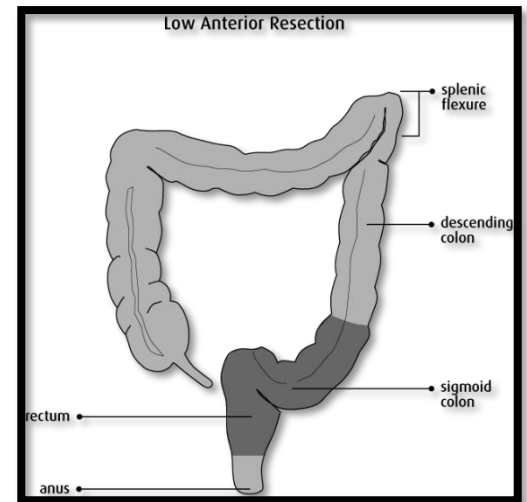
◆ **Proctocolectomy:** removal of the entire colon and rectum

◆ **Subtotal colectomy:** removal of part of colon / all of the colon without complete resection of the rectum



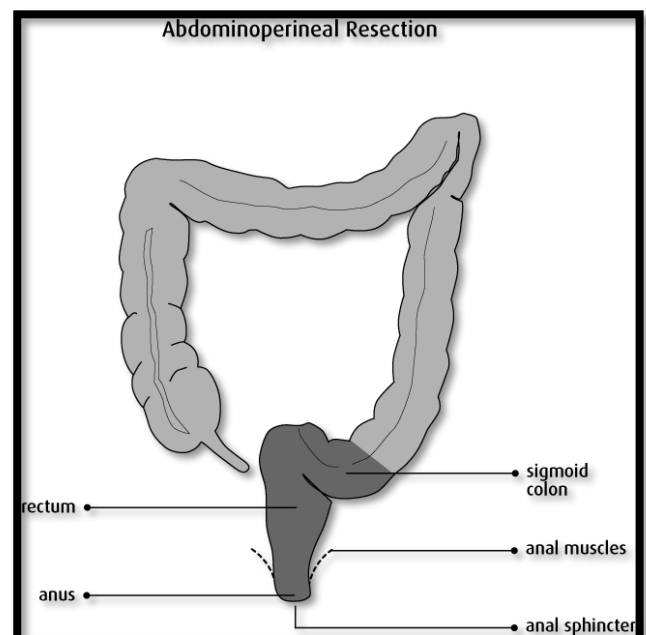
✚ Low anterior resection(LAR):

- resection of low rectal tumors through an anterior approach.
- Indications: proximal rectum cancer
- criteria:
 1. Tumors >4 cm from anal verge (with distal intramural spread <2 cm)
 2. must be able to get 2 cm margin
- If a rectal tumor doesn't meet these criteria, we have to do the radical (and bad) surgery; abdominoperineal resection, but in some cases, we may give neoadjuvant chemotherapy to down stage the tumor, then we do LAR
- includes total mesorectum excision
- Complications: incontinence , urinary dysfunction , sexual dysfunction , anastomotic leak(5-10%), stricture (5-20%)
- **Hartmann's procedure:**
 1. proximal colostomy.
 2. distal stapled off colon/rectum that is left in peritoneal cavity.



✚ Abdominal perineal resection (APR) :

- Removal of the rectum and sigmoid colon through abdominal and perineal incisions (patient is left with a colostomy).
- indications: distal rectum cancer / anal cancer
- done in tumors not fitting criteria for LAR
- the anus is closed
- permanent colostomy (due to removal of the anus)
- complications: stenosis , retraction or prolapse of ostomy , perianal wound infections



Diverticular diseases



INTRODUCTION

Colonic diverticula are false diverticula in which mucosa and submucosa protrude through the muscularis propria (not all the layers).

Diverticulosis is just the presence of outpouching without inflammation, diverticulitis is if they become inflamed.

Acquired herniations of mucosa through the muscle wall between the mesenteric and antimesenteric taenia.

Most common structural abnormality of the bowel.

The sigmoid colon is MC affected due to decreased luminal diameter and increased luminal pressure.

Incidence:

- < 40 yr = 5%
- > 85 yr = 85%
- **Sigmoid colon is involved in over 95%** of patients affected with diverticulosis
- In western countries left-sided diverticulitis predominates with right-sided diverticulitis occurring in only 1.5%
- 10-25% of pts will develop diverticulitis



ETIOLOGY

- 1) Low fiber diet
- 2) Elderly
- 3) Chronic constipation
- 4) Family history
- 5) Decreased physical activity, obesity.
- 6) Smoking.

Diverticulosis

- Most common cause of lower GI bleeding.



CLINICAL FEATURES

Symptoms:

- Asymptomatic (80% of cases).
- Bleeding. (and may be massive because the media of perforating artery adjacent to the colonic diverticulum may become attenuated and eventually erode). Bleeding is bright red and not associated with previous melena or chronic blood loss and most often from left colon.
- Diverticulitis and complications.



TREATMENT

- 1) If asymptomatic → High fiber diet is recommended.
- 2) If bleeding → Although it may be massive it is usually self-limited (80% spontaneously stop), resuscitation with fluids
- 3) Perform colonoscopy 6 weeks after inflammation (but not during attack due to risk of perforation) to rule out colon cancer as a cause of bleeding.

Surgical indications:

- 1) Elective resection of the affected colon segment:
 - Patients with recurrent bleeding
 - Need for long term anticoagulation
 - Excessive blood loss cannot be tolerated
- 2) Urgent resection of the affected colonic segment:
 - Active ongoing bleeding (> 6 units packed RBCs / 24 hours)

Diverticulitis



INTRODUCTION

Definition: Infection or perforation of a diverticulum.

Epidemiology: Occur in 10-25% of patients with diverticula (90% left sided , 10% right).



PATHOPHYSIOLOGY

Obstruction of the diverticulum by a fecalith leading to inflammation and micro-perforations leading to fecal extravasation and subsequent peri-diverticular and pericolic inflammation.

Classification:

- 1- Uncomplicated diverticulitis (75%): only inflammation (LLQ), usually resolve without surgery, classical triad (localized tenderness, fever and leukocytosis) → Its called left sided appendicitis because it has the same features.
- 2- Complicated diverticulitis: diverticulitis with abscess, obstruction, diffuse peritonitis, fistulas. **Hinchey classification** used to assess severity.



CLINICAL FEATURES

Presentation:

- 1) Lower left quadrant(LLQ) pain may radiate to suprapubic area, left groin or back, cramping or steady pain.
- 2) Fever, altered bowel habits (diarrhea), urinary urgency or dysuria, nausea and vomiting.
- 3) P/E : Varies with the severity of the disease but the most common is LLQ tenderness. a mass may suggest abscess or phlegmon.

Complications:

- 1) Diverticular abscess:
 - Usually identified on CT scan.

- A percutaneous drain should be placed under radiologic guidance –which avoids immediate operative drainage, and allows time for the inflammatory phlegmon to be treated.

- Treat with IV antibiotic

- Thus, one-stage procedure can be done (instead of 2 or 3 stages).

2) Generalized peritonitis:

- Rare; result from diverticular perforation leading to widespread fecal contamination.

- In most cases, resection of the diseased segment is possible and a Hartman procedure is done, the colostomy later closed (2-stages procedure).

- Another option for a patient without significant fecal contamination:

Sigmoidectomy + Colonic lavage + Colorectal anastomosis +/- loop ileostomy.

3) Fistulisation:

- Fistulas between colon and other organs may occur secondary to diverticulitis.

- **Colovesical fistulas are the most common and diverticulitis is the most common cause of colovesical fistulas.**

- Colovaginal and colovesical fistulas usually occur in women who have previously undergone hysterectomy.

- Colocutaneous and coloenteric fistulas are uncommon.

- Colonoscopy should be done after 6 weeks to rule out other causes of fistulas.



DIAGNOSIS

- 1- CT scan : may find segmental colonic thickening , swollen edematous wall, focal extraluminal gas, helpful to diagnose abscess formation.
- 2- CBC: high WBCs.
- 3- Sigmoidoscopy (not indicated due to risk of perforation), contrast enema (not indicated due to risk of barium / fecal peritonitis).



TREATMENT

Management: depends on whether it is an uncomplicated or complicated attack, and whether it is a first attack or not.

- First uncomplicated attack of diverticulitis should be treated conservatively, while complicated attacks (abscess, fistula, peritonitis, perforation, obstruction) need operative management according to each complication.

- Conservative:

- 1- Bowel rest
- 2- Clear liquids for 2-3 days then advance diet as tolerated
- 3- IV fluids
- 4- Antibiotics:
 - IV antibiotics that cover G-ve / anaerobes for 3-5 days then switch to oral to complete 10-14 day course.
 - Either monotherapy: Ticarcillin-Clavulanate or Piperacillin-Tazobactam or Ampicillin-Sulbactam.
 - Or Rocephin (Ceftriaxone) + Flagyl (Metronidazole).
- 5- May include percutaneous drainage of abscess.

After successful conservative treatment of 1st episode, 1/3 have a second attack, and 1/3 of those who have a 2nd attack have third attack.

Surgery indications:

- 1) After first or any complicated diverticulitis attack
- 2) After 2 or more episodes of uncomplicated

(Management is always individualized according to patient, these are general guidelines)

Hinchey classification:

To assess severity, degree of peritoneal contamination (which determine pre-op antibiotics and appropriate intervention), the Hinchey classification (and in 1999, modified Hinchey classification) was developed.

- 1) Stage 1: Pericolic or mesenteric abscess.
- 2) Stage 2a: Distant abscess. / Stage 2b: Complex abscess and fistula.
- 3) Stage 3: Generalized purulent peritonitis.
- 4) Stage 4: Generalized fecal peritonitis.

Stage 1 & 2 can be treated conservatively during attack, with percutaneous drainage of abscess. After the attack has resolved, an elective laparoscopic resection of diseased segment with primary anastomosis and stoma. This is followed by colostomy closure three months later.

Summary:

- Mild diverticulitis treated as outpatient with clear fluid diet and broad-spectrum oral antibiotics for 10 days.
- Severe diverticulitis: complete bowel rest, IV fluids, narcotic analgesia, broad-spectrum IV antibiotics.
- After episode: a high fiber low residue diet should be resumed. Fiber supplements and stool softeners should be given to avoid constipation.

Colonic Volvulus



INTRODUCTION

Definition: Twisting of colon on itself about its mesentery → resulting in obstruction and – if complete – vascular compromise with potential necrosis, perforation or both.

Types:

- 1) Sigmoid volvulus (most common) 75%
- 2) Cecal volvulus 25%

3) Transverse volvulus (rare)

Sigmoid Volvulus

? ETIOLOGY

Risk factors:

- High fiber diet
- Elongated colon
- Chronic constipation
- Laxative abuse
- Pregnancy
- History of abdominal surgery or distal colon obstruction

🔍 CLINICAL FEATURES

Signs and Symptoms:

- Acute abdominal pain
- Progressive abdominal distention
- Anorexia
- Obstipation
- Cramps
- Nausea and vomiting

Signs of strangulation:

- 1) Discolored / hemorrhagic mucosa on sigmoidoscopy
- 2) Bloody fluid in rectum
- 3) Frank ulceration / necrosis at the point of twist
- 4) Peritoneal signs
- 5) Fever / hypotension / increased WBC

Signs of necrotic bowel in colonic volvulus (in X-ray): Free air / Pneumatosis (air in bowel wall).



DIAGNOSIS

- Sigmoidoscopy or radiographic exam.
- Abdominal X-ray findings: distended loop of sigmoid colon, classic **omega sign** / **coffee bean sign**, with loop aiming toward right upper quadrant.
- With gastrografin enema if sigmoidoscopy and plain films fail to confirm diagnosis → bird's beak is pathognomonic seen on enema contrast study



TREATMENT

- Initially --non-operative:

If there are no strangulation → **sigmoidoscopic reduction** is successful in approx. 85% of cases (enema will reduce only 5%), **recurrence is approx. 40% !!!**

- **Indications of surgery (resection):** if strangulation is suspected / unsuccessful reduction.

- Most patients undergo resection after successful non-operative reduction due to high recurrence rate (~40%).

Cecal Volvulus



ETIOLOGY

- Idiopathic
- Poor fixation of the right colon
- History of abdominal surgery



CLINICAL FEATURES

Signs and symptoms:

- 1) Acute onset of abdominal colicky pain (starting in right lower quadrant and progressing to a constant pain)
- 2) Vomiting
- 3) Obstipation

- 4) Abdominal distention
- 5) Small Bowel Obstruction



DIAGNOSIS

- Abdominal X ray: dilated ovoid colon with large air-fluid levels in right lower quadrant (**coffee bean sign**) with apex toward epigastrium / left upper quadrant (must rule out gastric dilation with nasogastric aspiration).
- Water soluble contrast study – if diagnosis can't be made on abdominal X ray.



TREATMENT

- Emergent surgery → **Right colectomy** with primary anastomosis or ileostomy and mucus fistula (1ry anastomosis may be done in stable patients).

-Notes:

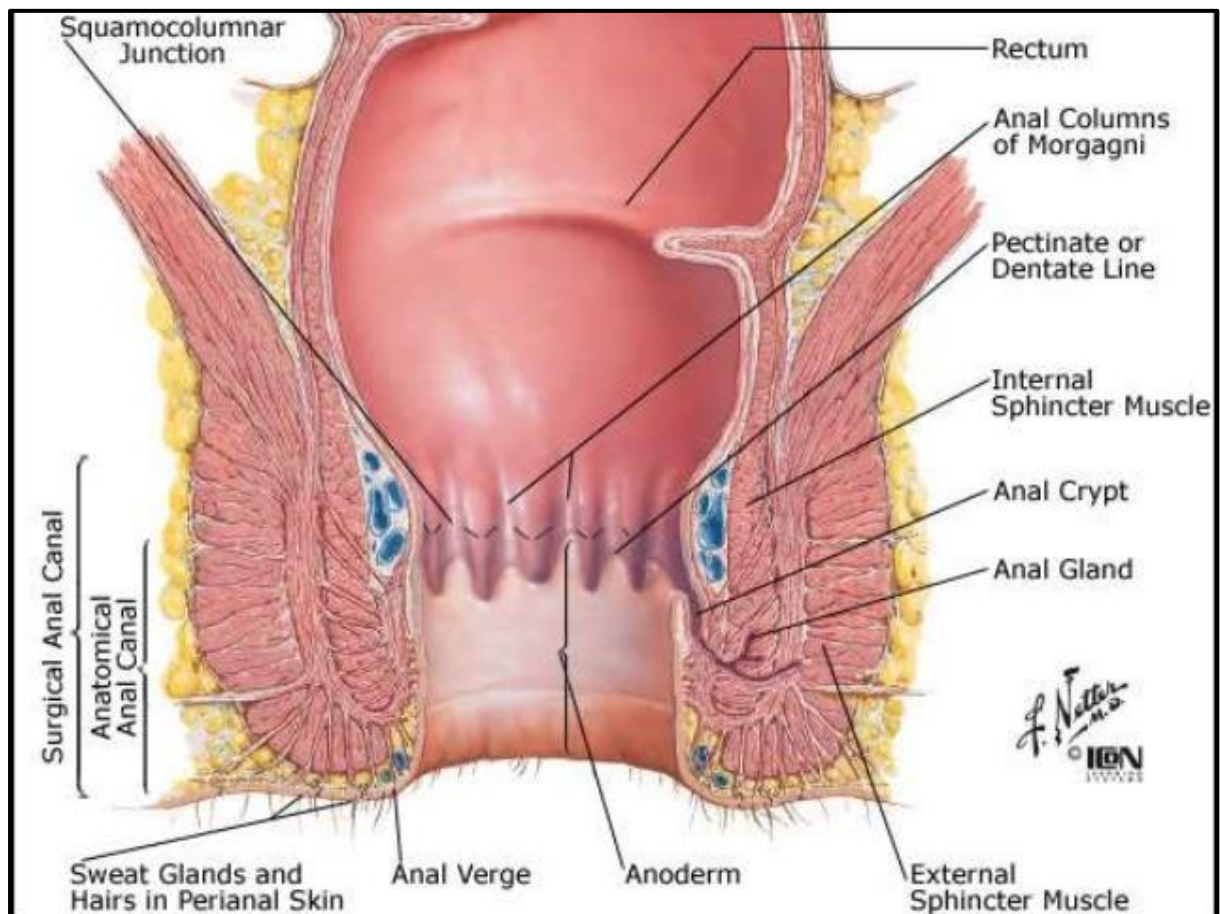
- Patients with cecal volvulus require surgical reduction while the vast majority of patients with sigmoid volvulus undergo initial endoscopic reduction of the twist.
- Transverse volvulus is very rare.
- Gastric volvulus can occur.

Anorectum

Embryology:

The rectum and the proximal anus are hindgut organs, so they are derived from **Endoderm**. Distal anus is derived from **ectoderm**.

Anatomy:



Rectum:

12-15 cm. Divided into upper, middle and lower thirds.

Upper third is covered by peritoneum anteriorly and laterally.

Middle third is covered by peritoneum anteriorly.

Lower third is extraperitoneal.

Fascia in front of the lower third is called Denovillier's fascia.

Waldey's fascia (rectosacral fascia): Condensations of presacral fascia in the lower part of the sacrum (S4).

Lateral ligaments: From the rectum to the sides of the pelvis. Contain middle rectal vessels.

Anus:

Anatomical anal canal: From anal verge to the dentate line (3 cm) (One embryonic and anatomical structure).

Surgical anal canal: From anal verge to the anorectal ring (5 cm).

Anal verge: The opening of the anus on the surface of the body. Or it is the transitional zone between the moist, hairless, modified skin of the anal canal and the perianal skin.

Dentate line (Pectinate line): A mucocutaneous line that separates proximal, pleated mucosa from distal, smooth anoderm (1–1.5 cm above anal verge)

Formed by series of cusps. The spaces within the cusps are called crypts, into which the ducts of mucus secreting anal glands open.

It is considered a watershed area because it separates two embryonic structures that differ in their epithelium, sensation, blood supply and lymphatic drainage.

Anal mucosa proximal to dentate line lined by columnar epithelium; mucosa distal to dentate line is a specialized form of skin (squamous) that is devoid of skin appendages. It is called the anoderm.

The transitional area (a.k.a. Cloacogenic area) is the actual mucocutaneous junction (not the dentate line). It is 1 cm above the dentate line. This area is lined by columnar, squamous or any type of epithelium.

Columns of Morgagni: 12–14 columns of pleated mucosa superior to the dentate line separated by crypts.

Anal glands:

- 8 – 12 in number.
- Lay in the intersphincteric plate.
- Their ducts open in the crypts.
- Most of them are located in the anterior part of the anus.

Anal sphincters: Internal and External.

The internal sphincter: specialized rectal smooth muscle (from inner circular layer); involuntary, contracted at rest, responsible for 80% of resting pressure.

The external sphincter: Striated muscle. A continuation of puborectalis muscle; responsible for 20% of resting pressure and 100% of voluntary pressure.

3-loop theory:

- a- Subcutaneous part
- b- Superficial part (attached to the coccyx).
- c- Deep part (attached to the pubis).

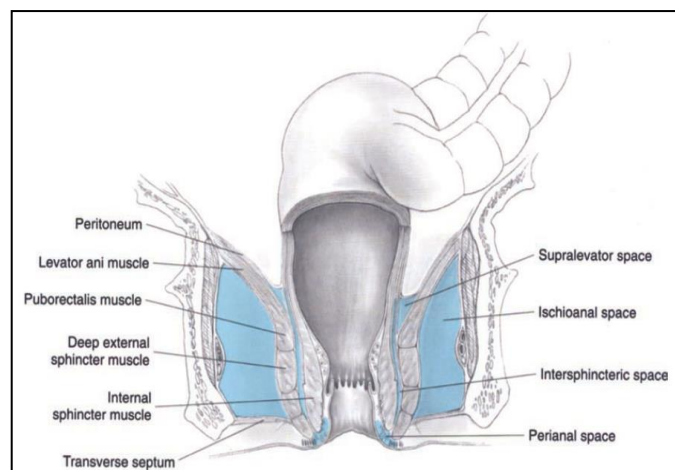
Anorectal ring: Formed by deep part of internal sphincter, deep external sphincter and puborectalis muscle

Important in continence mechanism; it maintains a right / acute angle.

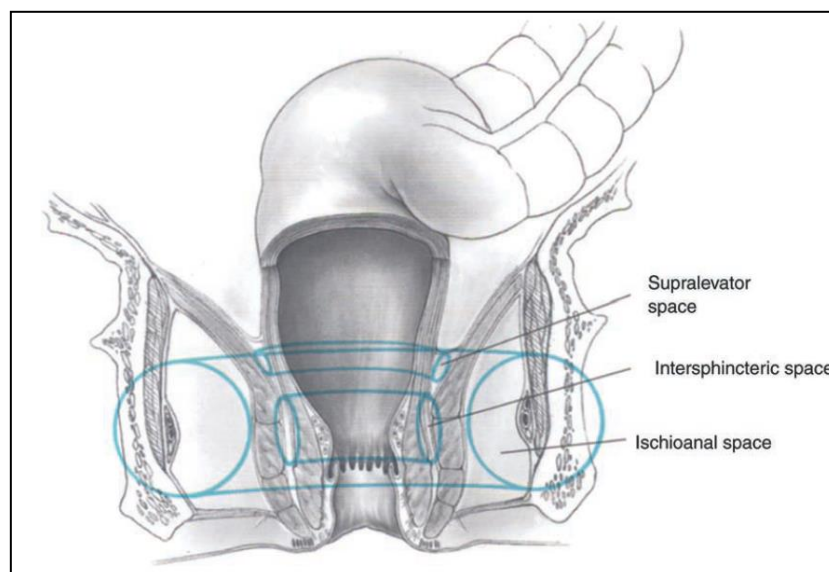
Ptosis in the anorectal ring will cause rectal prolapse.

Perianal spaces:

- Perianal space proper.
- Ischioanal fossa.
- Intersphincteric space.
- Supralelevator space.



The anorectal spaces connected in a horseshoe-shape:



Blood supply:

Arterial:

- Rectum: **Porto-systematic:**
 - 1- Superior rectal arteries from IMA – Portal.
 - 2- Middle and Inferior rectal arteries from Internal Iliac – Systematic.
- Anus: **Systematic:** Internal pudendal artery (from internal iliac).

Venous:

Drains to IMV, Internal iliac vein, internal pudendal vein and hemorrhoidal plexuses.

Hemorrhoidal plexuses: Three complexes within the anus (Internal; contains highly oxygenated blood) that drain into the superior rectal veins and one external complex that drains into the pudendal veins.

Lymphatic drainage:

- Perirectal lymphatics → Mesenteric (mostly) and internal iliac nodes.
- Anal lymphatics → Superficial inguinal nodes.

Note: Anal canal above dentate line drains to inferior mesenteric nodes or to internal iliac nodes. Lower anal canal drains to inguinal nodes.

Nerve supply:

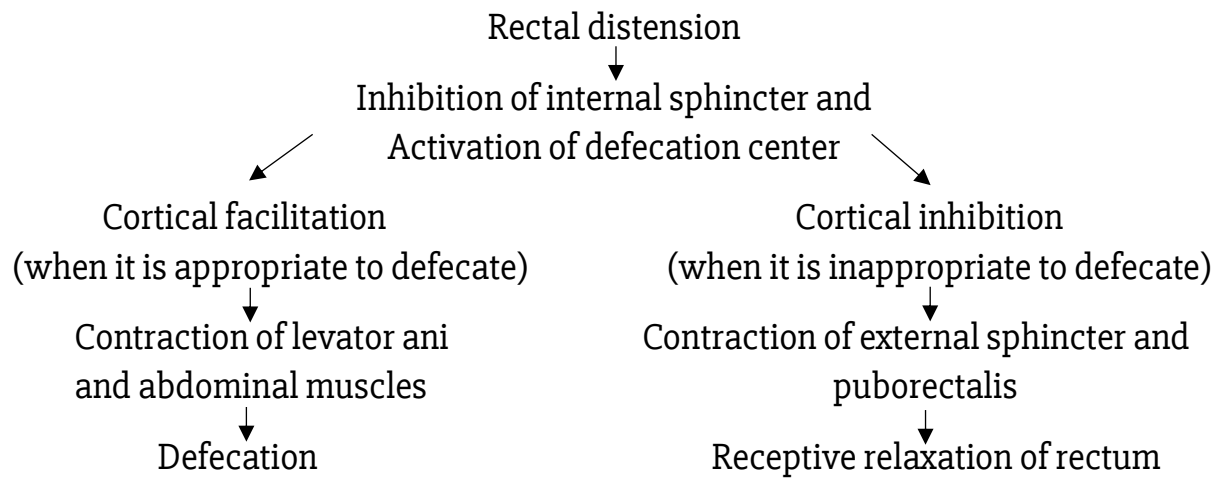
- Sphincters:
 - 1- Internal: Sympathetic (L1-L3) and parasympathetic (S2-S4) [Hypogastric plexus a.k.a. presacral plexus]
 - 2- External: Internal pudendal nerve (S2-S4).
- Anus: Internal pudendal nerve (S2-S4) [sensory and motor].
 - Below dentate → Sensitive to pain.
 - Above dentate → Insensitive to pain.

Notes:

- Internal sphincter is a smooth muscle; involuntary and has tonic activity. It does not fatigue.
- External sphincter is a skeletal muscle; voluntary and has somatic supply. Fatigues easily.

Physiology:

Defecation:



Receptive relaxation: It allows volume expansion without increment in the pressure (so when urge comes and no defecation occurs → dilation of rectum → urge will disappear).

Hemorrhoidal Disease



INTRODUCTION

Hemorrhoids are normal structures (anal cushions) that play a minor role in continence. When hemorrhoids enlarge, prolapse or bleed then they become hemorrhoidal disease.

Normal function of anal cushions: Compliant and conformable plug. Account for approximately 15%–20% of the anal resting pressure. Give sensory information that enables individuals to discriminate between liquid, solid, and gas.

Definition: It's a degenerative disease of the connective tissue.

40% of patients will develop symptoms.

Prevalence rate of 4.4%, peak between age 45 and 65 years.

Hemorrhoidectomies are performed 1.3 times more commonly in males than in females (equal incidence).

Divided into **internal** (above the dentate line) and **external** (below the dentate line).

External hemorrhoids comprise the dilated vascular plexus that is located below the dentate line and covered by squamous epithelium. Internal hemorrhoids are the symptomatic, exaggerated, submucosal vascular tissue located above the dentate line and covered by transitional and columnar epithelium.

Note: Hemorrhoids are **not only vessels**, they are composed of blood vessels, smooth muscle (Treitz's muscle), and elastic connective tissue in the submucosa. They are located in the upper anal canal, from the dentate line to the anorectal ring.

Note: Hemorrhoids is a recurrent disease!



ETIOLOGY

Thomson concluded that a sliding downward of the anal cushions is the correct etiologic theory (shearing).

Hemorrhoids result from disruption of the anchoring and flattening action of the

musculus submucosae ani (Treitz's muscle) and its richly intermingled elastic fibers. Hypertrophy and congestion of the vascular tissue are secondary. Higher anal resting pressures were found in patients with hemorrhoids.

Risk factors:

- Constipation / Straining.
- Pregnancy.
- Increased pelvic/abdominal pressure (ascites / tumors).
- Diarrhea
- Heredity
- Erect posture
- Absence of valves within the hemorrhoidal sinusoids.
- Aging (deterioration of anal supporting tissues).
- Internal sphincter abnormalities.
- Portal HTN (**hemorrhoids are no more common in patients with portal hypertension than in the population at large**).



PATHOPHYSIOLOGY

- 1- Problem in the venous channels / Engorgement of the venous plexuses.
- 2- Redundant mucosa.
- 3- Lax matrix.



CLINICAL FEATURES

Signs & Symptoms:

- **Painless bleeding** (Usually fresh blood) – **Major symptom** [not spontaneous, but is due to trauma i.e. related to defecation]. The patient complains of blood dripping or squirting into the toilet bowl. The bleeding also may be occult, resulting in anemia, which is rare, or guaiac-positive stools.
- Pain **when complicated**.
- Anal mass / prolapse.
- Itching.
- Excoriation of the perianal skin
- Mucous and fecal leakage

Soiling can occur specially if the hemorrhoids are always outside and some minimal incontinence can occur (specially of mucus) – which leads to pruritic as it makes the area wet. So one of the common presentations is pruritic ani.

Complications: Thrombosis / Ulceration / Infection.

V.imp → Hemorrhoids are **PAINLESS** unless they are complicated (e.g. inflamed or thrombosed).

Note: Always rule out colon CA with lower GI bleeding and hemorrhoids (hemorrhoids could be 2ry to colon CA).

Sites: (When examined in the left lateral position)

- Right anterior (11 o'clock).
- Right posterior (7 o'clock).
- Left lateral (3 o'clock).

Not all patients present like this, but the configuration is remarkably constant and apparently bears no relationship to the terminal branching of the superior rectal artery. Smaller discrete secondary cushions may be present between the main cushions.

Classification: (of internal hemorrhoids)

- **Grade 1:** Not prolapsed.
- **Grade 2:** Prolapse with defecation & return spontaneously.
- **Grade 3:** Prolapse with defecation and must be reduced manually.
- **Grade 4:** Prolapsed and irreducible.

Thrombosed external hemorrhoids: an abrupt onset of an anal mass and pain that peaks within 48 hours. The pain becomes minimal after the fourth day. If left alone, the thrombus will shrink and dissolve in a few weeks.

Occasionally, the skin overlying the thrombus becomes necrotic, causing bleeding and discharge or infection, which may cause further necrosis and more pain. A large thrombus can result in a skin tag.



DIAGNOSIS

By history, physical examination (Inspection + PR), and anoscopy / proctoscopy / sigmoidoscopy.

Differential diagnosis:

- Anal melanoma / carcinoma
- Hypertrophied anal papillae
- Rectal polyps / Rectal prolapse
- Fissure / Intersphincteric abscess



TREATMENT

Medical; 1st and 2nd degree. **Minor procedures;** failed medical Rx 1st and 2nd degree, some 3rd degree. **Surgery;** 3rd and 4th degree.

Grade 1-2:

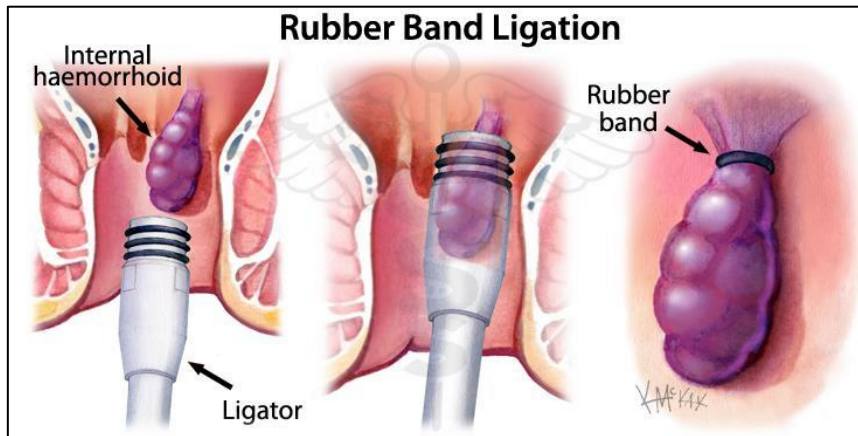
Conservative:

- High-fiber diet / Bulk forming agents and laxatives.
(to decrease shearing and trauma → decrease bleeding)
- Topical hygiene.
- Ointments, creams, gels, suppositories, foams, and pads.
- Sitz baths (warmth relaxes muscles).
- Vasoconstrictors, Protectants, Astringents, Antiseptics, Keratolytics, Analgesics, Corticosteroids.

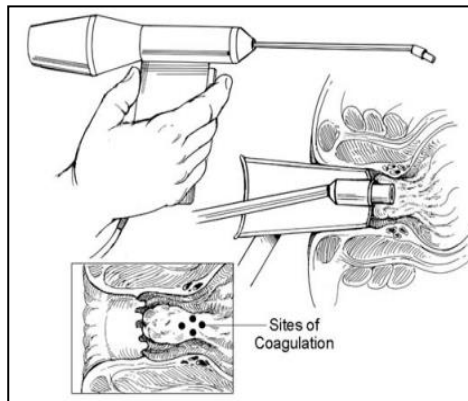
Outpatient procedures: (If refractory to medical treatment)

- Rubber band ligation (picture 1).
(usually anesthesia is not required for internal hemorrhoids)
- Injection sclerotherapy.
- Cryotherapy.
- Infrared coagulation (picture 2).
- Doppler guided hemorrhoidal artery ligation (picture 3).

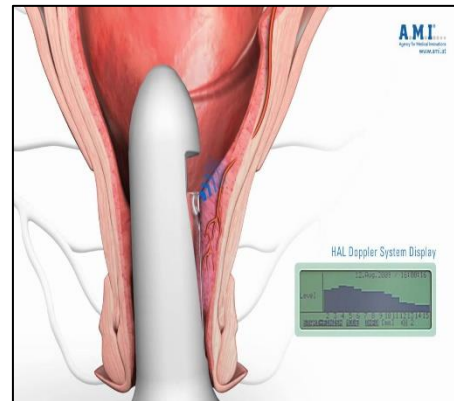
1



2



3



Grade 3-4:

Surgical:

- Anal dilatation (not used anymore).
- **Hemorrhoidectomy:**
 - Closed (sutures mucosa) or open (leaves mucosa open).
 - Whitehead Hemorrhoidectomy
 - Laser Hemorrhoidectomy
 - Stapled hemorrhoidectomy

Complications:

- 1- Exsanguination – Bleeding may pool proximally in the lumen of colon without any signs of external bleeding.
- 2- Pelvic infection – May be extensive and potentially fatal!
- 3- incontinence: Injury to the sphincters.

→ Hemorrhoidectomy is contraindicated in Crohn's disease (higher complications).

→ Removing too much skin may cause anal fibrosis and stenosis.

Anal Fissure

INTRODUCTION

Definition: Tear or fissure in the anal epithelium (Anoderm).

Younger and middle-aged adults but also may occur in infants, children, and the elderly. Fissures are equally common in both sexes.

? ETIOLOGY

- Hard stool passage (constipation).
- Hyperactive sphincter (**Primary fissures**).
- Disease process (e.g. Crohn's disease, HIV, anatomic problem [e.g. postpartum]) (**Secondary fissures**).

⚡ PATHOPHYSIOLOGY

Hypertonic (hyperactive) internal sphincter is the usual primary pathology, aided by other mechanisms (e.g. trauma by hard stool [constipation]).

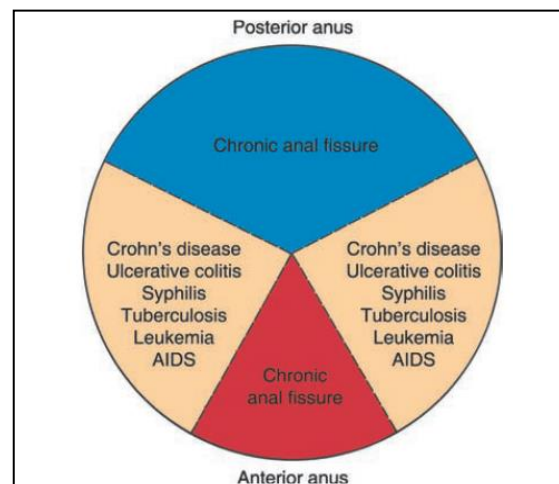
This will go into vicious circle: Pain → Spasm → Constipation

🔍 CLINICAL FEATURES

Anal fissure is located at the anoderm; so it is a **very painful** condition and this pain is due to stimulation by feces.

Site: Most common posteriorly. Anterior fissures are seen in females more than males but it's less common than posterior fissures.

Lateral fissures are usually seen in patients with Crohn's / US / TB.



Symptoms:

- Pain in anus during and after defecation.
- Rectal bleeding (usually minimal / appears as streaks in acute phase).
- Constipation; cause and consequence.
- Discharge.

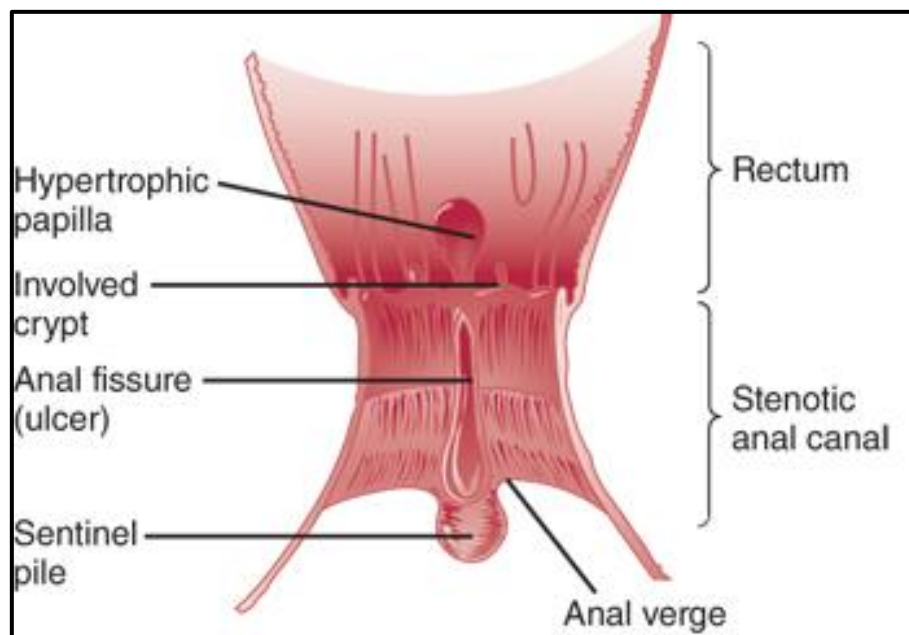
Sings:

- Blood on toilet tissue after bowel movement.
- Sentinel tag/pile.
- Tear in the anal skin.
- Painful PR exam.
- Hypertrophic papilla.

Acute fissure is a tear. Chronic fissure is an ulcer. The time needed for an acute fissure to become chronic is \approx 1 month. Signs of chronicity: 1- Sentinel Pile 2- Hypertrophic anal papilla 3- Fibrosis 4- submucous fistula.

Note: Constipation is related to anal fissure because the patient will be afraid to go to the toilet.

Note: Chronic fissure is a cause of submucosal fistula which is **not cryptogenic** (and managed in a different way i.e. is not treated by fistulotomy & sphincterotomy).





DIAGNOSIS

Anal fissure triad for chronic fissures:

- 1- Fissure / hypertrophic sphincter.
- 2- Sentinel pile.
- 3- Hypertrophic anal papilla.

Diseases that must be considered with a chronic anal fissure:

- IBD.
- Anal CA.
- Aids / STDs.



TREATMENT

→ **Acute:**

Conservative: High fiber diet, stool softeners and laxatives, local analgesia, Sitz bath, anal hygiene.

Pharmacologic Sphincterotomy: Glyceryl Trinitrate, Calcium Channel Antagonists, Botulinum Toxin.

Surgical: Sphincterotomy.

→ **Chronic:**

Conservative; same as acute.

Surgical:

- Lateral internal sphincterotomy (**LIS**) [lateral partial].
- V-Y Anoplasty (Advancement Flap Technique).
- Classic Excision.
- Finger Anal Sphincter Stretch (not used anymore).
- Controlled intermittent anal dilatation.

LIS: cut the internal sphincter to release it from spasm + Piles excision if present.

Indications of sphincterotomy: Fissure refractory to conservative treatment.

Contraindications: IBD.

Role of 90% for anal fissures:

- 90% occur posteriorly.
- 90% heal with medical treatment.
- 90% of patients who undergo surgery heal successfully.

Perianal suppuration

1) Anorectal abscess:



INTRODUCTION

Definition: Obstruction of anal glands ducts or the crypts with resultant bacterial overgrowth and abscess formation within the potential spaces.

Potential spaces (types): Perianal / Ischiorectal / Intersphincteric / Supralevator.



ETIOLOGY

Cryptogenic (unknown) or cryptoglandular.

Risk factors:

- Constipation / Diarrhea / IBD.
- Immunocompromise.
- History of recurrent surgery / trauma (impalement, enemas, prostatic surgery, episiotomy, hemorrhoidectomy).
- History of colorectal CA.
- History of previous anorectal abscess.



CLINICAL FEATURES

Symptoms:

- **Acute pain** often of sudden onset / throbbing / continuous / Pain occurs with sitting or movement and is usually aggravated by defecation and even coughing or sneezing.
- **Swelling.**
- Drainage of pus.
- Preceding bout of diarrhea
- Bleeding
- Fever / Chills / Malaise.

Signs:

- Tender induration.
- Pus may be seen exuding from a crypt.
- Examination under anesthesia is not only justified but also indicated.
- Supralelevator abscess: a tender mass in the pelvis may be diagnosed by rectal or vaginal examination. Abdominal examination may reveal signs of peritoneal irritation.

Note: In severely diabetics, horrible necrotizing soft tissue infection may follow; Watch them closely!

Diagnosis by: Physical examination, Examination under GA, MRI.



TREATMENT

Surgical drainage.

Complications of surgery:

- May extend upward.
- Fistula! (50% of patients with abscess will develop a fistula in ano within 6 months after surgery).

Indications of postop IV antibiotics:

- Recurrence.
- Deep and local spread.
- Cellulitis.
- DM / Immunocompromised / SIRS.
- Valvular heart disease.
- Sepsis.
- Leukocytosis.

2) Anorectal fistula:



INTRODUCTION

Definition: Epithelial communication between the anal canal and perianal skin.

Men predominate in most series with a male-to-female ratio varying from 2:1 to 7:1.

Age distribution is spread throughout adult life with a maximal incidence between the third and fifth decades.

Could be:

- **Complex;** more than one tract (branching).
- **High;** the main tract or a branch passes to the level of anorectal ring.
- **Horse-shoe;** the tract passes on both sides of the midline.



ETIOLOGY

Usually after perianal crypt / gland infection (perianal abscess).

The patient's history will reveal an abscess that either burst spontaneously or required drainage. Or a small discharging sinus.

Risk factors: Same as abscess.



CLINICAL FEATURES

External opening usually can be seen as a red elevation of granulation tissue with purulent serosanguinous discharge on compression. Opening is sometimes so small that it can be detected only when palpation around the anus expresses a few beads of pus.

An external opening adjacent to the anal margin may suggest an inter-sphincteric tract. A more laterally located opening would suggest a trans-sphincteric one.

The further the distance of the external opening from the anal margin, the greater is the probability of a complicated upward extension.

Crypt of origin is often retracted into a funnel by pulling the fibrous tract leading to the internal sphincter; this state is called the funnel, or “herniation sign” of the involved crypt.

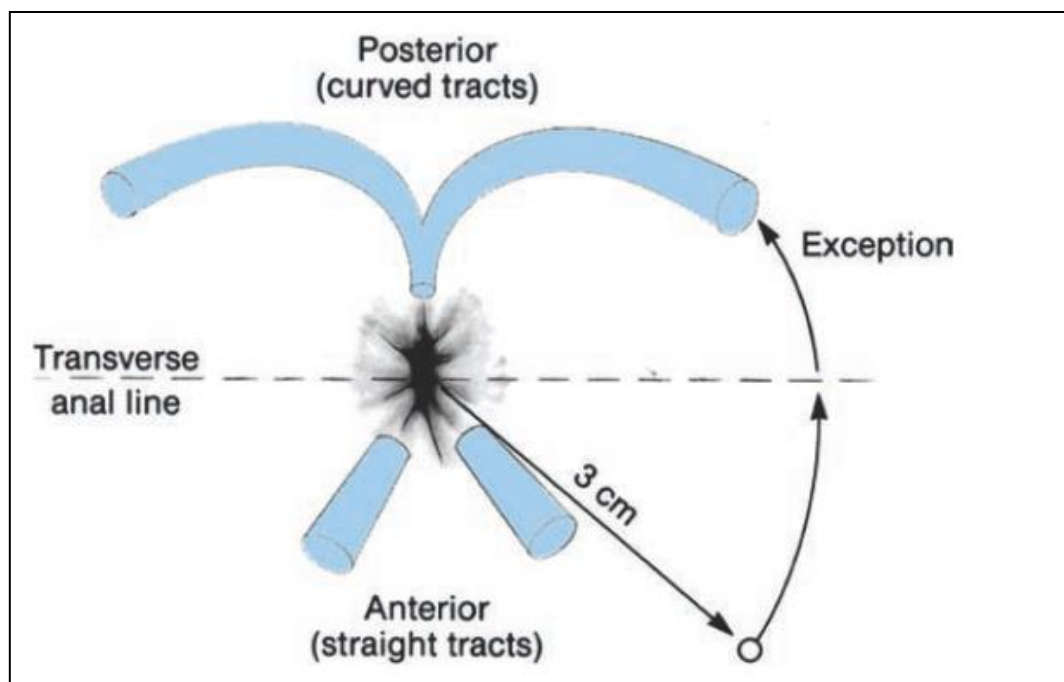
Signs and Symptoms:

- Perianal drainage.
- Recurrent abscess.
- Diaper rash / itching.

Note: The primary tract of a fistula may have secondary tracts arising from it.

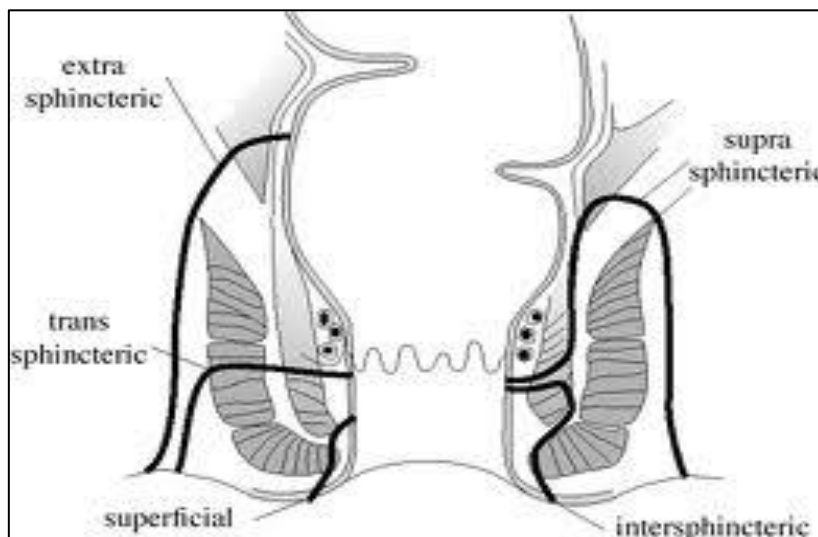
Goodsall's Rule: (Important)

Fistulas originating **anterior** to a transverse line across the anus will course **straight** ahead and open anteriorly in the anal canal. Whereas **posterior** fistulas have a **curved** tract and open in the posterior midline in the anal canal. (This rule works within 3 cm. from the anus. Fistulas lying more than 3 cm. from the anus may have a curved tract and open in the posterior midline of the anal canal).



Classification of anorectal fistulas (Park's classification):

- 1- Intersphincteric: 70%
 - Most common.
 - Does not cross the external sphincter.
- 2- Trans-sphincteric: 23%
 - Crosses both internal and external sphincters.
- 3- Supra-sphincteric: 5%
 - Very rare.
 - Usually iatrogenic.
 - Difficult to distinguish from high-level trans-sphincteric (but mangment is similar).
- 4- Extrasphincteric: 2%
 - Runs without specific relation to the sphincters and usually results from pelvic disease or trauma.



DIAGNOSIS

Physical (PR) and Proctoscope.

Investigations:

- Anoscopy and sigmoidoscopy.
- Fistulography.
- Endoanal Ultrasonography.
- Magnetic Resonance Imaging.
- Endoanal Magnetic Resonance Imaging.



TREATMENT

Surgical:

Rules: Define the anatomy. The primary opening of a tract must be identified. The relationship of the tract to the puborectalis muscle must be established. Division of the least amount of muscle in keeping with cure of the fistula should be practiced. Side tracts should be sought. The presence or absence of underlying disease should be determined.

Procedure: **Fistulotomy** (with marsupialisation).

+ Wound care: routine sitz baths and dressing changes.

+ Seton placement if fistula is through the sphincter muscle.

Seton: thick suture placed through fistula tract to allow slow transection of sphincter muscle; scar tissue formed will hold the sphincter muscle in place and allow for continence after transection.

Sitz baths: Sitting in a warm bath (usually done after bowel movement).

Marsupialization: is the surgical technique of cutting a slit into an abscess or cyst and suturing the edges of the slit to form a continuous surface from the exterior surface to the interior surface of the cyst or abscess. Sutured in this fashion, the site remains open and can drain freely. This technique is used to treat a cyst or abscess when a single draining would not be effective and complete removal of the surrounding structure would not be desirable.

Other procedures:

- Advancement rectal flap.
- Dermal Island Flap Anoplasty.
- Fistulectomy and Primary Closure.
- Video assisted anal fistula treatment.
- Cutting Seton.
- Fibrin Glue.
- Anal Plug.
- Lift Technique.
- Ablation (laser).

Note: Kindly see the doctor's last 20 slides of the procedures.

Other Anorectal Diseases

1) Pilonidal disease:



INTRODUCTION

Definition: a spectrum of clinical presentations, ranging from asymptomatic hair-containing cysts and sinuses to large symptomatic abscesses of the sacrococcygeal region that have some tendency to recur.

Pilo: Hair / Nidus: Origin; Indicating that it's associated with hair follicles.

Most common in **young males (20's-30's)**.



ETIOLOGY

Pilonidal disease is acquired, not congenital, and involves loose hair and skin and perineal flora.



PATHOPHYSIOLOGY

It has been postulated that hair penetrates into the subcutaneous tissues through dilated hair follicles, which is thought to occur particularly in late adolescence, though follicles are not found in the walls of cysts. Upon sitting or bending, hair follicles can break and open a pit. Debris may collect in this pit, followed by development of a sinus with a short tract, with a not clearly understood suction mechanism involving local anatomy, eventually leading to further penetration of the hair into the subcutaneous tissue. This sinus tends to extend cephalad, likely owing to mechanical forces involved in sitting or bending. A foreign body-type reaction may then lead to formation of an abscess. If given the opportunity to drain spontaneously, this may act as a portal of further invasion and eventually formation of a foreign body granuloma. Infection may result in abscess formation.

In summary, 3 pieces are instrumental in this process: (1) the invader, hair; (2) the force, causing hair penetration; and (3) the vulnerability of the skin.



CLINICAL FEATURES

Signs & Symptoms:

Either presents **acutely** as abscess (fluctuant mass), or **chronically** as a draining sinus with pain at the top of the gluteal cleft.



TREATMENT

I&E (incision and drainage). Under local anesthesia with removal of involved hair.

2) Anal / Perianal warts:



INTRODUCTION

Definition: Warts (small, rough, and hard growths that are similar in color to the rest of the skin) around anus / perineum.

They are part of genital warts (Condyloma Acuminatum).



ETIOLOGY

Human Papilloma Virus (HPV).



PATHOPHYSIOLOGY

Cells of the basal layer of the epidermis are invaded by human papillomavirus (HPV). These penetrate through skin and cause mucosal microabrasions. A latent viral phase begins with no signs or symptoms and can last from a month to several years. Following latency, production of viral DNA, capsids, and particles begins. Host cells become infected and develop the morphologic atypical koilocytosis of condyloma acuminatum.



CLINICAL FEATURES

Signs and Symptoms: In most cases, there are no symptoms of HPV infection other than the warts themselves. Sometimes warts may cause itching, redness, or discomfort, especially when they occur around the anus. Although they are usually without other physical symptoms.



TREATMENT

If small → Topical Podophyllin.

If large → Surgical resection or laser ablation.

Anal Cancer



INTRODUCTION

Types of anal cancers:

They are classified into:

- Anal skin cancers (a.k.a Anal margin tumors) [Anal verge out 5cm. onto the perianal skin].
- Anal canal cancers (epidermoid and malignant melanoma) [Proximal to anal verge up to the border of the internal sphincter].

Collectively, the types are:

- 1- Squamous cell carcinoma (most common – 80%).
- 2- Cloacogenic (transitional cell).
- 3- Adenocarcinoma.
- 4- Melanoma.
- 5- Mucoepidermal.

It is a **rare** cancer; 1% of colon cancers incidence.

SCC in situ is called **Bowen's disease**.

Adenocarcinoma in situ is called **(perianal) Paget's disease**.



ETIOLOGY

Risk factors:

- HPV / Condyloma / Herpes.
- HIV.
- Smoking.
- Immunosuppression.
- Chronic inflammation (fistula / Crohn's).
- Multiple sexual partners / Anal intercourse.



CLINICAL FEATURES

Signs and Symptoms:

- Anal bleeding (Most common symptom).
- Pain, mass, mucus per rectum, pruritus.

25% of patients are asymptomatic.

Sites of metastasis: L.N, Liver, Lung and bone (Remember, lymphatic drainage below the dentate line is to inguinal L.N.).



DIAGNOSIS

- History and physical (PR, Proctoscope and Colonoscopy).
- Surgical biopsy with histopathologic evaluation.
 - Histology: - Anal margin: SCC / BCC / Bowen's / Paget's disease.
 - Anal canal: Epidermoid (SCC or Transitional) and Melanoma.
- Abdominal / pelvic CT scan, trans-anal U/S.
- Chest X-ray / LFTs (for metastasis).

Clinical staging: History / Physical / Proctocolonoscopy / Abdominal or pelvic CT or MRI / CXR / LFTs / Transanal ultrasound.

Most patients are diagnosed late, and diagnosis is often missed!



TREATMENT

Based on **NIGRO protocol**.

- If anal canal epidermal CA → Chemotherapy + Radiotherapy + Scar biopsy (6-8 w after RTX).
90% of patients have complete response.
5-year survival = 85%.
If local recurrence happened after NIGRO → Repeat CTX/RTX or Salvage APR (Abdominoperineal resection).
Note: In anal canal tumors, local excision is not an option! – CTX & RTX are often successful. APR is done only if follow up biopsy indicates residual tumor.

- If anal margin CA → Smaller than 5 cm: Surgical excision with 1 cm margin.
Bigger than 5 cm: CTX.
- If anal melanoma → WLE (wide local excision) or APR (especially if large)
+/- postop RTX/CTX.

5-year survival = <10%.

Note: 1/3 of melanoma patients have amelanotic (not dark in color) tumor; making diagnosis difficult without pathology.

The end of the dossier

References

- Bhat M, S. (2016). *Srb's manual of surgery*. Jaypee Brothers Medical P.
- BLACKBOURNE, L. (2017). *SURGICAL RECALL*. WOLTERS KLUWER.
- Burnand, K., & Browse, N. (2015). *Browse's introduction to the symptoms & signs of surgical disease*. Boca Raton, FL: CRC Press, Taylor & Francis Group.
- Doherty, G. (2002). *The Washington manual of surgery*. Philadelphia: Lippincott Williams & Wilkins.
- Gaith, S. (2016). *GI surgery Dossier*. University of Jordan, Faculty of medicine.
- Kumar, P., & Clark, M. *Kumar & Clark's clinical medicine*.
- Latest Medical News, Clinical Trials, Guidelines – Today on Medscape*. (2018). *Medscape.com*. Retrieved 2017, from <http://www.medscape.com/>
- lectures & seminars*. (2017). University of Jordan, faculty of medicine.
- Smarter Decisions. Better Care..* (2018). *UpToDate*. Retrieved 2017, from <https://www.uptodate.com/>
- Williams, N., O'Connell, P., & McCaskie, A. *Bailey & Love's short practice of surgery*.