C.V.S

①B

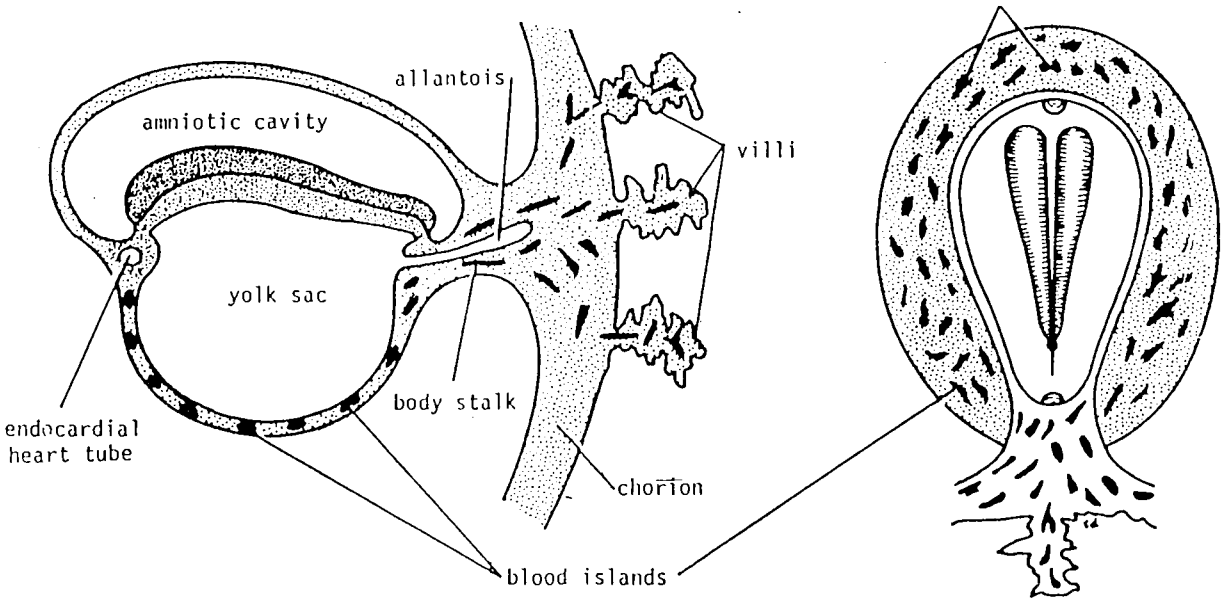

Fig. 7-1. Longitudinal section of embryo showing the appearance of blood islands in the splanchnic mesoderm of the wall of the yolk sac. Similar islands are appearing in the body stalk. These will ultimately join and form, with the capillaries in the chorionic villi, the extra-embryonic circulation.

Fig. 7-2. Embryonic disc as seen from above. The amnion has been cut away and removed.

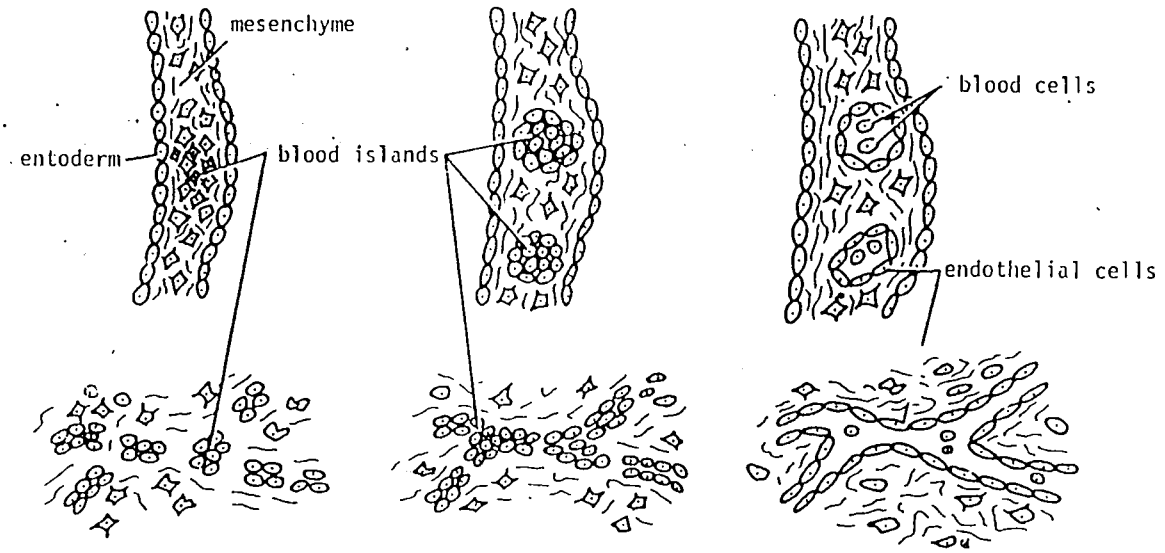

Fig. 7-3. Differentiation of mesodermal cells in a blood island to form endothelial lining cells and blood cells.

Blood islands → appears at the third week of development by clusters of mesenchymal cells in the yolk sac wall, chorion and body stalk → The peripheral cells of each island become flattened and form the endothelial lining of the vessels. The centrally located cells form the primitive blood cells.

⇒ blood islands enlarge, fuse with each other and the endothelial lined spaces become arranged to form capillary plexuses → Enlarge to form
- ① vitelline vessels in the wall of the yolk sac
- ② umbilical vessels in the chorion

(1+2) → Extraembryonic blood vessels → join blood vessels inside the embryo that have developed from the mesenchyme in a similar manner

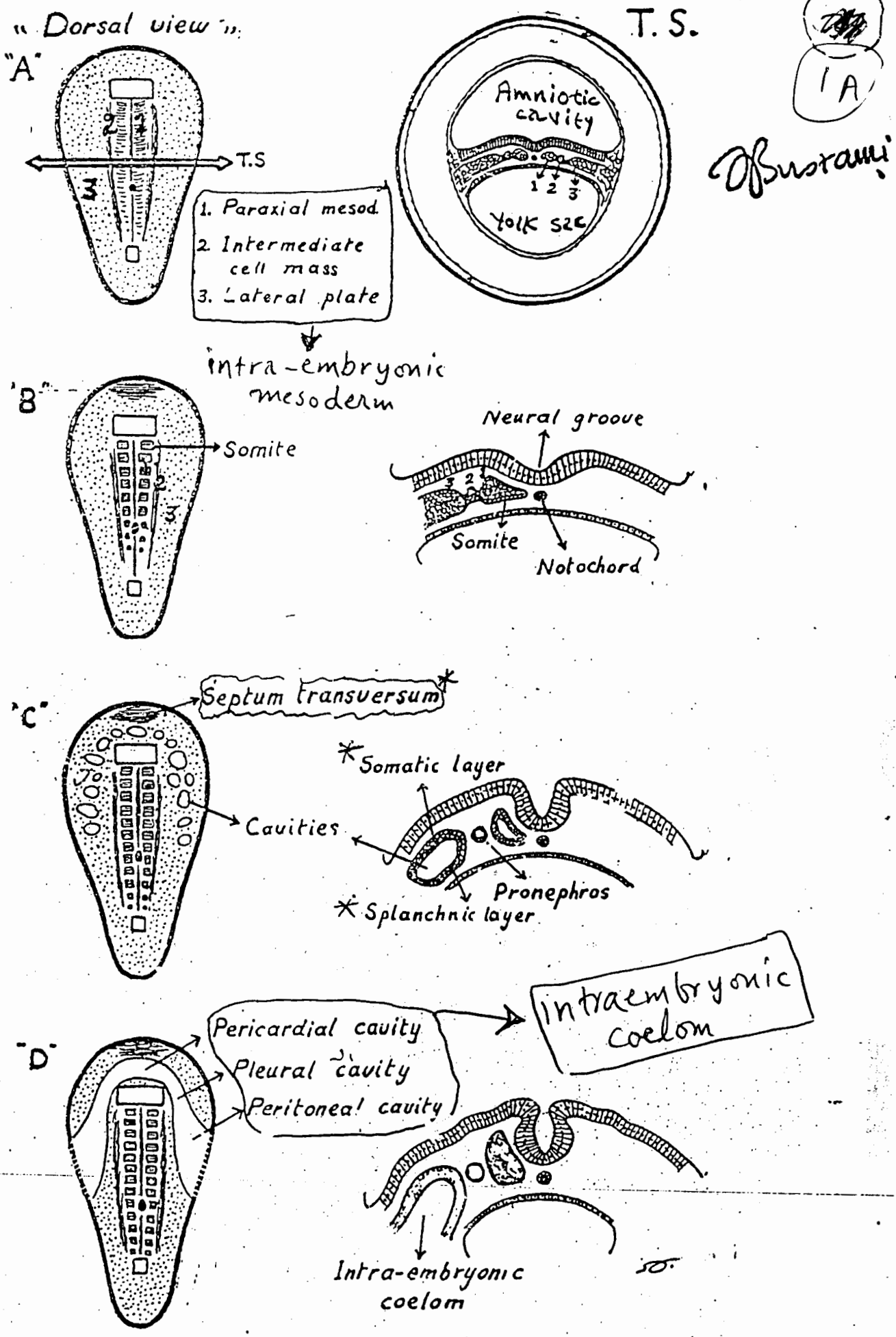

FIG. 17.—Diagrams illustrating the development of somites and intra-embryonic coelom

د. فرج البسطامي
صيف ١٩٩٤

(2)

DEVELOPMENT OF C. V. S.

DBustam

Read Snell chapter 7 page 81.
Notice in particular the following:

1. The Primitive heart tube is formed by fusion of a right and left endocardial heart tubes. Differential growth defines five segments of the heart tube which from caudal to cephalic OR according to direction of blood flow are:

Sinus venosus ——→ primitive atrium ——→ Primitive ventricle ——→ bulbus cordis (conus) ——→ truncus arteriosus

2. The sinus venosus represents the venous end of the heart. One vitelline vein from the yolk sac, One umbilical vein from the placenta and one common cardinal vein from the body wall, joins each horn of the sinus venosus.

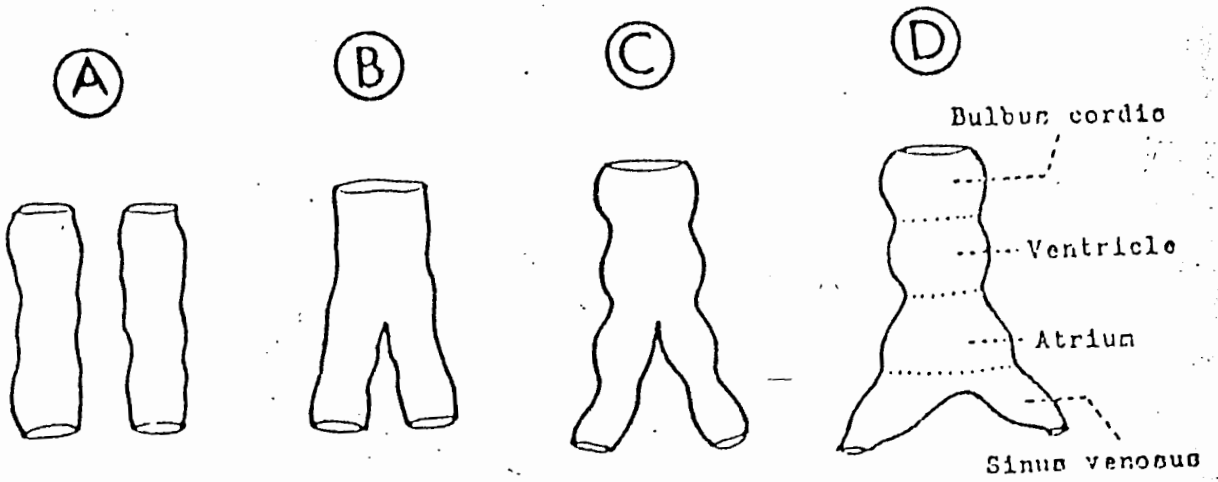

Fig. 15.1 Fusion of endothelial heart tubes.

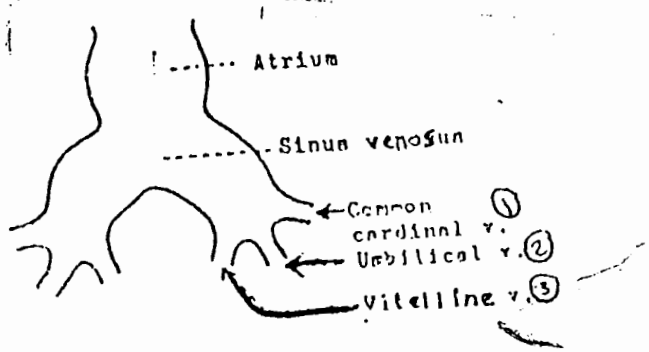

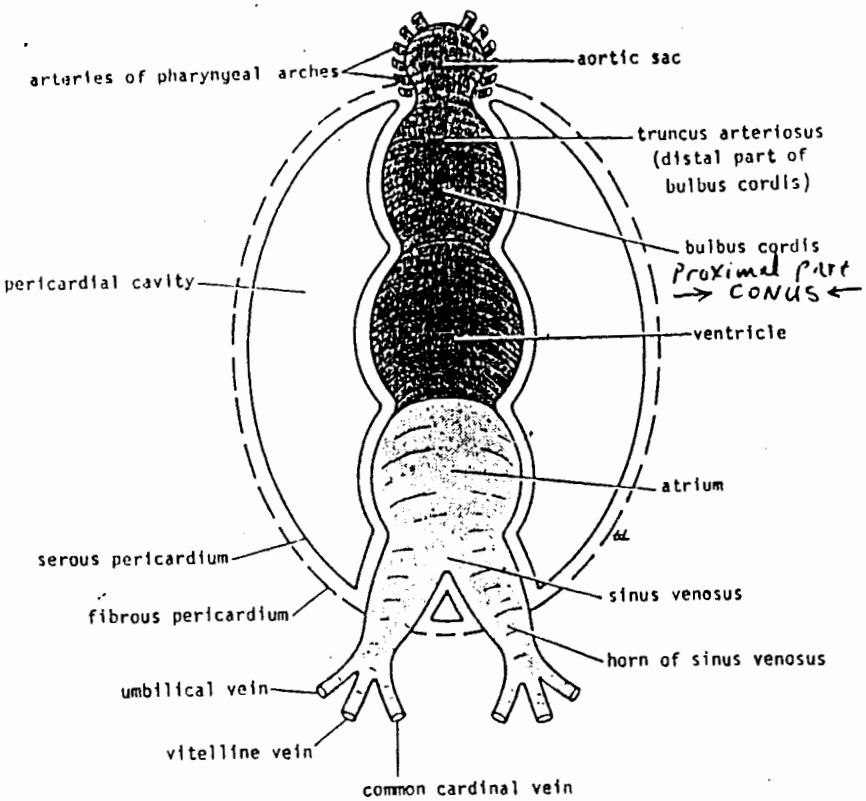

Dr Bustami

. The different parts of the endocardial heart tube within the pericardium. In the earliest stages, atrium and the sinus venosus lie outside the pericardial cavity.

1. Truncus arteriosus → forms → ascending aorta
   ↘ pulmonary trunk

2. Bulbus cordis (conus) ⊕ Ventricle → bulbo -ventricular chamber
   ↘ forms the trabeculated part of lt ventricle
   - infundibulum of Rt. ventricle
   - aortic vestibule of lt. ventricle
   - trabeculated part of Rt. ventricle

3. A-V canal → divided by the A-V (endocardial) cushions into Rt. & lt. A-V canals
   ↘ the A-V(endocardial) cushions form SEPTUM INTERMEDIUM

4. Atrium → forms → rough - walled ant. part of Rt. atrium including its auricle
   ↘ lt. auricle

5. Smooth parts of → Rt. atrium (formed by the Rt. horn of sinus venosus)
   ↘ lt. atrium (formed by absorption of pulmonary veins).

(This page to be read at the beginning & end of this chapter)

Obustami

3. After formation of the head fold, the heart tube lies dorsal to the pericardial cavity and ventral to the foregut. The tube now invaginates the pericardial sac from the dorsal side.
It is suspended from the dorsal wall of the pericardial cavity by two layers of pericardium that constitute the dorsal mesocardium. This mesocardium soon disappears and the heart tube lies free within the pericardial sac, suspended by its two ends (i.e. arterial and venous ends). However, at this stage the caudal (venous) part of the heart tube (atrium and sinus venosus) is embedded within the substance of the septum transversum.

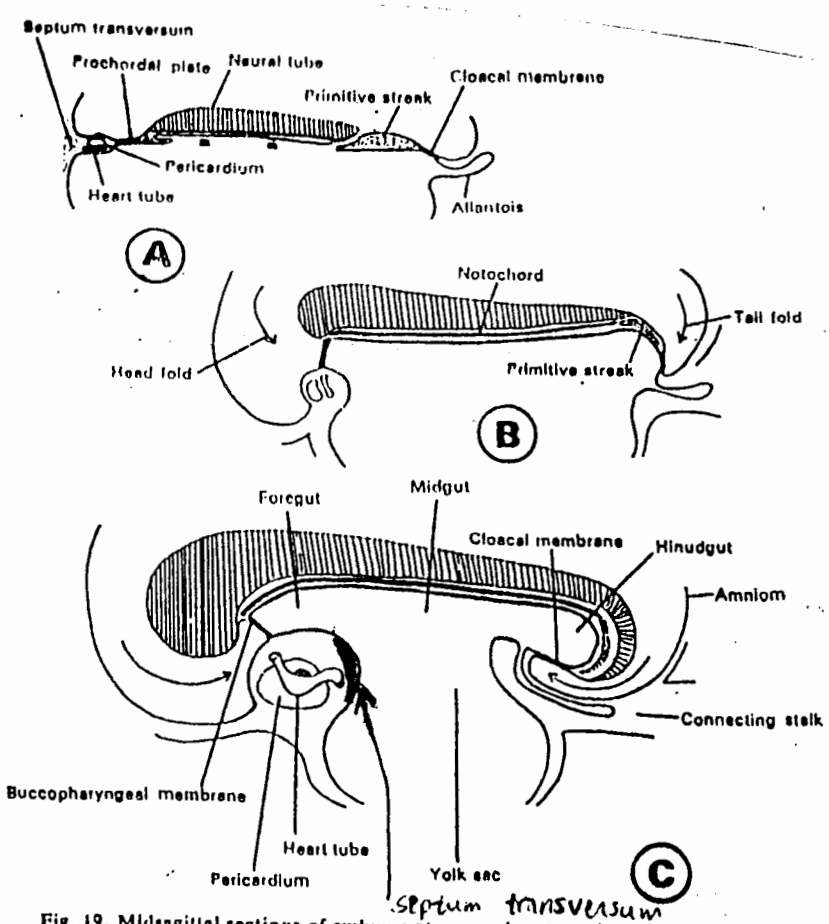

Fig. 19. Midsagittal sections of embyros at successive stages in head fold and tail fold formation. Note the changes in relative position of midline structures.

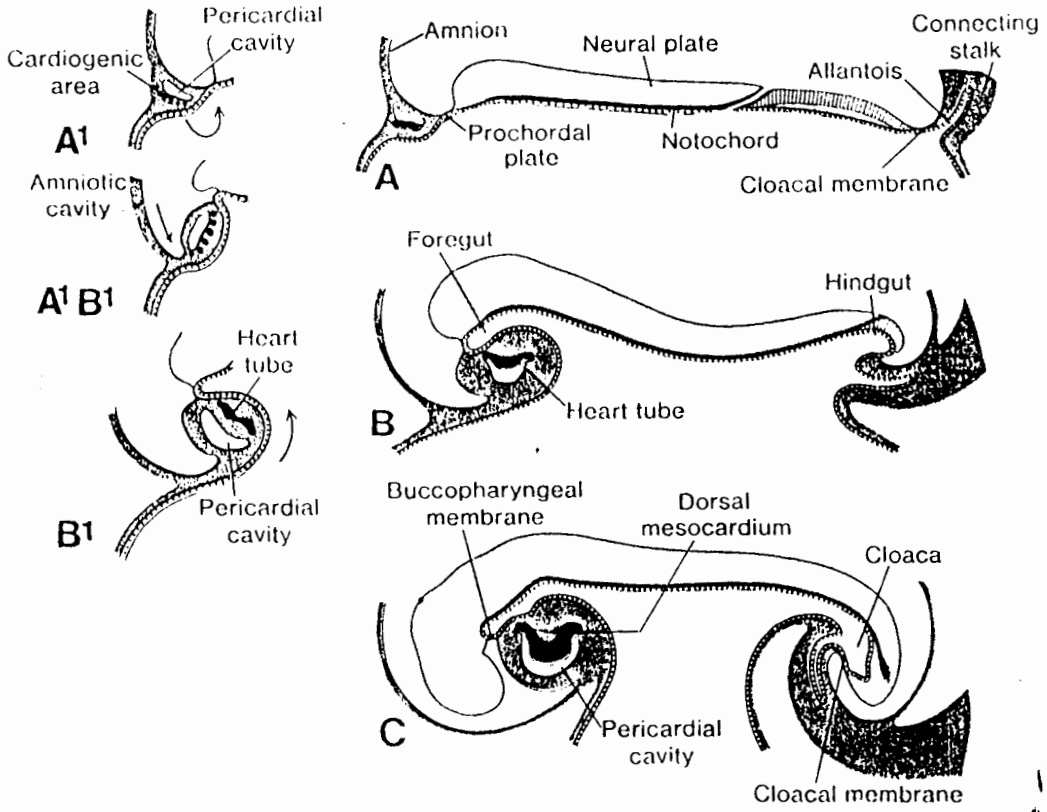

Figure 12-2. Drawings to show the result of the rapid growth of the brain vesicles on the position of the pericardial cavity and the developing heart tube. Initially the cardiogenic area and the pericardial cavity are located in the front of the prochordal plate. As a result of the rotation along a transverse axis through the prochordal plate, the cardiogenic area (heart tube) finally comes to lie dorsal to the pericardial cavity. **A**, 18 days; **B**, 21 days; and **C**, 22 days.

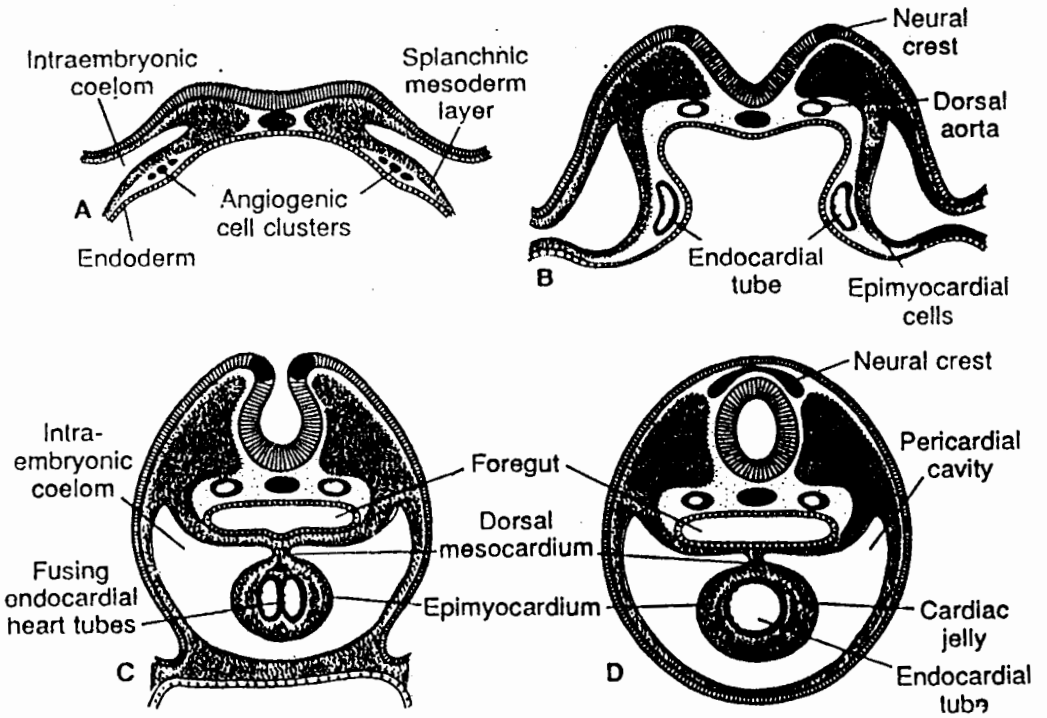

Figure 12-3. Schematic transverse sections through embryos at different stages of development, showing the formation of a single heart tube from paired primordia. **A**, Early presomite embryo (approximately 17 days). **B**, Late presomite embryo (approximately 18 days). **C**, At four somites (approximately 21 days). **D**, At eight somites (approximately 22 days). (Adapted from several sources.)

5B

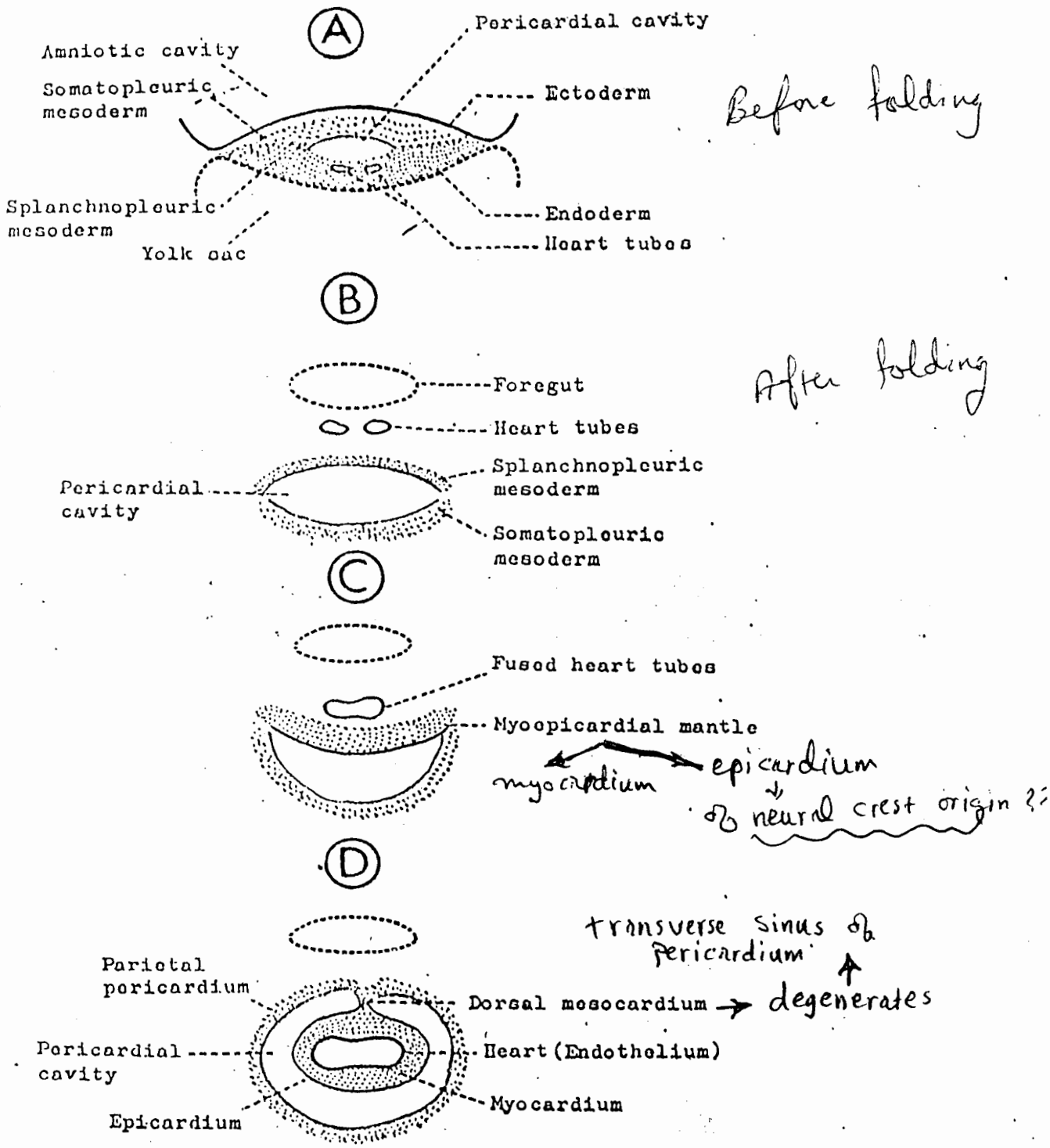

Fig. 15.4 Relationship of heart tubes to pericardial cavity (A) Before formation of head fold; (B) After formation of head fold. C and D show the process of invagination of the pericardial cavity by the single heart tube.

The part of the heart tube lying within the pericardial cavity is thus made up of bulbus cordis and ventricle. This part of the heart tube grows faster than the pericardial cavity and as a result becomes folded on itself to form a U-shaped bulbo-ventricular loop. Subsequently, as the atrium and sinus venosus are freed from the septum transversum, they come to lie behind and above the ventricle and the heart tube is now S-shaped. At this stage the bulbus cordis and ventricle are separated by a deep bulbo-ventricular sulcus.

This sulcus gradually becomes shallower so that the bulbus cordis and the ventricle come to form One chamber, which communicates with the truncus arteriosus (arterial end of heart tube).

The atrial chamber which lies behind the upper part of the ventricle and truncus arteriosus EXPANDS so that parts of it come to project forwards on either side of the truncus. As a result of these changes the exterior of the heart assumes its definitive shape.

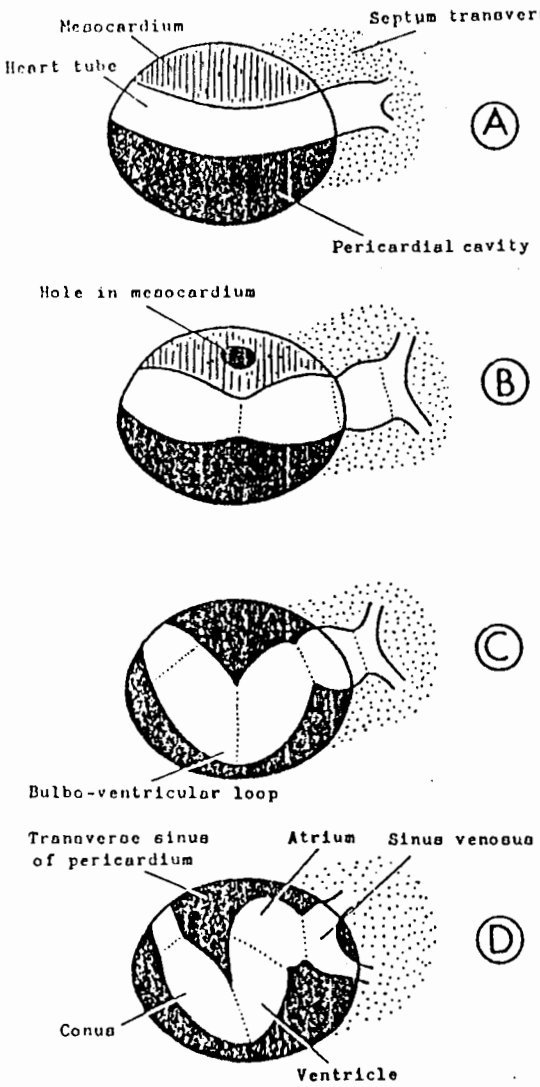

Fig. 15.5 Schemes to show (a) gradual freeing of heart tube from septum transversum; (b) folding of heart tube; (c) disappearance of mesocardium to form the transverse sinus of pericardium.

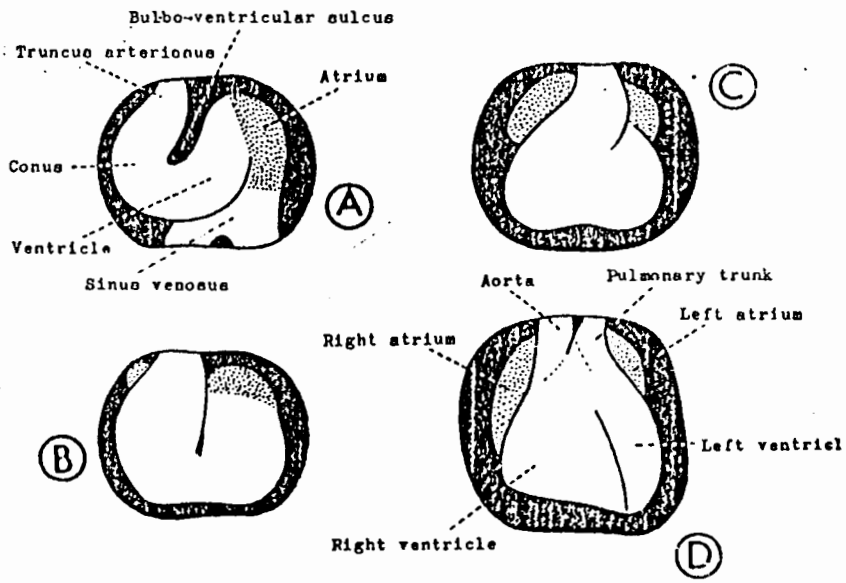

Fig. 15.7 Establishment of external form of the heart.

V. The bulboventricular portion of the heart tube grows much more rapidly than other regions, but growth of the pericardial cavity is slow. The heart tube bends over itself, forming a loop.

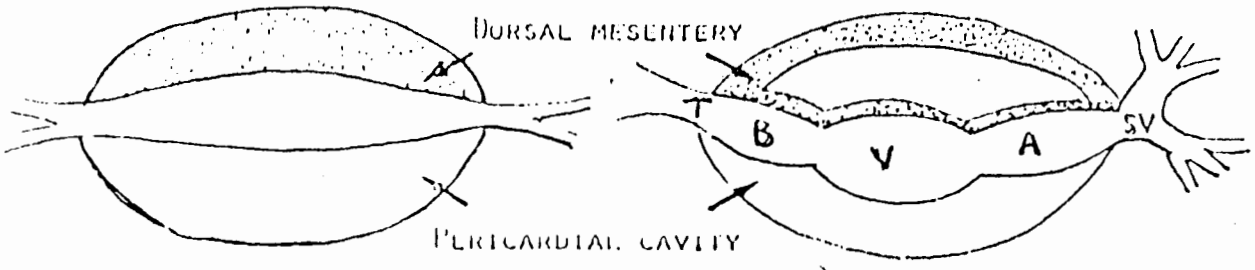

Fig. 12-3. Primitive heart suspended in the pericardial cavity.

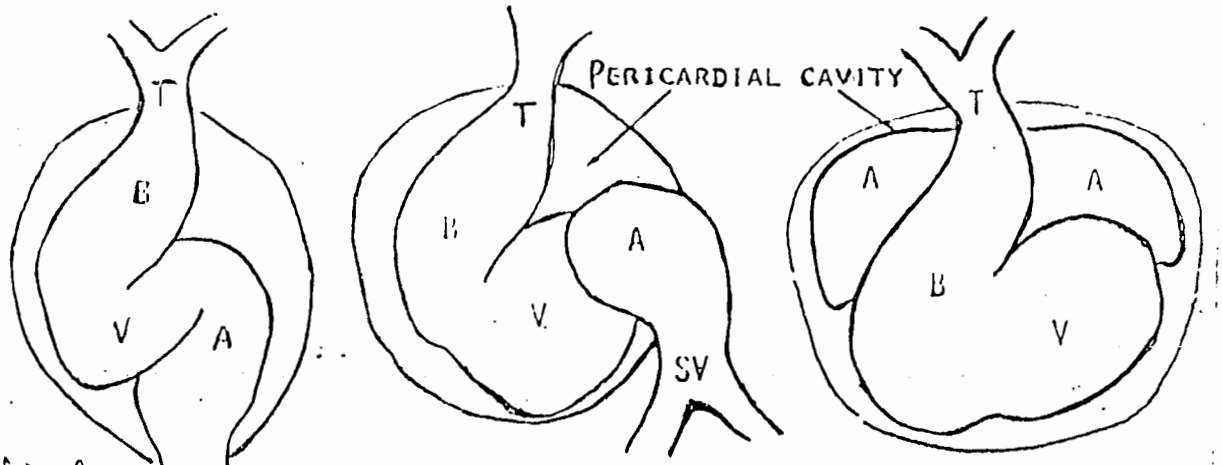

Fig. 12-4. Folding of the primitive heart.

Truncus arteriosus — Pulmonary trunk, Ascending aorta

Bulbus cordis (Conus)

- Proximal part → trabeculated part & Rt. ventricle (الأيمن)
- Midportion → outflow tract for both ventricles
  - infundibulum of Rt. ventricle
  - aortic vestibule " Lt. "
- distal part → through distal bulbar septum it will develop into:
  - pulmonary value
  - aortic "

- the Primitive ventricle of the heart tube will develop into the left ventricle (trabeculated part)

At the end of the loop formation, the venous and arterial ends are brought together as in adults.

Bustami

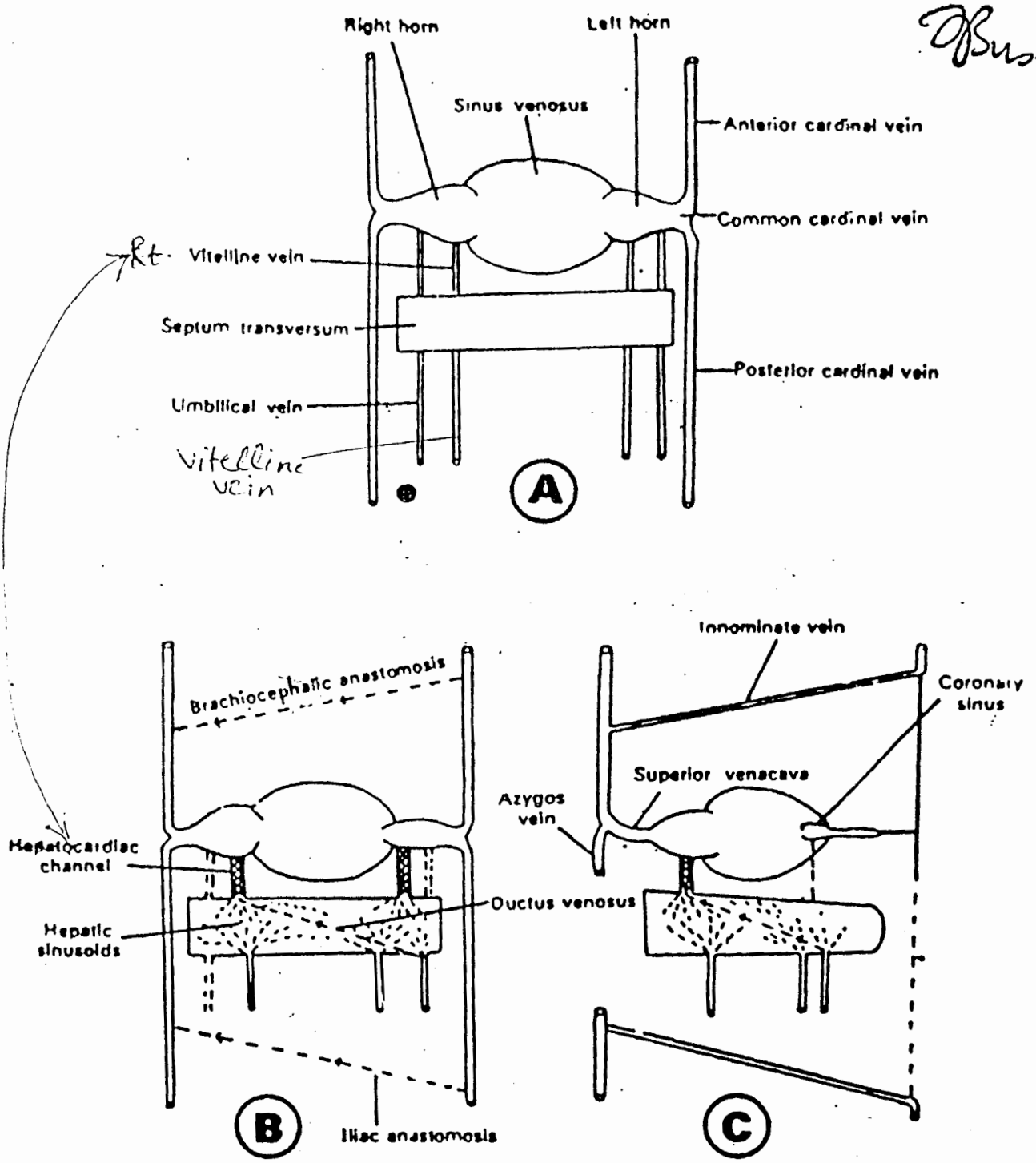

A—Major venous channels of an embryo at about 4 mm stage. B—Formation of innominate and iliac anastamoses (arrows). Ductus venosus connects the left umbilical vein and right hepatocardiac channel. C. Regression of major veins of left side.

FATE OF THE SINUS VENOSUS

Obsurani (9)

I. The sinus venosus develops lateral expansions called the right and left sinus horns. Each horn receives blood from the vitelline, umbilical, and common cardinal veins (Fig. 12-8).

II. Due to two left-to-right shunts of the blood, the right horn becomes larger than the left horn, and consequently, the sinoatrial opening moves to the right and opens into the right primitive atrium.

   A. The first left-to-right shunt of blood results from the transformation of the vitelline and umbilical veins.

      1. The caudal parts of the vitelline veins form the portal vein. The parts passing through the liver become incorporated into hepatic sinusoids. The cephalic part of the left vitelline vein disappears, whereas the cephalic part of the right vitelline vein forms the terminal portion of the inferior vena cava (hepato cardiac channel)

      2. The right umbilical vein and part of the left umbilical vein between the liver and sinus venosus degenerate. The remaining part of the left umbilical vein carries all blood from the placenta and becomes connected to the inferior vena cava through the ductus venosus, which develops in the liver.

   B. The second left-to-right shunt develops when the anterior cardinal veins become interconnected by an oblique anastomosis → forms lt. Brachiocephalic (innominate) vein

III. As a result of two left-to-right shunts of the blood, the left umbilical vein obliterates, the left vitelline vein obliterates, and finally the left common cardinal vein obliterates. The left horn loses its importance and becomes smaller. Eventually, its distal part remains as the oblique vein of Marshall, while its proximal portion forms the coronary sinus. (Look for other views)

IV. The right common cardinal vein and the right anterior cardinal vein become the superior vena cava.

V. The right horn enlarges and receives all the blood through the superior and inferior venae cavae and finally becomes incorporated as the smooth part of the wall of the right atrium.

VI. The entrance of the right horn, the sinuatrial orifice, adopts a slit-like configuration; and its margins form right and left venous valves (Fig. 12-5).

   A. Dorsocranially, the valves fuse to form septum spurium.

   B. The left valve and septum spurium fuse with the developing atrial septum.

   C. A portion of the right valve divides to form the valve of the inferior vena cava and the valve of the coronary sinus, & Crista terminalis

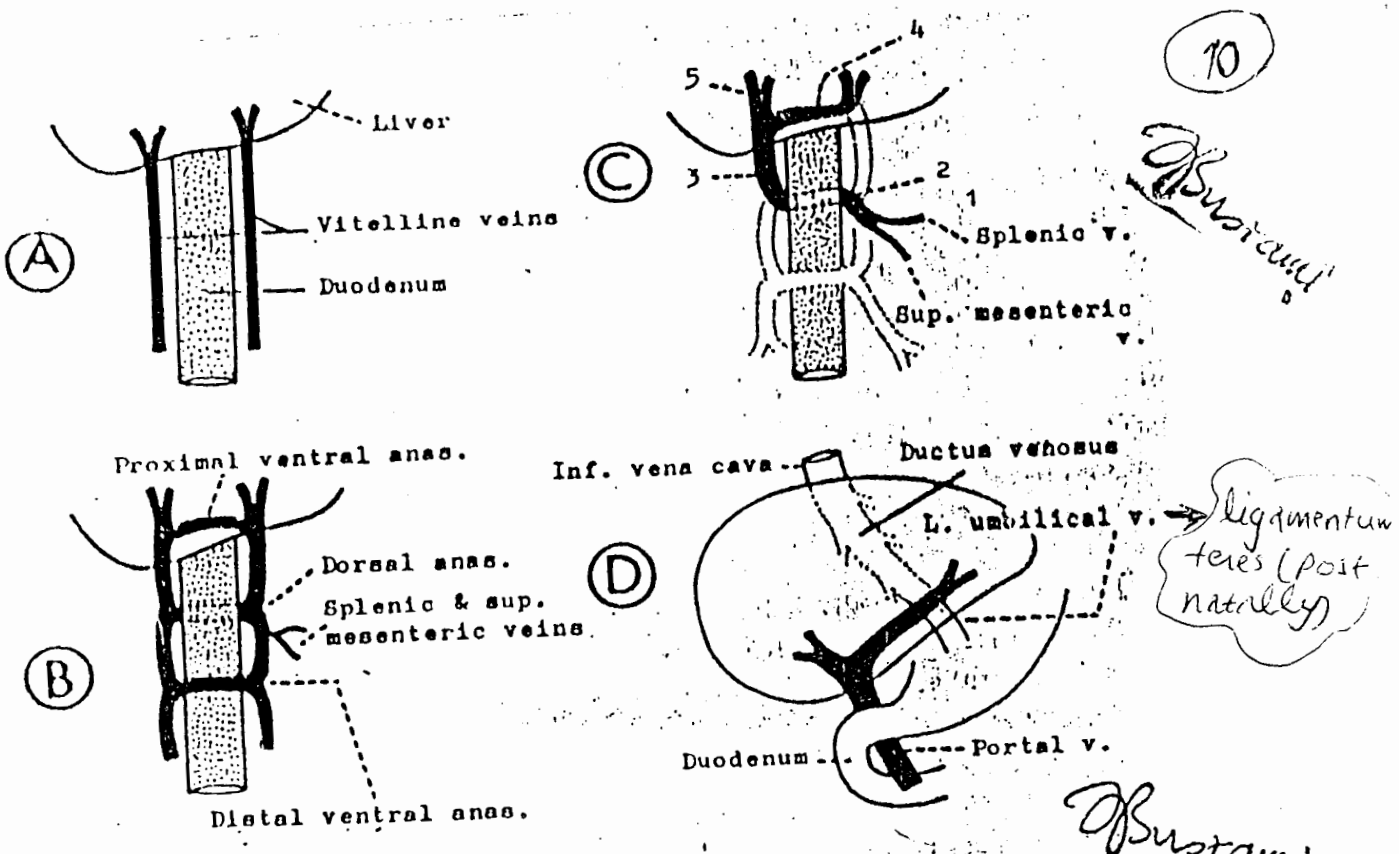

Fig. 15.42 Development of portal vein.

Notice that after formation of the Portal vein (from the caudal parts of both vitelline veins) → the left umbilical vein bringinning oxygenated foetal blood from the placenta will open into the LEFT branch of portal vein → ductus venosus arises from this part & opens into the Rt. vitelline veins (which forms the terminal part of inferior vena cava).

CIRCULATORY CHANGES IMMEDIATELY AFTER BIRTH

يُقرأ هذا الجزء عند الانتهاء من دراسة foetal circulation

I. The umbilical arteries (Fig. 12-9) constrict and later become the medial umbilical ligament. Proximal portions of these persist as superior vesical arteries.

II. The umbilical veins and ductus venosus no longer receive blood and become obliterated and remain as the ligamentum teres hepatis and ligamentum venosum.

III. With the expansion of the pulmonary capillary bed, the ductus arteriosus becomes constricted and later forms the ligamentum arteriosum.

IV. With the corresponding increase in volume of returning blood in the left atrium, the pressure in the left atrium is increased, which causes the flap of the foramen ovale to close (Fig. 12-10).

Fate of sinus venosus

(11)

The right horn of sinus venosus grows much more rapidly than the left ——→ the sinus opens on the right side of the primitive atrium ——→ Its opening becomes oriented in a vertical direction and its margins project into the right atrium as the right and left venous valves. The cranial ends of these valves later fuse to form a projection ——→ the septum spurium (. . . . . The right horn of sinus venosus ——→ taken into and becomes the posterior smooth part of the right atrium-(posterior to crista terminalis) The left venous valve ——→ regresses and disappear. The right venous valve becomes the valve of the inferior vena cava and the valve of coronary sinus. The left horn of sinus venosus ——→ remains small? (the left umbilical and vitelline veins disappear) and forms the coronary sinus.

& (Crista terminalis)

Bustami

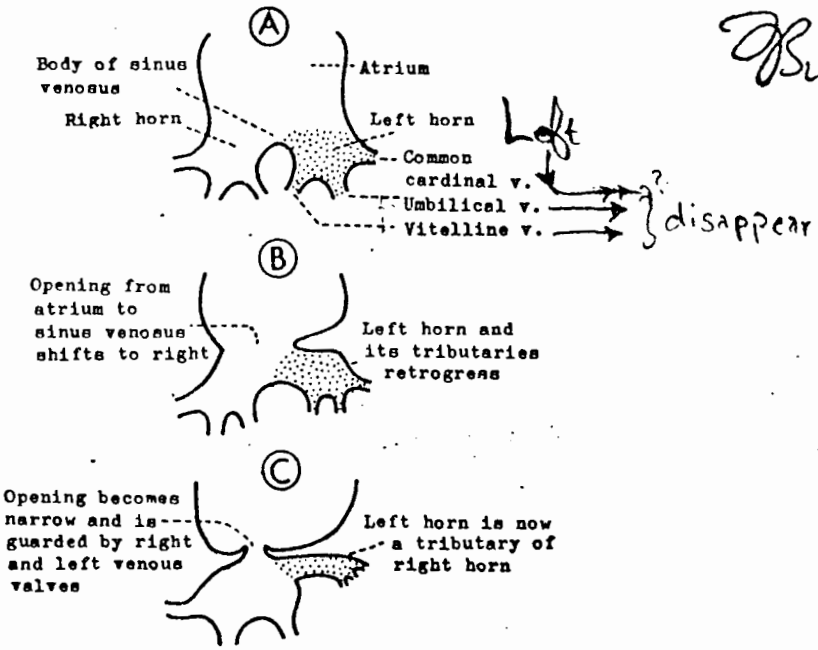

Bustami

Fig. 15.8 Retrogression of left horn of sinus venosus.

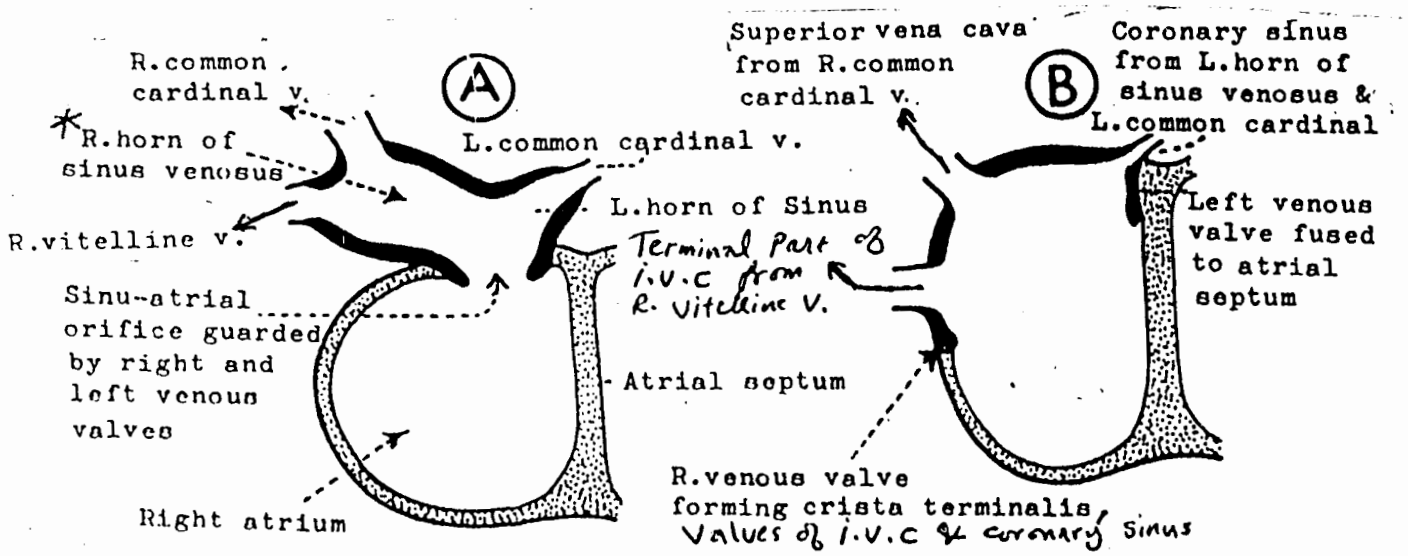

Scheme illustrating incorporation of sinus venosus into right atrium.

Fate of the Atrio-ventricular (A-V) canal

- First rounded, then becomes transverse
- Two thickenings, the atrio-ventricular OR endocardial cushions appear on its dorsal and ventral walls. They grow towards each other and fuse forming the septum intermedium, thus dividing the canal into right and left halves.

N.B. Congenital malformation of the endocardial cushions is usually accompanied by anomalies of the tricuspid and mitral valves as well as atrial and ventricular septal defects.

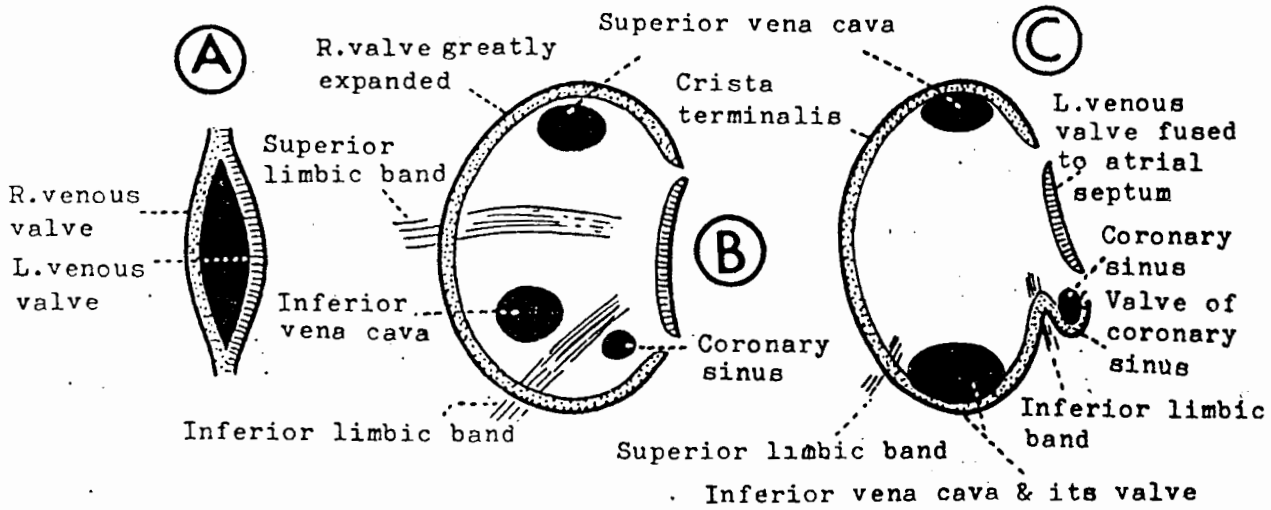

Fate of the right and left venous valves.

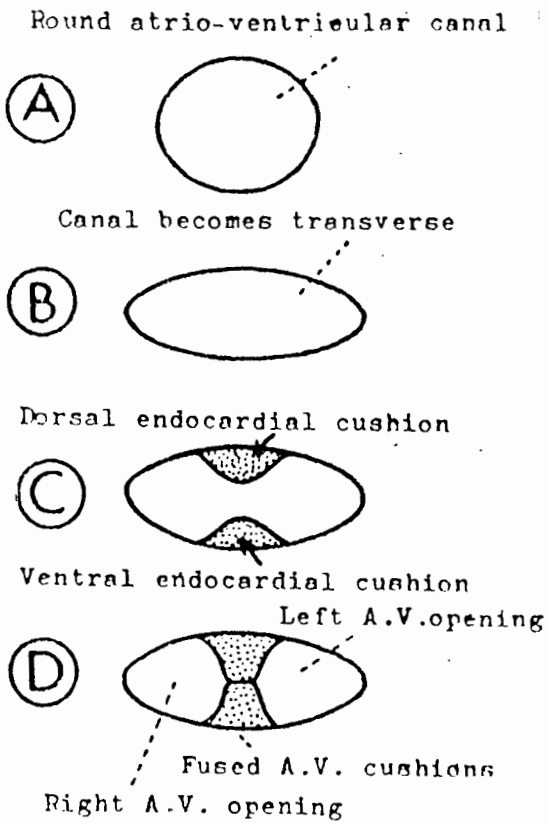

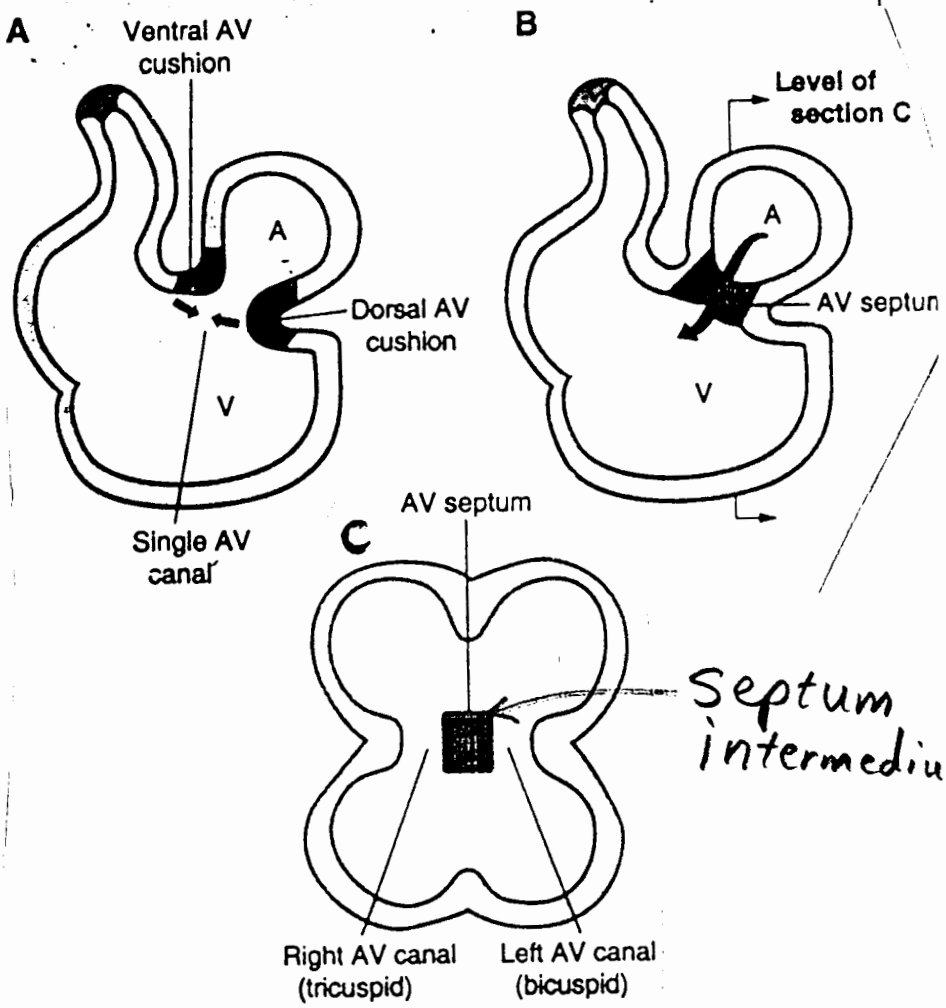

Formation of the interatrial sepum (page 87 Snell) Between 27th & 37th days of development

(13)

Septum primum ——→ sickle-shaped and extends from the roof down to and fusing with the endocardial cushions (septum intermedium). Its upper part breaks down to form the foramen secundum (ostium secundum)

Septum secundum ——→ to the right of the septum primum but does not reach the endocardial cushions leaving a valvular opening between it and the septum primum ——→ foramen ovale (persists throughout foetal life).

After birth ——→ left atrium begins to receive blood from the lungs ——→ the pressure inside it becomes greater than that in the right atrium ——→ the upper edge of septum primum pressess against the septum secundum thus closing the foramen ovale.(The lower edge of the septum secundum is thick and firm. In contrast, the edge of the septum primum that forms the lower boundary of the foramen secundum is thin and mobile like a flap. When blood tends to flow from the right to the left atrium, this thin flap moves away and there is no obstruction to blood flow. However, when there is a tendency for blood to flow from left to right this flap comes into apposition with the septum secundum and closes the opening.

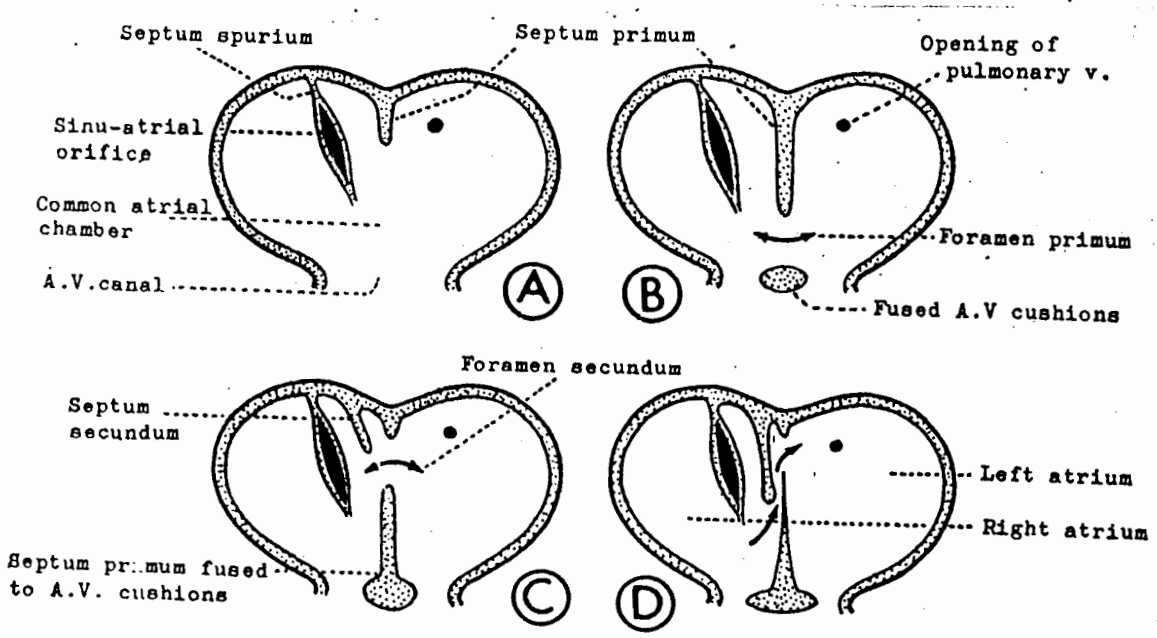

Formation of interatrial septum. The arrows in 'D' indicate the path of blood through the foramen ovale.

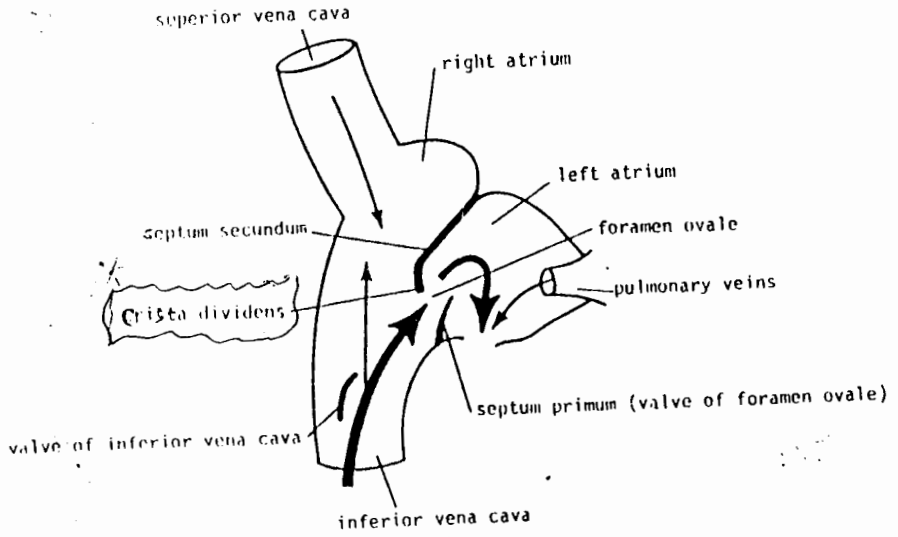

The oxygenated fetal blood, on reaching the foramen ovale, is divided into two streams by the *crista dividens* which is the lower margin of the septum secundum. The greater volume of blood enters the left atrium and the remainder, joined by venous blood from the superior vena cava and coronary sinus, passes from the right atrium into the right ventricle.

After birth

annulus ovalis ⟶ represents lower free edge of the septum secundum

floor of fossa ovalis ⟶ represents the septum primum

- From what has been said above it is evident that the right atrium is derived from

  a) right half of the primitive atrium (rough ant. part)
  b) right horn of sinus venosus (smooth post. part)

- The left atrium is derived from

  a) left half of the primitive atrium
  b) absorped proximal parts of the pulmonary veins. (smooth post. part).

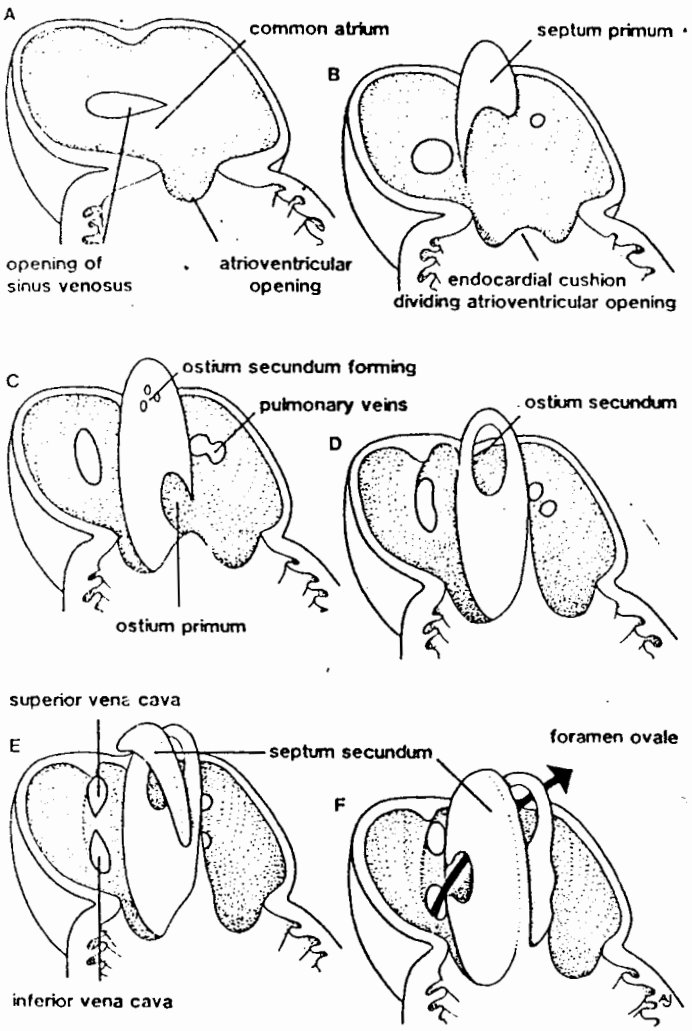

Fig. 2.12. Division of the common atrium. The anterior wall of the atrium has been removed to show the development of the septum. In F, the flow of blood through the foramen ovale is shown.

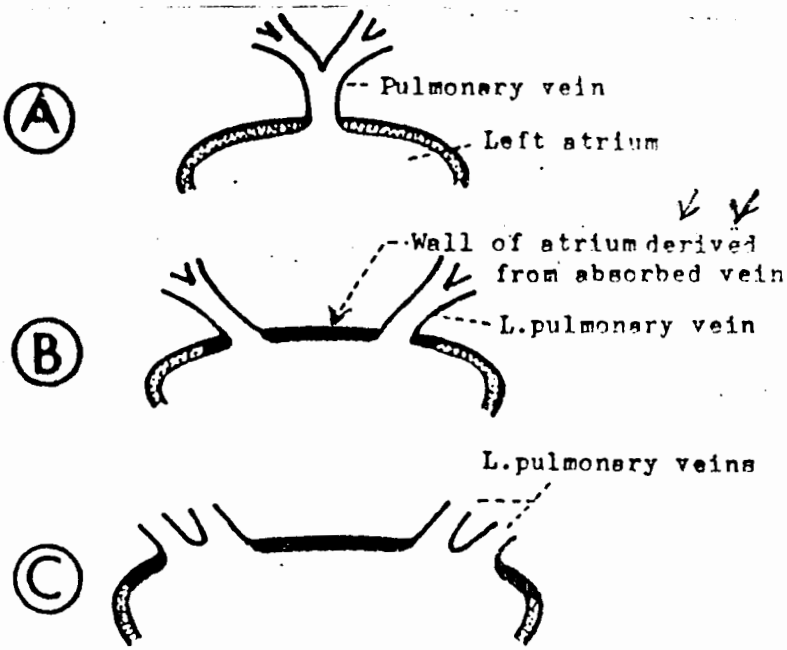

Absorption of pulmonary veins into left atrium.

Dr Bustami

Separation of the Two Ventricles

1- At this stage the bulbus cordis(conus), and ventricle, are separated by a deep bulbo-ventricular sulcus. This sulcus gradually becomes shallower so that the bulbus cordis (conus), and the ventricle, come to form one chamber, which communicates with the truncus arteriosus.

2- The bulboventricular chamber will develop into right and left ventricles by the development of three structures:
   - A- Ventricular septum.
   - B- Extension from the atrioventricular endocardial cushions (septum intermedium)
   - C- Proximal bulbar septum (bulbar ridges or conus swellings)

3- The ventricular septum begins its development as a projection from the base or the inferior wall of the ventricle. As it enlarges, the septum forms two horns which reach up to the corresponding a-v endocardial cushions. The upper crescentic border of the septum bounds a temporary connection between the two ventricles called the interventricular foramen. The ventricular septum form the muscular part of the interventricular septum (septum musculare).

4- At the end of the seventh week, a downward extension occurs from the right margins of the a-v endocardial cushions (septum intermedium) to close the interventricular foramen. This extension forms the membranous part of the interventricular septum (septum membranaceum).

5- The proximal bulbar septum develops as two ridges which fuse together. This septum divides the bulbus cordis longitudinally into the infundibulum of the right ventricle (Midportion) part of and the vestibule of the left ventricle. This septum shares in closing the interventricular foramen.

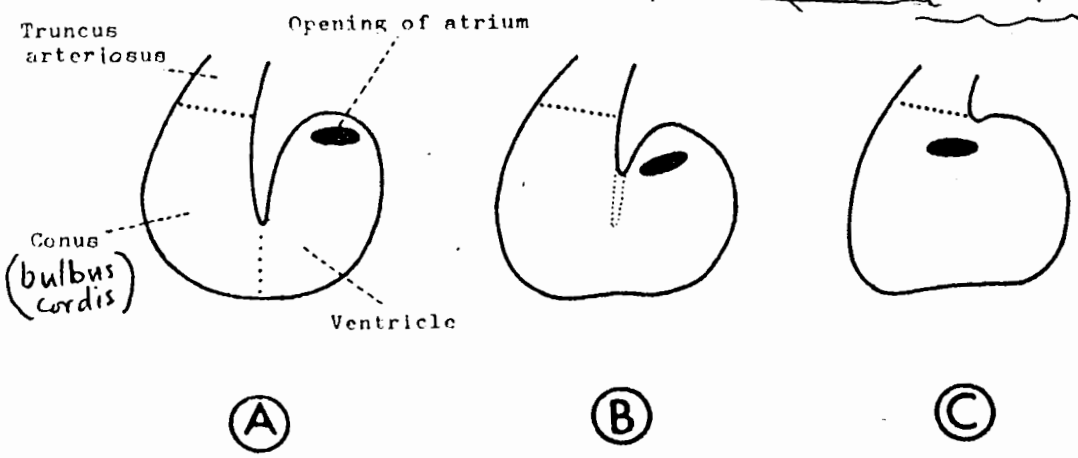

Fig. 15.6 Scheme to show incorporation of conus into the ventricle by disappearance of the bulbo-ventricular sulcus. Note that the opening of atrium into ventricle gradually shifts to the centre of the posterior wall of the common bulbo-ventricular chamber.

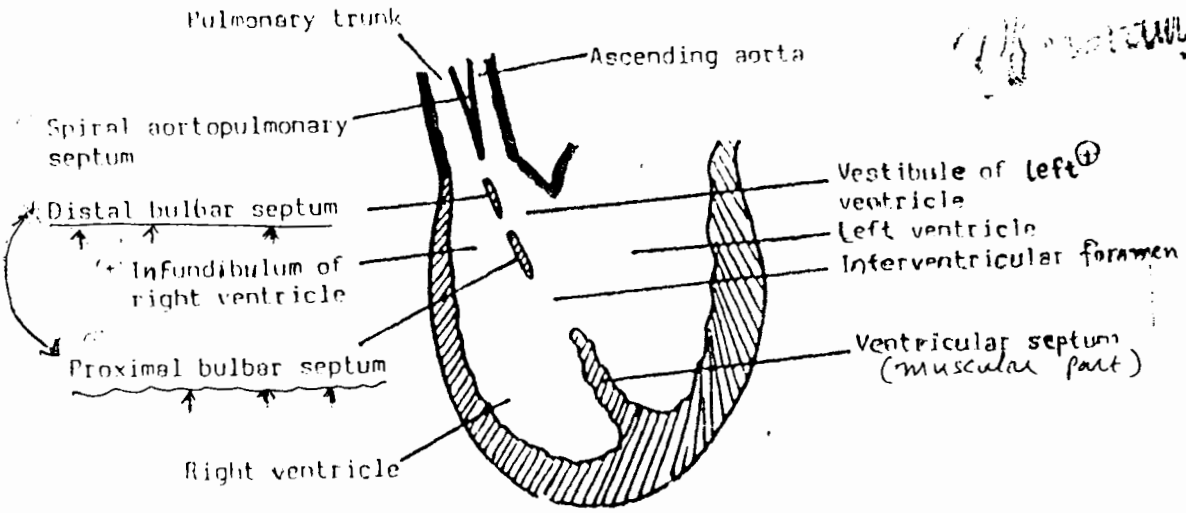

Separation of the two ventricles

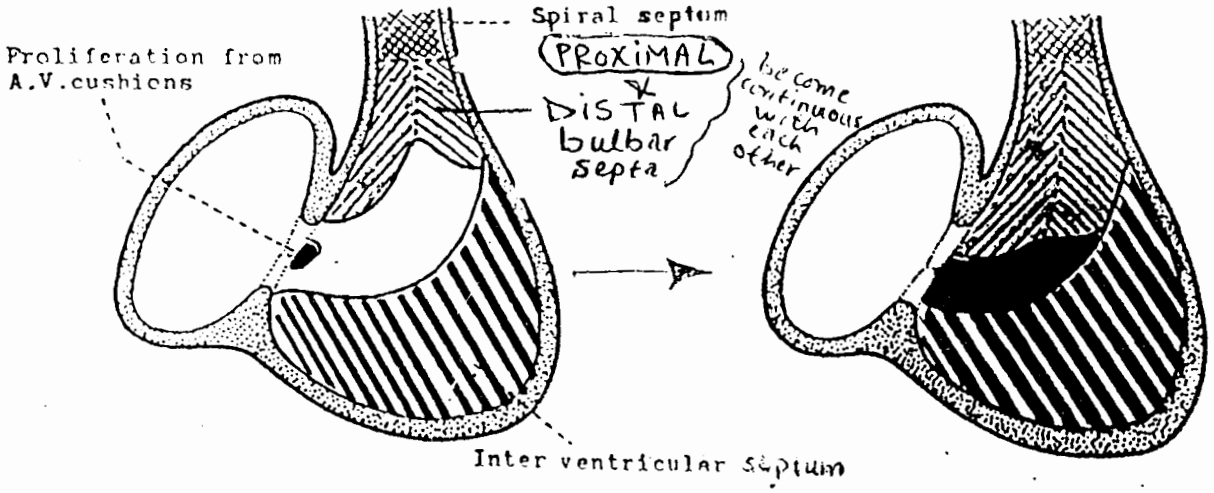

1) How the interventricular foramen is closed?
By proliferation from:
   a. endocardial cushions (septum intermedium)
   b. proximal bulbar ridges (proximal bulbar septum)

The proliferation from (a) and (b) will form the MEMBRANOUS PART of the interventricular septum which is divisible into an anterior part that separates the right and left ventricles and a posterior part that separates the left ventricle from the right atrium ——→ thus called ATRIO-VENTRICULAR SEPTUM.

2) Which parts of the bulbo-ventricular chamber contribute to the formation of the Rt. ventricle?
Both rough (trabeculated) part and smooth part (infundibulum) of Rt. ventricle are derived from the bulbus cordis (conus).

3) Which parts of the bulbo- ventricular chamber contribute to the formation of the lt. ventricle?
   a. the rough (trabeculated) part is derived from the primitive ventricle.
   b. the smooth part (aortic vestibule) is derived from the bulbus cordis (conus).

Dr Busrami

Distal Bulbar Septum

1- Four endocardial cushions; anterior, posterior and two lateral are developed in the distal part of the bulbus cordis (Conus)

2- A ridge is developed in the middle of each of the two lateral cushions. These two ridges fuse to form a complete septum called the distal bulbar septum. As a result, the distal part of the bulbus cordis is now divided into two orifices: the pulmonary orifice anteriorly and the aortic orifice posteriorly.

3- Formation of the distal bulbar septum divides each of the lateral cushions into two. As a result, each of the pulmonary and aortic orifices is guarded by three cushions. The cushions form the pulmonary and aortic cusps.

4- Originally, the cusps of the pulmonary valve are one anterior and two posterior. But, as a result of rotation of the vessels, two cusps become anterior and one posterior.

5- Originally, the cusps of the aortic valve are two anterior and one posterior. But, as a result of rotation of the vessels, one cusp becomes anterior and two posterior.

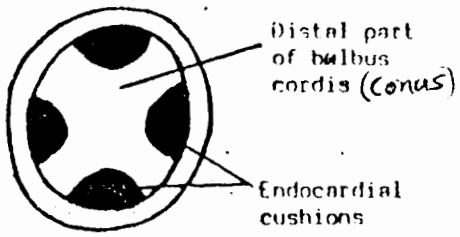

Development of the distal bulbar septum and formation of the aortic and pumonary valves

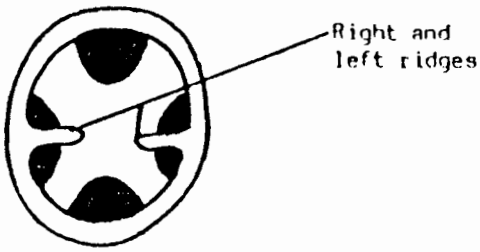

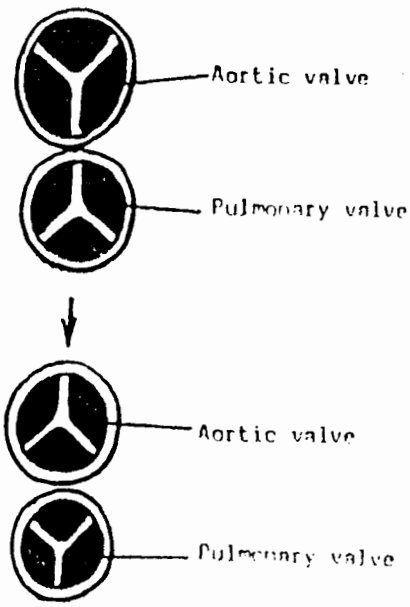

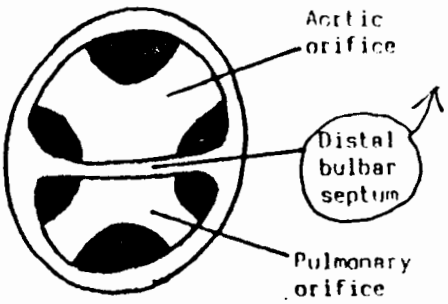

Rearrangement of the cusps of the pulmonary and aortic valve's due to rotation of the two vessels

Obusrami (18)

Spiral Aorto-pulmonary Septum

1- Two opposing ridges are developed in the wall of the truncus arteriosus during the fifth week of development. The ridges have varying positions in the different parts of the truncus arteriosus.

2- In the lower part of the truncus, the ridges are right and left. As traced upwards to the middle of the truncus, the Rt. ridge becomes anterior; while the Lt ridge becomes posterior. In the upper part of the truncus, the anterior ridge becomes left; while the posterior ridge becomes right.

3- When the two ridges fuse together, a spiral septum is formed. This septum is called the aorticopulmonary or aortopulmonary septum. This septum divides the truncus arteriosus into the ascending aorta and pulmonary trunk.

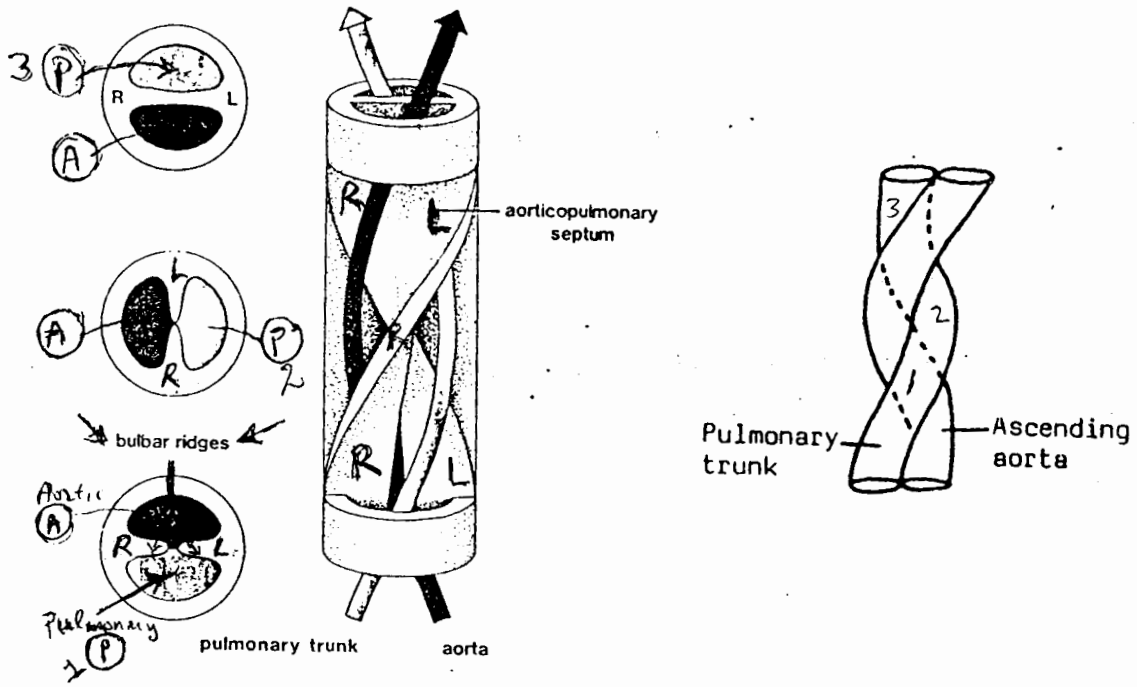

Fig. 2.13. Formation of the aorta and pulmonary trunk.

N.B The formation of the aortico-Pulmonary septum ensures that the blood from the Rt. ventricle will run in the pulmonary trunk and that from the Lt. ventricle will run in the ascending aorta ⇒ If the aortico-Pulmonary septum was STRAIGHT instead of being Spiral → the pulmonary trunk will receive blood from the Lt. ventricle (oxygenated) while the aorta will receive blood from the Rt. ventricle (deoxygenated) → Transposition of great vessels → incompatible with life ??

19

FOETAL CIRCULATION

Bustami

Read snell page 105-107, Notice the following:

a. In the foetus the right atrium receives two types of blood (oxygenated and de oxygenated).

1. highly oxygenated blood from the placenta along umbilical-vein ——→ ductus venosus (inside liver) ——→ Inf. vena cava ——→ Rt. atrium.

2. deoxygenated blood comes from the upper part of the body (head & neck, brain and upper limbs, through the superior vena cava.

VERY LITTLE MIXING occurs between these two types of blood inside the Rt. atrium.

The oxygenated blood will pass from the right atrium ——→ left attium (through foramen ovale) ——→ ——→ It. ventricle ——→ Aorta ——→ Head, neck, Brain, upper limbs.

- passage of blood from Inf. vena cava ——→ Rt. atrium ——→ left atrium? ?

(1) The valve of the inferior vena cava directs the blood flow to the foramen ovale.
(2) The pressure in the left atrium is much lower than the pressure in the right atrium (No pulmonary circulation in the foetus).
(3) Septum Primum as flap valve

passage of deoxygenated blood from sup. vena cava ——→ Rt. atrium ——→ Rt. ventricle? The lower border of the septum secundum hangs over the foramen ovale & prevents blood from passing into the left atrium through the foramen ovale.

The deoxygenated blood will pass through the following:-
Sup. vena cava ——→ Rt. atrium ——→ Rt. ventricle

——→ Pulmonary trunk ——→ ductus arteriosus ——→
——→ distal part of arch of aorta ——→ descending aorta ——→
——→ Internal iliac arteries ——→ Umbilical anteries ——→
——→ Placenta.

58%

Oxygenated blood pass from the placenta to the Umbilical vein (80% saturated with O_2) → to the liver → greater volume [bypasses] the liver & travels to i.v.c by way of ductus venosus

the remainder enters the liver sinusoids & enters the i.v.c by the hepatic veins

- Some (mixing) of < oxyg. / deoxyg. blood in the ductus venosus ? the ductus venosus receives poorly oxygenated blood from the gut through the lt. branch of the portal vein
- Another (mixing) occurs in the i.v.c (it receives venous blood from the caudal regions of the foetus)

I.V.C contains blood about 67% saturated with O_2

- the greater amount of oxygenated blood enters the left atrium through the foramen ovale
- the blood that remains in the Rt. atrium is (mixed) with venous blood from S.V.C & coronary sinus → this blood passes into Rt. ventricle → pulm. trunk → [ductus arteriosus] → aorta → lower ½ of body

i.c → has poorly oxygenated blood running through

In the lt. atrium → oxygenated blood is (mixed) with small volume of deoxygenated blood coming from the non-functioning lungs → blood is 62% saturated with O_2 → lt. ventricle → Ascending aorta → upper ½ of body (brain, head & neck, upper limb)

Remember → ductus venosus carries - conveys - highly oxygenated blood → after birth becomes the ligamentum venosum of liver

- lt. umb. vein → conveys highly oxygenated blood → after birth → ligamentum teres of liver
- ductus arteriosus → after birth → ligamentum arteriosum

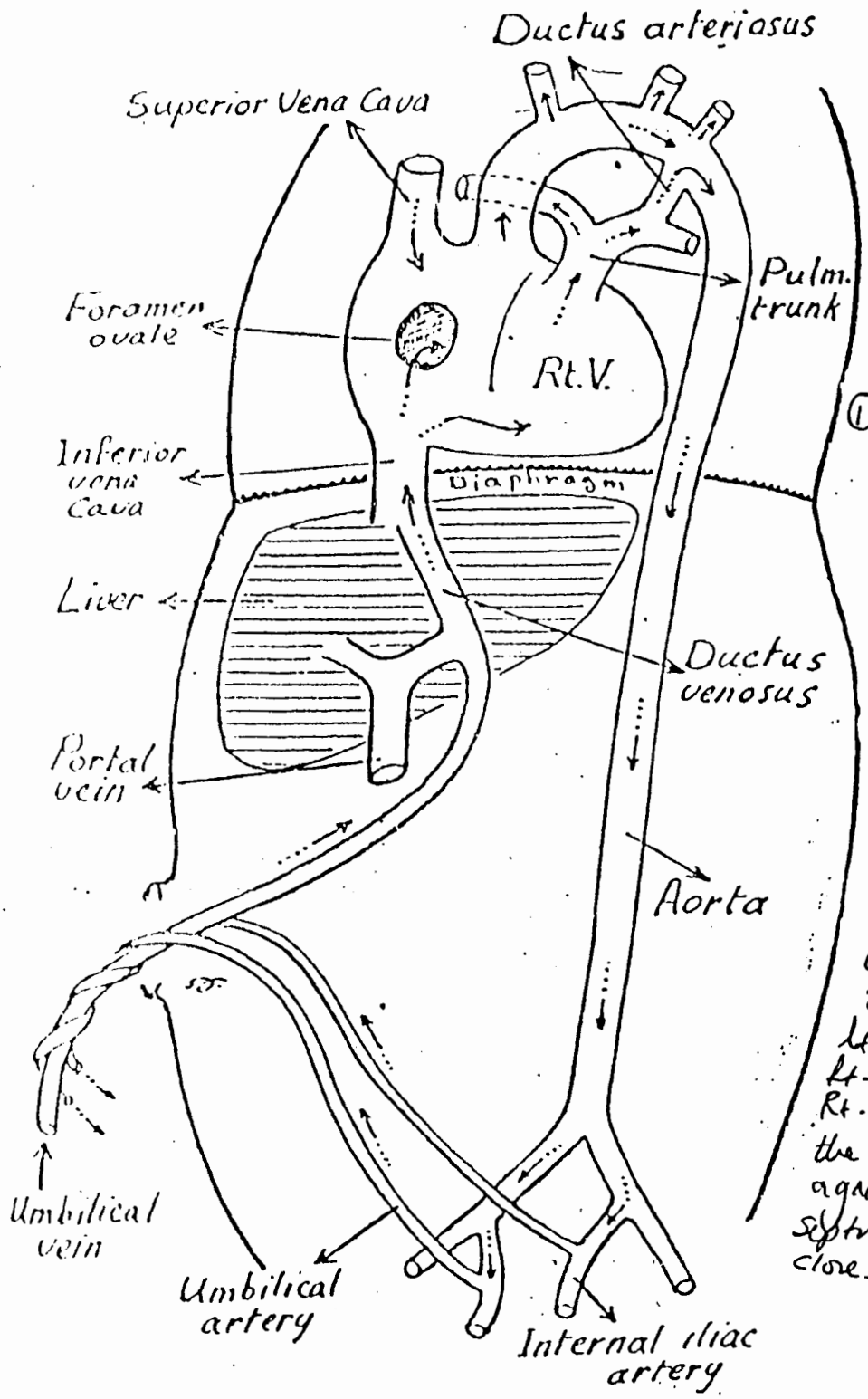

Circulatory changes at birth:

At birth → first breath of air is taken

→ Newborn is separated from the placenta

① Expansion of the lungs → pulmonary vascular resistance is suddenly reduced → ↑ pulmonary blood flow → fall of pressure in pulmonary trunk, Rt. ventricle & Rt. atrium

② on the left or systemic side the exclusion of the low-resistance vascular bed of placenta from the circulation results in an increase of overall systemic vascular resistance causing the pressure to rise in the aorta, lt. ventricle & lt. atrium ⇒ This ↑ in lt. atrial pressure and ↓ in Rt. atrial pressure PRESSES the thin septum primum against the more rigid septum secundum & FUNCTIONALLY closes the foramen ovale

Mixing of oxygenated and deoxygenated blood takes place ??

① at ductus venosus →

② at i.v.c → 67% saturated with O_2

③ at Rt. atrium

④ at lt. atrium 62%

Obstraw!

(1) Anomalies of the atrial septum → Atrial septal defects → A.S.D ← (23)

a. The <u>septum primum</u> may fail to reach the atrioventricular endocardial cushions, so that the foramen primum persists. This <u>osteum primum defect</u> may be associated with defects of the endocardial cushions.

b. The <u>septum secundum</u> may fail to develop so that the foramen secundum remains wide open (<u>osteum secundum defect</u>).

c. The septum primum and secundum may develop normally but the oblique valvular passage between them may remain patent (patent foramen ovale).

(2) Complete failure of the septum primum and septum secundum to develop → one atrium and two ventricles (<u>a trilocular biventricular heart</u>).

(V.S.D)(3) <u>Interventricular septal defects</u> may be seen either in the <u>membranous</u> or the <u>muscular</u> part of the septum. (More in the membranous, why??).

(4) <u>Persistent</u> <u>common atrio-ventricular</u> (A-V) canal (results from complete failure of fusion of the anterior and posterior endocardial cushions which normally divide the A-V canal into right and left orifices (usually associated with defects of the atrial or ventricular septa, why??). → usually combined with septal defects → Occurs in 20% of mongoloids

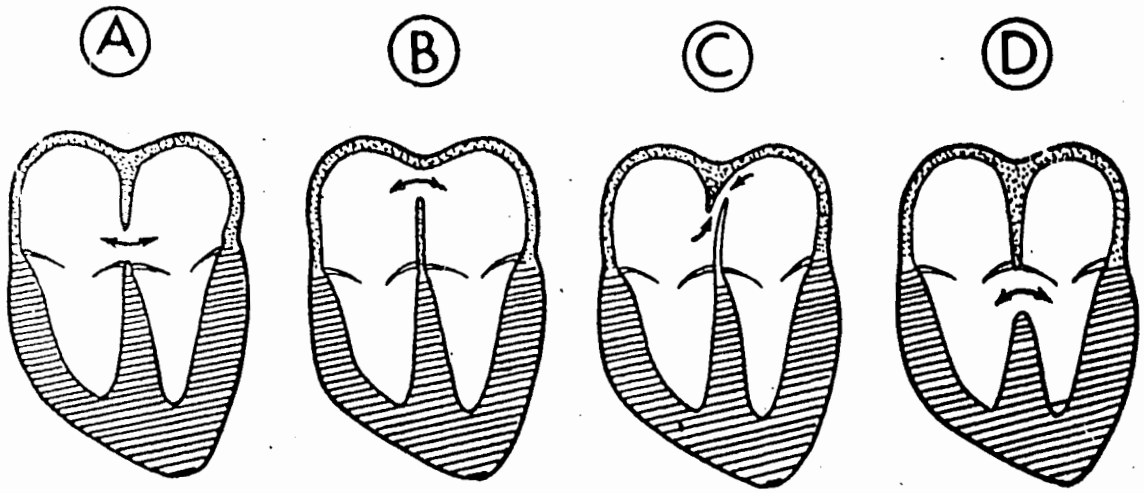

Fig. 15.23. Septal defects. A. Septum primum defect. B. Septum secundum defect. C. Patent foramen ovale. D. Interventricular septum defect

Endocardial cushion defect.
↓
Persistent A-V canal

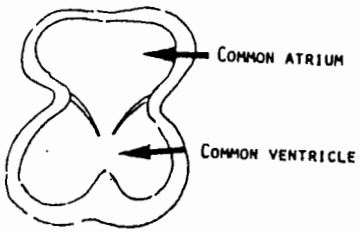

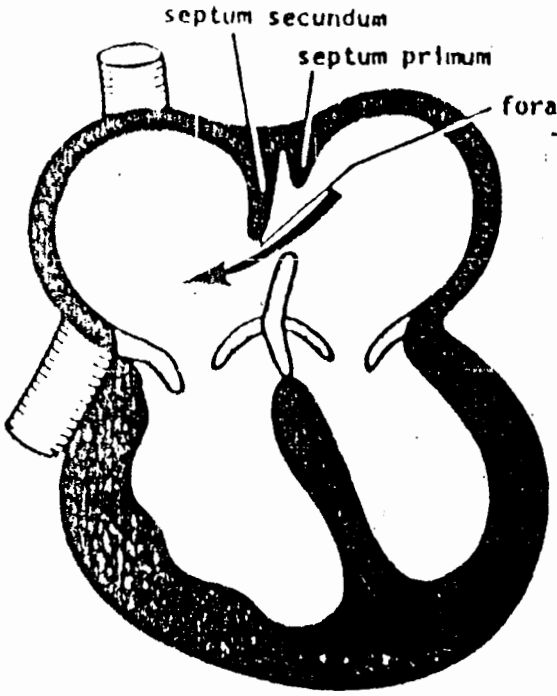

Atrial Septal Defect

A

Abnormalities of the truncus and conus

A. Unequal division of the truncus arteriosus results in tetralogy of Fallot which consists of the following defects:
   1. Pulmonary stenosis (smaller division)
   2. Overriding aorta (larger division)
   3. VSD (membranous part fails to develop)
   4. Hypertrophy of right ventricle (Fig. 12-13)

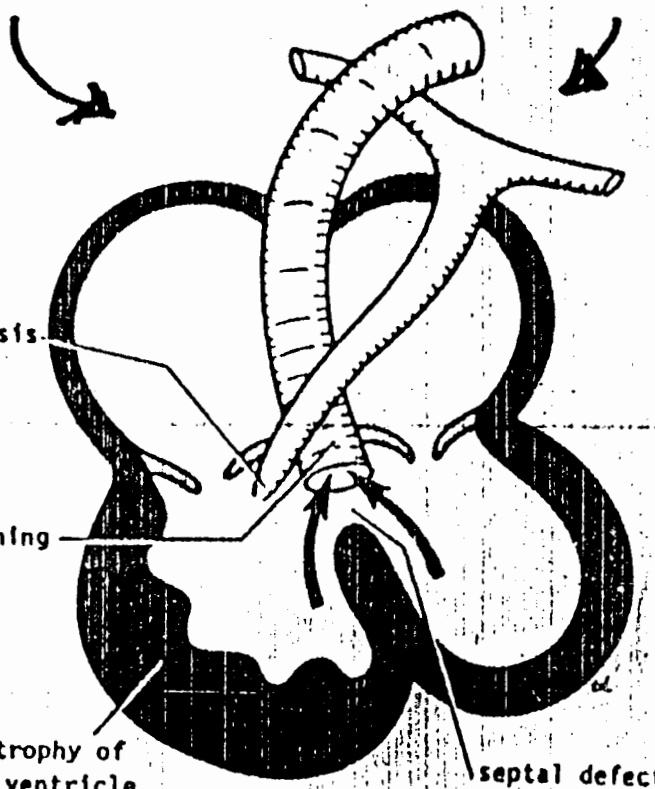

Tetralogy of Fallot

B

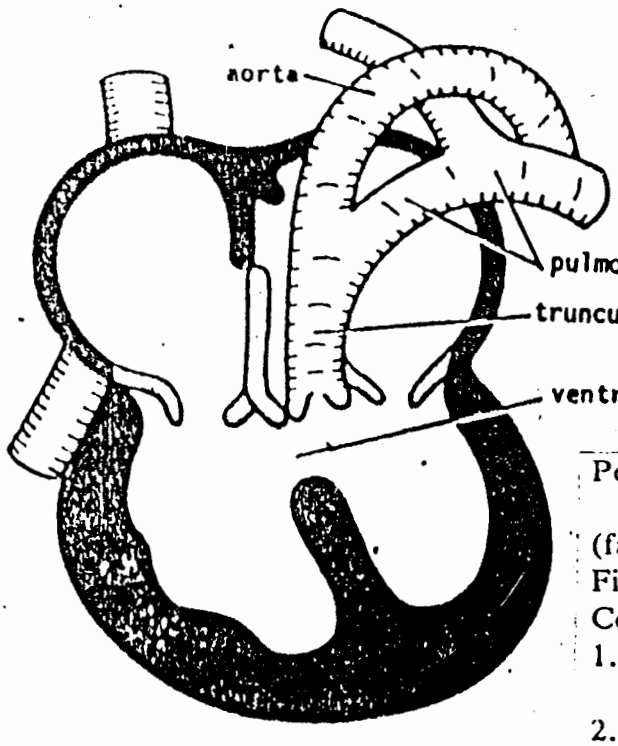

Persistent Truncus Arteriosus

C

Persistence of truncus arteriosus

This results from failure of truncoconal ridges to fuse (failure of the formation of aorticopulmonary septum) Fig. 12-14).

Complete transposition of the great vessels

1. The aorticopulmonary septum (truncoconal septum) fails to follow the normal spiral course.
2. The pulmonary trunk arises from the left ventricle and the aorta arises from the right ventricle (Fig 12-14).
3. This condition is incompatible with life unless it is associated with a septal defect or a patent ductus arteriosus.

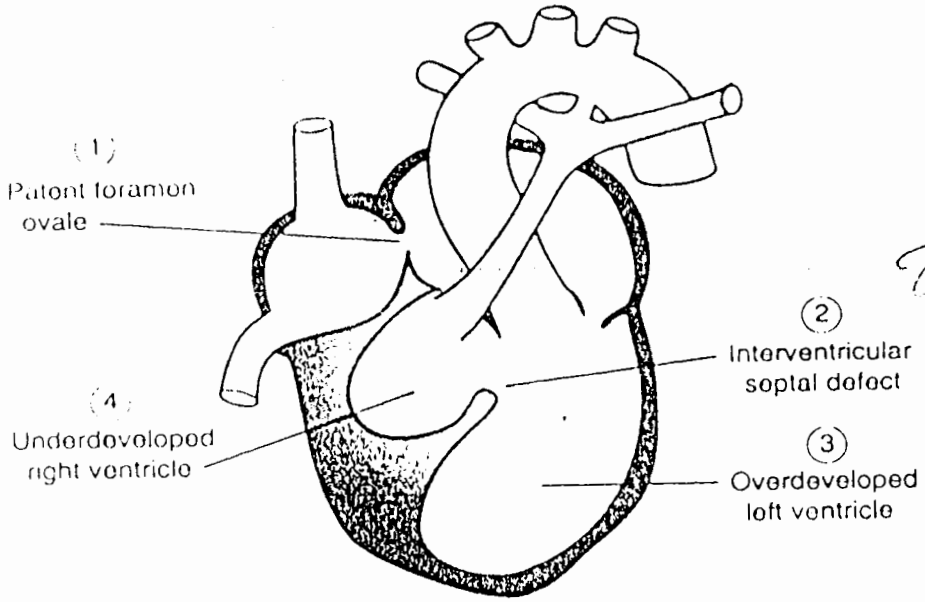

Figure 5-9. Tricuspid atresia, indicating the four main cardiac defects associated with this malformation.

c. **Tricuspid atresia** (Figure 5-9)

–is obliteration of the right AV canal.
–is characterized by absence of the tricuspid valve.
–is associated clinically with marked **cyanosis**.
–is always accompanied by the following:

(1) **Patent foramen ovale**
(2) **IV septum defect**
(3) **Overdeveloped left ventricle**
(4) **Underdeveloped right ventricle**

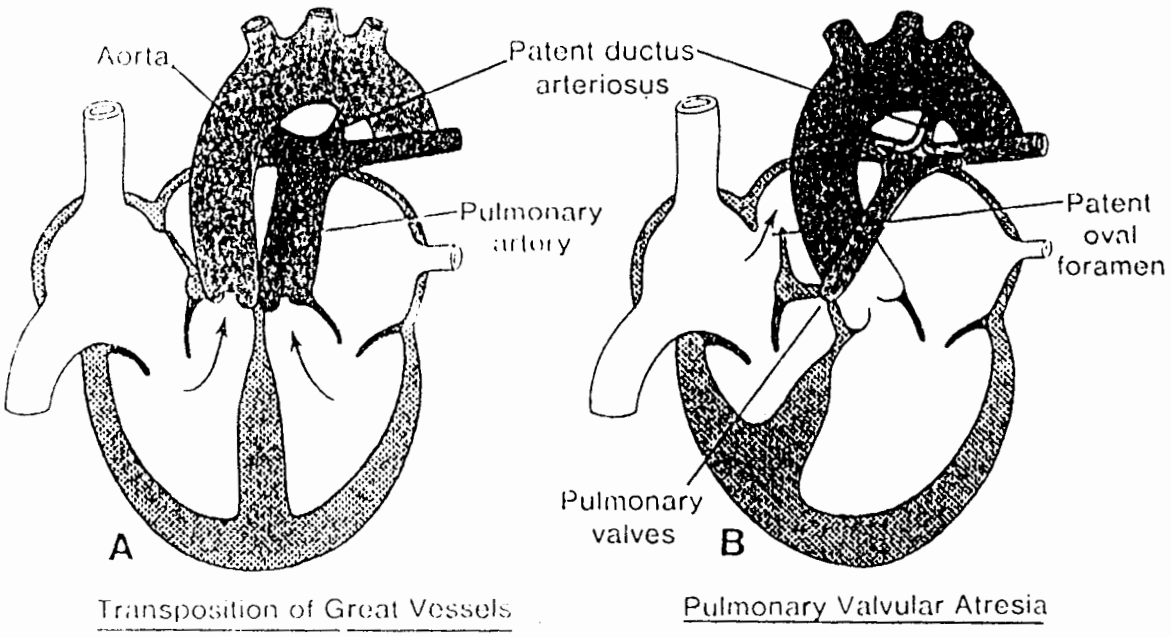

Figure 12-30. A, Transposition of the great vessels. B, Pulmonary atresia with normal aortic root. The only access route to the lungs is by way of the patent ductus arteriosus.

26

A. Coarctation of the aorta

A narrowing of the aorta either just above or below the ductus arteriosus (Fig. 12-16).

1. Preductal coarctation
   a) Generally associated with other serious congenital heart defects
   b) Prenatal circulation of blood is not seriously disturbed because most of the blood from the right ventricle is shunted through the ductus arteriosus, which is distal to the narrowing of the aorta.
   c) After birth this major shunt is closed, the pressure in the distal aorta remains low, and the blood flow to the body is impeded.
   d) Usually fatal in infancy.

Bustami

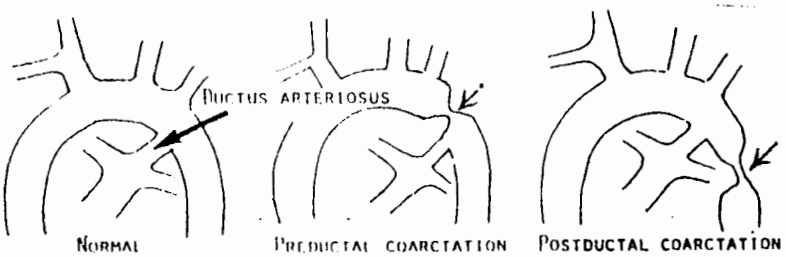

Fig. 12-16. Coarctation of the aorta.

2. Postductal coarctation
   a) The narrowing of the aorta is distal to the ductus arteriosus.
   b) Prenatal blood circulation through the aorta is impeded.
   c) A collateral circulation becomes established during fetal life which shunts the blood around the coarctation.
   d) As the collateral circulation is already well established, after birth no significant change occurs in the circulation.
   e) This is the common finding in cases of Turner's syndrome.

B. Patent ductus arteriosus

This condition may occur as an isoltaed abnormality or in combination with other heart defects. It is more common in females than in males. It is also the most common cardiac malformation associated with maternal rubella infection during early pregnancy.

VI. Abnormalities in the positioning of the heart

A. Dextrocardia (displacement of the heart to the right)

The heart tube bends to the left instead of the right, so the heart and the great vessels are reversed; otherwise, the heart functions normally. This is usually associated with situs inversus. Isolated dextrocardia usually results in other cardiac defects.

Other anomalies

Stenosis or atresia
(narrowing) (fusion of cusps)
of Pulmonary OR aortic Valves

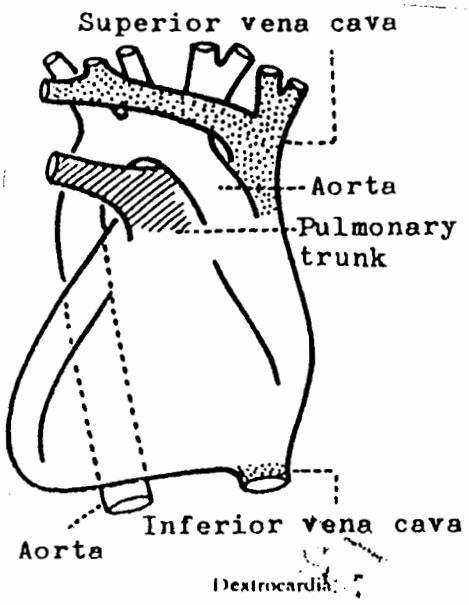

Dextrocardia

Cyanosis → is blue colouration of the skin and mucous membranes due to the presence of more than 5 gm. of reduced hemoglobin

Abustami

Central cyanosis due to → Veno-arterial shunt in congenital heart diseases
- affects tongue & peripheral parts
- O_2 tension → ↓

→ lung disease e.g fibrosis

Peripheral cyanosis due to → advanced congestive heart failure
- affects peripheral parts only
- arterial O_2 tension → Normal

→ local vasomotor disturbances

↓

Congenital heart diseases
- Non-cyanotic group
- Cyanotic group

Non cyanotic group

(a) with Rt. ventricular hypertrophy
- Pulmonary Stenosis
- A.S.D

(b) with lt. ventricular hypertrophy
- Aortic Stenosis
- coarctation of aorta
- patent ductus arteriosus (P.D.A)

(c) with biventricular hypertrophy
↓
Big ventricular septal defect (V.S.D)

(d) with No ventricular hypertrophy
↓
- small V.S.D (Roger's disease)
- dextrocardia

Cyanotic group → Fallot's tetralogy

- The more severe the pulmonary stenosis → the more is the blood which passes to the aorta and the more severe the cyanosis
- the Rt. ventricle hypertrophies slightly or moderately but never markedly because it has 2 pathways.

Congenital Pulmonary Stenosis

obstruction to the passage of blood from the Rt. ventricle to the pulmonary trunk due to narrowing of
- pulmonary valve (valvular stenosis)
- outflow part of Rt. ventricle (infundibular stenosis)

The obstruction causes
- ↓ amount of blood passing to the lungs
- ↓ pulmonary trunk pressure
- ↑ Rt. ventricular pressure
- Rt. ventricular hypertrophy → if severe → Rt. V. failure

Atrial septal defect A.S.D → more in ♀

due to
- persistence of ostium secundum → high A.S.D
- " " " primum → low A.S.D

haemodynamics → because the pressure is higher in the lt. atrium → blood is shunted from this chamber to the Rt. atrium → Rt. ventricle → pulmonary trunk → lungs → back to left atrium ⇒ ① decrease left ventricular output ② enlargement of Rt. atrium, Rt. ventricle & pulmonary trunk

Coarctation of the aorta

narrowing of the aorta usually below the lt. subclavian artery

haemodynamics
- → decrease amount of blood going to the lower part of the body
- → Rise of blood pressure in the upper part of the body as a result of mechanical obstruction & the renal ischemia
- → collateral develop to by-pass the constriction

Branches before the obstruction → from subclavian artery → internal thoracic → anterior intercostal ars

↕

Branches below the obstruction → Posterior intercostals from descending aorta

⇓

→ Visible or palpable pulsations of the collateral vessels particularly in the interscapular region

x-ray → Notching of the lower margin of the ribs due to pressure by collaterals

→ double aortic knuckle (post-stenotic dilation)

Patent ductus arteriosus

→ Because of the pressure differences → blood is shunted from the aorta to the pulmonary artery in systole & diastole

Big ventricular septal defect

Because of the pressure difference → blood is shunted from the left to the right ventricle in Systole

↓

No shunt occurs in diastole because the diastolic pressure in the two ventricles is ZERO

↓

The shunted blood passes from the Rt. ventricle to → Pulmonary trunk → lungs → lt. atrium → again to lt. ventricle

↓

* Diminution of lt. ventricle output
* Enlargement of both ventricles

× Vasoconstriction of pulmonary arterioles (protective mechanism) → Pulmonary hypertension → Reversal of shunt (Eisenmenger complex)

Left Heart Failure (LHF): occurs when the left side of the heart is unable to pump the total volume of blood it receives from the right side of the heart

↓

As a result the the pulmonary circulation becomes congested with blood (backward effect) that cannot be moved forward and the systemic blood pressure falls (forward effect).

↓

The most common cause of left heart failure is **MI** (myocardial infarction); other causes include systemic hypertension, valvular → stenosis or insufficiency

Backward effects

* ↓ emptying of lt. ventricle *

↓

↑ end-diastolic volume & pressure in lt. ventricle

↓

↑ volume (pressure) in the lt. atrium

↓

↑ volume in pulmonary veins

↓

↑ volume in pulmonary capillary bed

↓

Transudation of fluid from capillaries into the interstitial spaces around the alveoli & finally into the alveoli

chronic!! ↓

(Acute) Pulmonary oedema

↓

impair gas exchange which can be life-threatening

↓

Affected individuals exhibit dyspnea & orthopnea → inability to breath in the supine position

Bustami

Forward effects

↓ cardiac output → ↓ systemic blood pressure *

↓ perfusion of body tissues

↓

↓ blood flow to kidneys and glands

↓

Renin-angiotensin-aldosterone system is stimulated → further vasoconstriction & Na^+ and H_2O retention

↓

↑ extracellular fluid volume

↓

↑ total blood volume

↓

↑ systemic blood pressure

↓

Pt. c/o → Easy fatigue weakness & dizziness

occurs when hypoxia of body tissues occurs because of ↓ cardiac output and ↓ O_2 saturation of the blood

weakness → loss of K^+ by ↑ levels of aldosterone

dizziness → caused by brain hypoxia

Right heart failure (RHF) occures when the output of the right ventricle is less than the input from the systemic venous circulation (venous return). → As a result the systemic venous circulation is congested (backward effects) and the output to the lungs decreases (forward effects)

The major cause of RHF ↓ is LHF ⟹ the right ventricle fails because of the excessive pulmonary pressure generated by failure of the left heart *

Other causes include COPD !!, congenital heart defects especially those that involve ↑ blood flow to the lungs and pulmonary hypertension

Backward effects (diastolic dysfunction)

↓ emptying of Rt. ventricle
↓
↑ volume and end-diastolic pressure in Rt. ventricle
↓
↑ volume (pressure) in Rt. atrium (central venous pressure) CVP
↓
↑ volume and pressure in the great veins (CVP)
↓
↑ volume in the systemic venous circulation
↓
↑ volume in distensible organs (hepatomegaly & splenomegaly)
↓
↑ pressure at capillary line
↓
[Dependent edema]

Forward effects (systolic dysfunction)

↓ volume from the right ventricle to the lungs
↓
↓ blood return to the lt. atrium and subsequent ↓ cardiac output
↓
All the forward effects of left heart failure
↓
↑ blood volume and vasoconstriction

Bustami