

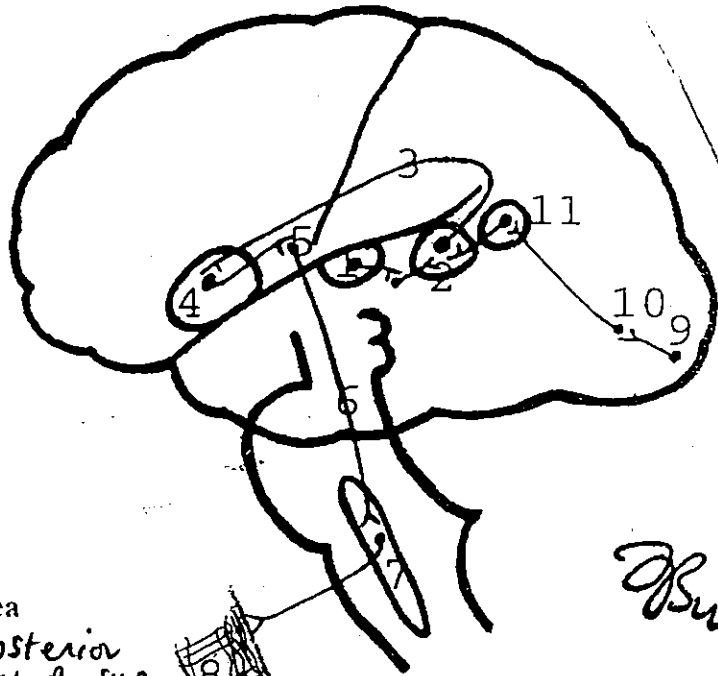
Speech & Language (1)

Basically involves the Understanding of $\left\{ \begin{array}{l} \text{spoken} \\ \text{printed} \end{array} \right\}$ words besides the ability to express ideas in $\left\{ \begin{array}{l} \text{speech} \\ \text{writing} \end{array} \right\}$

Aphasias

fluent (sensory)
non-fluent (motor)

Abnormalities of language functions that are NOT due to defects of vision or hearing or to motor paralysis → They are caused by lesions in the categorical hemisphere.



- 1-Primary auditory area
- 2-Associated auditory area and Wernick's area (posterior part of sup. temporal gyrus)
- 3-Arcuate bundle
- 4-Broca's area (inf. frontal gyrus)
- 5-Motor area
- 6-Corticobulbar tract
- 7-Nucleus ambiguus, hypoglossal nucleus and other cranial nuclei that supply speech muscles
- 8-Speech muscles (larynx, palate, tongue, lips)
- 9-Primary visual area
- 10-Associated visual area
- 11-Angular gyrus (inferior parietal lobule)

Reading

FIGURE 15-3: Cortical areas and pathways that are probably mediate spoken language (communication) and written language (reading).



Speech & Language

(2)

In 95% of people → the LEFT cerebral hemisphere contains the centres for language & comprehension

< Dominant Hemisphere >

Normal communication between people by spoken language needs at least 4 cortical areas

- Primary auditory area (41, 42)
 - Wernick's area (post. part of area 22)
 - Broca's area (44, 45)
 - inferior frontal gyrus
 - Premotor & motor areas
- Bustani*

* Wernick's area — Sensory speech area
important to understand the spoken words that reach the primary auditory area from the ears → Send the necessary information about speech to Broca's area

send motor signals through the descending motor tracts to the Speech muscles → larynx, tongue, lips & palate
send the necessary information to Motor & premotor areas

* Written words to be spoken needs
→ Visual areas in the occipital lobe (17, 18, 19)
→ Angular gyrus (area 39)
→ Wernick's area → Broca's area → Motor area

Lesions in Wernick's area → allow a person to hear different words perfectly But make him unable to arrange these words into a coherent thought. Likewise, the person is capable of reading but cannot understand the ideas conveyed by the read words.

At one time used to be called general interpretative area → Receive impulses from $\left\{ \begin{array}{l} \text{sonic} \\ \text{visual} \\ \text{auditory} \end{array} \right\}$ association areas

Wernick's area

A centre in the mind for interpreting Sensory experiences (relates them to past experiences)

for formation of thought in response to that interpretation

for choice of words to express thoughts

Projects via the ARCULATE Fasciculus

To 1 Broca's area of the dominant hemisphere if speech is involved

or to 2 Area of hand skills in premotor area 6 if writing is involved

Broca's area

Processes the information received from Wernick's area into coordinated pattern of vocalization & project that pattern to the motor cortex → initiate movement of muscles of speech in the tongue, lips & larynx via the corticobulbar fibres of the pyramidal tract.

If writing is concerned

→ the information received from Wernicke's area is processed in the area of hand skills → (4)

The result is a coordinated pattern of muscle movements projected to arm and hand region of the motor cortex which initiates the necessary muscle movements in the hand & arm required for writing a particular word

Broca's area (Brodmann's area 44, 45)

→ Motor speech area occupies the left inferior frontal gyrus DIRECTLY in front of the motor cortex controlling muscles of speech.

→ Stores speech programs that are used by the motor area to produce normal speech

→ It receives INPUT from the Sensory speech area (Wernicke's area)

→ Sends OUTPUT to the lower part of the motor area which controls the speech muscles


→ A lesion confined to Broca's area results in MOTOR (Expressive) aphasia

Bustami

In this type of aphasia:

- ① the patient knows what he wants to say but has great difficulty in saying it leading to SLOW POOR & Nonfluent speech. (speech muscles are Not paralyzed)
→ Non-fluent aphasia
- ② The patient understands spoken & written words but has trouble in speech & finds writing difficult or impossible
- ③ In severe cases, the patient may be limited to 2-3 words with which to express a whole range of emotions

Wernicke's area \rightarrow Post. part of area 22
 ↓ lesion is the Sensory speech centre



Severe disturbances of speech content

of Broca's

Although hearing & vision are normal \rightarrow individuals with this disability show an essentially \rightarrow **TOTAL FAILURE TO COMPREHEND EITHER THE SPOKEN and/or WRITTEN LANGUAGE**

* Their speech is **FLUENT** but **MEANINGLESS** (key words are omitted)
 * The patient is unaware of his errors \rightarrow (fluent aphasia)

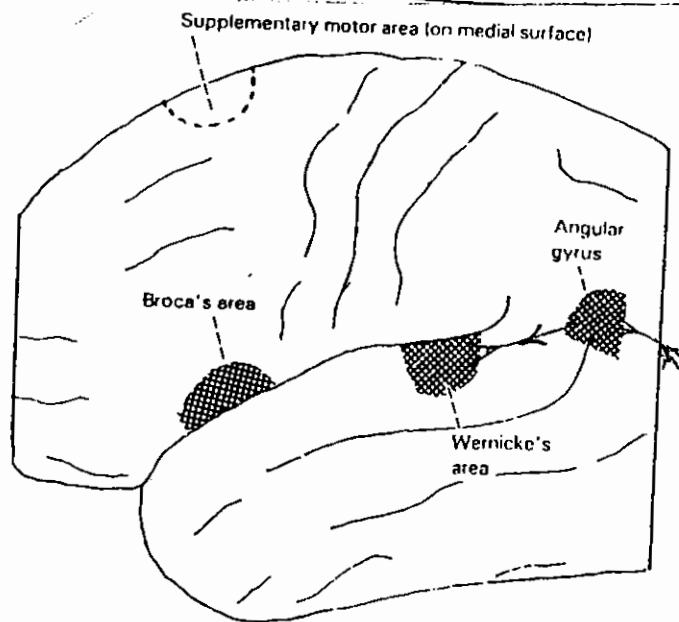
* **Wernicke's area** receives inputs from \leftarrow auditory association cortex
 projects to \rightarrow angular gyrus
 Broca's area (via the arcuate fasciculus) \leftarrow premotor cortex (hand skill area)

Fluency is quite normal, but three kinds of abnormality occur in the use of nouns:

- 1 Circumlocution. Instead of 'I use a knife', 'I use the thing you cut with'. *الشيء الذي تقطع به*
- 2 Verbal paraphasia (the use of words of allied meaning). Instead of 'I cut with a knife', 'I cut with a fork'.
- 3 Phonemic paraphasia (the use of made-up words having appropriate sounds. Instead of 'knife and fork', 'bife and dork'.

Table 25-1 Comparison of Broca's and Wernicke's aphasia

| | Aphasia | |
|---------------|---------|------------|
| | Broca's | Wernicke's |
| Articulation | Slurred | Normal |
| Speed | Halting | Rapid |
| Comprehension | Good | Poor |
| Awareness | Yes | No |



Angular gyrus

\rightarrow it is area 39 which caps the superior temporal sulcus
 \rightarrow the left angular gyrus is the VISUAL-AUDITORY CONVERSION AREA

\rightarrow receives from \leftarrow visual association cortex on its own side
 \leftarrow its partner opposite through the corpus callosum
 \rightarrow projects to \rightarrow Wernicke's area

THE LEFT ANGULAR GYRUS IS ESSENTIAL FOR THE CONVERSION OF THE WRITTEN WORD TO ITS AUDITORY EQUIVALENT (FROM GRAPHEMES TO PHONEMES)

A lesion here causes written words to become meaningless hieroglyphics \rightarrow **ALEXIA** \rightarrow This because we need to hear the written word while reading. (No difficulty in speech or understanding of auditory information)

alexia

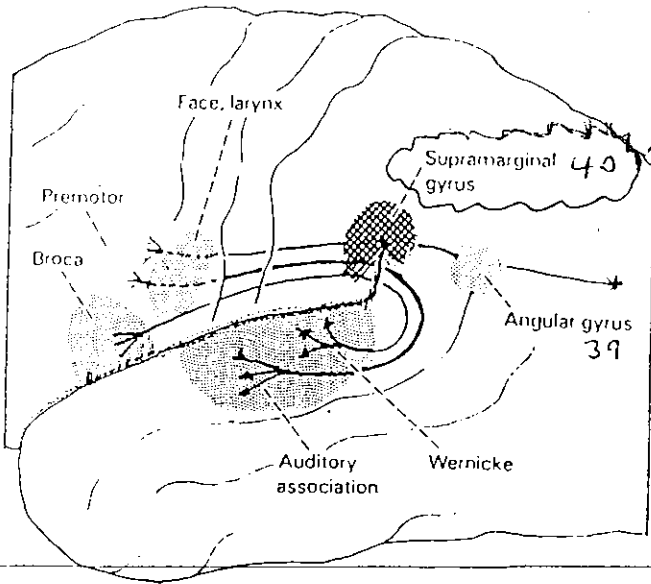
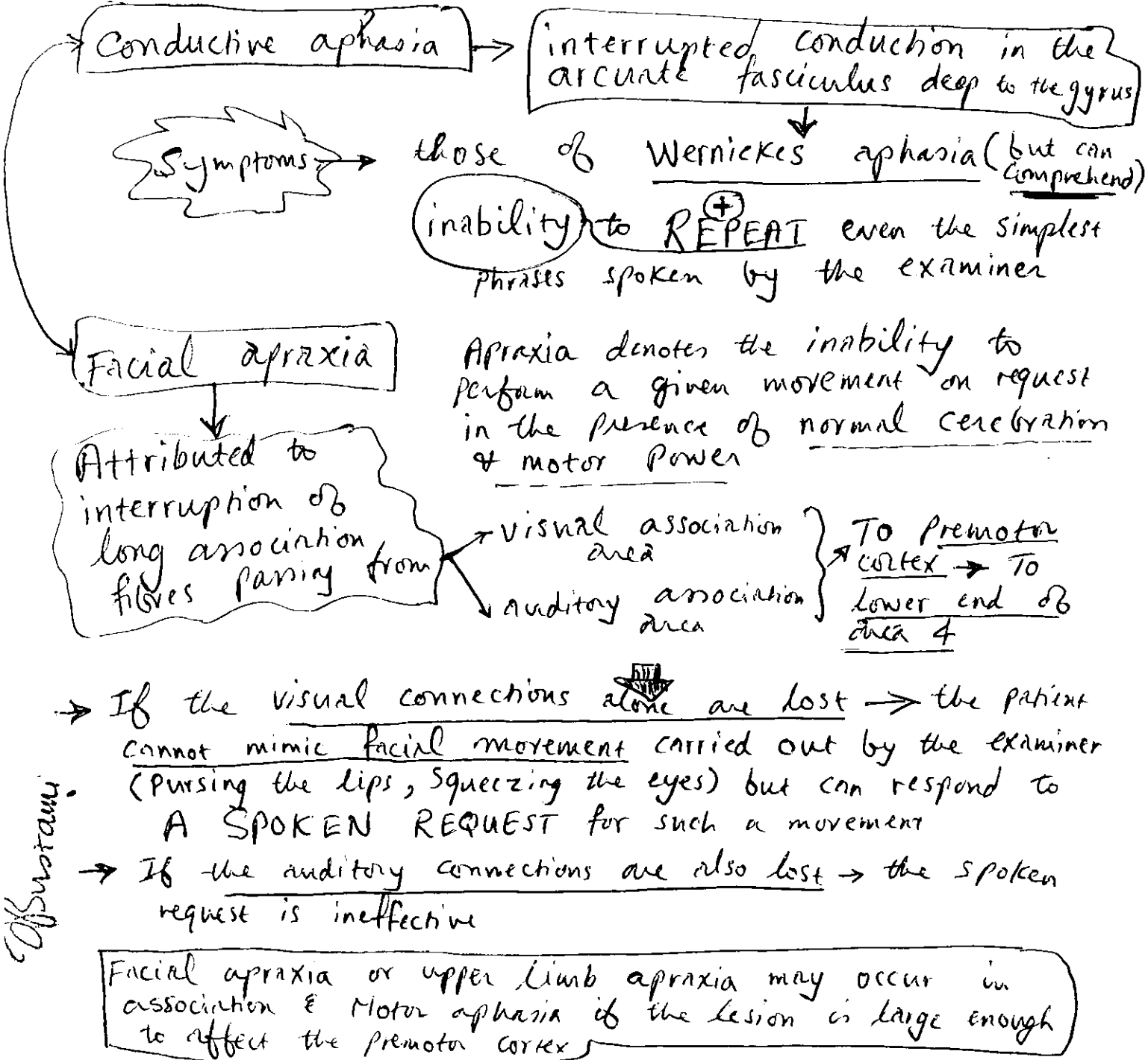


Fig. 25-5 Three sets of long association fibers underlie the supramarginal gyrus.

Supramarginal gyrus (area 40) (7)
 ↓
 Surrounds the upturned posterior end of the lateral sulcus
 ↓
 Lesion here which include the underlying white matter may result in
 Conductive aphasia *
 Facial apraxia *



of Swotank

Global aphasia → is seen with large lesions affecting (8)

both Wernicke's & Broca's areas.

Marked hemiparesis occurs ⊕ inability to comprehend & to speak

→ Seen with large infarcts in the middle cerebral artery territory (often due to occlusion of the left internal carotid artery or trunk of middle cerebral artery).

Examination of the aphasic patient

- 1) Listen to speech output → Is it fluent or nonfluent?
if fluent the lesion is posterior, if nonfluent, it usually is anterior
- 2) Can the patient READ & WRITE with no errors? If so → aphasia is not present
- 3) IS there HEMIPARESIS? If so, the lesion is anterior involving motor area

4) In fluent aphasia → check whether the patient can Repeat Comprehend name?

- a) In Wernicke's (sensory) aphasia → pt. cannot Repeat or Comprehend, names poorly
- b) conduction aphasia → cannot repeat but can comprehend, names poorly
- c) Anomic → can both repeat & comprehend but has trouble with naming

of Sustains

The importance of defining the aphasia!!

1. The definition of the aphasia Localizes the level of the nervous system lesion. (9)

{ If aphasia is present → the lesion is usually }
in the left cerebral cortex }
Bustami

A patient with Paresis of the Right hand (U.L) and a mild aphasia has a lesion in the cerebral cortex but not a brachial plexus lesion (LMNL)

2. Aphasia implies dysfunction of the middle cerebral artery territory & is often caused by disease of the internal carotid artery in the neck → Marked stenosis of the internal carotid may be surgically correctable → if recognized & treated → a mild transient aphasia may be prevented from becoming global

3. The sudden onset of fluent aphasia without hemiparesis → often means an embolus to the posterior branch of the middle cerebral artery → Look for an embolic focus in the heart or in the carotid artery (If the heart is the source anticoagulation should be considered)

Remember the clinical rule → the sudden onset of aphasia without hemiparesis suggests embolus

- Remember %
- ① patients with global aphasia have a poor prognosis & almost never recover completely
 - ② patients with anomic & conduction aphasias have good prognosis & complete recovery occurs frequently
 - ③ Broca's and Wernicke's aphasia patients have an intermediate prognosis & show wide range of outcome
 - ④ In general patient with traumatic cause of aphasia do better than those in whom stroke is the cause

Alexia (Dyslexia)

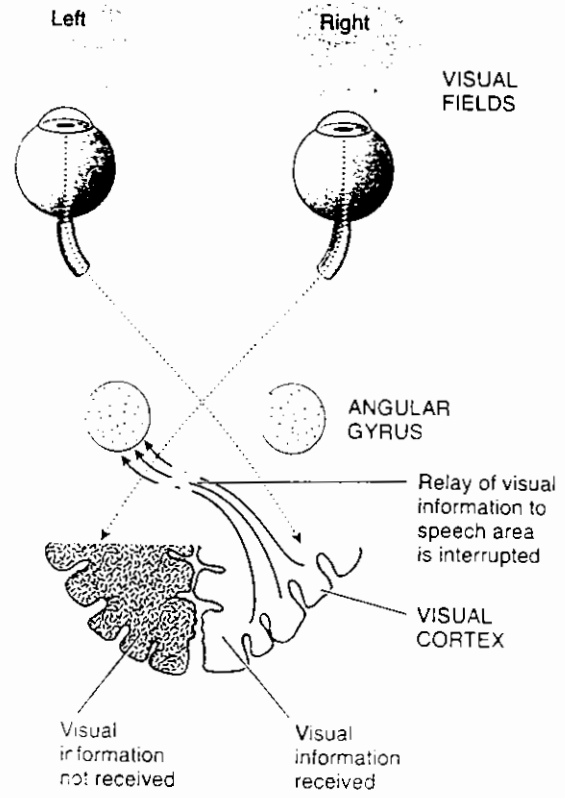
Inability to comprehend written language (Reading disability)

acquired (in stroke patient) 1
developmental 2

(inability to learn to read normally from childhood)

Acquired alexia

- Ⓐ Pure alexia (without agraphia)
 Pure word blindness
- Ⓑ alexia with agraphia (Parietal alexia)
 Bustanji



(pure alexia without agraphia) → the defect in comprehension may manifest as an inability to read letters or words or both → the lesion → in the LEFT primary visual area coupled with another lesion in the splenium of corpus callosum

- ① The lesion in the left visual area prevents visual stimuli entering the left hemisphere from reaching the left (dominant) angular gyrus which is necessary for comprehension of written language
 - ② The lesion in the splenium of the corpus callosum prevents visual stimuli entering the intact right visual area from reaching the left angular gyrus
- Writing is normal but the patient cannot read what he or she writes

* Pure alexia without a splenic lesion ? deep lesion in the occipitotemporal region that isolates both visual cortices from left angular gyrus !!

* In alexia with agraphia → there is a defect in both reading comprehension & writing → lesion in the dominant angular gyrus hence the name Parietal alexia

Callosal Syndrome

Disconnection of Rt. from Lt. hemisphere by lesion in the corpus callosum

11

of Sustani

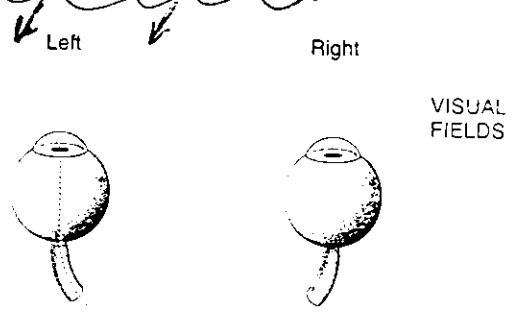
isolation of each hemisphere in such a way that each has its own learning processes & memories that are inaccessible to the other hemisphere

Visual Effects → Each hemisphere Retain its own Visual images & memories

only the Lt. hemisphere is able to communicate through Speech or Writing!! because of callosal disconnection

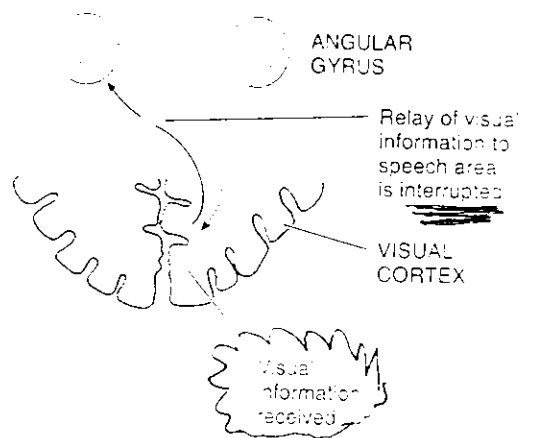
Hemialexia = Patients are unable to read material presented in the left hemifield

This occurs when the splenium of the corpus callosum is involved in the lesion → Such visually presented material reaches the Right visual cortex but CANNOT BE COMPREHENDED because the splenic lesion interferes with transmission of the visual impulses to the left angular gyrus



Unilateral (left) tactile Anomia

patients with callosal disconnection are unable with eyes closed to name or describe an object placed in the left hand although they readily name the same object in the right hand !!



The object placed in the left hand is perceived correctly in the Right Somatosensory cortex but cannot be identified because the callosal lesion that disconnects the right parietal cortex from the left (dominant) hemisphere

12
O'Rourke

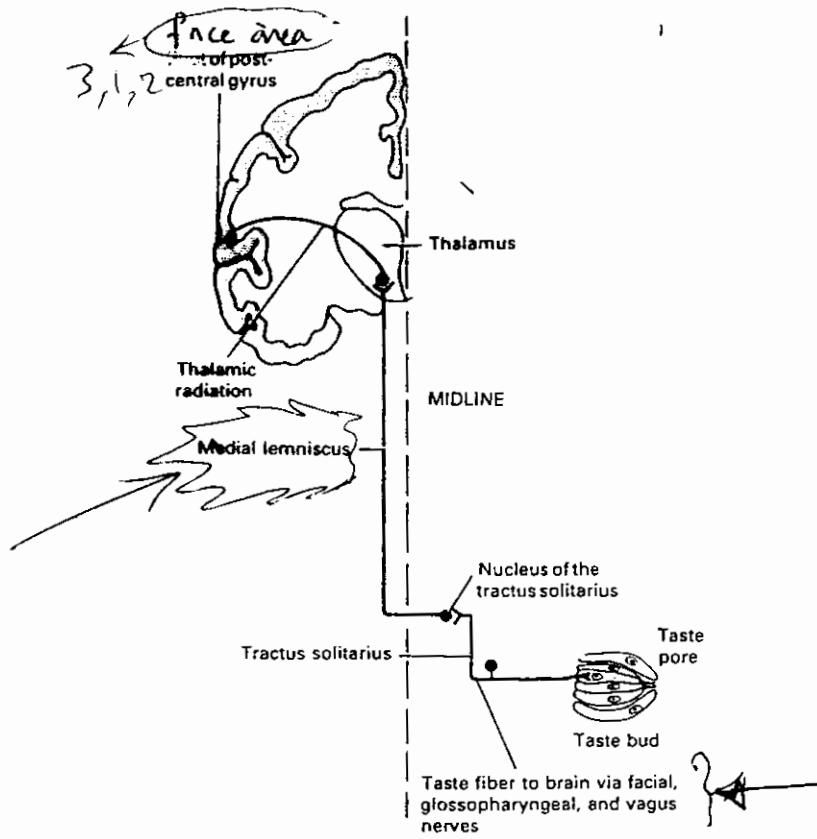


Figure 10-7. Diagram of taste pathways.