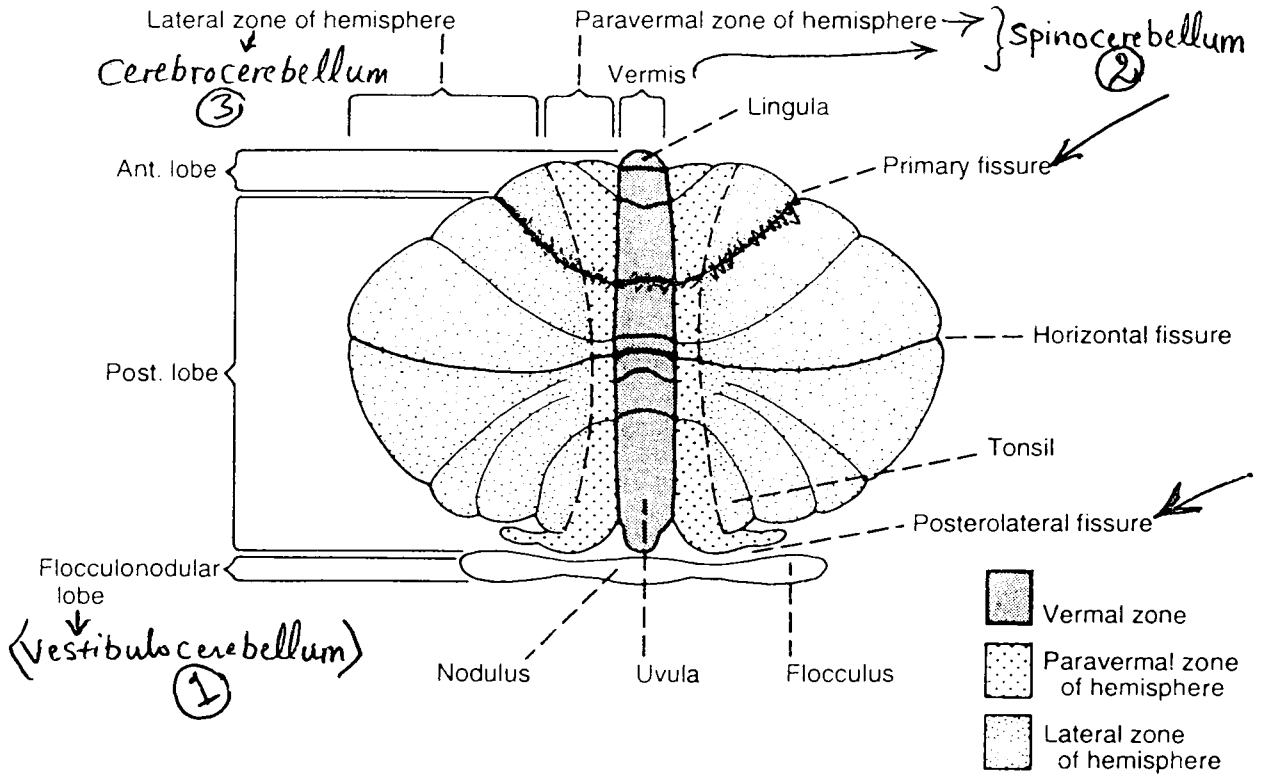

Figure 15.1. Schematic diagram of the fissures, lobules, and lobes of the cerebellum. Functional longitudinal zones of the cerebellum are associated with cerebellar nuclei. The vermal (median) zone projects to the fastigial nucleus; the paravermal (paramedian) zone projects to the interposed nucleus; the lateral zone projects to the dentate nucleus.

The LOBES and LOBULES of the CEREBELLUM

- The true division of the cerebellum is not into a median vermis and 2 cerebellar hemispheres but into lobes & lobules.

- Deep transverse fissures divide the cerebellum into different lobes and lobules. The fissures cut the vermis (transversely) and extend laterally into the hemispheres.

Therefore:

- Each lobe has a median part (in the vermis) and a pair of lateral extensions (in the hemispheres).

- A postero-lateral fissure separates the flocculo-nodular lobe (nodule in the middle and flocculus on either side) from the main part of the cerebellum.

- The most important fissure is the primary fissure which divides the main part of the cerebellum into anterior and posterior lobes.

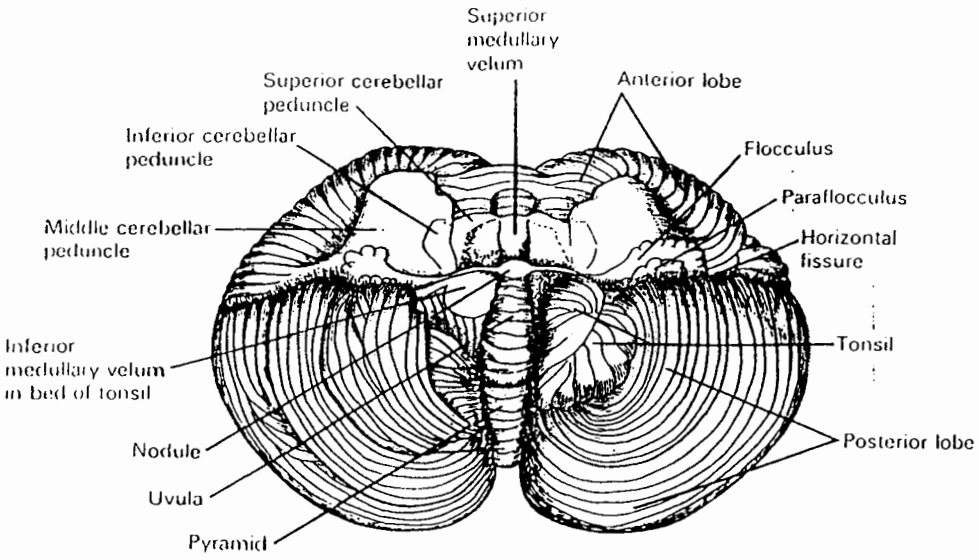

Fig. 7.2 Anteroventral surface of the cerebellum. The right tonsil of the cerebellum has been removed to show the inferior medullary velum.

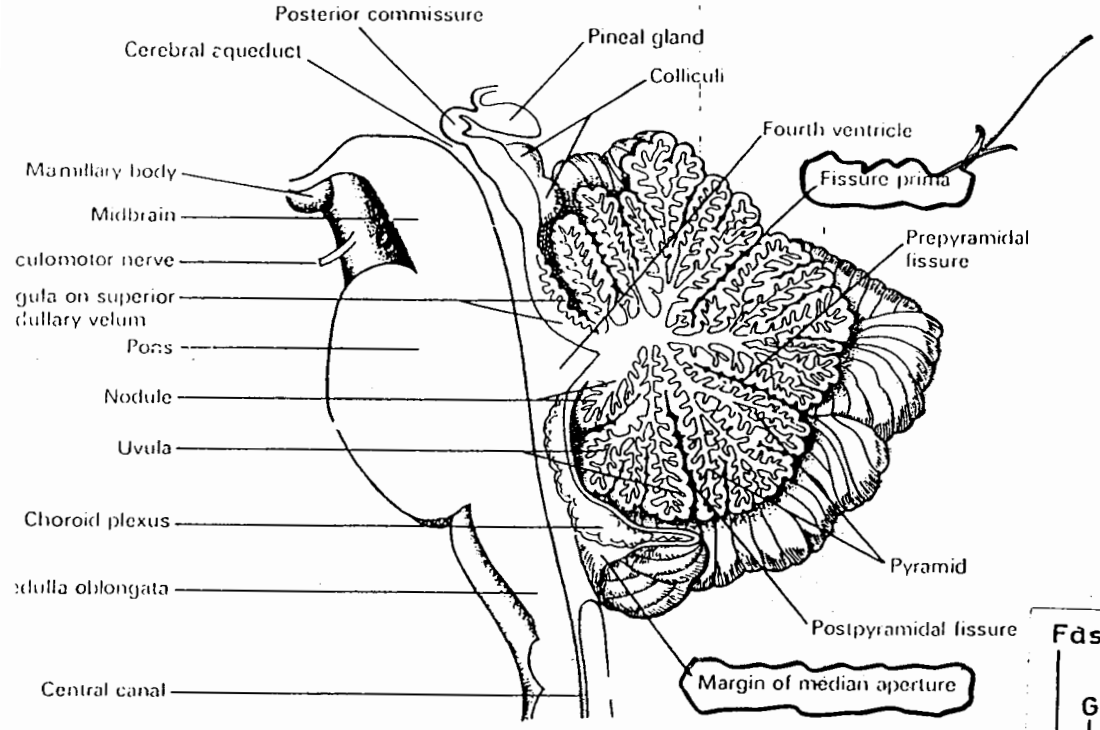

Fig. 7.3 Median sagittal section of the cerebellum and brainstem.

. Buried in the white matter are the deep cerebellar nuclei. The dentate nucleus, shown in Fig. 14-10, is the most lateral of these. The other deep nuclei include the emboliform, globose, and fastigial nuclei. (In cats the emboliform and globose nuclei combine to form the interpositus nucleus.)

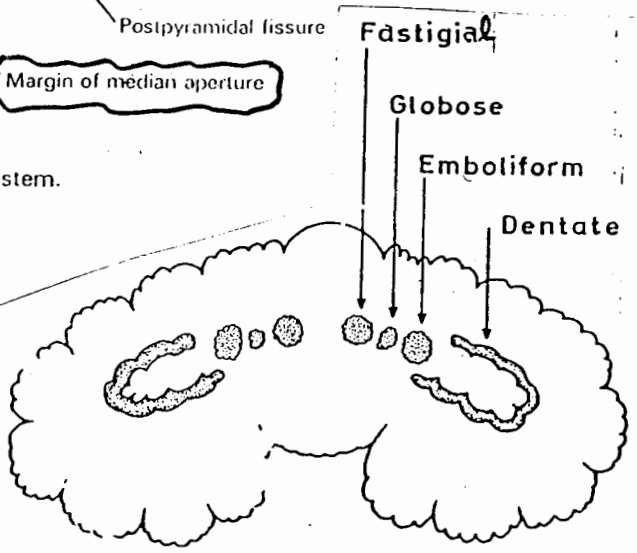

Schematic diagram showing the spatial arrangement of the deep cerebell

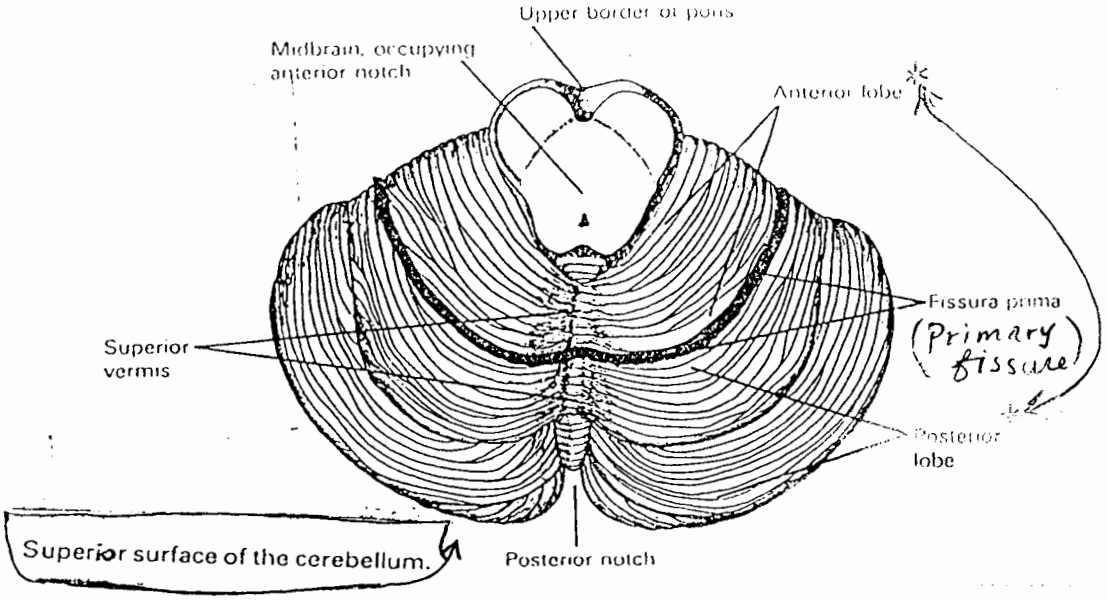

Superior surface of the cerebellum.

Anatomy

3/A

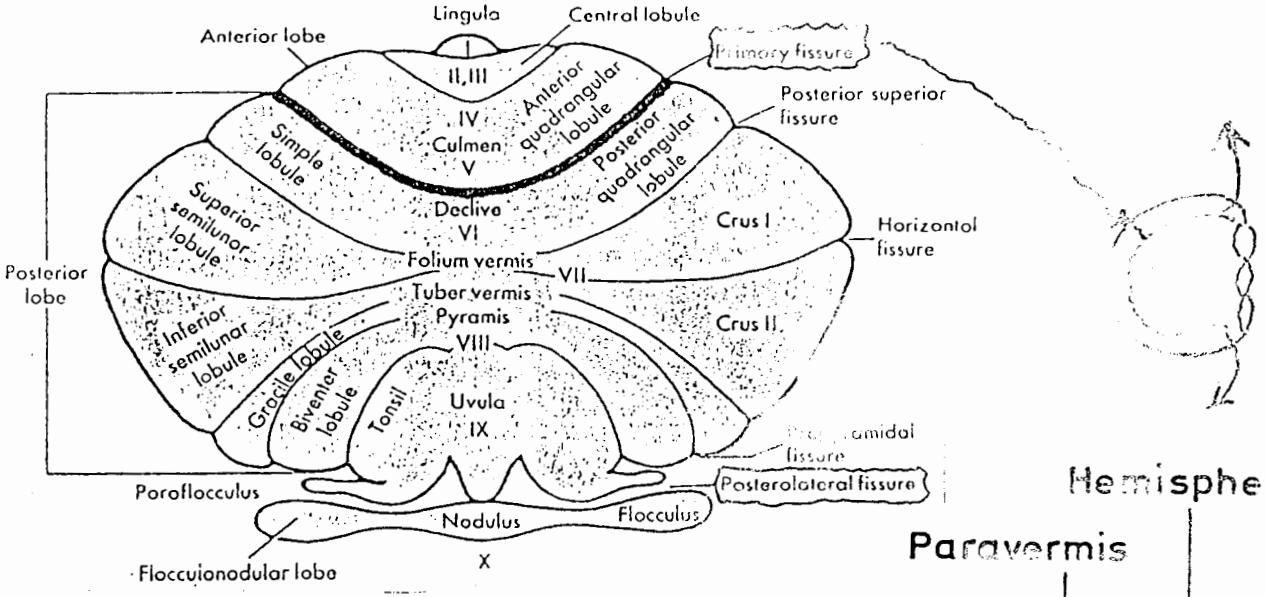

Diagram showing the Projection of the different cerebellar Zones into the deep cerebellar nuclei

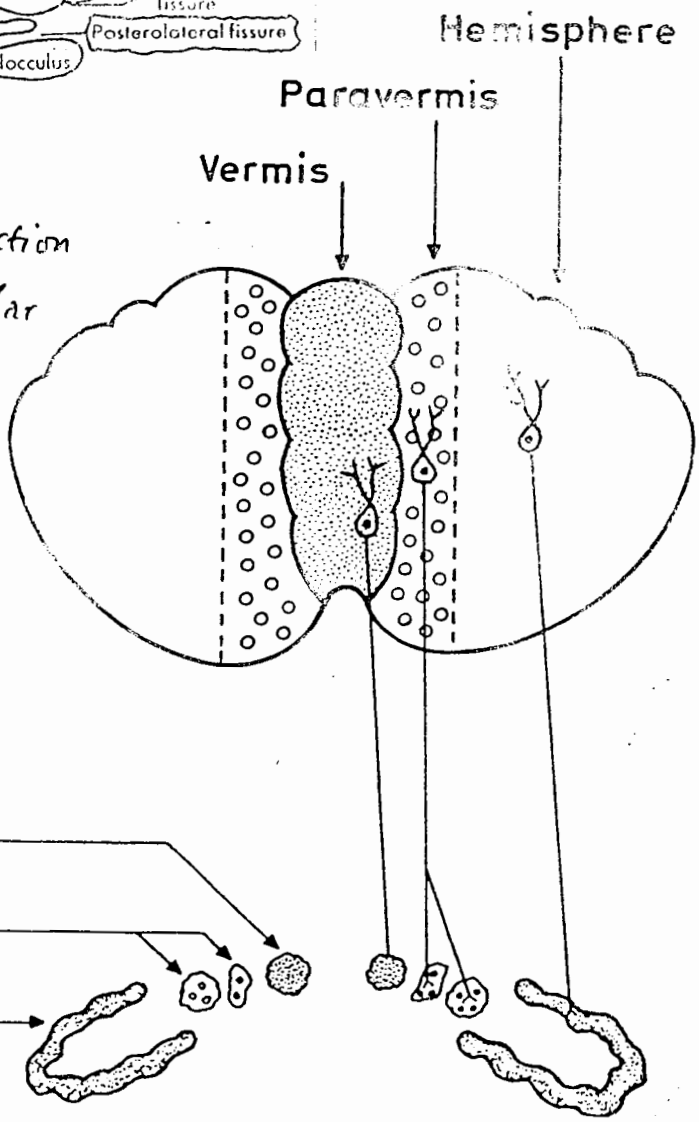

Bustami

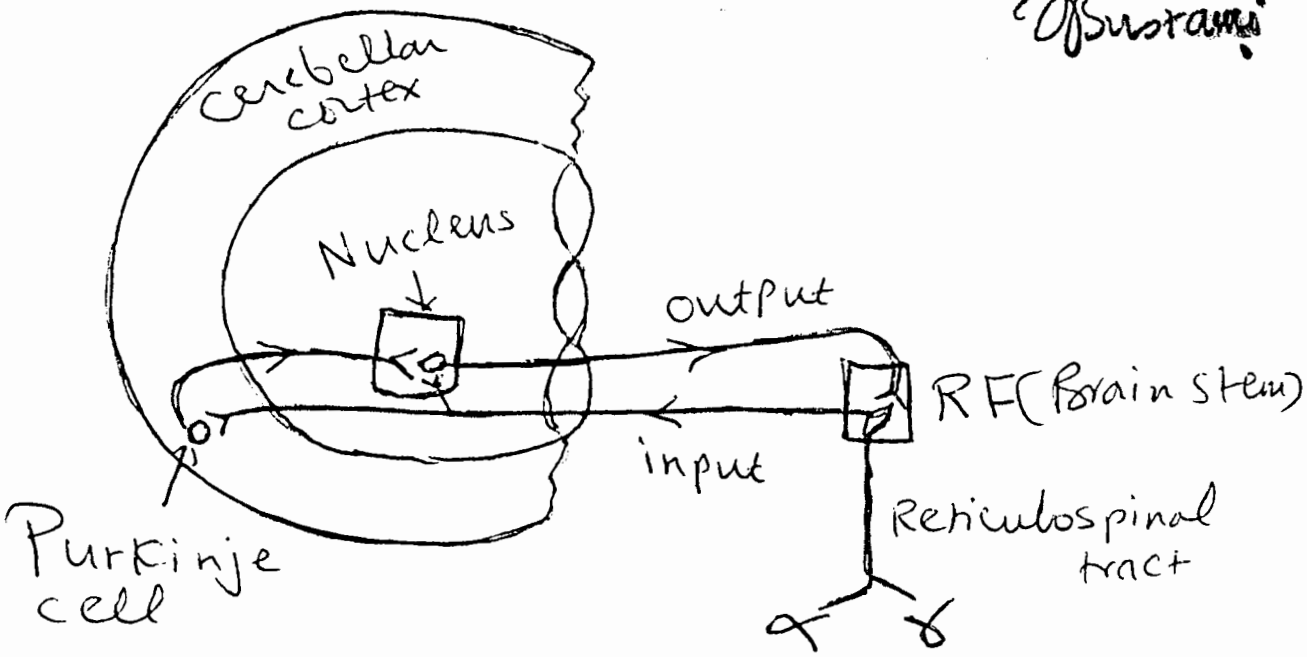
Cerebellar cortex
Nucleus
output
RF (Brain stem)
input
Reticulospinal tract
Purkinje cell

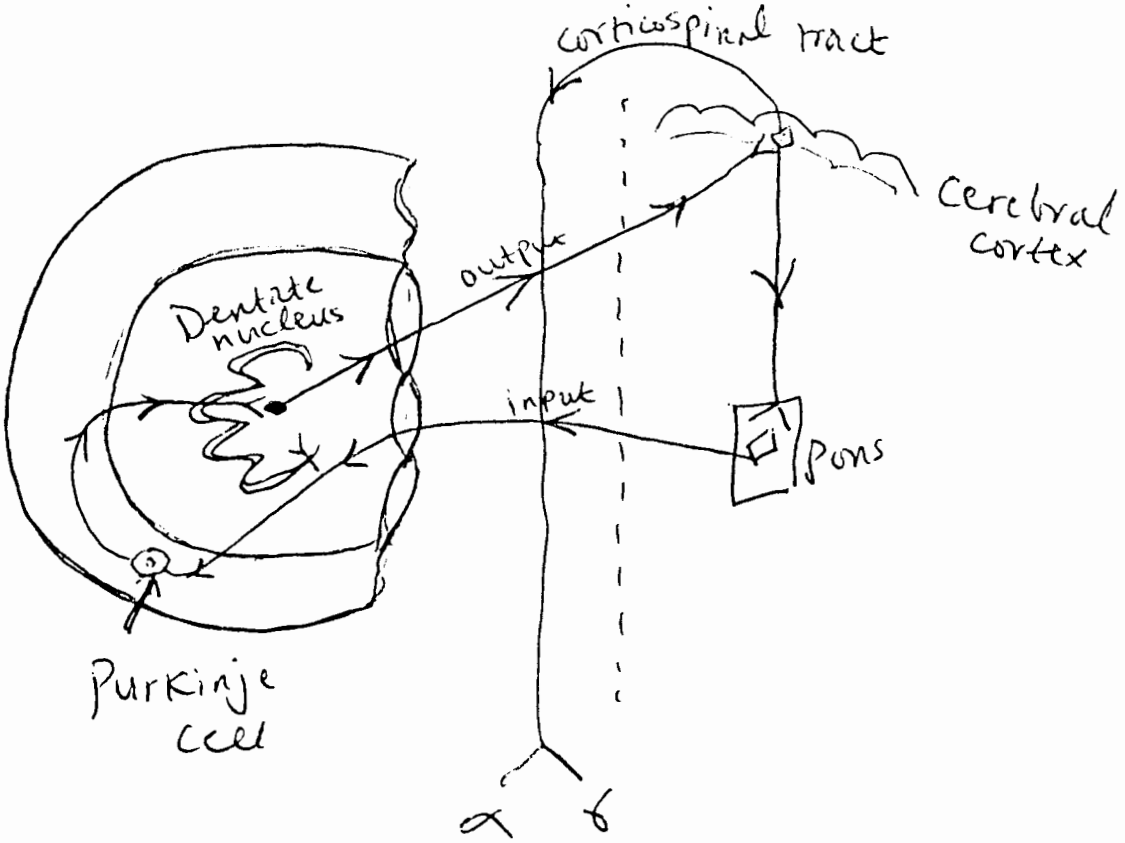
corticospinal tract
Cerebral cortex
output
Dentate nucleus
input
Pons
Purkinje cell

Bustami

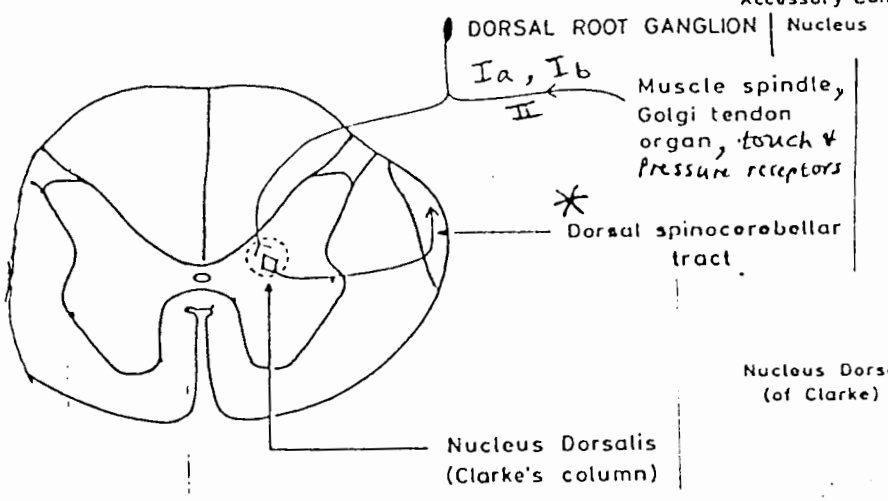

Spinocerebellar pathways (Fig. 9-12)

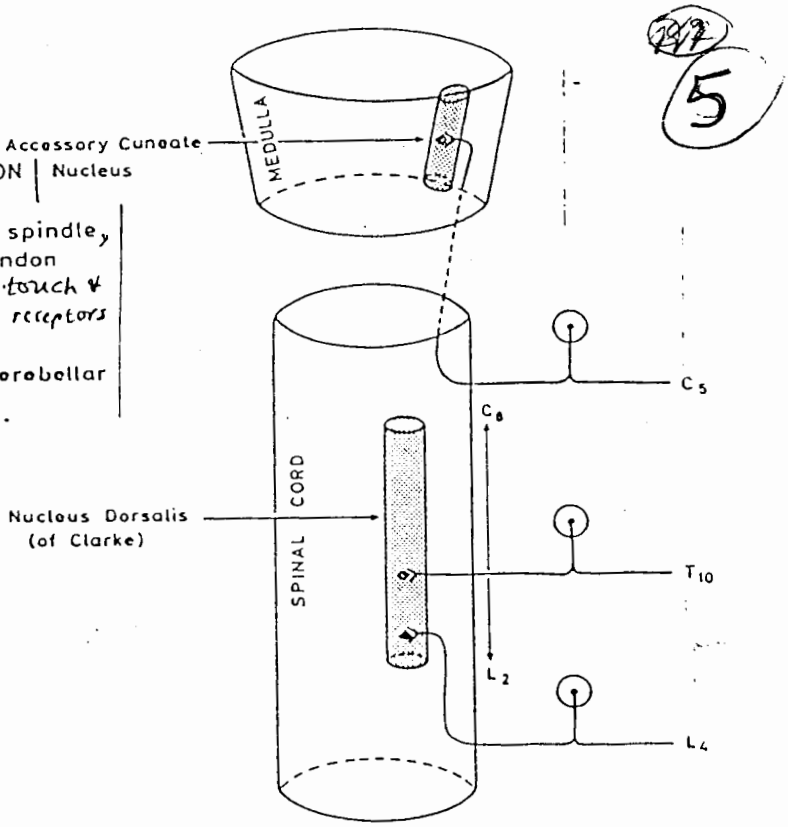

Figure 5.10. Schematic diagram of the spinal cord showing the homology of the accessory cuneate nucleus and the nucleus dorsalis of Clarke.

Pathway	Primary afferents from	Transmission cells (nucleus)
1. Posterior (dorsal) Spinocerebellar tract	Ia, II, Ib from muscle spindle, Golgi tendon organ touch & pressure receptors (from skin) from Lower limb & Lower trunk	Clarke's column → their axons are the largest in the entire CNS → ascend ipsilaterally & enters inferior cerebellar peduncle

* Remember that the nucleus dorsalis (of Clarke) is limited to $C_8 - L_2$ segments, then how afferents below L_2 reach this nucleus ??

2. Cuneocerebellar tract	Same afferents as the posterior sp. cerebellar tract but from UPPER LIMB	accessory cuneate nucleus (Rostro-lateral to cuneate nucleus in medulla) → axons ascend & enters ipsilateral inferior cerebellar peduncle

3. Anterior spinocerebellar tract (Exclusively Ib afferent from Golgi tendon organ)

↓

Along this pathway the cerebellum receive afferents from interneurons of spinal reflex arcs → Thus their function is to provide feedback to the cerebellum about on-going spinal reflexes

laminae V to VII

↓

axons cross in sp. cord → ascend in brainstem → cross again & enters cerebellum along superior cerebellar peduncle

1 + 2 + 3 → Carry Unconscious Proprioception

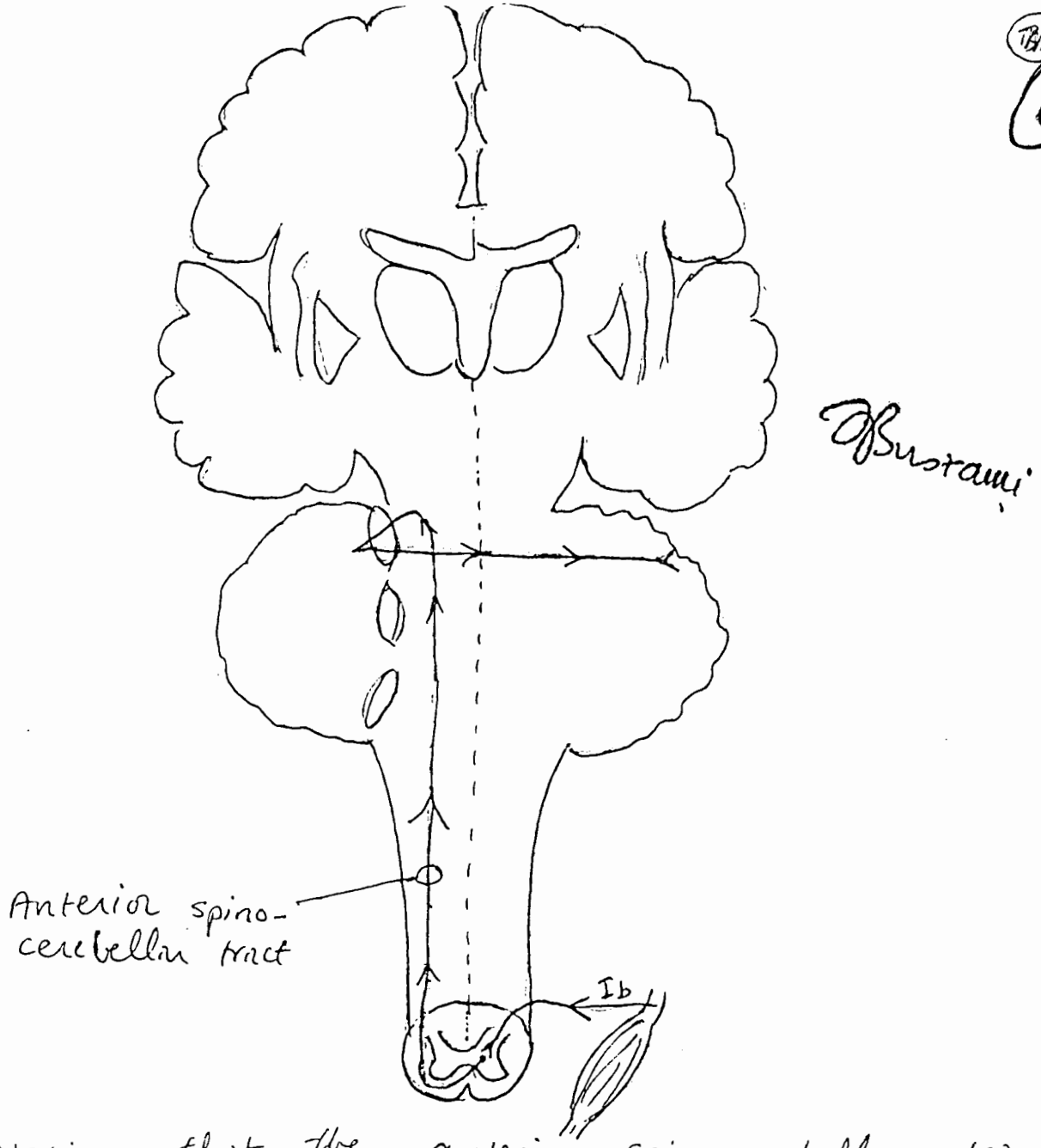

Notice that the anterior spinocerebellar tract undergoes double crossing, one in the spinal cord and another in the cerebellum-brainstem → This is in keeping with the known control by each cerebellar hemisphere of movements on its own side of the body (unlike the motor cortex which controls contralateral movement)

. of the organization of the flexion–crossed extension reflex.

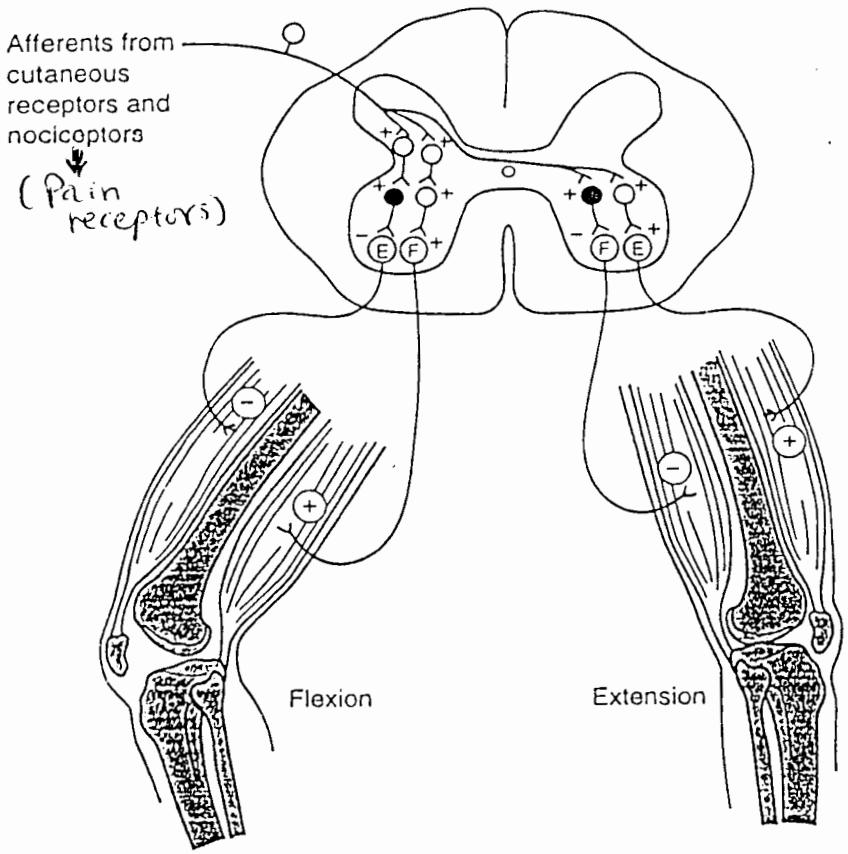

The flexion reflex is polysynaptic (Fig. 11-7). The afferent fibers enter the spinal cord and excite interneurons of the dorsal horn. The interneurons then act on alpha motor neurons through relay pathways involving other interneurons. The response is an excitation of alpha motor neurons to the flexor muscles and inhibition of alpha motor neurons to the extensor muscle of the stimulated limb (ipsilateral). In addition, this is frequently accompanied by excitation of alpha motor neurons to extensor muscles and inhibition of flexors to the contralateral muscle. This behavior is the appropriate response to painful stimuli; for example, if a person steps on a sharp object, the injured foot is withdrawn (flexion), while the other limb of the pair is extended, thereby providing support for the body and preventing the person from toppling.

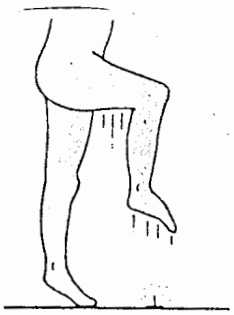

Fig. 10-3 Flexor reflex with crossed extensor thrust. The black internuncial is inhibitory.

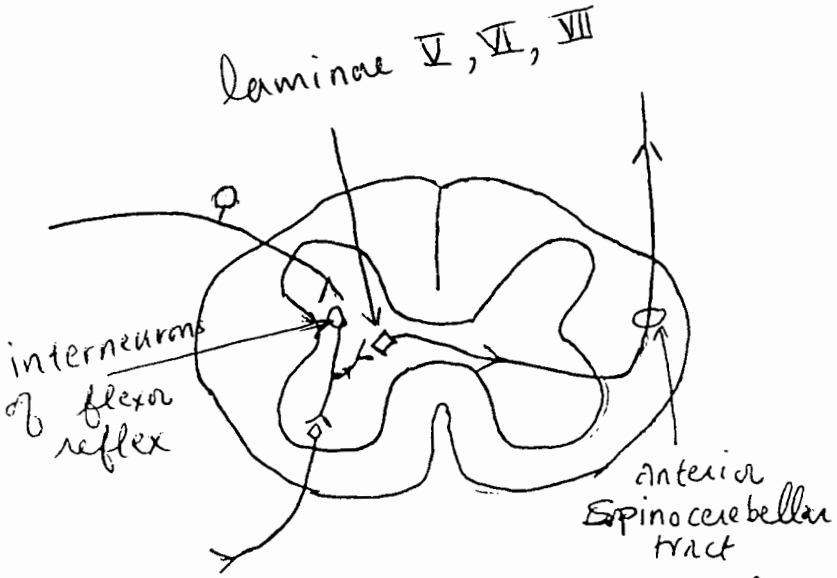

The transmission cells of the anterior spinocerebellar tract (in laminae V, VI, VII) receive afferents from interneurons of the flexor reflex → Their function is to provide feedback to the cerebellum about on-going spinal reflexes

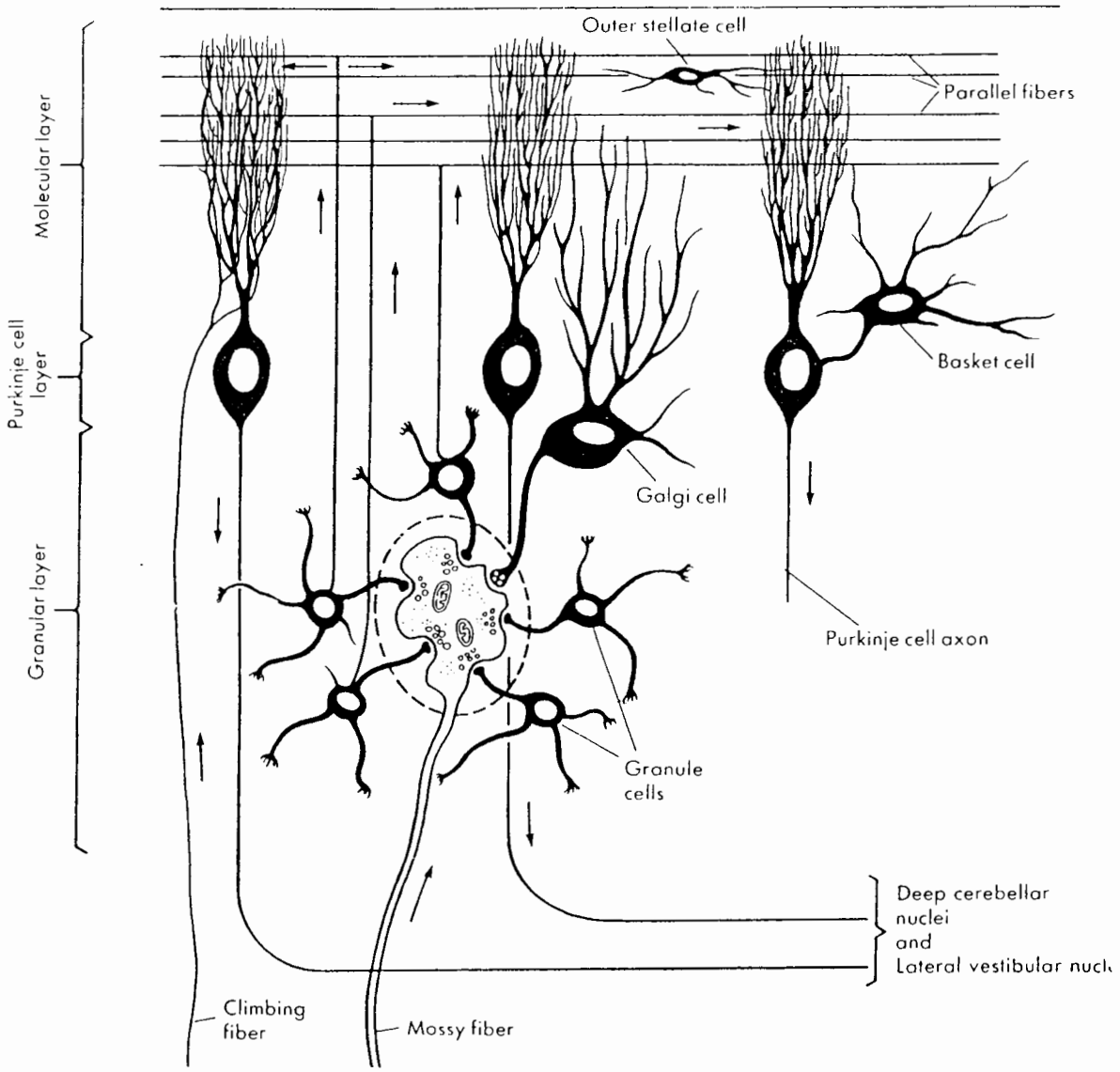
Outer stellate cell
Parallel fibers
Molecular layer
Purkinje cell layer
Granular layer
Basket cell
Galgi cell
Purkinje cell axon
Granule cells
Deep cerebellar nuclei and Lateral vestibular nucl
Climbing fiber
Mossy fiber

Bustami

9

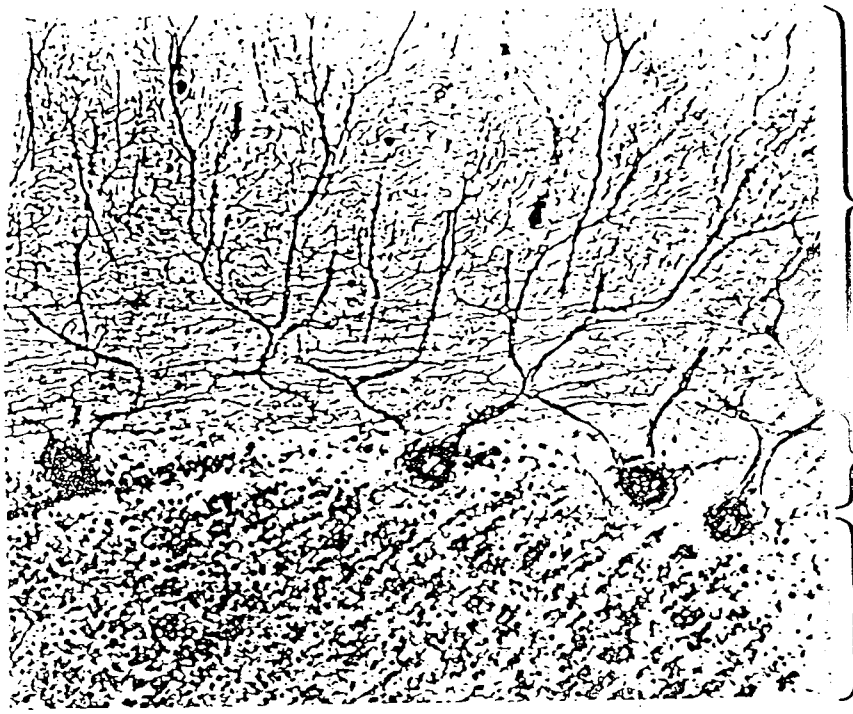

Molecular layer (outermost)

2 types of neurons < Stellate & basket cells

dendrites of Purkinje and Golgi type II cells

axons (T-shaped parallel fibres) of the granule cells

Purkinje cell (Midden layer)

their dendrites pass into the molecular layer

their long axons synapse upon deep cerebellar nuclei (or vestibular nuclei)

Granular cell layer (innermost layer)

numerous granule cells (neurons)

Golgi type II cells (neurons)

glomeruli*

Complex synaptic nodules which contain AXONS of incoming MOSSY FIBERS (vestibulo-cerebellar, spinocerebell. & corticopontocerebellar)

(+) AXONS & DENDRITES of Golgi type II a

(+) DENDRITES of granule cells

* a section through the cerebellar cortex. (Cajal silver stain, ×300.)

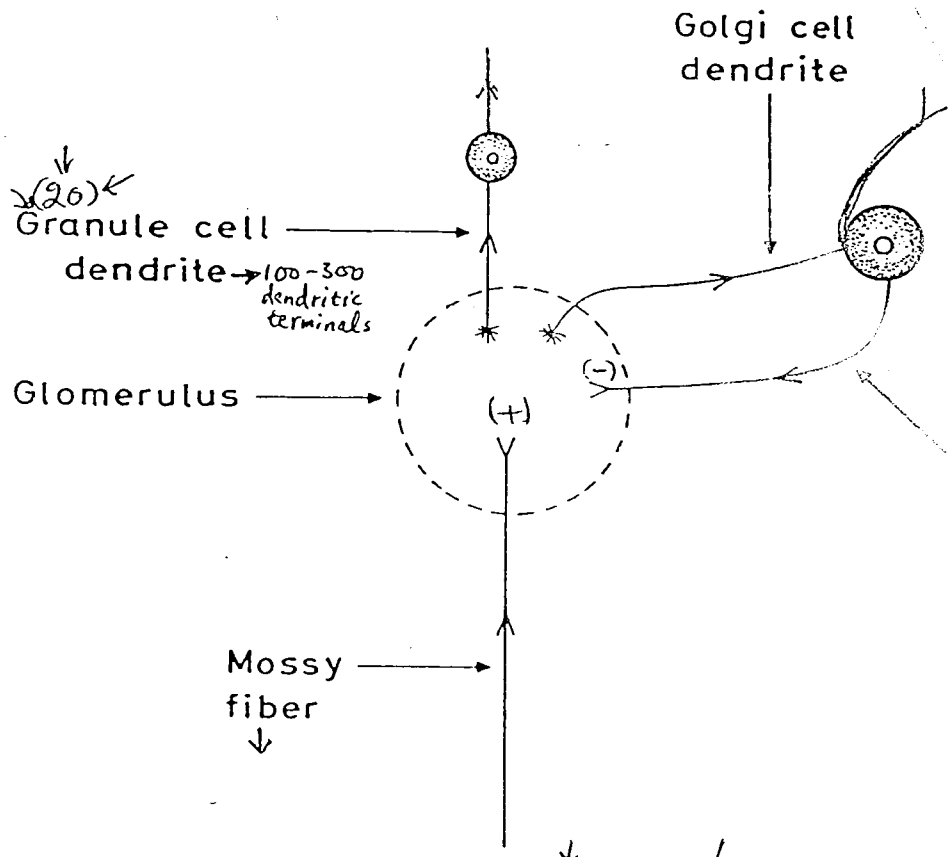

Figure 11.9. Schematic diagram of a cerebellar glomerulus showing the different sources of converging fibers.

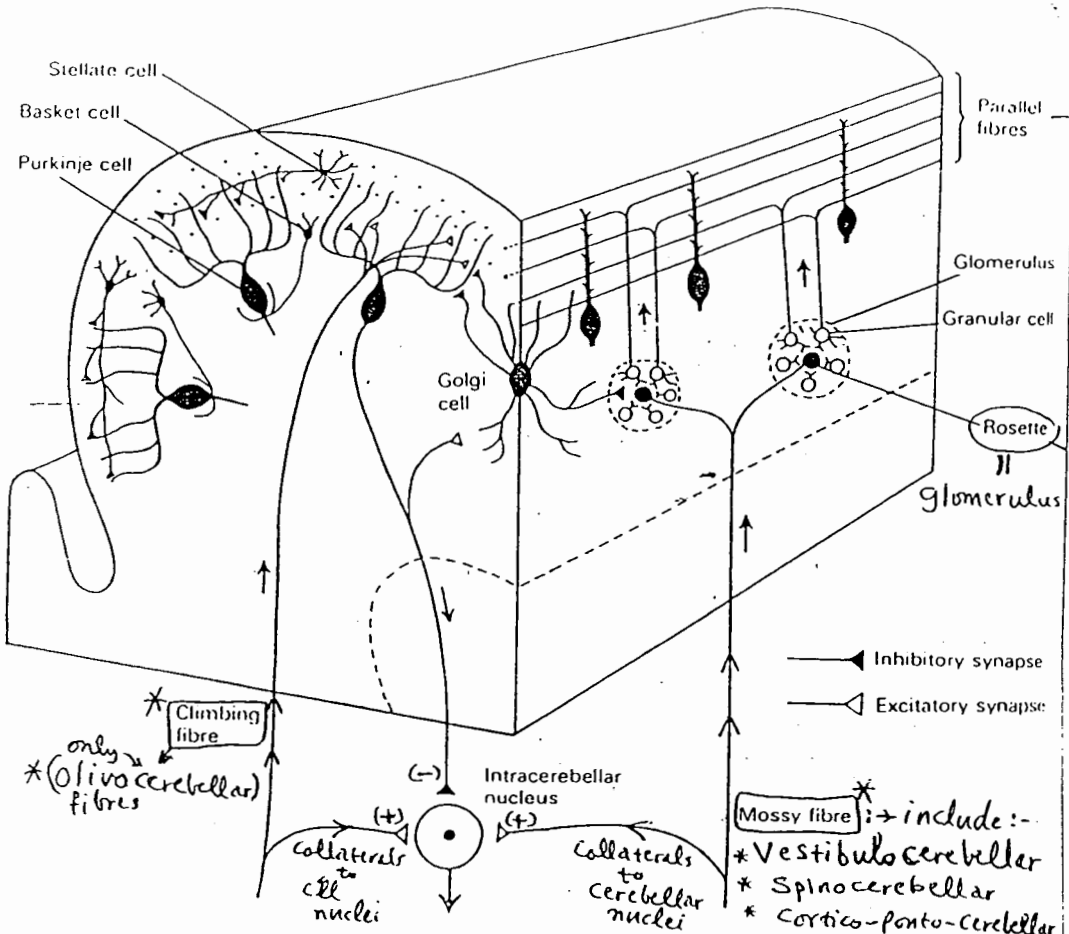

Fig. 7.7 Neuronal organization of the cerebellar cortex.

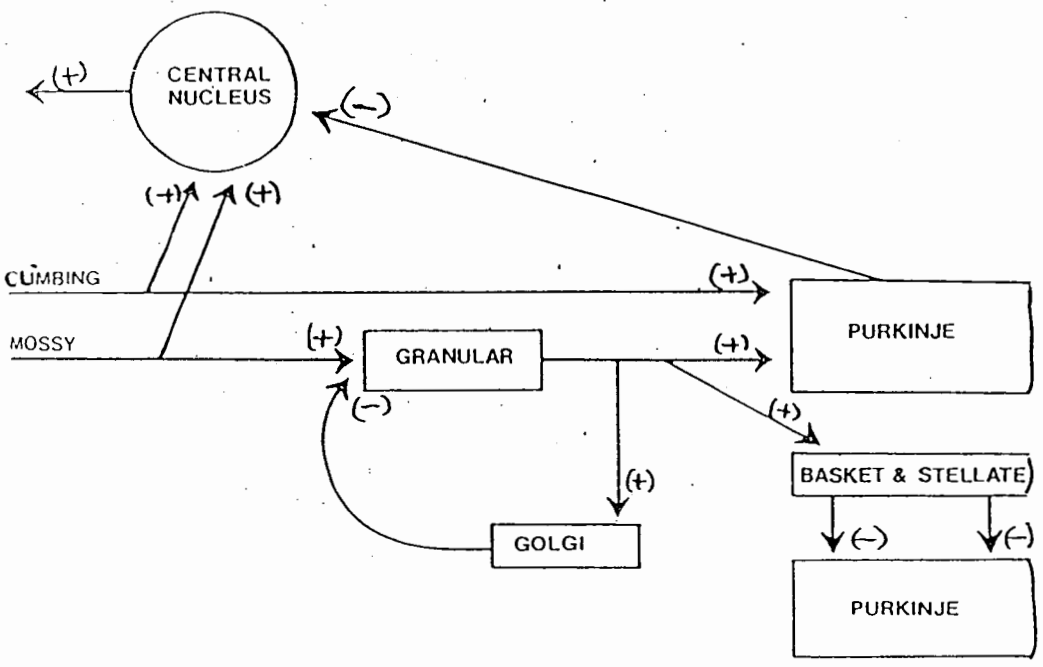

Fig. 7.8 Diagram of neuronal circuitry in the cerebellum: excitation is indicated in red (+) inhibition in black (−)

Afferents (input) to the cerebellum termina either in the granular cell layer (in the glomeruli as MOSSY FIBERS or upon the dendrites of Purkinje cells as CLIMBING FIBERS

⇓

Both inputs are excitatory

↓

Excited granule cell can excite Purkinje cells, basket and stellate, cells and Golgi type II cell.

↓

In turn the basket and stellate cells inhibit Purkinje cells.

- the Golgi type II cells inhibit granule cells

⇓

Finally the Purkinje cells (the bottleneck for all information coming out of the cerebellar cortex) are inhibitory to the deep cerebellar nuclei.

⇓ i.e

The cerebellar nuclei are subjected to initial Excitation (by incoming climbing and mossy fibres) which is followed after few milliseconds by inhibition (from Purkinje cells)

⇓

A balance between Excitation & inhibition normally exists keeping an output from cell nuclei (cerebellar)

The motor pathway (Motor cortex or brainstem nuclei) will receive an early excitation from cerebellar nuclei (which correct and modify the motor movement of the agonist), which is followed within a few milliseconds by excitation of the antagonists → To stop movement at the proper point ⇒ Damping ⇐

Connections of the Vestibulocerebellum (flocculonodular lobe)

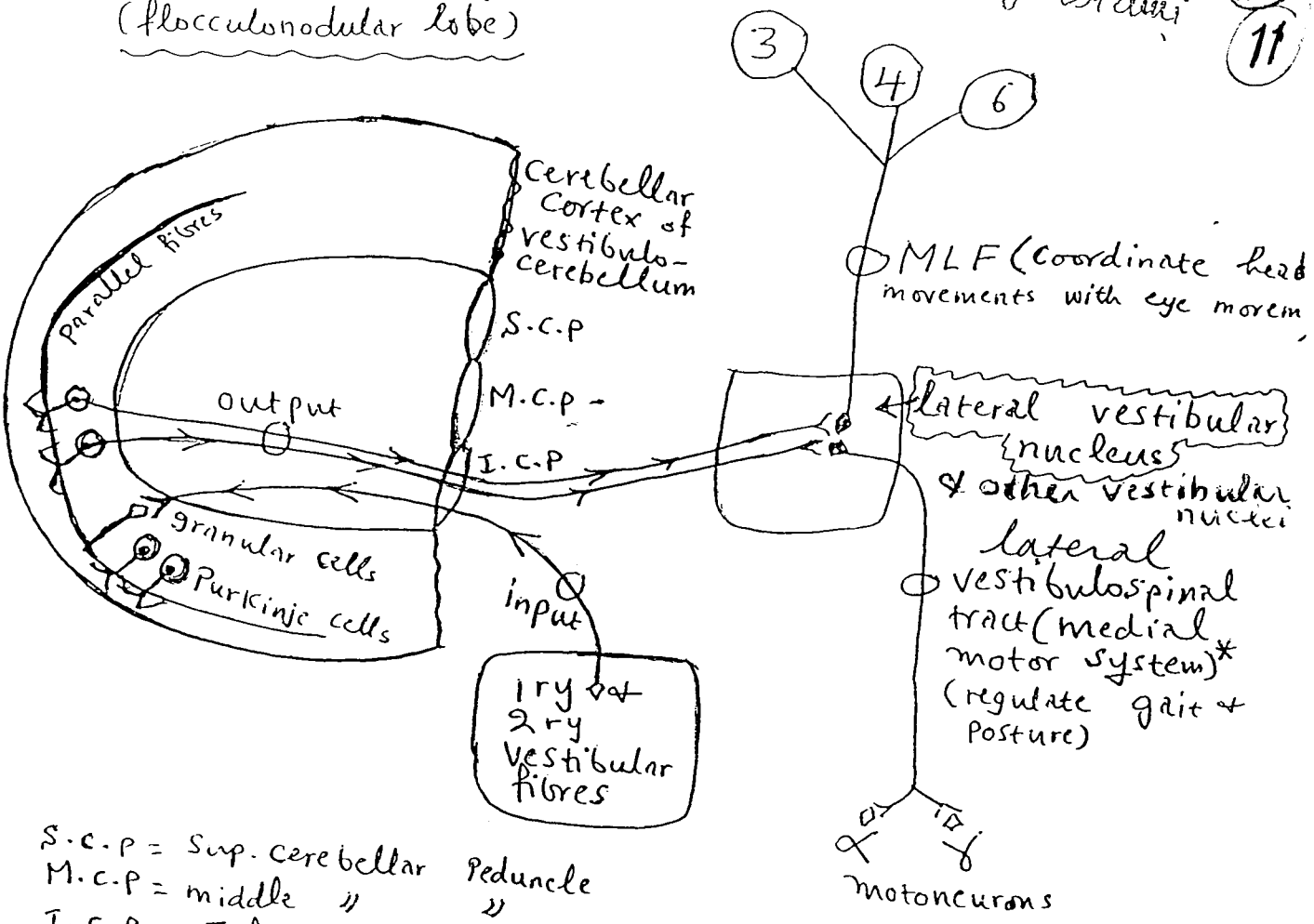

S.C.P = Sup. cerebellar Peduncle
M.C.P = middle " "
I.C.P = Inferior " "
MLF = (medial longitudinal fasciculus)

Input to the vestibulocerebellum (flocculonodular lobe)

Primary (from labyrinth) and secondary (from vestibular nuclei) vestibular fibres → Enter the cerebellum (mostly through Inferior cerebellar peduncle) and end as mossy fibres of the flocculonodular lobe → The mossy fibres synapse with granule cells (within the glomeruli) which in turn synapse with the Purkinje cells in the molecular layer of the cerebellar cortex

Output of the vestibulocerebellum

- The Purkinje cells of the vestibulocerebellum Project to the lateral vestibular nucleus (Exception to the rule) ???
- The lateral vestibular nucleus Sends down the lateral vestibulospinal tract (Part of medial motor system) which facilitates α & γ motoneurons that supply extensor muscles (gait & posture).

B Spinocerebellum — Vermis, paravermis

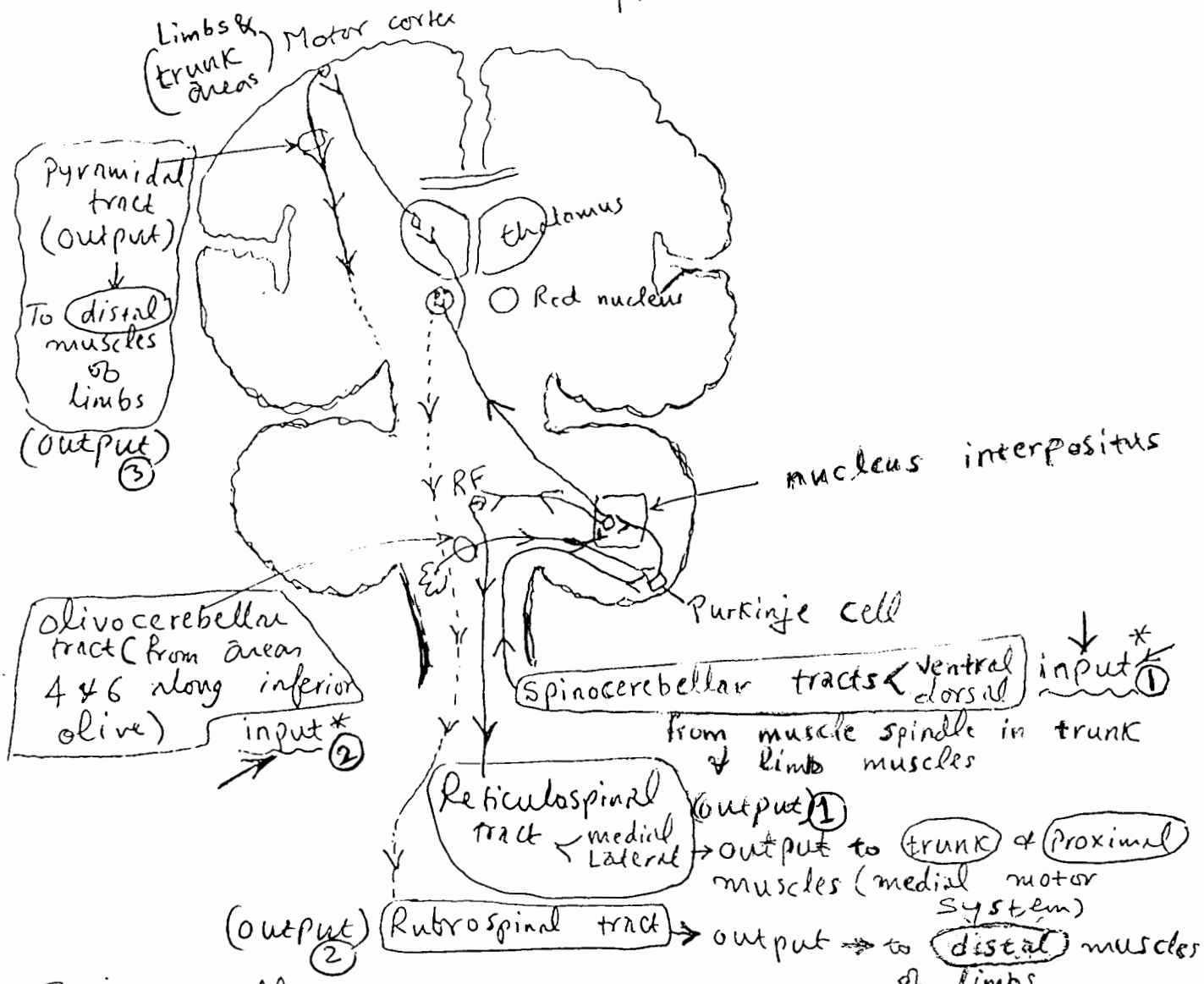

Spinocerebellum

input — Spinocerebellar tracts (1)
olivocerebellar : (cortico-olivo-cerebellar tract) (2)

Output (from nucleus interpositus)

To RF (reticular formation) → Reticulospinal tracts
= Red nucleus → Rubrospinal tract
To thalamus → motor cortex area (4) (6) → Pyramidal tract

Spinocerebellum functions in the regulation of axial (trunk), Proximal & distal muscles of Ipsilateral

it controls, SYNERGY (coordination) among muscles (especially coordination between agonist and antagonist)

↓

(1) it Receives input from Receptors in muscles & joints about **actual** performance (movement)

(2) it Receives input from cerebral cortex about **intended** performance (movement)

↓

it Compares the 2 inputs and when needed → Sends Corrective signals that control **RATE**, **RANGE**, **FORCE** & **DIRECTION** of movement

↓

The corrective signals reach muscles along

- **Pyramidal tract** → i.e Lateral motor system → To distal muscles
- **Reticulospinal** → medial motor system → To axial & Proximal muscles
- **Rubrospinal** tracts → lateral motor system → distal muscles

N.B The **Spinocerebellum** and **Vestibulocerebellum** affect the motor act while it is in progress i.e they affect actual movement

Input of Cerebrocerebellum

(17)

CORTICO-PONTO-CEREBELLAR tract

from 4, 6, (3,1,2), (5,7) & ASSOCIation cortex

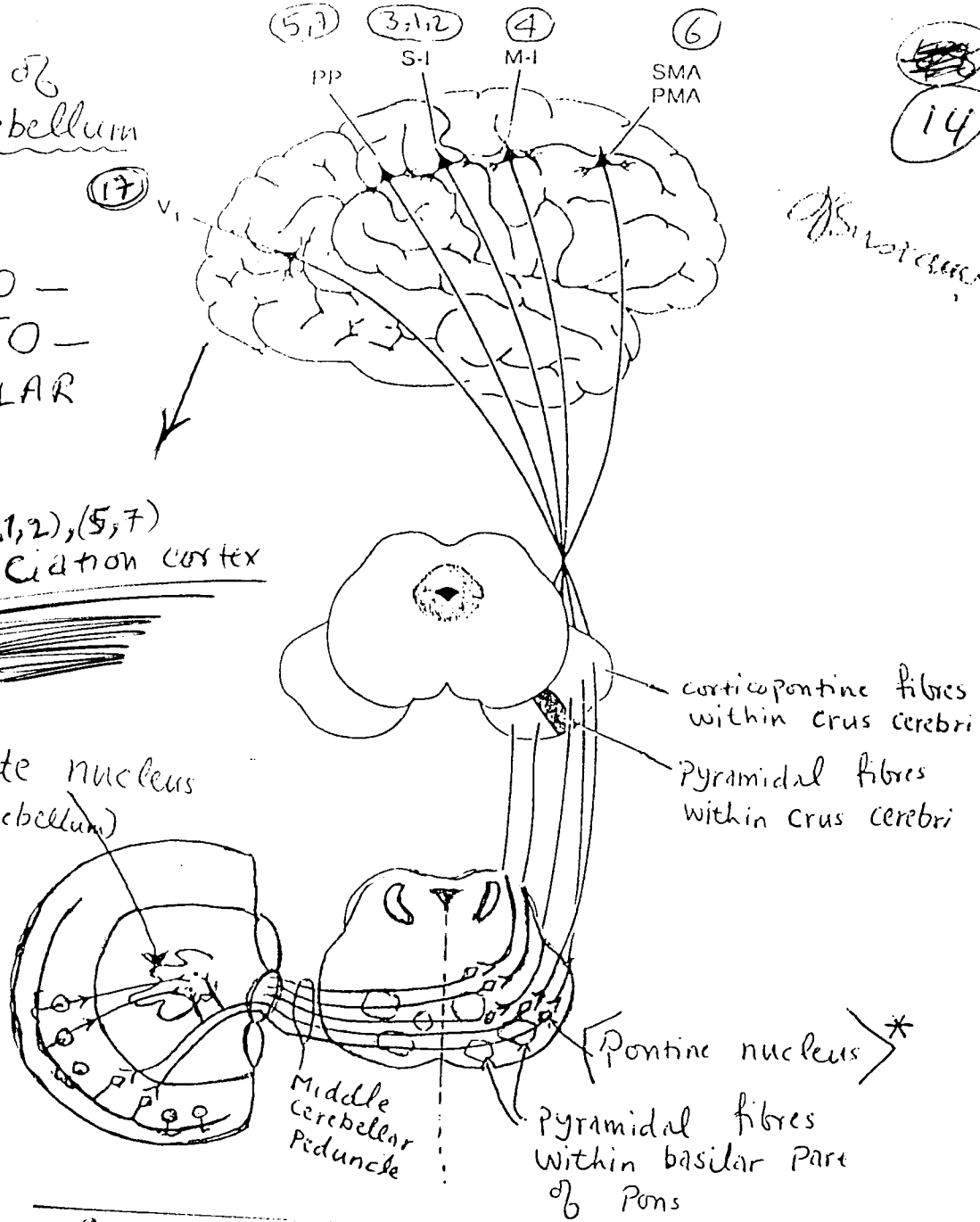

The deep pontine nuclei receive afferent fibers from most parts of the cerebral cortex. *PMA*, premotor area; *SMA*, supplementary motor area; *M-I*, primary motor cortex; *S-I*, primary somatosensory cortex; *PP*, posterior parietal cortex; *V1*, primary visual cortex;

Notice → the Middle cerebellar Peduncle (M.c.p) is formed by the axons of Pontine nuclei (20 million axons) of the opposite Side → enter the cerebellum and end as Mossy fibres of the cerebrocerebellum → (send collaterals to the Dentate nucleus and end by synapsing with granule cells which in turn synapse by the Purkinje cells) *

Bustami

42
15

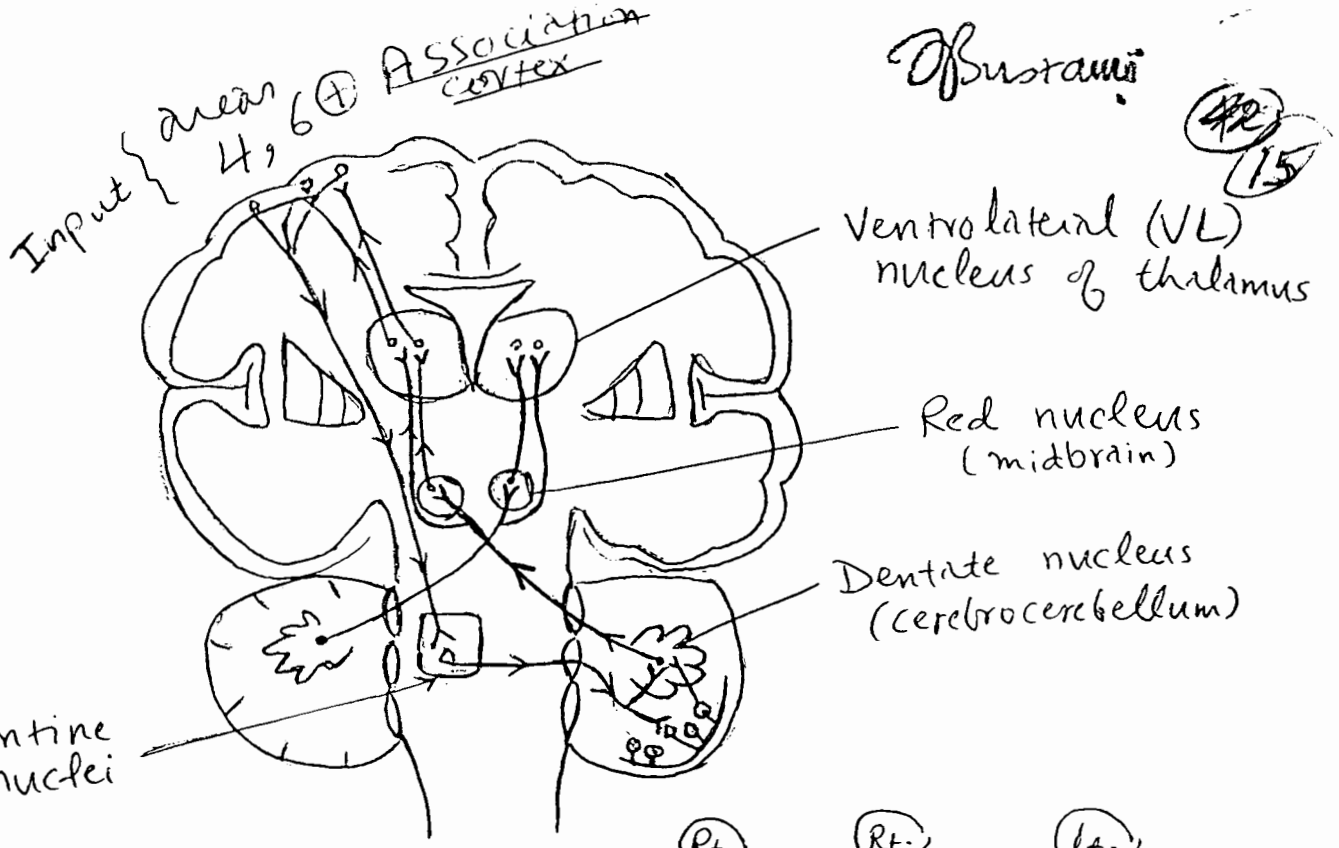

* Input of cerebrocerebellum — Cortico (Rt.) → Ponto (Rt.) → Cerebellar (Lt.) tract
(synapse)

* Output of cerebrocerebellum

(Lt.) Dentato → (crossing of sup. cerebellar peduncles) → Rubro (Rt.) ⟹ thalamo (Rt.) → cortical (Rt.) tract → areas 4, 6

Dentate nucleus in cerebrocerebellum

Some fibres synapse within the red nucleus, others, run around it forming capsule of red nucleus

VL nucleus of thalamus

* Functions of cerebrocerebellum — ~~Regulation of ballistic movement~~ planning, initiation & timing of sequential movement

* The cerebrocerebellum receives information from primary motor area, Premotor & Supplementary motor areas (concerning the motor command that is about to be executed i.e about intention movement) and from the sensory areas of the parietal lobe (about the postural state of the body) ⟹ The output from the cerebrocerebellum feeds back to the red nucleus and the primary motor cortex where it can affect the motor command BEFORE THE EXECUTION of THE COMMAND → Thus the cerebrocerebellum is arranged to act like a FEED-FOREWARD CONTROL SYSTEM (This is in contrast to the vestibular and spinal divisions of the cerebellum which act as typical feedback control systems → The output from the vestibulocerebellum and spinocerebellum affect the motor act while it is in Progress i.e affect actual movement

Lesions to the cerebellum DO NOT produce Paralysis. Without the cerebellum, however, precise, coordinated movements are impossible →

These observations suggest that the cerebellum acts as a REGULATORY SYSTEM that modifies motor acts initiated by other regions of the CNS

↓

Deficits associated with lesions of the cerebellum can be grouped into 3 main classes:

Disturbances of < Synergy = Asynergia
equilibrium
tone

* Asynergia or impaired coordination results from errors in RATE, FORCE, RANGE & DIRECTION of movements. Asynergia can manifest itself in a number of ways

* Lesion of Vestibulocerebellum → ① Disturbance of equilibrium (inability to maintain upright posture)

⊕ a ② staggering ataxic gait with a tendency to fall toward the side of the lesion

⊕ ③ NYSTAGMUS (spontaneous oscillating eye movements in which the eyes move slowly in one direction and rapidly in the other (jerky eye movement when fixing the gaze on an object).

- nystagmus reflects asynergia of the extrinsic eye muscles

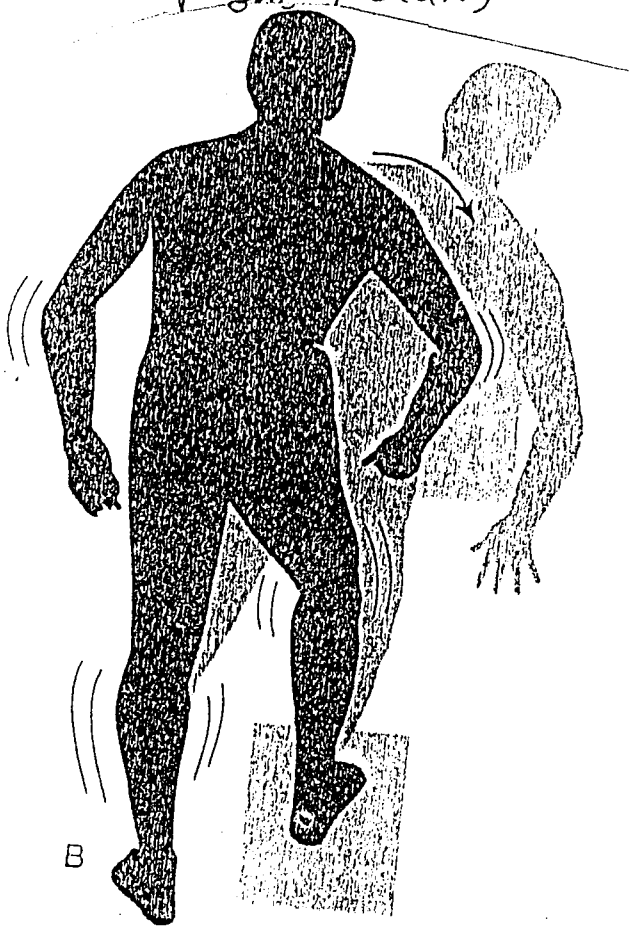

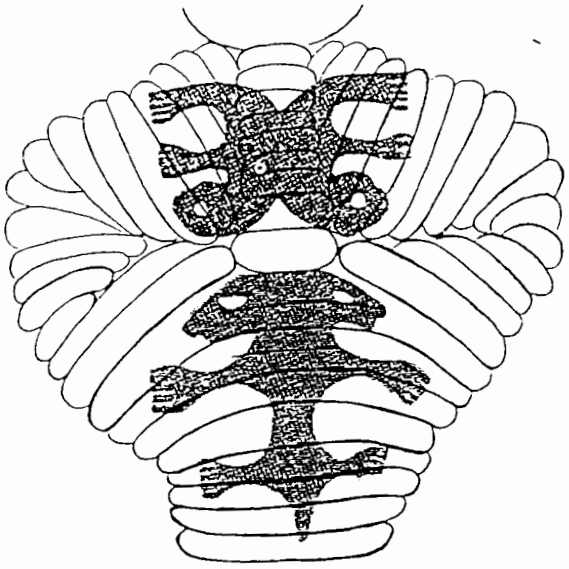

Topographic representation of the body in the cerebellum

There are two separate representations. In the anterior lobe the body is represented upside down, while it is erect in the posterior lobe. The axial portions of the body lie in the vermis (Fig. 17.68) whereas the limb and facial regions lie in the intermediate zones. Obviously, the lateral zones would have no topographic representations of the body as these areas have different functions, i.e. planning and co-ordination of sequential patterns of muscular activity.

The Cerebellum is called the Silent area !!
comment → Stimulation of cerebellum does not give rise to any Sensation & causes almost no motor movement



Often
The condition is seen in young children with → medulloblastoma arising in the roof of the 4th ventricle
↓
In severe cases it is impossible for the patient to sit or stand without falling
↓
The patient has no control over the axial muscle & hence attempts to walk on a wide base with the trunk constantly reeling & swaying

Flocculonodular lobe syndrome: Truncal ataxia. Standing on wide base and reeling from side to

Lesions of the spinocerebellum & cerebrocerebellum are difficult to differentiate → There is difficulty in initiation, Execution & termination of movement.

The clumsy movement is called Cerebellar ataxia

18

(Signs of Spinocerebellar and Cerebrocerebellar injury)

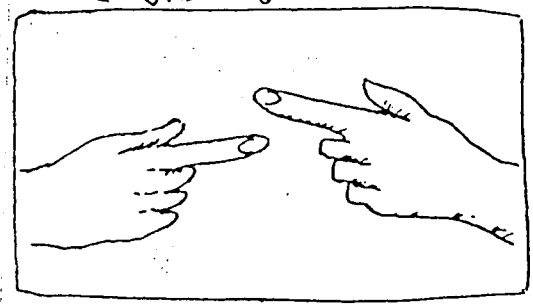

DYSMETRIA → hand overshoots mark (errors in direction & force of movements).
- limb overshoot → hypermetria
- " under " → hypometria

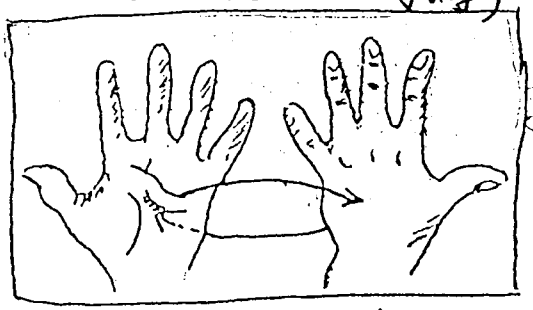

DYSDIADOCHOKINESIA → difficulty in performing rapid alternating movements e.g Supination & Pronation

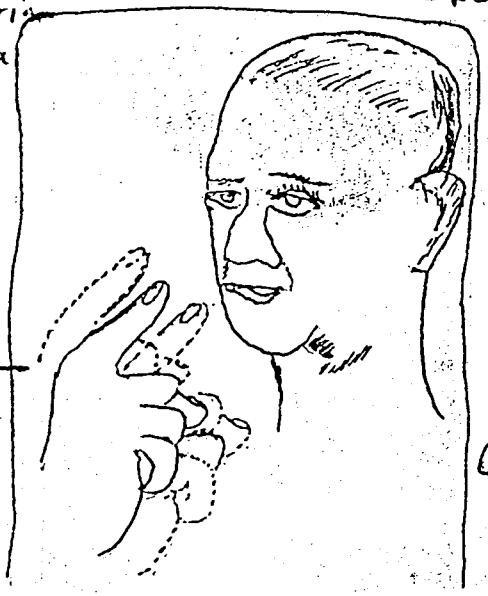

INTENTION TREMOR e.g finger-nose test

- evident during Purposful movement
- worst at the end of movement
- absent during rest
- Mostly follow a lesion involving the S.C.P
- due to defective feedback control from cerebellum on cortically-initiated movement.

Dysmetria & Dysdiadochokinesia ⟹ are the result of absence of Proper TIMING in (initiation) and (termination) of movements e.g a delay in the (termination) of movements produced by a delay in the intervention of the antagonistic muscle to check the movements results in dysmetria-and overshooting. A delay in (initiation) of each successive movement will lead to dysdiadochokinesia

* Remember that intention tremor appears during movement as a result of cerebellar disease while rest tremor (Pill-rolling, Nodding) is the result of disease in the basal ganglia and related nuclei

HYPOTONIA ⊕ Pendular stretch reflex

insufficient signals are sent via the dentato thalamo cortical system to the motor cortex resulting in inappropriate control of γ-neurons via the descending motor pathways

↓

A deficiency in tonic stretch reflex

↓

hypotonia ⊕ pendular jerk

SPEECH

↓

DYSARTHRIA

↓

* Speech is slurred & explosive with a telegram-staccato space (pauses in the wrong places)
* is the result of the incoordination of the muscles used in speaking i.e ataxia of respiratory & laryngeal muscles

GAIT → Wide-based & unsteady (Sailors walk)

Pendular reflexes & hypotonia are related signs → they reflect REDUCED FACILITATION of γ-motoneurons → muscle tone is reduced because the decreased facilitation of the γ-motoneurons is reflected in a decreased facilitation of the α-motoneurons → with less resting muscle tone → less resistance to passive movement after the initial stretch reflex contraction i.e the leg swings back & forth like a pendulum because of its own mass & not because of active muscle contraction

The term **ataxia** is used clinically for incoordination of gait عدم اتزان which appears as staggering ترنح

(a) **Sensory ataxia** → caused by disease of the dorsal column of spinal cord. The patient staggers because he cannot perceive the position or movement of his legs, in other words he lacks conscious proprioception → to compensate he uses visual guidance

(b) **cerebellar ataxia** → The patient staggers because the cerebellum is unable to coordinate the muscles of walking e.g alcoholic intoxication. Visual guidance cannot compensate

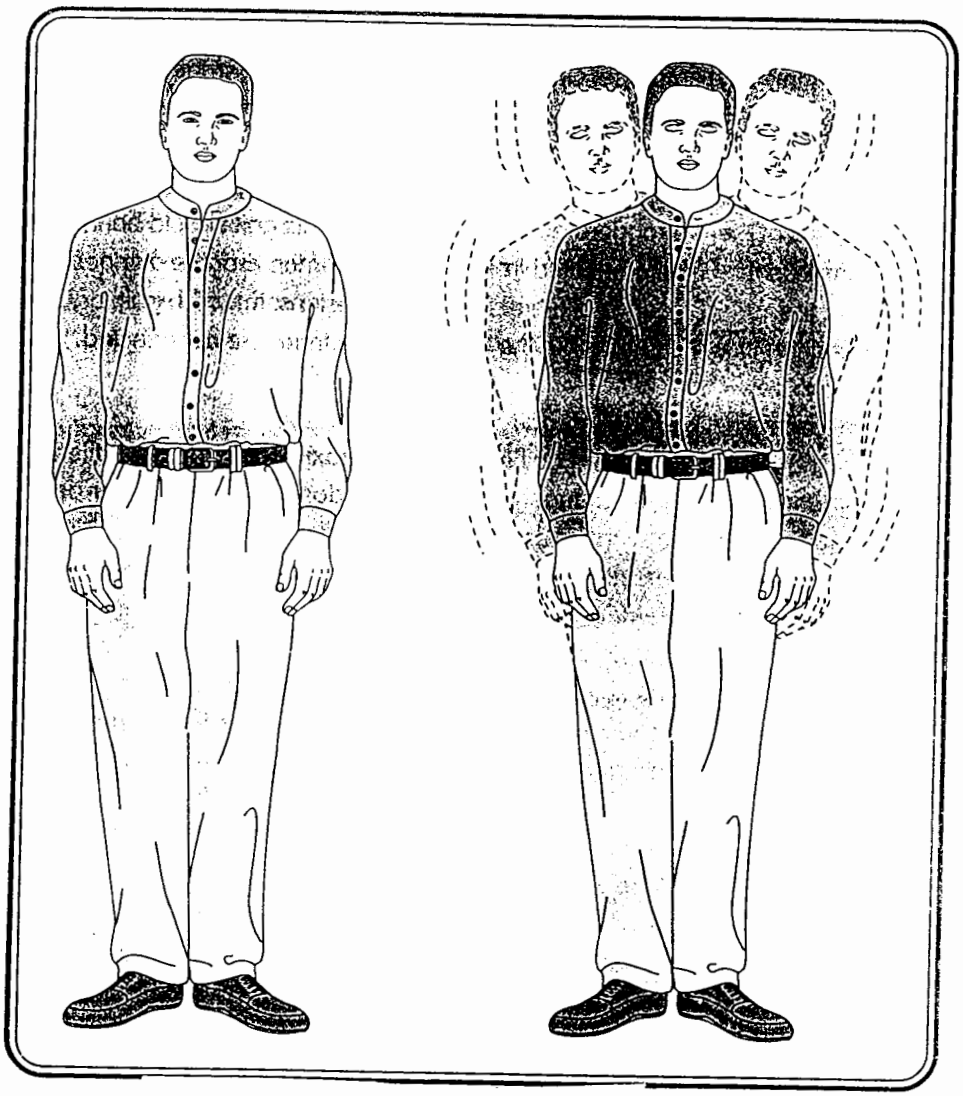

20

Romberg's test

To perform Romberg's rest, ask the patient to stand with his or her feet together and assess his or her stability. Next, ask the patient to close his or her eyes, making sure that you will be able to support him or her if he or she falls (Fig. 12.8).

Vestibular
cerebellar
Ataxia ← Sensory

Patients with cerebellar or vestibular lesions are usually ataxic on a narrow base with their eyes open. Their ataxia might get marginally worse when the eyes are closed. Patients with propioceptive sensory loss ↓

(patients with sensory ataxia
→ lesion in dorsal column - medial Lemniscus system)

might be slightly ataxic on a narrow base with their eyes open, but they fall when they close their eyes (positive Romberg's test).

Remember that in Sensory ataxia the patient staggers because he cannot perceive the position or movements of his legs (he lacks Conscious proprioception). In cerebellar ataxia the patient staggers because the cerebellum is unable to coordinate the muscles of walking

* He Cannot compensate by visual guidance

Damping function of the cerebellum

Essentially all voluntary movements being performed develop MOMENTUM (force keeping it moving) which would cause OVERSHOOTING of the movements beyond the intended point (ie Pendular movement)

To overcome this → the cerebellum sends appropriate signals which stop the movement at the required point and prevent overshooting

If the cerebellum is damaged → overshooting occurs → The cerebral cortex recognizes the overshooting and initiates a movement in the OPPOSITE direction to bring the moving part, for example the arm, to the intended point

But due to its momentum → the arm again overshoots and correcting signals are again sent from the cortex

Thus the arm Oscillates beyond the point of intention several times before it settles on the intended point

This forms the basis of the Kinetic or intention tremors of the spino cerebellar & cerebro-cerebellar Syndromes



Uncoordinated, clumsy movements of lower limbs

Anterior lobe syndrome: Gait ataxia. Clumsy movements of lower limbs.

23

Anterior lobe syndrome

Commonest cause → malnutrition accompanying CHRONIC ALCOHOLISM

→ results in damage to Purkinje neurons

→ Patients suffer the loss of coordination chiefly in the lower limb

→ have marked gait instability

→ walks as if drunk

→ Heel-shin test: sliding the heel of one foot smoothly down the shin of the other leg → extremely difficult

→ If degeneration progresses posteriorly → upper limbs & speech may also be affected

Bustami

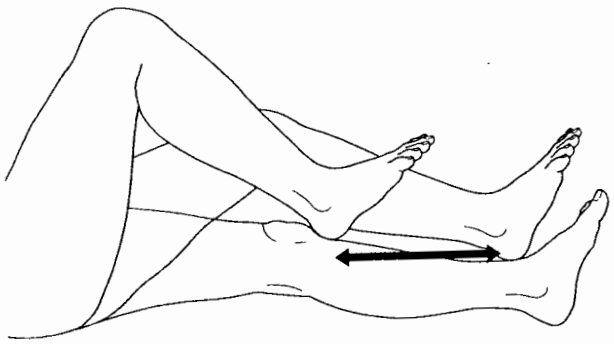

Chronic alcoholic

Marked gait instability

walks as if drunk

may show intention tremors

may show staccato speech

} late signs

Fig. 8.50 Performing the heel–shin test with the right leg.

Anorami

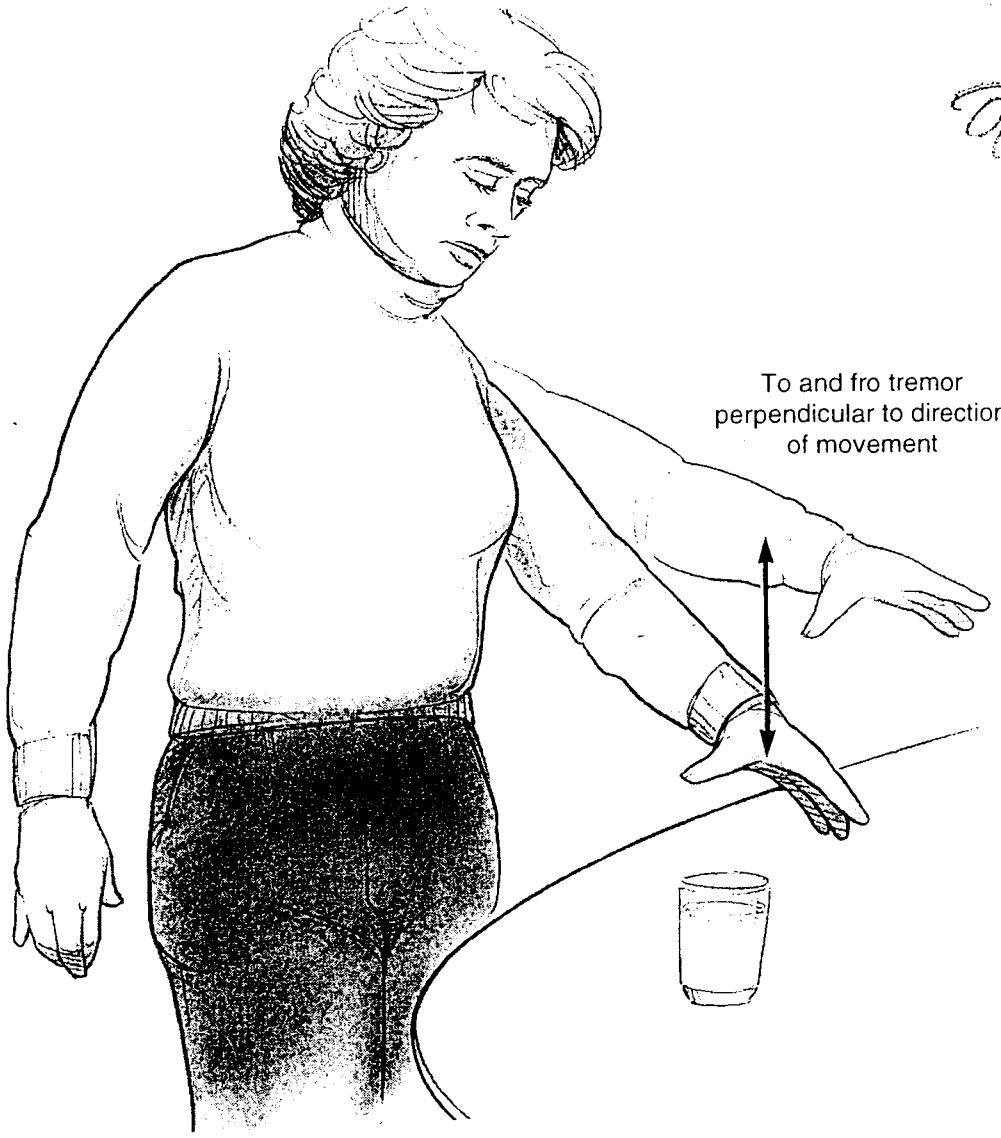

Posterior lobe syndrome (neocerebellar syndrome)

commonly results from CVA tumours, trauma or degenerative disease

manifested by Loss of Coordination of Voluntary movement
→ **ATAXIA** ⊕ decreased muscle tone (in acute lesions)

– (Rate) (Range) (Force) (direction) of movements are ABNORMAL

↓

The ataxic patient is unable to direct the limb to a target without its progression being interrupted by by a swaying to & fro movement that is perpendicular to the movement → This is referred to as (intention tremor)* (absent at rest)

– other manifestations of (Post-lobe Syndrome)
- dysmetria
- dysdiadochokinesia
- speech disturbance