C-SHAPE **TRACHEA**-
transeverse section

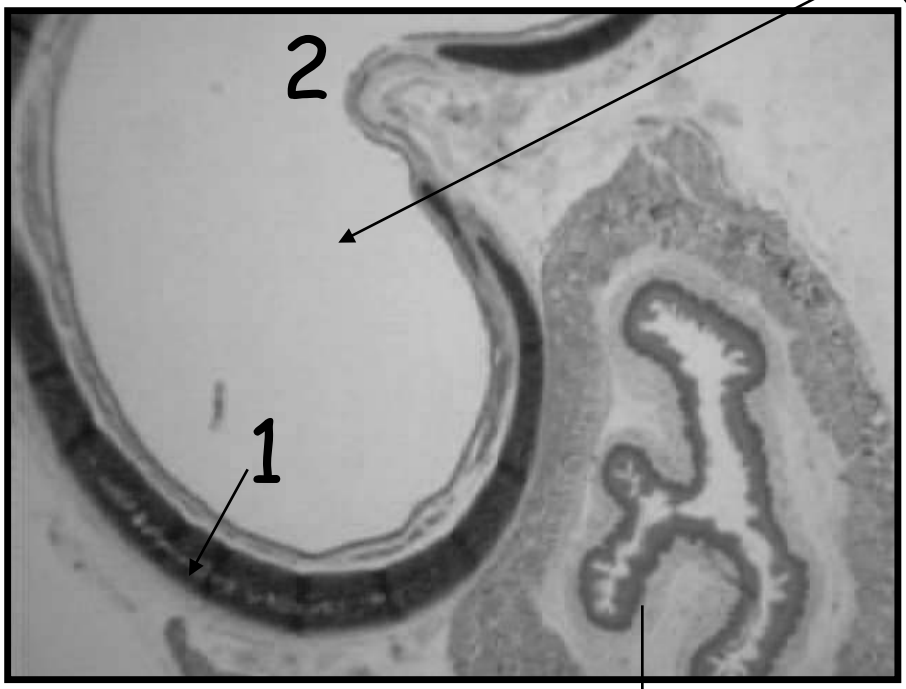

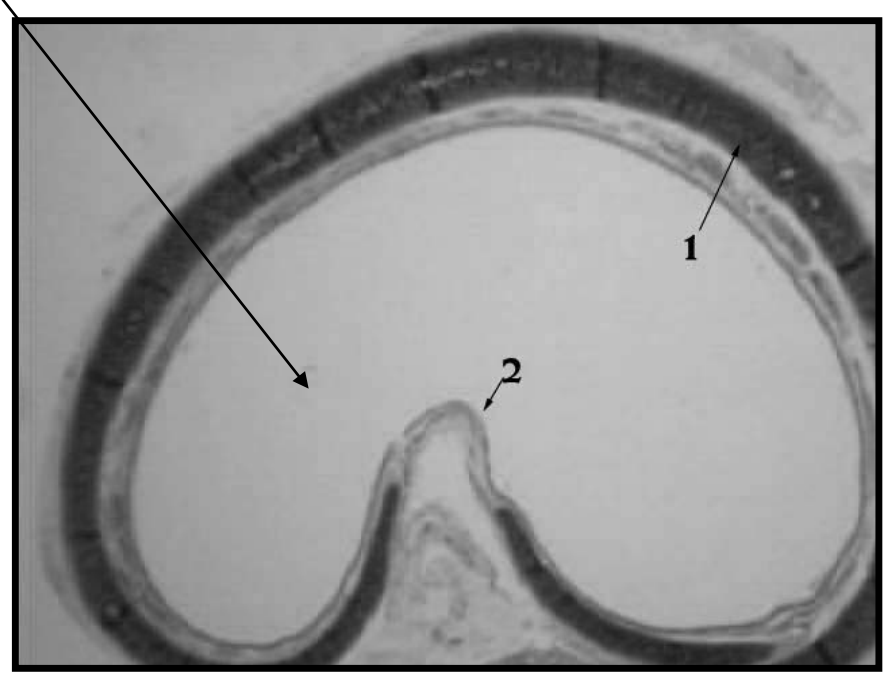

ESOPHAGUS-
posteriorly

TRACHEALIS (SMOOTH) MUSCLE

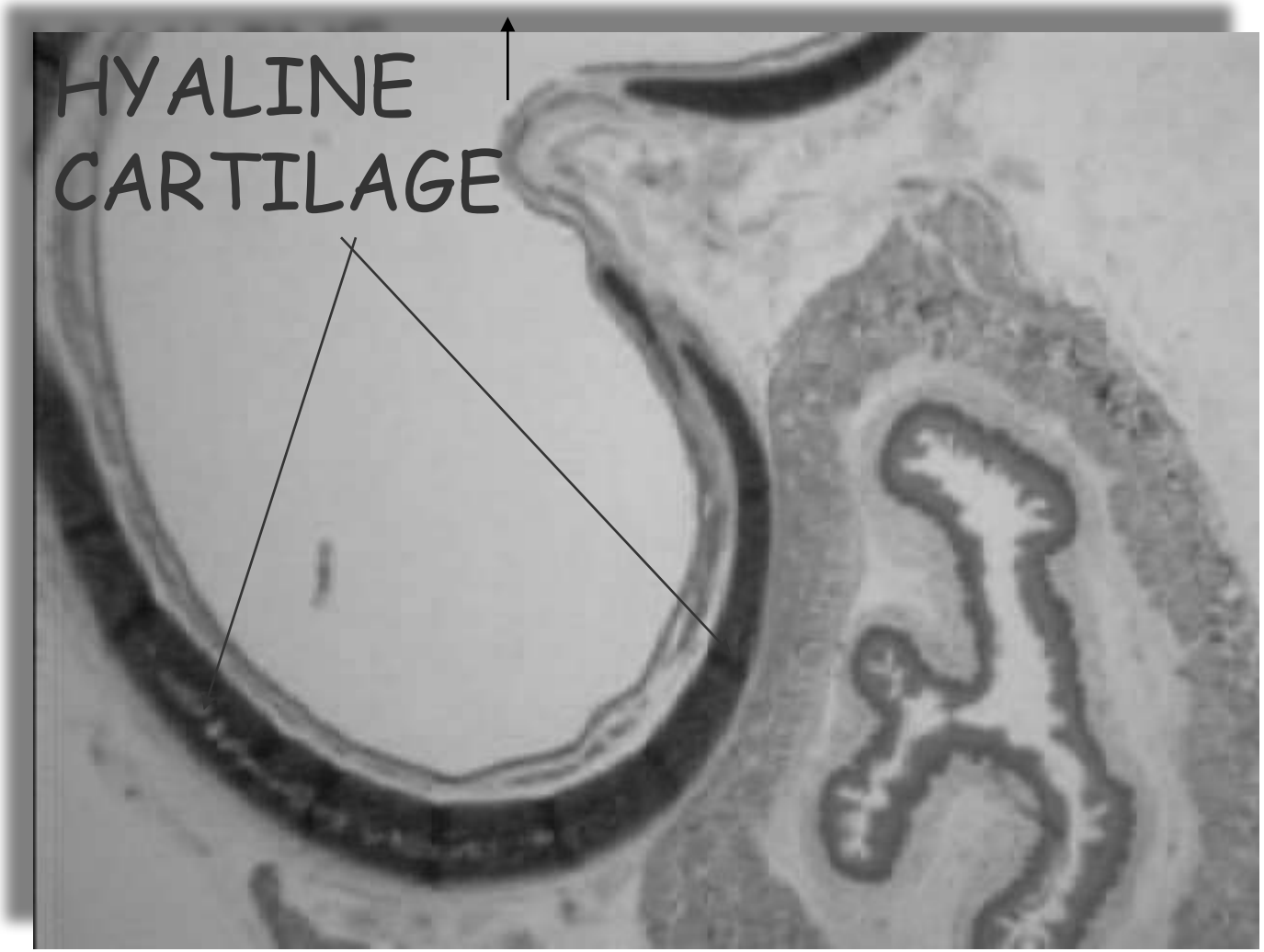

MUSCLE TRACHEALIS (SMOOTH)

MUCOSA ,SUBMUCOSA,CARTILAGE.ADVENTITIA

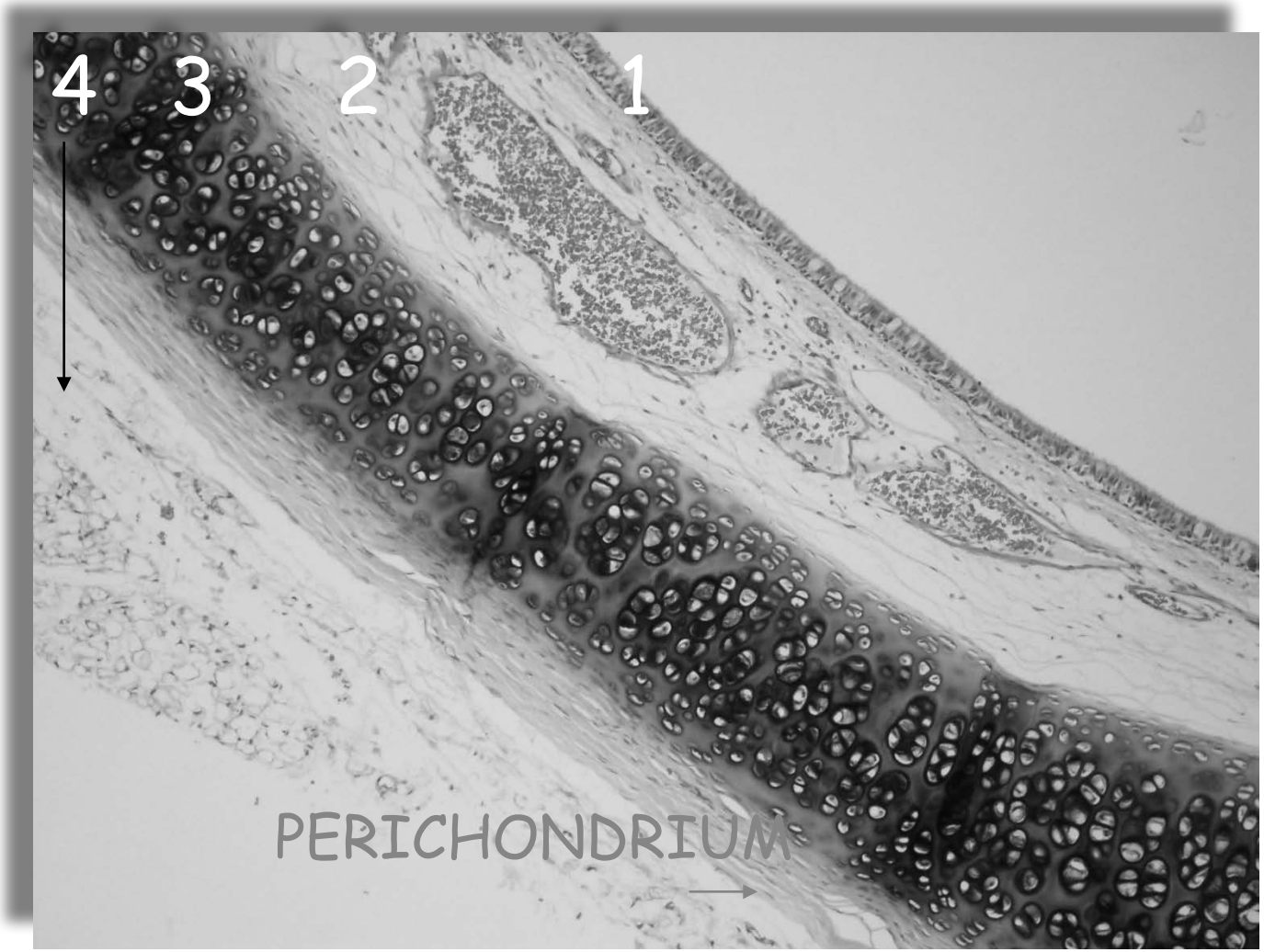

RESPIRATORYEPITHELIUM TRACHEAL GLAND IN SUBMUCOSA

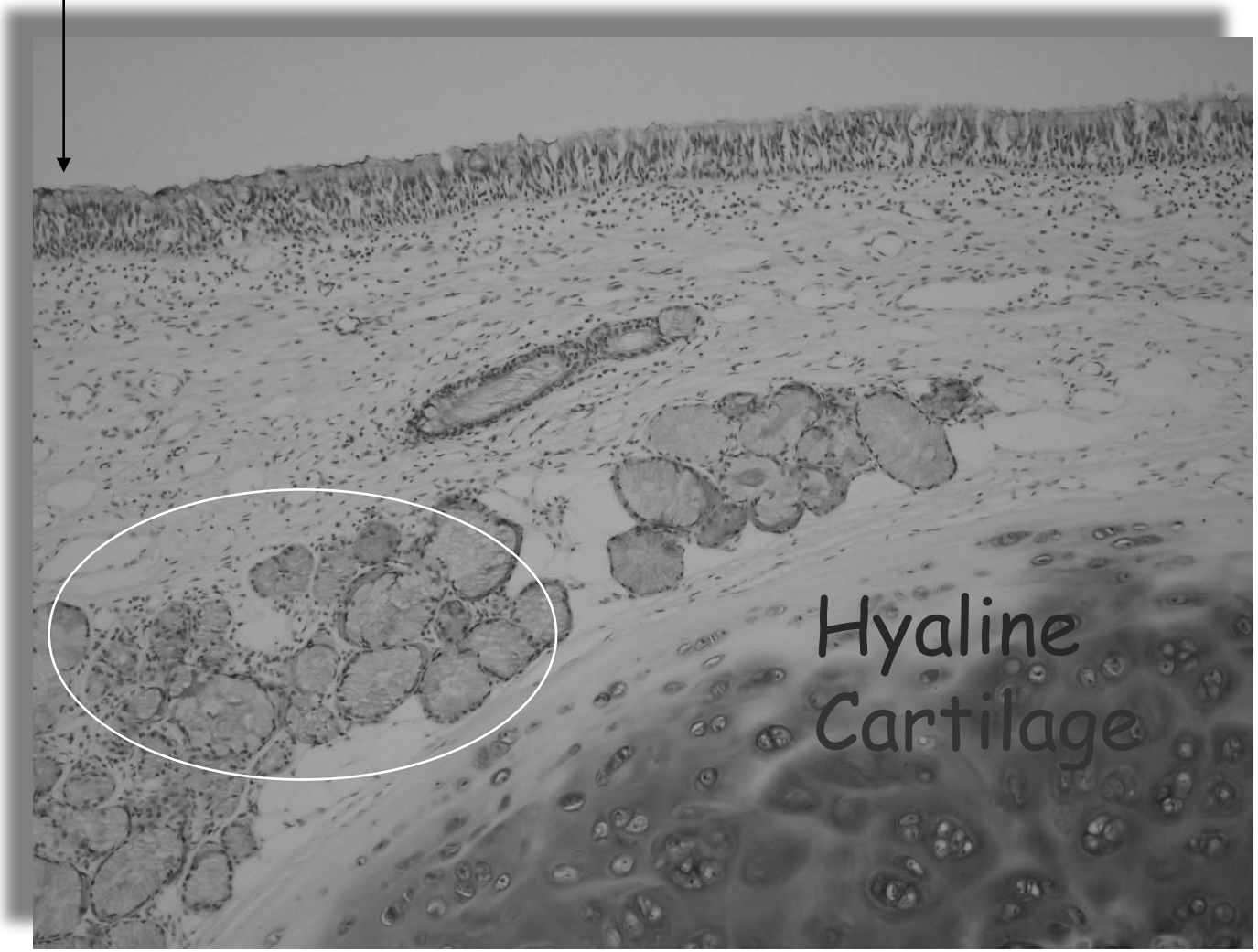

Branched seromucous gland

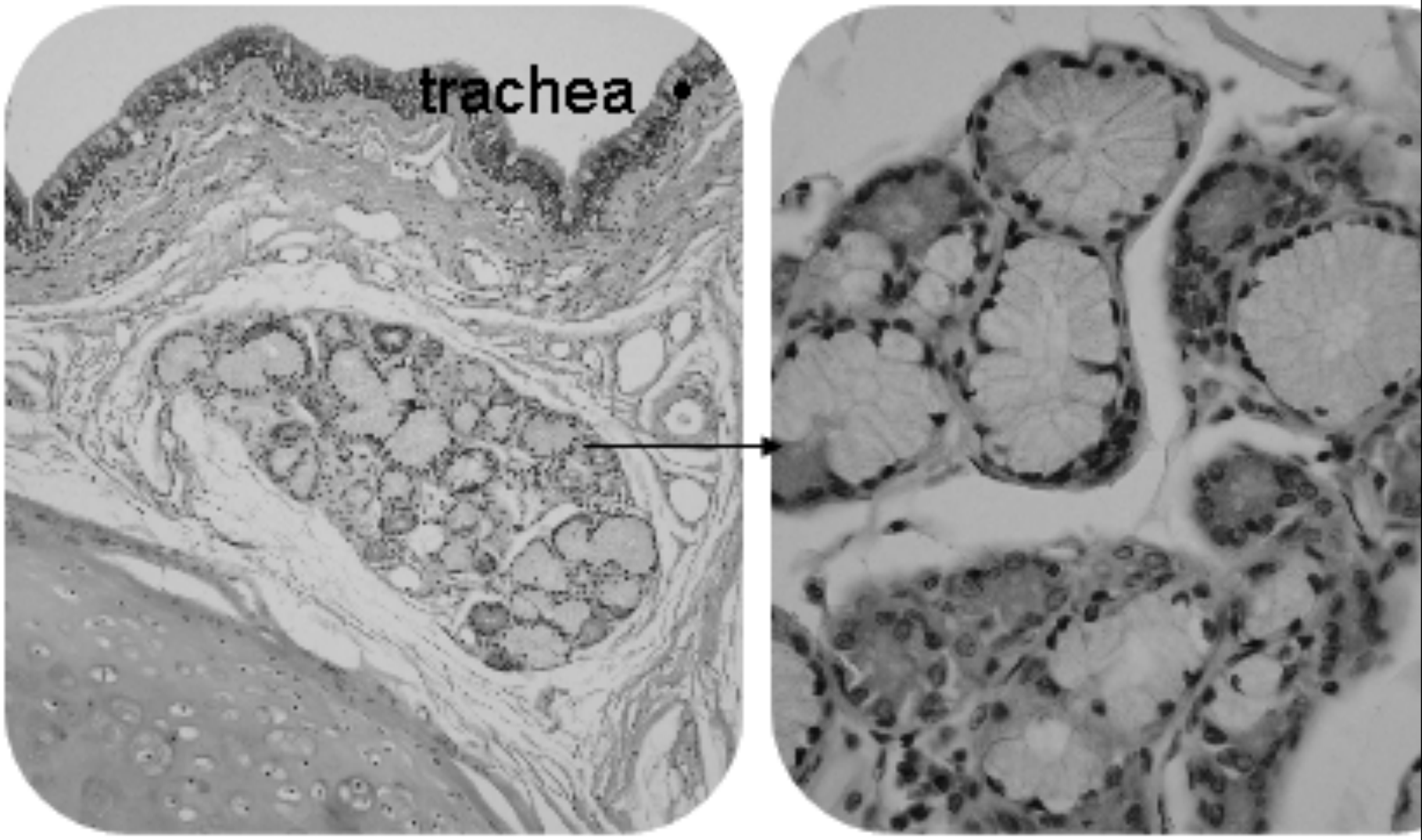

ADVENTITIA

BASEMENT MEMBRANE

GOBLET CELL

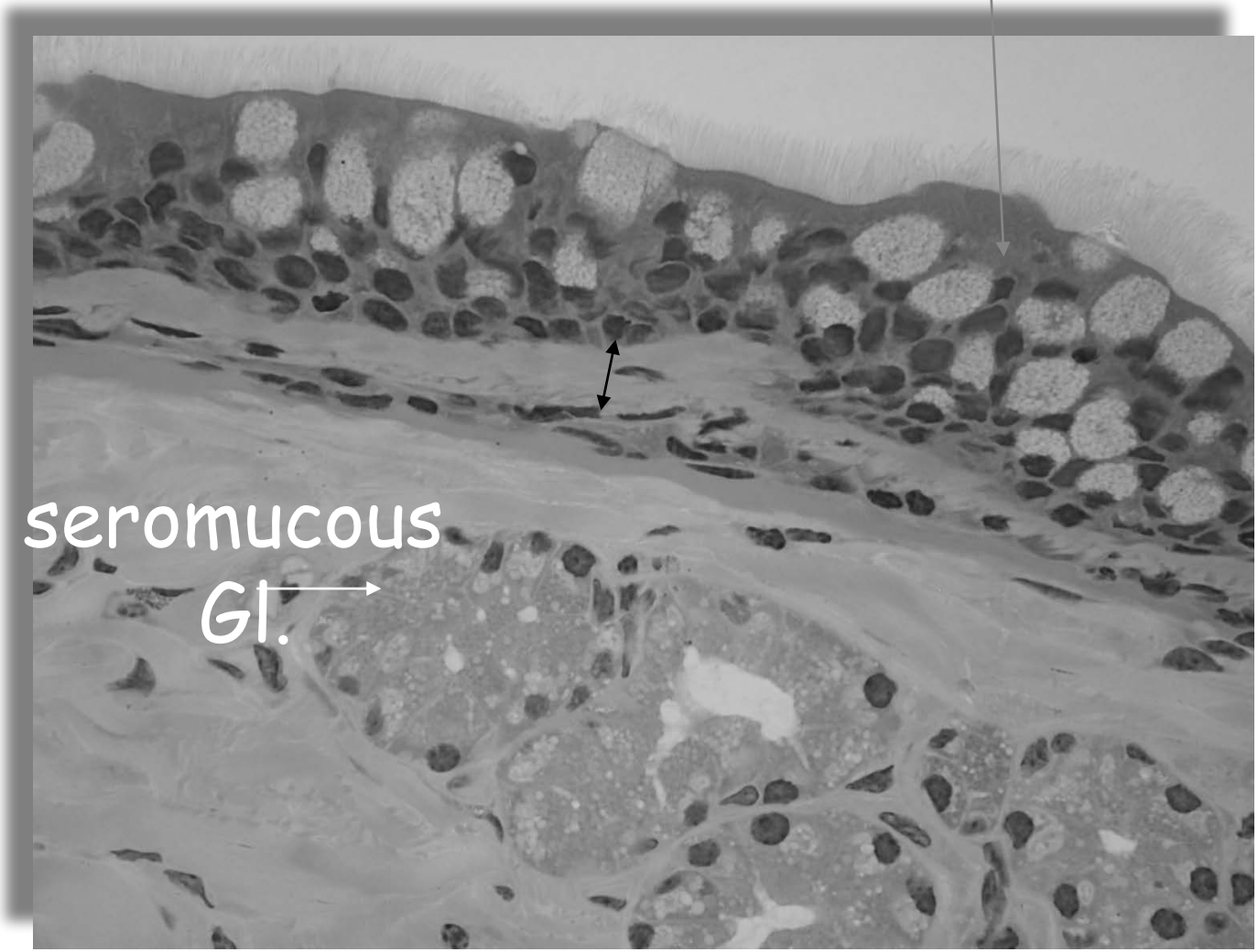

EXTRAPULMONARY

BRONCHUS=primary

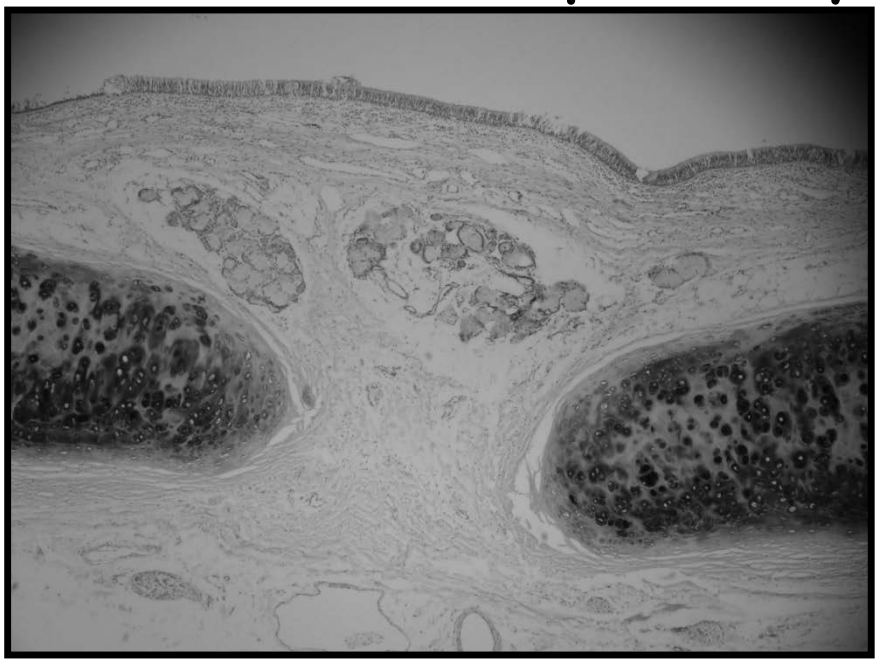

TRACHEA

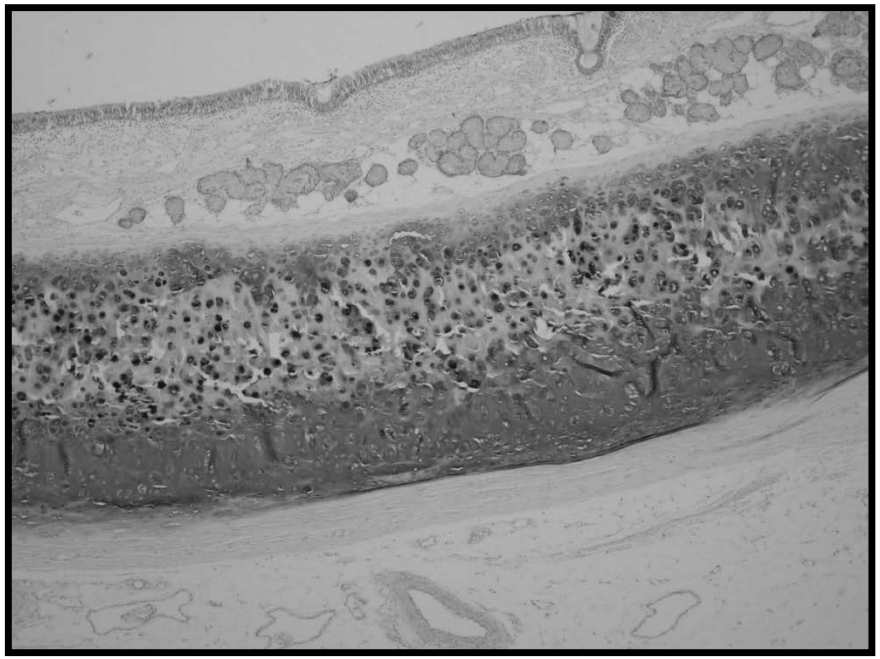

EXTRAPULMONARY BRONCHUS;(as trachea)except cartilage is segmented

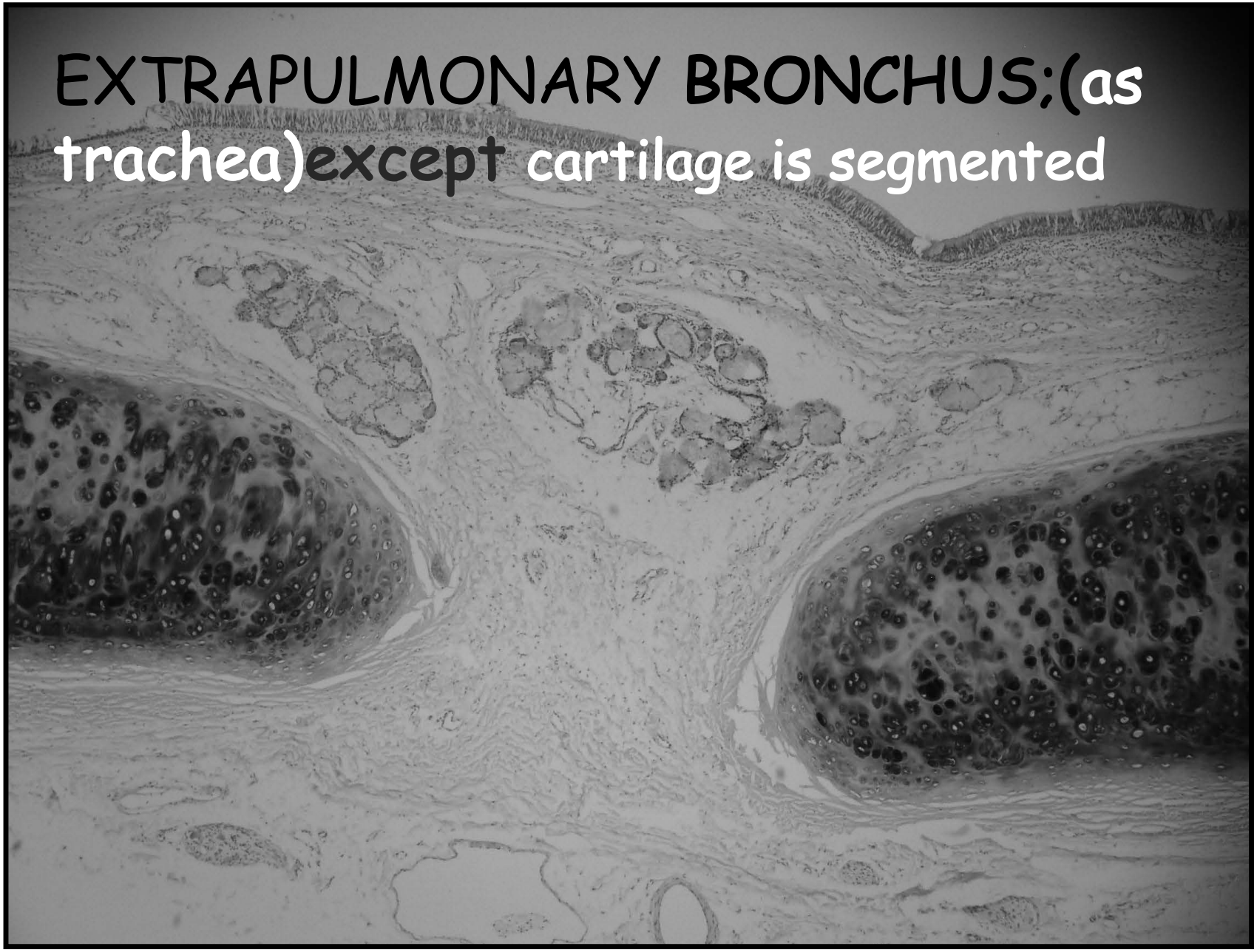

INTRAPULMONARY BRONCHUS (LARGE)

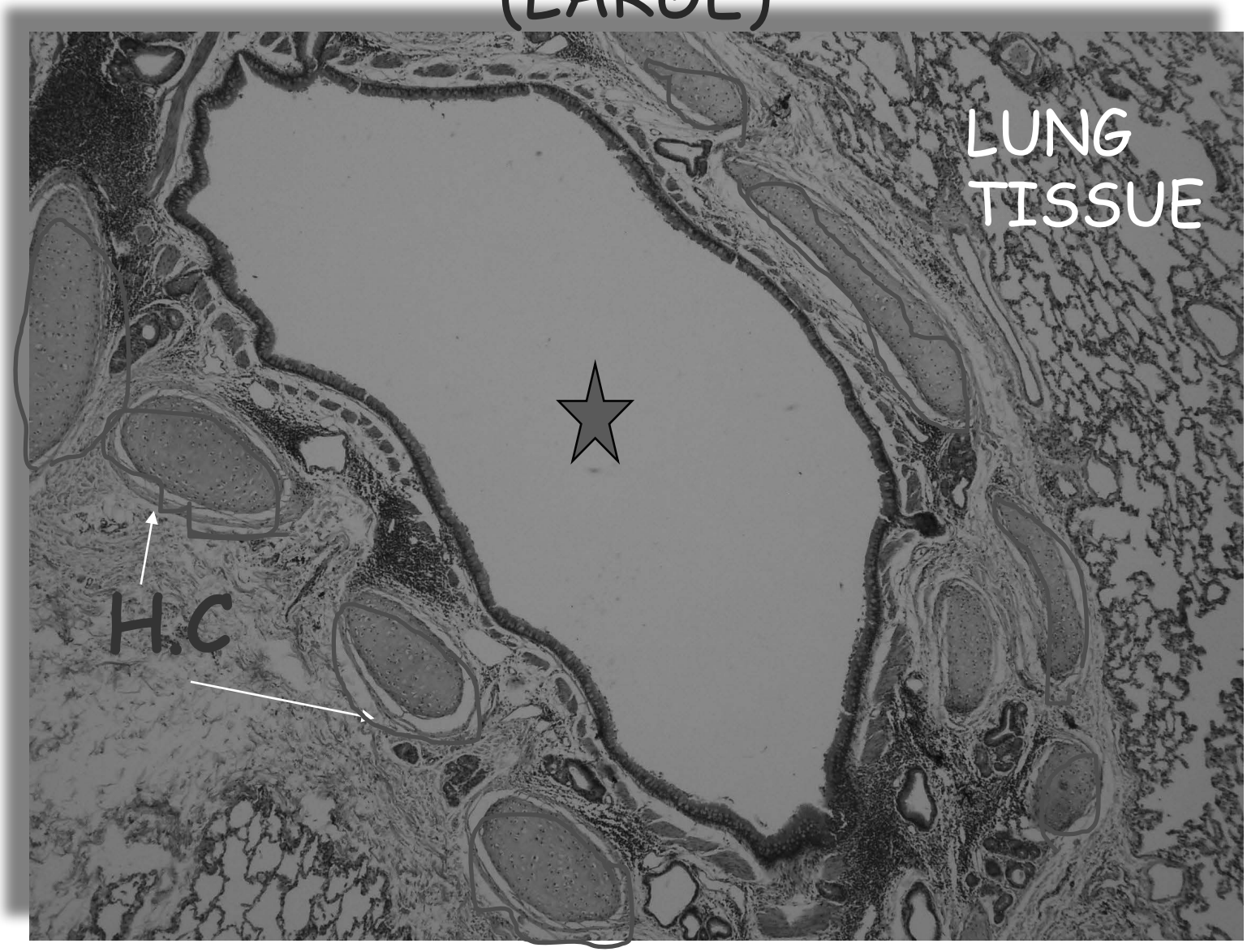

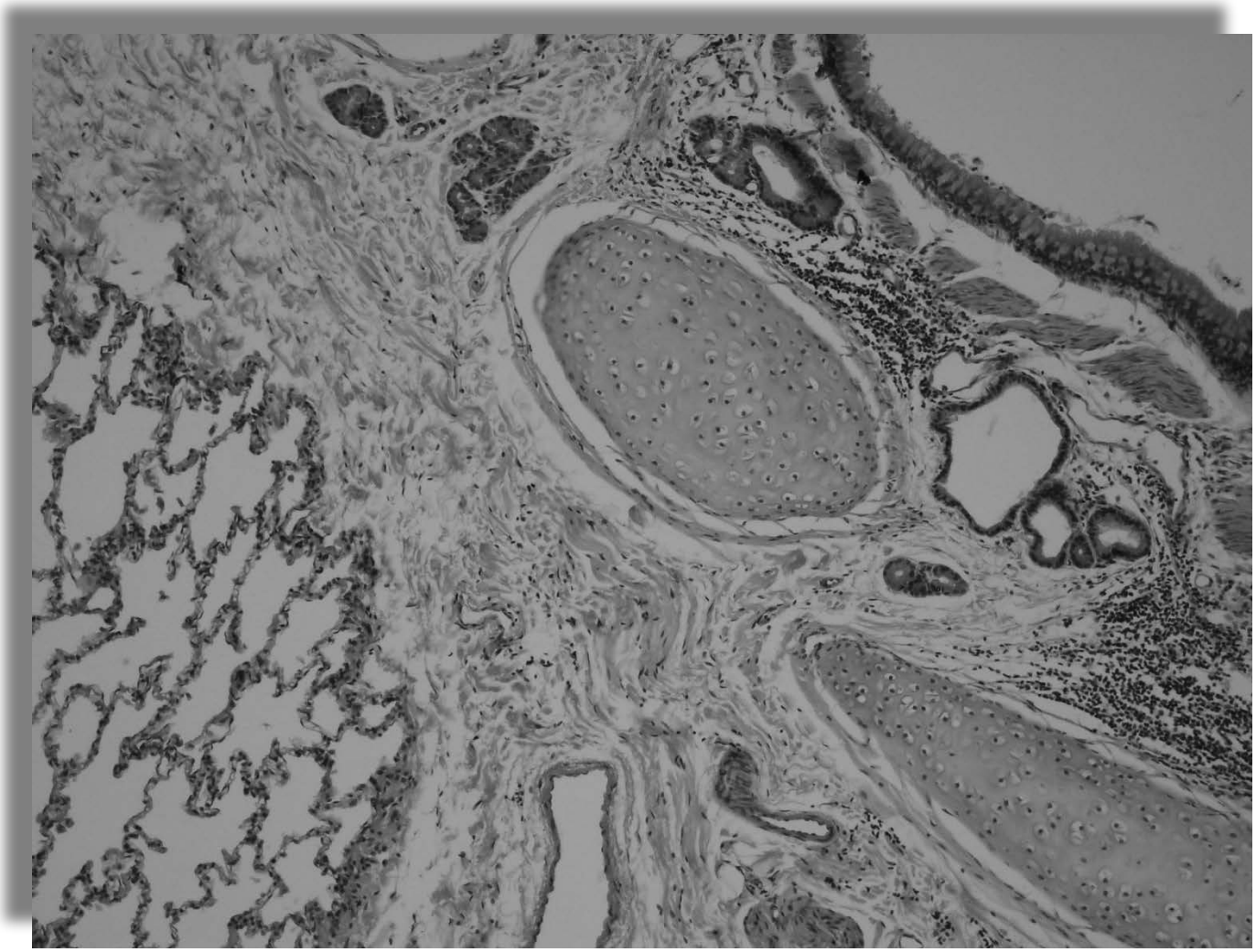

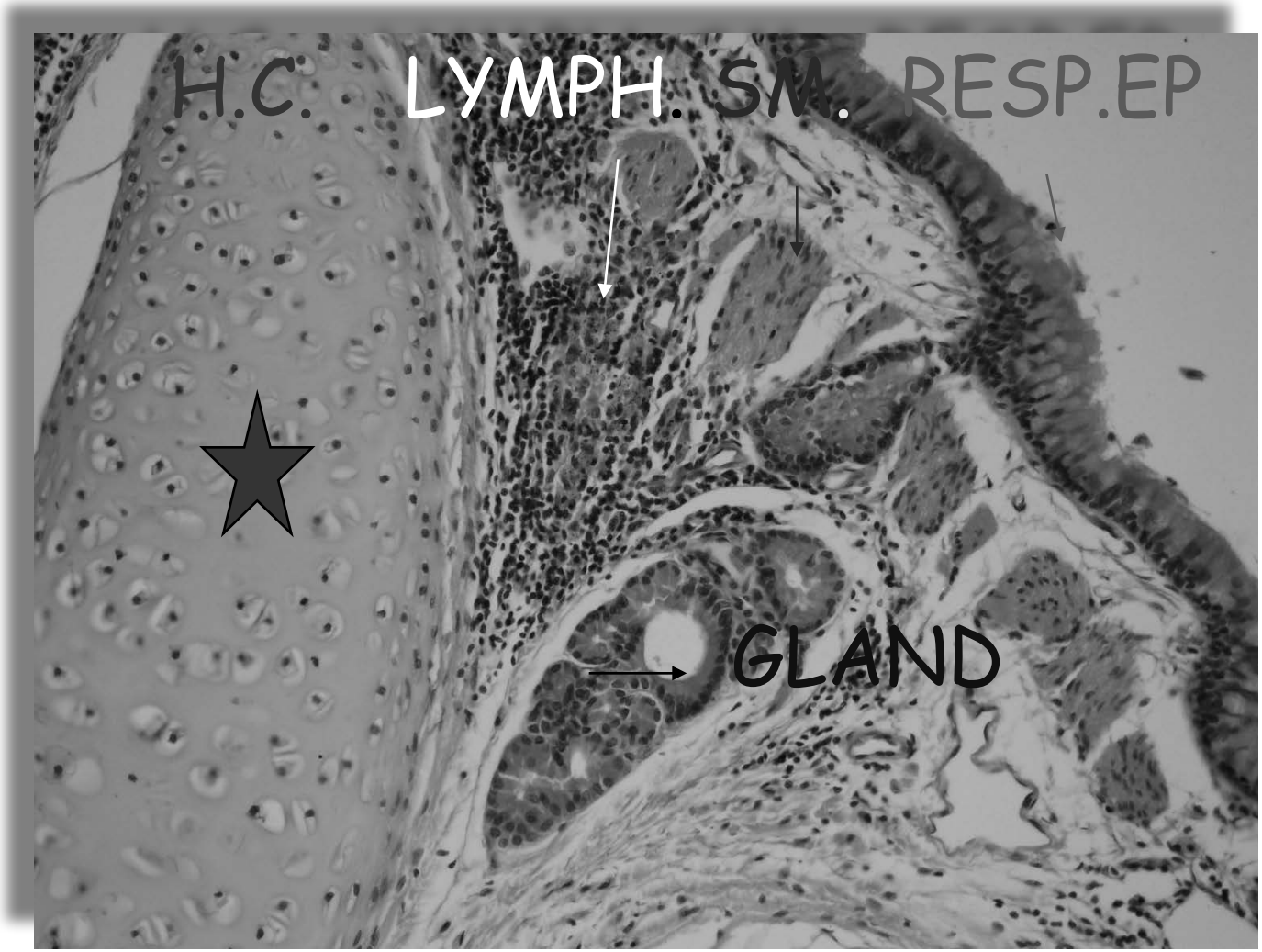
H.C.
LYMPH.
SM.
RESP.EP
GLAND

PSEUDOSTRATIFIEDCOLUMNAR CILIATED +GOBLET CELL

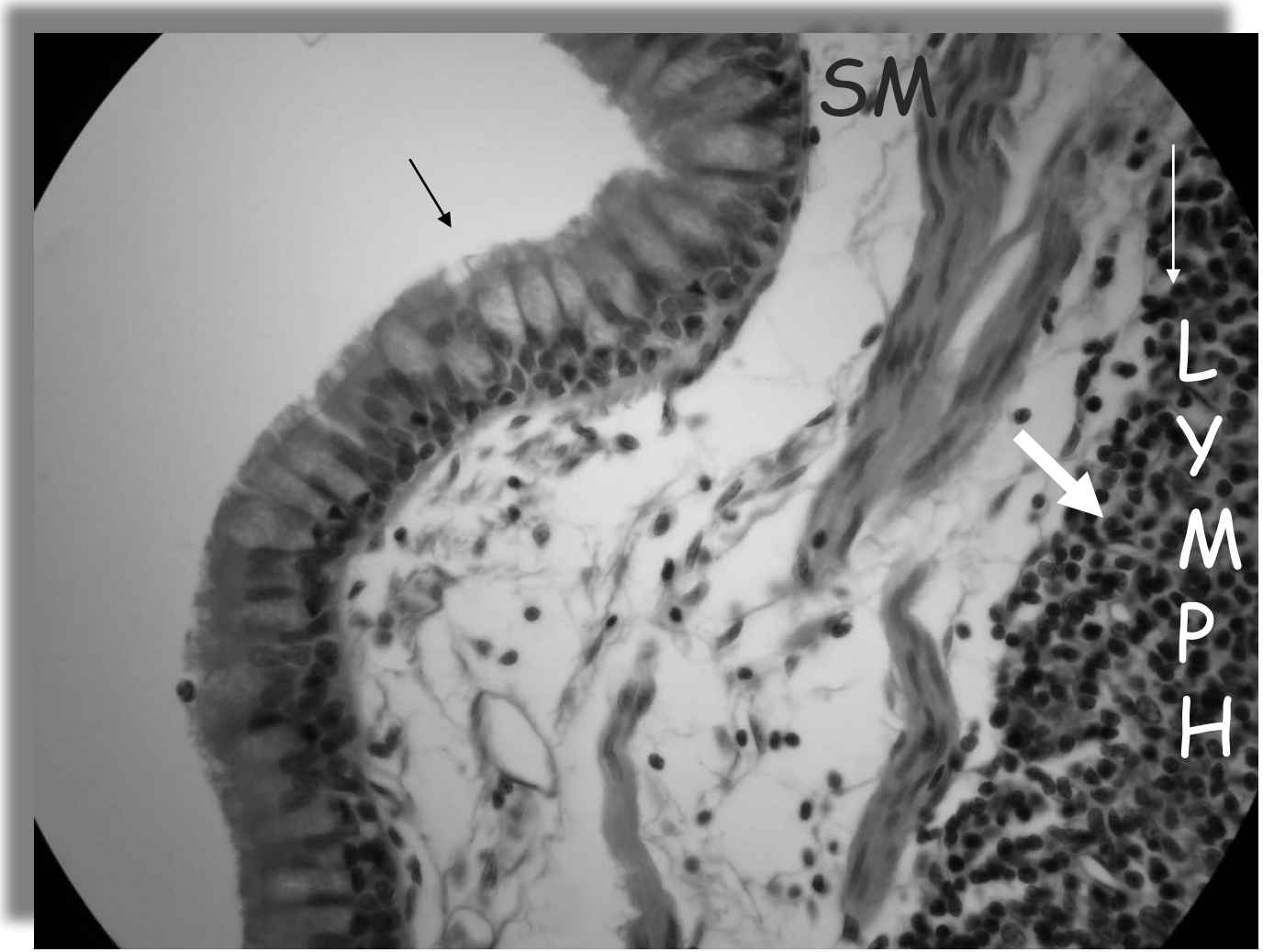

INTRAPULMONARY BRONCHUS- **secondary**

LARGE

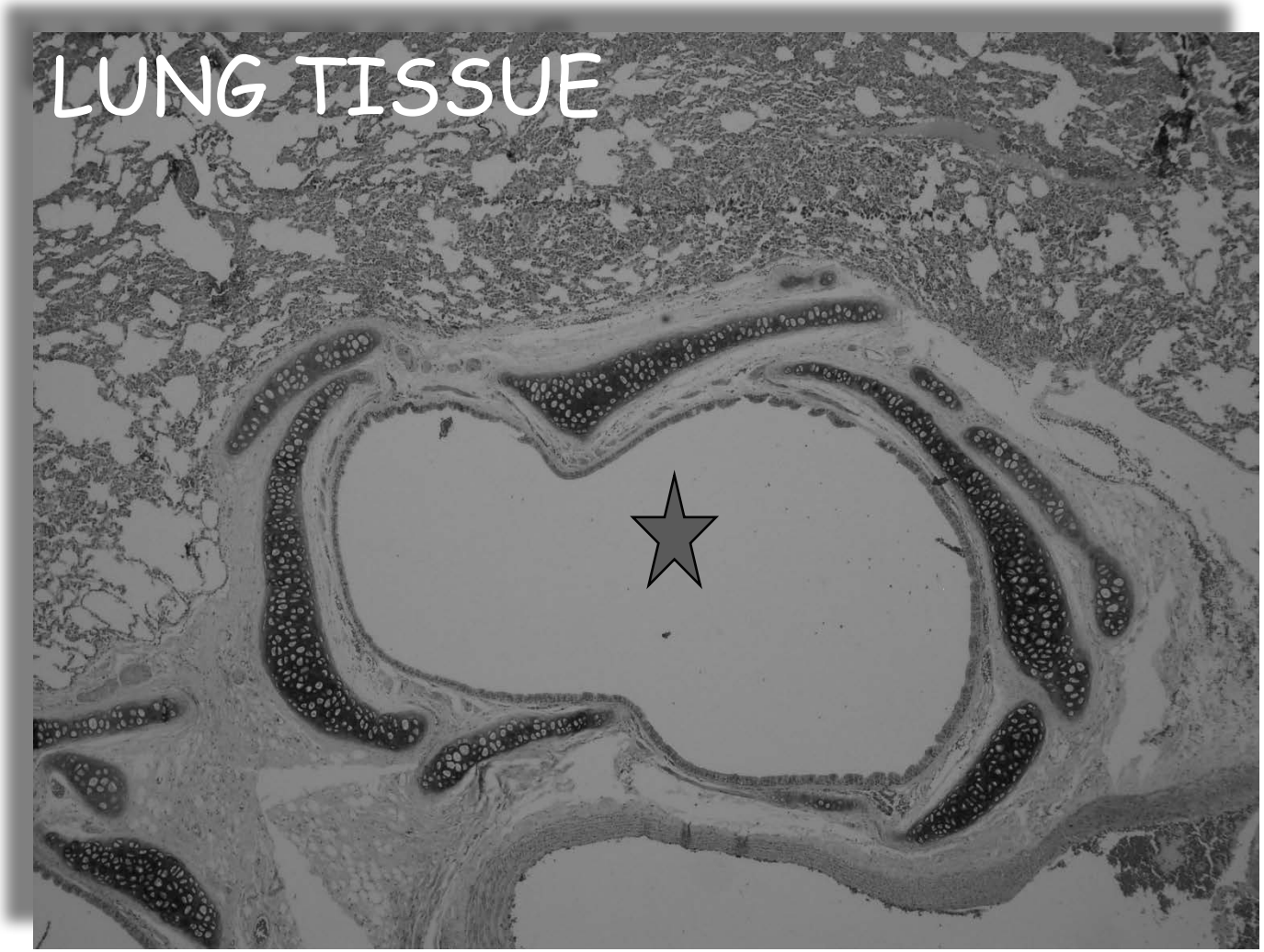

INTRAPULMONARY BRONCHUS:

tertiary SMALL

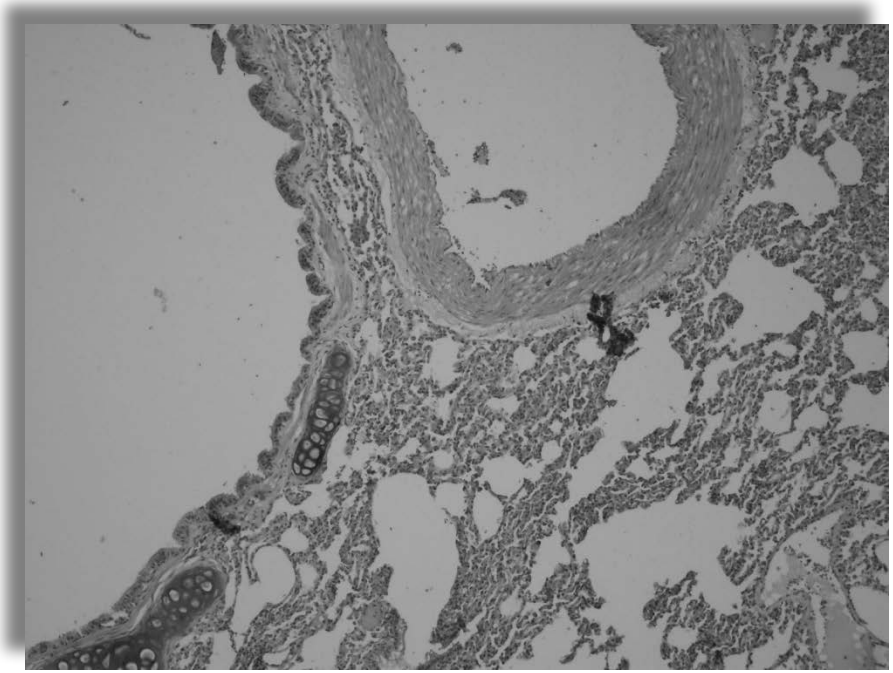

secondary LARGE

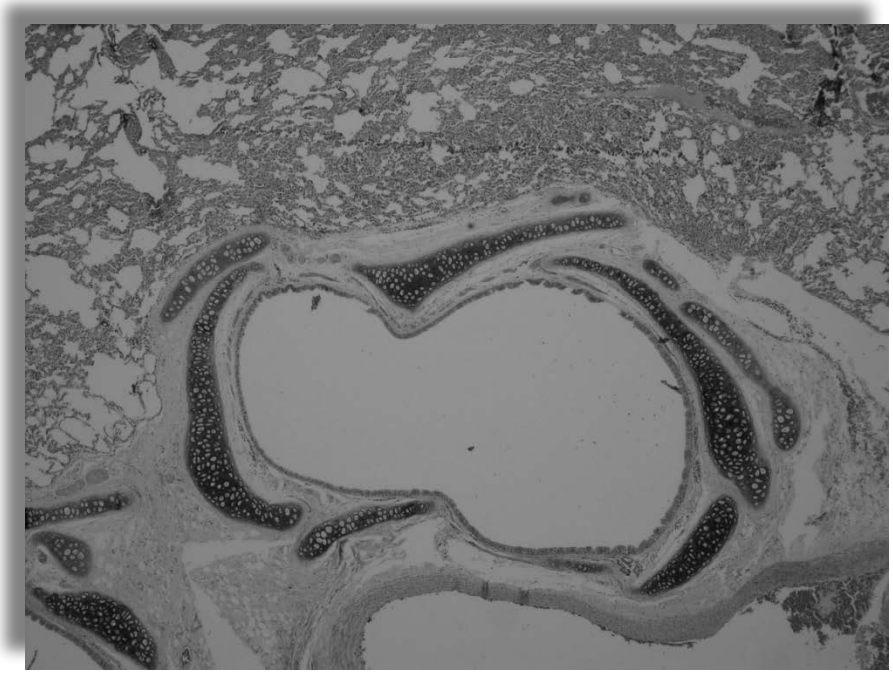

tertiary

SMALL

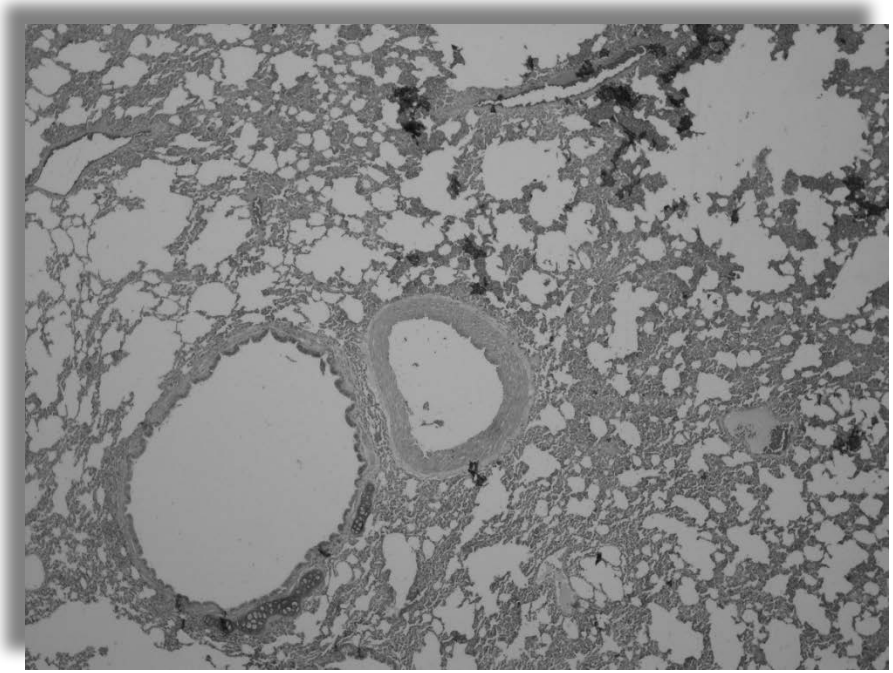

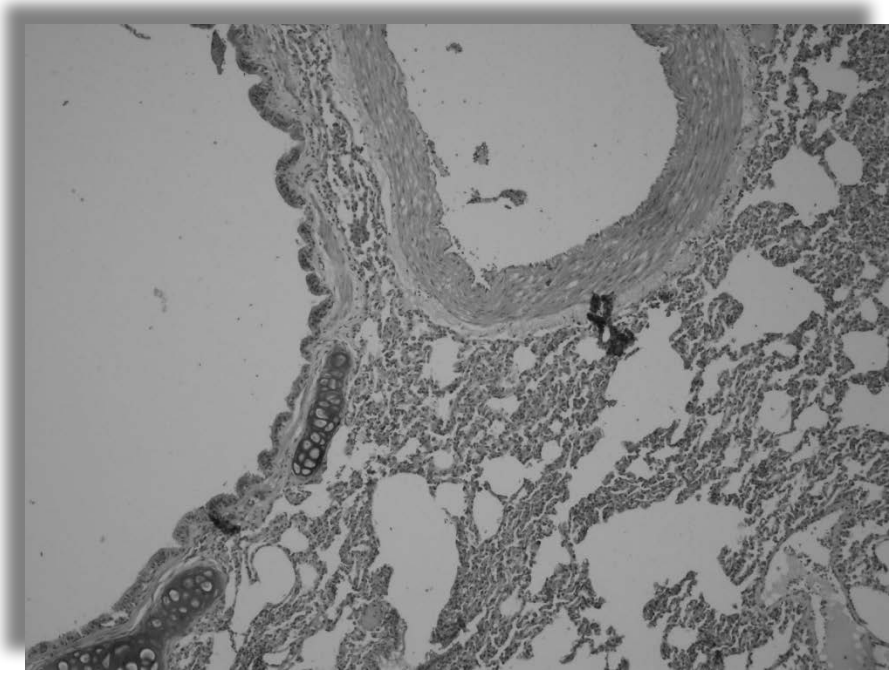

INTRAPULMONARY BRONCHUS

PULMONARY VESSEL

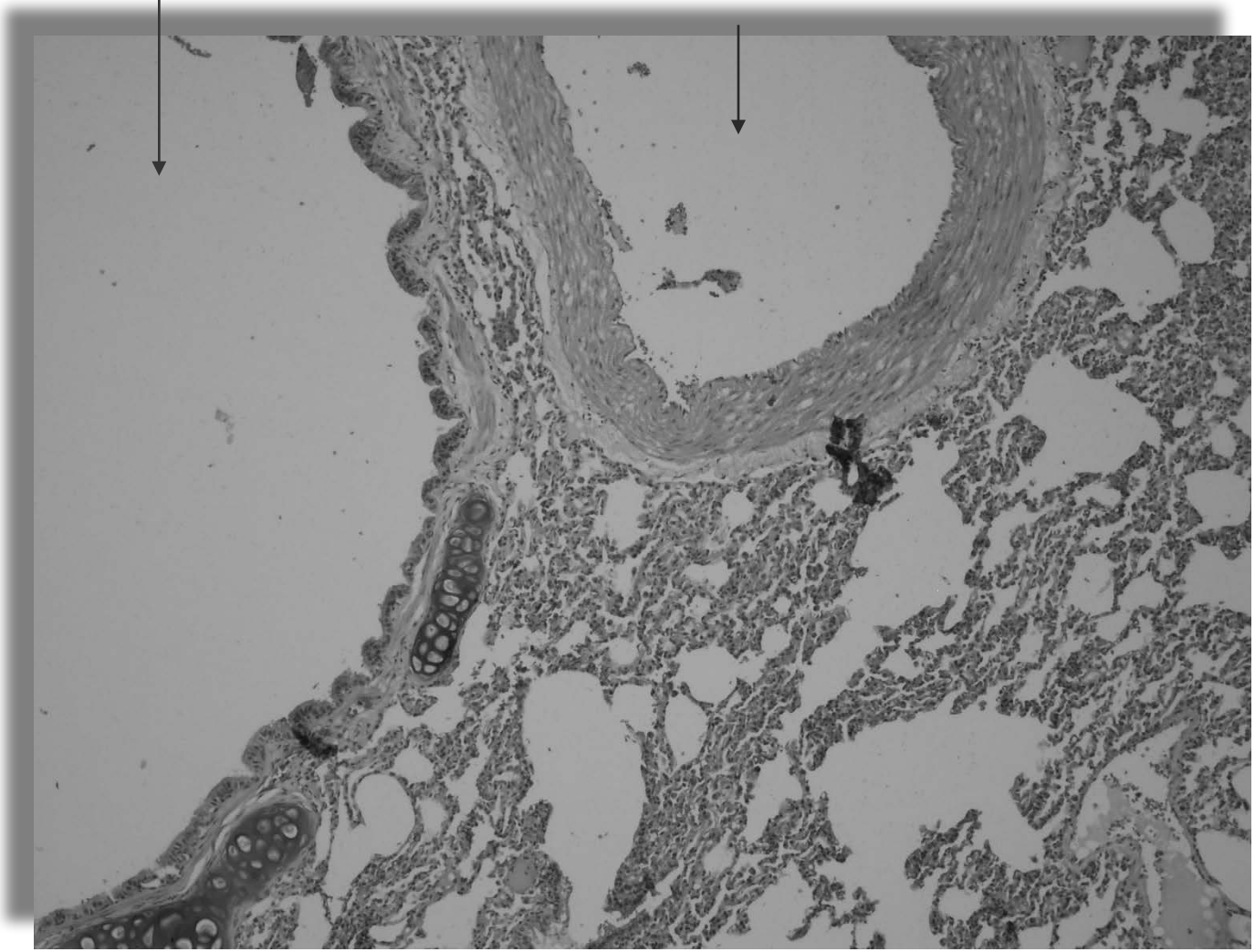

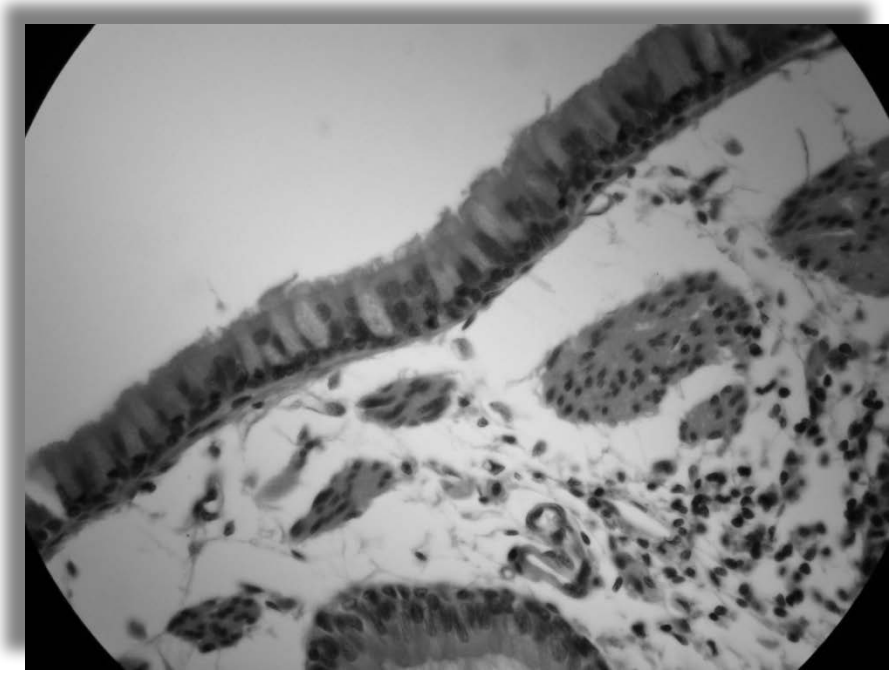

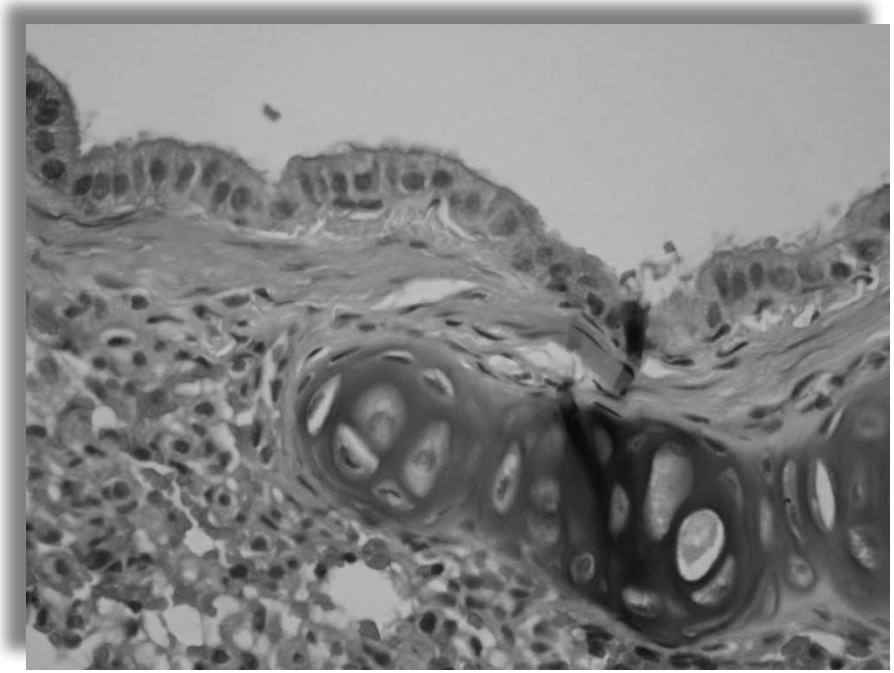

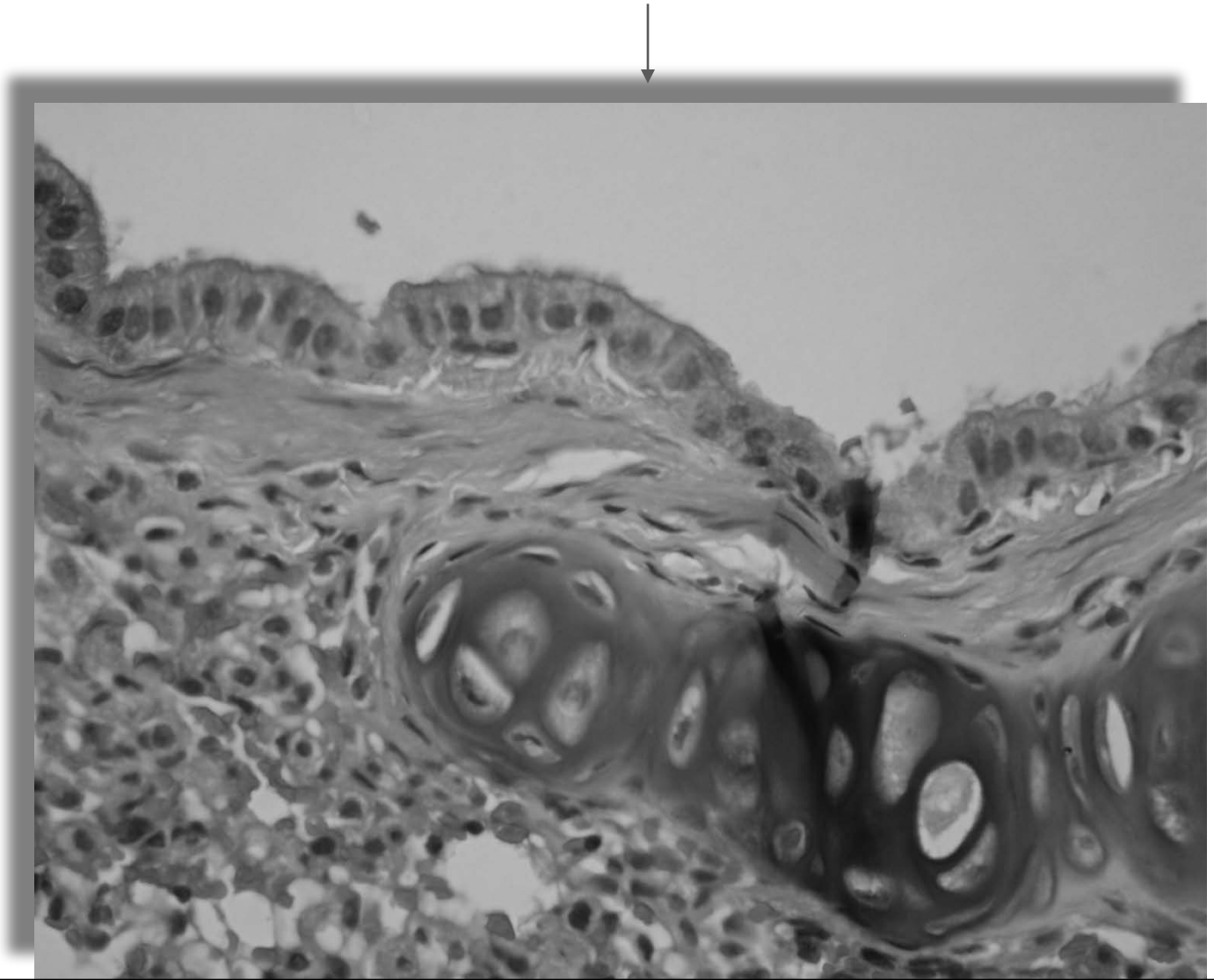

conductingBRONCHIOLEs TERMINAL+large

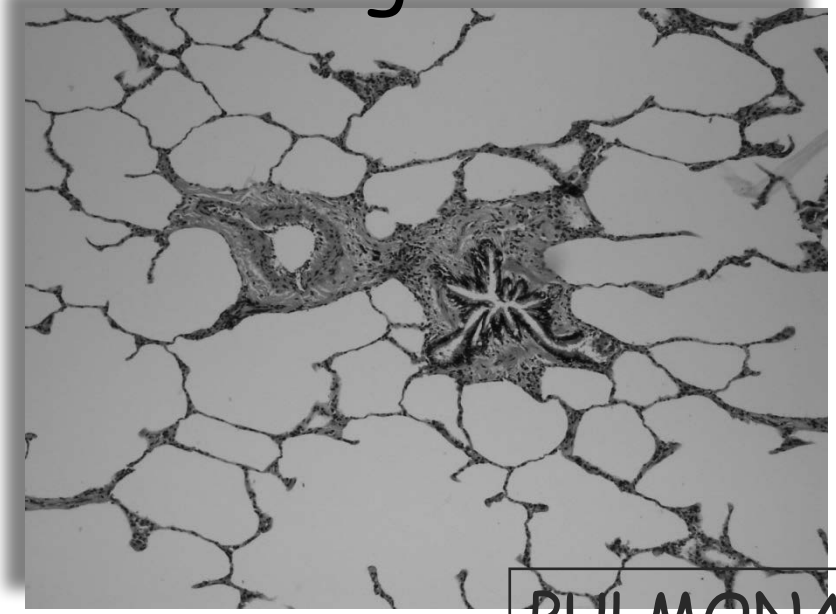

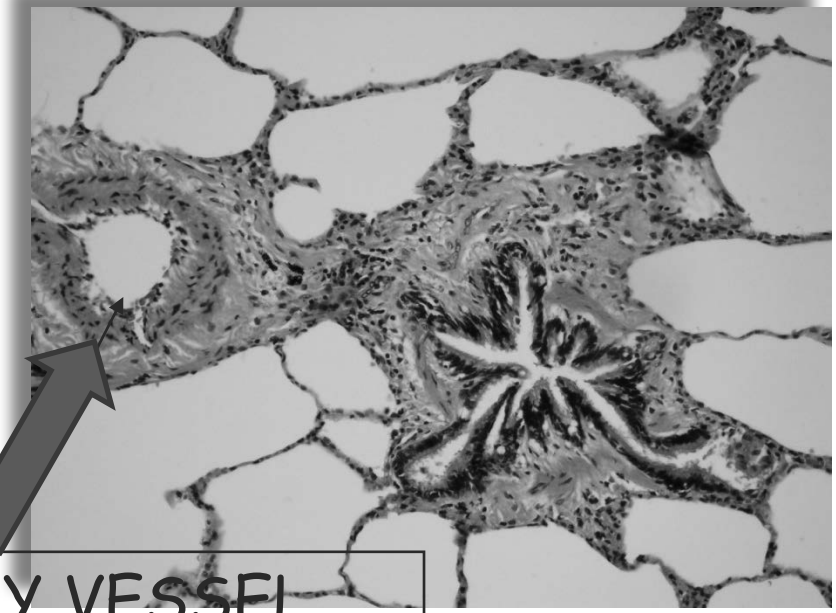

PULMONARY VESSEL

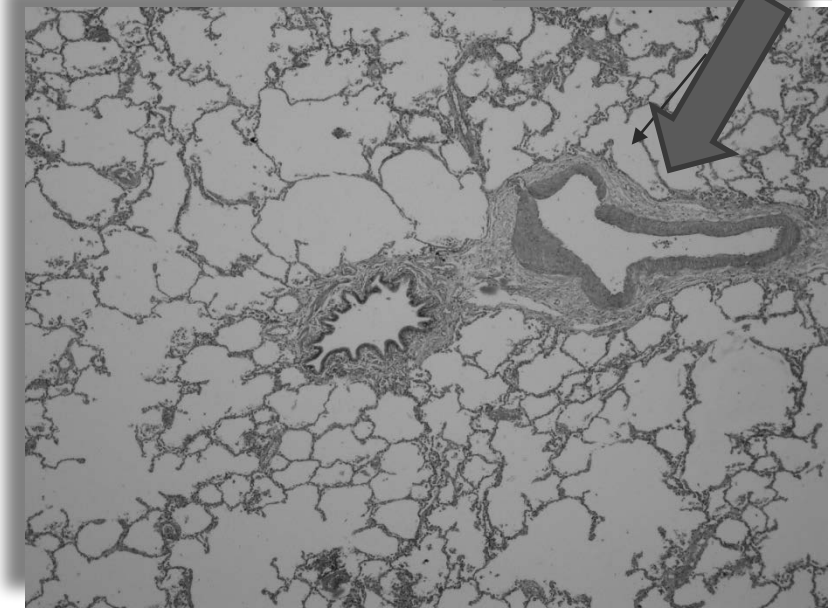

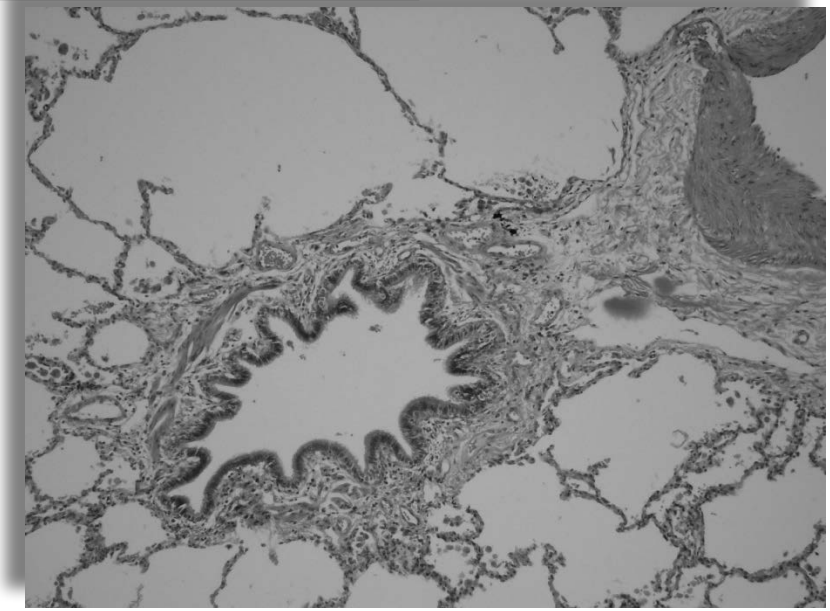

SIMPLE COLUMNAR CILIATED EP.

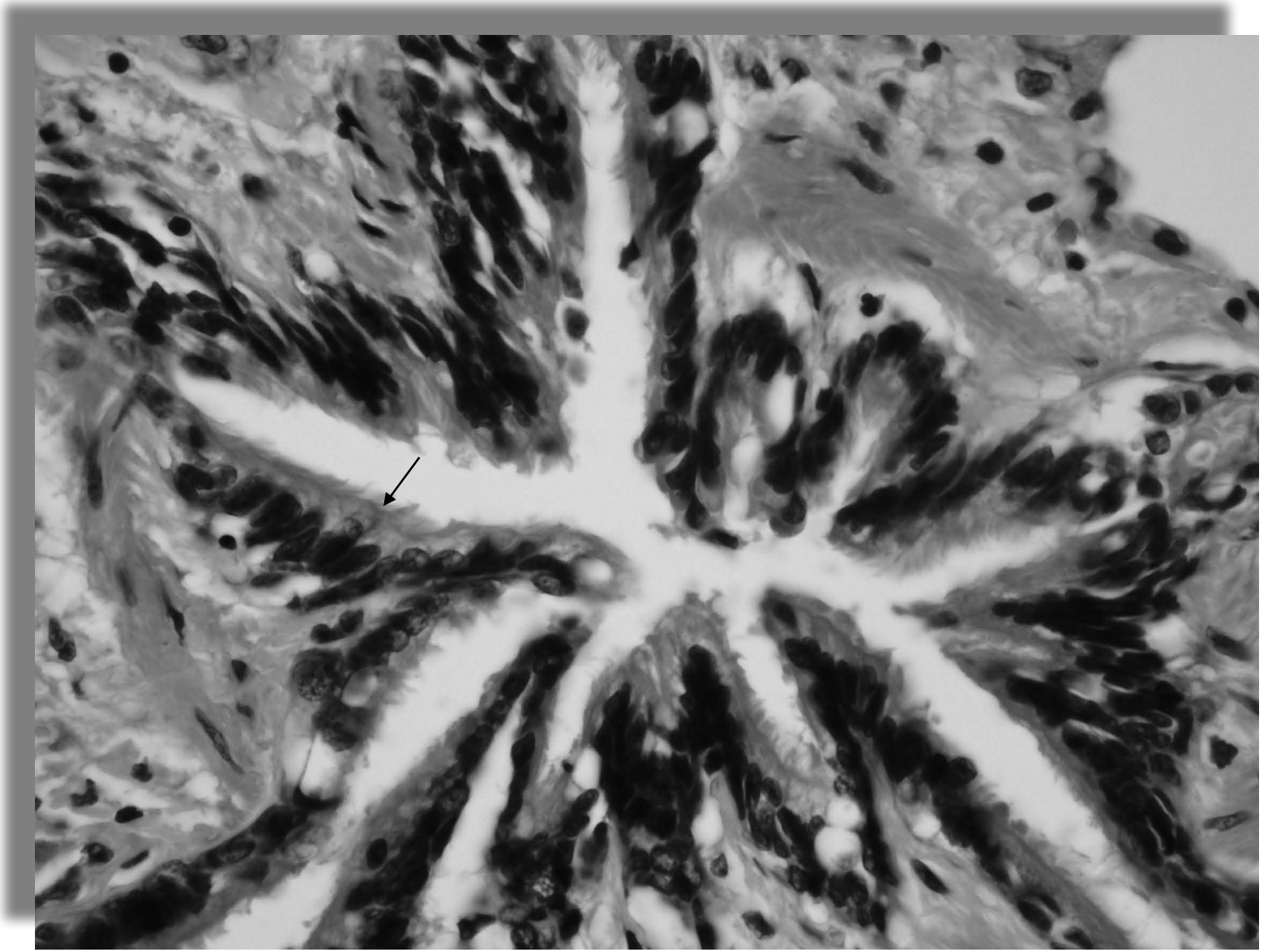

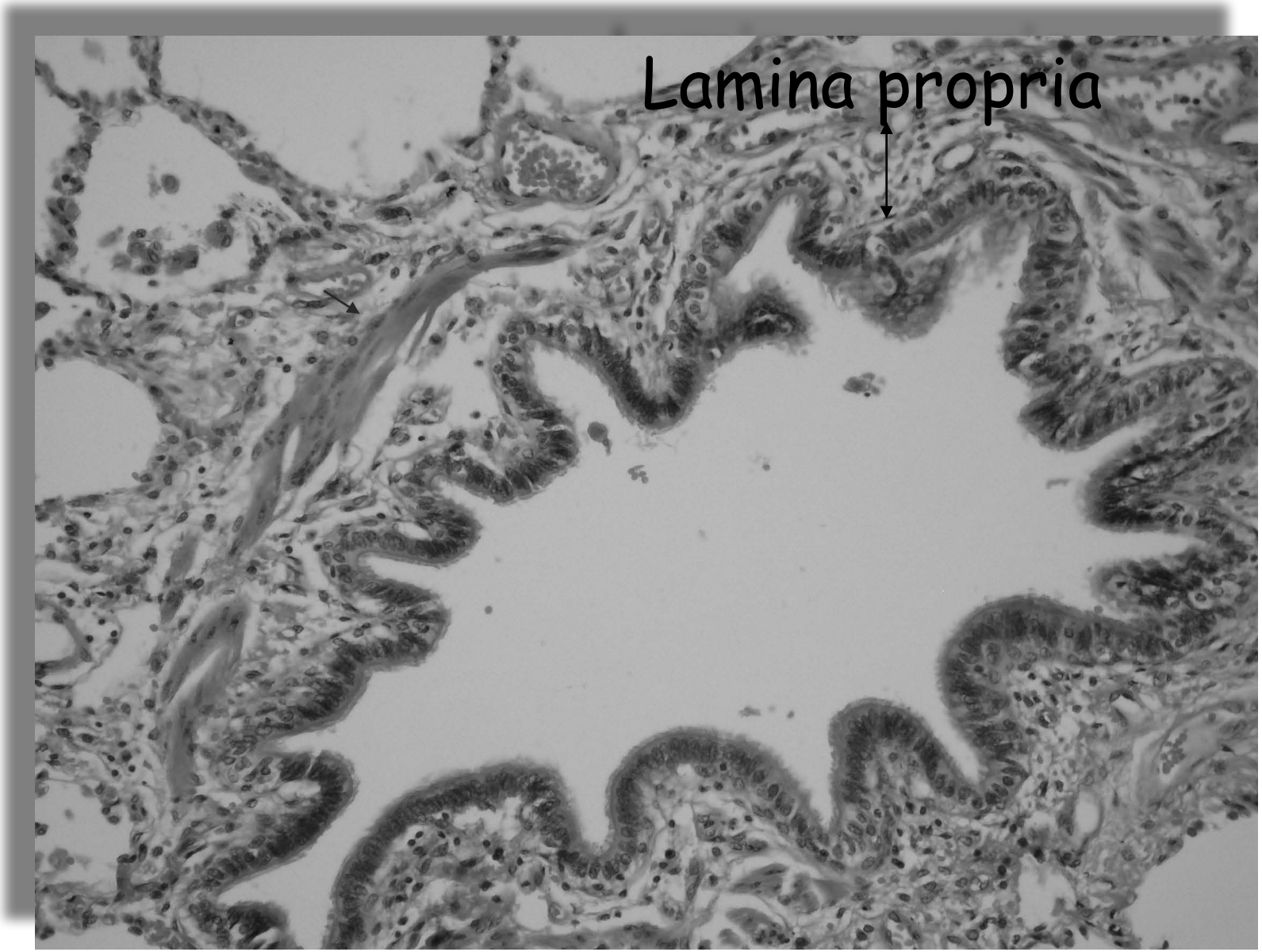
Lamina propria

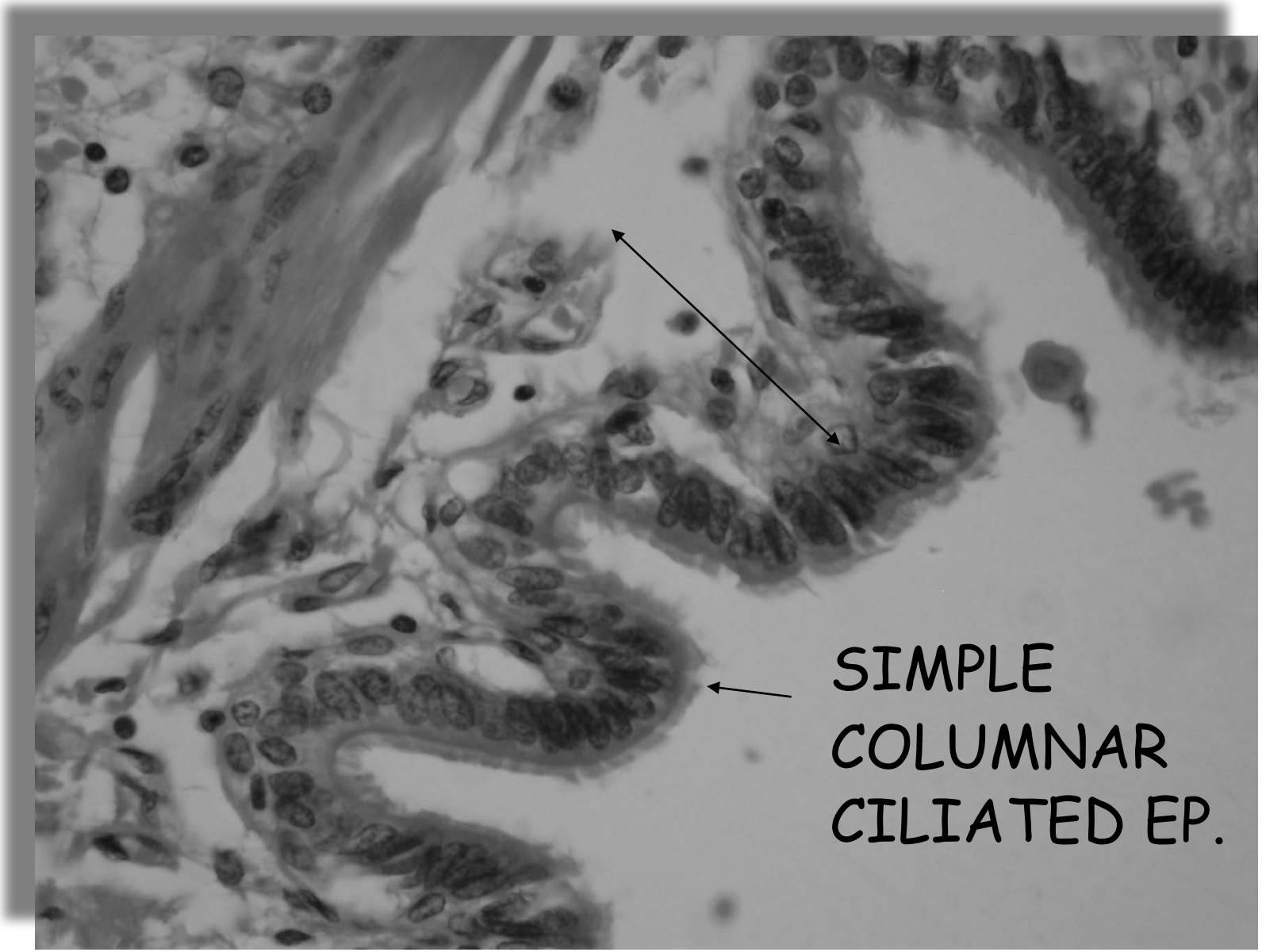
SIMPLE
COLUMNAR
CILIATED EP.

Respiretory bronchioles in lung tissue

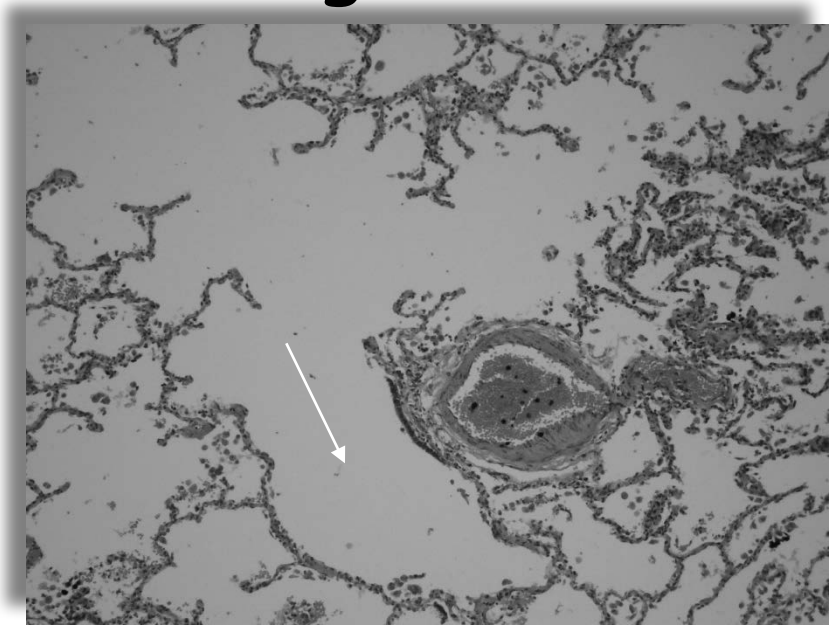



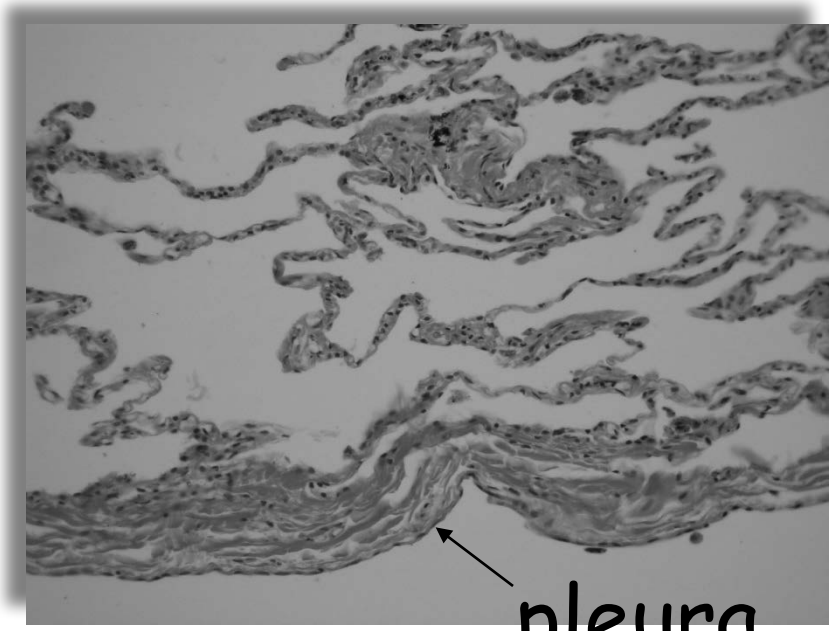

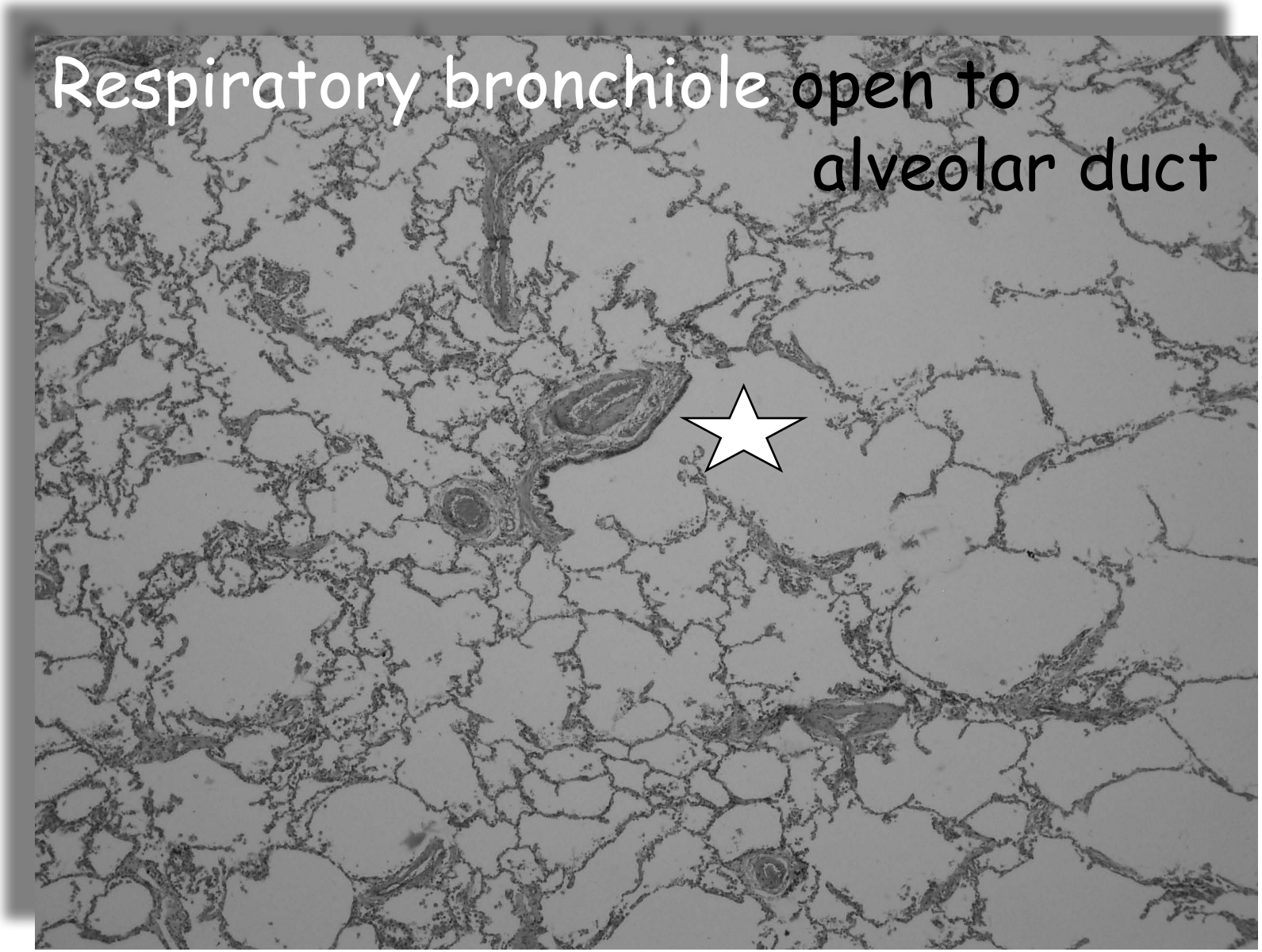
Respiratory bronchiole open to
alveolar duct

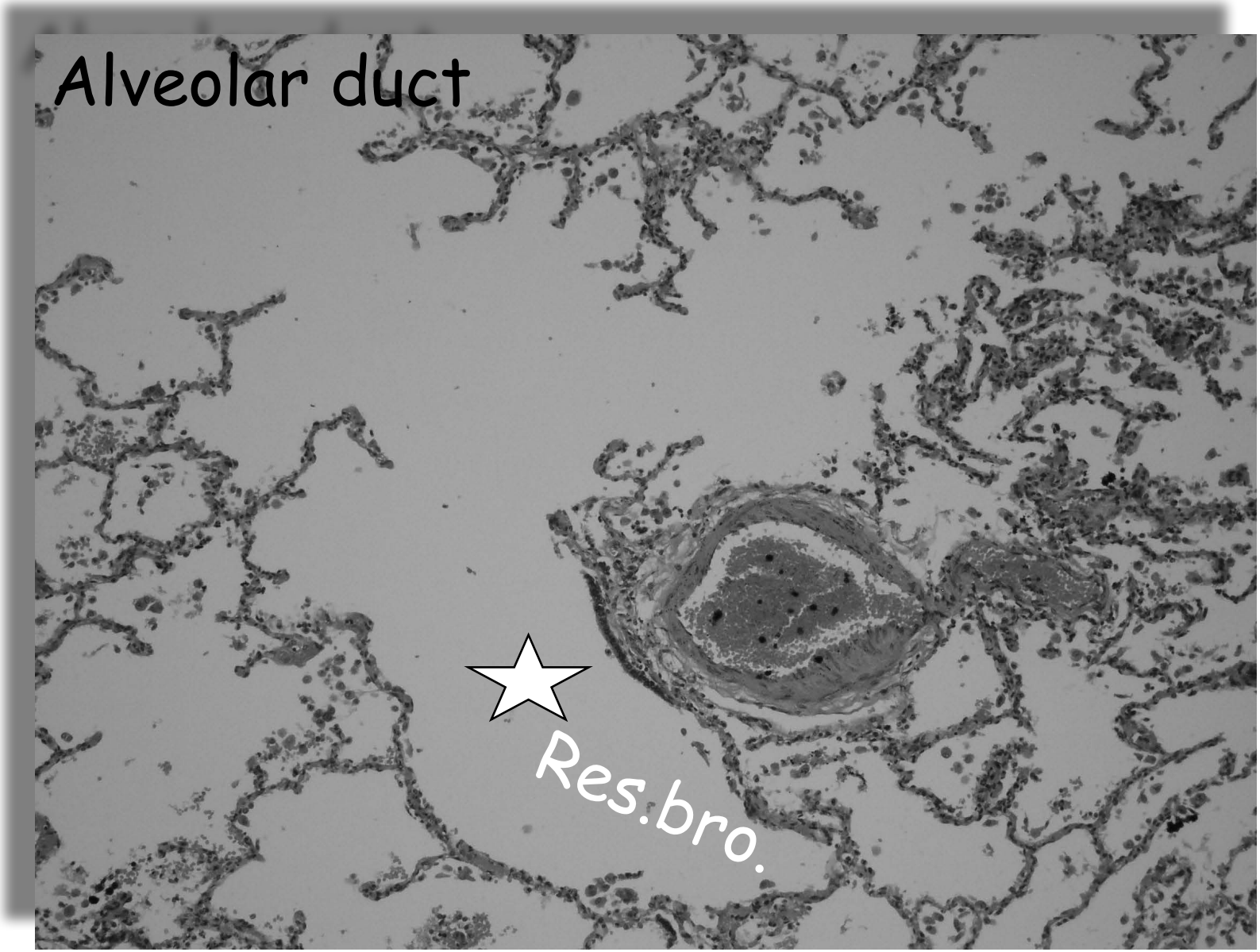
Alveolar duct
Res.bro.

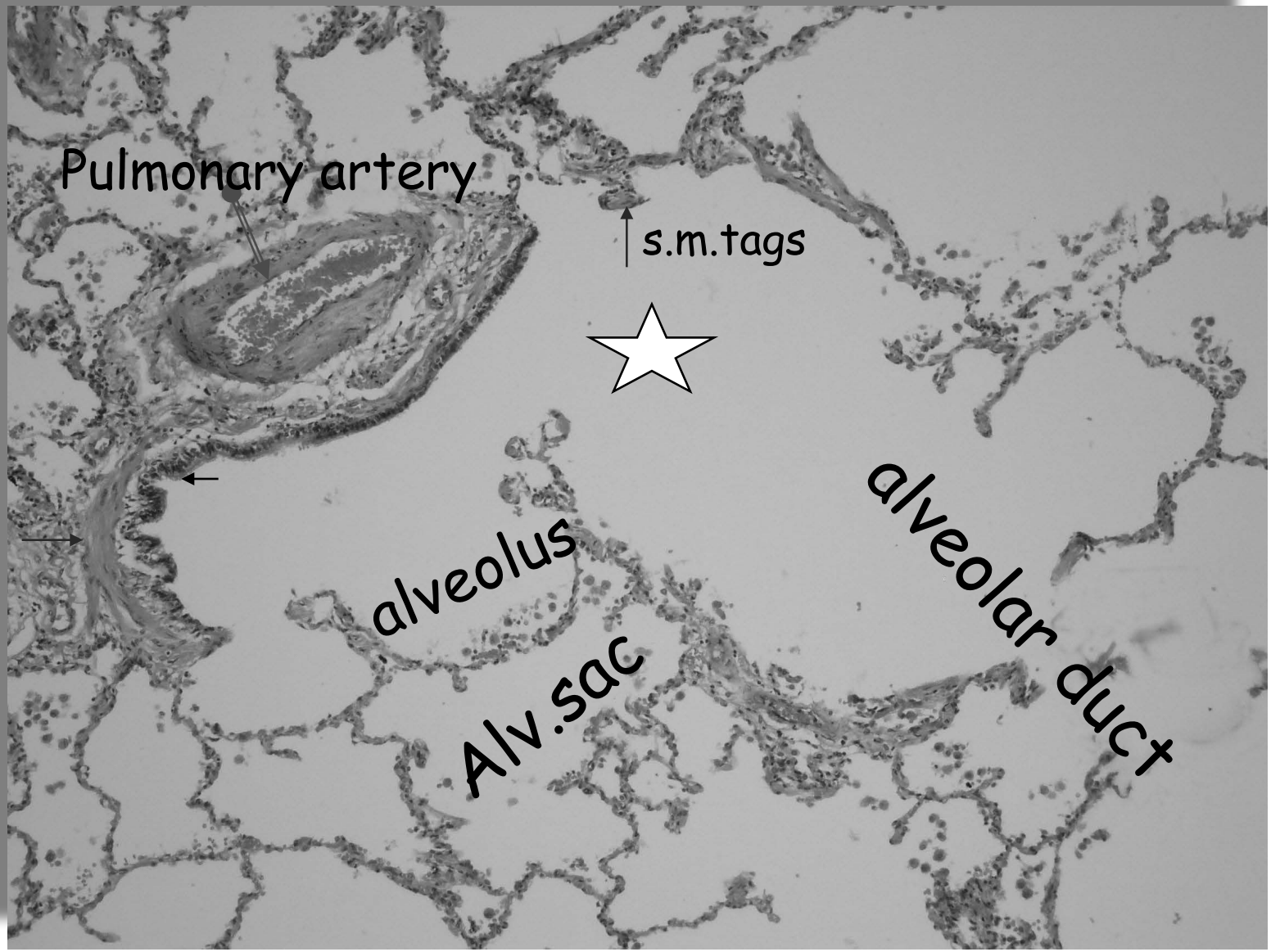
Pulmonary artery
s.m.tags
alveolus
Alv.sac
alveolar duct

Bronchial wall:

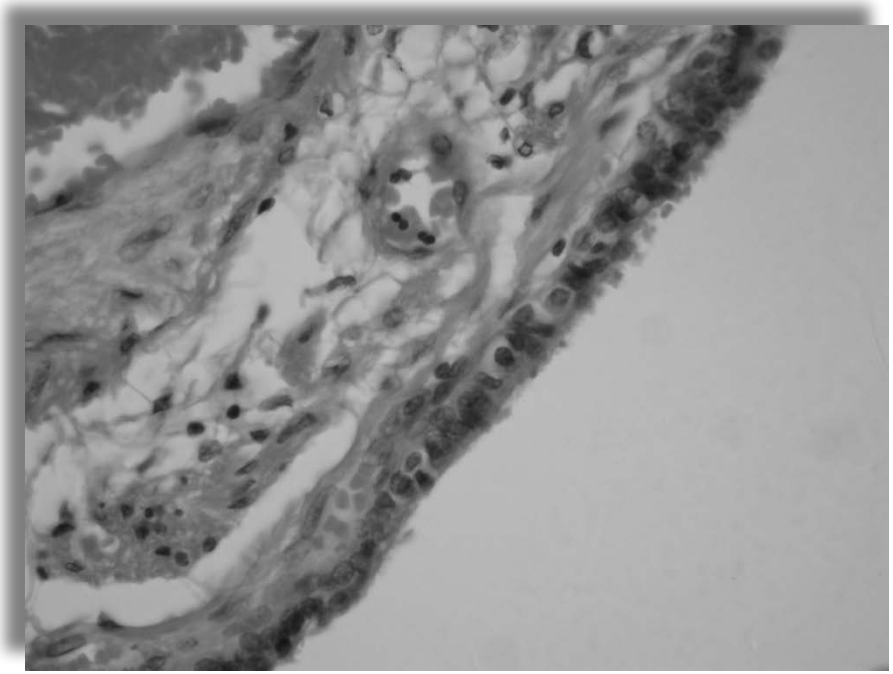

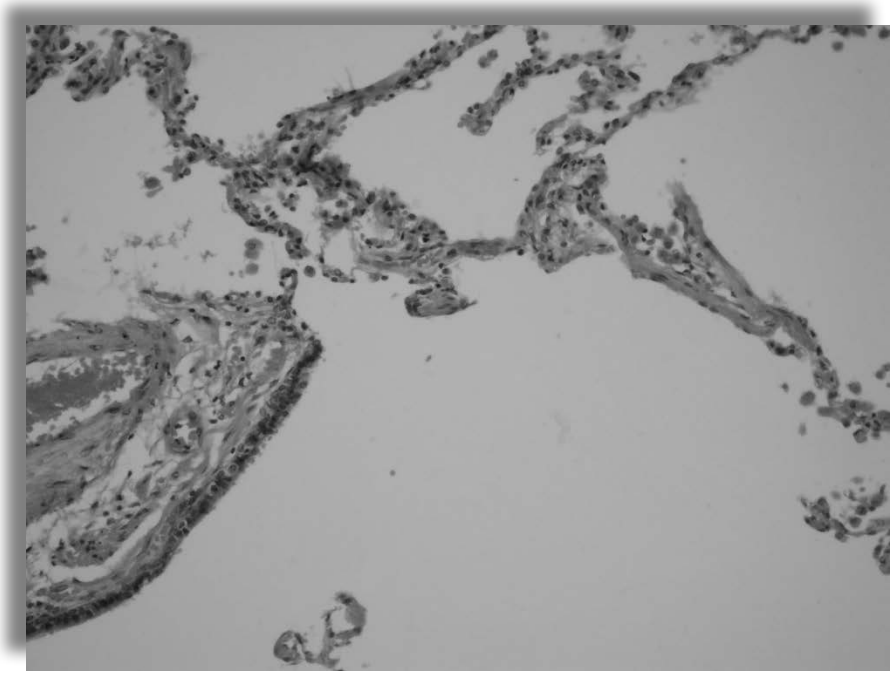

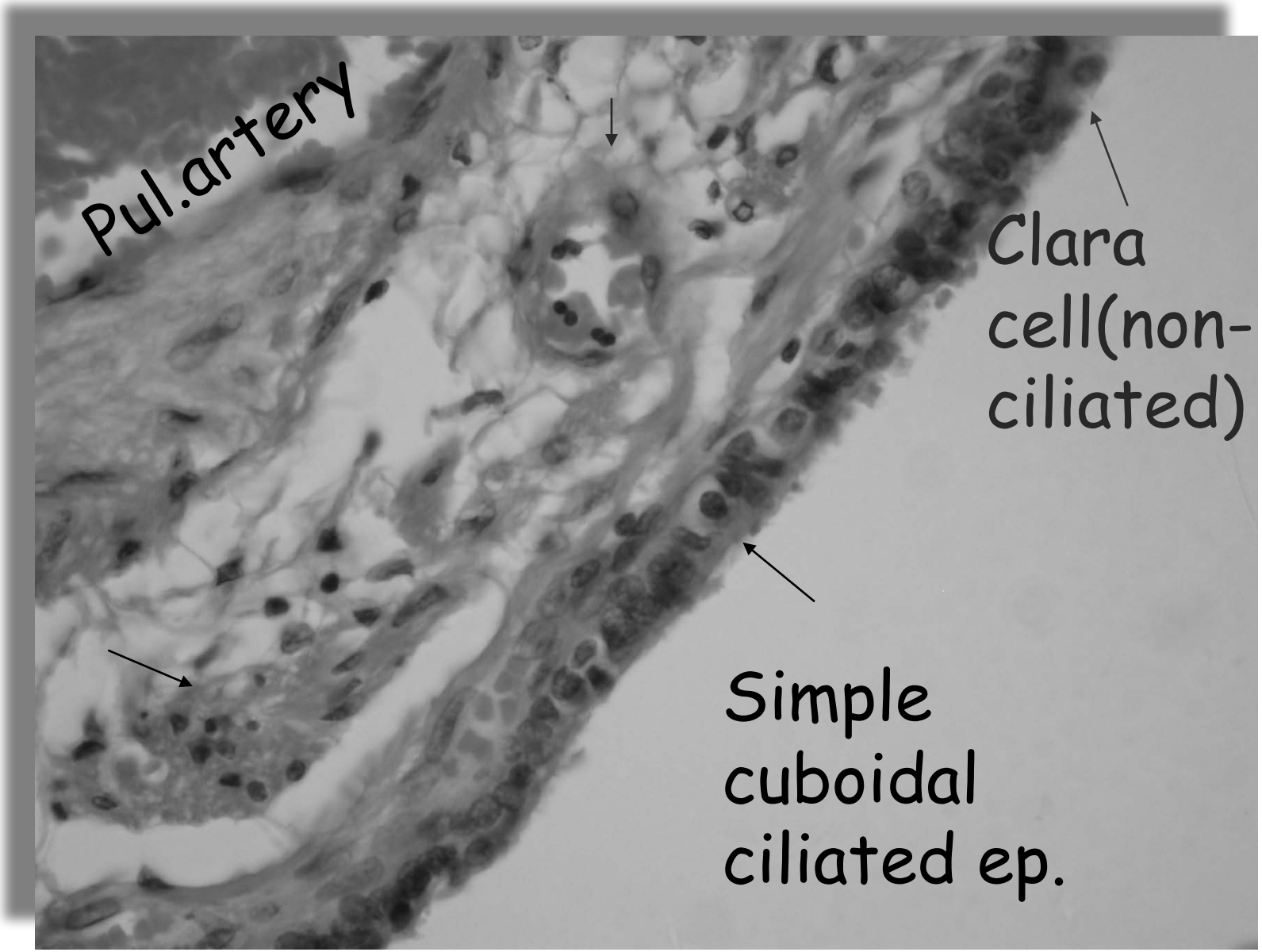
Pul.artery
Clara cell(non-ciliated)
Simple cuboidal ciliated ep.

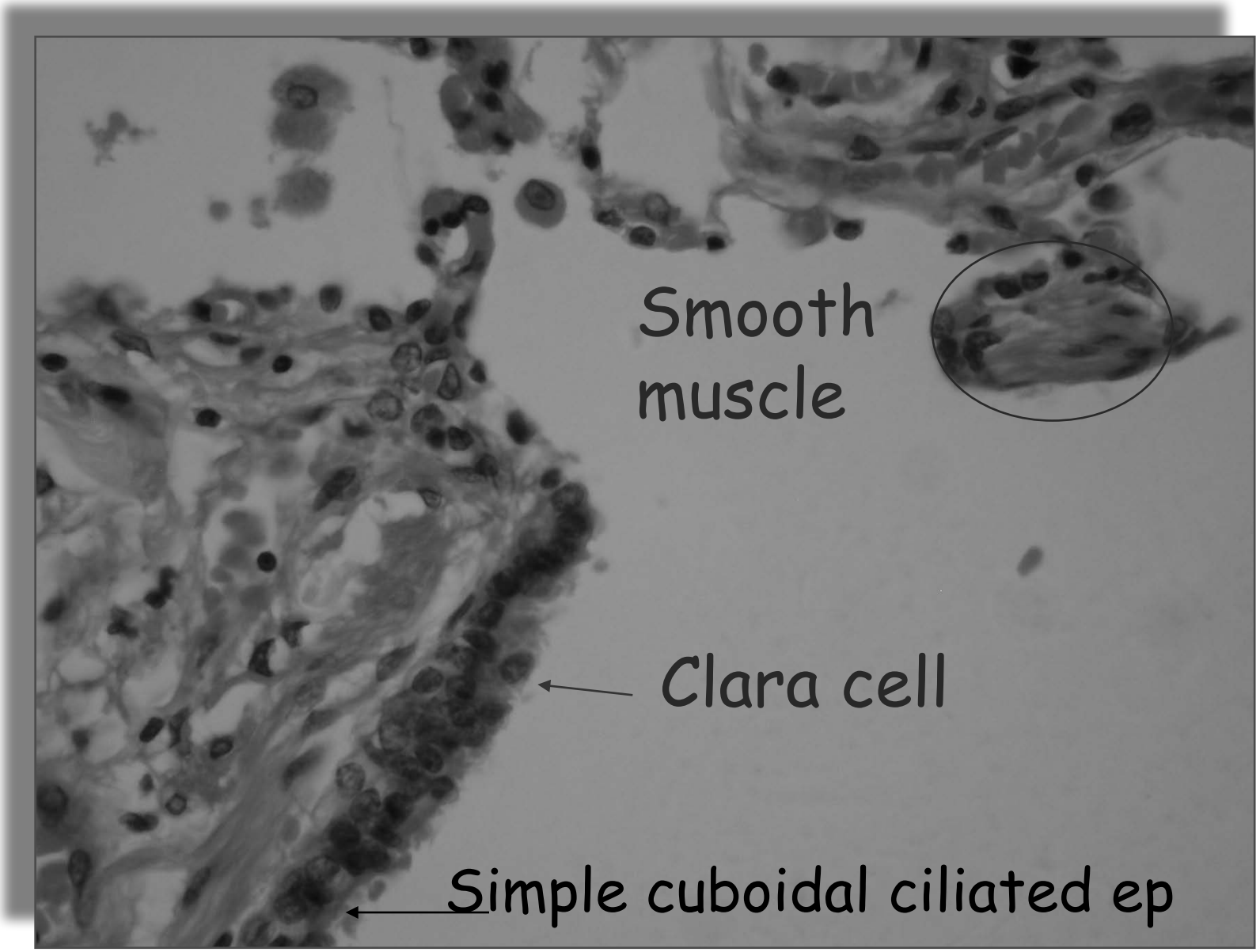
Smooth
muscle
Clara cell
Simple cuboidal ciliated ep

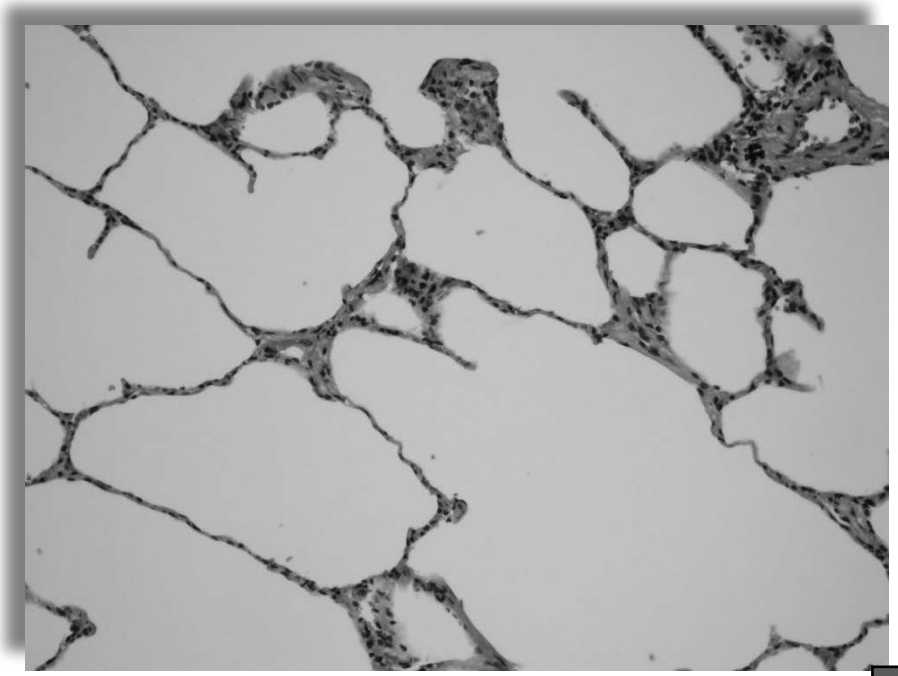

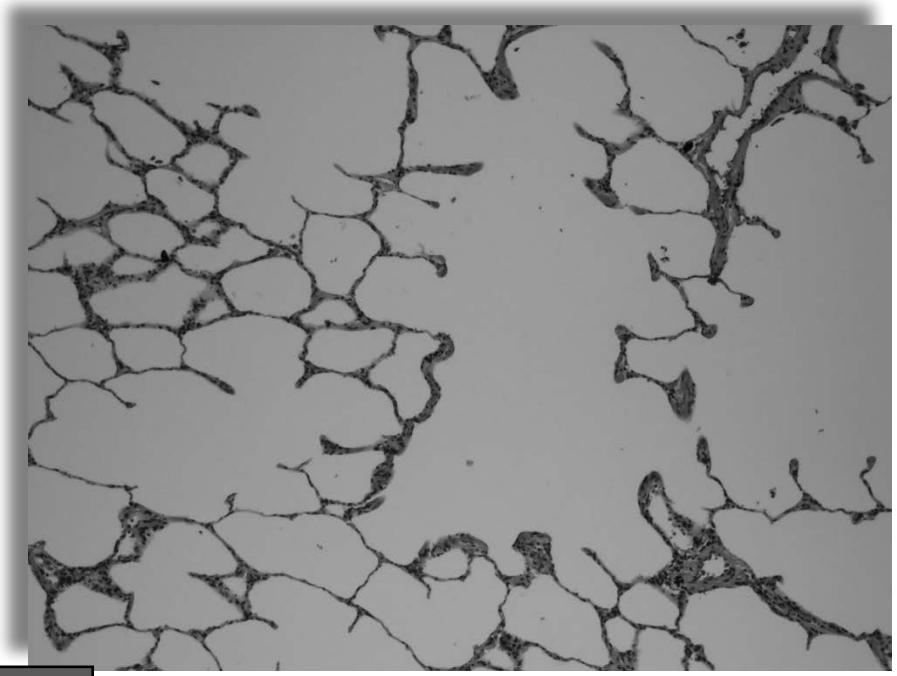


Alveo
lus
sac
Alveolar
duct
Alveolar
sac

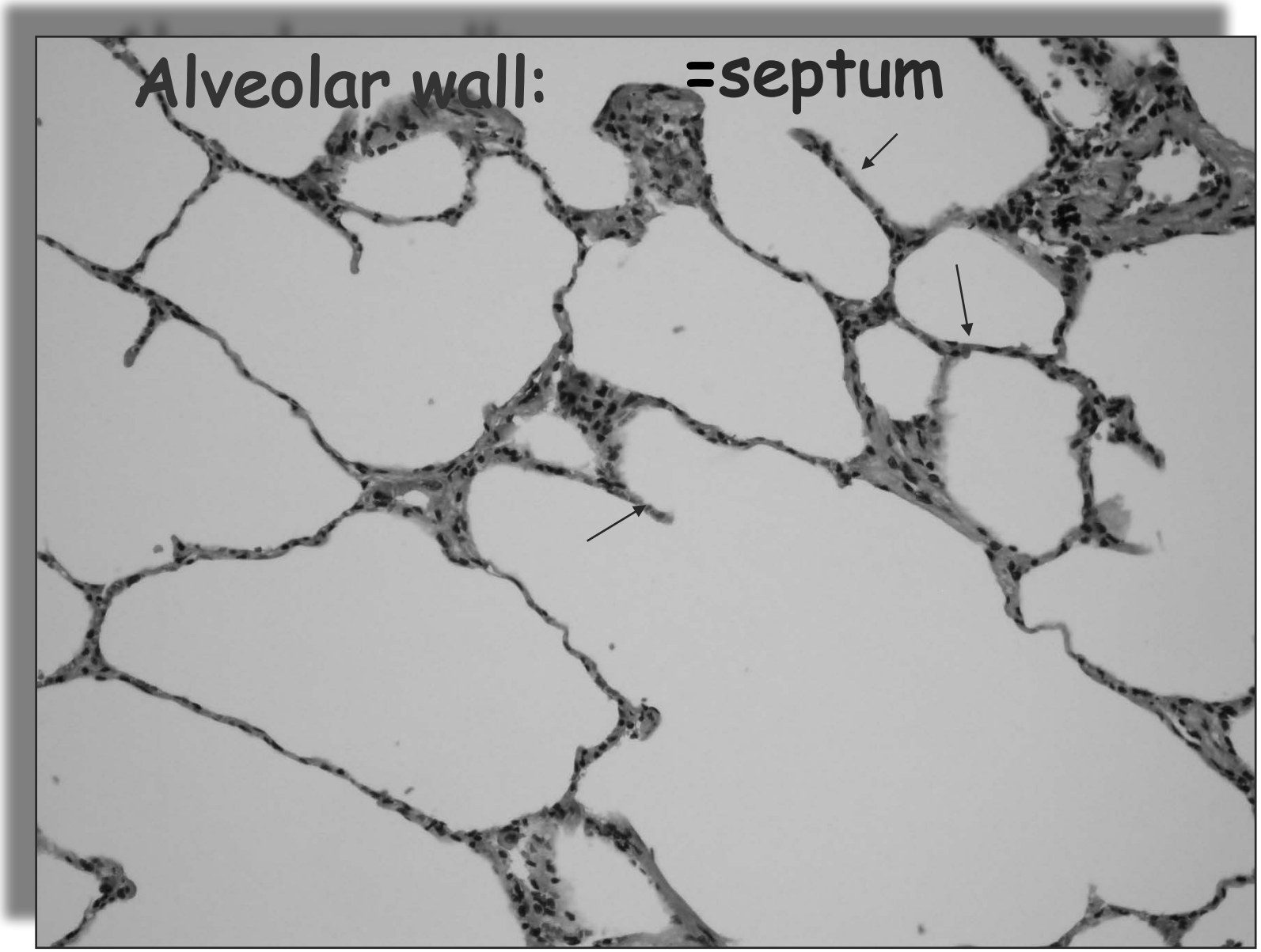
Alveolar wall: =septum

Alveolar septum epithelial cells:-

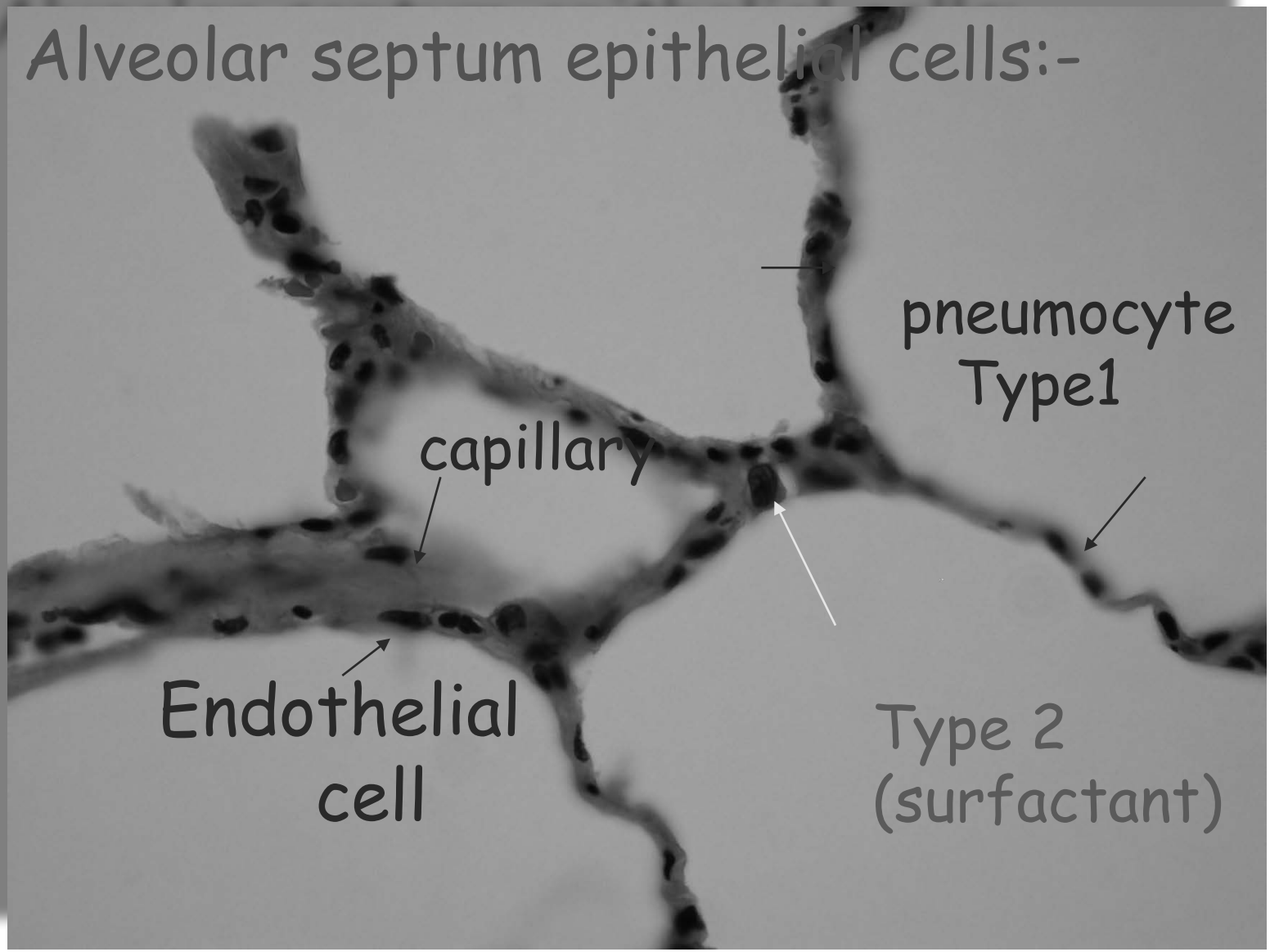

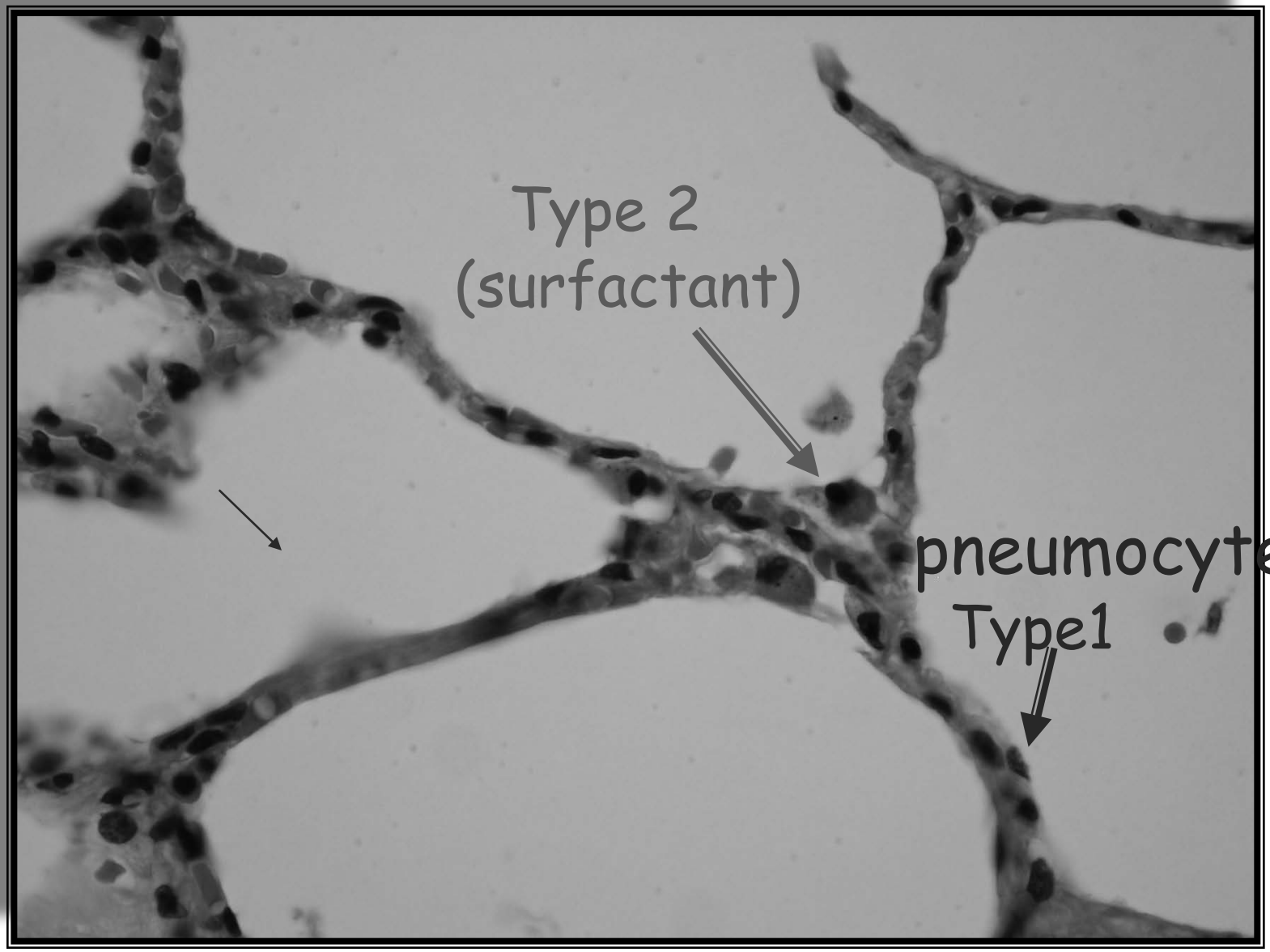
Type 2
(surfactant)
pneumocyte
Type1

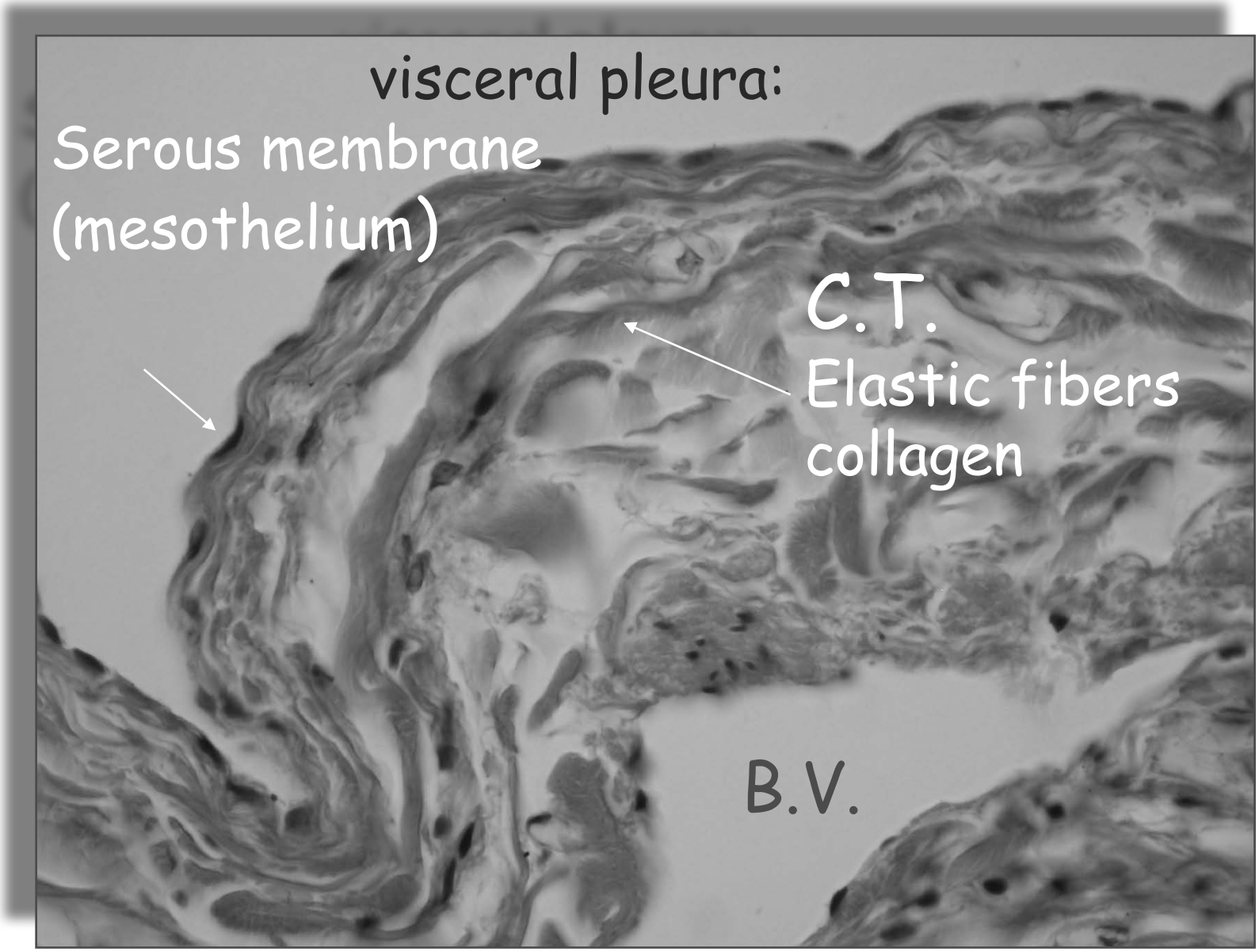
visceral pleura:
Serous membrane
(mesothelium)
C.T.
Elastic fibers
collagen
B.V.
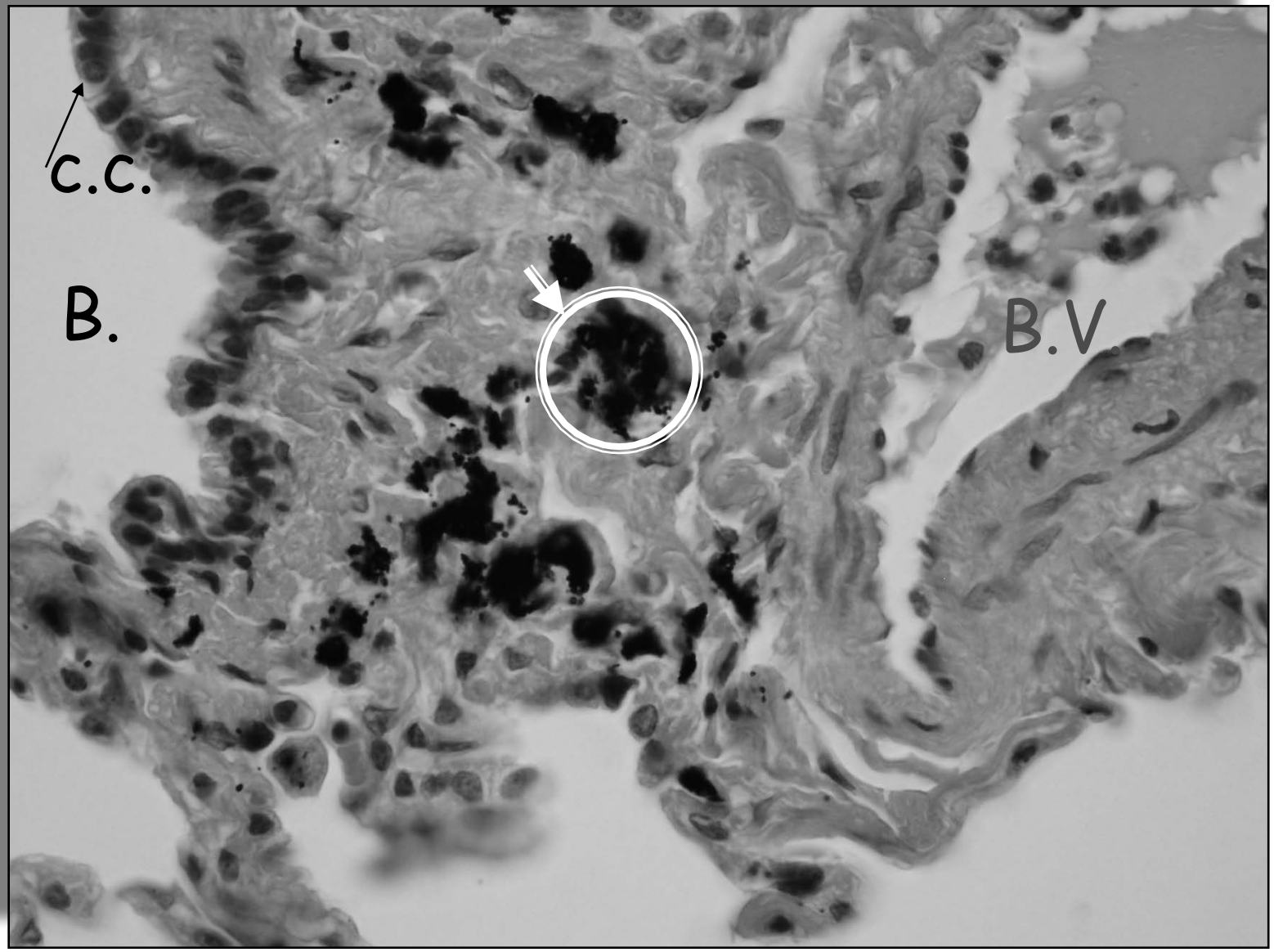
Alveolar macrophage= dust cells