Female Reproductive System

Ovary: cortex&medulla

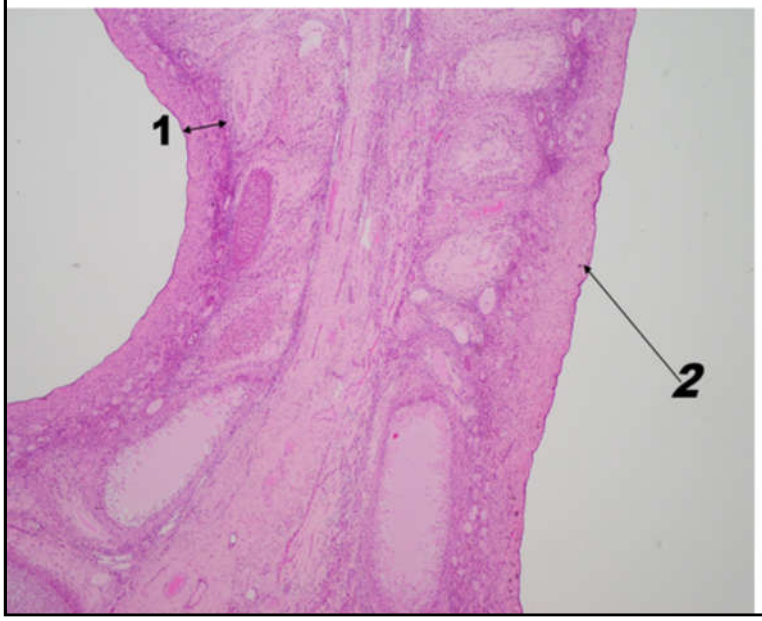

A section in the ovary (Low Magnification).

- A section in the ovary shows the outer covering, the germinal epithelium (2) and tunical albuginea (1) below it, as well as the cortex and medulla.
- The cortex contains growing follicles at various stages of development and degeneration. At this magnification, it's very hard to know the stage of the follicle.

  - The free surface of the ovary is covered by a single layer of cuboidal cells that constitute the germinal epithelium (2).

- The term "germinal epithelium" is a misnomer. The epithelium does not produce germ cells.
- Germ cells are not derived from the germinal epithelium but rather from the wall of the yolk sac.
- The basis of the formation of gonads (testes in males and ovaries in females) is the migration of primordial germ cells from the wall of the yolk sac to the genital ridge (the embryonic structure that then gives rise to the testes and ovaries). In other words, if primordial germ cells didn't migrate, the gonads will not develop.

  T or F:
  - Structure 2 plays an important role in the formation of ova.
  False. This is the germinal epithelium, that is continuous with the mesothelium lining the peritoneum, and represents modified epithelium (because it's cuboidal not simple squamous epithelium like the rest of the mesothelium).

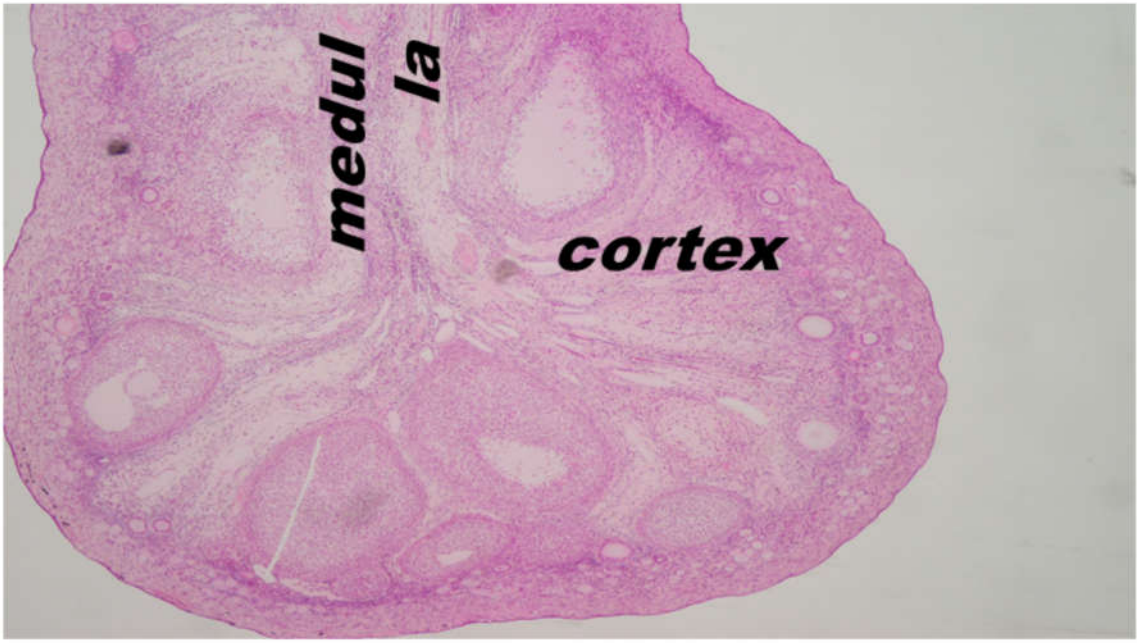
medul
la
cortex

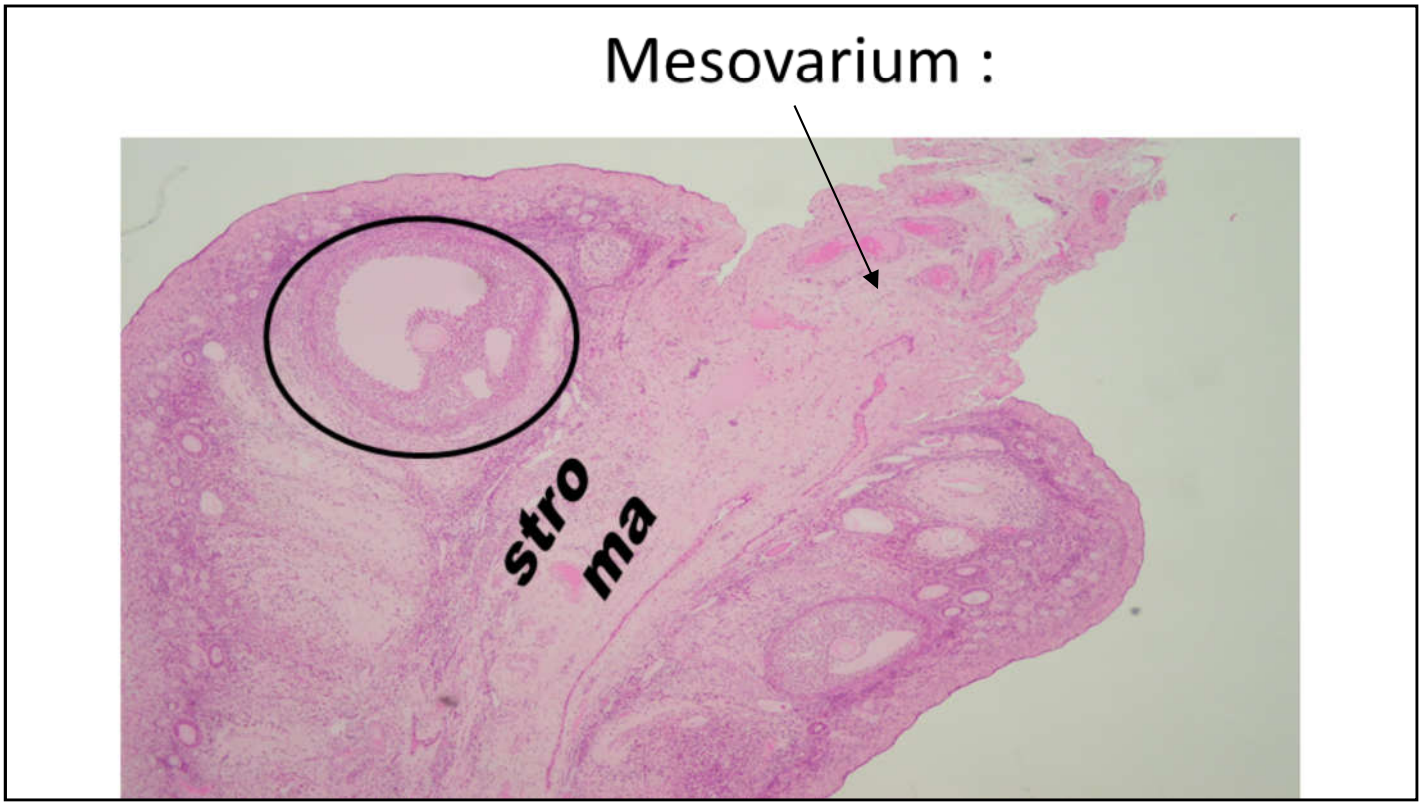

This sections shows the following:
1- Mesovarium: the mesentry of the ovary through which arterial branches to the ovary enter. It contains branches from the ovarian artery, as well as the uterine artery. In oophorectomy (surgical removal of the ovary), the surgeon should ligate the mesovarium, but not the ovarian or uterine artery (because both arteries supply structures other than the ovary, so we shouldn't

2- Secondary follicle:
- Lies in the cortex of the ovary.
- Contains more than one cavity.
How to distinguish between secondary follicle and mature Graffian follicle? We look at the number of the cavities.
One cavity + Large follicle + Ovum close to the periphery → Mature Graffian follicle
More than one cavity → Secondary follicle
- Does the formation of this follicle need FSH?
Yes. And, the need for FSH during follicular growth is as follows,
(Primordial follicle → Primary unilaminar → primary multilaminar) → These two steps don't require FSH.
(Primary multilaminar → Secondary follicle → Mature Graffian follicle) → These two steps require FSH.
- The follicle contains an oocyte. Is this oocyte primary or secondary?
Primary.
Is it mature?
Absolutely immature. It's a primary oocyte suspended in prophase of 1st meiotic

division.

- What prevents this primary oocyte from completing its first meiotic division? Oocyte maturation-inhibiting factor, produced by follicular cells (AKA granulosa cells).
- Around this secondary follicle, there is theca interna and theca externa. Theca interna cells have LH receptors and produce androgens (LH stimulates Cholesterol Desmolase). These androgens diffuse and are then absorbed by follicular cells.
- Follicular cells have FSH receptors. FSH acts on these cells and stimulates an enzyme called aromatase, that will convert androgens into estrogens.

T or F:

- Around the circled follicle, there are cells that are equivalent to Sertoli cells in males.

True. Theca interna cells

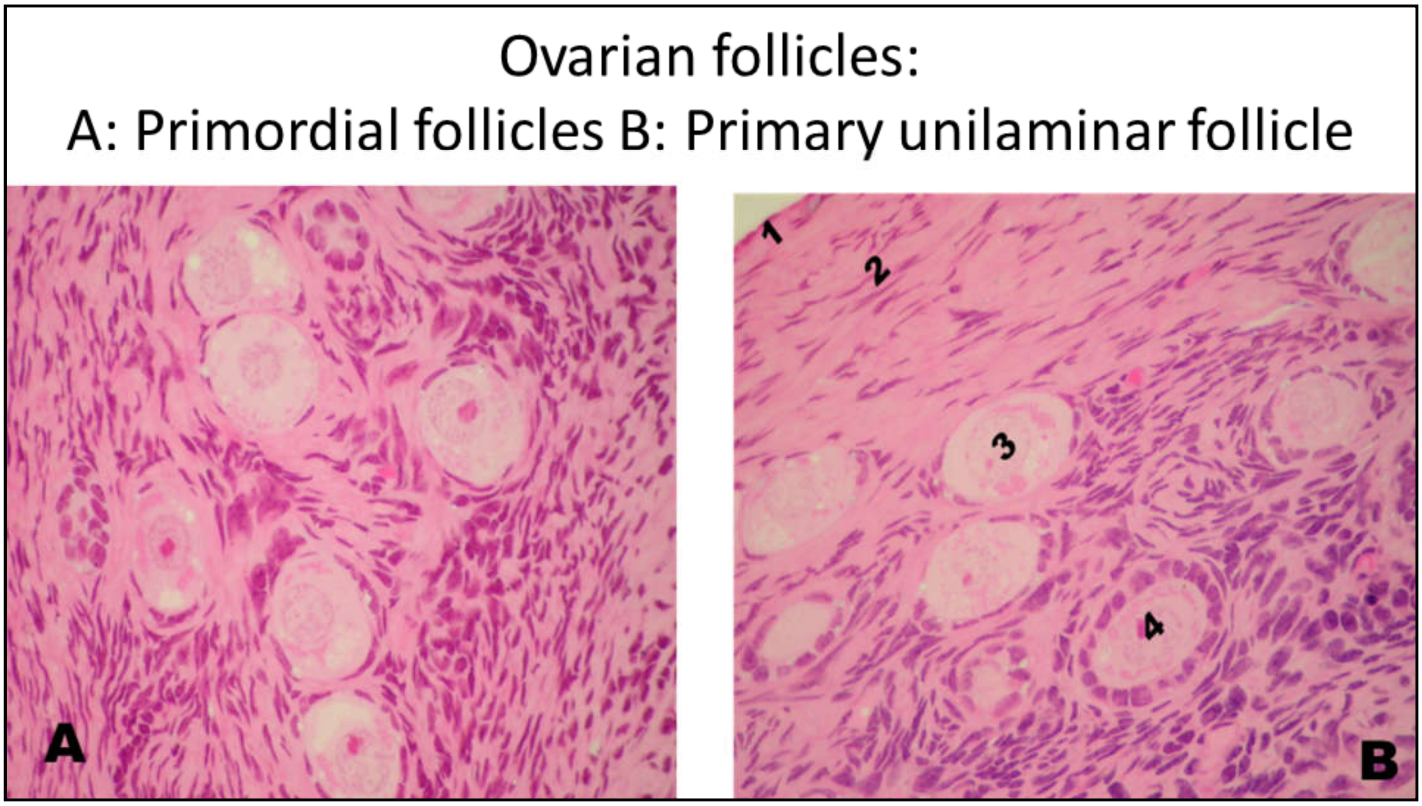

This sections shows primordial follicles.

A: Primordial Follicle
How to know that they are primordial follicles?
They are surrounded by flattened cells (simple squamous epithelium).

- The oocyte here is:
1- Immature 2- Primary oocyte suspended in prophase of 1st meiotic division.

B: Primary unilaminar follicle

Structures:
1- Germinal epithelium
2- Tunica albuginea
3- Primordial follicle (the epithelium is simple squamous epithelium)
4- Primary unilaminar follicle (the epithelium is cuboidal)

- For the follicle to grow from a primordial follicle to a primary unilaminar follicle, we don't need FSH.

What prevents the oocyte from completing the 1st meiotic division?
Oocyte maturation-inhibiting factor, produced by follicular cells (AKA granulosa cells).

- At the time of birth, the ovary contains 300,000-400,000 primordial follicle. These follicles contain primary oocytes suspended in prophase of 1st meiotic division and will remain so until the time of puberty. After puberty, each month, 7-10 primordial follicles grow. Only one of these follicles will become a mature Graffian follicle and the others will degenerate and become atretic.
  → Oocyte-maturation inhibiting factor prevents the growth of follicles during childhood (before puberty).
- Under the effect of LH (due to LH surge), one of the monthly-growing primordial follicles will become a mature graffian follicle, and the primary oocyte will complete the 1st meiotic division and become an immature secondary oocyte suspended in metaphase of 2nd meiotic division.
- The oocyte will never become mature until the time of fertilization.

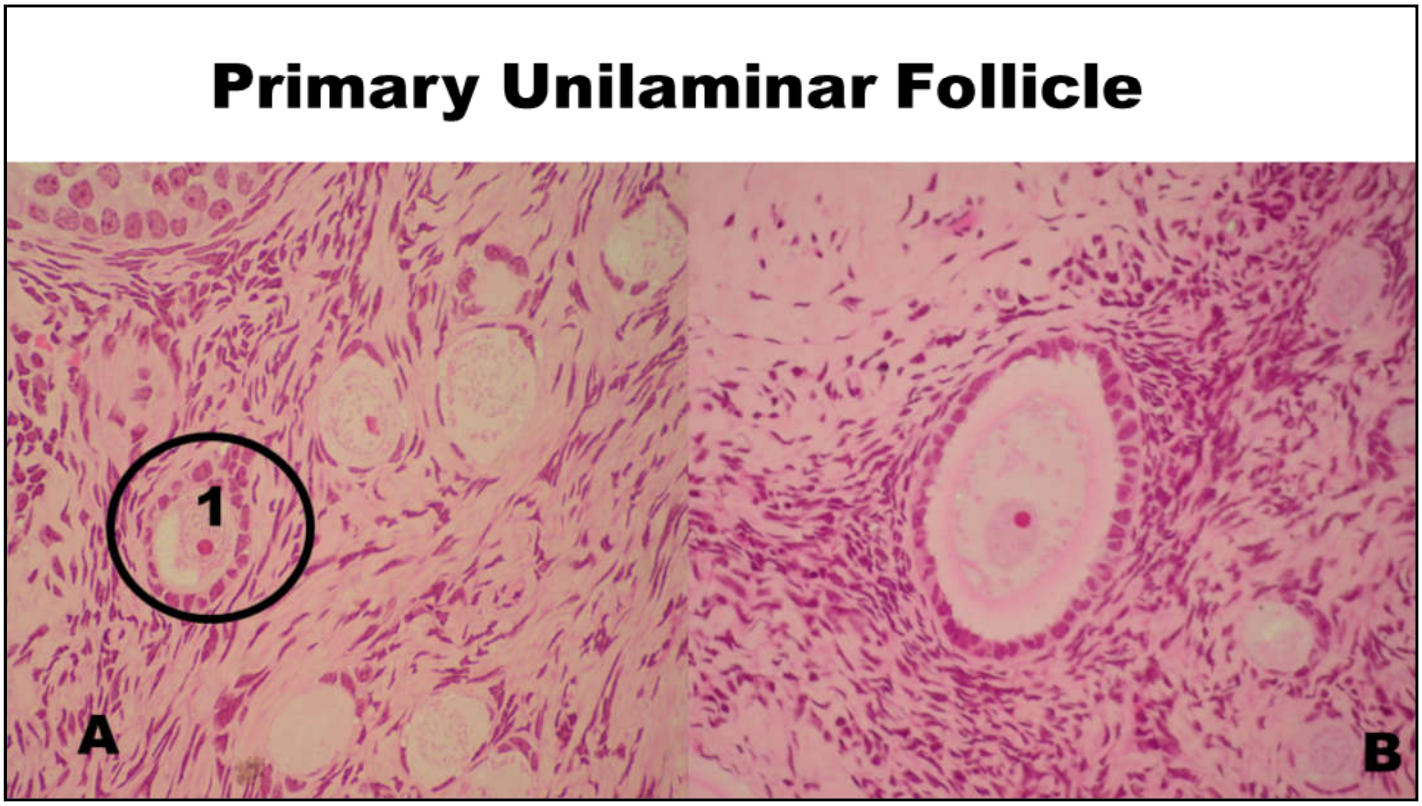

Sections A and B show primordial, as well as primary unilaminar follicles.

A:
1- Primary unilaminar follicle.
The oocyte is still immature primary oocyte suspended in prophase of 1st meiotic division.

B: Primary unilaminar follicle
- Follicular cells become cuboidal.
- Zona pellucida around the oocyte starts to develop.

- What happens for the primordial follicle to develop into a primary unilaminar follicle?
  1- The oocyte increases in size.
  2- Increase in number of golgi apparatus, RER, and ribosomes.
  3- Zona pellucida starts to develop between the oocyte and the surrounding follicular cells.
  4- The flattened follicular cells become cuboidal to columnar.
  5- The adjacent stroma starts to form theca interna and theca externa.

  - Here, we can see the nucleus and nucleolus.
- -

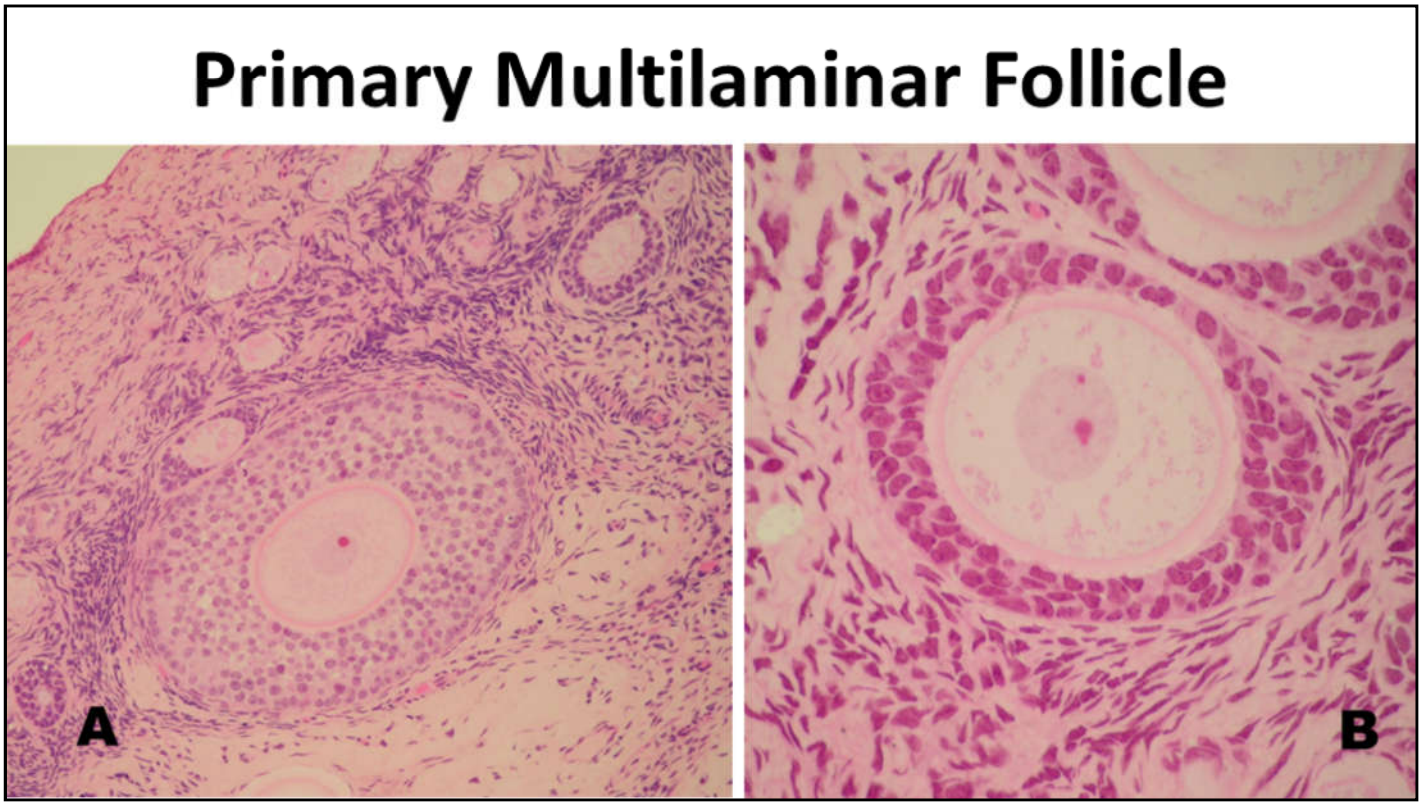

- In which part of the menstrual cycle do these follicles grow?
  In the proliferative phase or the follicular phase (Preovulatory).
- During the proliferative phase, ovarian follicles are growing. As they grow, follicular cells increase in number and the follicle increases in size. Therefore, the follicle produces progressively increasing amounts of estrogen that aid in the proliferation of the endometrium (hence the name, proliferative phase).
- The estrogen that these follicles produce is 17-β- estradiol, the most important and potent estrogen. How do follicles produce estrogen?

Theca interna, under the effect of LH, produces two androgens; a weak androgen (androstenedione), and a strong androgen (testosterone). These androgens are absorbed by the follicular cells (granulosa cells) to be transformed into estrogen under the effect of aromatase, an enzyme induced by FSH.

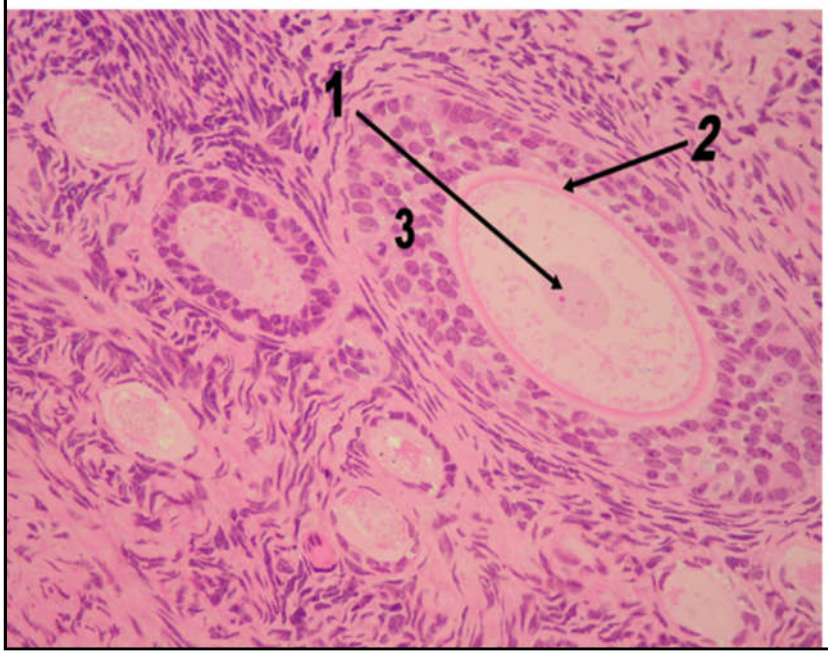

Primary Multilaminar Follicle:

1- Oocyte:
Primary oocyte suspended in prophase of 1st meiotic division.

2- Zona pellucida:
A glycoprotein membrane between the oocyte and the surrounding follicular cells.
It's one of the layers that should be penetrated by the sperm during fertilization.

3- Follicular cells

T or F:
1- Structure 3 has FSH receptors and produces estrogen.
True. Follicular cells contain aromatase enzyme and converts androgens into estrogen.

Secondary Follicle

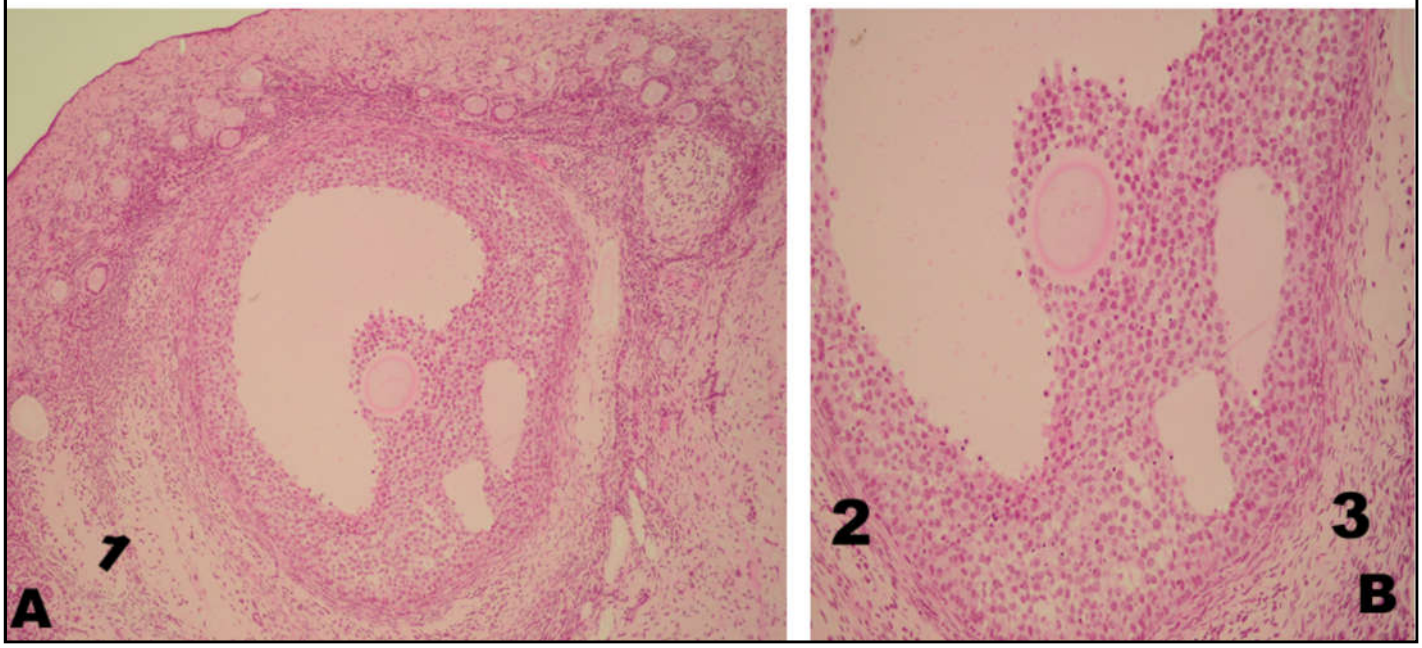

These two sections show secondary follicles:

A: A secondary follicle.
- This follicle contains more than one cavity.
- The oocyte is still a primary oocyte suspended in prophase of 1st meiotic division.
- This follicle is FSH dependent. (It needs FSH to develop from the primary follicle)
- Note: Before ovulation, Follicular cells have FSH receptors, but at one time, they will have acquire LH receptors the effect of FSH and Estrogen (LH receptor will induce the follicle to transform into corpus luteum after ovulation).
- Note: Follicular cells of the maturing follicle (primary or secondary) secrete inhibin, which will inhibit FSH release (negative feedback) along with estrogen. (But remember that at the middle of the cycle the estrogen will induce the release of FSH and LH)

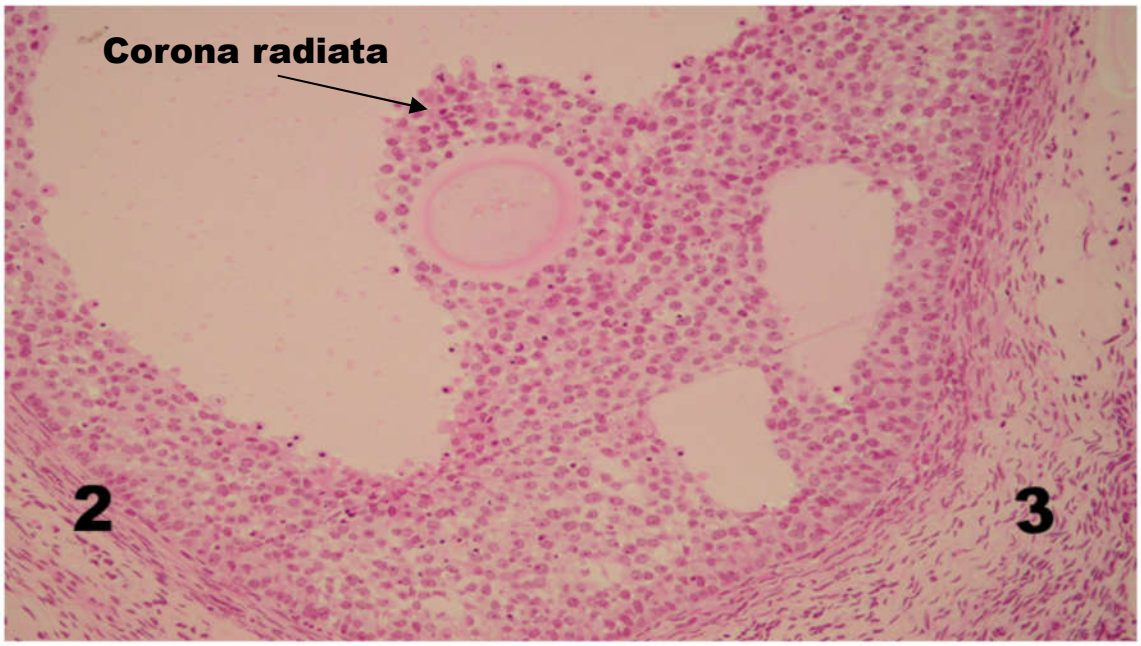
Corona radiata
2
3

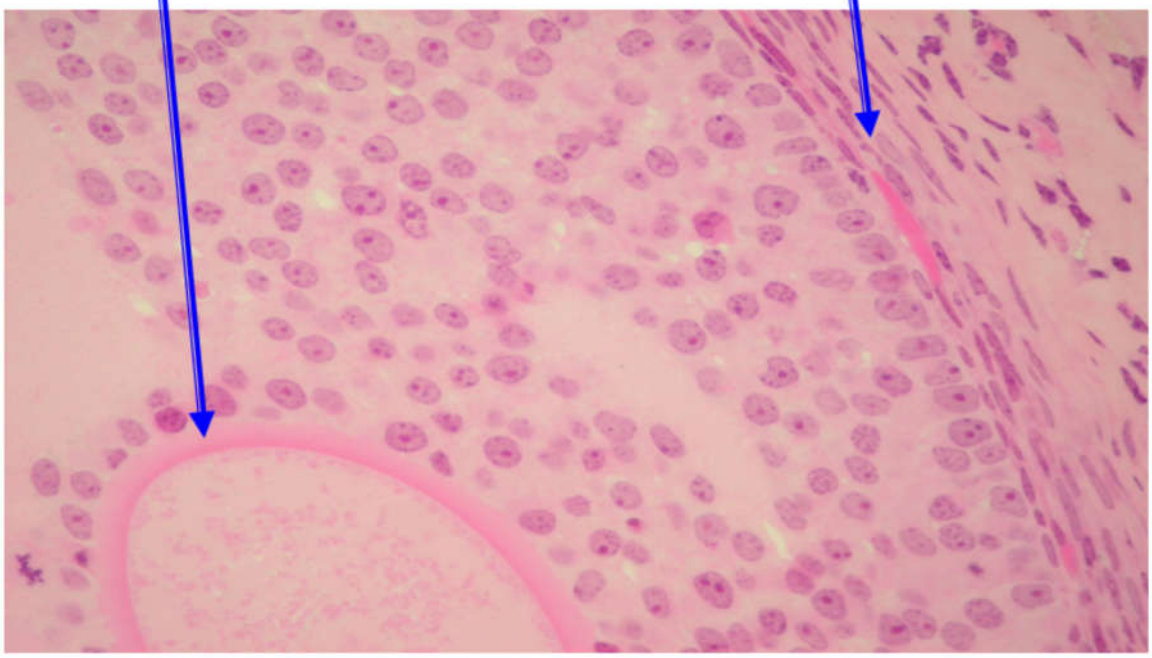
zona pellucid
theca Interna

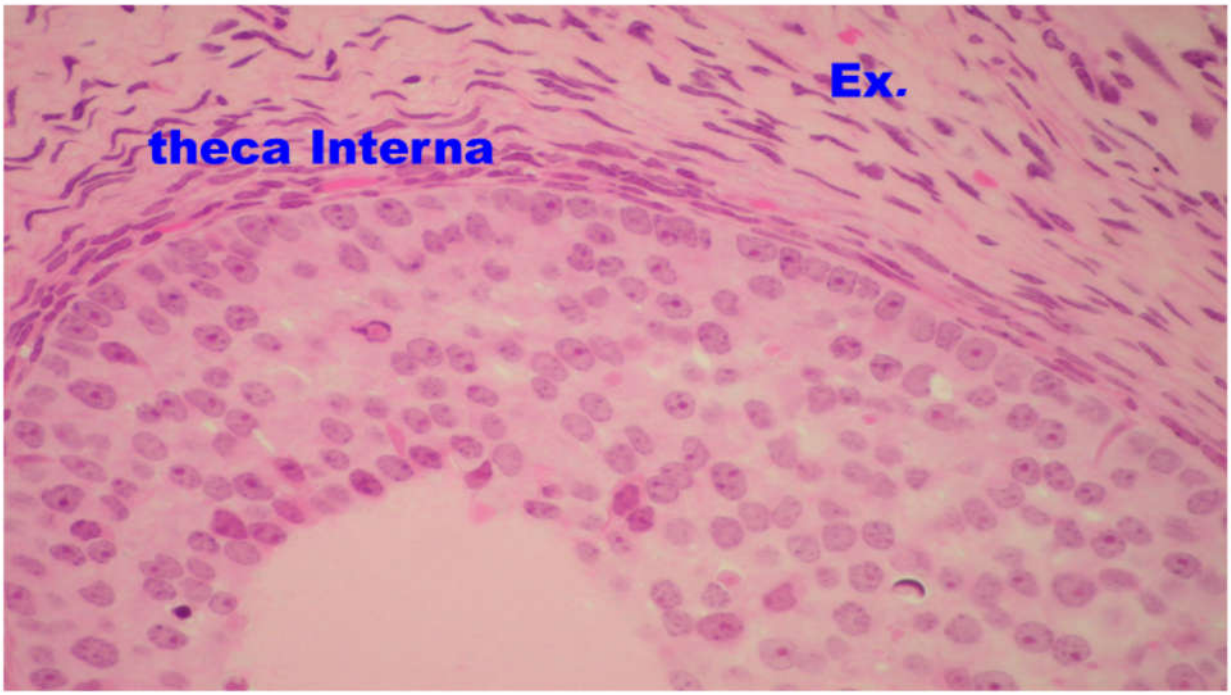
Ex.
theca Interna

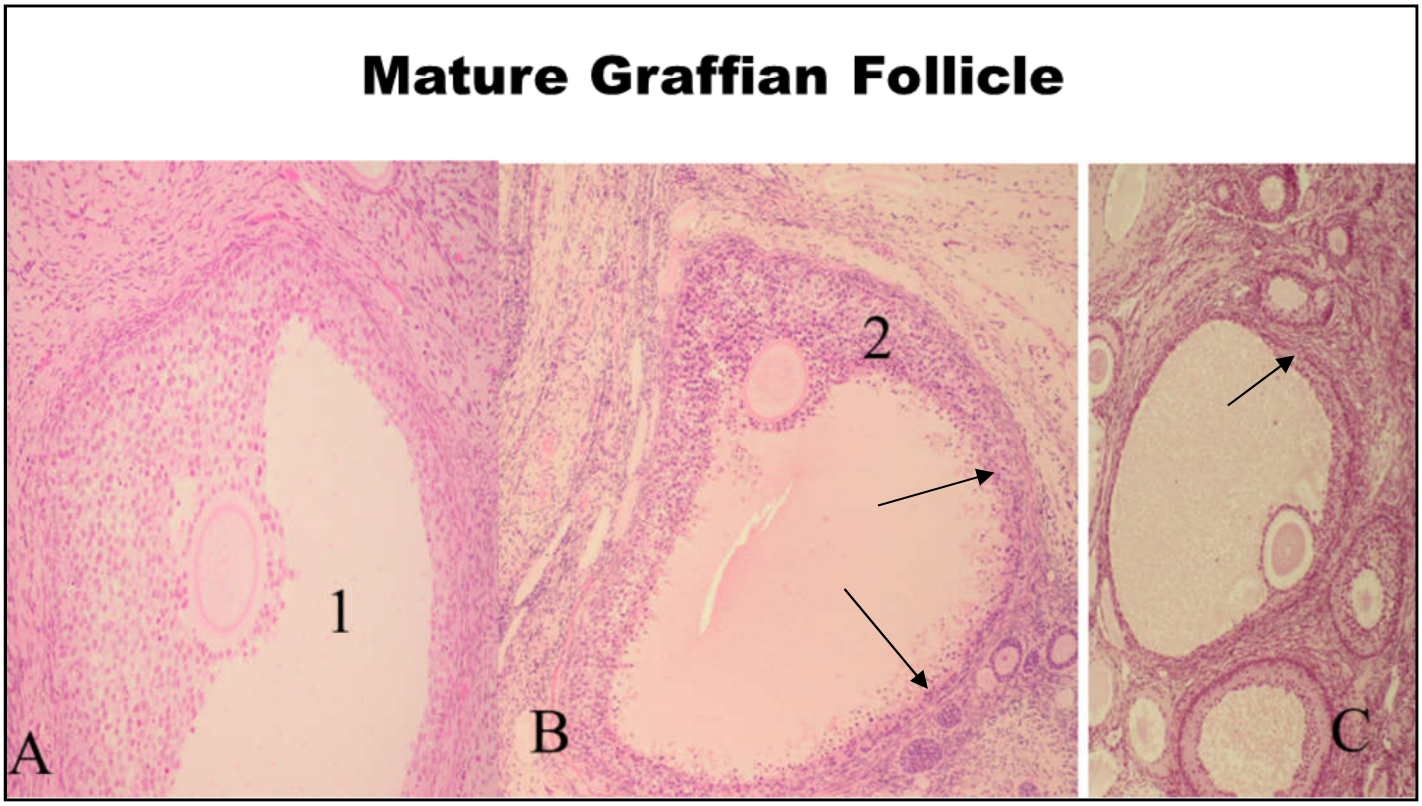

- Mature Graffian follicle:
  In A, B, and C, there is a single cavity called follicular antrum. The presence of only one cavity means that it's mature Graffian follicle.

- In the mature Graffian follicle, the ovum is eccentric (close to the wall) making it ready for ovulation.
- A: Although the ovum is not very close to the periphery, it's considered mature Graffian follicle because it contains only a single cavity, the antrum.
  1: This cavity is a single antrum full of liquor folliculi (follicular fluid).

- B & C: These are more typical mature Graffian follicles. The ovum is on the periphery.
- The surrounding cells are called corona radiata; a barrier that should be penetrated by sperms during fertilization.
- The cells that connect the ovum to the wall of the follicle are called comulus oophorus

- The cells on the wall are called membrana granulose (arrow).
- What's the type of ovum in this follicle?
  1-2 days before ovulation, one follicle becomes a mature Graffian follicle. At this stage, the ovum is still a primary oocyte suspended in prophase of 1st meiotic division and is considered an early mature Graffian follicle.

A few hours before ovulation, and under the effect of LH surge, the oocyte completes the 1st meiotic division and becomes a secondary oocyte suspended in metaphase of 2nd meiotic division.

What's the type of the ovulated ovum?
Immature secondary oocyte suspended in metaphase of 2nd meiotic division.

When does it complete the 2nd meiotic division?
At the time of fertilization.

- The hormone responsible for completing the first meiotic division is LH.
- The most important function of LH surge is completion of the 1st meiotic division, transforming the primary oocyte into a secondary oocyte.
- Ovulation is the release of a secondary oocyte from the late Graafian follicle.
- Growing follicle in the first half of the menstrual cycle produce increasing amounts of estrogen. This estrogen is responsible for the proliferative phase of the menstrual cycle. It increases the size and number of endometrial glands.
- Estrogen is responsible for repair and regeneration of the endometrium during the first half of the menstrual cycle.

- What's the cause of LH surge at the middle of menstrual cycle?
  At midcycle, estrogen has positive feedback effect on LH secretion from the anterior pituitary.

Corona radiata comulu oophorus

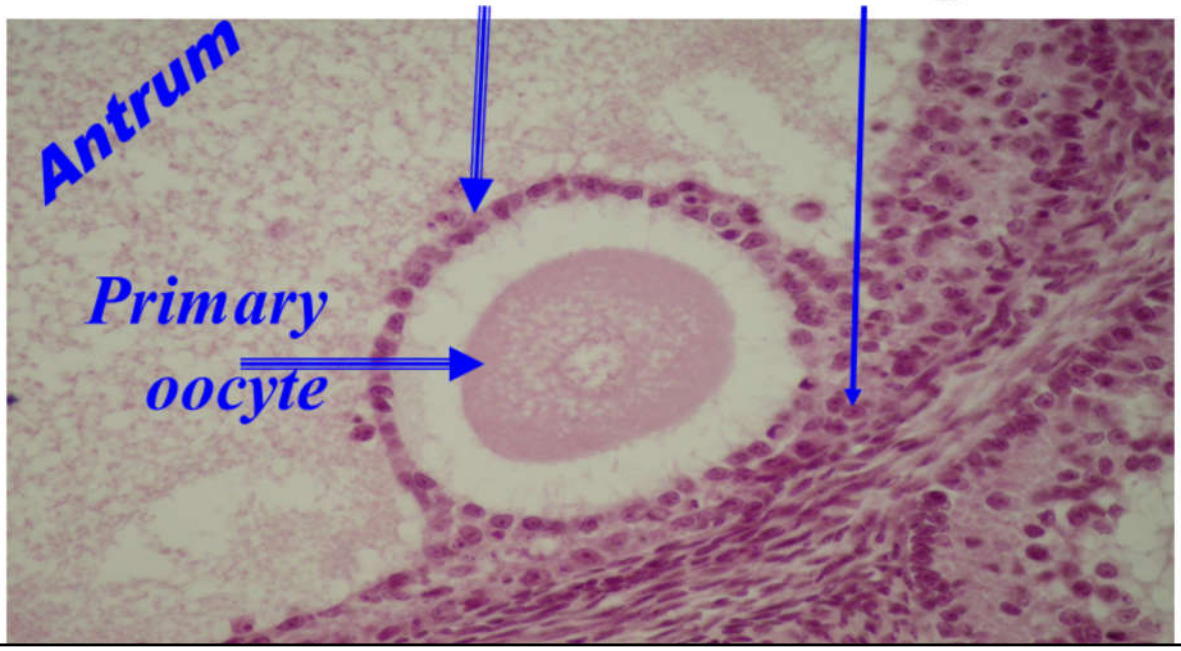

Atretic follicle:

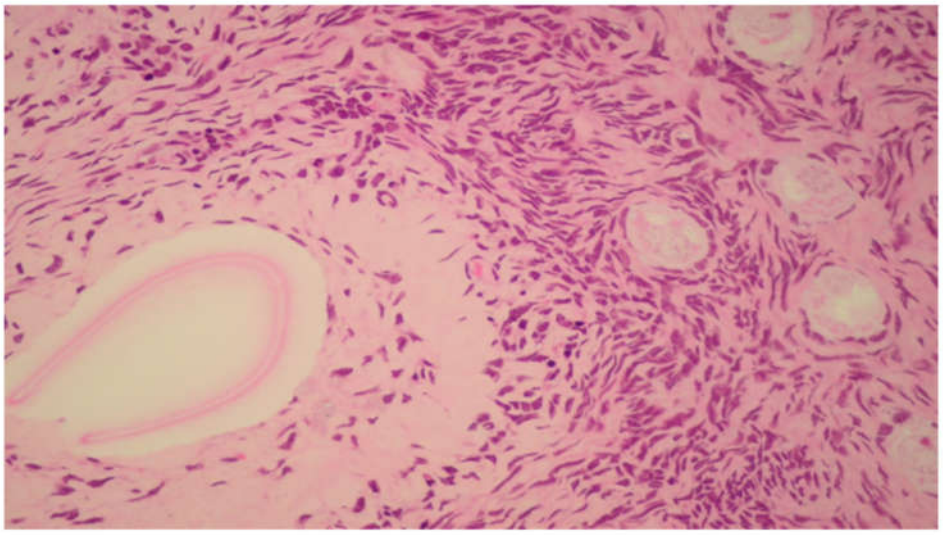

Atretic follicle: Degeneration of developing follicles (of any stage).

- Granulosa cells and theca cells disappear.
- The basement membrane between granulosa cells and theca interna persists for a longer time than do granulosa and theca cells, forming a glassy membrane.
- Glassy membrane is characteristic of atretic growing follicle, and indicates that atresia has occurred at an advanced stage
  → When a primordial or a primary follicle become atretic, there's no glassy membrane.

→ When a primary multilaminar or a secondary follicle becomes atretic, there's a glassy membrane.

Corpus luteum:

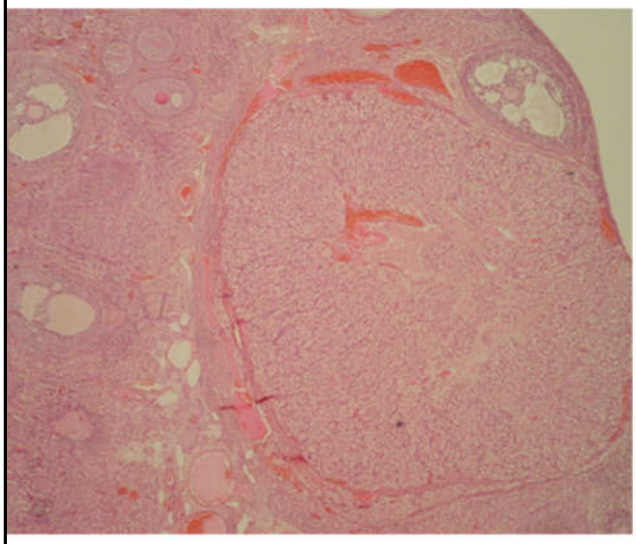

- Corpus luteum is a temporary endocrine gland.
- Formed of granulosa cells and theca interna cells that remain in the ovary after ovulation (i.e. the secondary oocyte surrounded by corona radiata is ovulated, leaving behind granulosa cells and theca interna cells). Under the influence of LH surge, these remnants of Graffian follicle form the corpus luteum.
- Corpus luteum produces mainly progesterone, as well as estrogen.
- How long does it survive?
  The corpus luteum survives for 14 days if there's no pregnancy. If there is pregnancy, it will persist for 2-4 months to produce progesterone and estrogen to maintain pregnancy. After that, it degenerates and the placenta acts as a source of estrogen and progesterone.
- What's the importance of progesterone in the luteal phase?
  Preparation of endometrium for pregnancy. It increases glandular secretion and makes endometrial glands tortous.
- hCG prevents regression of corpus luteum during the first 3 months of pregnancy.
- hCG level increases in the pregnant woman 8 days after fertilization. Therefore, detection of elevated hCG helps the female know that she's pregnant even before the next menstrual cycle.
- Whenever you hear hCG, remember these three important facts:
  1- It prevents regression of corpus luteum.
  2- Pregnancy test.
  3- May be responsible for morning sickness (nausea and vomiting of pregnancy). T3 may also play a role in morning sickness.

What prevents the formation of new follicles during the second half of the menstrual cycle?
Corpus luteum produces estrogen, progesterone, and inhibin. All these three hormones show negative feedback on FSH and LH secretion. Suppression of FSH secretion prevents the formation of new follicles → During the luteal phase, no new primordial follicles develop because of decreased FSH. (The doctor emphasized mainly on inhibin)

- During the menstrual phase of the next cycle, new follicles start to develop. How does that happpen?
  Toward the end of luteal phase, the corpus luteum starts to regress → Estrogen, progesterone and inhibin levels start to decrease, and consequently FSH level increases. This increase in FSH stimulates recruitment of new follicles for the next cycle. (Also here the doctor emphasized mainly on inhibin regression)

- During the formation of corpus luteum, and under the effect of LH, granulosa cells and theca cells increase in size, and accumulate lipids in the cytoplasm. They become also rich in SER, indicating that they will become steroid-synthesizing cells. These changes will convert granulosa cells and theca interna cells to granulosa lutein cells, and theca lutein cells, respectively.

- Corpus تعني الجسم
  Luteum تعني الأصفر
  فمثلا Corpus striatum تعني الجسم المخطط و corpus albicansالجسم الأبيض و corpus luteumالجسم الأصفر
  - يسمى الجسم الأصفر لأن الخلايا المتبقية من حويصلة غراف تمتلئ بالدهون وتصبح صفراء اللون، أي أنها تصبح شبيهة بخلايا الغدة الكظرية المنتجة لل steroid hormones

Corpus Luteum

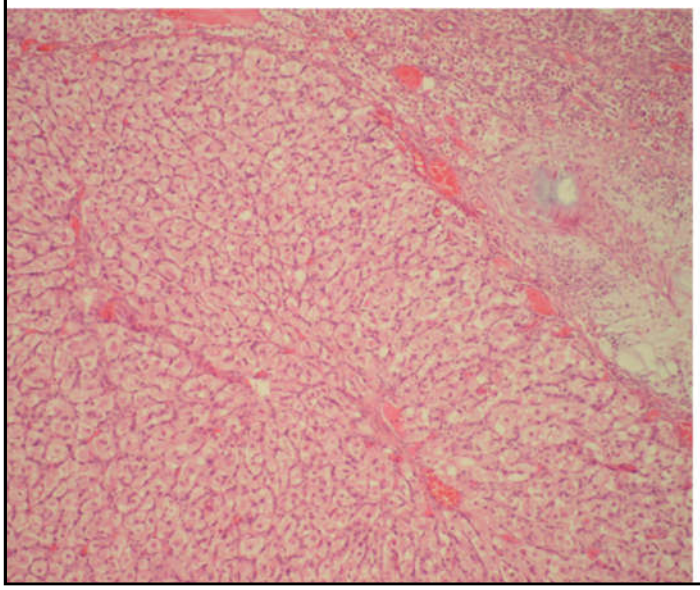

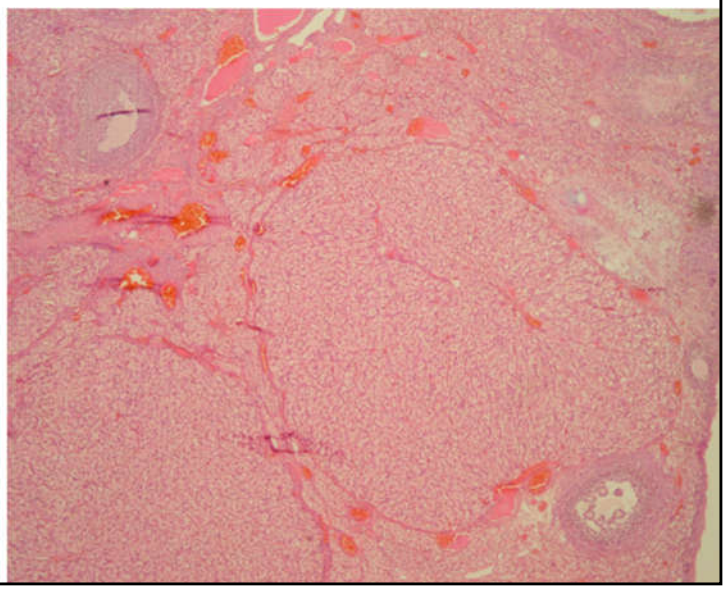

Corpus Luteum

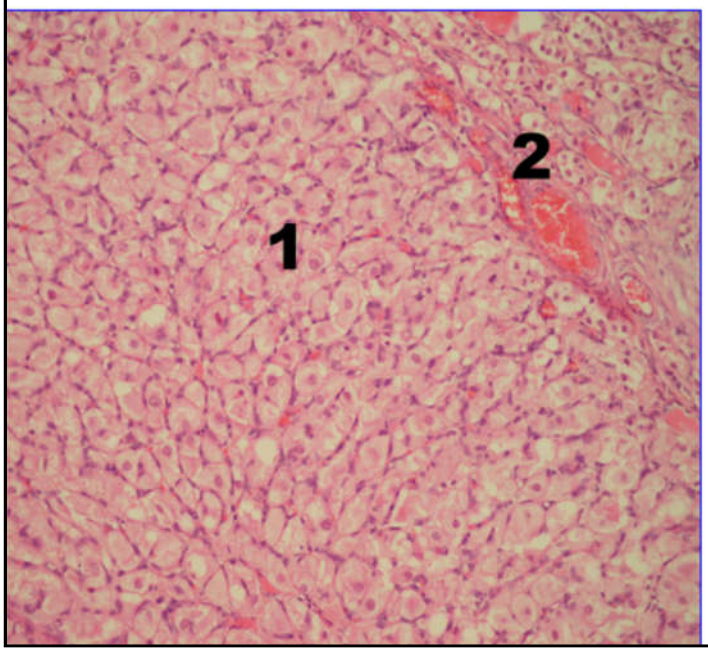

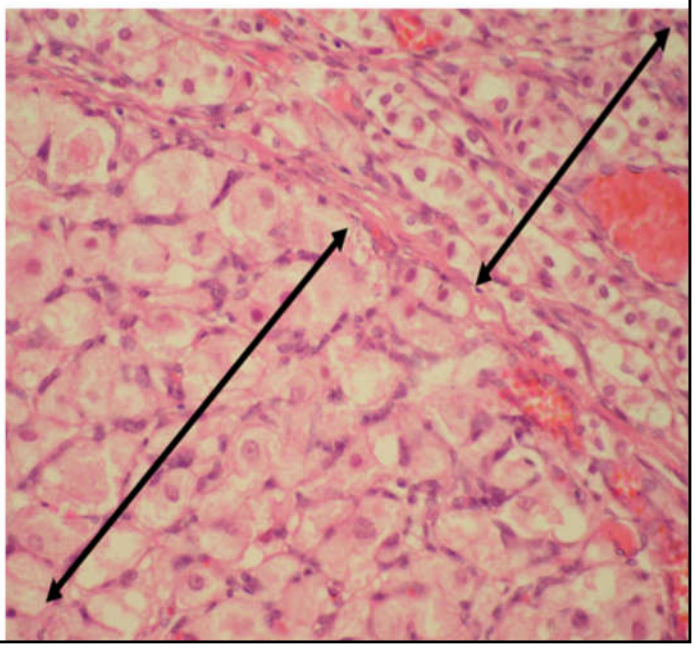

- What corresponds to this in the endometrium?
  Secretory Phase
- What corresponds to this in the pituitary?
  Decreased FSH and LH because of the negative feedback effect of estrogen and progesterone during the luteal phase.
- Describe the endometrial glands at this stage.
  They are rich in secretions and tortous under the effect of progesterone produced from the corpus luteum.

- Estrogen and progesterone are produced from both theca lutein cells and granulosa lutein cells (mainly by granulosa lutein).

1 → Granulosa lutein cells
2 → Theca lutein cells

Corpus albicans

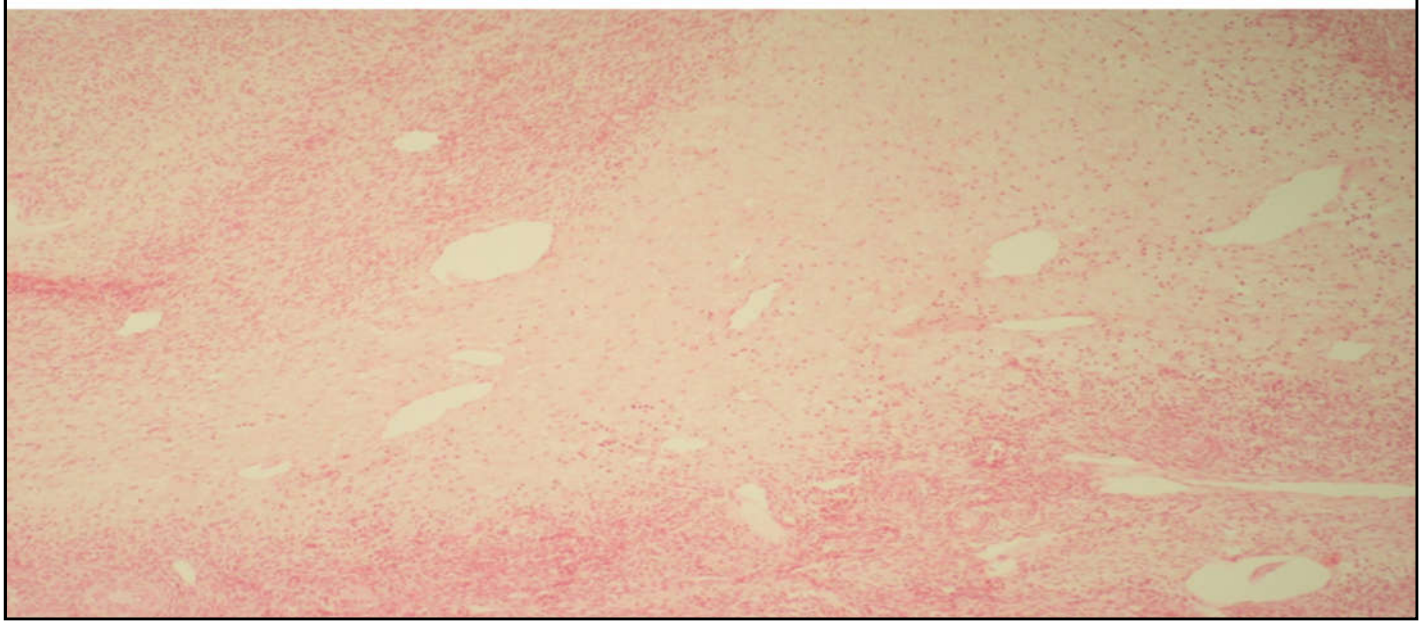

- If the ovum is not fertilized, the corpus luteum persists for only 14 days and then undergoes involution.

- When the corpus luteum involutes, it's replaced by an irregular white scar called, corpus albicans (الجسم الأبيض).
- A dominant feature of the human ovary is that it contains many corpora albicantia. These represent the degenerated corpora lutea of the previous menstrual cycles.
- The corpus albicans doesn't persist for the entire life. It disappears over the following months.

أي أن مبيض امرأة عمرها 45 سنة لا يحتوي على مئات الأجسام البيضاء لكل دورة شهرية مرت عليها في حياتها، وإنما يحتوي على الأجسام البيضاء الناشئة من الأجسام الصفراء لآخر بضعة أشهر فقط.

- The scar is made of Collagen type 1.

Uterine Tube

Labyrinth Mucosa

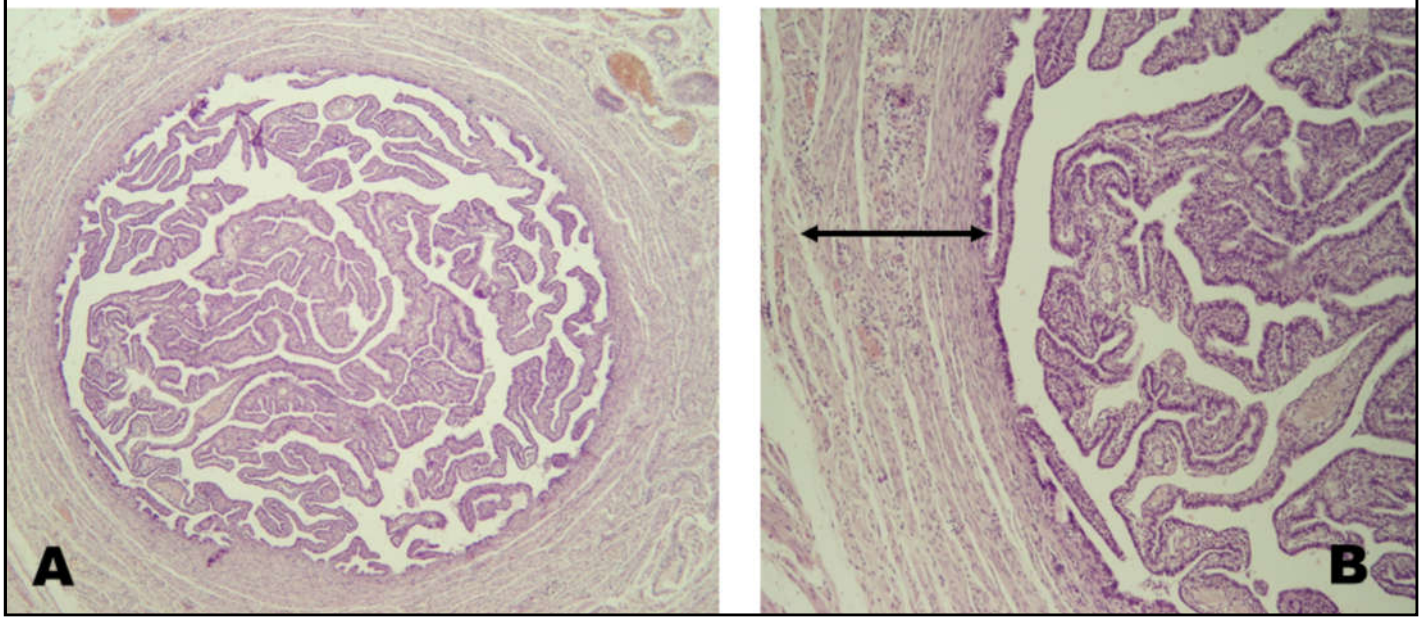

- The uterine tube is a narrow tube that transmits the ovum from the ovary to the uterus. Its diameter is the widest in the ampulla (4 mm) and the thinnest in the intramural part (1 mm).
- Layers of uterine tube: Mucosa (highly folded) → muscular layer → serosa (visceral peritoneum lined by simple squamous epithelium).
- The mucosa is highly folded. It contains numerous longitudinal folds that branch into secondary and tertiary folds, especially in the ampulla.

- In section A, the mucosa lining the ampulla of uterine tube is highly folded and resembles a labyrinth (متاهة).
- This highly folded mucosa makes the uterine tube narrower.
- Being narrow, any infection (for example, gonorrhea) affecting the uterine tube causes obstruction. Obstruction of the uterine tube prevents the movement of the ovum, causing infertility.
  Dr. Faraj called it "Natural Contraception" (i.e. the female will not get pregnant, even without taking contraceptives or using IUD).

B:
- The mucosa is highly folded.
- Muscular layer: Inner circular and outer longitudinal.
- Serosa

Epithelial lining of Mucosa

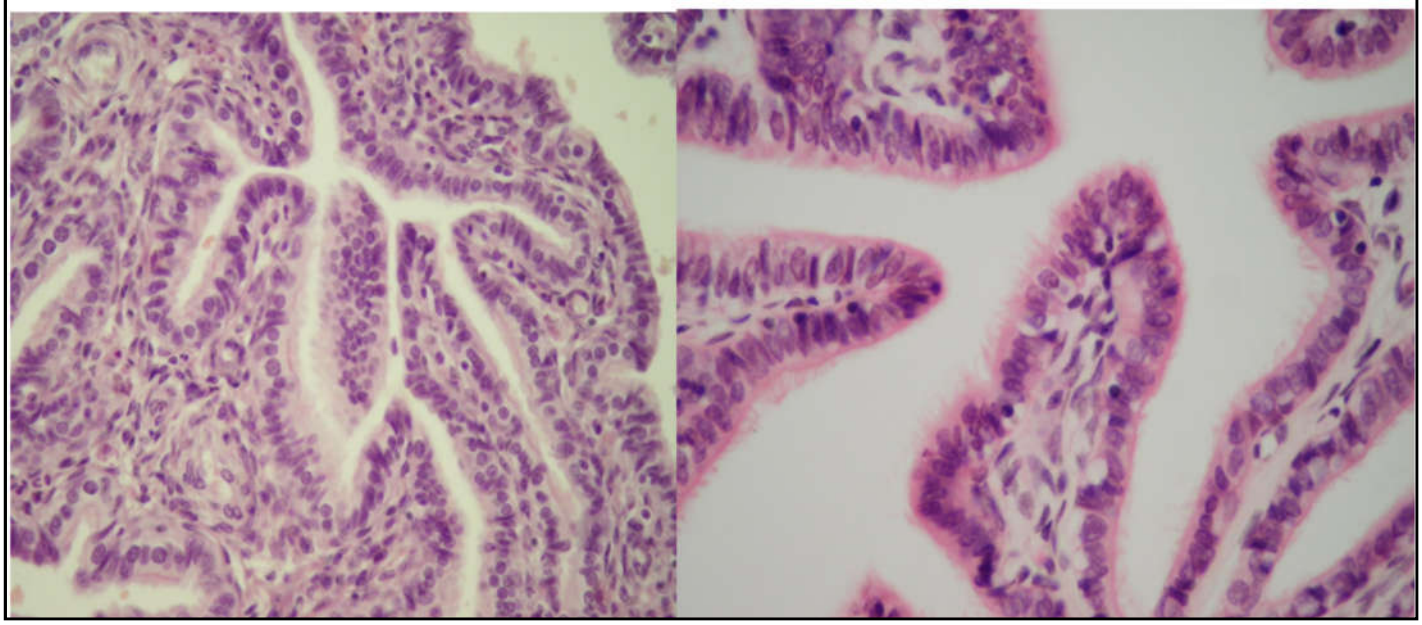

- The epithelial lining of the mucosa is simple columnar epithelium. There are two types of epithelial cells:
  1- Ciliated columnar cells: responsible for ciliary movement that sweeps fluid toward the uterus.

2- Secretory peg cells (non-ciliated columnar cells). Their secretion may permit the survival of the embryo for days or weeks in the case of ectopic pregnancy.

- The ciliated columnar cells are most abundant in the fimbriae. This facilitates the movement of the ovum from the ovary to the uterine tube. Also facilitates the zygote to reach the uterus. If the cilia is damaged, this may affect fertilization or implantation.

- Case: A 30-year-old woman has given birth to two children, but failed to get pregnant thereafter despite of pregnancy attempts for 3 years.

  A possible cause of infertility is chronic salpingitis (was a common complication in the past, but with modern therapy, this is becoming a less prevalent cause of female infertility).
  Chronic salpingitis may occlude the uterine tube and damage the cilia. If cilia of ciliated columnar epithelium are damaged, the ovum will not be able to move through the uterine tube, and this would be the cause of infertility.
- How can we know if ovulation has happened or not?
  We look for progesterone level in the plasma. If elevated, this indicates that corpus luteum is producing large amounts of progesterone, and that ovulation has occurred.

- Does the mucosa of the uterine tube shows cyclic changes associated with the ovarian cycle?
  Yes.
  1- Follicular phase (Before ovulation)
  Ciliated cells increase in height, and secretory cells increase production/synthesis of secretions (in preparation for receiving the ovulated ovum).
  2- Luteal phase (After ovulation)
  Ciliated cells decrease in height and number and lose their cilia, and secretory cells increase secretion in this phase (the ovum has already been taken into the uterine tube → there's no need for cilia at this stage).

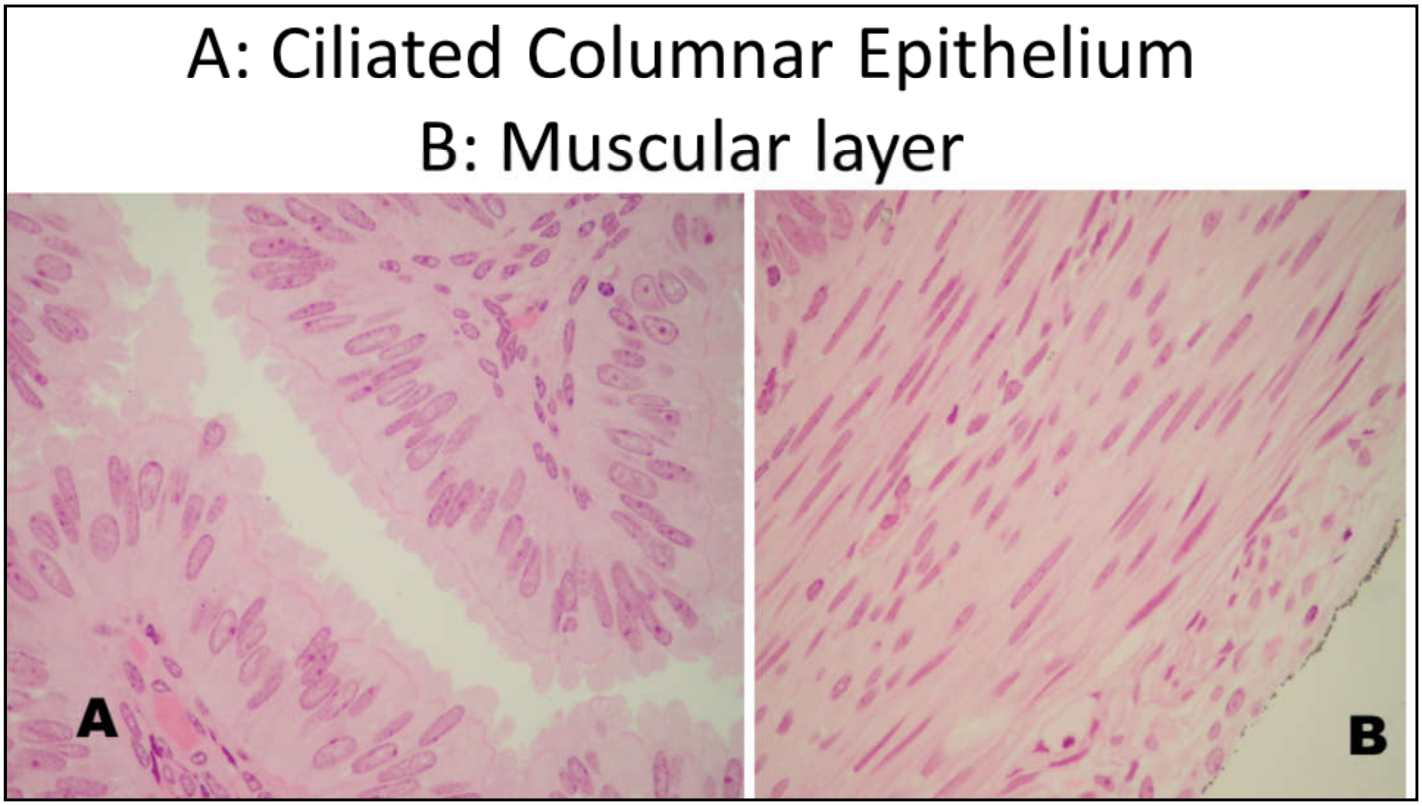

A: Ciliated columnar epithelium
B: Muscular layer

Muscular layer

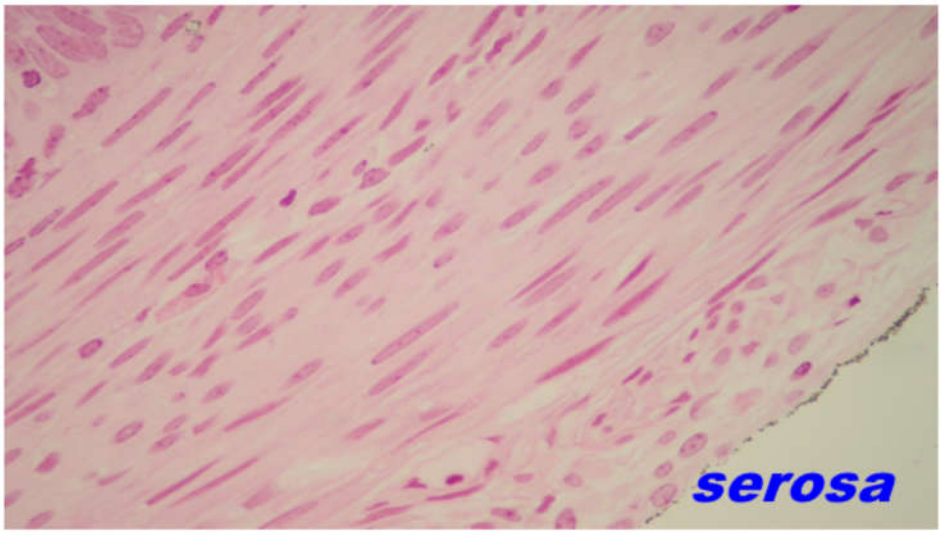

uterus:

]endometrium

Myometrium

Serosa or advent.

Proliferative phase:

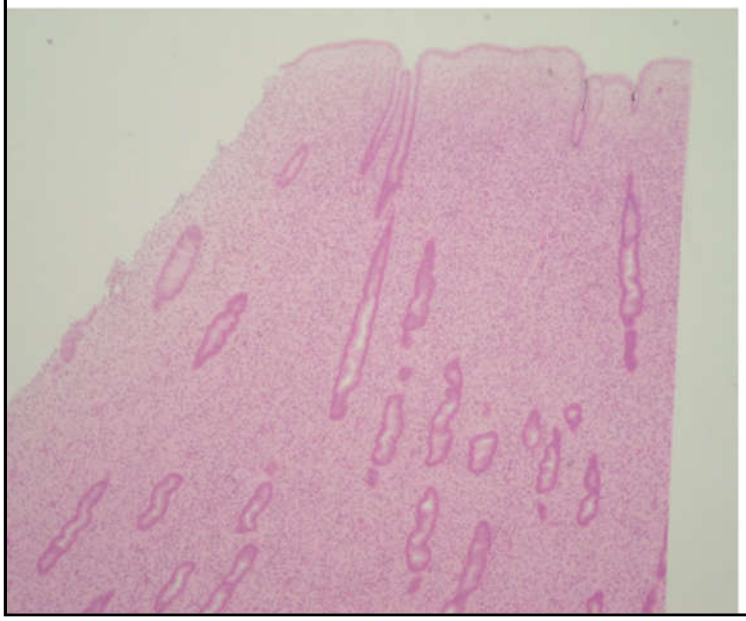

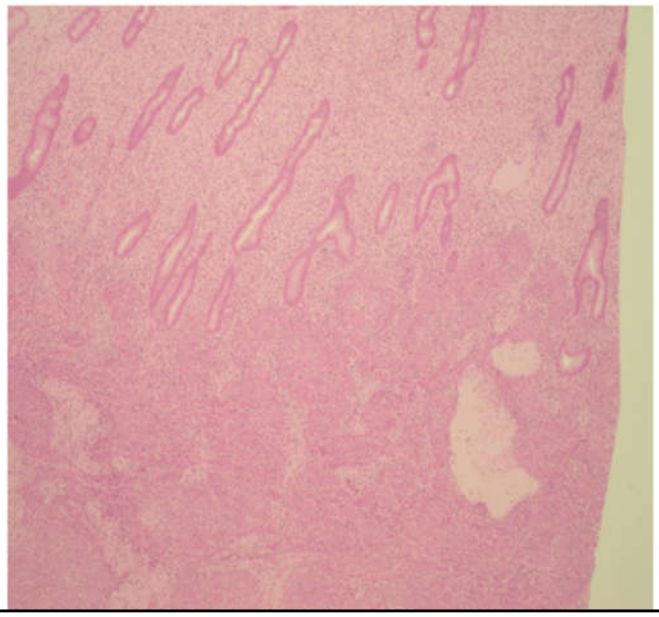

- The uterus is covered by simple columnar epithelium that contains ciliated and non-ciliated cells.
- There is no submucosa (Lamina propria lies directly on the muscularis layer).
- The epithelium dips down into the stroma, forming uterine glands.
- Uterine glands are simple tubular glands.

- When the glands are straight → Proliferative phase
- When the glands are tortous → Secretory phase

- Here, we have to link what happens in the uterus, with what's happening in the ovaries and in the pituitary.
- These two sections show straight glands → Proliferative phase
  Proliferative phase means that the endometrium is growing under the effect of estrogen, produced by the growing follicles.
- In the pituitary, there's low secretion of LH and FSH (in the first half of the menstrual cycle, estrogen causes negative feedback on the pituitary).

Uterine Glands

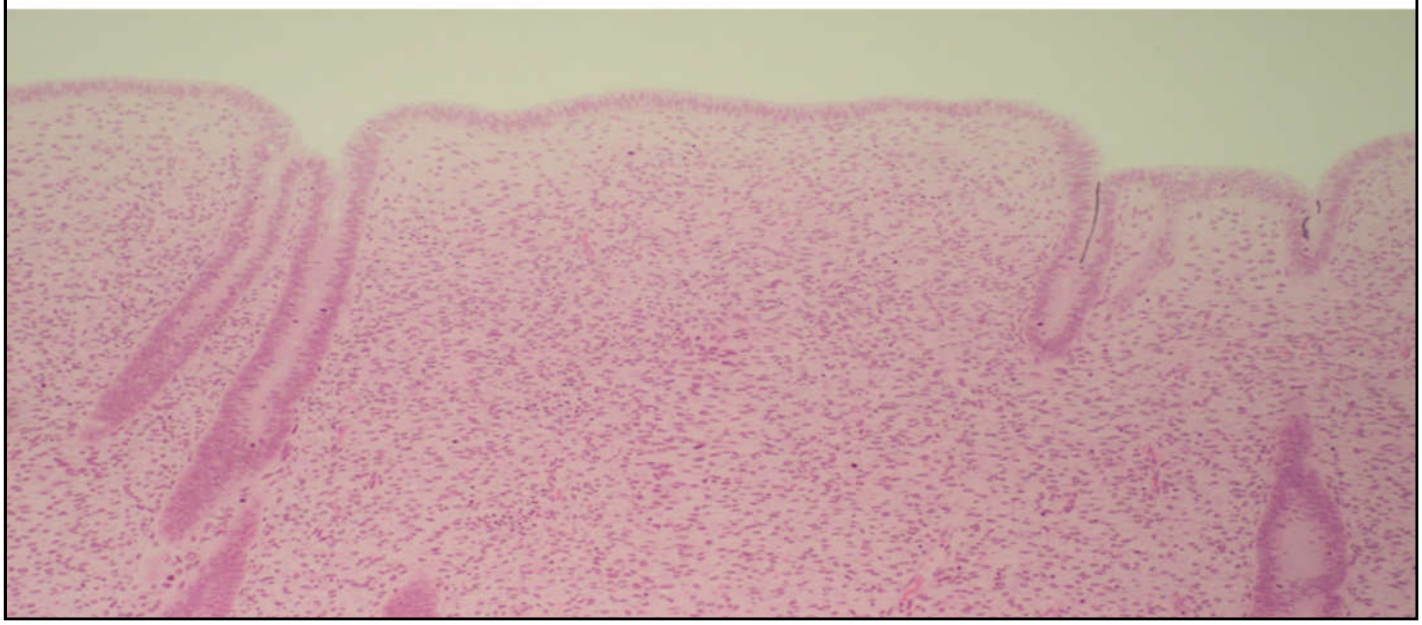

- Uterine glands are simple tubular.
- Here, the glands are straight → Proliferative phase.

Secretory phase:

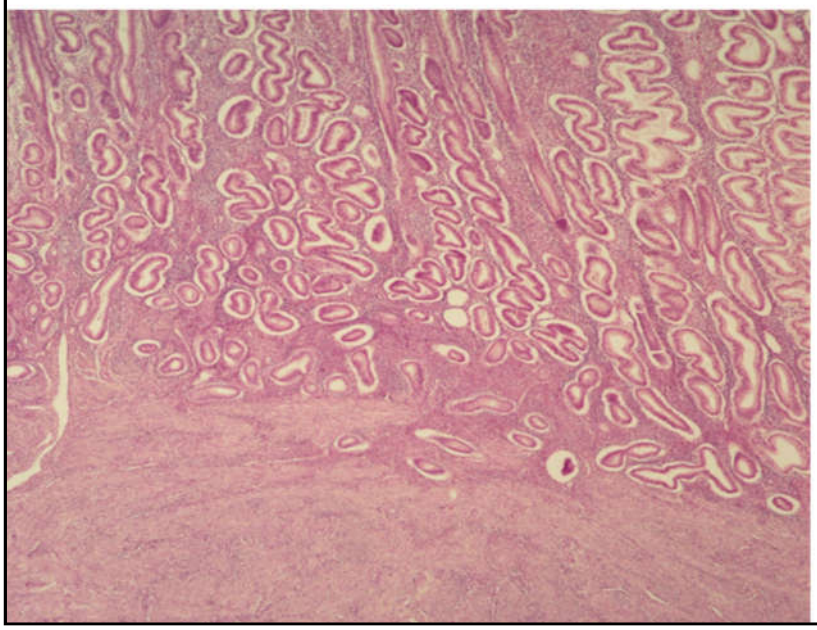

- Glands are tortous → Secretory phase.
- During this phase, there's corpus luteum in the ovary not growing follicles.
- The corpus luteum produces progesterone that does the following:
  1- Makes uterine glands rich in secretions.

2- Makes the endometrium edematous and vascular in preparation for receiving the fertilized ovum.

Coiled uterine glands:

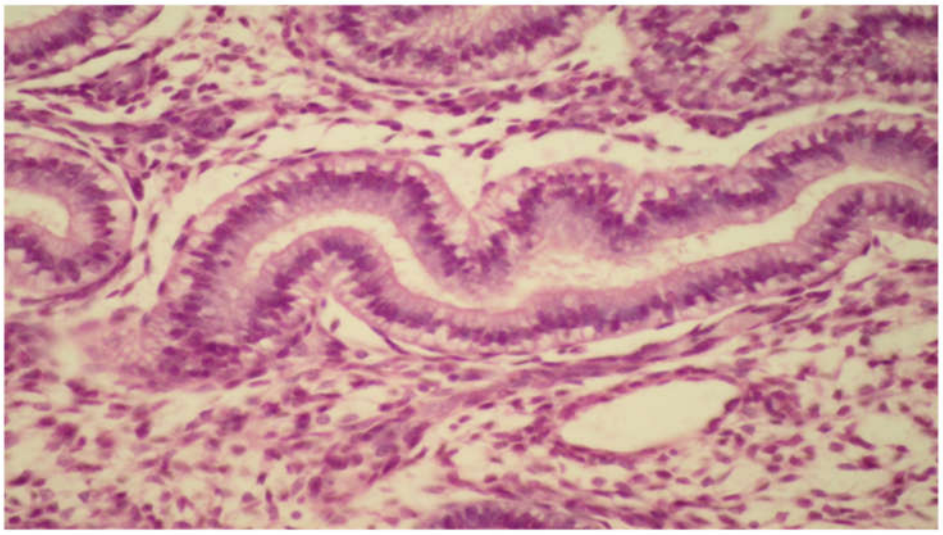

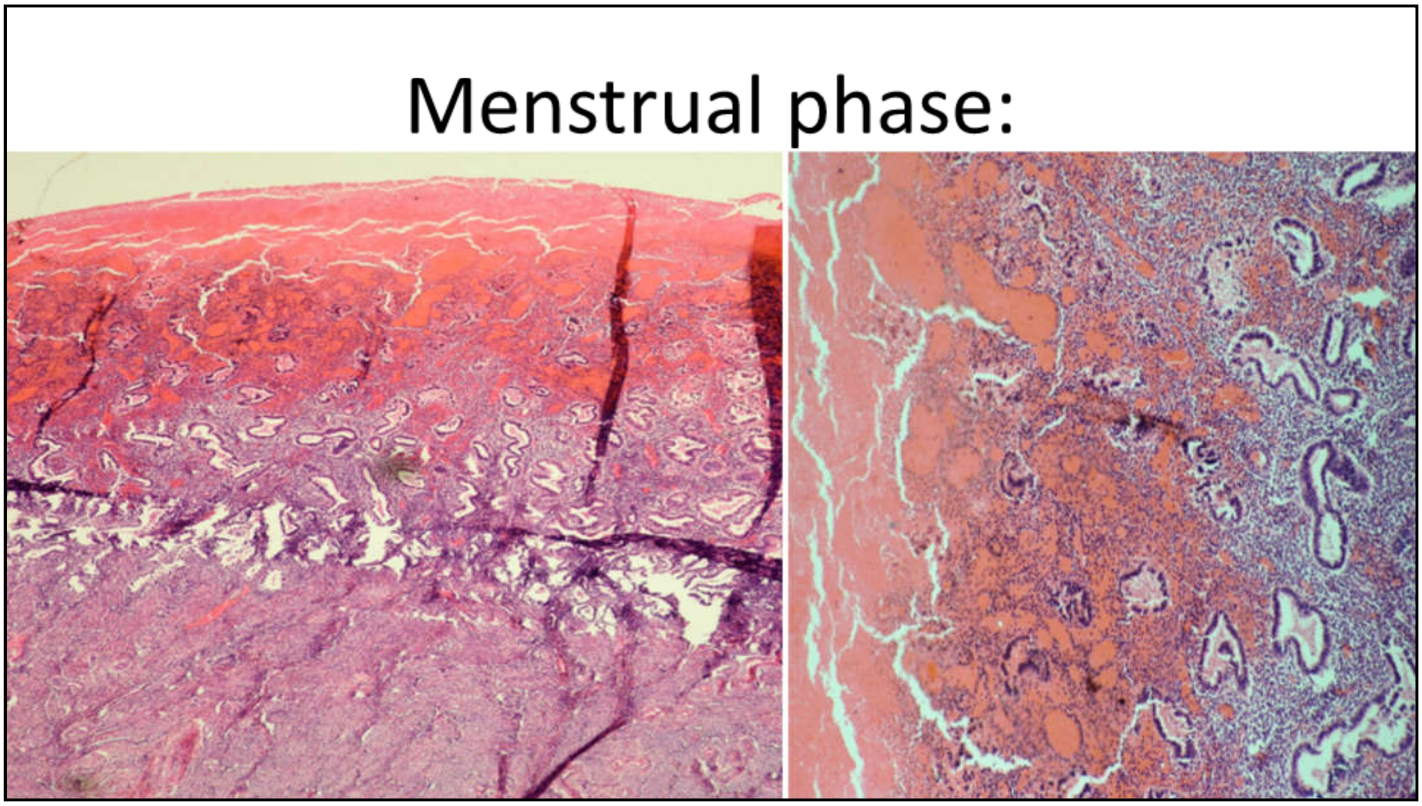

- In this phase you can notice the accumulation of blood.
- The endometrium is formed of two layers:
  1- Stratum functionalis
  2- Stratum basalis
- These two layers have different structure, function, and blood supply. Stratum functionalis is what sheds during the menstrual phase (the accumulated blood will help in shedding). Stratum basalis is the regenerative layer, from which new endometrium develops during the proliferative phase.

What's happening in the ovary during the menstrual phase?
New generation of growing follicles are recruited for the next cycle.
During the luteal phase, corpus luteum produces inhibin that suppresses FSH secretion.This FSH suppression is of value, as it prevents further ovulation during the luteal phase. However, during the menstrual phase, new generation of primordial follicles start to grow. How does that happen?
It's believed that at the end of luteal phase, there's decrease in inhibin secretion from the corpus luteum, and consequently increased FSH that facilitate recruitment of new follicles for the next cycle.

vagina

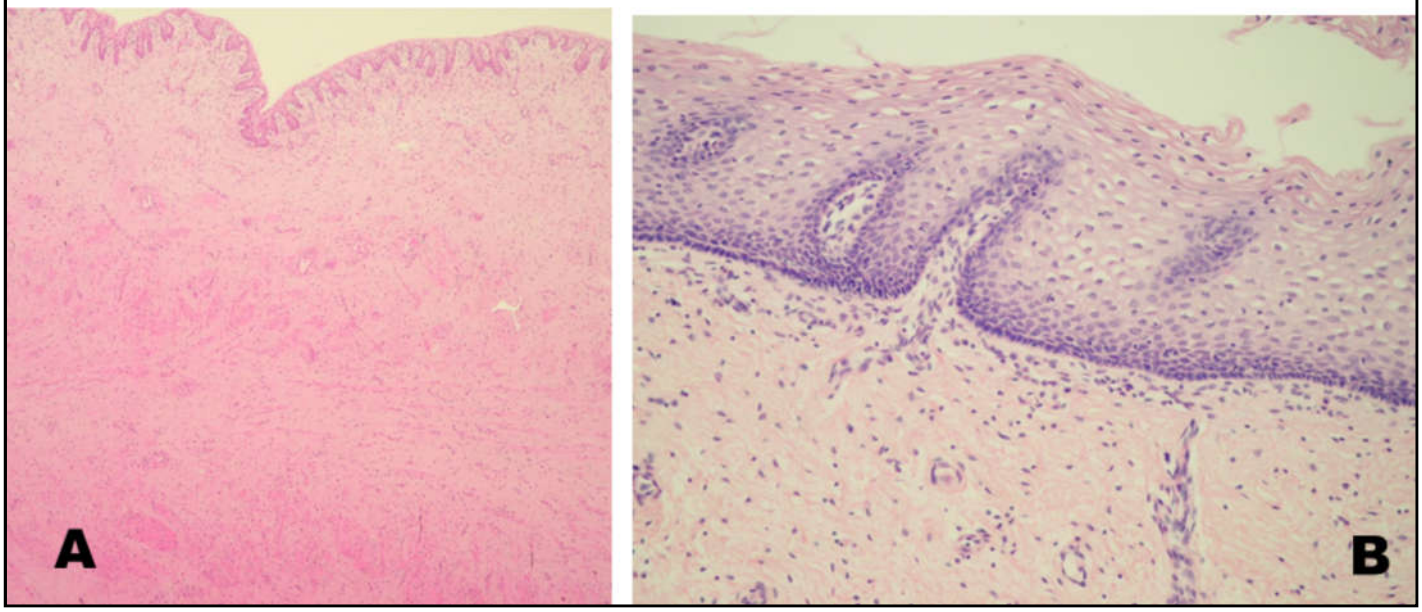

A: Layers of the vaginal wall.
Mucosa → Muscular layer → Adventitia

- There's no glands in the vagina.
- There's no submucosa in the vagina.
- The muscular layers is formed of an outer longitudinal and an inner circular layers.
- The mucosa is lined by stratified squamous non-keratinized epithelium. Below it is the lamina propria.

B: The vagina is lined by stratified non-keratinized squamous epithelium.

- The epithelium is thick and the cells contain large amounts of glycogen in their cytoplasm, giving the cytoplasm a vacuolated appearance.
- When the surface cells are desquamated, the glycogen is liberated and fermented by Doderlein's bacilli which convert it into lactic acid. This lactic makes the vaginal lumen acidic and thus prevent the growth of pathogenic bacteria.
- This acidity would kill any sperms entering into the vaginal lumen if not neutralized. Hence, the semen contains slightly alkaline secretions from the prostate and seminal vesicle that will neutralize the acidity and give the sperms the chance to live inside the vagina.

- Note: There's no glands in the vagina. The mucous present in the vagina is produced by glands of the cervix.
- Bartholin's gland is secrete fluids into the vaginal opening, rather than the vaginal lumen.
- → Rule: Any secretion in the vaginal lumen comes from the glands of the cervix.
- Hostile Cervix: when the cervix secretions decrease or become poisonous due to inflamation causing infertility
-

Cervix

Cervix

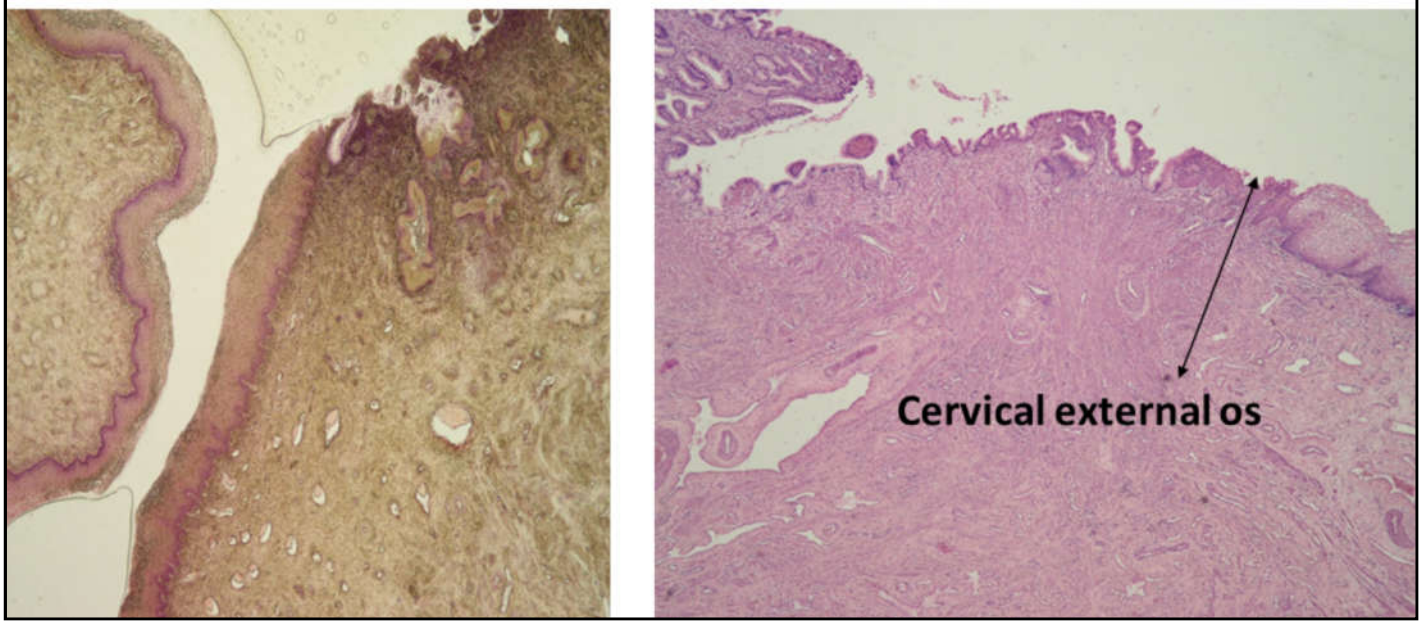

A:

- The intravaginal part of the cervix is covered by stratified squamous epithelium exteriorly.
- Inside the cervix, we can find the cervical canal.
- The cervical canal is lined by simple columnar epithelium.

B:

- The outer layer of the cervix is the mucosa or endocervix. The intravaginal part of cervix and external os are covered by stratified squamous epithelium (just like the vagina).
- Just inside the external os and throughout the cervical canal, the lining epithelium is simple columnar.

- The transitional area is just inside the external os. This transitional area is believed to be the starting site of cervical carcinoma.

- The external os (the arrow)

Cervical glands:

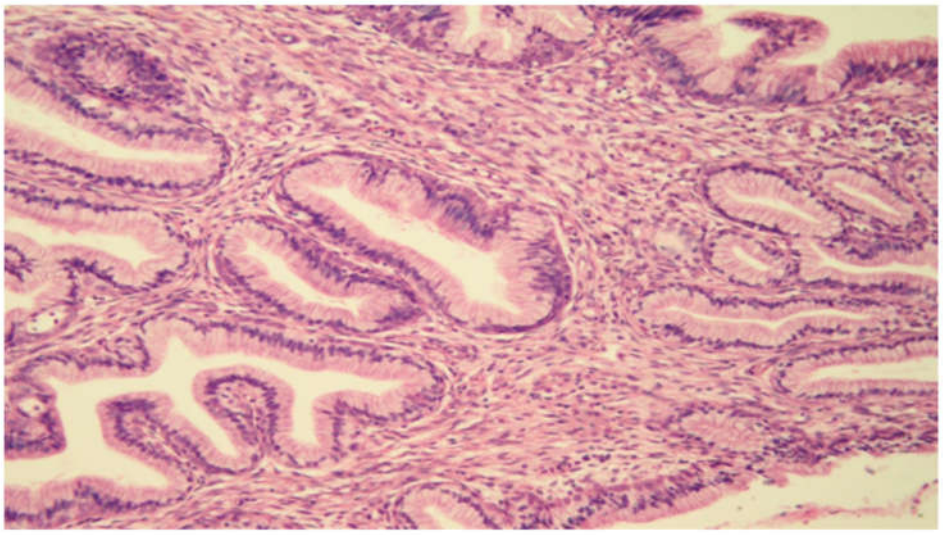

- The cervical wall is full of glands that secrete mucus.
- If the duct of the gland is occluded, it will be filled with secretions, forming Nabothian cysts.

Dense connective tissue + smooth muscle.

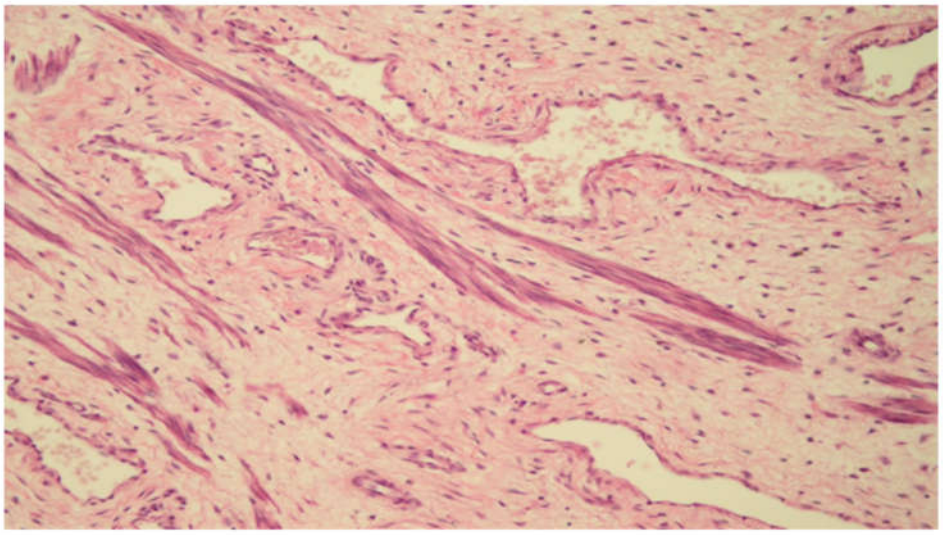

The smooth muscles in the cervix are few, despite the fact that the cervix is dilated during labor. The dilation of the cervix will take a lot of time specially in the first pregnancy.

Mammary Gland:

Inactive: duct system

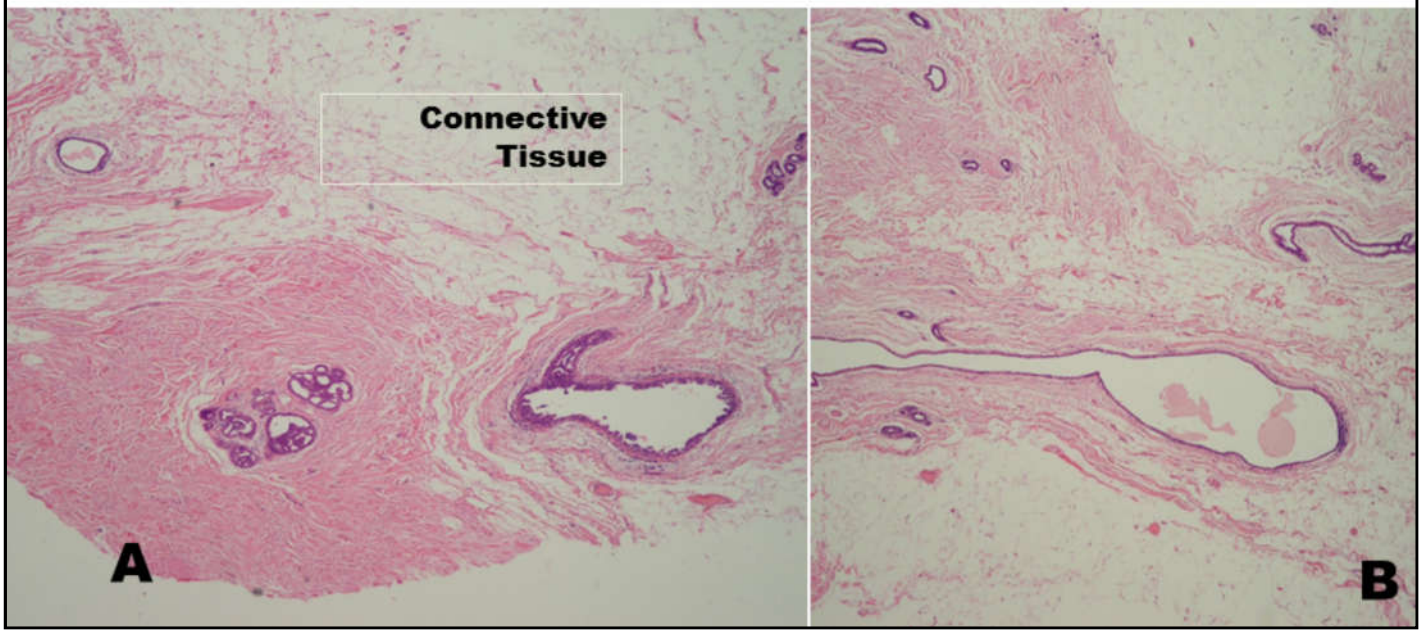

A: Resting, inactive, non-lactating breast.

- Primordial breasts are the same in males and females. Only at puberty, when estrogen level increases, the breast starts to enlarge.

- Estrogen is capable of stimulating breast development from a primordial infantile breast into an adult resting, inactive, non-lactating breast (i.e. no alveoli to produce milk, and no prolactin).
- This is called resting, inactive, non-lactating breast.
- At this stage, it's largely formed of ducts. These ducts form lobules.
- Ducts are lined by cuboidal to low columnar epithelium. Wider ducts are lined by a double layer of cuboidal to low columnar cells, while narrower ducts are lined by a single layer.
- There's connective tissue inside the lobules (intralobular connective tissue), and in between the lobules (interlobular connective tissue).
- Intralobular connective tissue is cellular and devoid of fat.
- Interlobular connective tissue is dense, fibrous and rich in fat.

True or False:
1- Section A is taken from a pregnant woman in her 3rd trimester.

False. This section is taken from an adolescent female who has never got pregnant. At this stage, the glandular tissue is not well formed (because the function of the breast is not to produce milk, now) → You can hardly see alveoli.
2- Section A is rich in ducts and alveoli.
False. Resting breast doesn't contain milk-producing alveoli.
3- Section A contains lobules that are widely separated and composed mainly of ducts.
True. The interlobular connective tissue is fibrous and rich in fat, and this makes the lobules widely separated.

- The breast is rich in adipose tissue, with little glandular tissue.

B: Lactiferous Sinus:
Each lobe drains into a lactiferous duct that opens at the summit of the nipple. Some distance from its termination each lactiferous duct shows a dilation called the **lactiferous sinus.**

Pregnant:

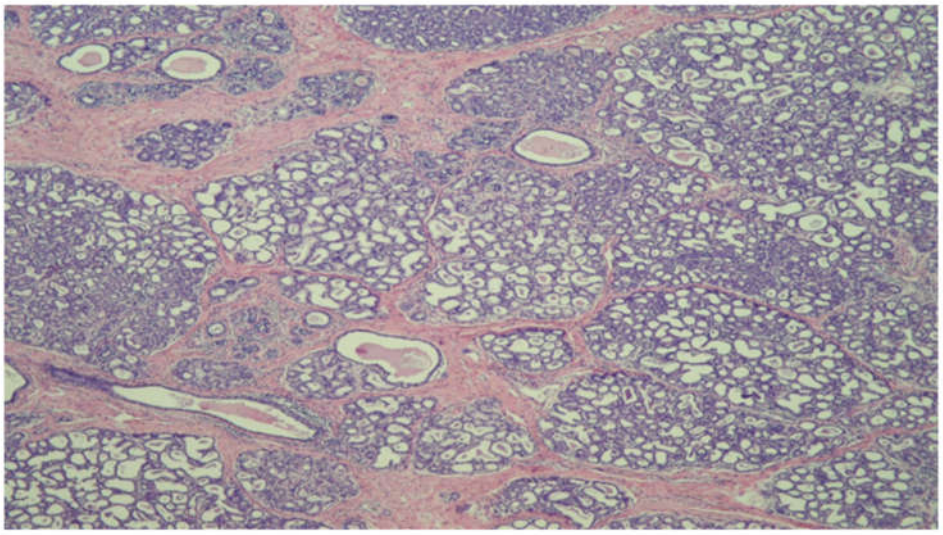

- During pregnancy, the main function of the breast is to prepare itself for the coming baby. It takes 6 months for the breast to be ready for this job. What happens during these 6 months?

1- the ducts undergo marked proliferation and branching.

2- Their terminal parts develop into proper alveoli.

→ For milk to be produced, we need alveoli. And for this milk to be ejected into the nipple, we need ducts → During the first 6 months of pregnancy, under the effect of gestational hormones (estrogen and progesterone produced from the corpus luteum and later from the placenta), the breast develops ducts and alveoli.

→ During these 6 months, there's no production of milk, the alveoli are empty and are not distended.

In the 3rd trimester, alveoli start to produce colostrum. Colostrum is a serous fluid, that's rich in proteins and poor in fat.

→ We should encourage the lady to lactate the baby after delivery, as this colostrum is rich in immunoglobulins that are protective to the baby.

→ There's no production of milk until 2-3 days after delivery.

→ The alveoli are surrounded by myoepithelial cells that contain oxytocin receptors.

- What stimulates milk production?
  Suckling.
  - Suckling initiates the suckling reflex. It sends sensory input to the hypothalamus, and causes increased production of prolactin from the anterior pituitary, and oxytocin from the posterior pituitary.
- Prolactin stimulates production of milk.
- Oxytocin stimulates ejection of milk. The alveoli

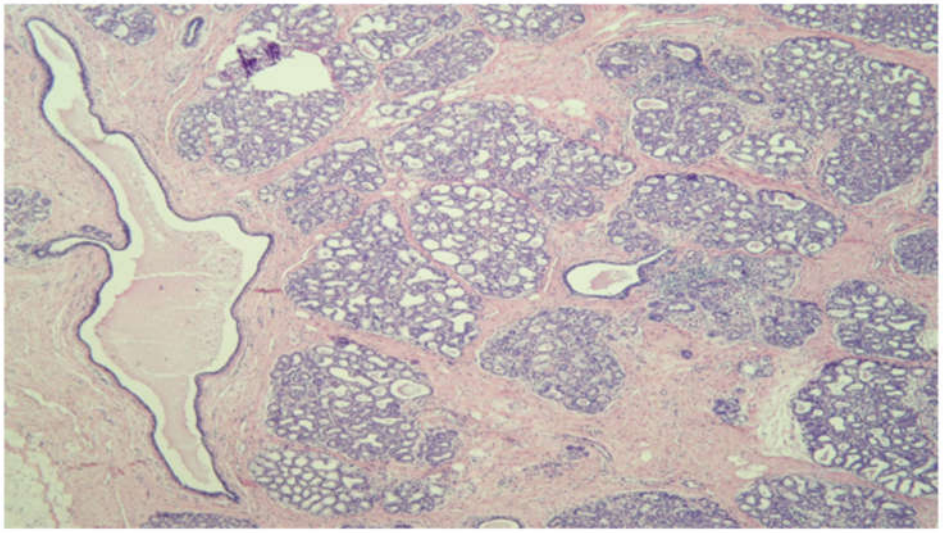

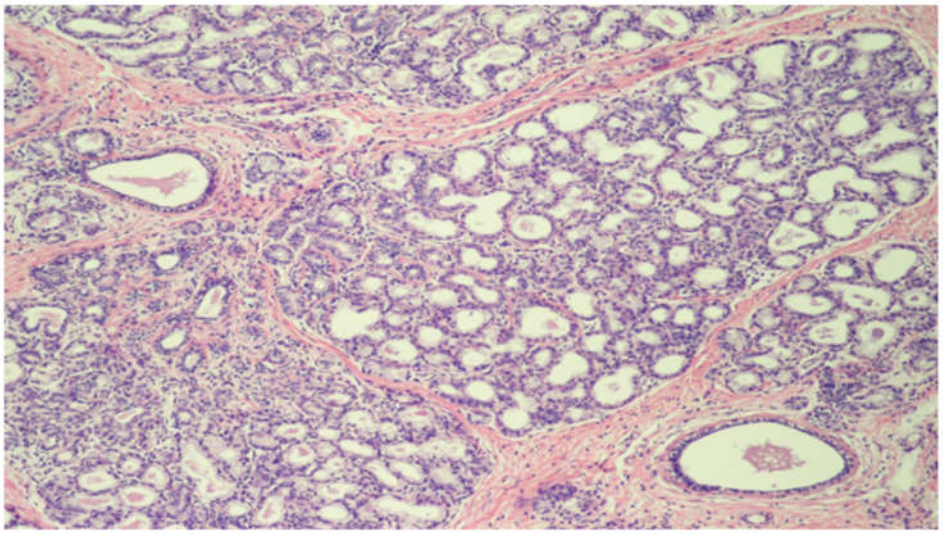

- The alveoli are empty → This is active proliferative breast.

True of False:
1- This section is taken from a pregnant female, either in the 1st or 2nd trimester.
True. Alveoli develop in the first two trimesters, but they remain empty (no secretion of colostrum until the 3rd trimester & no secretion of milk until 2-3 days after delivery).

alveoli

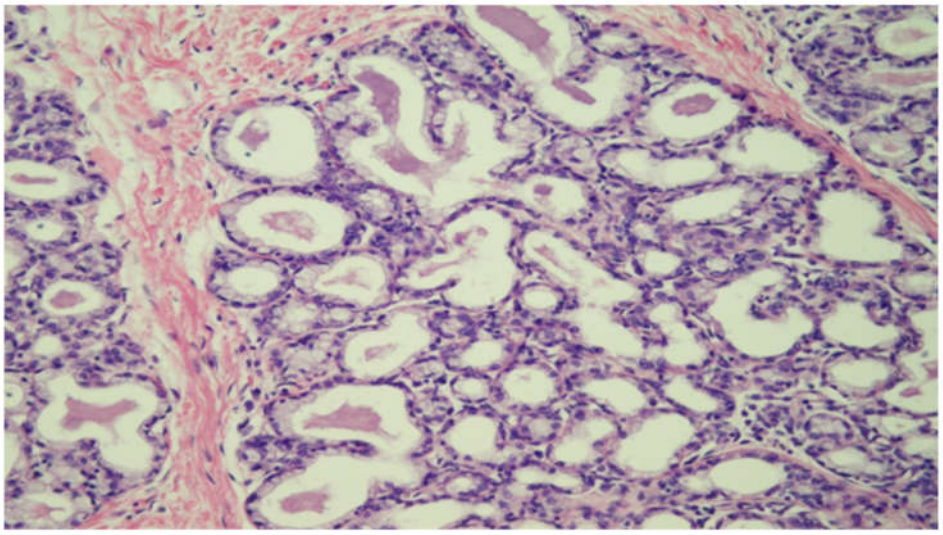

Lactating:

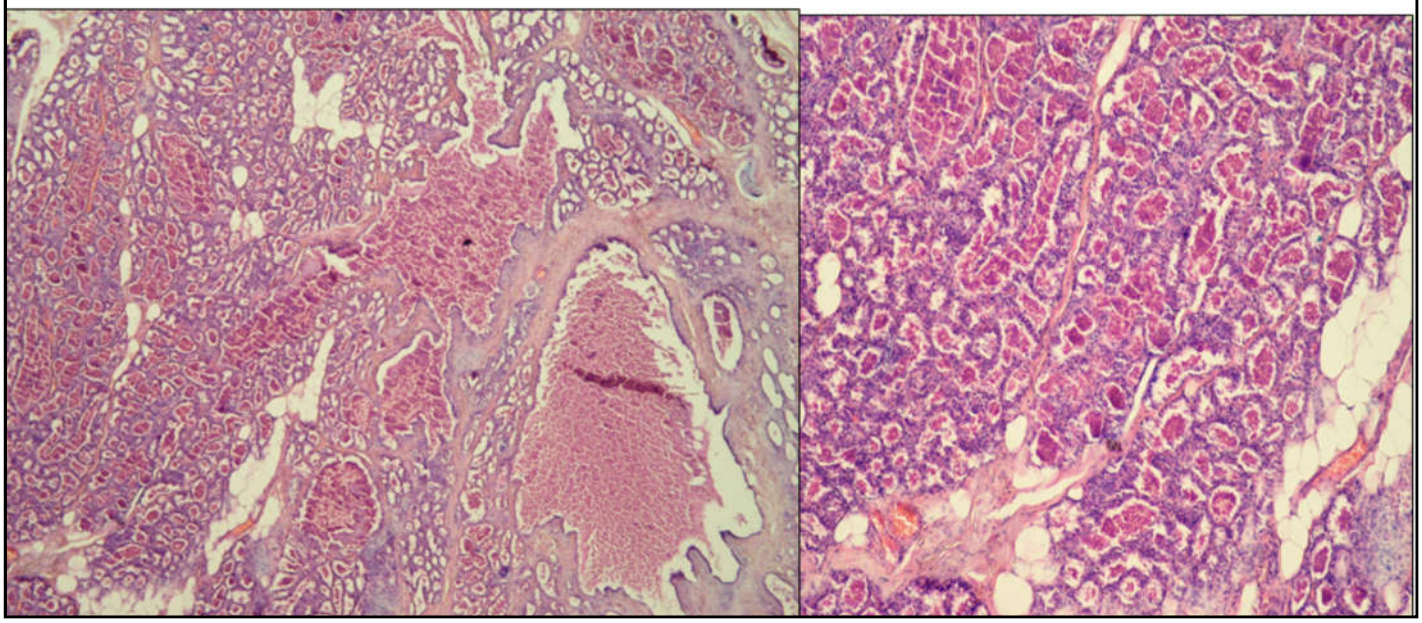

A & B: Active Lactating Breast

- Alveoli become saccular and distended with milk.
-

- As long as lactation continues, ovulation is mostly suppressed. Prolactin inhibits GnRH secretion from the hypothalamus and LH, FSH secretion from the anterior pituitary, hence suppressing ovulation.

In the past, when most women were exclusively breastfeeding their babies, they were able to maintain constant levels of prolactin in their blood. In this way, they were able to prevent ovulation and pregnancy until they wean the baby (this is called lactational amenorrhea and is most effective in the first 6 months after delivery).

These days, most women don't exclusively breastfeed their babies, and are becoming more and more dependent on contraceptive pills and other birth control strategies.

Note: Dr. Faraj overestimated the efficacy of this method. It's only effective in the first 6 months after childbirth, and this what actually made the fertility rates very high 5-6 decades ago.

Milk secretion

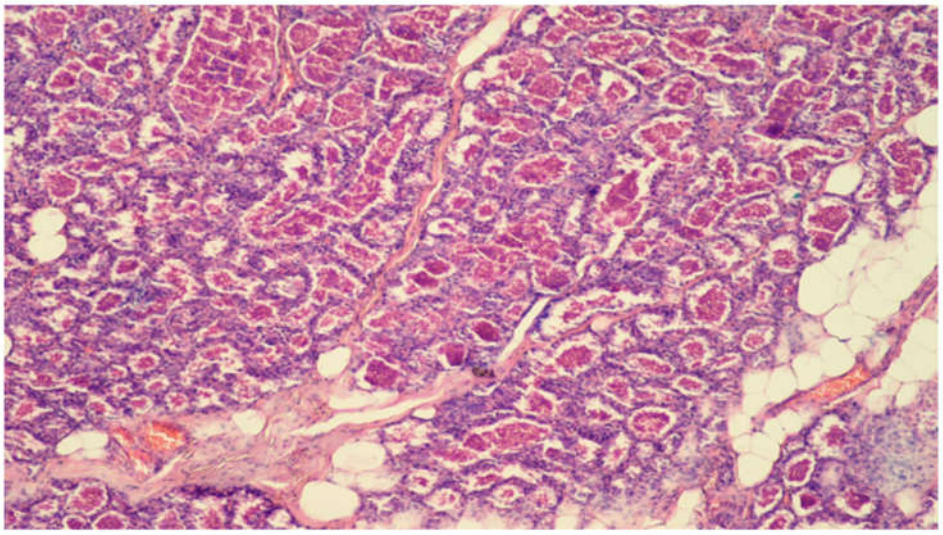

Lactiferous sinuses in nipple

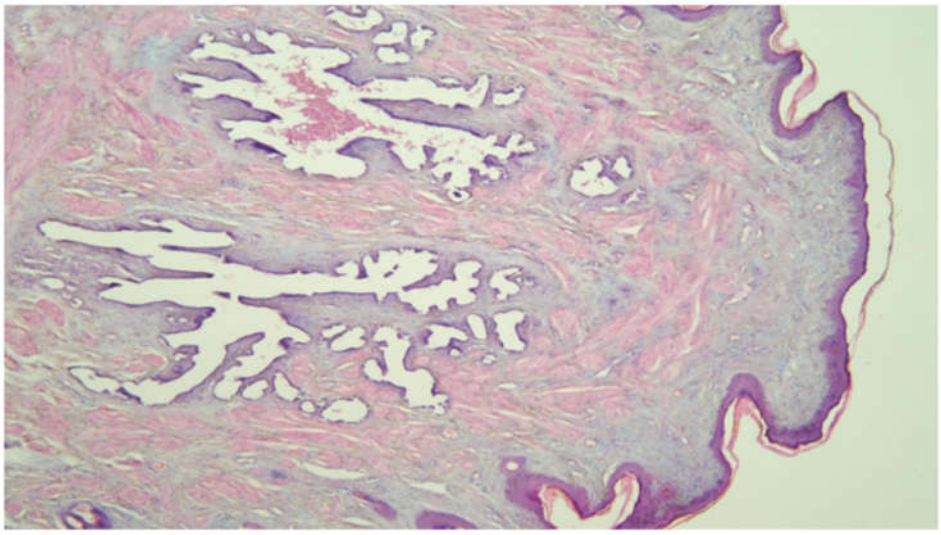

Montogomry gland

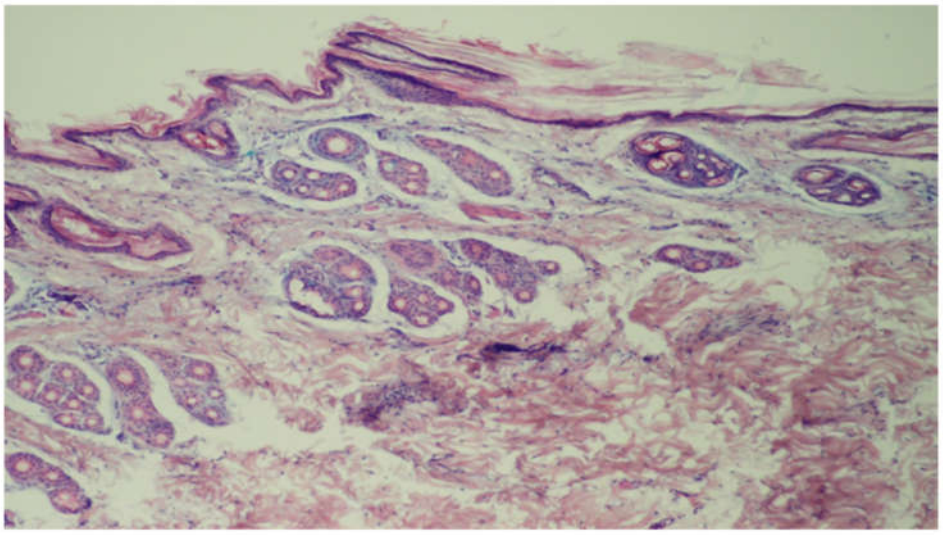

- The areola becomes deeply pigmented after first pregnancy.
- Deep to the areola are modified sebaceous glands called Montgomry glands.
- They enlarge during pregnancy forming tubercles, known as tubercles of Montgomery.
- They secrete oily secretions to prevent laceration of the areola and nipple.
- In the areola, there are sweat glands, hair follicles, sebaceous glands, and modified sebaceous glands.