Hematology

HISTOLOGY

☑ Sheet ☐ Slide ☐ Handout

Number: 6

Subject: Secondary lymph. Organs + lymphatic vessels

Done By: Lina Mansour

Corrected by: Yousef Al-As3d

Doctor: Faraj Al-Bustami

Date: 21/9/2016

Price:

THIS SHEET IS NOT LONG, IT IS JUST FULL WITH FIGURES AND SPACES

In this lecture, we will discuss: -record-sec3

- ☑ The spleen
- ☑ Diffuse lymphatic Tissue (tonsils + MALT)
- ☑ Lymphatic vessels
- ☑ Lymph nodes

Before we start, remember that the bone marrow and the thymus are considered primary lymphatic organs, anything besides these two is considered as secondary lymphatic organ. Now let us start:

- ✓ The spleen is the **largest** lymphatic organ.
- ✓ Anatomical position: the spleen is located at the upper left quadrant of the abdomen, it is related to the diaphragm and to the 9th -11th ribs.
- ✓ At Its medial wall there is the splenic **hilum**, where the splenic artery and nerves **enter** while the splenic vein and efferent lymphatic vessel **exit** the spleen.
- ✓ Unlike the lymphatic nodes the spleen do not have afferent and efferent lymphatic vessels , it just have efferent lymphatic vessel.

Histology of the spleen –figure1

- ✓ the spleen is encapsulated (like the lymph node)
- ✓ the capsule send septa. (plural of septum) – Note ; trabeculae= septa

- ✓ Between different septa there are a network of reticular fibers and cells. [this can only be visualized by special stain "silver stain"]
- ✓ Unlike the lymph nodes the spleen do not have cortex and medullae instead it have white pulp and red pulp,
  the red pulp is predominant and made of blood
  the white pulp have lymphatic tissue..

|| Dig in

The spleen have a very distinctive arrangement of lymphatic tissue -figure2
this based on the fact that the structure of the spleen is built around the blood supply.
so in order to understand how the splenic lymphatic T is distributed we need to understand the blood vessels distribution –look at figure2 while reading this:

- ✓ In every trabecula (septum) there's a branch of the **splenic artery** and the corresponding vein called **trabecular artery** and vein, respectively. (We will follow the course of the trabecular artery for now).
- ✓ The trabecular artery give rise to several **central arteries** that enter the stroma (pulps) of the spleen.
- ✓ Now, as we said earlier the lymphatics of the spleen is built around the blood supply, so u will find around the central artery an aggregation of lymphatic tissue called **periarterial lymphatic sheath** that keep surround the central artery throughout it curse until –at the end – the aggregation of lymphatic tissue become much larger to the extent that it forms a follicle (**splenic follicle**) around the sheath and the artery.
  White pulp = periarterial lymphatic sheath+ splenic follicle

Lymphocytes distribution in spleen

Periarterial lymphatic sheath contains T lymphocytes and its APC (interdigitating dendritic cell)
But in the splenic follicles mainly B lymphocytes and its APC (follicular dendritic cell)

So the spleen can carry on both antibody and cell mediated immune rxn as it contains both T and B lymphocytes.
The doctor did emphasis on this fact:
When an immune rxn is carried by the spleen (or any other lymphatic organ) the lymphocyte proliferate in this organ >> we do not wait for bone marrow to produce them from their precursors >> as WE DO NOT HAVE TIME for that >>so as soon as lymphocyte meet its antigen , it get insane and proliferate at the "meeting place".
so we can said that spleen (and lymph nodes) produce lymphocytes. –not only the bone marrow.
Note : in the splenic follicles u also see T_H lymphocytes as they secret important cytokines for the Antibody mediated immune rxn of B lymphocyte.

Figure1: histology of the spleen

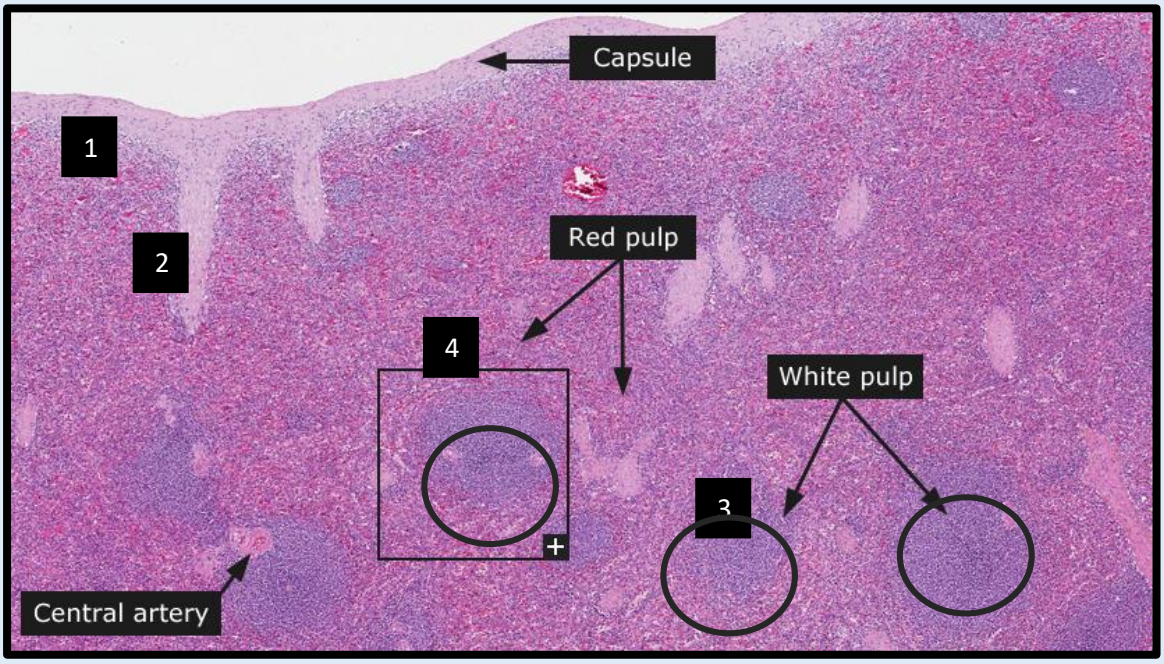

the spleen is surrounded by a capsule (1) it send septa (2) >
the spleen is made of white (3 /circulated)-bluish in color and red pulp (4) reddish in color

So after all the spleen is built around its blood supply .
the white pulp around the arteries and the red pulp around the veins (sinusoids)

Red pulp of the spleen

here you must identify these structures: -figure3a

- ✓ **Capillary Sinusoids** - its structure (figure3b) is simply endothelium lies on basal lamina.. but here in between the endothelial cells there's no junction>> this mediate the filtering function of the spleen –discussed later
- ✓ **Splenic cords** (any red pulp beside the sinusoids)

Both of these structures contain blood (venous blood mainly). But how the arterial supply connects with the venous supply?

Open Vs closed circulation theories:

The central artery ends as a structure known as penicillar artery, in the closed circulation theory this artery will open in the sinusoids directly. In the open theory it will open in the splenic cords and then return to the venous system through sinusoids.

You have to know that: any blood in the spleen (in the cords or arterial blood) is collected in the sinusoids. The sinusoids is turned into venules. and venules into trabecular vein then group of these will make the splenic vein that will exit the spleen throughout the hilum.

Macrophages of the spleen, the marginal zone & the reticular gate

the spleen works as a filter for the blood, it take away both foreign antigens and old (not well functioning) RBCs. This function is mediated by two things :

First. Presence of Macrophages (that will eat old RBCs and present foreign antigen to lymphocytes)

Second. the presence of sinusoids .

actually this filter thing is based on the fact that all blood will get back to the sinusoids, so the sinusoids take advantage of this and put macrophages on its periphery to form kind of a gate "a **reticular gate**" that will only allow healthy RBCs to pass, while old RBCs (that loss their flexibility and cannot anymore pass through

the gate) won't pass and they are phagocytosed by macrophages.
the **marginal zone** is a group of sinusoids that surround the splenic follicle .these sinusoids contain APCs and macrophages (and to lesser extinct lymphocytes) these sinusoids are directly connected to the central artery so if the arterial blood contain any bacteria or foreign antigen the macrophages of this sinusoids will eat them ..the APCs will present foreign antigen on their surfaces and link them to MHC molecules so that the lymphocytes can identify the presence of foreign antigen and initiate an immune rxn.

So,
Macrophages of marginal zone sinusoids (white pulp macrophages) eat foreign antigens/bodies – like bacteria, while
macrophages of other sinusoids (red pulp macrophages) eat old RBCs.

another function of the sinusoids (of the marginal zone) that the proliferative lymphocytes (due to an immune rxn) pass through them to get access to systemic blood.at the same time if memory cells or old lymphocytes want to get back to the spleen (to look if their antigen is there or not) they get back through the sinusoids.
طريق باتجاهين–
the newly formed lymphocytes get out
the old lymphocytes get in.

Functions of the spleen
by now we can easily identify the functions of the spleen :

1. Filter for the blood
2. Form lymphocytes (B and T)
3. Run both antibody- and cell- mediated immune rxn
4. In embryonic life (at the second trimester of pregnancy) some of the hematopoiesis – occur in spleen.
5. Cemetery for old RBCs – rem. The red pulp macrophages.

Figure2: Blood and Lymphatic distribution of the Spleen

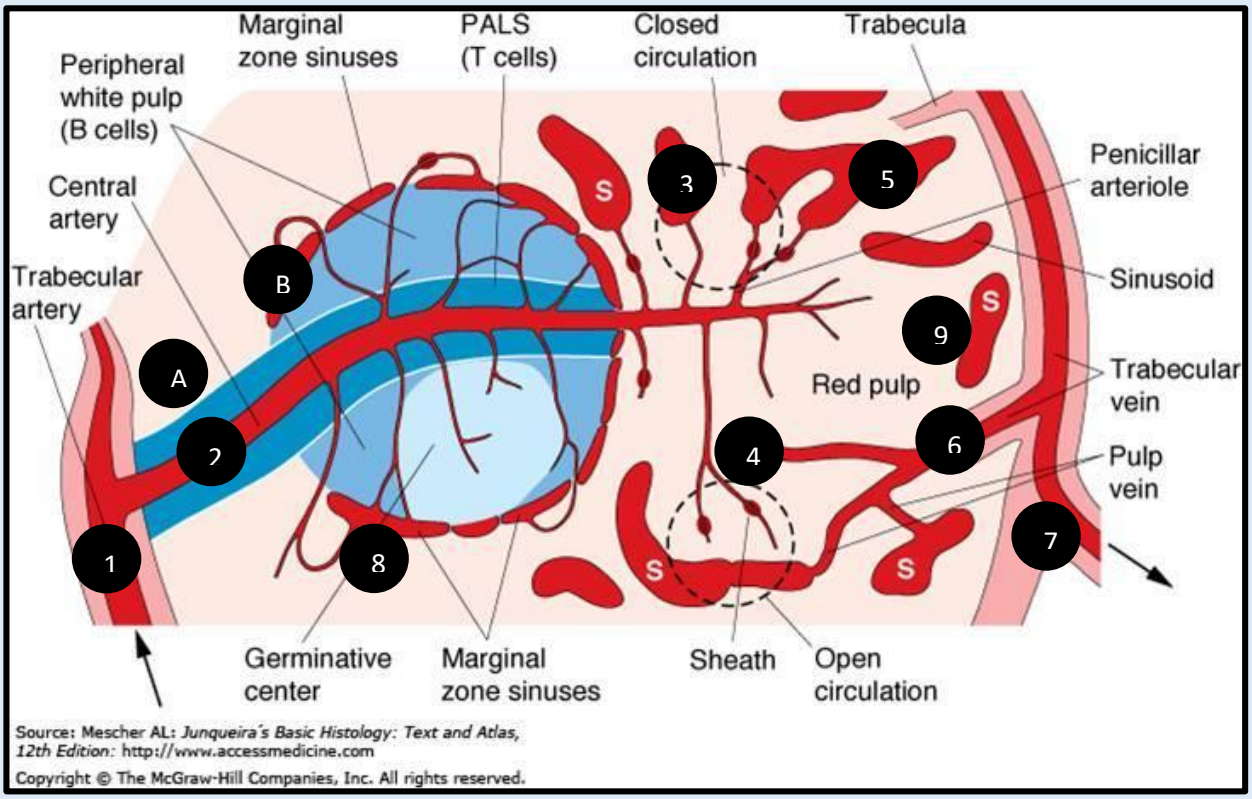

Blood supply of the spleen, atrial: [1] trabecular artery (branch of splenic artery) give rise to [2] central artery. the central artery may end in sinusoids >> closed circulation [3], or do not end in sinusoids >>open circulation [4]. Venous : sinusoids [5] , venules [6] , trabecular vein [7].. around the central artery notice : the periarterial lymphatic sheath [A] >>contains T and the splenic follicle [B] >>contain B.

notice the marginal zone "sinuses" [8] and the reticular gate suggested location [9] macrophages are present in both 8 and 9 , in 8 >> they phagocytose antigens while in 9 >> they phagocytose old RBCs.

Figure3: Venous structure

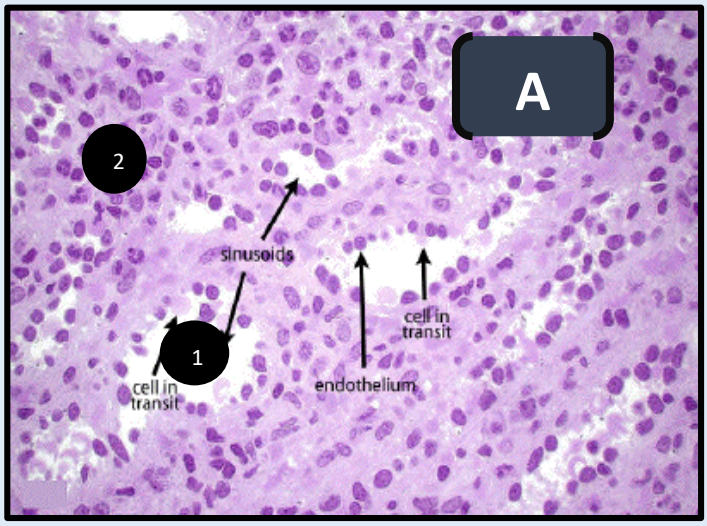

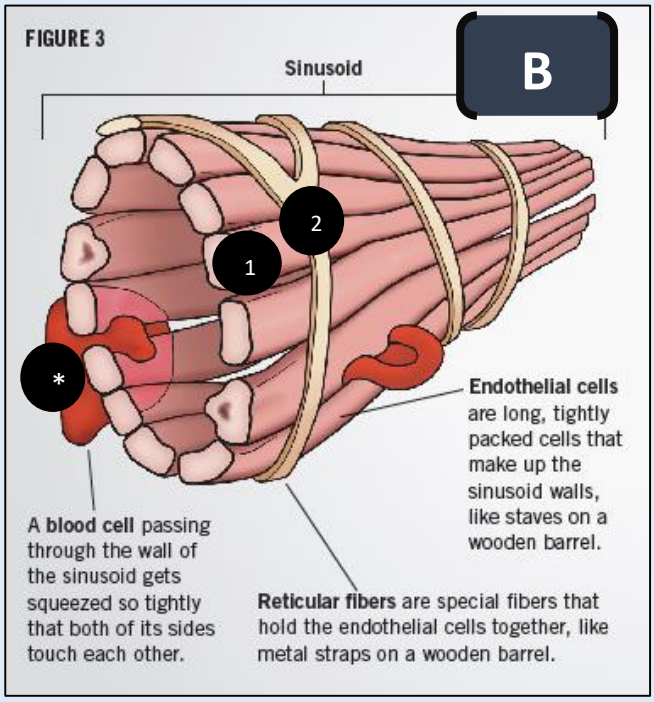

In A : you can the red pulp , notice [1] the sinusoids and [2] splenic cords .
In B : you can see the structure of the sinusoid , notice [1] the endothelial cells and how loose they are and [2]the reticular fibers around 1 which represent the BL.
also notice how the RBC squeeze itself to pass into the sinusoid , if the RBC is old (not flexible) it can not pass "reticular gate' indicated as [*].

Two thing left to add:

- ✓ The doctor didn't call the reticular gate >>a reticular gate, I found this term in a book "pathoma' I preferred to use it as it make things more understandable. –the doctor hasn't name it.
- ✓ We have stated that Old RBCs lose their flexibility and cannot penetrate the spaces between the endothelial cells so they get phagocytosed by macrophages, the underlying mechanism is that these cells lose sialic acid from their membranes , this expose their surface galactose which attract macrophages to phagocytose the whole RBC. When phagocytosed every component of RBC is broken into its basic structure, the hemoglobin is broken to Heme+ globin, the globin is a protein so it's further broken into

aa. The Heme is broken into Iron and protoporphyrin ring , the iron is carried by transferrin to bone marrow to be used again in RBCs synthesis , the ring is turned into bilirubin >> excreted by liver bile .

Clinical case : Malaria and splenomegaly

In region where malaria is endemic, the patient who have chronic malaria have also anemia , but why?

the malaria live inside the RBC and by doing so the RBC flexibility then it cannot pass into the sinusoids then they are trapped in the spleen (in the splenic macrophages particularly) and the spleen become bigger, ie. Splenomegaly.

Diffuse Lymphatic Tissue

- ✓ This "system' include all lymphatic tissue that are not encapsulated , including those distributed at the digestive , respiratory , urinary and reproductive tract.
  *recall in GI the mucosa associated lymphatic tissue is situated in the mucosa (or the submucosa) of the intestines -in the ileum they are aggregated in groups known as payer's patches.

- ✓ Example on diffuse lymphatic tissue is Tonsils

|| Tonsils

The tonsils are aggregates of lymphatic tissue at the pharynx and the abdominal cavity.
They are 4 in number (indicated in figure4)

1. The palatine tonsils (figure5) : situated at the lateral wall of the oropharynx (between the soft palate and the Tongue) , covered by striated squamous epithelium, deep inside the epi u can find the lymphatic tissue,
   here there are something known as crypts these are invagination filled with desquamated epi.
   Note: the palatine tonsils actually have capsule but it's incomplete.

Clinical case : Acute Palatine Tonsillitis and tonsillectomy
when the tonsil are inflamed they appear as a strawberry, they get red with white dots on it; the redness is due to the immune rxn that occur in it , the white dots are pus inside the crypts.
when removing the tonsils ie. Tonsillectomy , we actually strip off the it from its surrounding structure by cutting the capsule. >> this cause pain and dysphagia

2. Pharyngeal tonsils: situated at the junction of the roof of the nasopharynx+ its posterior Wall. It's covered by epithelium , type: ciliated pseudostratified (regular respiratory epi.) , no crypts , have a thin capsule.

Clinical case : acute pharyngeal Tonsillitis (Adenoid)- اللحمية
when the pharyngeal tonsil is inflamed the child (patient) will have difficulty in breathe << actually he will present with "mouth breath"

3. Lingual tonsils : situated at the oral cavity (posterior third of the tongue)>> responsible for killing injected bacteria associated with dirty food.
   these are smaller and more numerous than the palatine/pharyngeal T situated at the base of the tongue – covered by stratified squamous epithelium.
   Note : here each lingual tonsil have a single crypt that receive a duct from an accessory salivary gland .
   rem. The salivary glands are classified as major (parotid, submandibular& sublingual salivary gland) and minor glands (accessory-many).
   major salivary gland are responsible for liberating food (work when the food is ingest food only) responsible for liberating mouth (all the time)
4. The appendix, surgeons call it Tonsil of the abdomen.

Distribution of lymphoid Tissue inside the tonsils

as stated earlier the tonsils are covered by epithelium and they have crypts ,, deep inside u can notice the lymphatic nodules (follicles) that have B lymphocyte and its APC. Also u will find T_H cell as they are important for the immune rxn mediated by B lymphocyte.

Figure4 : Tonsils

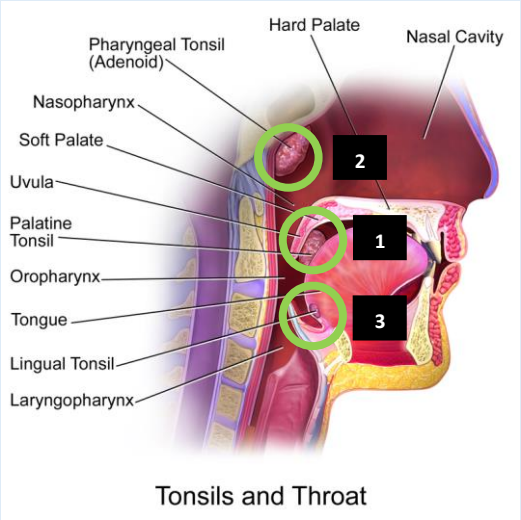

1: palatine tonsils , 2 : pharyngeal tonsils , 3: lingual tonsil notice the surrounding structure

Figure5: histology of the palatine tonsil

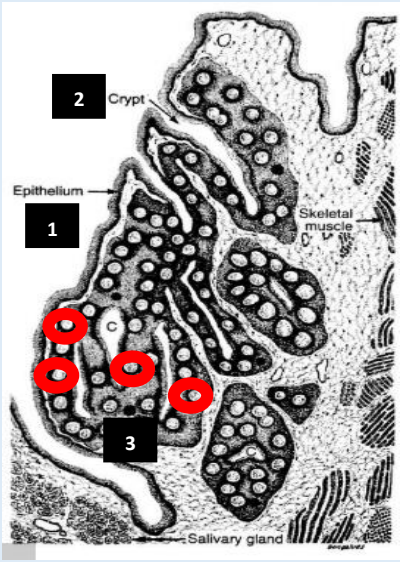

1:lining epi. , 2:crypt , 3: nodules that contain B lymphocyte(some circulated with red)

Lymphatic vessels

The lymphatic vessels are either deep or superficial :

- ✓ Superficial >>in the superficial fascia fat (beneath the skin /out of the deep fascia) and they run along the **superficial veins** (like the superficial veins of the upper limb "cephalic and basilic veins, and median cubital vein' and those of the lower limb "saphenous veins)
  Note : we cannot see these lymphatic vessels unless they got inflamed.>>appear like fine red lines on the skin.
- ✓ Deep lymphatic vessels run with **arteries** within the muscles and deep fascia

Major lymphatic vessels –figure6

First. Cisterna chyli and lumbar trunks

cisterna chyli is a lymphatic "cyst" situated in the abdominal cavity , at the level of L1-L2 deep to the diaphragm. It receive lymph from the lower limb, the abdomen and the pelvis. How ?

the lymph is actually collected through other lymphatic vessels that eventually collect as one lumber lymphatic trunk on each side (right and left) the lumber trunks open in the cisterna chyli. These lumber trunk collect lymph from the lower limb, the pelvis and the anterior abdominal wall. Another trunk opens in the cisterna chyli which is the intestinal trunk this collect lymph from the viscera of the abdomen (with some exceptions like the bare area of the liver –not mentioned) – so overall the cisterna chyli has collected lymph from the lower part of the body.

Second. Thoracic duct (left lymphatic duct)

this emerges from the cisterna chyli (in the abdomen) then go up through the diaphragm (from the aorta opening on the diaphragm) and run up to the root of the neck where it opens at the junctions of two major veins –the internal jugular and the subclavian. But just before opening the thoracic duct receive another lymphatic trunk , called left bronchomediastanial trunk , which receive lymph from left thoracic wall , left lung , anterior part of diaphragm and left part of heart.- so this trunk collect lymph from left thorax.

remember that the internal jugular vein comes from neck and head, while the subclavian comes from the upper limb.

Third. Right lymphatic duct and right bronchomediastanial trunk

these receive lymph from the right half of neck , head and thorax . the right bronchomediastanial trunk open in the R. lymphatic duct which itself opens at the junction of the internal jugular vein and the subclavian vein.

So we can say that the thoracic duct overall collect lymph from ALL the body except from the right side of the thorax , head , neck.
Notice that the lymph eventually return to VENOUS blood.

Figure6 : major lymphatic vessels

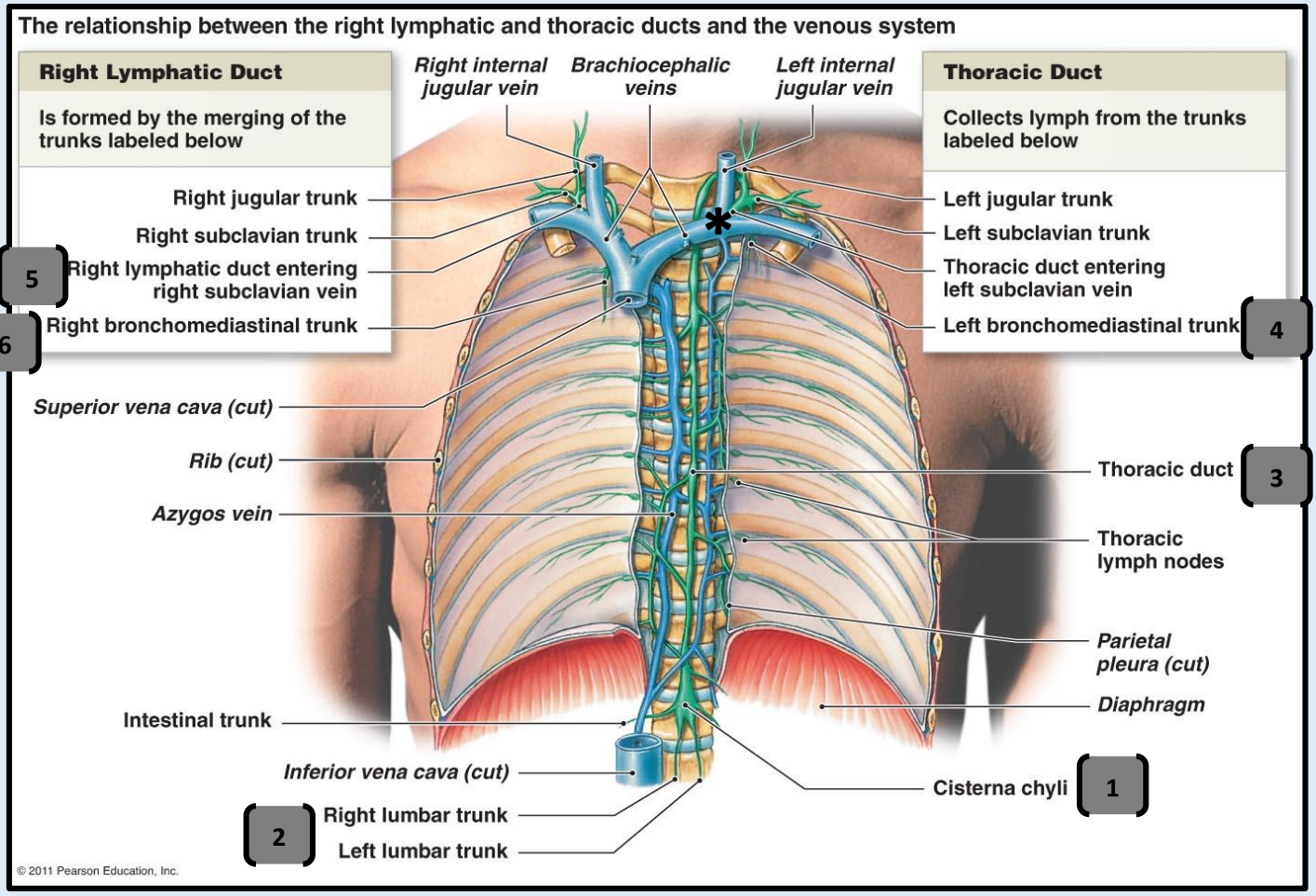

Major lymphatic vessels :

1: cisterna chyli (at the level of L1/2)

2: R/L lumbar trunk (open at the cisterna chyli)

3: thoracic duct , notice in (*) where it opens at the junction of the left subclavian and left internal jugular.

4: left bronchomediastanial trunk that open in 3

5: right lymphatic duct

6: R bronchomediastanial duct

Lymph Nodes

lymph nodes are collected togather within groups in certain places of the body: you can see lymph nodes at the neck , the axilla , lower limb and so on ..
here we will make a breif review of ingunal lymph nodes and axillery lymph nodes.
but first , what is the function of lymph nodes ?
the lymph nodes filter the lymph , how is that mediated ?
by the presence of afferant lymph vessel and efferant lymph vessel >> so bad lymph enter the lymph node then good lymph exit it.

Superfecial Inguinal lymph nodes –figure 7

these are arranged in two groups vertical group and horizantal group. The horizantal group is furthur divided into : lateral and medial horizantal.
each group recive lymph from different destination ,
the **Vertical group** receive lymph from the skin of the lower limb
and it's associated with the termination of the great saphenous vein (on the superfecial fascia)
exceptions of the vertical group : THE HEEL and THE BUTTOCK
the heel send its lymph to the popliteal lymph nodes with short saphenous veins then from there to the vertical lymph group (but not directly)
the buttock sends its lymph to the lateral horizantal group
**we are talking about skin here
Medial horizantal recives lymph from the perineum (external genitalia of male and female), the Ant. abdomenal wall below the umblicus and the pelvis including lower third of the anal canal and lower third of the vegina
but do not recive lymph from testis (as these follow abdominal lymph nodes – due to their embryological origin)

Lateral horizantal reveive lymph from the skin of the back below the iliac crest +the skin of the buttock.
based on these information, you should be able to understant the next clinical case.

Clinical case: Enlargement of lymph nodes (Lymphadenitis).

clinically if the lymph node is enlarged , what does this mean?
it means that the lymph which the lymph node receives contain foreign antigen that initiate an immune rxn at the lymph node >>so it get larger due to the proliferative lymphocytes induced by the immune rxn . this implies that if the lower limb skin is ulcered/infected (in diabetic patient for example) then its corresponding lymph nodes will be enlarged (vertical group) .
if the heel is ulcered the first lymph node that I expect to be enlarged is the popliteal lymph node(behind the knee) then the vertical group.
during delivery , they tend to cut the lower third of the vegina to ease the delivery process (the surgery is called **episiotomy**). if this surgical lesion was infected you can notice an enlargement of the medial horizontal group.
so we are facing two scenarios:

- ✓ The patient complain from an enlarged lymph nodes >>then you are guided to the origin of the problem .or,
- ✓ The patient comes to u with the problem (like ulcered leg) and you confirm that [Ah , this an inflammation!] by observe an enlargement of the corresponding lymph node.

Actually the enlarged lymph node do not always means inflammation, there are 2 pattern of enlargement:

- ✓ soft, movable and tender (painful when pressed on) enlarged lymph node= Inflammation (due to bac.)
- ✓ Hard as rock enlarged lymph node = metastases and cancer

Note: The term lymphadenitis does not indicate inflammation of the lymph node. It means the enlargement of lymph node due to the increment of lymphocytes after an immune reaction

Figure7- Superficial inguinal lymph nodes

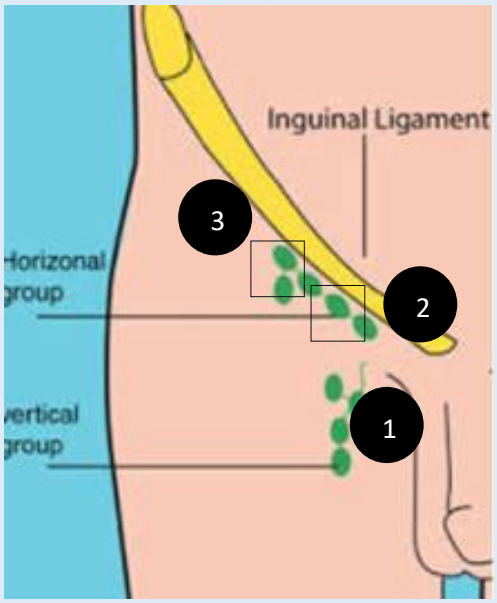

1: vertical group
2: medial horizontal
3: lateral horizantal

Lymph nodes draining the breast (axillary lymph nodes)

-figure8

First. **Anterior (pectoral) group**

behind the pectoralis major muscle, receive lymph from anterior abdominal wall skin (above the umbilicus) and from the outer half of the breast.

Note : the upper outer quarter of the breast is common site for metastasis (carcinoma)

Second. **Posterior (subscapular group)**

anterior to the subscapularis muscle, receive from the skin of the back down to iliac crest level.

Third. **Lateral group**

surround the brachial artery receive the upper limb lymph except the thumb, index , the lateral part of the forearm and the lateral part of the

arm >>these send their lymph to delto-pectoral group of lymph nodes (present between the deltoid m. and the pectoris m.)

Fourth. **Central group**

this is present at the fat of the axilla receive lymph of the lateral , anterior and posterior group and send it to the apical group.

Fifth. **Apical group**

at the apex of the axilla, receive the lymph of the central group. Then this send the lymph to major lymphatic vessels (on the R >> right lymphatic duct , on the L >> to the thoracic duct

Sixth. **Internal mammary**

around the internal thoracic artery, receive lymph from medial half of the breast.

Important note: There is a direct connection between the anterior group and the apical group ..and between the lateral group and the apical.

Clinical case : Breast cancer

In breast cancer I expect the previous mentioned lymph nodes to be enlarged , exactly

-the internal mammary will be enlarged if the medial half of breast is affected.

-if the lateral half of breast is affected , three groups may be involved:

-lateral group (obviously)

-central group (as it receive from the lateral group)

-apical group (as it is connected with the lateral group)

Clinical case : systemic Vs local pathology and lymph nodes enlargement

in local conditions just one group of lymph nodes will be enlarged , while in systemic pathology (like leukemia /lymphoma) more than one group is involved (through out the body).

which implies that if the patient come with an enlarged lymph node at certain place , then u must observe lymph nodes of other places to make sure it is not a systemic pathology.

Figure8 : axillary lymph nodes

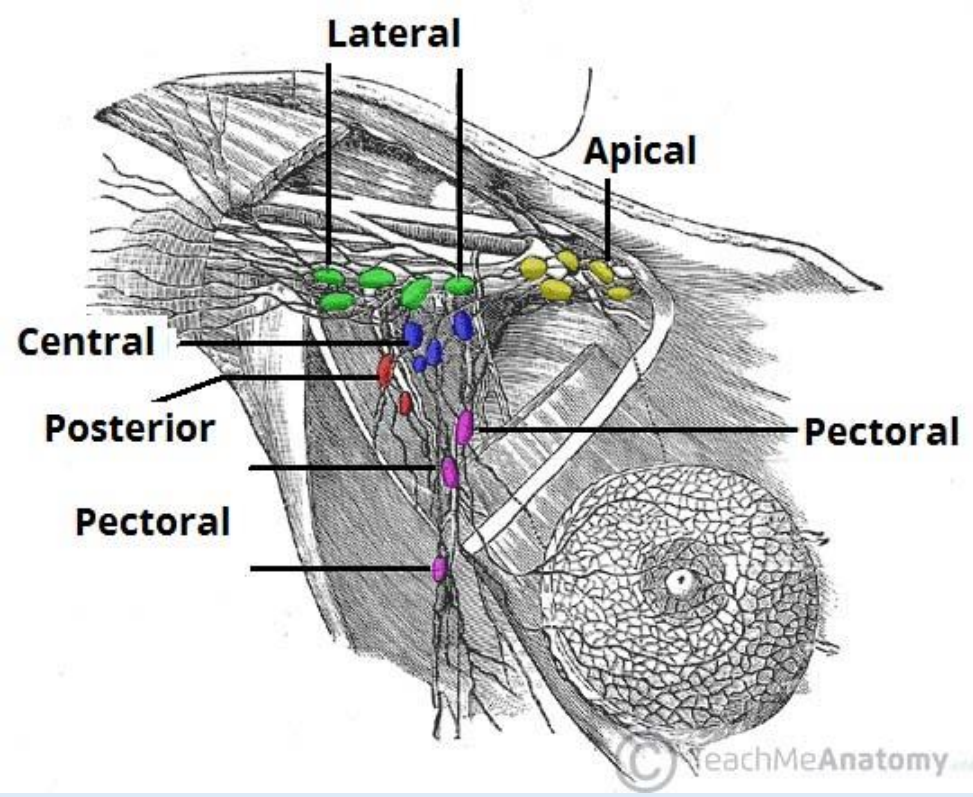

they are indicated will in this figure . the internal mammary is not shown (present at the med line)

-END OF TEXT :3