Clinical Hematology

Problem Based Learning

Hikmat Abdel-Razeq, MD.
Chief Medical Officer & Deputy Director General
Chairman, Department of Internal Medicine
Head, Section of Hematology and Medical Oncology
King Hussein Cancer Center

慷慨

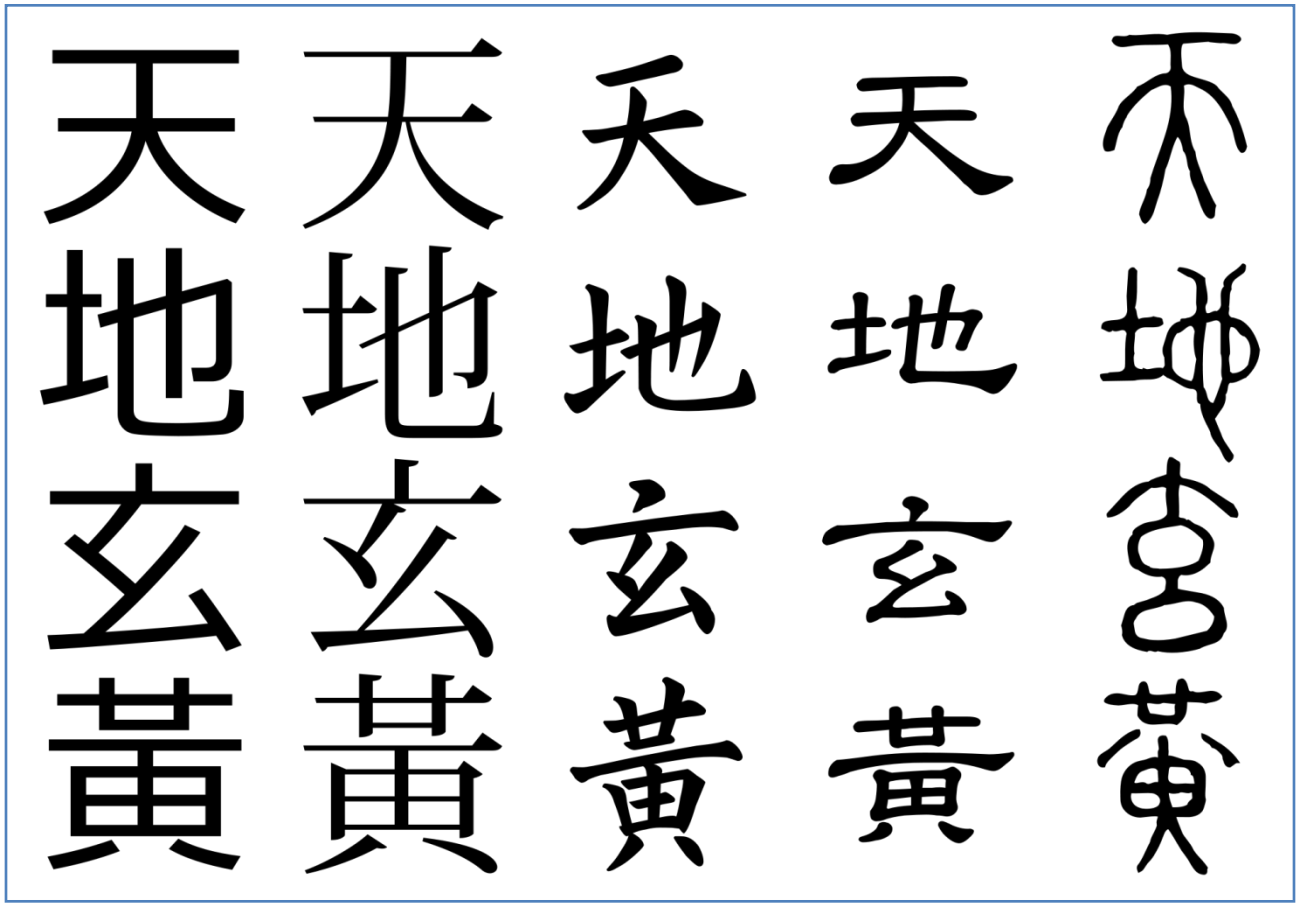

Clinical Hematology

1. Benign Hematology
2. Malignant Hematology
3. Hemostasis and Thrombosis
4. Transfusion Medicine

Clinical Hematology

Benign Hematology

- Anemia
- Benign WBC disorders
- Bone marrow disorders (non-malignant)

Clinical Hematology

Malignant Hematology

- Leukemia: acute/chronic
- Lymphomas: NHL/ HL
- Plasma cell disorders
- Myeloproliferative neoplasms (MPN)
- Myelodysplastic syndrome (MDS)

Clinical Hematology

Hemostasis and Thrombosis

- Platelet disorders
- Thrombosis
- Anticoagulation
- Hemophilias

Transfusion Medicine

Four Components

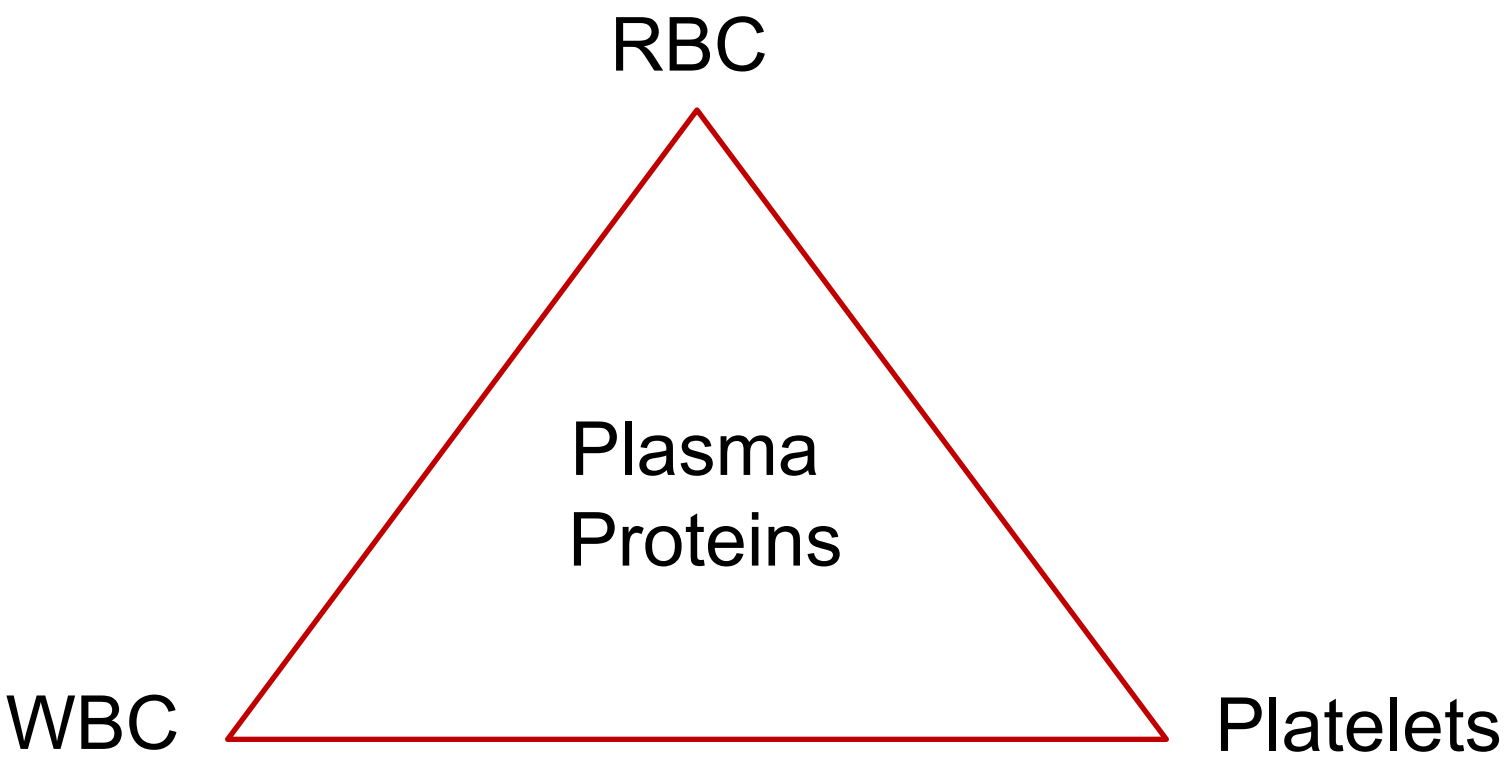

Red Blood Cells

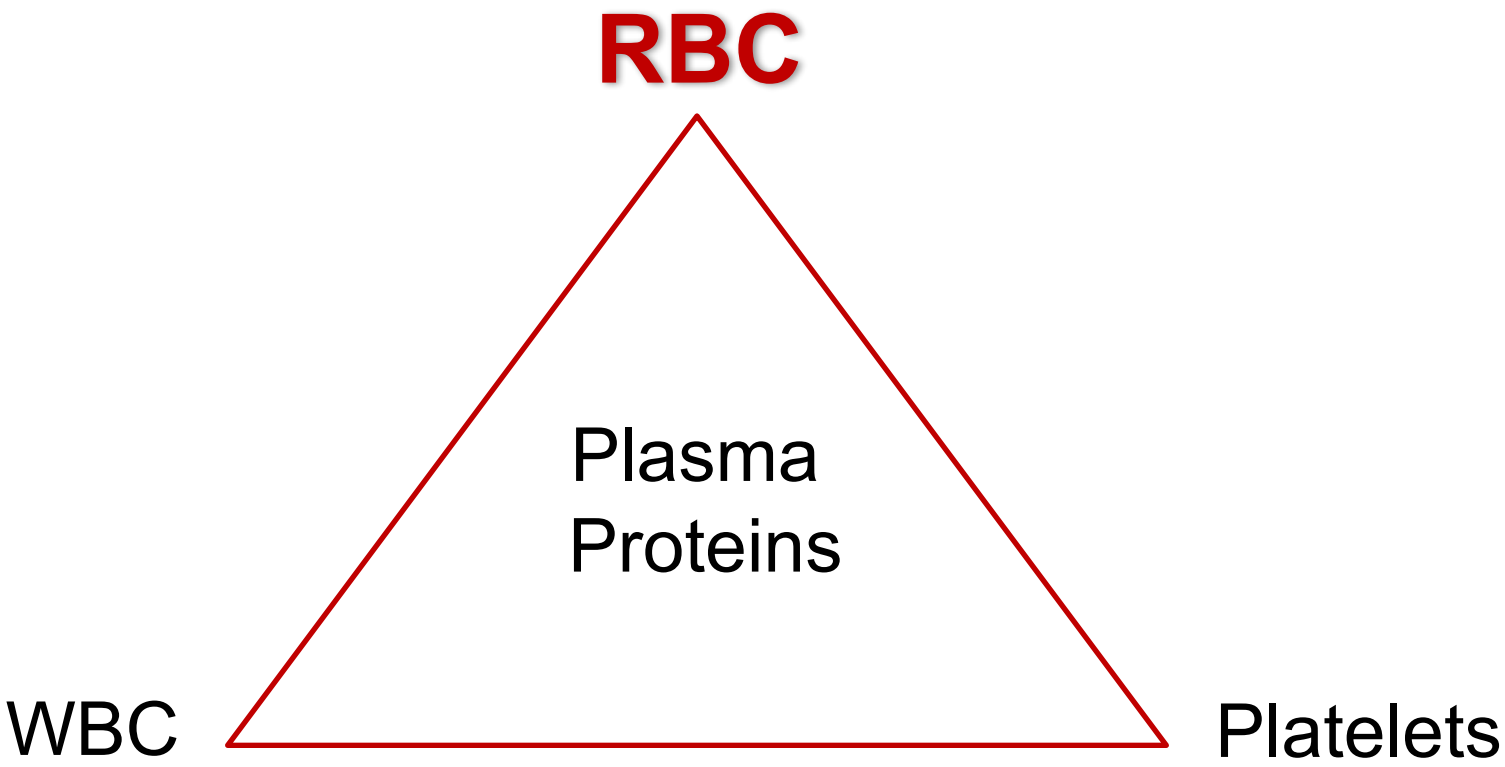

RBC

- **Less RBC:**
  - Anemia
    - Low production
    - Increase destruction
- **More RBC:**
  - Erythrocytosis
    - Polycythemia

Anemia



Laboratory Diagnosis

	Men	Women
Hemoglobin (g/dL)	14-17.4	12.3-15.3
Hematocrit (%)	42-50%	36-44%
RBC Count ($10^6/mm^3$)	4.5-5.9	4.1-5.1
Reticulocytes	1.6 ± 0.5%	1.4 ± 0.5%
WBC (cells/mm^3)	~4,000-11,000	
MCV (fL)	80-96	
MCH (pg/RBC)	30.4 ± 2.8	
MCHC (g/dL of RBC)	34.4 ± 1.1	
RDW (%)	12-15%	

Laboratory Diagnosis

	Men	Women
Hemoglobin (g/dL)	14-17.4	12.3-15.3
Hematocrit (%)	42-50%	36-44%
RBC Count ($10^6/mm^3$)	4.5-5.9	4.1-5.1
Reticulocytes	1.6 ± 0.5%	1.4 ± 0.5%
WBC (cells/mm^3)	~4,000-11,000	
MCV (fL)	**80-96**	
MCH (pg/RBC)	30.4 ± 2.8	
MCHC (g/dL of RBC)	34.4 ± 1.1	
RDW (%)	12-15%	

MCV

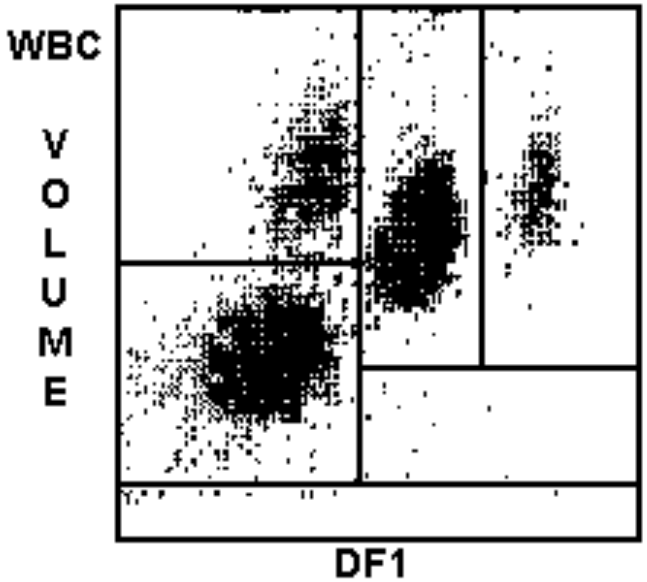

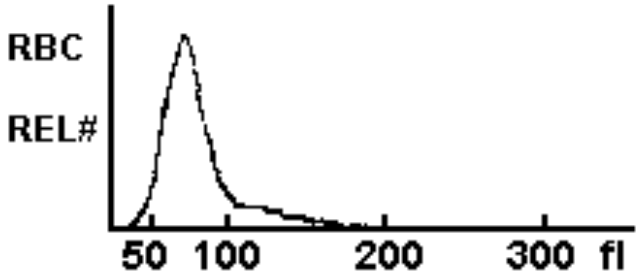

WBC	5.5		
	%		#
NE	54.7		3.0
LY	34.1		1.9
MO	7.5		0.4
EO	3.0		0.2
BA	0.7		0.0
RBC	4.28	L	
HGB	9.7	L	
HCT	29.9	L	
MCV	69.7	L	
MCH	22.6	L	
MCHC	32.4	L	
RDW	18.4	H	
PLT	331		
MPV	8.8		

Laboratory Diagnosis

	Men	Women
Hemoglobin (g/dL)	14-17.4	12.3-15.3
Hematocrit (%)	42-50%	36-44%
RBC Count ($10^6/mm^3$)	4.5-5.9	4.1-5.1
Reticulocytes	1.6 ± 0.5%	1.4 ± 0.5%
WBC (cells/mm^3)	~4,000-11,000	
MCV (fL)	80-96	
MCH (pg/RBC)	30.4 ± 2.8	
MCHC (g/dL of RBC)	34.4 ± 1.1	
RDW (%)	**12-15%**	

RDW: Red Cell Distribution Width

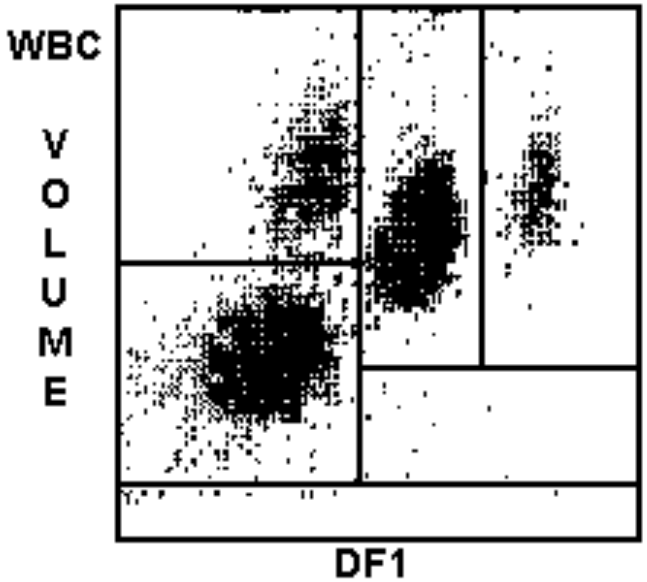

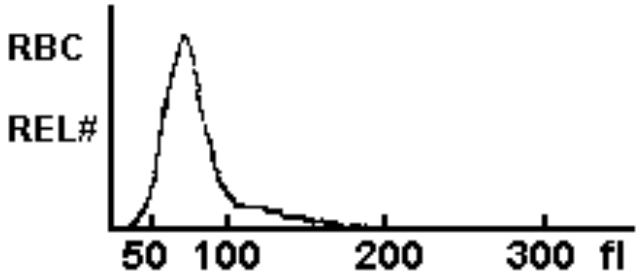

WBC	5.5		
	%		#
NE	54.7		3.0
LY	34.1		1.9
MO	7.5		0.4
EO	3.0		0.2
BA	0.7		0.0
RBC	4.28	L	
HGB	9.7	L	
HCT	29.9	L	
MCV	69.7	L	
MCH	22.6	L	
MCHC	32.4	L	
RDW	18.4	H	
PLT	331		
MPV	8.8		

White Blood Cells

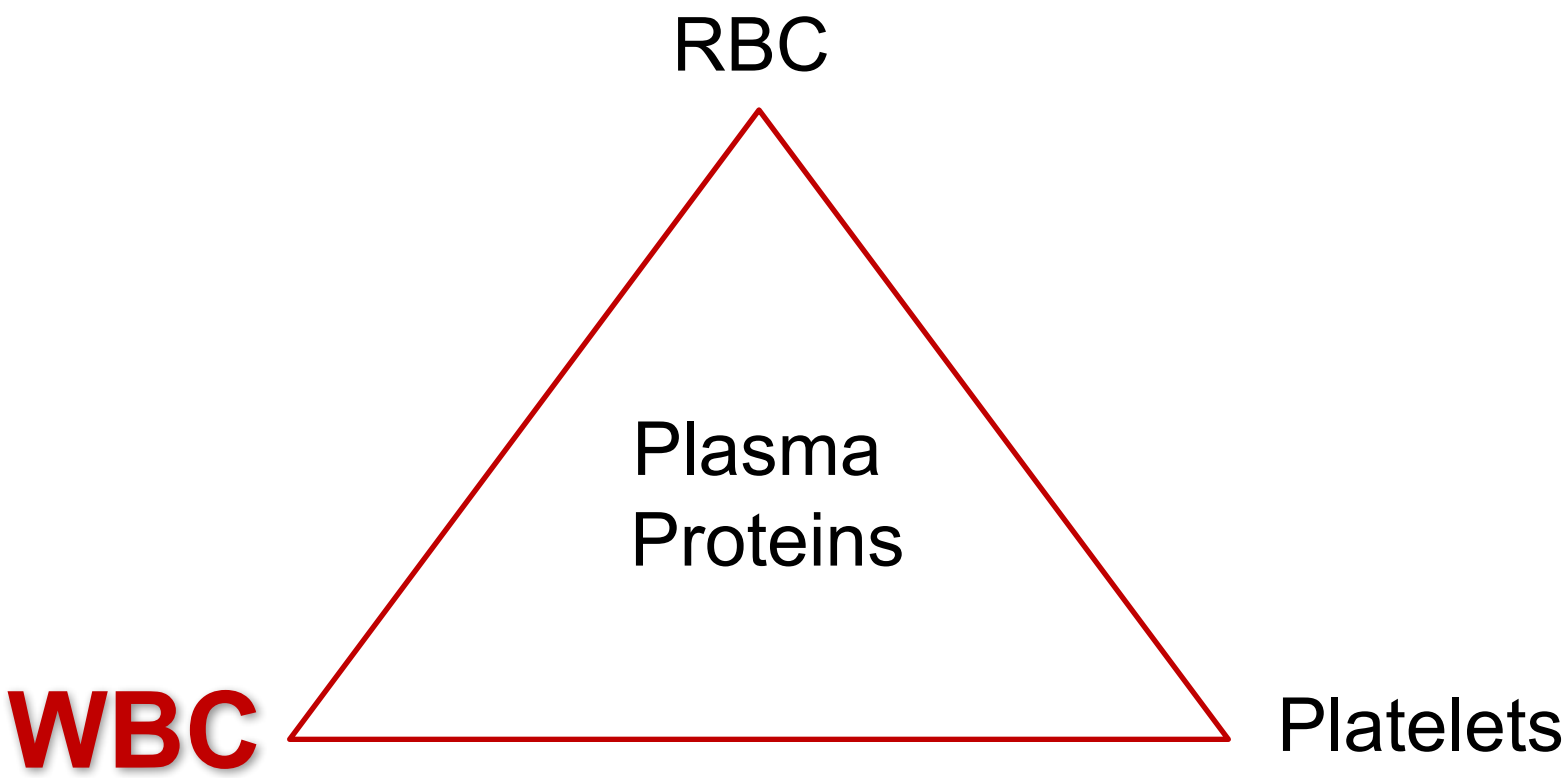

WBC

- **High WBC** (Leukocytosis):
  - Infection (Leukemoid reaction)
  - Inflammation
  - Leukemia
- **Low WBC** (Leukopenia)
- Normal in number (Dysfunction):
  - Immune deficiency

Platelets

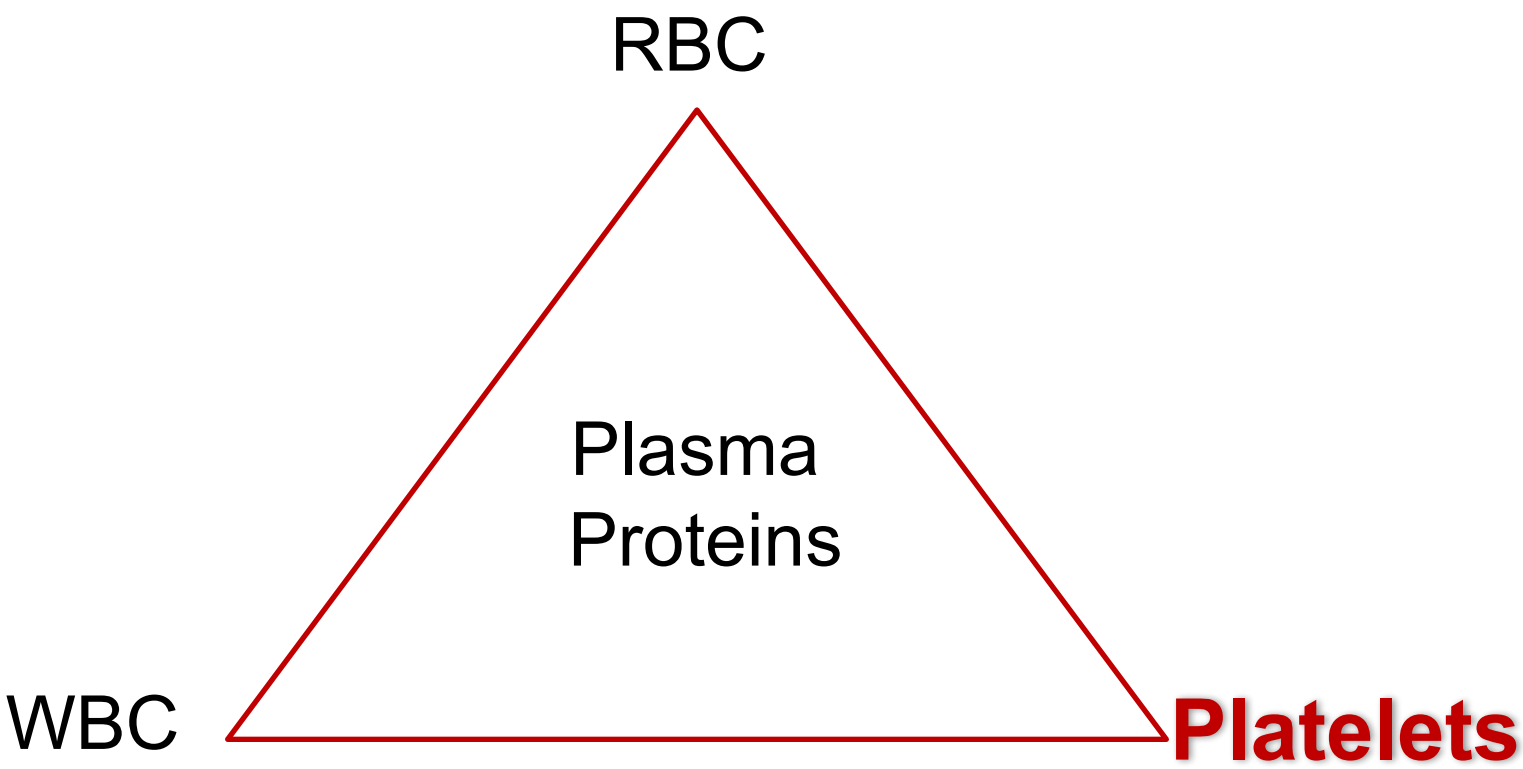

Platelets

- **Low Platelets** (Thrombocytopenia)
  - Increased destruction
  - Decreased production
- **High Platelets** (Thrombocytosis)
  - Inflammation
  - Essential thrombocythemia
- **Normal in number** (Dysfunction)

Plasma Proteins

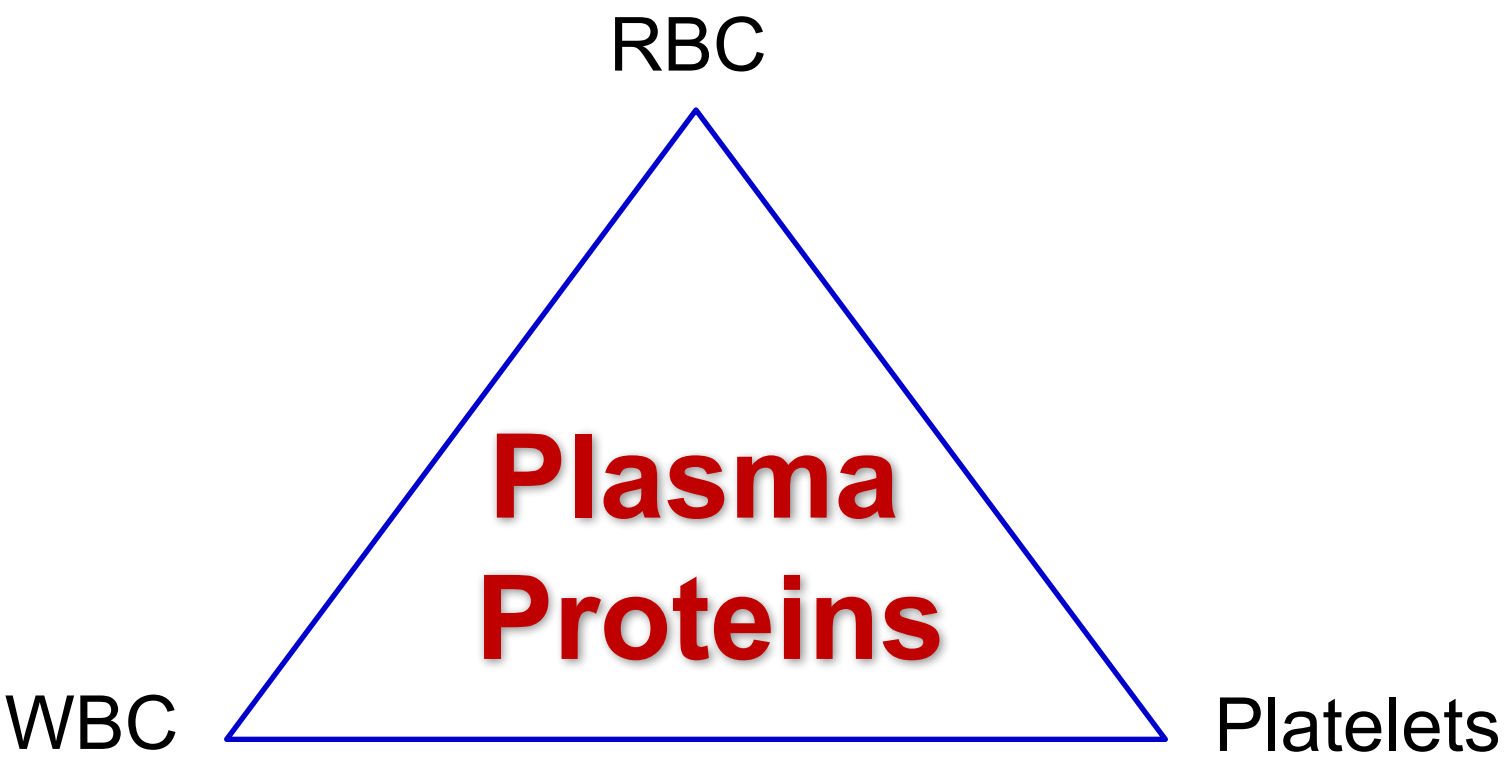

Plasma Proteins

- **High:**
  - Hyperviscosity
- **Low:**
  - Coagulation factors: **Bleeding**
  - Albumin: can lead to edema

CASE-1

Elderly with low back pain

Case-1

- 68 year old male patient
- Complains of back pain for several months
- Fractured his left leg 2 days ago.

Case-1

- 68 year old male patient
- Complains of back pain for several months
- Fractured his left leg 2 days ago.

Investigations

- Hb: 7.3, WBC: 8.6, Plt: 200
- ESR: 120

- BUN: 115, Creatinine : 3.2
- Total proteins: High
- Serum albumin: low
- Serum calcium: 13 mg/dL (5-10)

- Blood film
- Serum protein electrophoresis

Blood Film

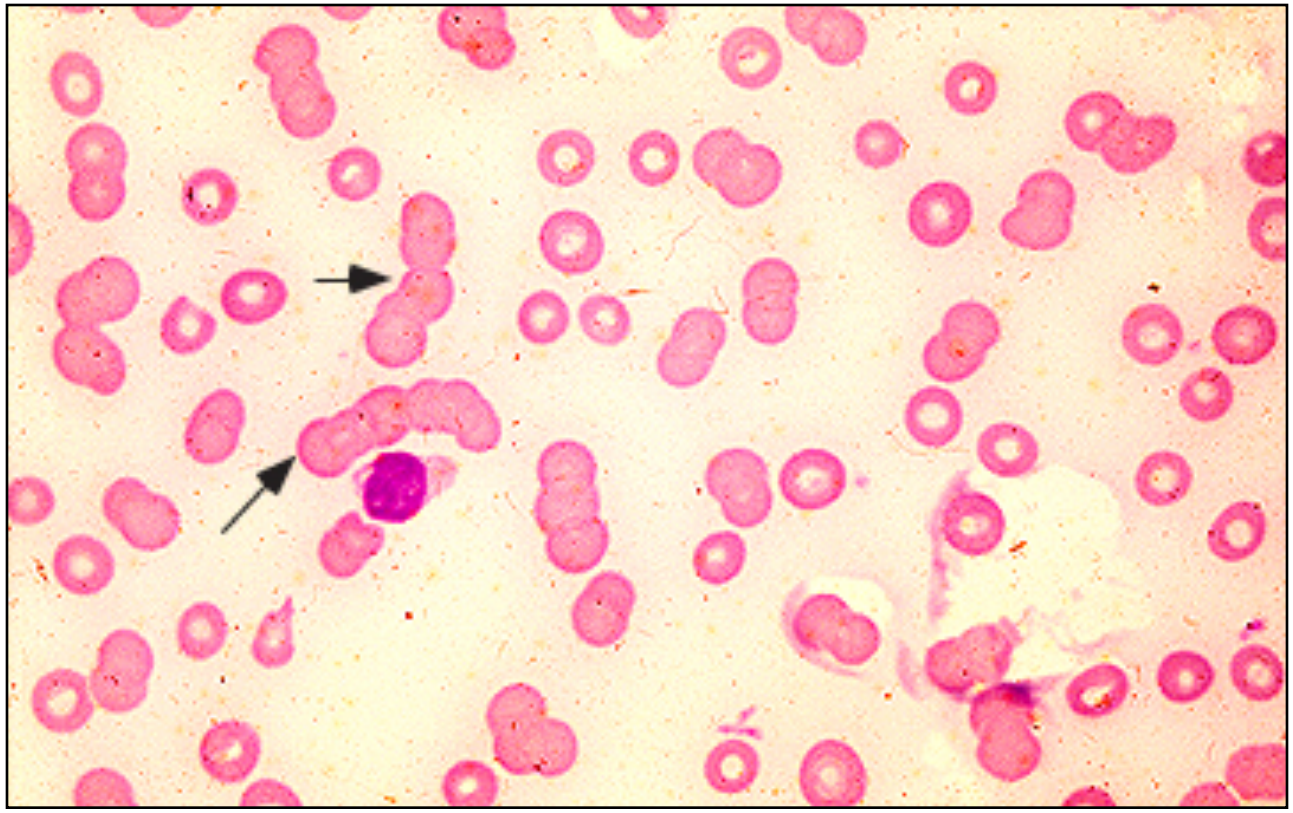

Normal SPEP

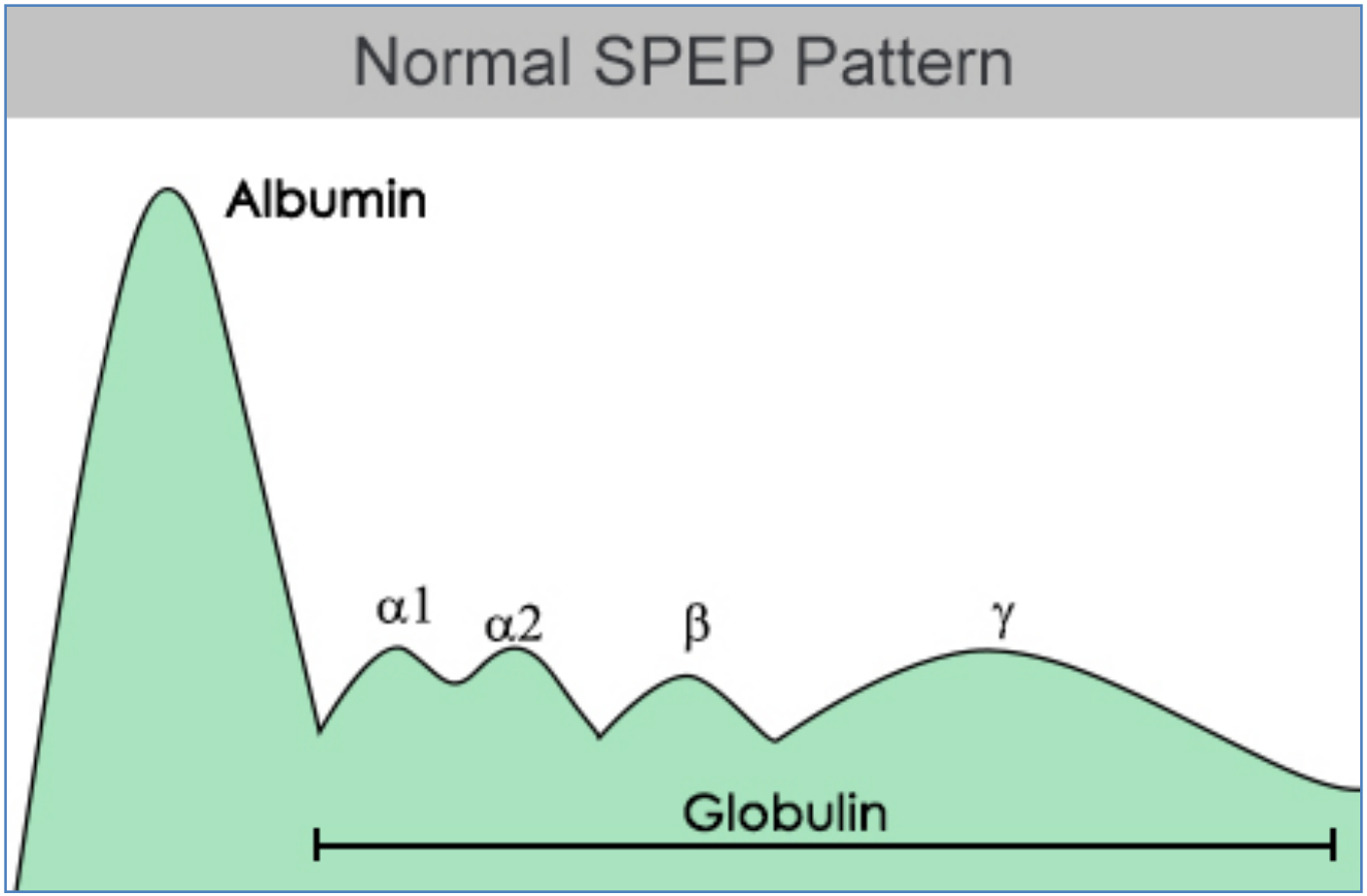

~~Normal SPEP~~

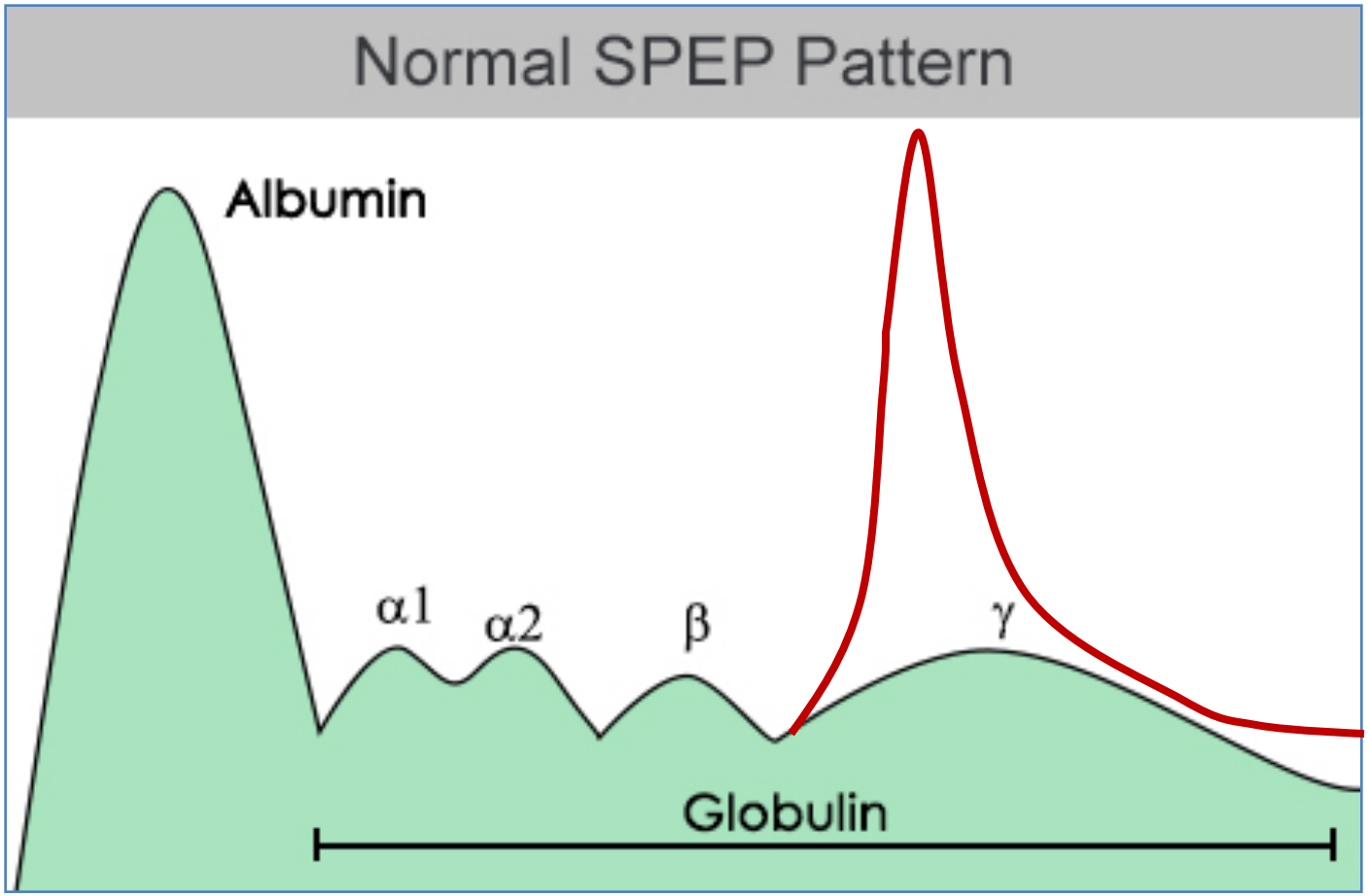

SPEP

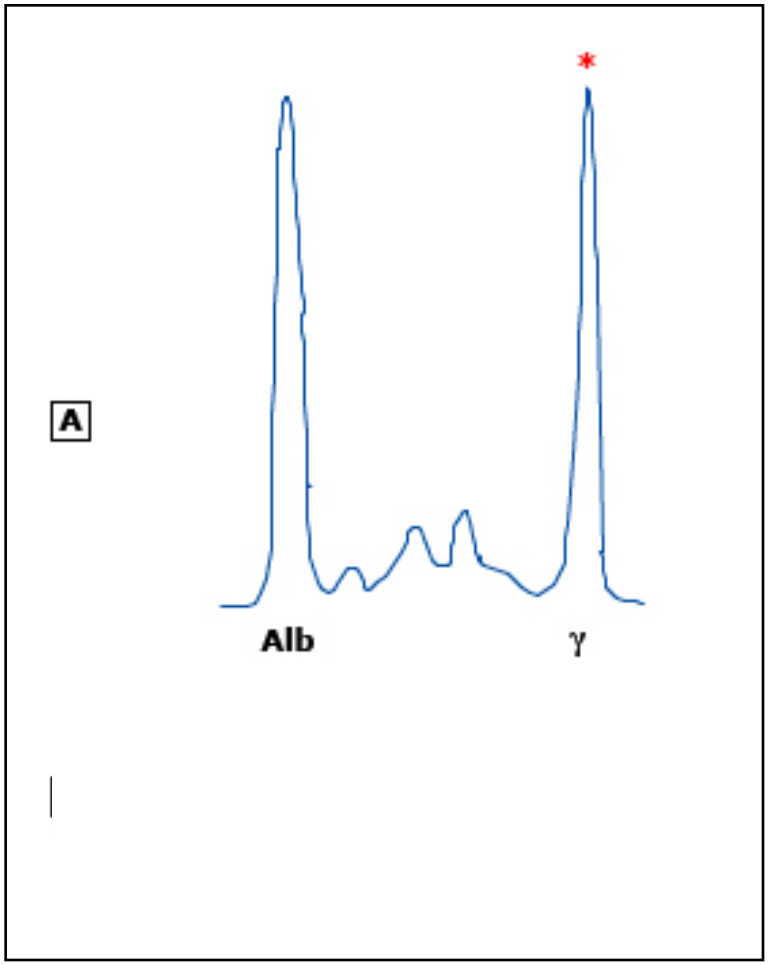

CASE-2

Elderly with loss of balance

Case-2

- A 68-year-old man is evaluated for loss of balance and paresthesia of the hands and feet of 8 months' duration.

- **Past History:**
  - Type 2 diabetes mellitus: 23 years
- **Social History:**
  - Drinks three cans of beer daily.

- **Physical examination:**
  - Short-term memory loss.
  - No stigmata of chronic liver disease.
  - Absence of vibration and proprioception in the toes and ankles

- The Romberg test becomes positive when the patient closes his eyes.

Case-2

Laboratory Studies:

- Hb: 9.7
- MCV: 105
- WBC: 8500/µL
- Platelets: 250,000/µl

- A peripheral blood smear is shown

Blood Film

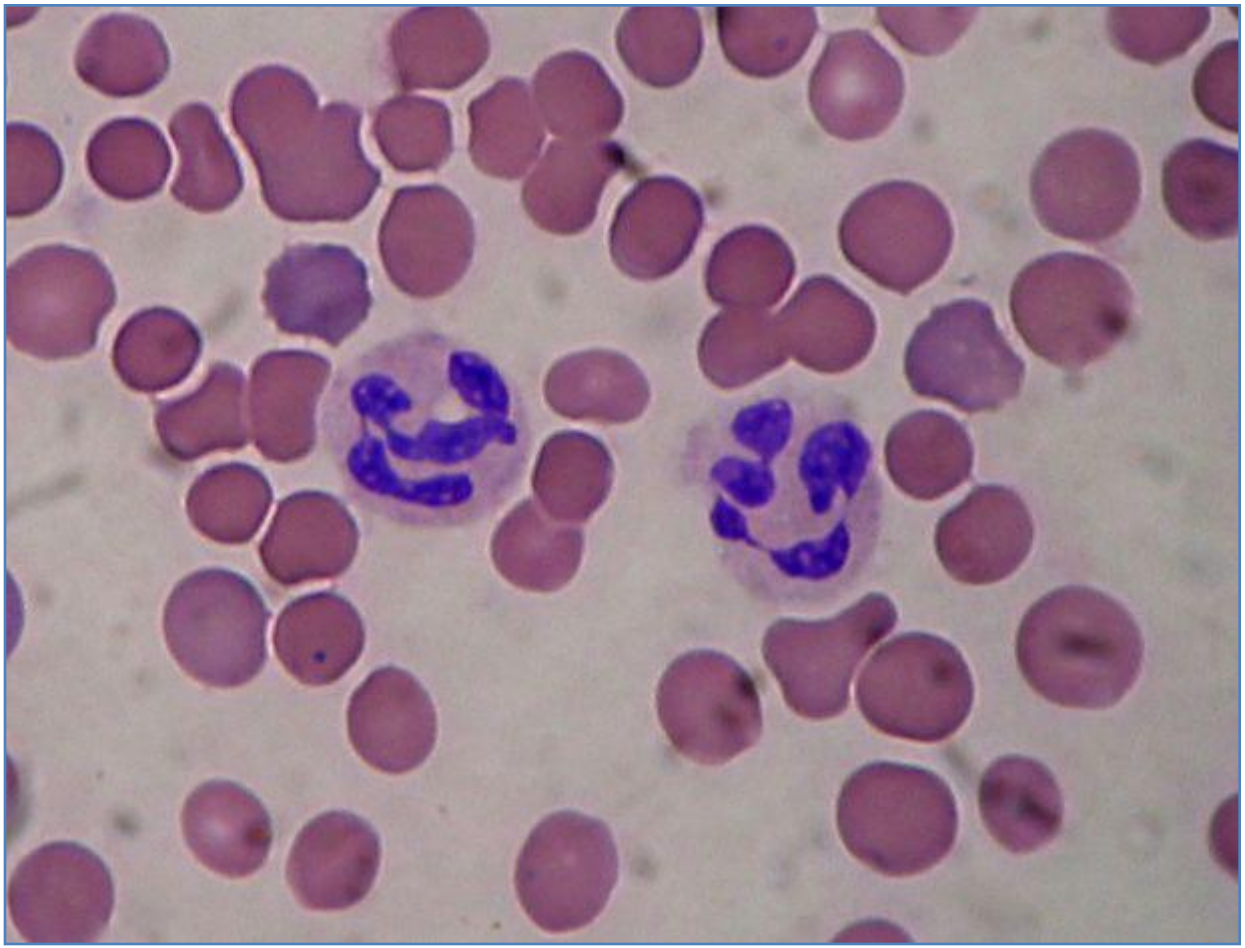

CASE-3

62 year old male with anemia

Case-3

- 62 year old male patient presented to his internist:
  - Progressive SOB (shortness of breathe)
  - Generalized weakness.

- His physical exam :
  - Pale
  - Nail changes
  - Mouth

Pallor

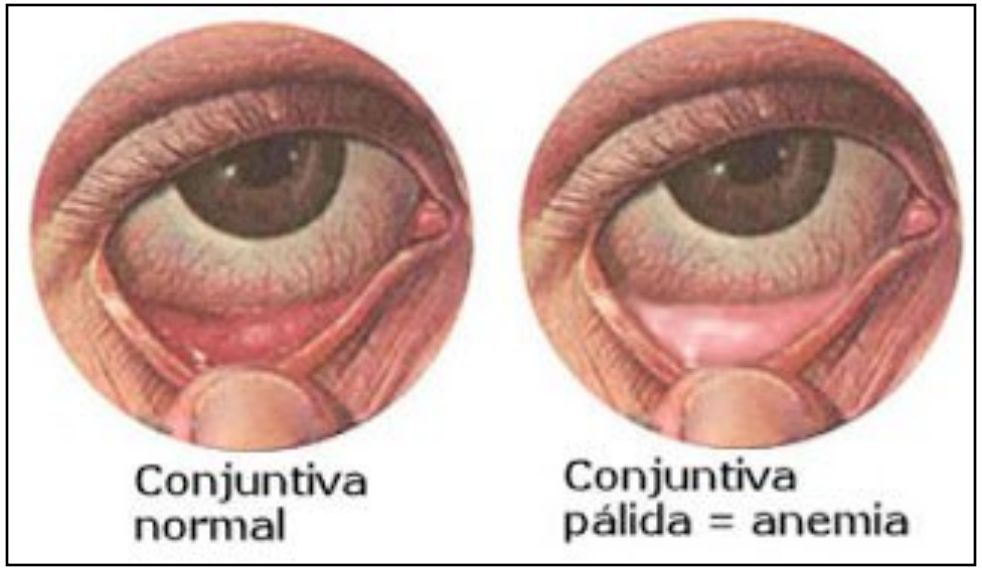

Nails

Anemia

CBC

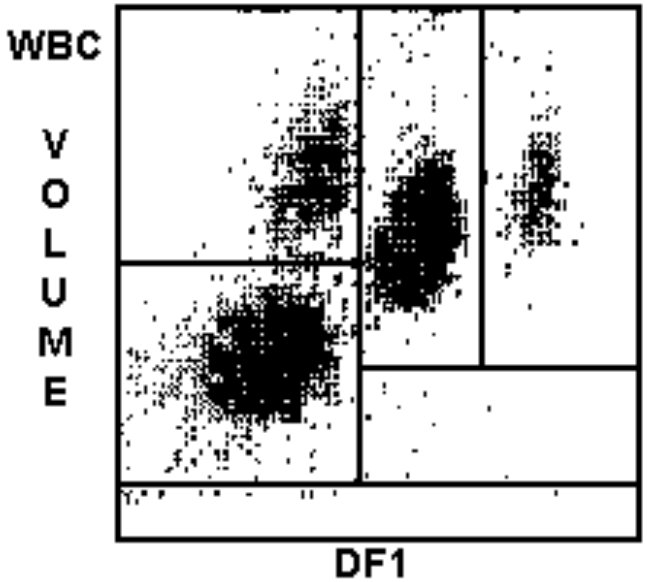

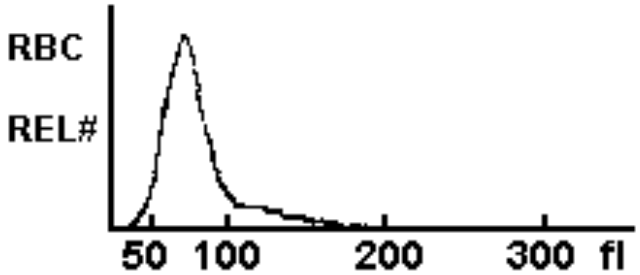

WBC	5.5		
	%		#
NE	54.7		3.0
LY	34.1		1.9
MO	7.5		0.4
EO	3.0		0.2
BA	0.7		0.0
RBC	4.28	L	
HGB	9.7	L	
HCT	29.9	L	
MCV	69.7	L	
MCH	22.6	L	
MCHC	32.4	L	
RDW	18.4	H	
PLT	331		
MPV	8.8		

CBC

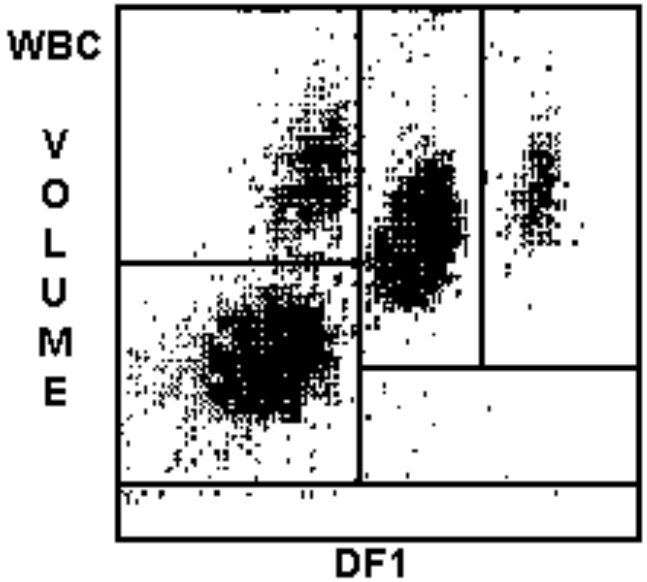

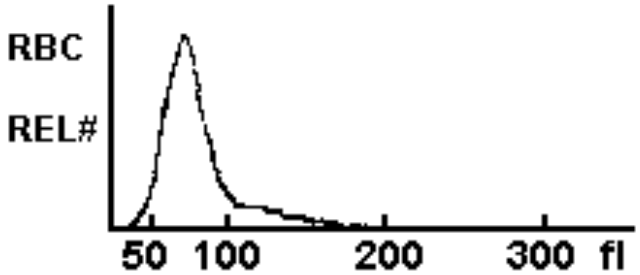

WBC	5.5		
	%		#
NE	54.7		3.0
LY	34.1		1.9
MO	7.5		0.4
EO	3.0		0.2
BA	0.7		0.0
RBC	4.28	L	
HGB	9.7	L	
HCT	29.9	L	
MCV	69.7	L	
MCH	22.6	L	
MCHC	32.4	L	
RDW	18.4	H	
PLT	331		
MPV	8.8		

CBC

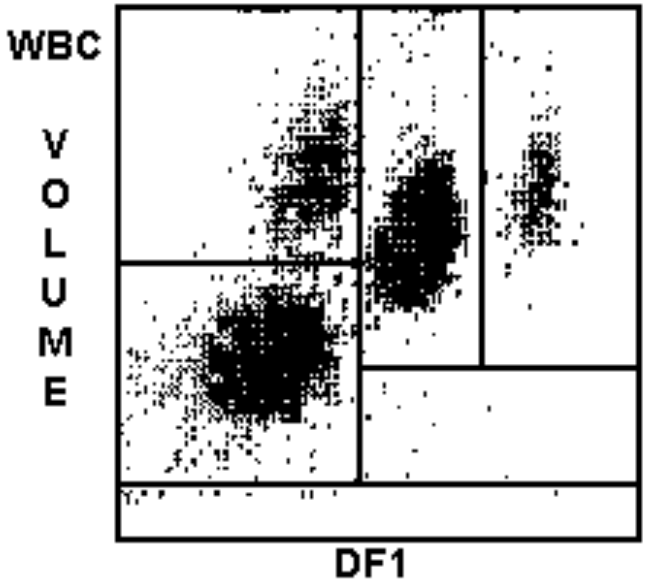

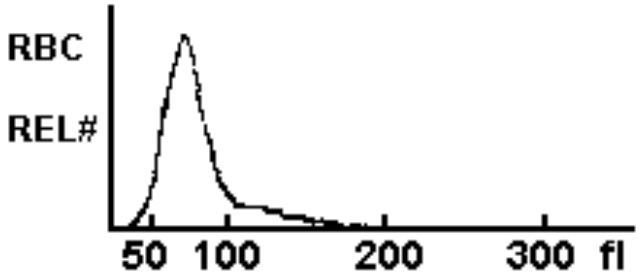

WBC	5.5		
	%		#
NE	54.7		3.0
LY	34.1		1.9
MO	7.5		0.4
EO	3.0		0.2
BA	0.7		0.0
RBC	4.28	L	
HGB	9.7	L	
HCT	29.9	L	
MCV	69.7	L	
MCH	22.6	L	
MCHC	32.4	L	
RDW	18.4	H	
PLT	331		
MPV	8.8		

Blood Film

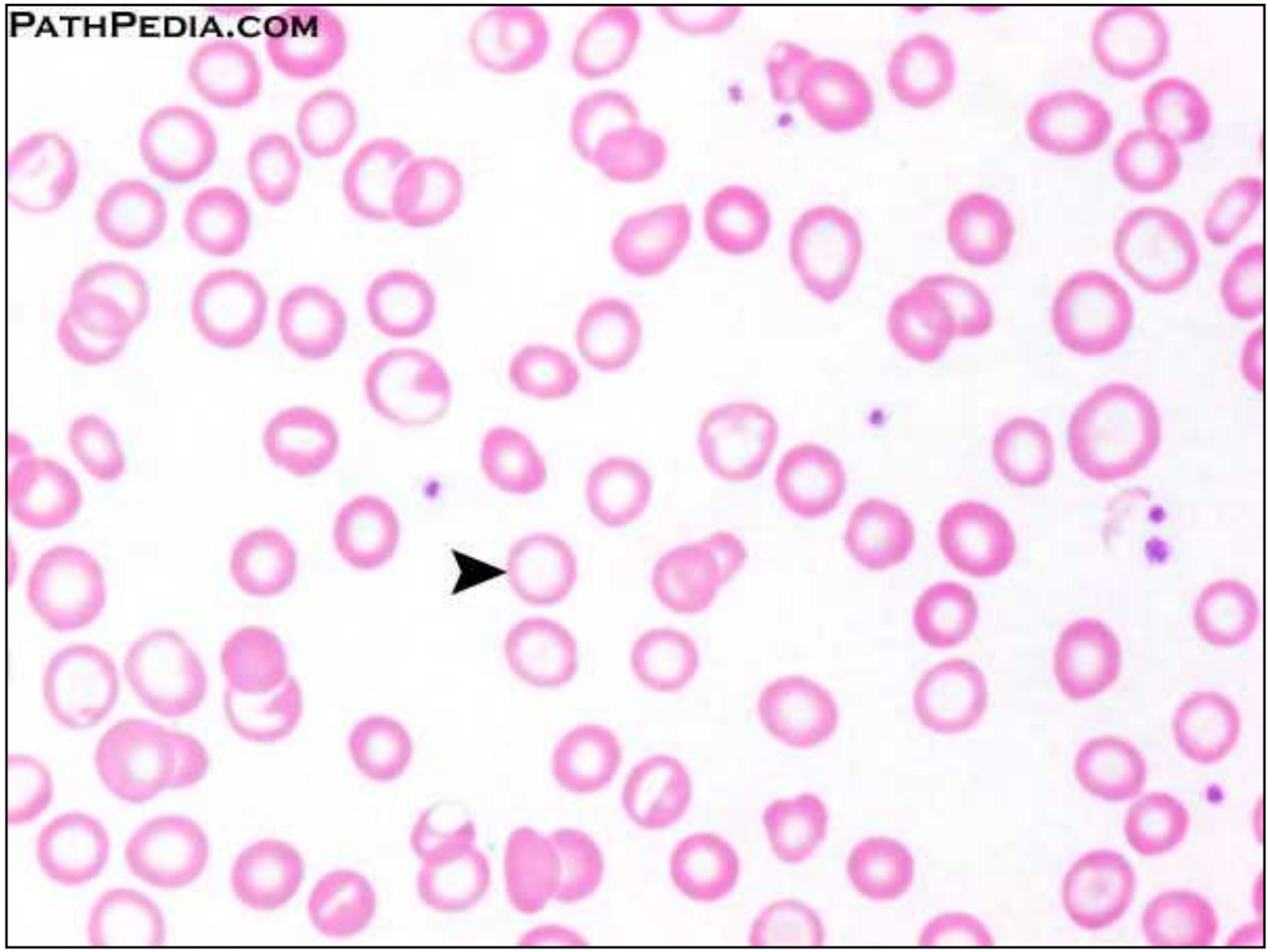

Iron Studies

- Serum Fe: 10 µg/dL
- Serum Ferritin: 2 ng/ml
- Total iron binding capacity (TIBC): 450 µg/Dl

Colonoscopy

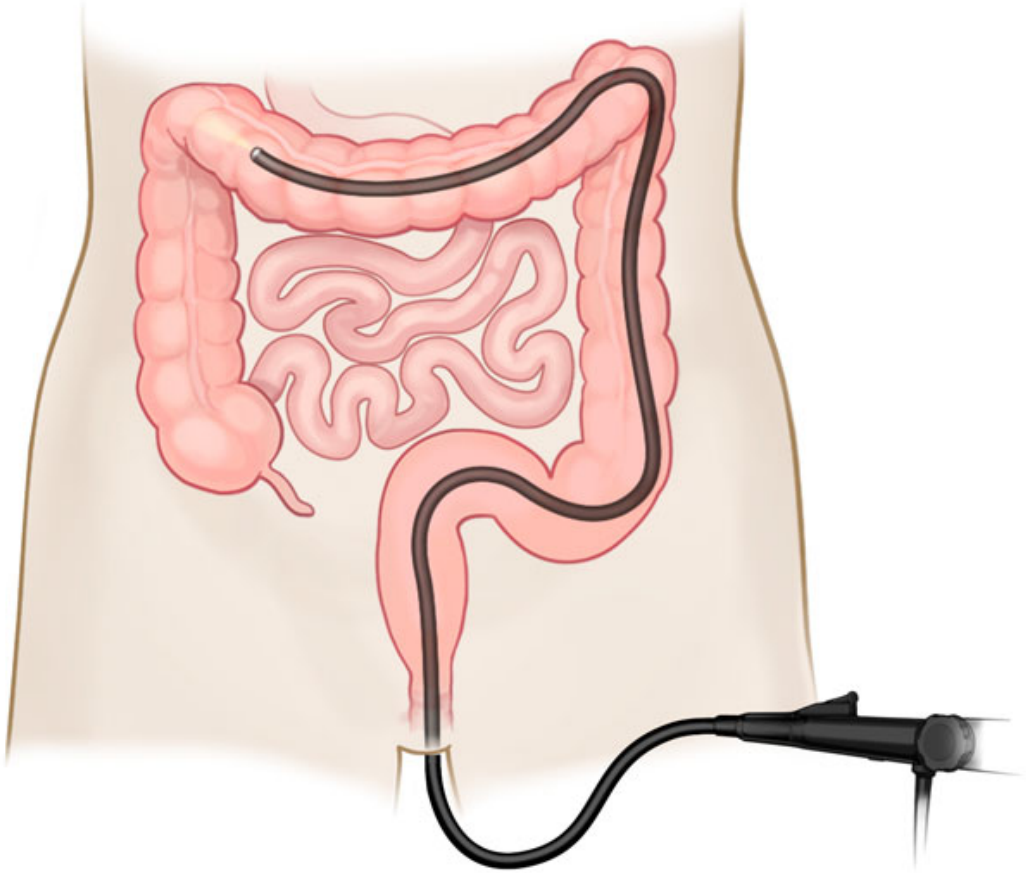

Colonoscopy

CASE-4

Young woman with fever, confusion and low platelets

Case-4

- A 40-year-old woman presented with one week history of fever and confusion.

- Physical examination:
  - T 38.2 C, P 100/minute, RR 20/minute, and BP 100/60 mm Hg.
  - Her legs are shown

- Laboratory studies showed:
  - BUN: 52 mg/Dl, Creatinine 5.3 mg/dL.
  - Hb:12.2 g/dL, MCV: 93 Fl
  - Platelets: 19,000/microliter, WBC: 8180/microliter.
  - Blood film

Case-4

Case-4

- A 40-year-old woman presented with one week history of fever and confusion.

- Physical examination:
  - T 38.2 C, P 100/minute, RR 20/minute, and BP 100/60 mm Hg.
  - Her legs are shown

- Laboratory studies showed:
  - BUN: 52 mg/Dl, Creatinine 5.3 mg/dL.
  - Hb:12.2 g/dL, MCV: 93 Fl
  - Platelets: 19,000/microliter, WBC: 8180/microliter.
  - Blood film

Case-4

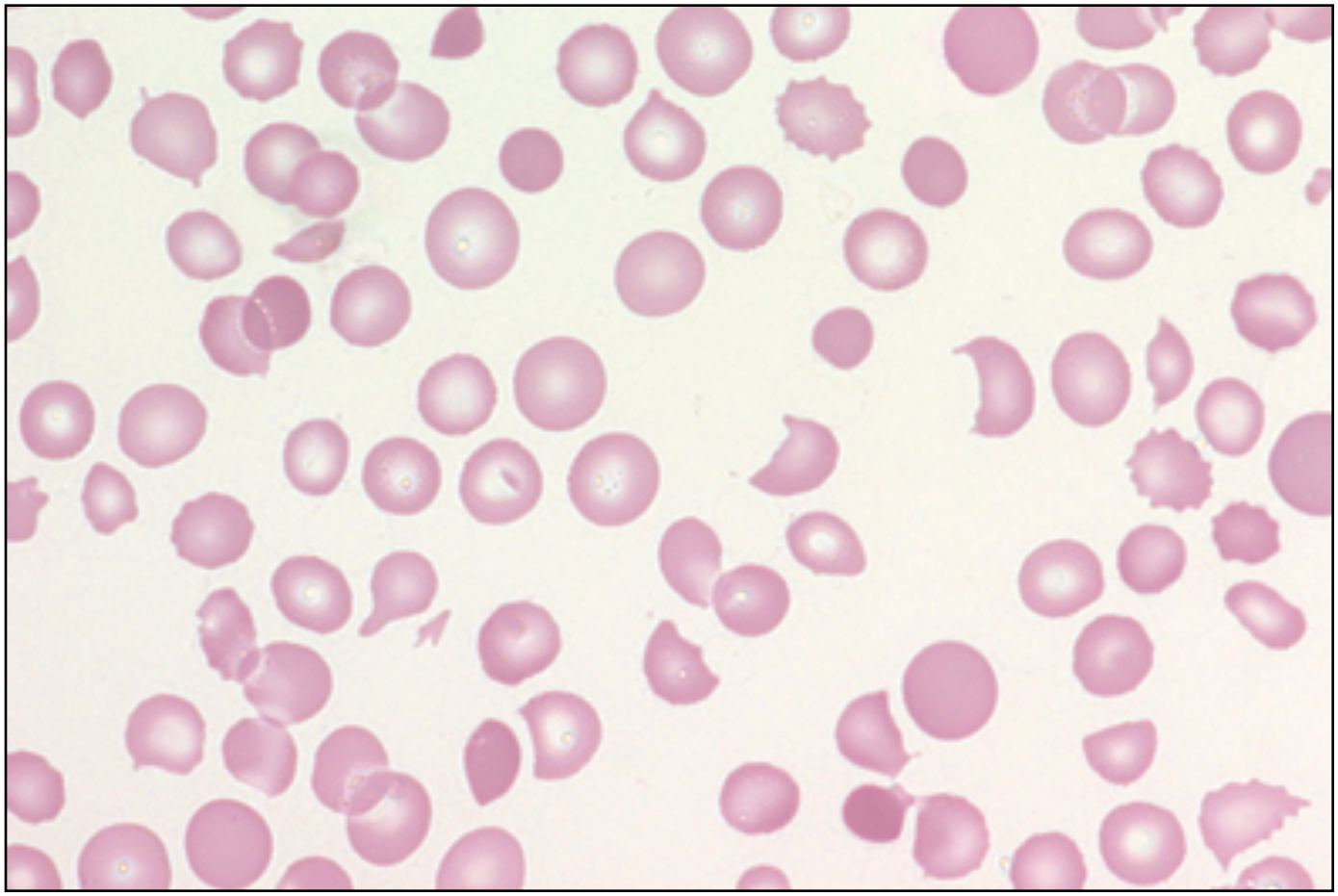

Case-4

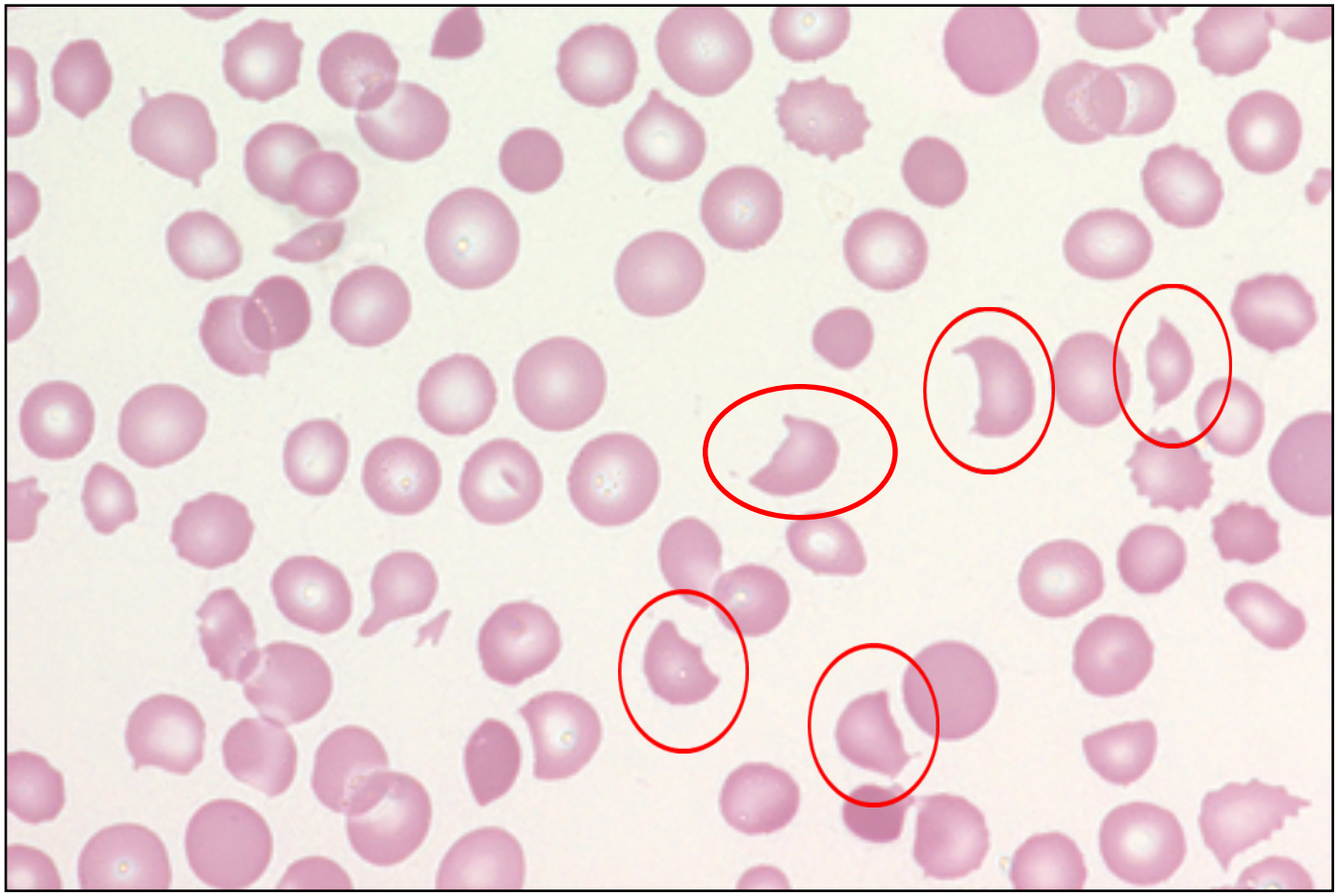

Case-4

- A 40-year-old woman presented with one week history of fever and confusion.

- Physical examination:
  - T 38.2 C, P 100/minute, RR 20/minute, and BP 100/60 mm Hg.
  - Her legs are shown

- Laboratory studies showed:
  - BUN: 52 mg/dL, Creatinine 5.3 mg/dL.
  - Hb:12.2 g/dL, MCV: 93 Fl
  - Platelets: 19,000/microliter, WBC: 8180/microliter.
  - Blood film

Case-4

Which of the following is the most likely diagnosis?

a. Disseminated intravascular coagulopathy (DIC)

b. Idiopathic thrombocytopenic purpura (ITP)

c. Thrombotic thrombocytopenic purpura (TTP)

d. Trousseau syndrome

e. Warm autoimmune hemolytic anemia

CASE-5

64 Male with asymptomatic leukocytosis

Case-5

- A 64 -year- old man is found to have an elevated WBC count while being worked up in a preoperative clinic for a hernia repair.
- No fever, night sweats, fatigue, or shortness of breath.
- Past history:
  - Mild hypertension
- Physical examination:
  - “Shotty” adenopathey
  - Inguinal hernia
- His spleen is not palpable

Lymphadenopathy

Lymphadenopathy

Lymphadenopathy

Case-5

- Laboratory studies:
  - Hemoglobin: 14 g/dL
  - WBC: 22.0 x 10^9/L
    - 75% Lymphocytes
  - Platelets: 203 x 10^9/L.
  - Peripheral blood smear
  - Flow cytometric analysis:
    - Monoclonal, mature B-cell population that is positive for CD5 and CD23 and negative for CD 10.

Blood Film

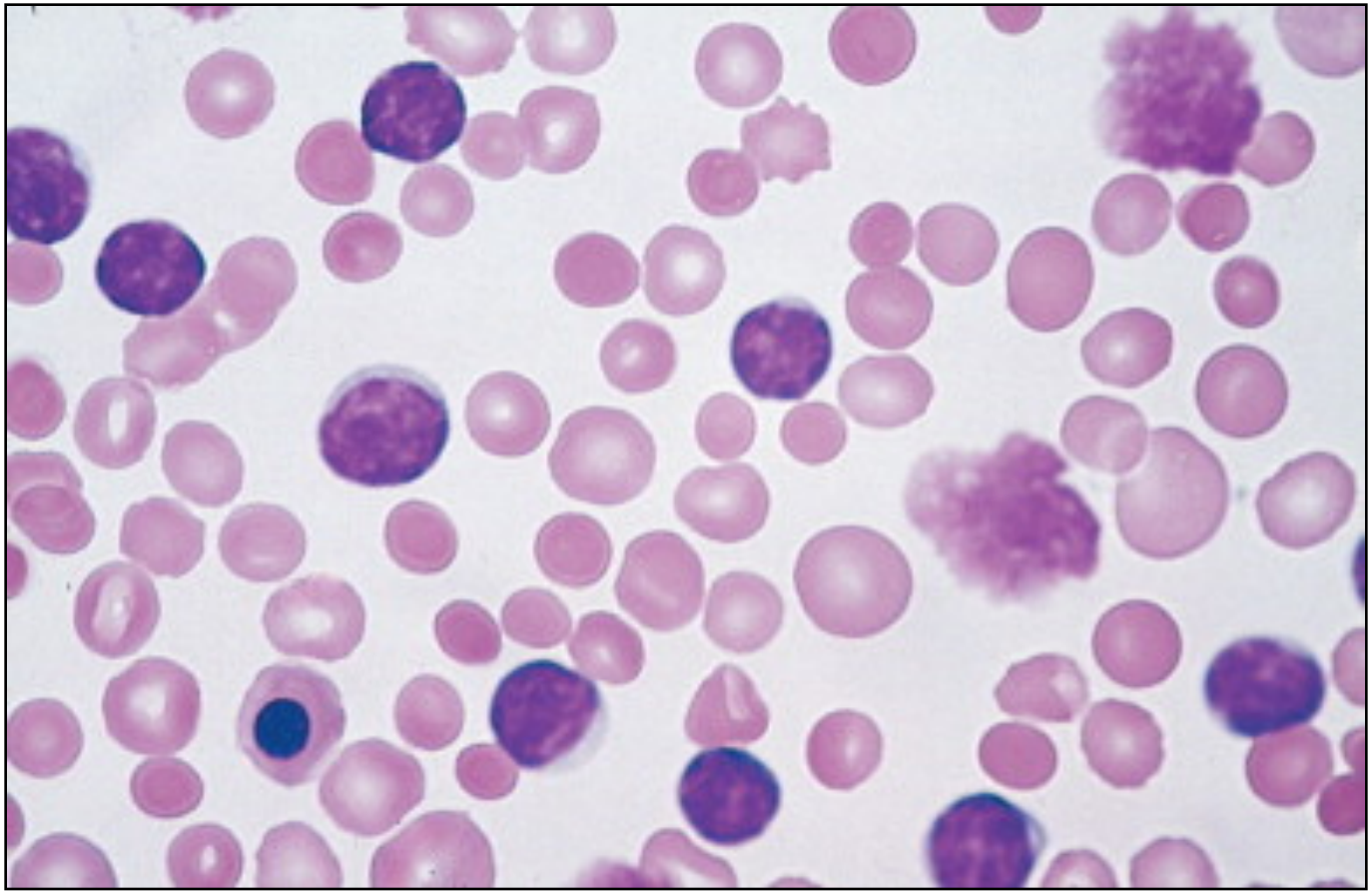

Case-5

- Laboratory studies:
  - Hemoglobin of 14 g/dL
  - WBC: 22.0 x 10^9/L
    - 75% Lymphocytes
  - Platelets: 203 x 10^9/L.
  - Peripheral blood smear
  - **Flow cytometric analysis**:
    - Monoclonal, mature B-cell population that is positive for CD5 and CD23 and negative for CD 10.

Case-5

Which of the following is the most likely diagnosis ?

a. Hairy cell leukemia

b. Chronic lymphocytic leukemia

c. Mantle cell lymphoma

d. Follicular lymphoma

e. Lymphoplasmacytic lymphoma.

Immunophenotypes

	CD 5	CD 43	CD 22	CD 23	CD 25	CD 103	Cytogenetics
CLL/SLL	+	+	-/+	+	+/-	-	
Mantle	+	+	-/+	-	-	-	T (11,14)
PLL	-/+	+	+	-/+	-	-	
HCL	-	+	+	-	+	+	
MZL	-	-/+	+/-	+/-	-	-	
Follicular	-/+	-	-/+	-/+	-	-	T (14,18)

What if ?

- A patient presents with abdominal lymphadenopathy and peripheral blood lymphocytosis.

- The immunophenotype is CD22+, CD5+, and CD23−
- Cytogenetic analysis shows a t(11:14) translocation.

- What is the diagnosis?

What if ?

What is the diagnosis?

a. Mantle cell lymphoma
b. Marginal zone lymphoma
c. Follicular lymphoma
d. Small lymphocytic lymphoma

CASE-6

Young female with high aPTT

Case-6

- 36 year old female patient was recently diagnosed with Rt. breast cancer.
- On admission mastectomy she was found to have a **normal PT** but her **aPTT was 120 seconds**.
- On further questioning, she denied any history of bleeding including a cesarean section and three other normal deliveries.
- She had no family history of bleeding.
- **1:1 mixing study**:
  - aPTT was 48 seconds that was increased to 52 seconds after one hour of incubation.

Coagulation Cascade

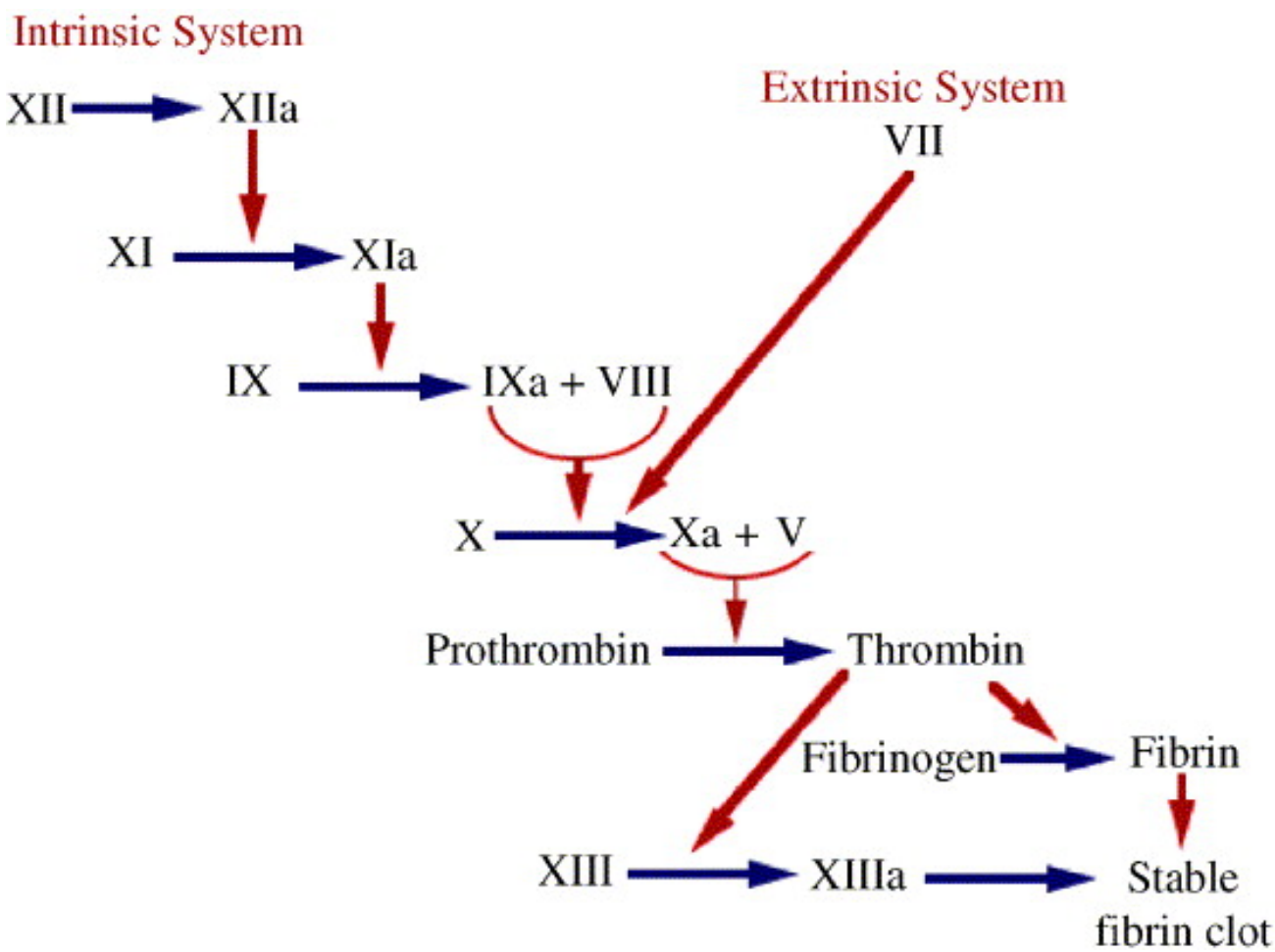

Case-6

Which of the following factor deficiency can explain her situation?

a. Factor VIII deficiency
b. Factor IX deficiency
c. Factor X deficiency
d. Factor XI deficiency
e. Factor XII deficiency

CASE-7

Young male with leukocytosis

Case-7

- A 30-year-old man has had a progressively worsening productive cough for one month.

- On physical examination:
  - Small non-tender lymph nodes are palpable in the axillae
  - Tip of the spleen is palpable.

- Laboratory studies showed:
  - Hb: 8.2 g/dl, MCV 90 fL
  - WBC: 67,000/microliter
  - Platelets: 36,000/microliter.

- Peripheral blood smear is shown

Blood Film

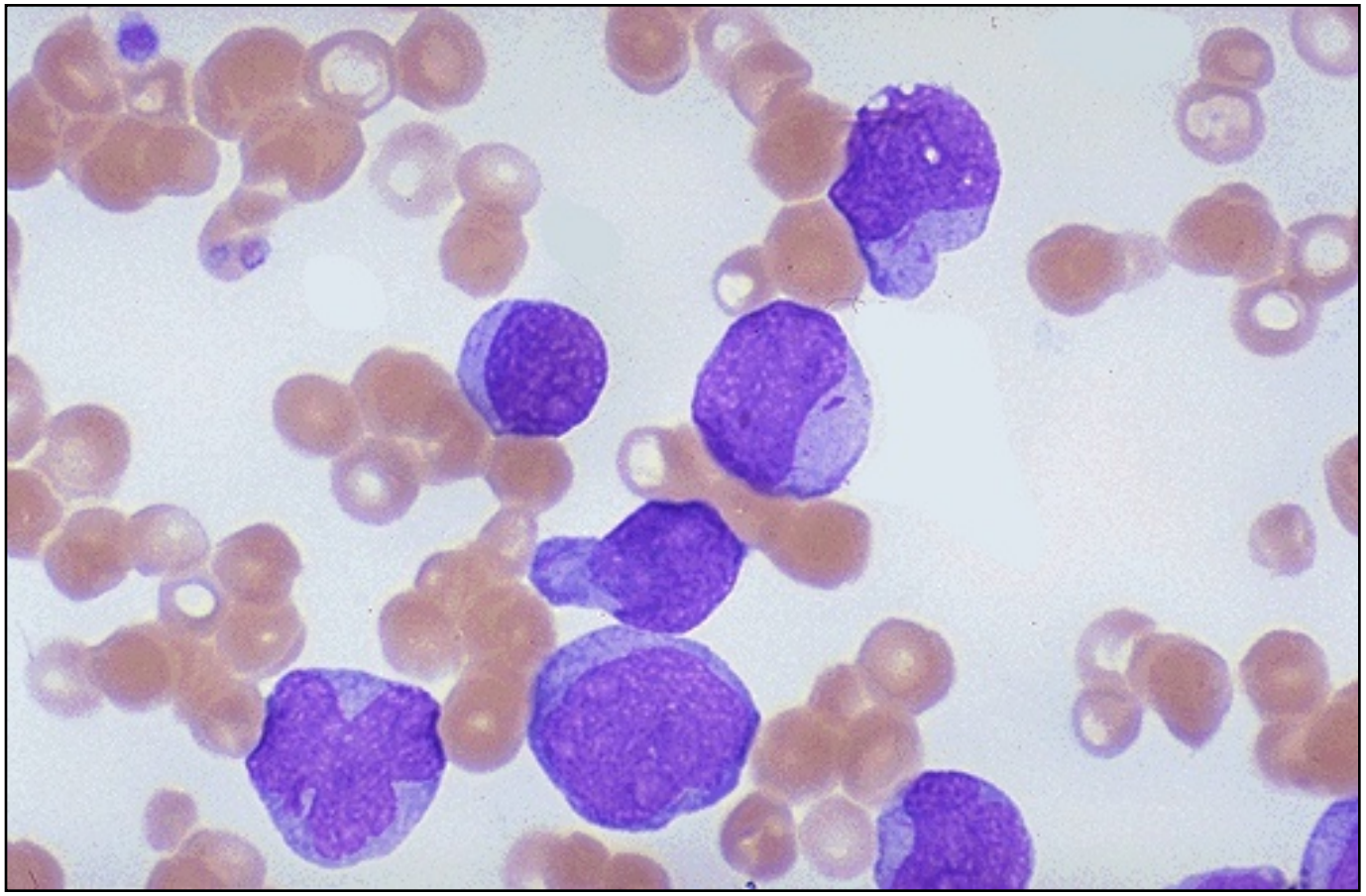

Case-7

Which of the following is the most likely diagnosis?

a. Leukemoid reaction
b. Acute myelogenous leukemia
c. Chronic lymphocytic leukemia
d. Acute lymphoblastic leukemia
e. Leukoerythroblastosis

CASE-8

Young male with leukocytosis, thrombocytosis and splenomegaly

Case-8

- 41 year old male patient presented with one month history of:
  - Increasing generalized weakness and easy fatigability.
  - Epigastric pain but with no vomiting.

- Exam was significant for significant splenomegaly but with no lymphadenopathy.

Case-8

- His initial work up:
  - WBC: 78,000
  - Hb: 10.2
  - Platelet counts: 890,000

- Blood film is shown

Blood Film

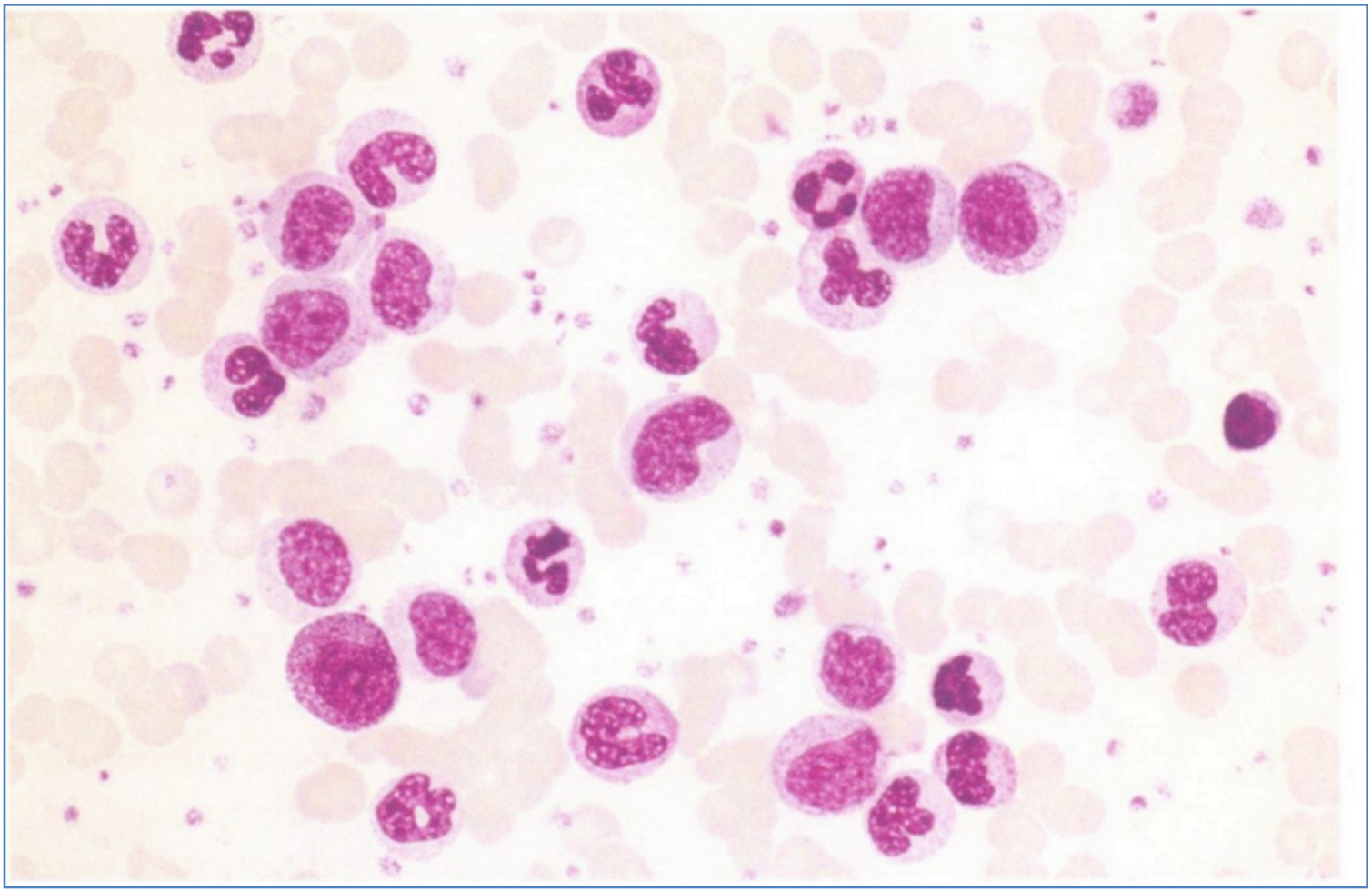

Case-8

- Which one of the following is the most likely diagnosis?

A. Chronic granulocytic leukemia
B. Acute granulocytic leukemia
C. Acute lymphocytic, T-cell type leukemia
D. Acute lymphocytic, B-cell type leukemia
E. Chronic Lymphocytic Lymphoma

CASE-9

57 Male with progressive weakness and anemia

Case-9

- A 57-year-old man is evaluated because of a 3-month history of progressive easy fatigability and shortness of breath when walking quickly.

- His physical examination is significant for splenomegaly
- Hemoglobin level of 9.1 g/dL.

- His stool is negative for occult blood when tested on three different occasions.

- The patient's peripheral blood smear is shown

Case-9

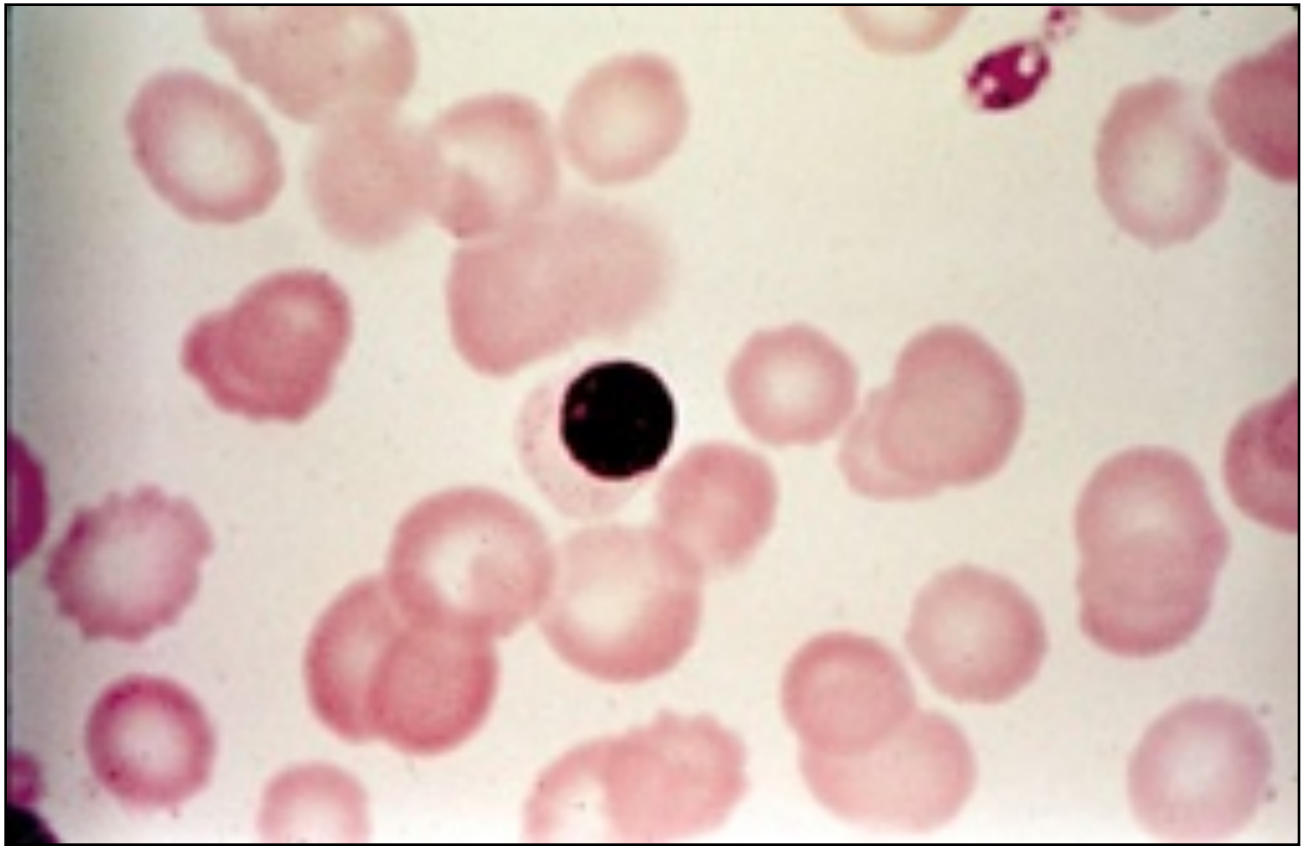

CASE-10

Known CLL with anemia

Case-10

- A 63-year-old man with chronic lymphocytic leukemia (CLL) is evaluated for increasing dyspnea on exertion that has developed over the past 2 weeks.

- He currently takes no medications.

- On physical examination:
  - afebrile.
  - Pale conjunctivae
  - Scattered axillary and inguinal lymphadenopathy that are unchanged from his last examination 1 year ago.

Laboratory Studies

- Hb: 6.2 (one year ago was 14.2)
- Platelet count: 285,000/µl
- WBC : 12,000/µL (25% polymorphonuclear , 75% lymphocytes)
- Reticulocyte count of 10%

- A peripheral blood smear is shown

Blood Film

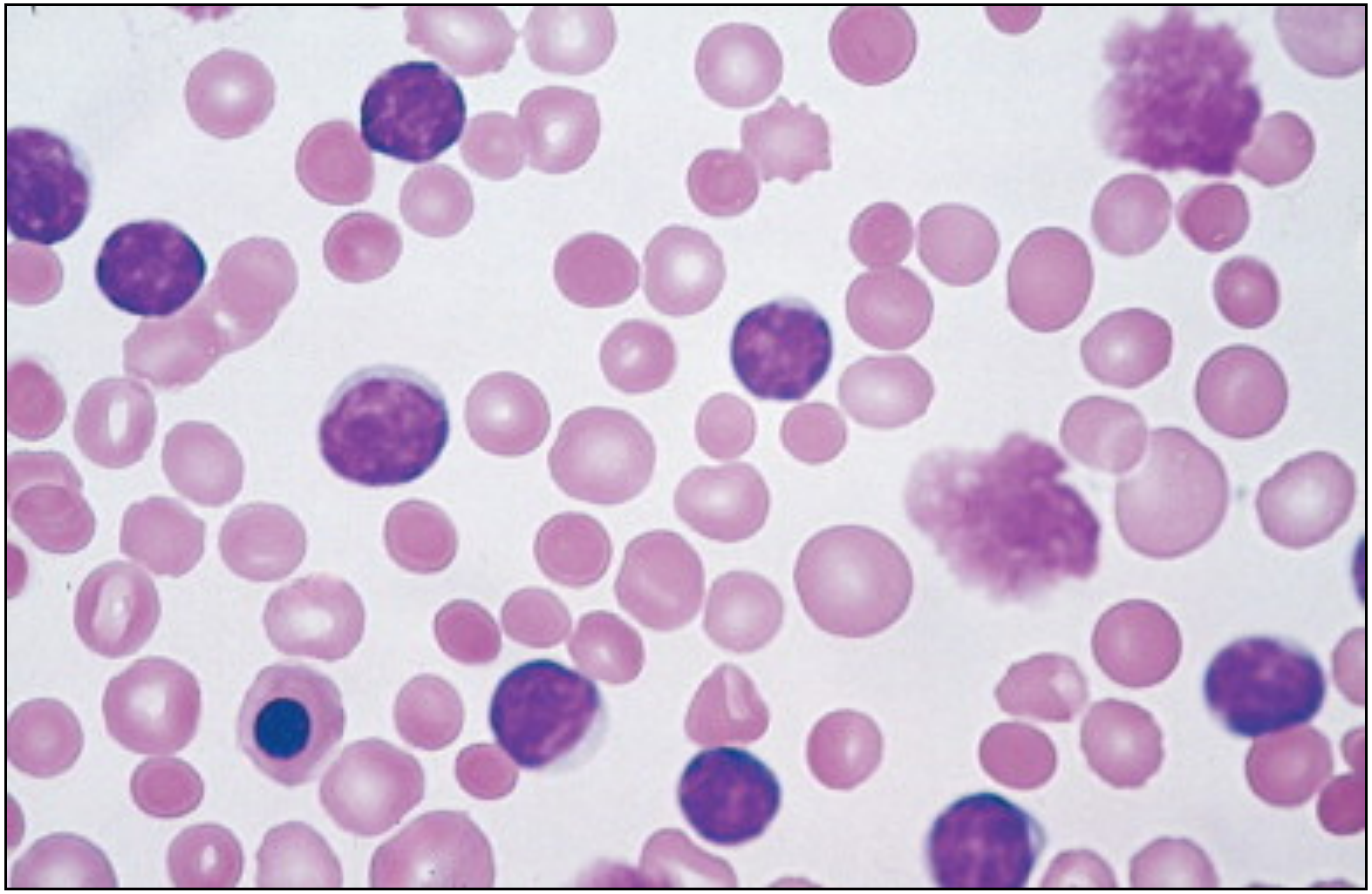

CASE-11

Young male with Hb of 4.0!

Case-11

- A 26-year old man is evaluated because of two weeks history of:
  - Progressive fatigue
  - Dyspnea on exertion .
  - Vague non exertional chest discomfort
  - Mild cough
- He takes no medications.
- He works as a carpenter and exercises regularly but has been unable to jog in recent weeks because of marked fatigue.
- Physical examination is normal except for pallor.

Case-11

Laboratory studies:

- Hemoglobin 4.8g/dL
- Hematocrit 13%
- Leukocyte count 8300/uL; normal differential
- Reticulocyte count 0
- Platelet count 320.000/uL
- Routine biochemical profile Normal
- Serum total bilirubin Normal
- Liver enzyme studies Normal

Case-11

- A chest radiograph is shown
- CT of the chest confirms a 4 x 5-cm anterior mediastinal mass.

- Bone marrow biopsy showed:
  - Absent erythrocyte precursors
  - Normal megakaryocytes
  - Normal leukocyte numbers and maturation

CXR

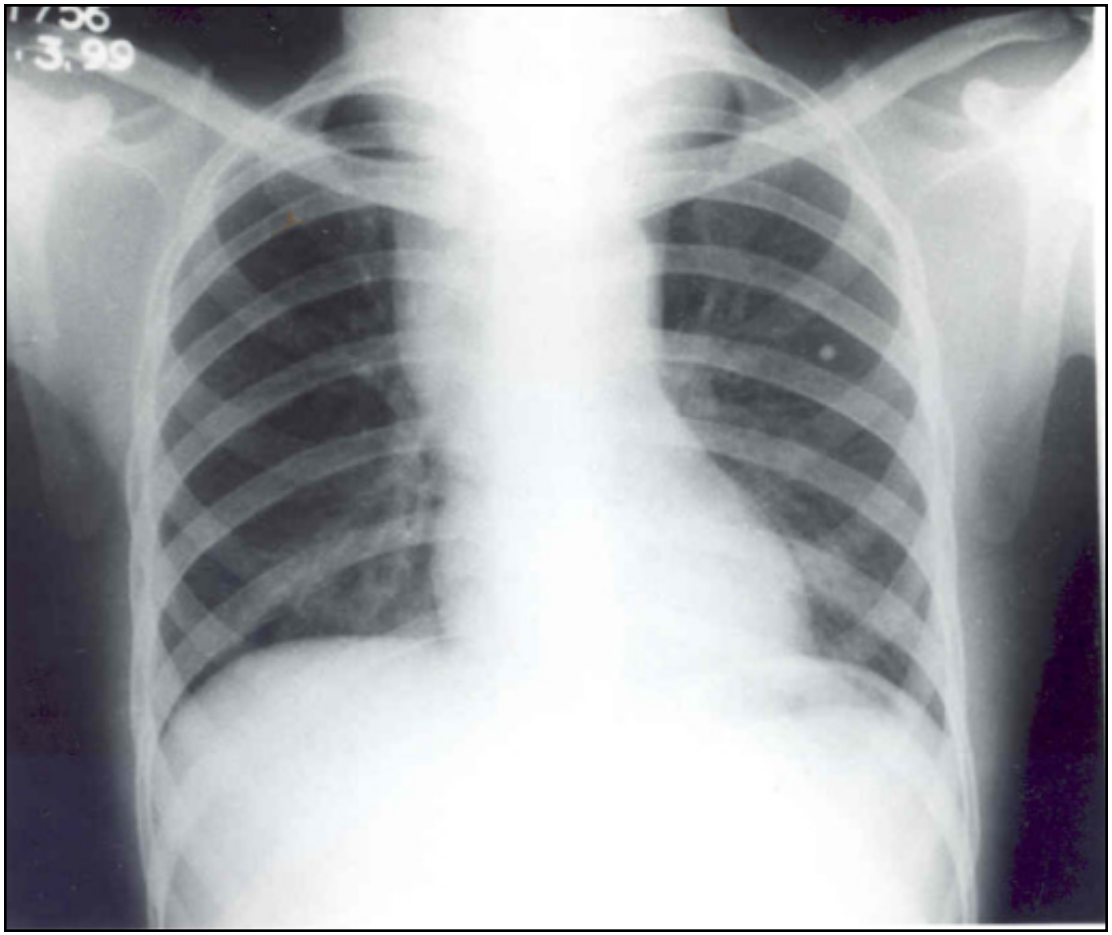

Case-11

- Which of the following is the most likely cause of the mediastinal mass?

a. Hodgkin's disease
b. Non-Hodgkin's lymphoma
c. Thyroid carcinoma
d. Thymoma
e. Germ cell carcinoma

Case-12

- A 33-year-old woman has experienced low grade fevers, night sweats, and generalized malaise for the past 2 months.
- On physical examination she has non-tender cervical and supraclavicular lymphadenopathy.
- A cervical lymph node biopsy is performed.

Case-12

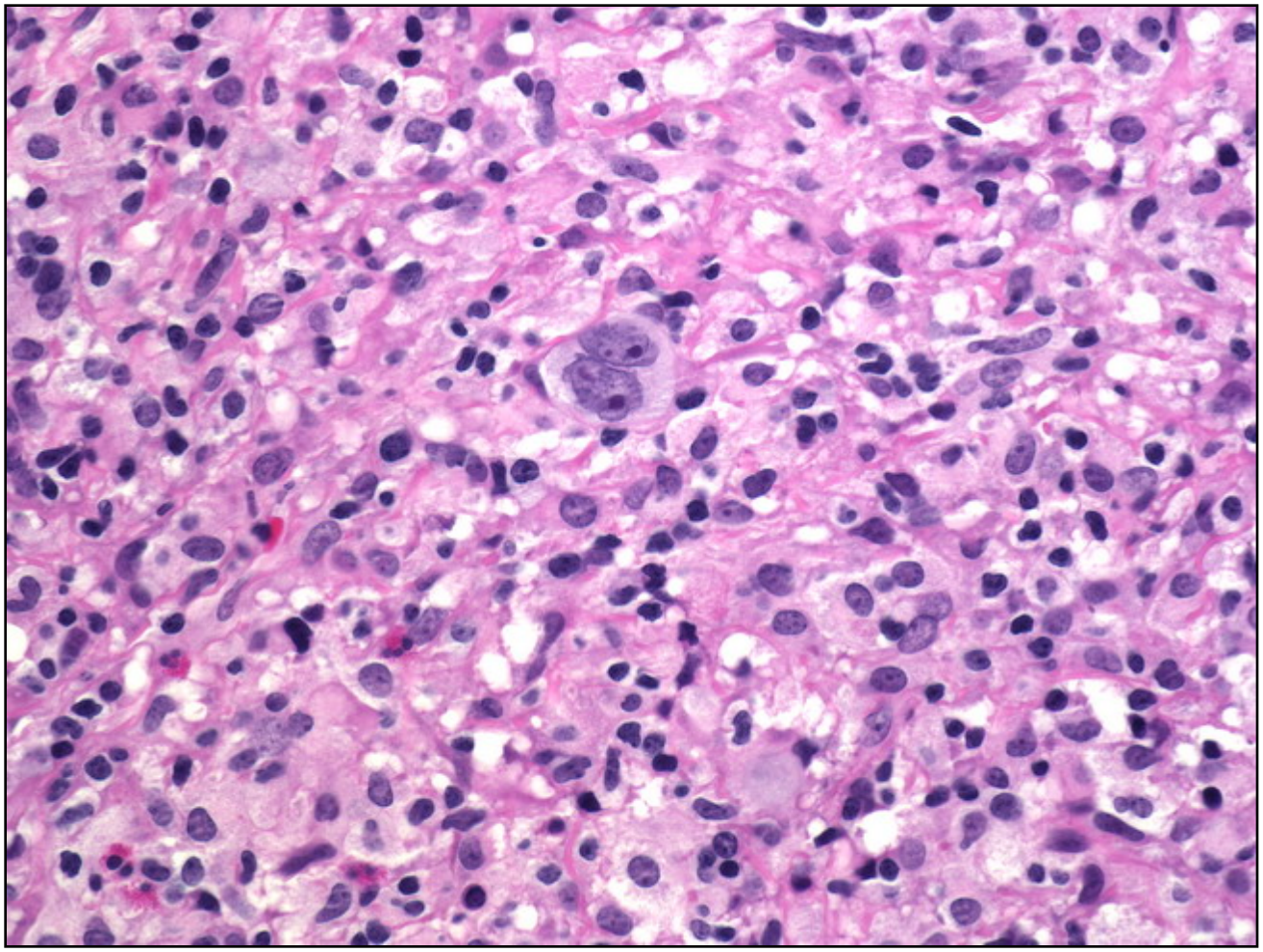

Case-12

Which of the following is the most likely diagnosis?

a. Burkitt lymphoma
b. Hodgkin lymphoma
c. Cat scratch disease
d. Mycosis fungoides
e. Multiple myeloma

Case-12

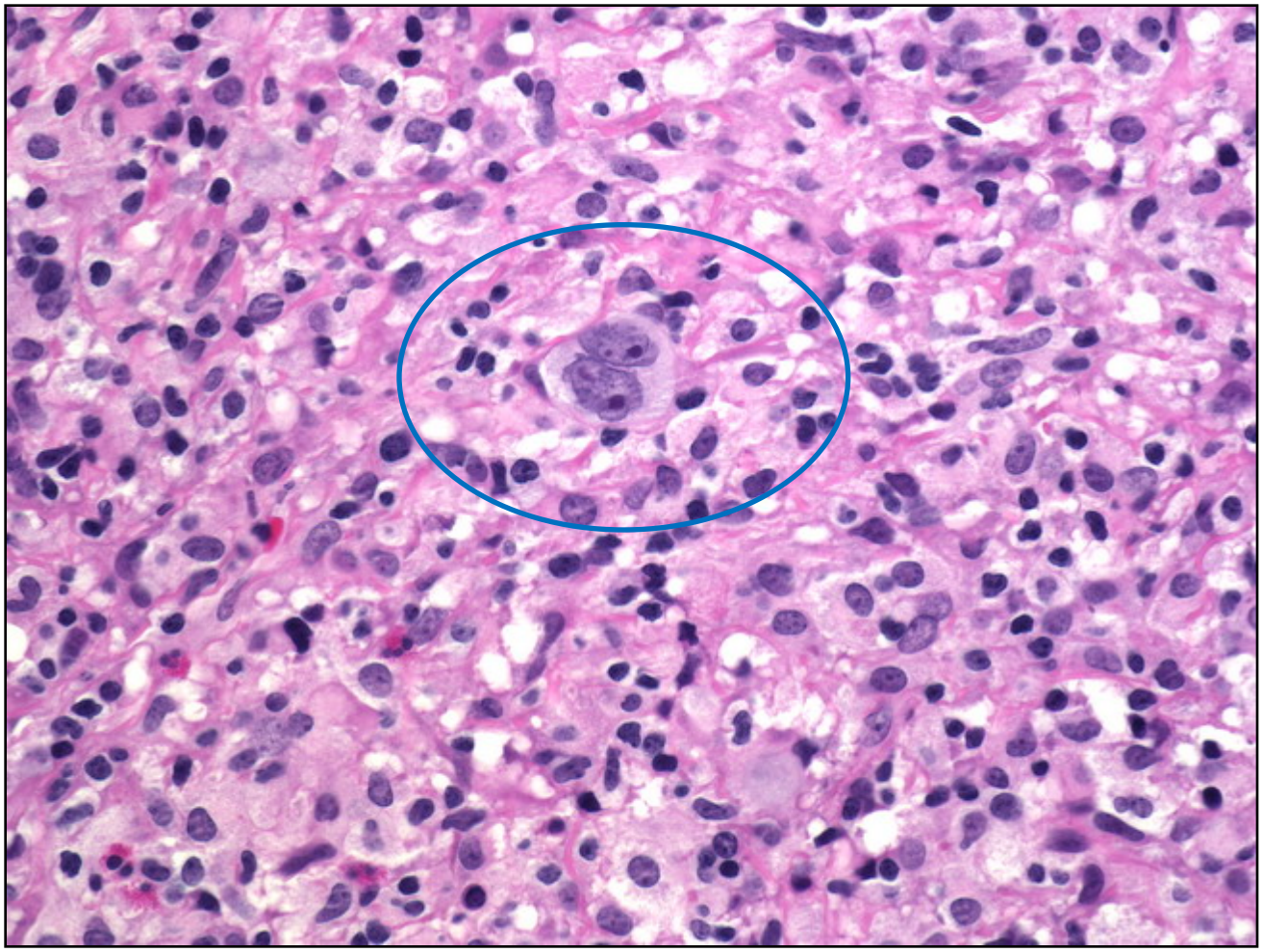

CASE-13

Young kid with bleeding

Case-13

- 8 year old boy presented with unexplained large bruises over skin.

- Physical examination showed no sings of anemia.

Case-13

- Hb: 14
- WBC: 7.2
- Platelets: 50
- PT, PTT: normal
- Bleeding time: 19 min (3-10)
- Blood film

Blood Film

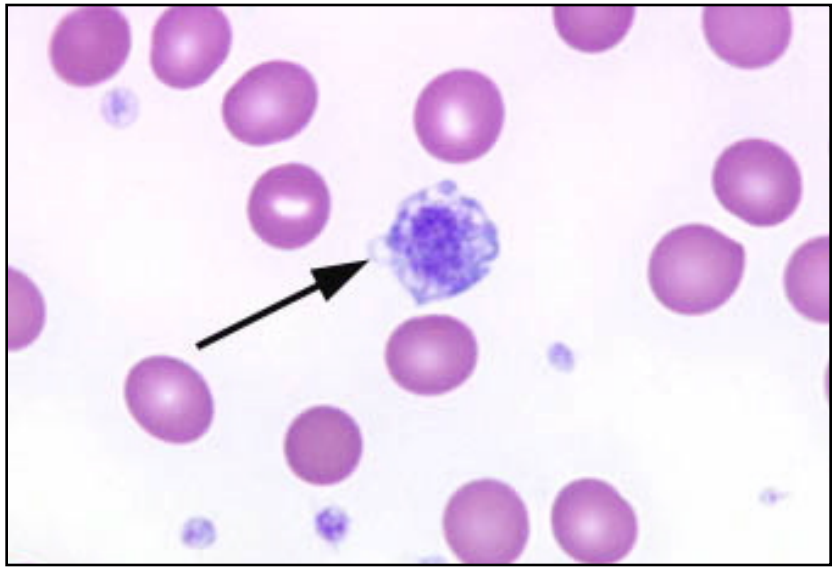

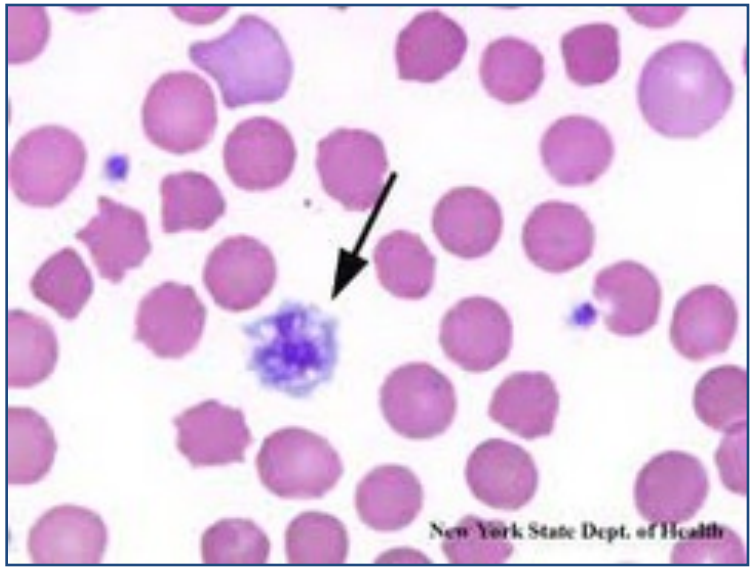

CASE-14

Rt. leg swelling

Case-14

- 69 year old female who had Rt. Hip replacement 10 days ago.
- Presented with Rt. leg redness, hotness and tenderness.
- Doppler ultrasound confirmed a diagnosis of DVT

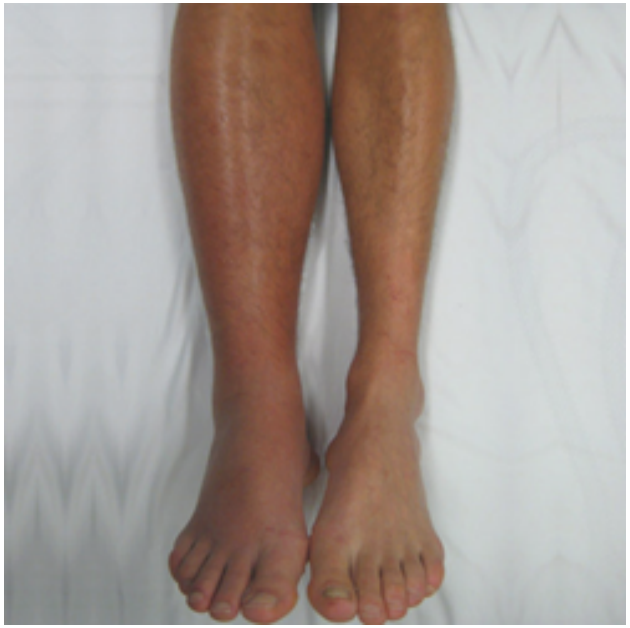

Doppler Ultrasound

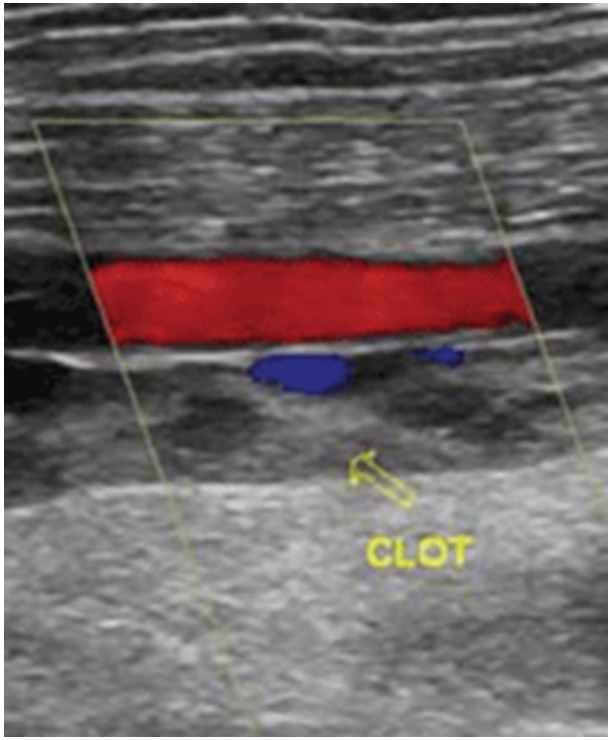

Doppler Ultrasound

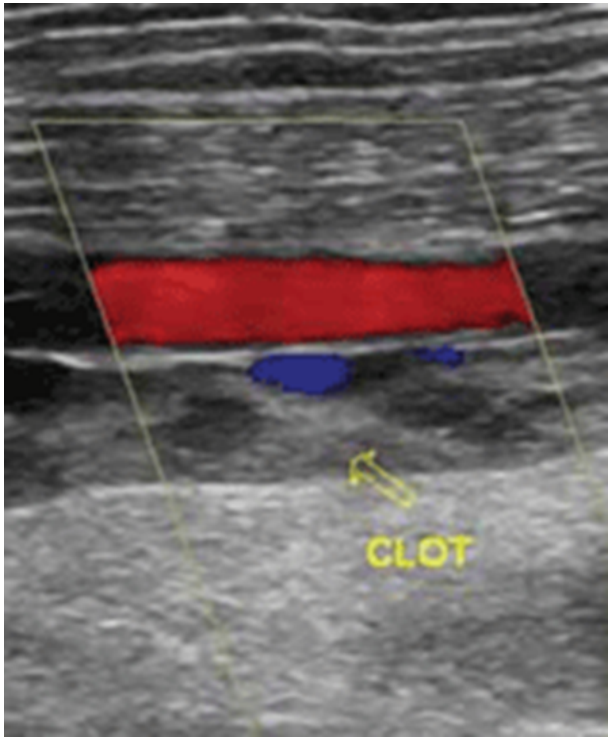

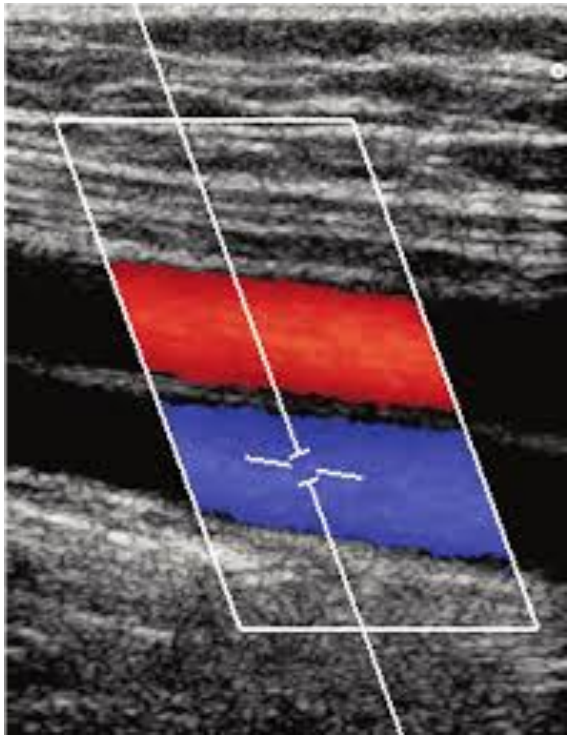

Case-14

What is the best treatment option?

a. Enoxaparin
b. Rivaroxaban
c. Warfarin
d. Dabigatran
e. Fondaparinux

CASE-15

Lymphoma on Chemotherapy with hyperkalemia

Case-15

- 77 year old male patient with history of CAD was recently diagnosed with diffuse large cell lymphoma with bulky lymphadenopathy.

- Three days after starting chemotherapy he was seen in ER with severe fatigue, nausea, mild abdominal discomfort.

Case-15

- His initial lab work up showed:
  - Potassium 5.3 meq/L
  - Calcium 8.1 mg/dl
  - Phosphate 5.5 mg/dl
  - LDH 28,900 U/L
  - Uric acid 14.3 mg/dl
  - Creatinine 1.1 mg/dL

Case-15

Which of the following is helpful to avoid this problem:

a. IV Hydration

b. Allopurinol

c. Rasburicase

d. All of the above

Thank You

Hikmat Abdel-Razeq, MD.