Pathology of The Gastrointestinal Tract

(Edited Slides)

Introduction

- The GI tract is divided into segments
- Each segment has its own diseases
- In each of the diseases discussed, we are concerned with:
  - Definition of the disease
  - Pathogenesis
  - Clinical presentation
  - Radiology or lab test findings

Pathology of The Esophagus

- Before discussing esophageal diseases, it's important to mention 4 main clinical manifestations that might be seen in esophageal diseases:

  - Dysphagia (difficulty in swallowing)
  - Heartburn (restrosternal burning pain)
  - Hematemesis (vomiting of blood)
  - Melena (blood in stool)

Dysphagia

(difficulty in swallowing), which is attributed either to

- deranged esophageal motor function

  or to

- narrowing or obstruction of the lumen which is common to occur at the distal end of the esophagus near the gastro-esophageal junction.

Heartburn

(retrosternal burning pain) usually reflects regurgitation of gastric contents into the lower esophagus.

Note: the lining of the esophagus is different from that of the stomach. When the esophageal mucosa is exposed to gastric acid, it will cause this burning pain.

Hematemesis

(vomiting of blood)

It's a serious sign that reflects **mucosal damage.**

and it's usually the result of a serious disease.

Melena

(blood in stool)

More characteristic of lower GI, but can occur and be related to the esophagus.

Hematemesis and Melena are evidence of severe inflammation, ulceration, or laceration of the esophageal mucosa.

Note: if blood in stool is coming from the esophagus or stomach, due to the long pathway, it will usually not be obvious and will only give the stool a dark color (we don't see fresh blood in stool if the esophagus is the source).

Pathologic conditions of the esophagus

- Achalasia
- Hiatal hernia
- Lacerations (Mallory-Weiss Syndrome)
- Esophageal Varices
- esophagitis
- Barret esophagus
- Esophageal carcinoma

1. Achalasia

- Achalasia means "failure to relax”

  referring to the lower esophageal muscles, due to abnormality of the muscles. In contrast, in the normal situation, upon swallowing, the lower esophageal sphincter muscles should relax in order for the gastro-esophageal junction to open and allow food passage into the stomach.

- It is incomplete relaxation of the lower esophageal sphincter in response to swallowing.

- This produces **functional obstruction** of the esophagus, with consequent dilation of the more proximal esophagus.

  Note: **functional** obstruction → that's why endoscopy would not reveal esophageal abnormalities.

- Manometric studies (studies to assess motor function of esophageal muscles) show 3 major abnormalities in achalasia:

1. Aperistalsis (absence of peristalsis, due to failure of relaxation in the wall of the esophagus)
2. Partial or incomplete relaxation of the lower esophageal sphincter with swallowing
3. Increased resting tone of the lower esophageal sphincter (resting tone → when there is no action)

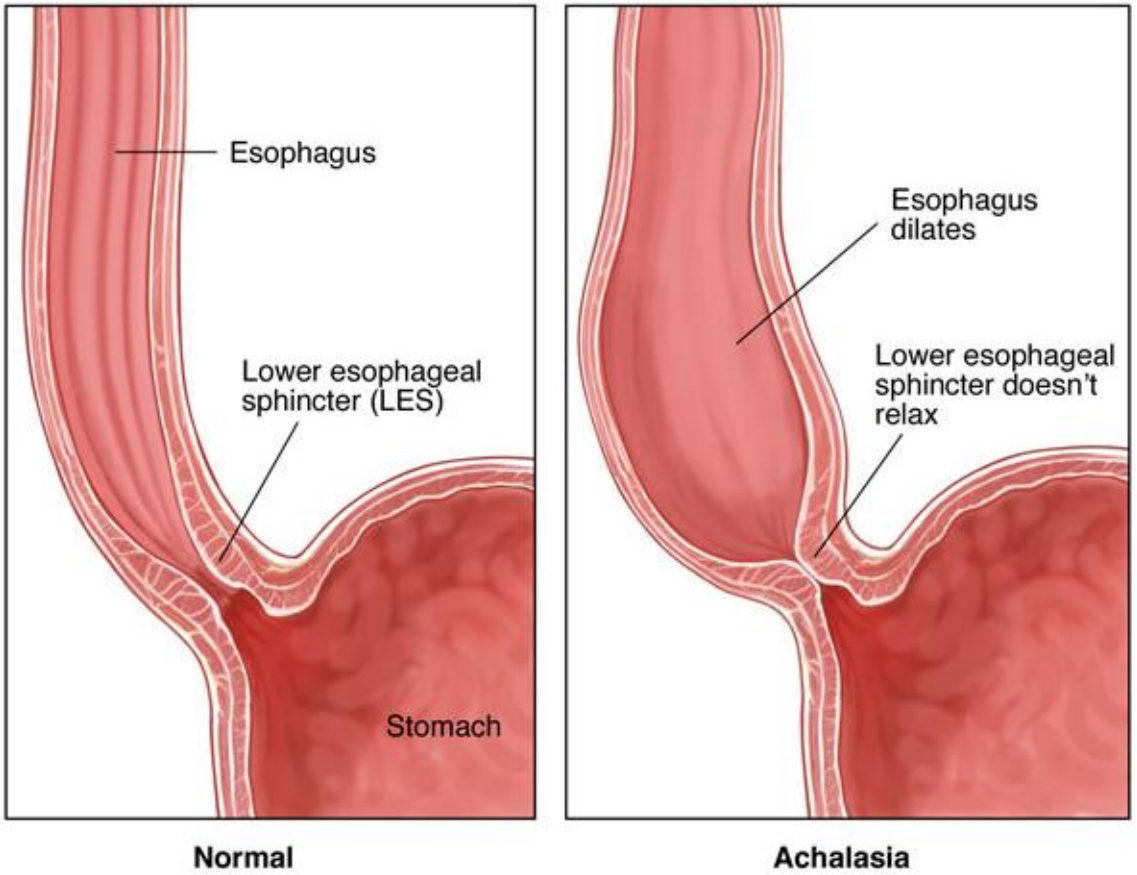

Esophageal Achalasia

Types of Achalasia

(primary and secondary)

(1) Primary achalasia

→ the problem originates from the muscle.

loss of intrinsic inhibitory innervation of the lower esophageal sphincter and smooth muscle segment of the esophageal body leads to loss of sphincteric action of lower esophagus and failure of relaxation.

- **Progressive dilation of the esophagus above the level of the lower esophageal sphincter.**

Note: in general, in the GI tract → proximal to any obstruction, the bowel will dilate because it will accumulate the content. Look at the figure in the previous slide.

- Primary achalasia is important because it's a chronic condition.
- The wall of the esophagus may be of normal thickness, thicker than normal because of hypertrophy of the muscularis or markedly thinned by dilation.
- Characteristic finding:

  The myenteric ganglia are usually absent from the body of the esophagus but may or may not be reduced in number in the region of the lower esophageal sphincter.
- Inflammation in the location of the esophageal myenteric plexus is pathognomonic of the disease..

  (sometimes, the disease is associated with inflammation when the process is chronic and associated with reflux, the mucosa of the esophagus will be damages and there will be inflammation)

(2) Secondary achalasia

→ also related to loss of innervation, but here, this loss is due to damage by a disease process.

arises from pathologic processes that impair esophageal function.

1. **Chagas disease** -common-, caused by ***Trypanosoma cruzi***, which causes destruction of the myenteric plexus of the esophagus, duodenum, colon, and ureter.
2. **Disorders of the dorsal motor nuclei** -rare- such as polio, and autonomic neuropathy in diabetes

Clinical manifestations
of primary achalasia

- **stasis of food** may produce mucosal inflammation and ulceration proximal to the lower esophageal sphincter.

  food will not pass to the stomach, it will accumulate in the esophagus leading to pressure on the mucosa and sometimes inflammation and ulcerations.

- **progressive dysphagia** and inability to completely convey food to the stomach.
- nocturnal **regurgitation and aspiration** of undigested food. **Aspiration of undigested food can sometimes cause pneumonia.**

- It (primary achalasia) usually becomes manifest in young adulthood, but it may appear in infancy or childhood.
- **The most serious outcome is esophageal squamous cell carcinoma** in about 5% of patients and typically at an earlier age than in those without achalasia.

  (Achalasia is one of the risk factors for esophageal squamous cell carcinoma)

Clinical case #1...(Achalasia)

- A 40 yr old man complains of difficulty of swallowing & a tendency to regurgitate his food.

it's obvious that the problem involves the proximal parts of the GI tract... We think of the esophagus for example.

- Endoscopy reveals no esophageal or gastric abnormalities

Endoscopy is a very helpful procedure and is frequently done to look at lesions in the esophagus or other sites and look for abnormalities. We usually get biopsies by endoscopy. But here, we have to do something else since endoscopy showed that esophageal mucosa is normal.

(See the next step)

- Manometric studies show:

1. a complete absence of peristalsis of the esophagus
2. failure of the lower esophageal sphincter to relax upon swallowing
3. increased intraesophageal pressure

Manometric studies are concerned with muscle strength in the esophagus, particularly, to measure the tone of the muscles at the lower part of the esophagus. This procedure is not done frequently, but here it was the way of diagnosis because the previous three points indicate that the problem is related to the <u>function of the muscles</u> of the esophageal wall, particularly at the lower part.

- Your diagnosis is ? **Achalasia**

2. Hiatal Hernia

- separation of the diaphragmatic crura and widening of the space between the muscular crura and the esophageal wall permits a dilated segment of the stomach to protrude above the diaphragm.

Two anatomic patterns are recognized :

1-The axial, or sliding, hernia (95%) .

2-The nonaxial, or paraesophageal, hernia.

(1) Sliding Hernia

protrusion of the stomach above the diaphragm creates a bell-shaped dilation, bounded below by the diaphragmatic narrowing.

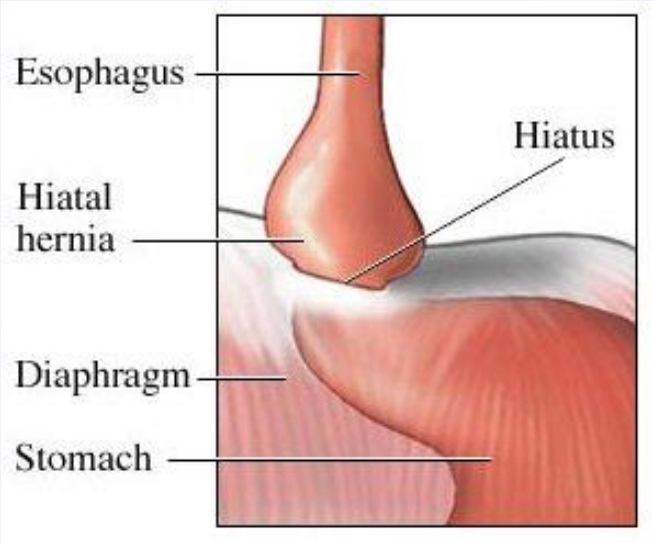

(2) Paraesophageal Hernia

a separate portion of the stomach, usually along the greater curvature, enters the thorax through the widened foramen.

(the herniated segment of the stomach is not related to the lower esophageal area, it's rather part of the wall which is next to the lower esophageal area. In these patients, the lower esophageal sphincter is still located below the diaphragm.)

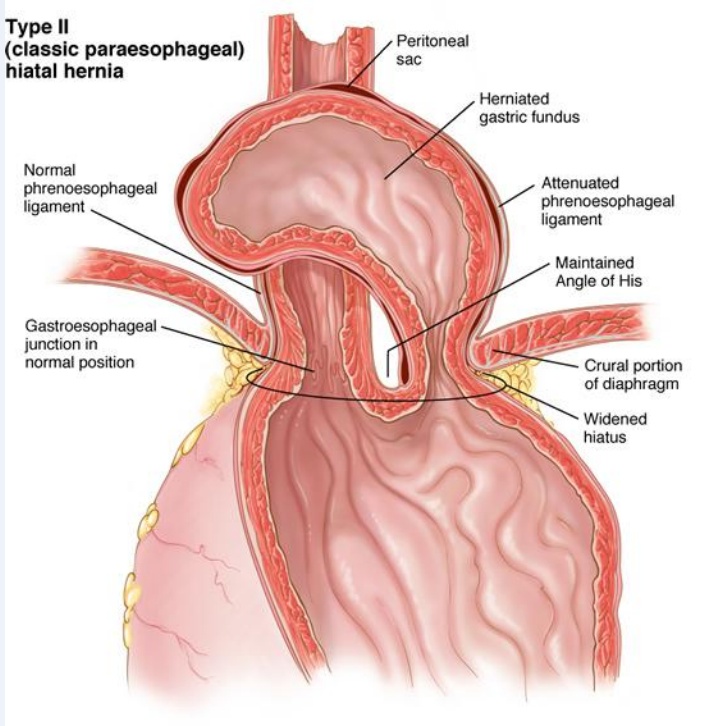

Achalasia vs. esophageal hernia

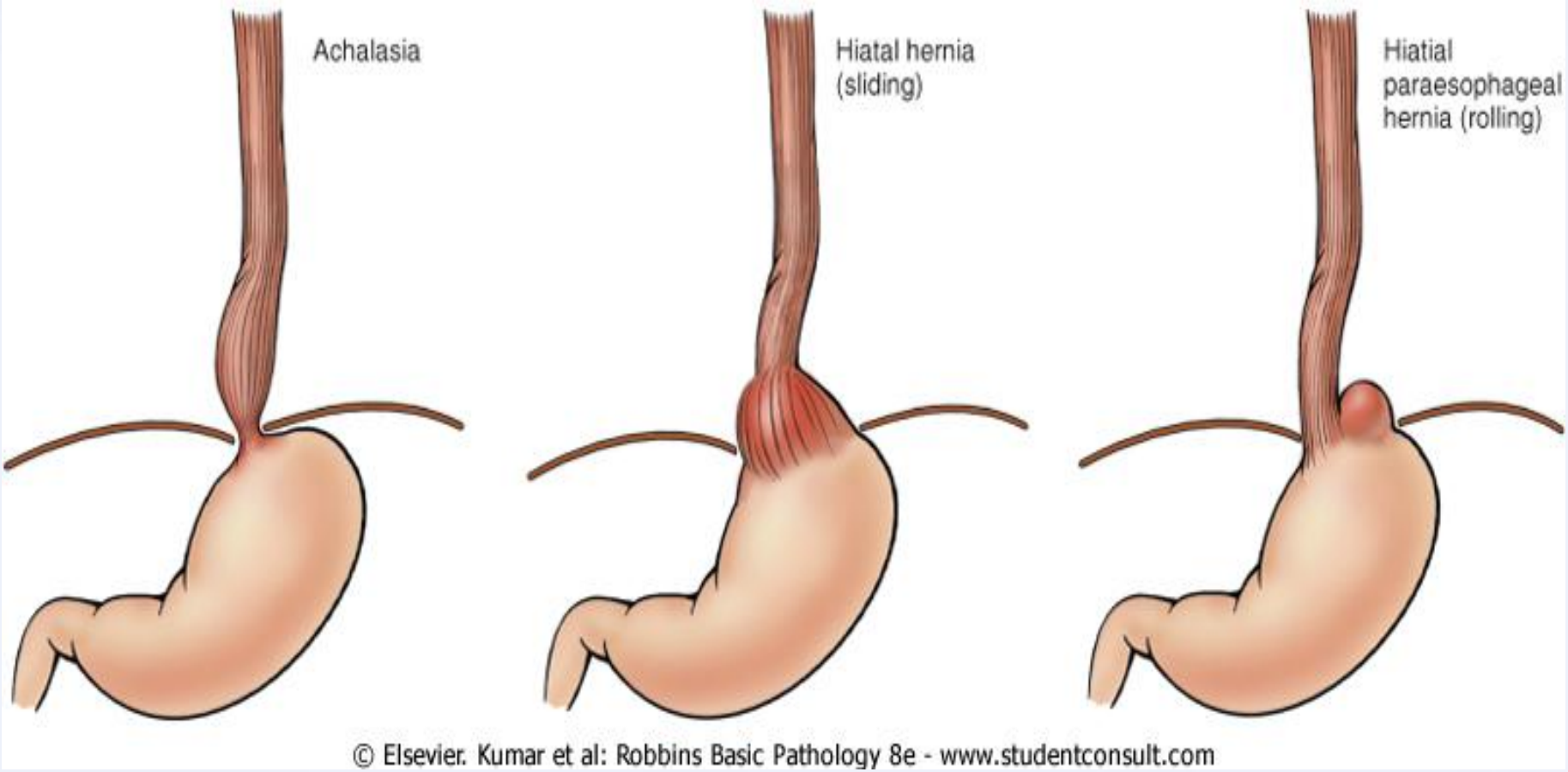

- The cause of this deranged anatomy whether congenital or acquired is unknown.
- Hiatal hernias are reported in 1-20% of adult subjects -they are common-, **increasing in incidence with age.**
- ~ 9% of these adults suffer from heartburn or regurgitation of gastric juices into the mouth. some patients may have hiatal hernia without having any symptoms.
- symptoms more likely result from incompetence of the lower esophageal sphincter than from the hiatal hernia per se
- symptoms accentuated by positions favoring reflux (bending forward, lying supine) and obesity. The patient must be told to avoid such positions.

Complications

(these do not occur in all patients)

1. **Reflux esophagitis.**
   individuals with severe reflux esophagitis are likely to have a <u>sliding hiatal hernia</u> although most individuals with sliding hiatal hernias do not have reflux esophagitis.
2. **Mucosal ulceration ...acid can cause damage to the lining of the esophagus→ chronic regurgitation is associated with inflammation and ulceration.**
3. **Bleeding... Due to ulcer**

4. **Perforation...** Leakage of gastric acid and content into the mediastinum due to thinning of the wall because of inflammation, and this may lead to mediastinitis (a serious problem).

5. **Paraesophageal hernias can become strangulated or obstructed.**

   Obstruction of paraesopheal hernias can be complicated by inflammation and ulceration.

   Because paraesophageal hernias represent herniation of the bowel wall into the area above the diaphragm through a space which is not so wide, this might cause the regurgitated part to be filled with secretions leading to an increase in its size

   →ischemia due to pressure on vessels supplying the wall

   →strangulation

Clinical case #2...(Hiatal Hernia)

- A 47 yr old obese man complains of long-standing heart burn and dyspepsia.
- A chest x-ray shows a retrocardiac gas-filled structure.

(gas in the thorax...???)

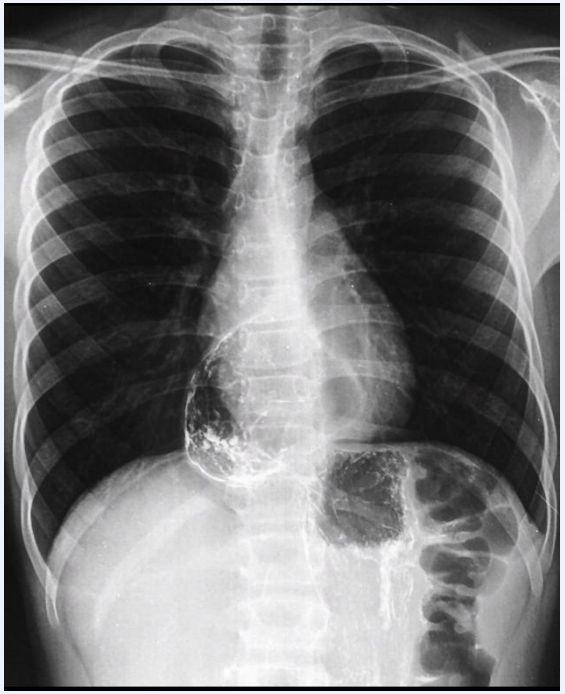

Stomach has air in the fundus.

In normal situations, the stomach and the lower part of the esophagus are located under the diaphragm, but sometimes, the proximal part of the stomach can ascend and become above the diaphragm and this explains the previous X-Ray finding.

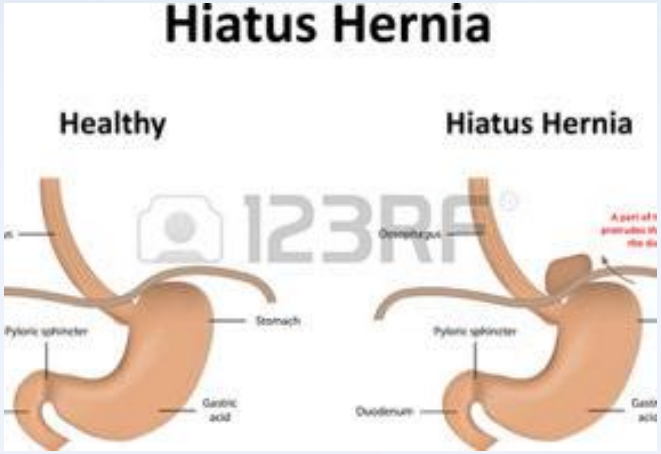

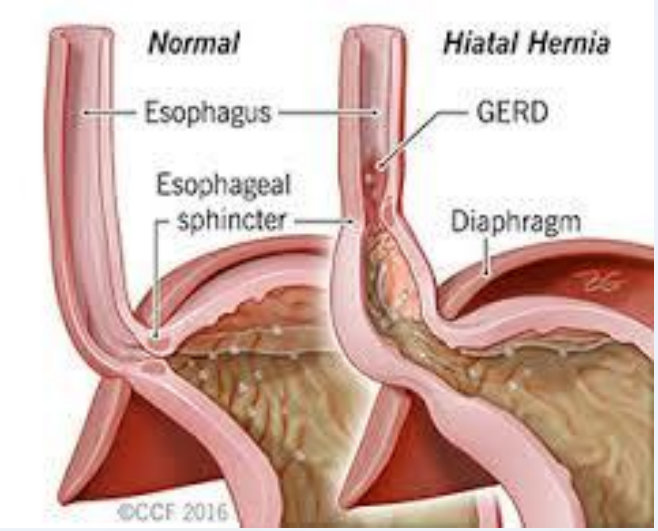

YOUR DIAGNOSIS IS..??

Hiatal Hernia

3. Lacerations (Mallory- Weiss Syndrome)

- Longitudinal tears in the esophagus at the gastroesophageal junction.
- Note:

  Laceration : shallow

  Ulceration : deep
- They are shallow but can produce symptoms because they reflect the damage of the mucosa.

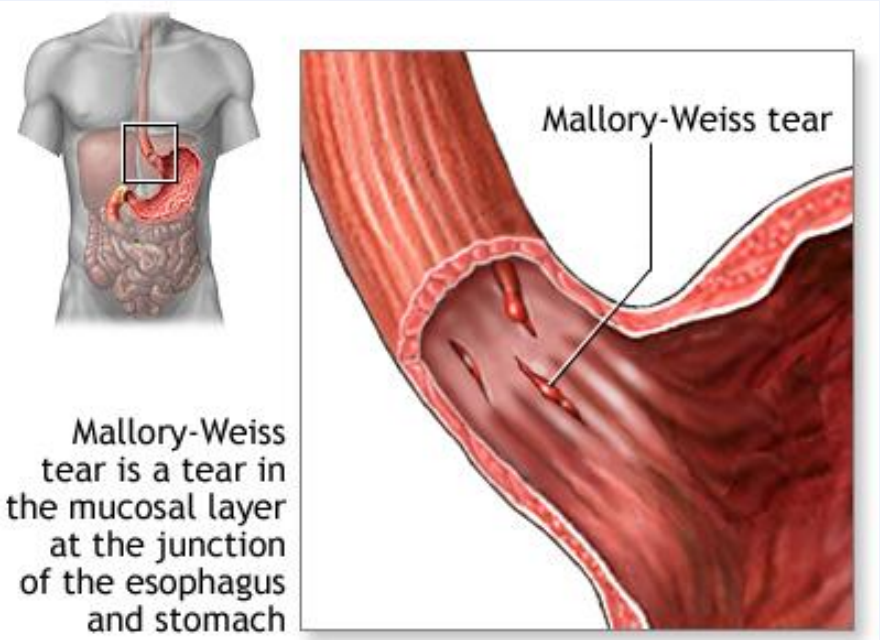

- **They are seen in :**

1. **chronic alcoholics after a bout of severe retching or <u>vomiting.</u>**
2. **during acute illnesses with severe <u>vomiting</u>.**

Clinical Manifestation

- 5-10% of **upper GI bleeding** episodes.
- Most often bleeding is not profuse and ceases without surgical intervention, but life-threatening hematemesis may occur.
- If the underlying cause is treated, Healing is usually prompt with minimal to no residual problems.

Esophageal mucosa can regenerate usually with complete healing because lacerations are usually superficial.

Pathogenesis

- **Inadequate relaxation of the musculature of the lower esophageal sphincter during vomiting with stretching and tearing of the gastro-esophageal junction at the moment of propulsive expulsion of gastric contents.**

- a hiatal hernia is found in more than 75% of patients with Mallory-Weiss tears.
- normal variability in intra-abdominal pressure can be transduced through a hiatal hernia occasionally leading to a Mallory-Weiss tear.

- Almost half of individuals presenting with upper GI bleeding attributable to a Mallory-Weiss tear have no antecedent history of nausea, retching, abdominal pain, or vomiting, meaning that it can occur suddenly and acutely for the first time.

Complications

1. Tears may involve only the mucosa or <u>may penetrate the wall</u>.
2. <u>Infection</u> of the defect may lead to an inflammatory ulcer or to mediastinitis.

4. Esophageal Varices

- Varices = dilated tortuous vessels
- Esophagus is one of the few potential sites for communication between the intra-abdominal portal circulation and the systemic venous circulation
- When portal venous blood flow into the liver is impeded by cirrhosis or other causes, the resultant portal hypertension induces the formation of collateral bypass channels wherever the portal and systemic systems communicate.

- Portal blood flow is diverted through the stomach veins into the plexus of esophageal subepithelial and submucosal veins then into the azygos veins and the superior vena cava.
- The increased pressure in the esophageal plexus produces dilated tortuous vessels called varices.

- **Varices are present in approximately 2/3 of all cirrhotic patients.**

Extra images

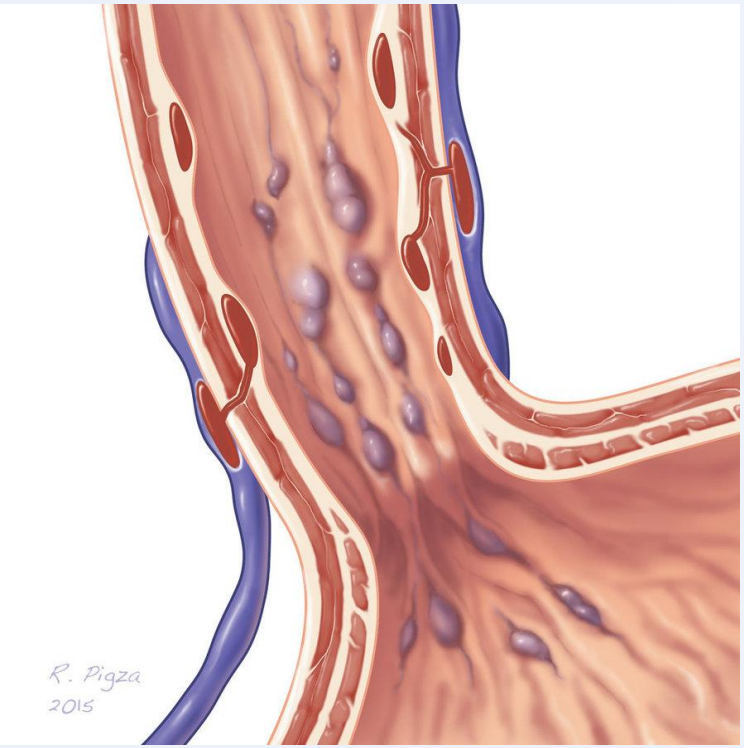

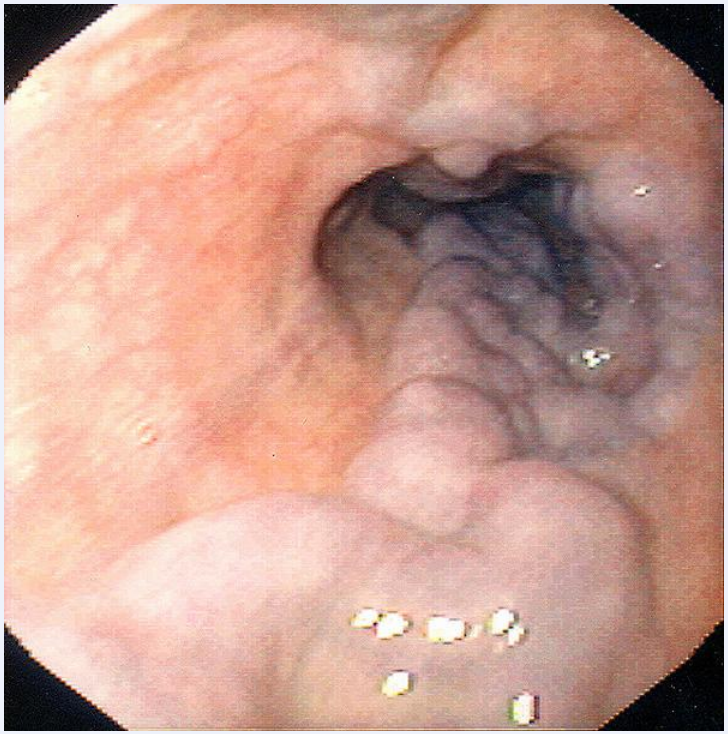

- **<u>Variceal rupture produces:</u>**

1. massive **hemorrhage** into the lumen
2. **suffusion of blood** into the esophageal wall.

If there's upper GI bleeding, think of esophageal varices and cirrhosis.

- **The conditions leading to initial rupture of a varix are unclear:**

1. **Silent erosion of overlying thinned mucosa**
2. **Increased tension in progressively dilated veins**
3. **Vomiting with increased intra-abdominal pressure are likely to be involved.**

- 50% of those affected are found to have coexistent **hepatocellular carcinoma**.

  Development of HCC on top of cirrhosis aggravates the complications.

- In only 50% of cases variceal hemorrhage subsides spontaneously.
- 20-30% of patients die during the first episode of bleeding.
- In 70% of those who survive the first episode, rebleeding occurs within 1 year, with a similar rate of mortality for each episode. That's why we have to keep eye on these patients.

5. Esophagitis

The inflammation may have many origins:

1. **reflux of gastric contents (reflux esophagitis).**
2. **prolonged gastric intubation** (in ICU, major surgeries.., the tube can cause pressure and friction with esophageal mucosa)
3. **Uremia** (increase in the uric acid concentration and other toxic substances in blood)
4. **ingestion of corrosive or irritant substances ..**like strong acids or alkaline
5. **radiation**
6. **chemotherapy**

Reflux Esophagitis

- Contributing factors :

1. Decreased efficacy of esophageal antireflux mechanisms.
2. Inadequate or slowed esophageal clearance of refluxed material
3. Impaired reparative capacity of the esophageal mucosa by prolonged exposure to gastric juices

---

4. **C**NS depressants
5. **A**lcohol
6. **T**obacco

---

7. The presence of a sliding hiatal hernia
8. Increased gastric volume contributing to the volume of refluxed material

Incidence

- In northern Iran the prevalence of esophagitis is more than 80%
- It is also extremely high in regions of China.
- Gastroesophageal reflux disease affects

  ~ 0.5% of the US adult population.
- Affects adults >age 40 and occasionally infants and children.

Clinical Features

- **Heartburn, the dominant symptom.**
- **Regurgitation of a sour brash.**
- **Attacks of severe chest pain mimicking a heart attack.**

- **The severity of symptoms is not closely related to the presence and degree of anatomic esophagitis.**
  Sometimes, severe manifestations can result from mild reflux and vice versa.
  → severity of symptoms and degree of esophagitis are not closely related.

Complications of reflux esophagitis

- **1- Bleeding**
- **2- Stricture formation**
- **3- Barrett esophagus with its predisposition to malignancy.**

Remember:
Till now, bleeding can be a complication of :
Hiatal hernia,
Esophageal varices, and
Reflux esophagitis.

Reflux esophagitis

Numerous Eosinophils (***arrows***) **are present within the mucosa, and the stratified squamous epithelium has not undergone complete maturation because of ongoing inflammatory damage.**

Eosinophils are small cells with eosinophilic granules filling the cytoplasm.

The number of eosinophils correlates with the degree of esophagitis.

6. Barrett Esophagus

- Replacement of the normal distal stratified squamous mucosa by **metaplastic columnar epithelium containing goblet cells.**
- **It is a complication of long-standing gastro-esophageal reflux.**
- Occurs in 5-15% of persons with persistent symptomatic reflux disease & in about the same proportions in asymptomatic populations.

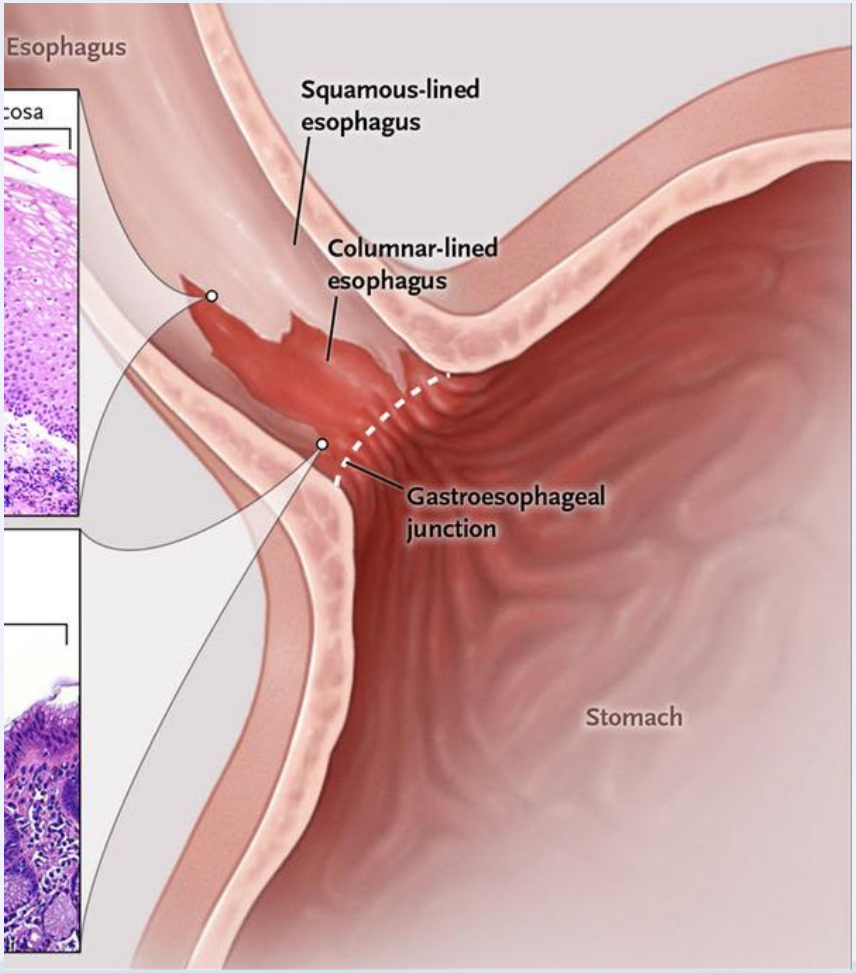

- It is unclear why individuals with few symptoms and little inflammation develop Barrett esophagus, and, conversely, why others have erosive esophagitis without Barrett esophagus.

(development of Barrett Esophagus is not related to the degree of reflux)

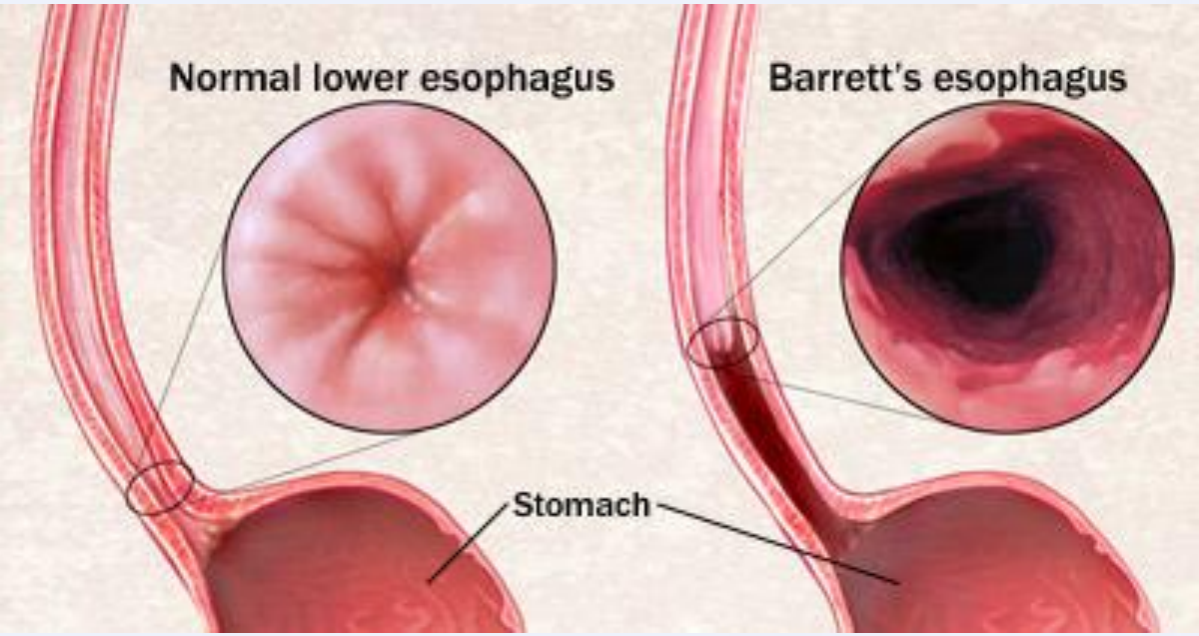

- More common in males, M:F ratio 4:1
- Common in whites more than in other races.

Pathogenesis

- Prolonged and recurrent gastroesophageal reflux is thought to produce inflammation and eventually ulceration of the squamous epithelial lining.
- Healing occurs by ingrowth of progenitor cells and re-epithelialization.

← pathogenesis, cont.

- In the microenvironment of an abnormally low pH in the distal esophagus caused by acid reflux, the cells differentiate into columnar epithelium.
- **Metaplastic columnar epithelium is thought to be more resistant to injury from refluxing gastric contents.** **This is why the progenitor cells of the mucosa change their differentiation pattern and this is why Gasreo-Esiphageal Reflux Disease (GERD) is a predisposing factor to Barrett esophagus.**
- The metaplastic epithelium is not a typical intestinal epithelium as absorptive enterocytes.

Complications

(USA: Ulcer, Stricture, Adenocarcinoma)

1. **Ulcer**
2. **Stricture**
3. **Development of Adenocarcinoma. (this point is very important)**

- Persons with Barrett esophagus have a 30-100X greater risk of developing esophageal adenocarcinoma than do normal populations, the greatest risk being associated with high-grade dysplasia. **We should follow up these patients by endoscopy to monitor dysplasia, because a higher grade of dysplasia means a higher chance of developing malignancy.**

Important:

Achalasia is a risk factor for →

Esophageal sqaumous cell carcinoma.

Barrett esophagus is a risk factor for →

Esophageal Adenocarcinoma.

A-normal gastro-esophageal junction
B-the granular zone of Barrett esophagus (*arrow*)

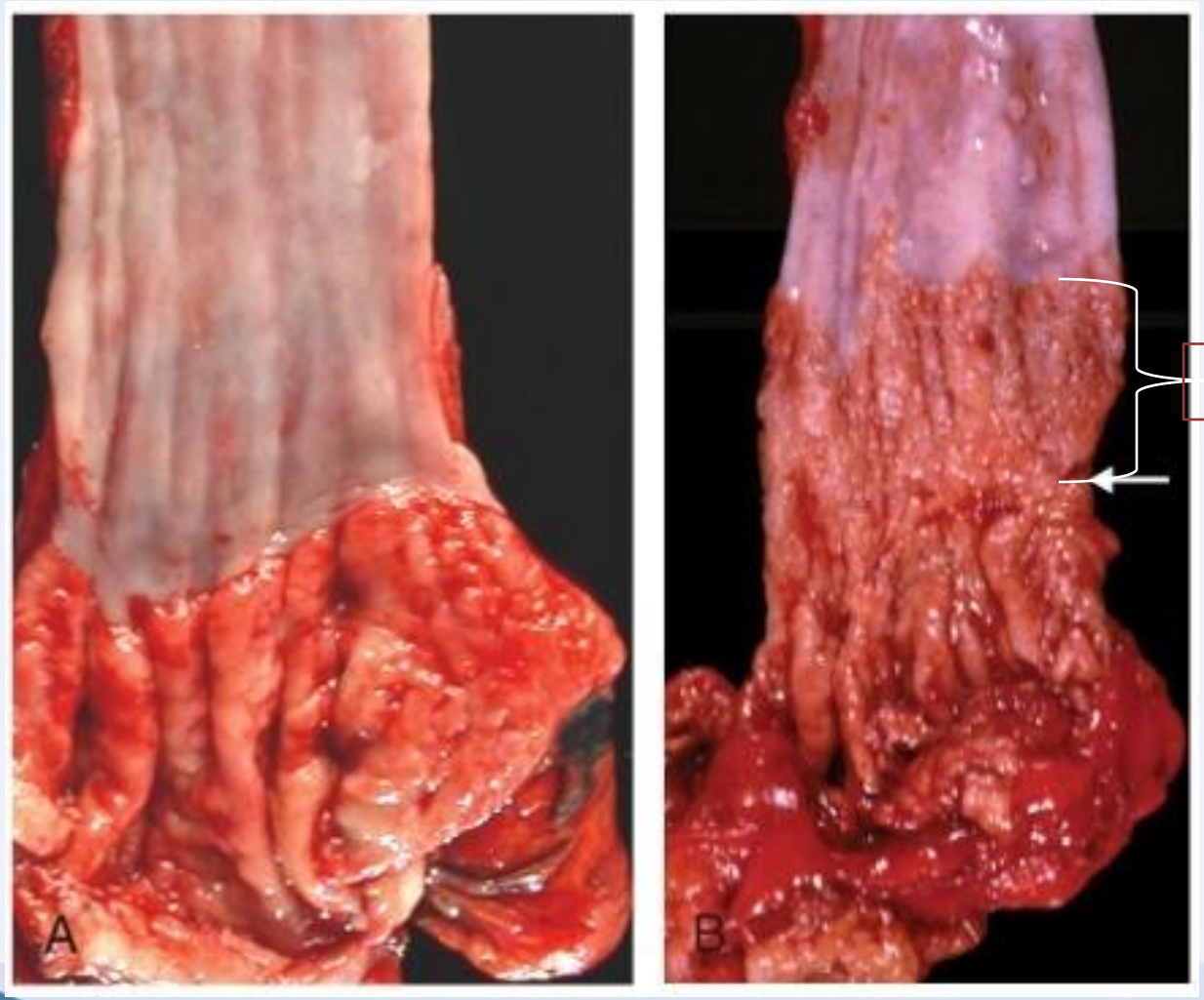

metaplasia

Barrett esophagus

Endoscopic view showing red velvety gastrointestinal-type mucosa extending from the gastro-esophageal orifice.

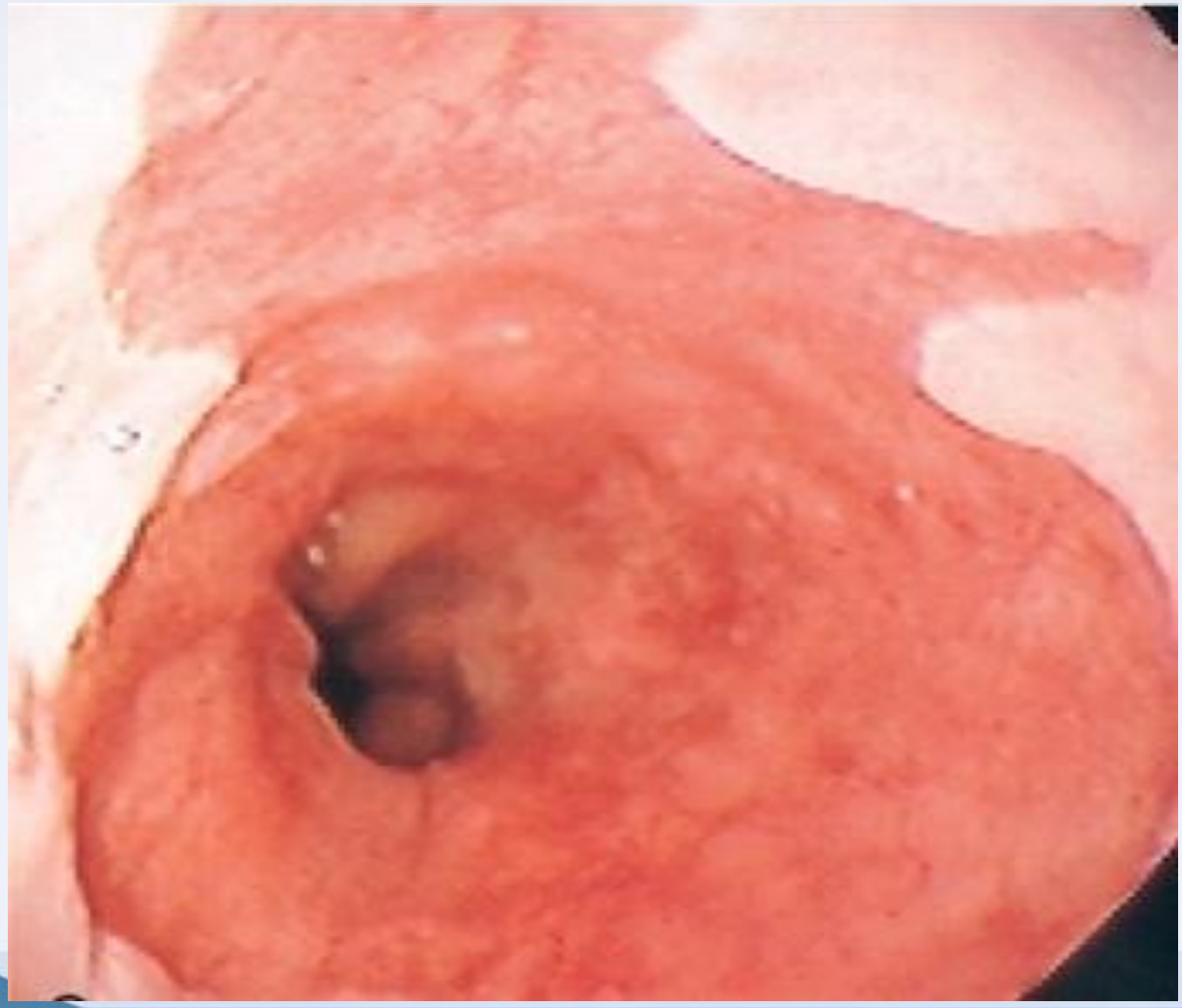

Note: the metaplasia can either be of intestinal type or of gastric type, because both can resist acidity.

Barrett esophagus

squamous mucosa (*left*) and intestinal-type columnar epithelial cells in glandular mucosa (*right*).

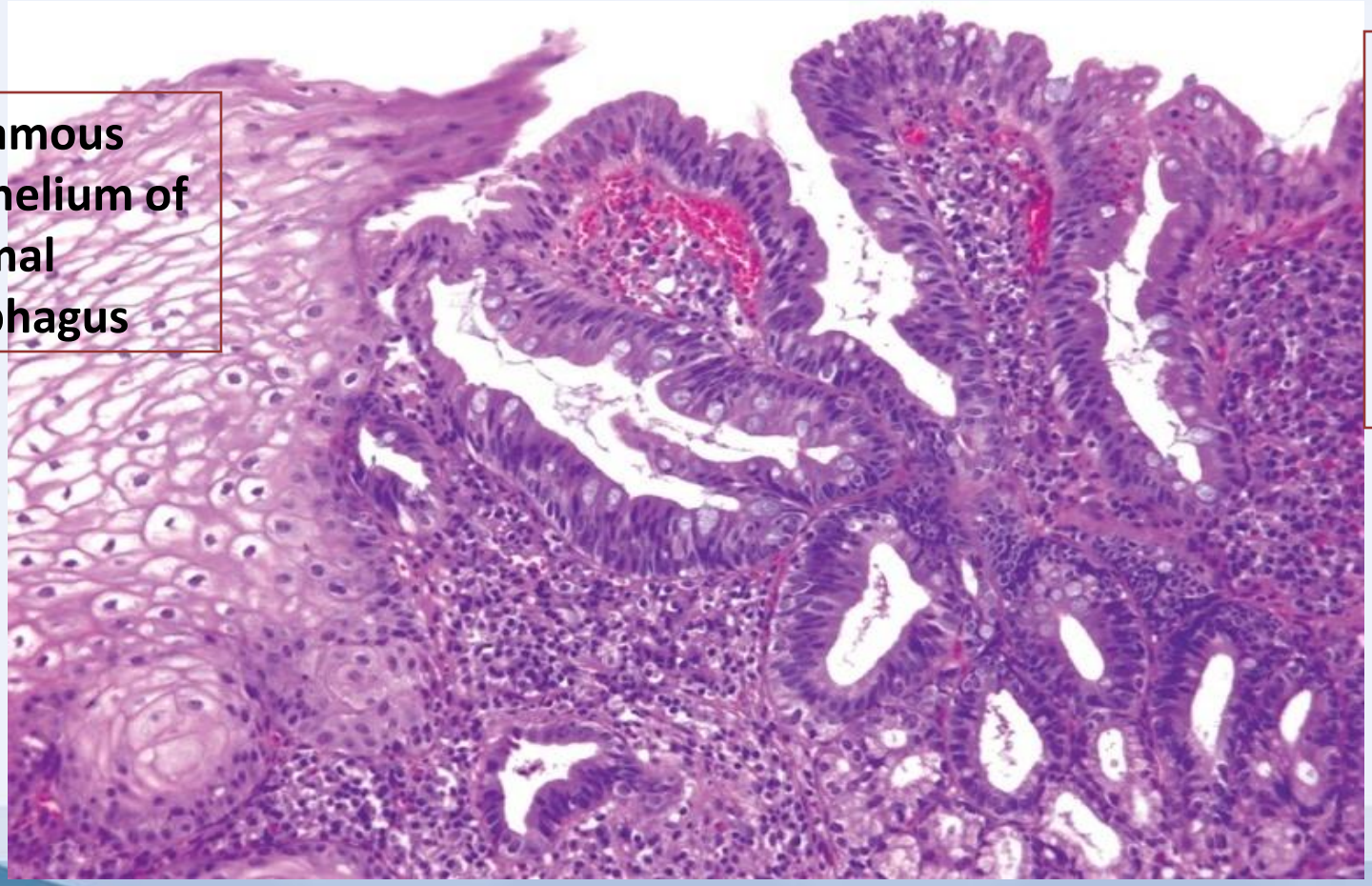

Squamous epithelium of normal esophagus

Mucosa similar to gastric mucosa and there are goblet cells

Clinical case #3...(Barrett Esophagus)

- A 55 yr old man with long history of indigestion & heartburn after meals, and upper abdominal pain.
- He was treated for GERD (gastro-Esophageal Reflux Disease) 3 yrs ago.
- **Endoscopy of the esophagus shows red gastrointestinal-type mucosa extending from the gastro-esophageal orifice.**

In normal situations:

- the mucosa of the esophagus is; pale (light pink to white), with homogenous color, and with no masses. *See the figure to the right*
- The mucosa of the esophagus is pale –because it's thicker (stratified squamous)-, while the gastric mucosa is darker (more pinkish or reddish in color) because it's thinner.

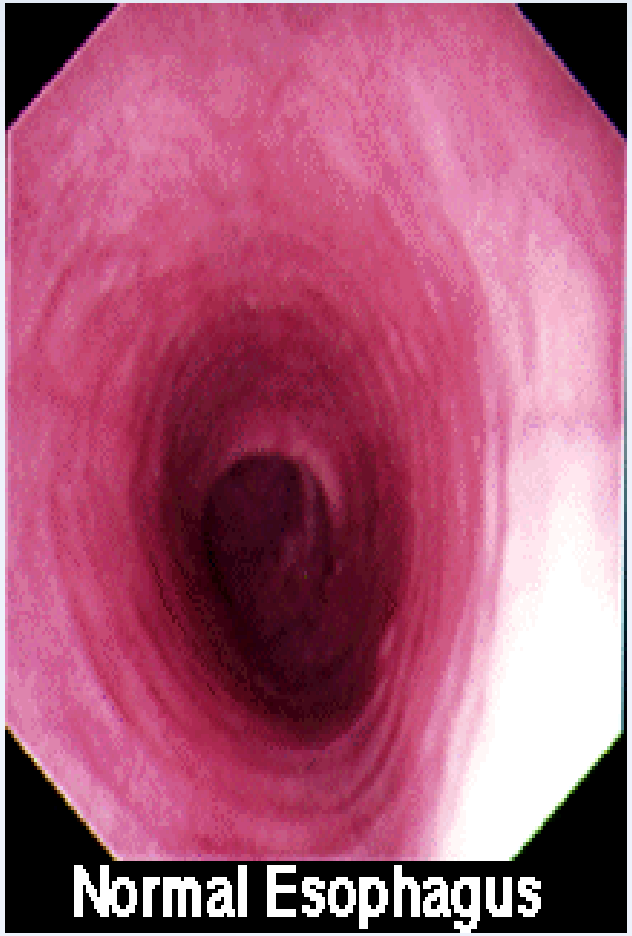

But **endoscopy** of the esophagus in our patient revealed the following:

- **We find pale areas (normal), but we also find what looks like extensions from the mucosa of the stomach (darker in color).**
- **The reason behind the presence of the "more pinkish" areas is the change in epithelial differentiation pattern from stratified squamous to gastric type.(metaplasia)**

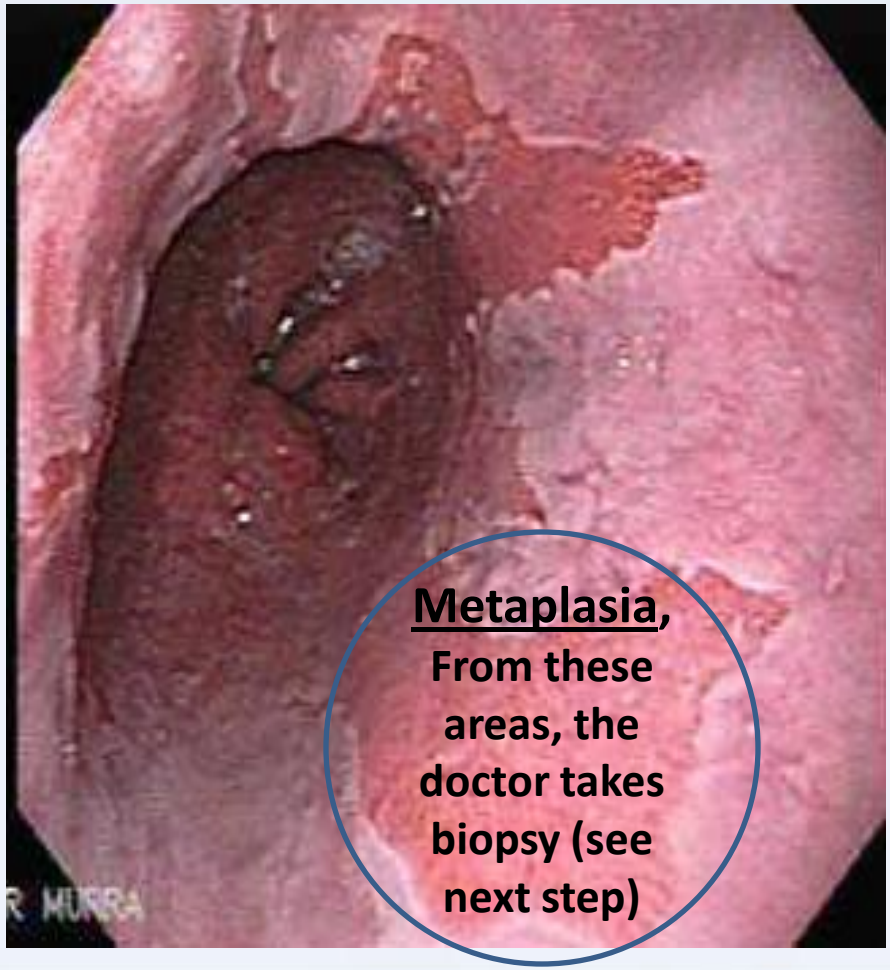

- **Biopsy** showed esophageal mucosa lining composed of columnar epithelium with goblet cells instead of normal stratified squamous epithelium.

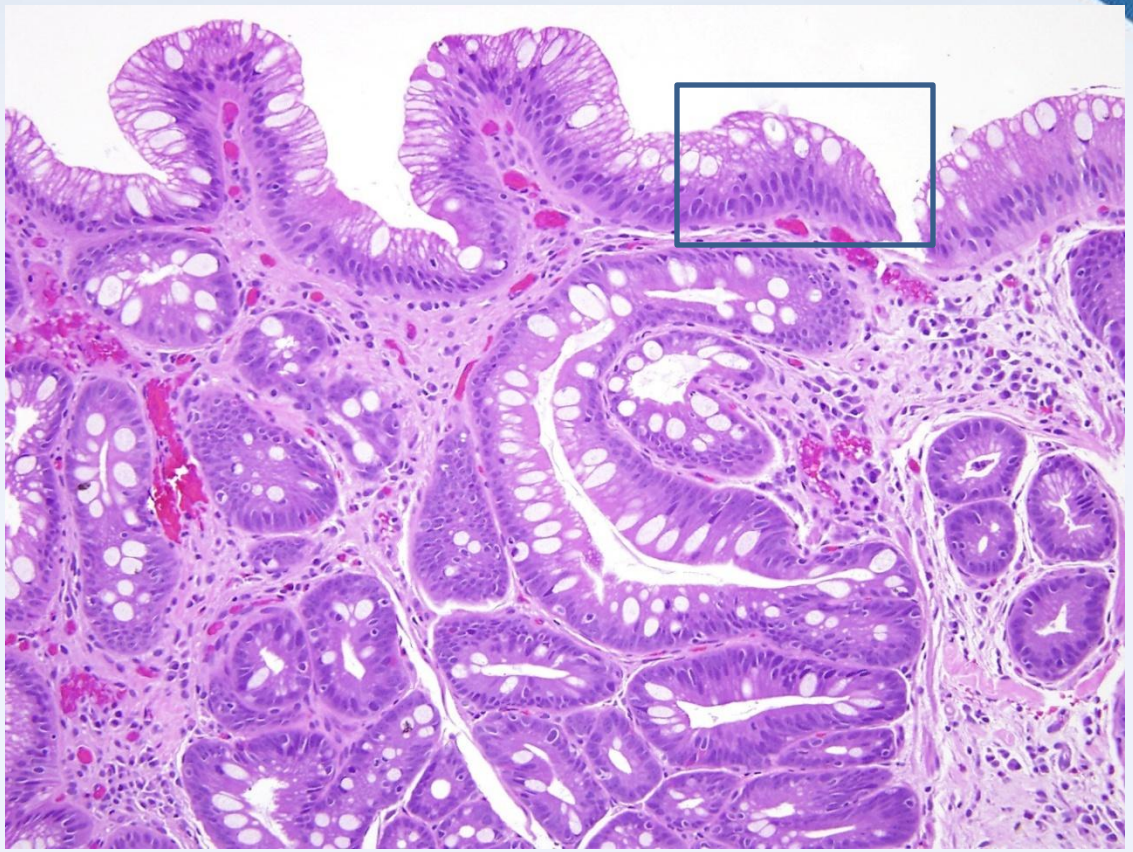

YOUR DIAGNOSIS IS..?? **Barrett Esophagus**

7. Esophageal Carcinoma

- **Types:**

1. ***Squamous cell carcinomas (*90% of esophageal cancers)....** More common because the lining of the esophagus is squamous cells

2. ***Adenocarcinomas*....**less common because there are no glands.

- In the USA 3-5X increase in the last 40 years in the incidence of adenocarcinomas associated with Barrett esophagus.
- Adenocarcinoma arising in Barrett esophagus is more common in whites than in blacks. (Adeno., أبيض)
- Squamous cell carcinomas are more common in blacks worldwide. (squamous., أسود)
- Incidence is variable according to the geographical area; high in china and Iran, low in the states.
- In USA 6 new cases/100,000/population/year
- In regions of Asia extending from the northern China to Iran, the prevalence is well over 100/ 100,000

Squamous Cell Carcinoma

- Important contributing variables:

1. prolonged mucosal exposure to potential **carcinogens** such as those contained in tobacco and alcoholic beverages .
2. **chronic esophagitis** which is often the consequence of alcohol and tobacco use.

   Chronic inflammation leads to chronic irritation of cells and an increase in the chance of developing carcinoma.

Risk Factors for Squamous Cell Carcinoma of the Esophagus

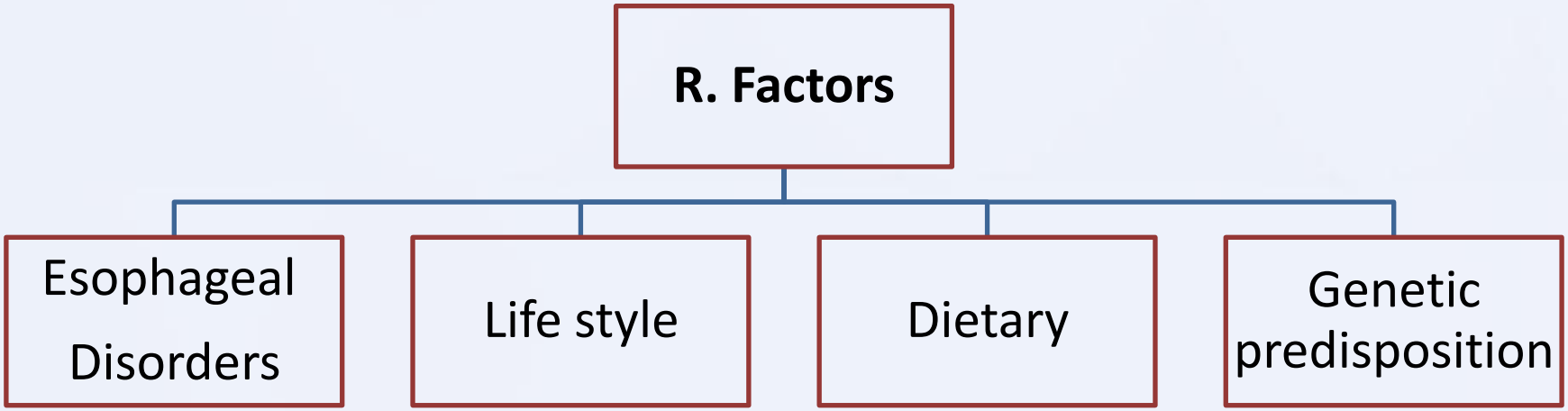

1-Esophageal Disorders

- Long-standing esophagitis
- Achalasia
- Plummer-Vinson syndrome (esophageal webs, microcytic hypochromic anemia, atrophic glossitis)

2-Life-style

- Alcohol consumption
- Tobacco abuse

3-Dietary

- Deficiency of vitamins (A, C, riboflavin, thiamine, pyridoxine)
- Deficiency of trace metals (zinc,molybdenum)
- Fungal contamination of foodstuffs
- High content of nitrites/nitrosamines

- **The high levels of nitrosamines and fungi contained in some foods probably account for the very high incidence of this tumor in some regions of China.**

- **A strong association with HPV occurs only in high-incidence areas.**

4-Genetic Predisposition

(p16/INK4 ..... EGFR ..... P53)

- **Abnormalities affecting the *p16/INK4* and EGFR are frequently present in squamous cell carcinoma of the esophagus.**
- **Mutations in *p53* are detected in as many as 50% of these tumors and are generally correlated with the use of tobacco and alcohol.**

- **Unlike in colon carcinomas, mutations in the *K-RAS* and *APC* genes are uncommon.**

Large ulcerated squamous cell carcinoma of the esophagus

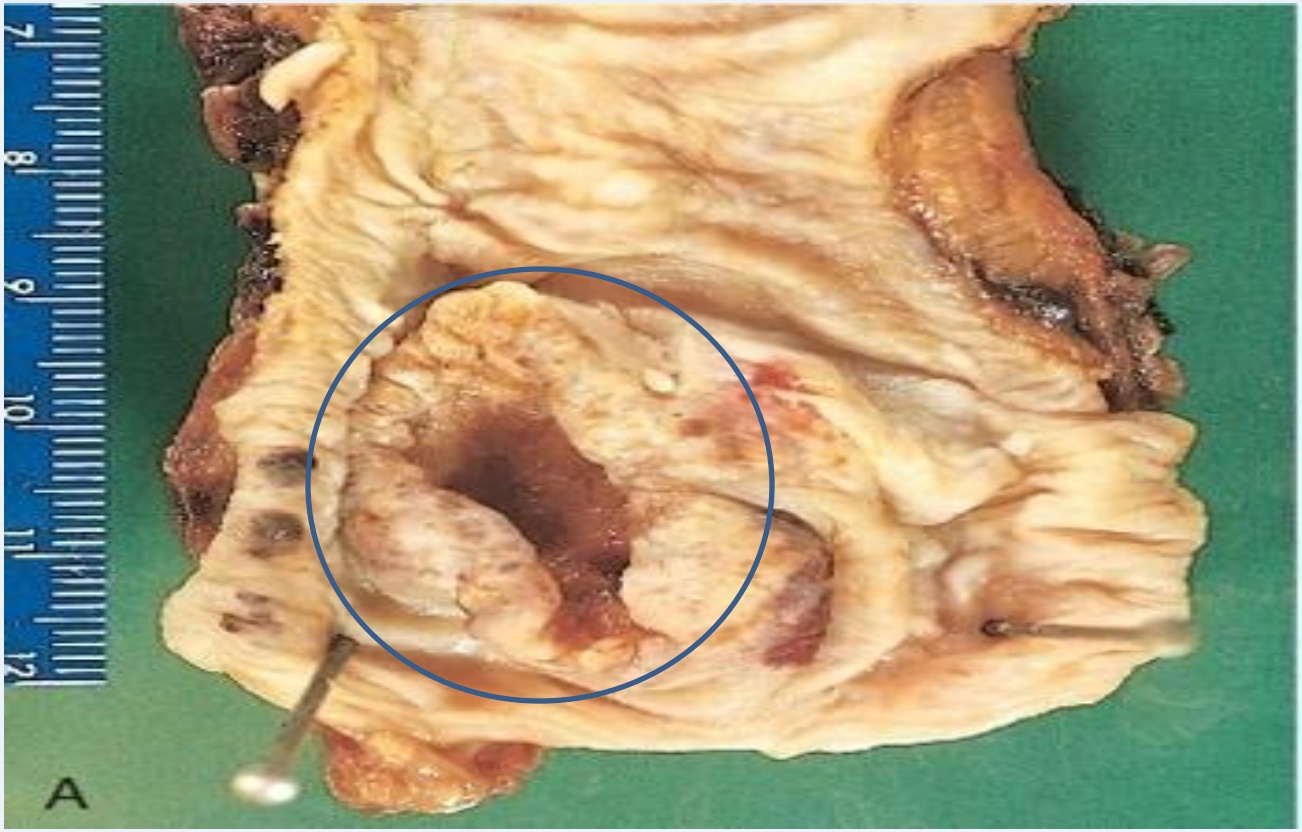

- We can see a large mass with ulcerated necrotic center.
- A biopsy must be taken in order to prove malignancy.

Low power view of esophageal SCC invasion of the submucosa.

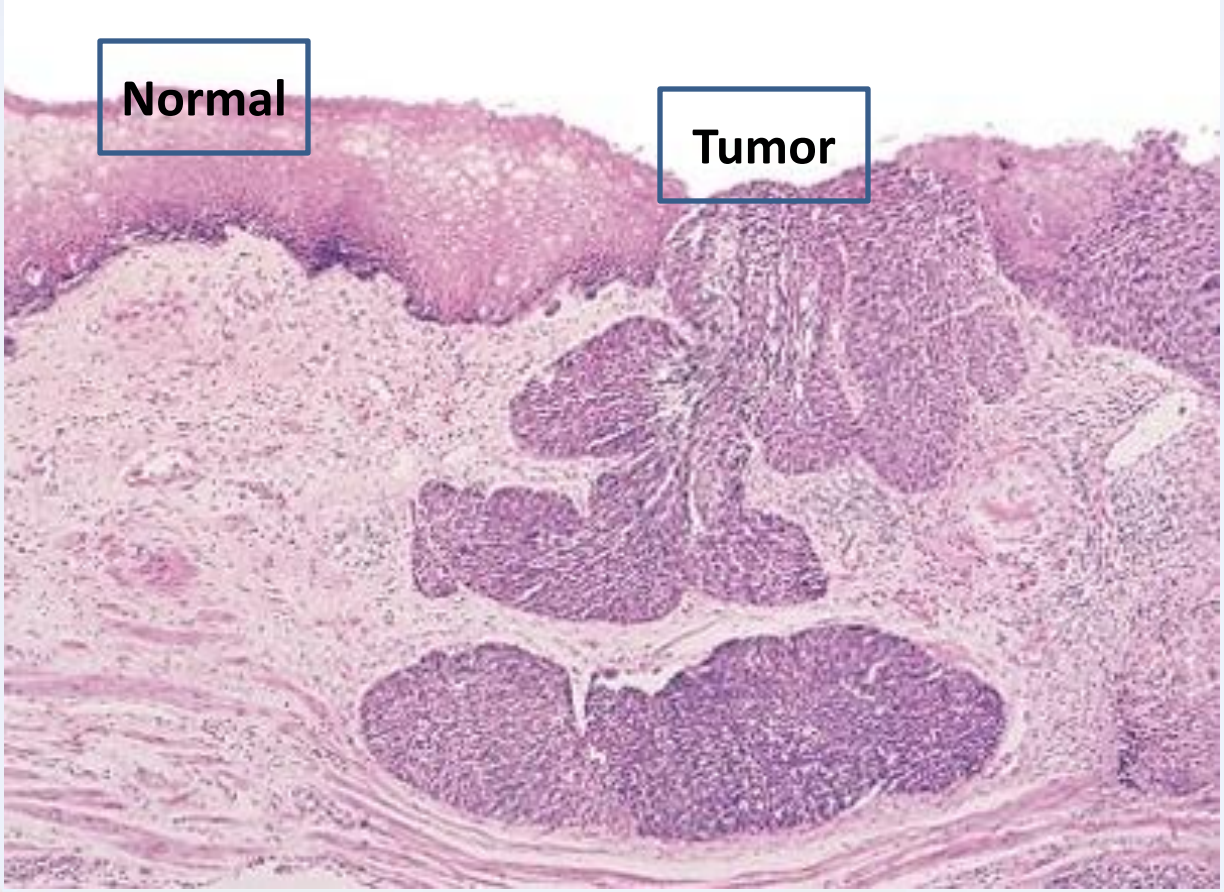

- The tumor is originating from the lining mucosa and going downwards (tumor infiltration into the esophageal wall).
- Esophageal carcinoma is very bad, and surgery is difficult.

Clinical Features

(but keep in mind that some patients can be asymptomatic)

- insidious in onset
- **dysphagia** and obstruction gradually and late.

+

Signs of malignancy:

- Weight loss
- Anorexia
- Fatigue
- Weakness
- pain, usually related to swallowing.

- Diagnosis is usually made by imaging techniques and **endoscopic biopsy**.
- Esophageal SCC extensively invades the rich esophageal lymphatic network and adjacent structures relatively early in their development.
- Surgical excision is rarely curative.

Extra Slide, histology: Differentiate between Esophageal Squamous Cell Carcinoma (slide 73), and Esophageal Adenocarcinoma (this slide)

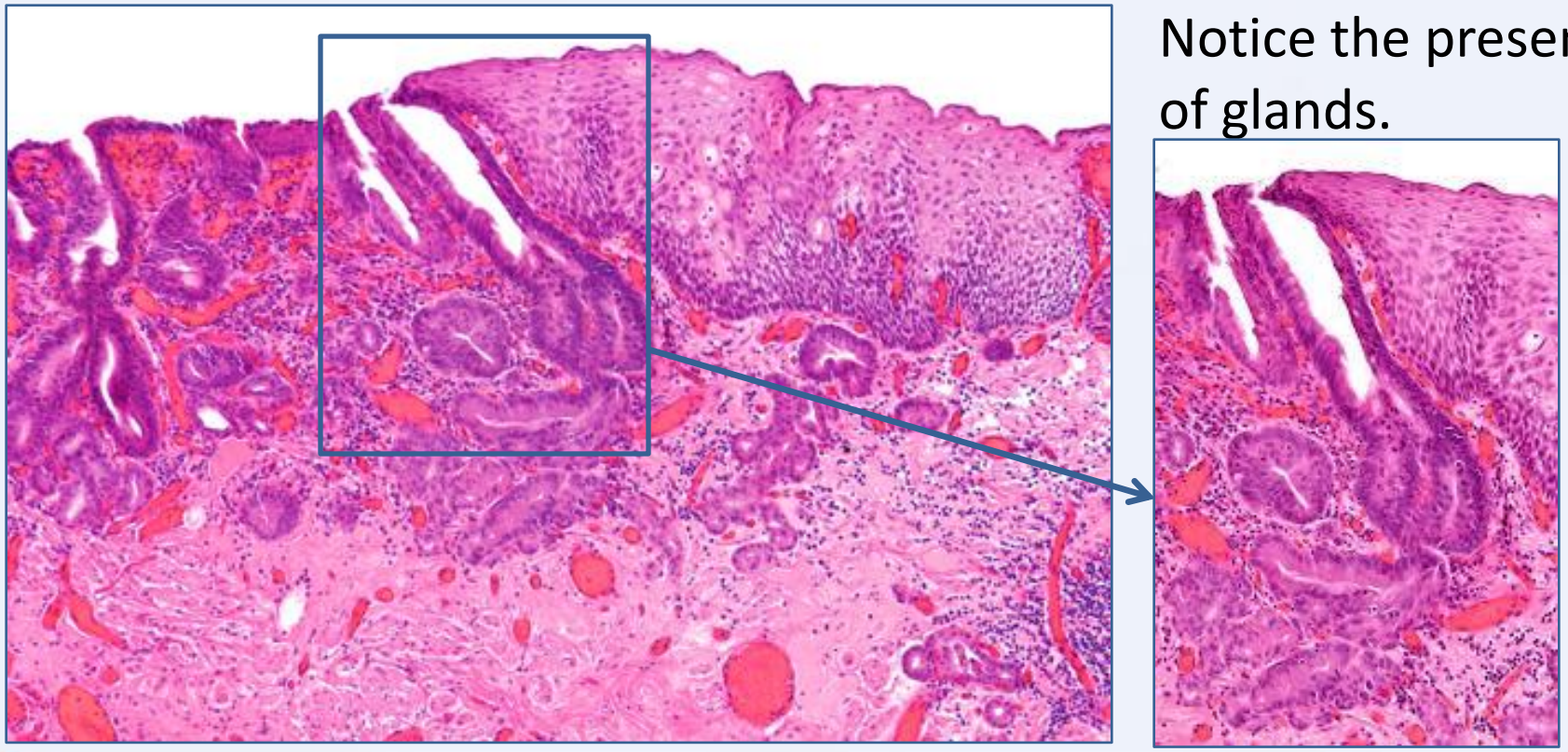

Notice the presence of glands.

Clinical case #4...(Esophageal Carcinoma)

- A 70 yr old man with hx (history) of progressive dysphagia over several months and weight loss.
- A CT scan of the abdomen reveals of hiatal hernia.
- **Endoscopy** revealed narrowing of the lower third of the esophagus.

- Bx (biopsy) revealed the presence of proliferating dysplastic cells infiltrating into the esophageal wall.

YOUR DIAGNOSIS IS...?? **Esophageal Carcinoma**

The End :’D