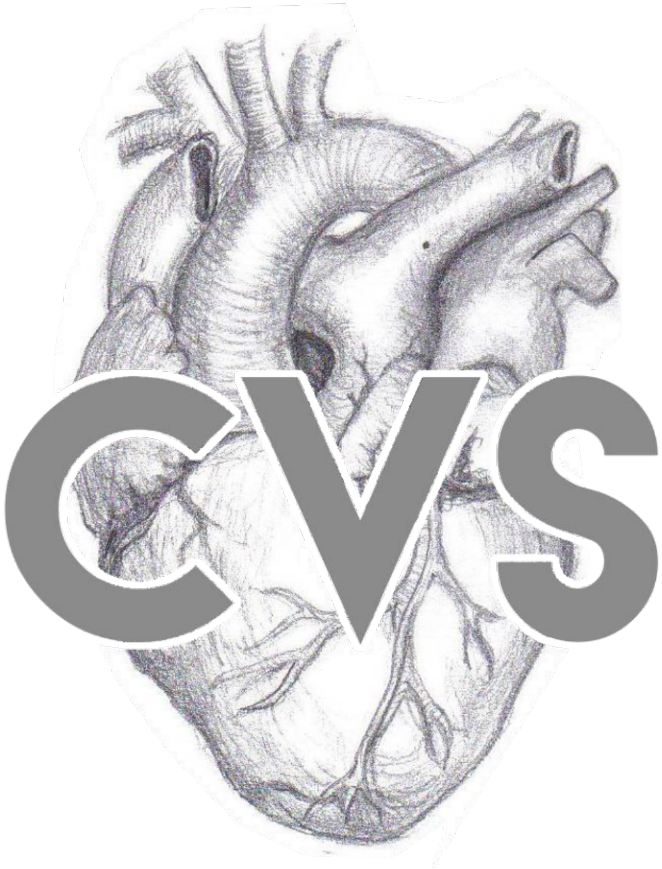

PHYSIOLOGY

☑ Sheet ○ Slide ○ Handout

Number

6

Subject

Vectorial Analysis of ECG

Done By

Ayat M. Zghoul

Corrected by

Hashim Ahmad

Doctor

Faisal I. Mohammed

Date: **00/00/2016**

Price:

By the name of Allah the Compassionate the Merciful

- In this sheet we will discuss :
  - I. **Bipolar , unipolar and chest leads .**
  - II. **Draw the Hexagonal axis of the ECG** and **Principles of Vectorial Analysis of ECGs.**

Bipolar, unipolar and Chest Leads

1. **Einthoven's Triangle**: It's an equilateral triangle, so when we draw a circle around it, its center would be the center of the circle. When we use three leads, the triangle is convenient, but as mentioned in the last sheet, we use a 12-lead ECG, using 6 limb leads and 6 chest leads. To represent these 6 limb leads, the triangle is not useful, so we have to transform it into a circle.

   Remember: We are dealing here with vectors that have values and magnitudes. So, when we transform the vectors, we move them **parallel to their original positions, without changing the direction of the value.** This forms our **Trigonal axis of the Heart (that formed by the 3 bipolar limb leads).**

- Einthoven derived the idea from Kirchhoff's second law of electrical circuits LI+LII+LIII=0 but he reversed the direction of electrodes in lead II. (As explained in sheet 5).

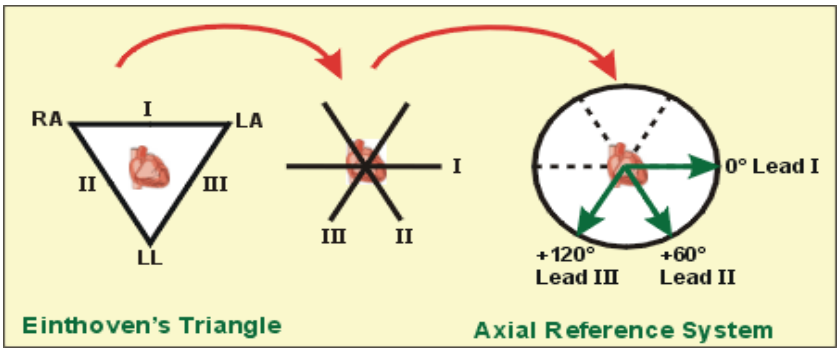

2. **Unipolar limb leads**:
   What they did is to make **the negative electrode equal Zero " indifferent electrode by** connecting the negative electrode to three limbs **through a very high resistance**. The positive electrode is once connected with the right arm, once with left arm and once with left foot. When they recorded the ECG, the recording was very small!
   Then they thought of something else, which is to connect the negative electrode

to two limbs with high resistance **“ indifferent electrodes “** and the positive electrode with the third limb, they noticed that the recorded values are augmented, then it was called **Augmented Unipolar** > as seen in the figure .

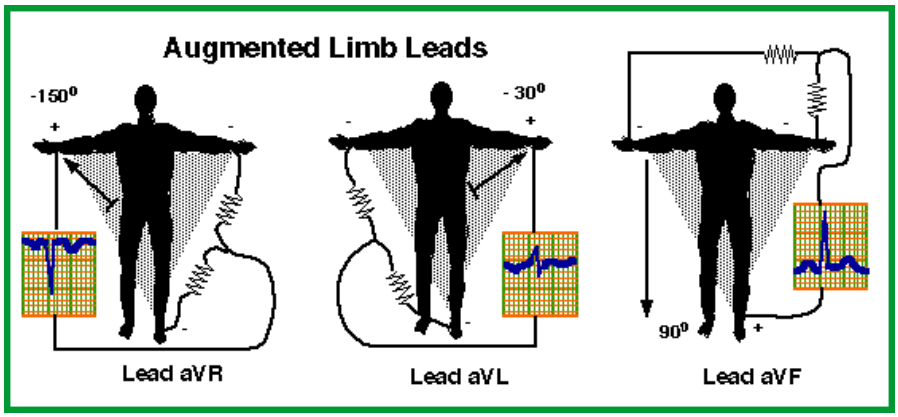

- **Notes:**

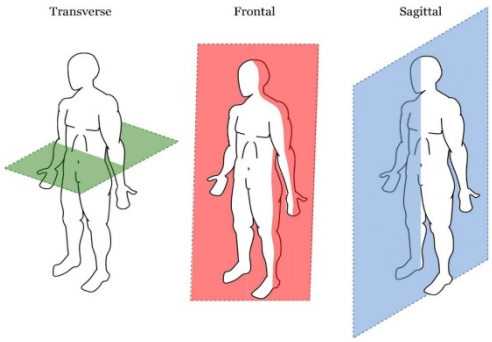

I. The mean electrical axis **is to the left and anterior,** so we have to analyze it in 3D; because it’s to the left we analyze it in the frontal plane {using the limb leads}, and because it’s to the anterior, we analyze it in the transverse “horizontal“ plane {using the chest leads} .

II. If the electrical axis is going **towards the positive** electrode, then the recording is positive (**upward** deflection).

III. If the electrical axis is going **away from the positive electrode,** then negative (**down** deflection).

IV. From the notes I and II, we can explain why the QRS in aVR is down deflection while in aVL and aVF are upward deflections.

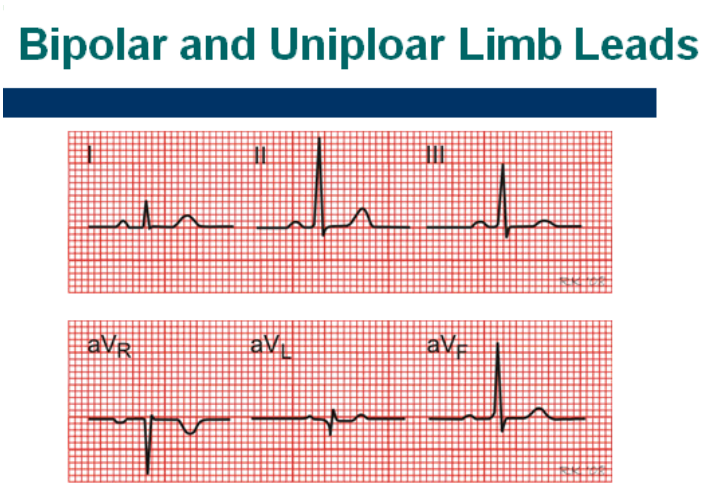

3. Chest leads

- ✓ To present the transverse plane >> Precordial (Chest) Leads (unipolar)
  { V1-V6 } or { C1-C6} according to the type of machine used. V >> Vector , C >> Chest

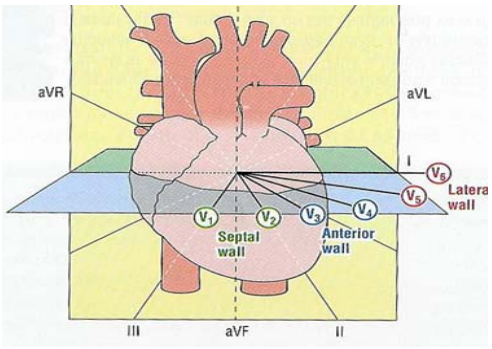

- ✓ To determine any point we need two lines; horizontal and perpendicular lines:

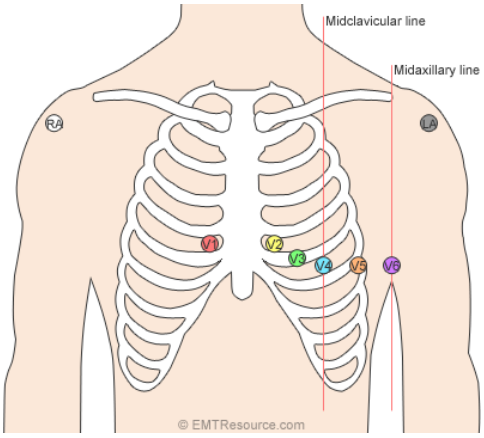

Position according to sternum				Recording(+/-)
On the right side	V1	Vertical	Parasternal line right	Negative
		Horizontal	4th Intercostal space right	
On the left side	V2	Vertical	Parasternal line left	
		Horizontal	4th Intercostal spaceleft	
	V3	Between leads V2 and V4		Same(equel)
	V4	Vertical	Mid-Clavicular line left	Positive
		Horizontal	5th Intercostal Space left	
	V5	Vertical	Anterior Axillary lineleft	Positive
		Horizontal	5th Intercostal Space left	
	V6	Vertical	Mid-Axillary line left	Positive
		Horizontal	5th Intercostal Space left	

- The table is taken from last year sheet !
- Please, memorize them from the figure, the table just clarifies the positions shown on the figure. Make an imaginary curve in your brain to imagine where each electrode resides.

- ✓ We do too many leads to know the abnormality EXACTLY {where is it? left side? right side? Anterior or posterior part of the heart?}
- ✓ If the abnormality is in the posterior aspect of the heart, so how can we discover it?!

  - Doctor Faisal mentioned "the posterior aspect of the heart" while talking about QRS complex. In that context, he means the posterior part of the ventricle which is the last to depolarize. Here, he means the posterior wall of the heart.

  We put an **esophageal lead** which is a unipolar lead. Remember the esophagus is posterior to the heart separated from the left atrium by PERICARDIUM. Then we are able to record an accurate ECG.

- ✓ Nowadays there is something called **transesophageal echocardiogram** {echo} (التصوير الصوتي للقلب they put the transducer in the esophagus “very close to the heart ".
- ✓ We may put the lead in the back but because of too much muscle then that may interrupt the recording.

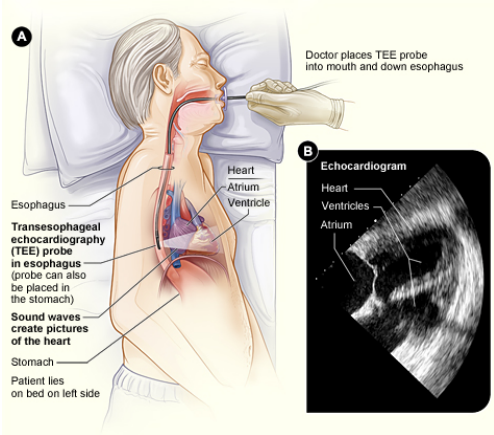

*In both V1 and V2, the **Total** QRS recording is **negative** deflection, why ?!*
Bcz the mean electrical axis is to the left and anterior, so they move Away from these two leads!
Plz see the figure in the next page

*In V3, the **total** would be **zero** (in the figure the R equal S but different directions then the total = Zero), why?!*
it is located in the middle

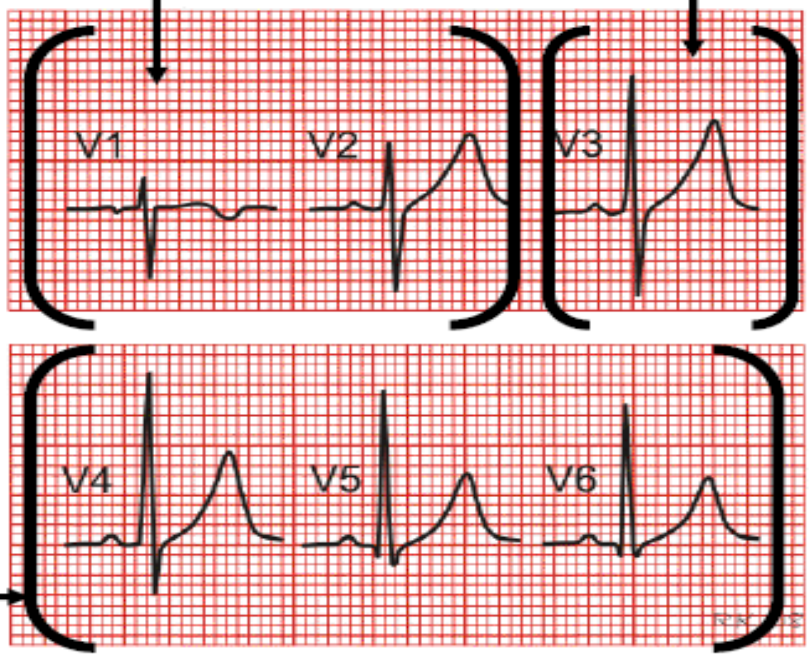

In V4,V5 and V6, the QRS recording is positive deflection, why ?!
Bcz the mean electrical axis is to the left and anterior, so they move towards these vectors!

- ✓ **This figure shows us the chest leads from V1 to V6 and the mean electrical axis. It's upward view not anterior (plz don't get confused!)**
  from this figure we can see that the mean electrical axis is going toward the V4,5 and 6 and away from V1 and V2. This explains the difference in the direction and magnitude of the QRS complex in different chest vectors!

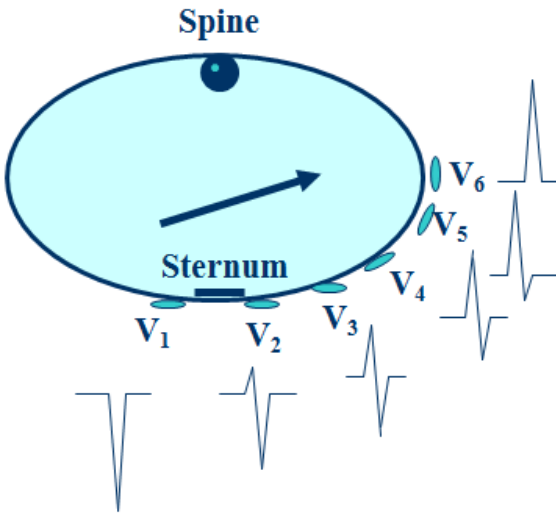

- ✓ This is the ECG for the 12 leads we discussed before:

Animation for the 12 leads https://www.youtube.com/watch?v=kwLbSx9BNbU

- The objectives for this lecture and next lectures are:
  1) **Recognize the normal ECG tracing we may discuss some abnormalities!**
  2) **Calculate the heart rate**
     we can calculate the heart rate from the ECG m but keeping in mind it's regular .
  3) **Determine the rhythm**
     i. the rhythm of Heart Rate may be regular or irregular .
     the irregularity could **be irregular in irregularity** (RR interval in first cardiac cycle is .8 the second cycle .6 then .7 then .9) or **regular in irregularity** (RR interval in first cardiac cycle is .8 the second cycle .6 then .7 then .8 then .6 then .7 then .8 an so on) .
  4) **Calculate the length of intervals and determine the segments deflections**
     i. To calculate the intervals, we count the small squares then multiplying it with 0.04 seconds.
     ii. In segments, we don't care about the duration of the segment but rather we look at it if it's elevated or depressed from the isoelectric line.
  5) **Draw the Hexagonal axis of the ECG**
  6) **Find the mean electrical axis of QRS (Ventricular depolarization)**

Draw the hexagonal axis of QRS.

- In this sheet we will discuss how to draw the Hexagonal axis of the ECG then try to Find the mean electrical axis of QRS (Ventricular depolarization).

- We knew that the current of the heart will move from the depolarized area to the still-polarized area, the vector has direction “the angle“ and value "the length of the vector“.
- The normal mean QRS vector is 60° { in Guyton + 59} ,,, the normal range is (-30◦ - 110◦) , but clinically normal range is (0-90)
  { that will explained later in the sheet }

- At any instance there are a lot of vectors for different directions then we have to calculate the resultant!
- The depolarization of the ventricle, from the septum to the majority of ventricle and finally to the posterior part (Base).



- When we discussed Einthoven's triangle, we draw the trigonal axis of QRS, as in this figure :
  *Note that **the lower half of this circle is positive and the upper half is negative !**

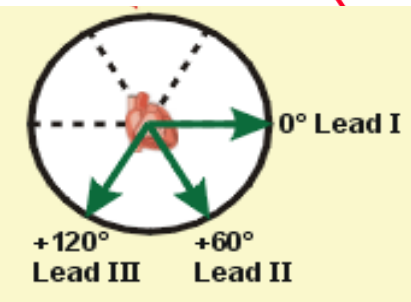

- Now, how to draw the hexagonal axis:
  - ✓ We draw the trigonal axis then add the Augmented unipolar leads.
    - aVL: from the heart to the left arm, intersects (bisects) the angle between the **lead III and lead I →** the resultant angle would be **-30**

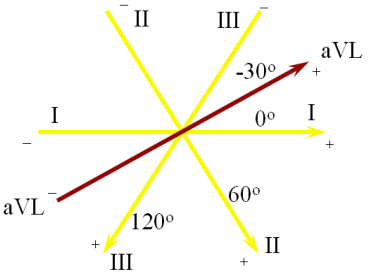

    - aVR: from the heart to the right arm, intersects (bisects) the angle between the **lead II and lead I →** the resultant angle would be **210** (180 +30)

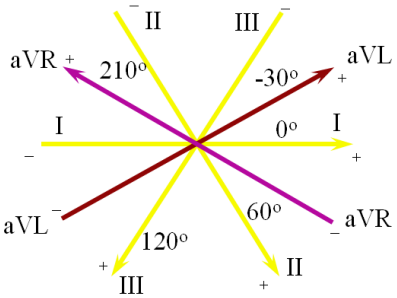

- aVF: from the heart to the left foot, intersects (bisects) the angle between the **lead II and lead III** , the resultant angle would be **90** .

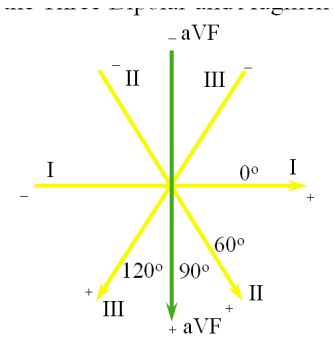

✓ There are some things should be taken in consideration:

I. **Lead I and aVF** should be perpendicular to each other.
II. **Lead II and aVL** should be perpendicular to each other.
III. **Lead III and aVR** should be perpendicular to each other.

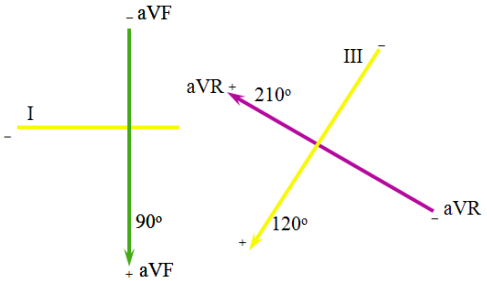

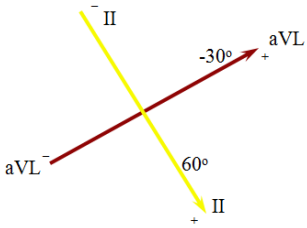

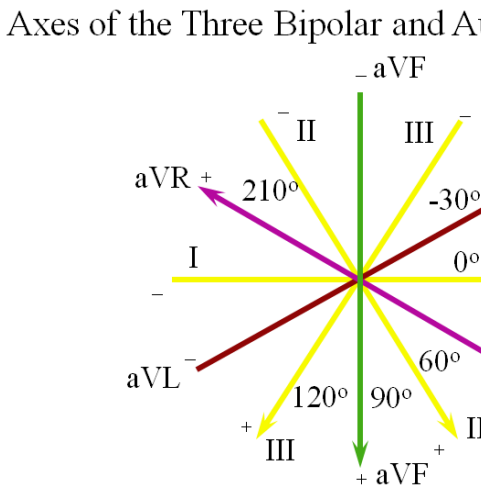

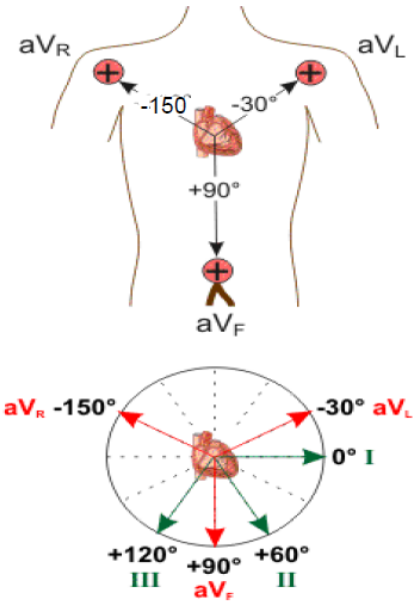

➢ Since we are talking about the same plane "frontal plane" for all leads, so we can choose any two leads and draw the mean electrical axis. The doctor prefers Lead I and aVF (because they are perpendicular to each other).

❖ Now if we have th ECG and want to draw the mean electrical axis:

1) **Take any two leads** you want, let's take Lead I and aVF , then measure the length of t**he R , Q and S waves by counting the number of small squares** and do **algebraic summation {** counting the number of small squares of R , S and Q for each QRS complex in each lead and taking the direction in consideration if it's down deflection then negative and if it's positive deflection then it's positive and sum them together. Let's say that the R is 14 ss positive deflection and the S is 4 ss down deflection the Q is 3 ss down deflection then the totla is 7 ss positive **}**. Let's say that the mean of QRS in lead I is 7 small square and the mean of QRS in the aVF is also 7 small squares.

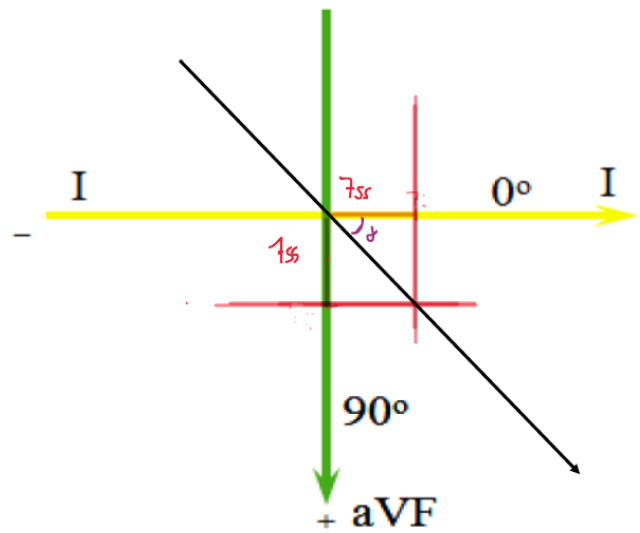

2) Count 7 small squares from the center **and Draw a line perpendicular to the lead I axis.**
3) Count 7 small squares from the center **and Draw another line perpendicular to the aVF axis "**perpendicular to the first line" .
4) At the **site of intersecion**, draw a line extending to the **center**.
5) Measure the angle by using **Tan** { opposite / adjacent }, by using the calculator find the angle !in this case it's 45 .
6) the mean electrical vector is 45 then it's Normal .
   watch this video https://www.youtube.com/watch?v=jg5X3V5IPS4

➢ If the algebraic summation of **lead I is positive** and the algebraic summation of **aVF is also positive**, then the mean electrical axis is between 0 and 90, which is **the normal range!**

- If the algebraic summation **of lead I is positive** and the algebraic summation of **aVF is negative**, then the mean electrical axis between 0 and -90, then **it's left axis deviation!**

- If the algebraic summation of **lead I is negative** and the algebraic summation of **aVF is positive** then the mean electrical axis between 90 to 180 then **Right axis Deviation !**

- If the algebraic summation **for both is negative** then between the -90 and -180 then **extreme axis deviation** , don't know is it right or left ?! so we have to look to the patient ; if he has **right heart disease then it's Extreme RIGHT** Axis Deviation but ; if he has **left heart disease then it's Extreme LEFT** Axis Deviation .

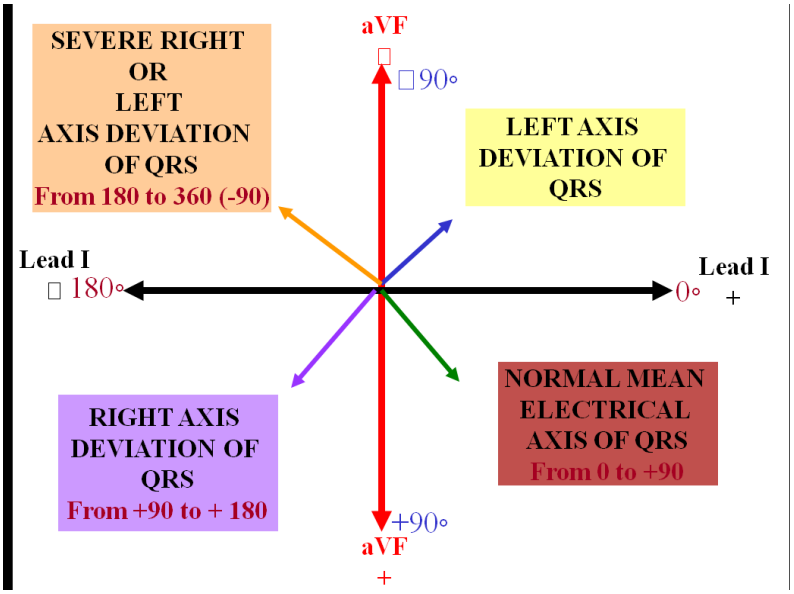

- https://www.youtube.com/watch?v=_CCUWdAaQoA , watch it to make sure that you understand the idea .

Now , why **the QRS complex is composed of three waves ?!**

- The depolarization of the ventricles occurs firstly in the septum then spread through the ventricles until reaching the base of ventricle (the last are to be depolarized) and **for every instant there is a value.**

A. The first are to be depolarized is the **septum**, at this instance there is a resultant vector. If we analyze it in lead I, II and III to measure its value {note that the vector is going toward the positive side then it's up deflection in the three leads}

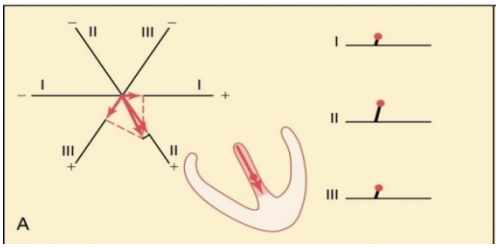

B. The depolarization will **continue and spread, so the result in a new vector** (different value and direction).
note that the value in the three leads **increases**.
The depolarization vector is large because now about half of the ventricles is depolarized! {toward the positive electrode → up deflection}

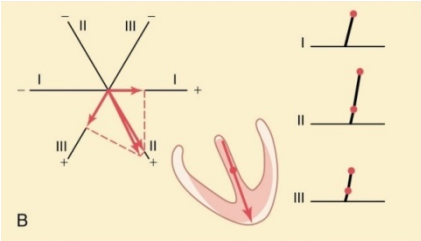

C. There is **decrease** in the in value?! Because the outside of the heart apex is now electronegative, neutralizing much of the positivity of the other surfaces .
Also, there is shifting toward the left side because the left ventricle is slower to depolarize that the right ventricle.

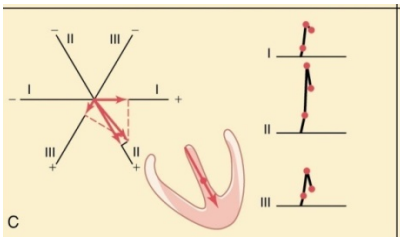

D. Here, the last depolarization occurs in the posterior part of the ventricle.
Remember that the current of the heart will move from the depolarized {most of the ventricle} to the still polarized area {the posterior part of the ventricle} that's why it'll be negative deflection in both lead II and III { away from the positive electrodes } but in lead I will be less positive , **This is S wave**

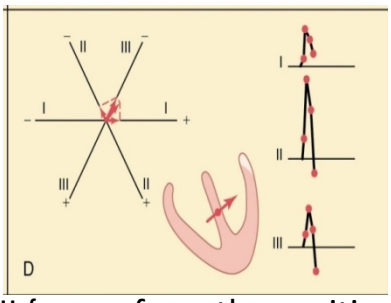

E. Completely depolarized ventricle, note we record the R and S waves, with no instantaneous vector. So, now we have **isoelectric segment!**

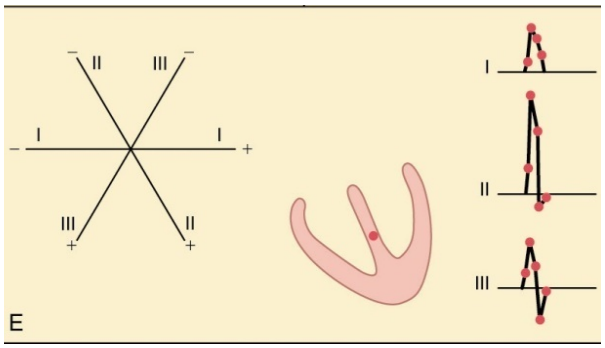

❖ **Notes :**

1) the Q wave is not always recorded, it's recorded when **the left side of the interventericular septum is depolarized before the right side {the direction of the vector is to right then away from the positive electrode } and it's usually have small value**.
if the value of the **Q wave increase** then we have to think of **multi node infarction**! in these patients we notice that there **is elevation in the ST segment!**

2) **stress Test:**

while the patient is doing exercise, we do ECG. If after a while the ST segment is depressed then patient may have obstruction in LAD so we have to do catheterization {CATH} for him!
remember: any elevation or depression in the ST segment >>> Ischemia.

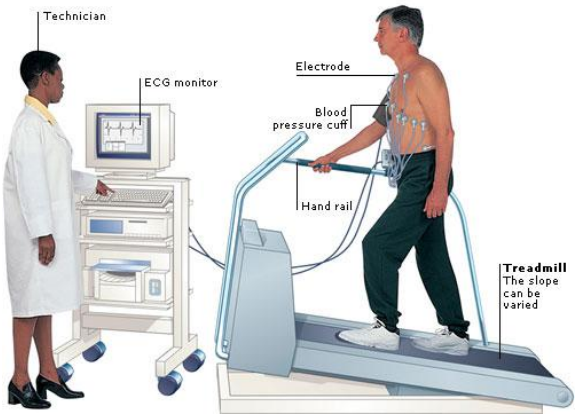

➢ **The T Wave (Ventricular Repolarization) :**

✓ First area to repolarize is near the apex of the heart to the base (from the pericardium to the endcardium) because after the QRS the

ventricles will contract that will compress the middle and inner layers more than the outer layer that will weaken the blood flow to the inner layer and change the permeability of the endocardium fibers, which will delay the action potential of the endocardium making the pericardium repolarize first.

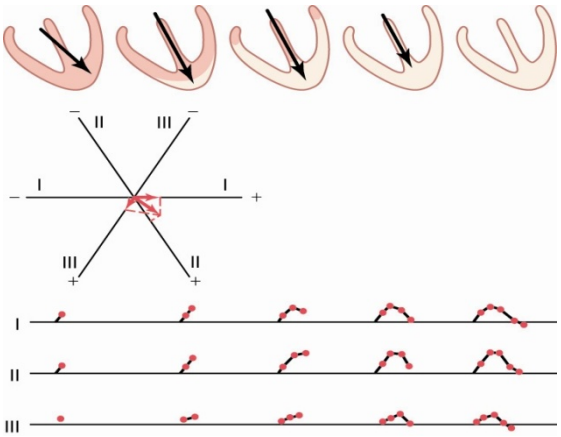

- ✓ **Last areas, in general, to depolarize are the first to repolarize.**
- ✓ Repolarized areas will have a + charge first; therefore, a + net vector occurs and a positive T wave.
- ✓ It won't be sharp but it's **gradual and slow** bcz of slow K channels.

- **Atrial Depolarization (P-Wave) and Atrial Repolarization (Atrial T Wave):**
  - ✓ Atrial depolarization begins at sinus node and spreads toward A-V node. This should give a + vector in leads I, II, and III.
  - ✓ Atrial repolarization can't be seen because it is masked by QRS complex. If it's seen it will be **down deflection**! Bcz Atrial depolarization is **slower than in ventricles, so first area to depolarize is also the first to repolarize.**
    This gives a negative atrial repolarization wave in leads I, II, and III .

- Slides 15-19 are examples for how to draw the mean electrical axis, plz study them !
- If there is something you don't understand or for better understanding plz refer to **Dr. Najeeb's videos** they are very useful <3!

Wish you all best of luck !
sorry for any mistake ^^
Ayat M. Zghoul