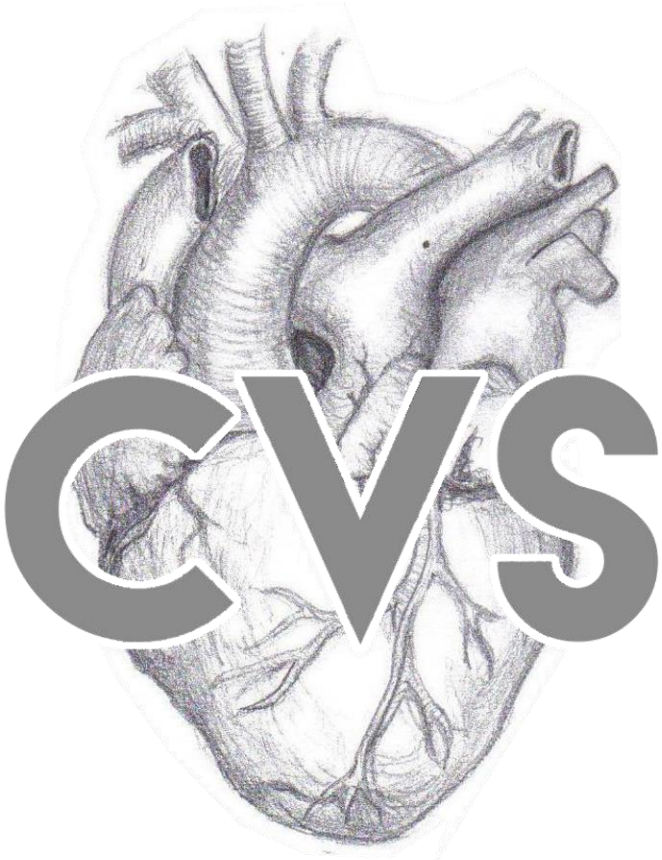

PHYSIOLOGY

☑ Sheet ○ Slide ○ Handout

Number

4

Subject

Electrocardiography ECG (1)

Done By

Aseel abdulhakim

Corrected by

Heba Al-lala

Doctor

Faisal Mohammad

Date: **19/10/2016**

Price:

This sheet was written according to section 2 recording

الى كل من يقرا اتمنى ان يصادفك يوم جميل ... بغض النظر عن الشيت ههه

In this sheet we are going to talk about the ECG which is one of the most important subjects in this system

This lecture is not hard it is actually fun if you are a physics lover ☺

In the previous lecture we talked about

1.frank-starling law of the heart

2.the conduction system of the heart and its components (SA node ,AV node ,AV bundle ,bundle branches and purkinji fibers

3.the pathway of the heart beat

4.the sympathetic and parasympathetic effect on the conducting system of the heart

Sympathetic : + chronotropic effect

+ dromotropic effect

+ inotropic effect

And it supplies all parts of the heart

Parasympathetic: - chronotropic effect

It does not supply the ventricles and this is why it doesn't have inotropic effect

(doesn't affect contraction)

The objectives of this lecture

We are going to :

1.describe the normal waves in a normal electrocardiogram

2.recall the normal P-R and Q-T interval time of the QRS wave

3.distinguish the difference in depolarization and repolarization waves

4.recognise the voltage and time calibration of an electrocardiogram chart

5.point out the arrangement of electrodes in the bipolar limb leads ,chest leads and unipolar leads

So let's start

The main topic of today's lecture is **ELECTROCARDIOGRAPHY**

the sheet seems long but it is just full of figures and pictures

This is a very imp subject because if anyone enters the hospital with a chest pain or any cardiac symptom the 1st thing the doctor asks for is an **ECG (**AKA **EKG** because the pioneers of this mechanism are German and in Dutch language cardio is written with a k)

Electrocardiography is recording the electrical changes that happen in the heart (depolarization and repolarization aka the action potential of the ventricle and atrium) and it has nth to do with the mechanical changes (systole, diastole …contraction, relaxation or heart rate)

Although heart rate can be measured using ECG 'we will know how later in this sheet ,but this is not the main purpose for it

***NOTE:** one action potential in one cell in the atrium will be transmitted to the rest of the cells in the atrium at the same time (they work as if they are one cell) and this implies to the ventricles as well and this happens due to the gap junction between the cells (**syncytium**)

Electrocardiography is recorded using a machine called the galvanometer that records voltage difference. it has 2 poles (bipolar) ..Logically this 2 poles must be put in the surface of the heart

But no one in this world or at least no one with a brain in his head will accept to have his chest opened just for an **ECG :P**

That's why we will record them from the surface of the body (we must measure and record it from different angles to have a full picture of the heart …. One pole in the right arm and the other in the left foot. right foot left hand and so on)

how much is the potential differences that occur in the heart and how much it differs from the potential differences that occur at the level of the skin ?

The membrane potential at the resting state is =-90 and in the overshot (max)= 30

So there is difference of almost 120 .. and this is at the level of the heart

At the level of the skin it is going to reach 2-3 millivolt due to resistance

-so how is this problem solved

By amplification

*So the machine or the instrument that is used in ECG is **electrocardiograph** which is a galvanometer that records voltage difference (action potential) and an amplifier

Depolarization and Repolarization waves

Lets imagine(look at figure 1 :P) that we have a strip of muscle that is in the **resting state** 'polarized' (outside is positive and inside is negative) the galvanometer record will be zero because there will be no potential difference ALL WITH THE SAME CHARGE

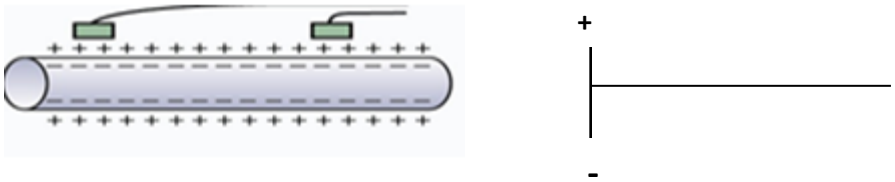

1

When the wave of depolarization starts electrical potential differences can be recorded . part of the muscle depolarize (outside neg and inside positive) and the other part is still in the resting state

This potential difference is going to increase until we reach the midway (when half of the muscle is depolarized and the other half is still in its resting state) **figure A**.

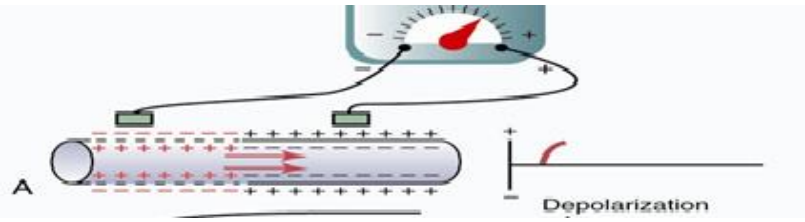

When reaching the **midway** maximum recording (maximum pot difference) is recorded and then it will start to decrease until the whole membrane is depolarized (outside they will be all negatively charged, no potential difference ,recording=zero) **figure b**

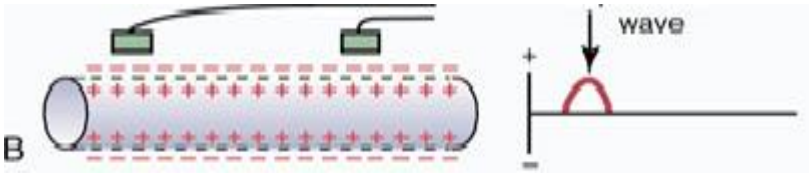

Reaching the Isoelectric line

This wave is called the **depolarization wave**

Note: depolarization wave doesn't always mean an upward reflection this can be changed and this depends in the arrangement of the 2 electrodes

But it has been agreed internationally that the depolarization wave is an upward reflection and repolarization wave is a downward reflection

Repolarization state :where the k+ potassium channel open until reaching the resting state again .

the membrane is fully depolarized (neg outside, positive inside) then **repolarization** starts to happen and now charges outside the membrane are becoming positive again (increase the pot difference) until reaching the maximum level **midway figure c**

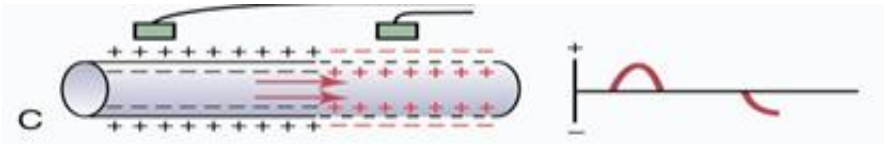

then after exceeding the midway it starts to decrease till reaching the **fully repolarized** state (outside positive and recording is zero) **figure d**

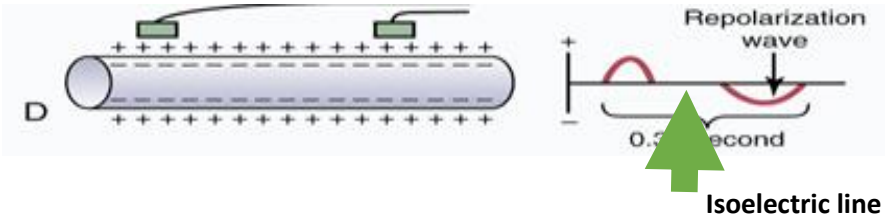

note: the isoelectric line means : no potential difference , recording=zero , fully depolarized or fully repolarized state

Normal EKG:

*** everything we are going to discuss is for normal EKG for a healthy person**

This figure shows a normal EKG (it shows depolarization of the atrium , depolarization and repolarization of the ventricles)

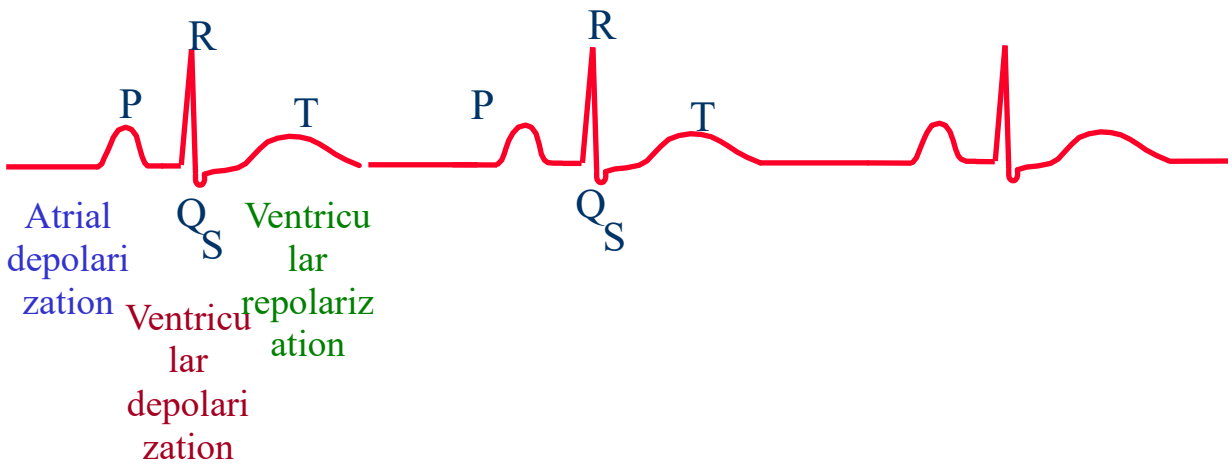

Waves

P wave :that shows the depolarization of the atrium

Qrs wave : depolarization of the ventricles

T wave :repolarization of the ventricle

*There are also intervals and segments that we are going to discuss later in this sheet

Note: this recording doesn't stop.. if the recording stopped and a continuous straight line appeared this means this person is dead

As death is diagnosed with a straight line in the EKG

As u can see depolarization of both atrium and ventricles are shown but only the repolarization of the ventricle .

We can't see the atrial repolarization ..why ?!

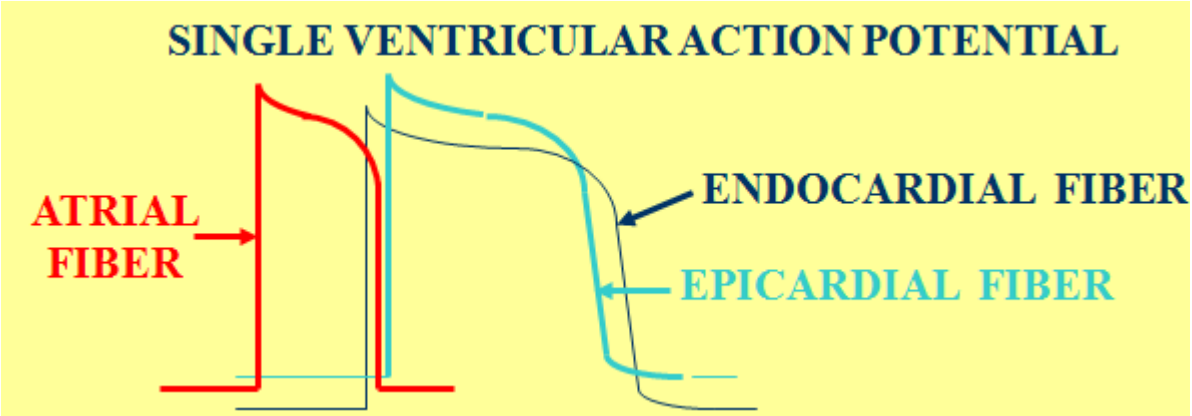

3

As you can see from figure 3 , the atrial repolarization happens while the ventricle is being depolarized

So the atrium repolarization doesn't show up because 1. It is small 2. It is masked by ventricle depolarization

(**Phase 3 of the atrium happens at the same time as phase 0 of the ventricle)**

- ✓ another thing that we can see from the EKG is that the depolarization of the ventricle and the **repolarization** waves (QRS wave and the T wave) are **upwardly** recorded !

before saying why that happens note to self we said that the direction of depolarization and repolarization depends on how the electrodes are arranged so changing the poles direction changes the direction of the wave but logically this is **not** the case here.

→this means that the change happened from the heart itself and not from the electrodes…

depolarization starts from the endocardium to pericardium and from the base of the heart to the apex

but repolarization is different it starts from pericardium to endocardium and from apex to base

why?!

1.the intrinsic property of the muscle: the pericardium action potential is shorter in duration than the endocardium so the wave of repolarization starts from the pericardium to the endocardium

2. depolarization is followed by contraction, when contraction of the ventricle occurs it will go to the center, the center can't handle the force by its own so it will start to compress and induce pressure mostly to the endocardium and this will change the permeability of the endocardium fibers, which will delay the action potential of the endocardium making the pericardium repolarize first.

So back to the normal EKG

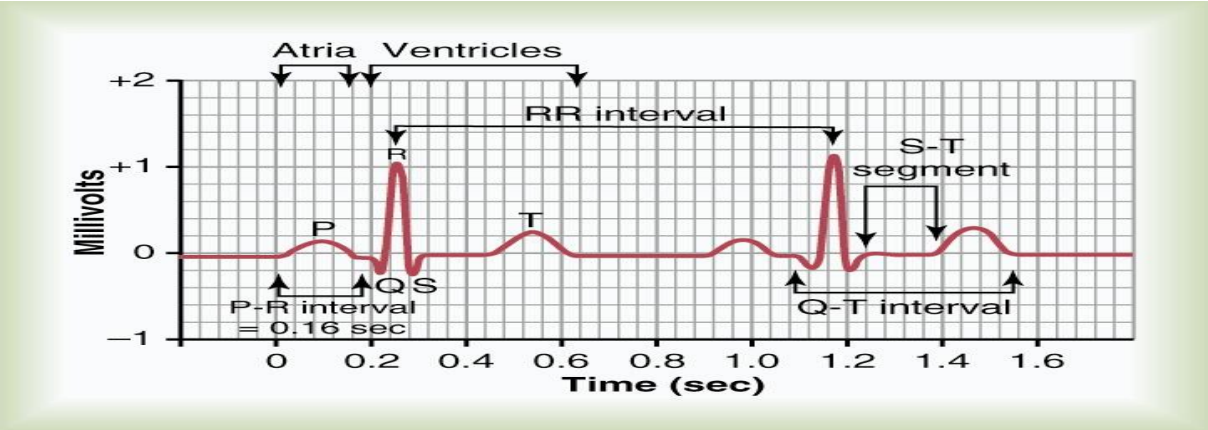

It will be recorded at a speed of 25mm/sec in a paper (x axis presents the time and the y axis presents the voltage)

As u can see the paper is full with squares

Each square (the smallest square) = 1mm

So that means each square presents =0.04 sec

1 sec ⟶ 25 mm

x ⟶ 1 mm

X =1/25 = 0.04

We said before that we are going to discuss other things from the figure

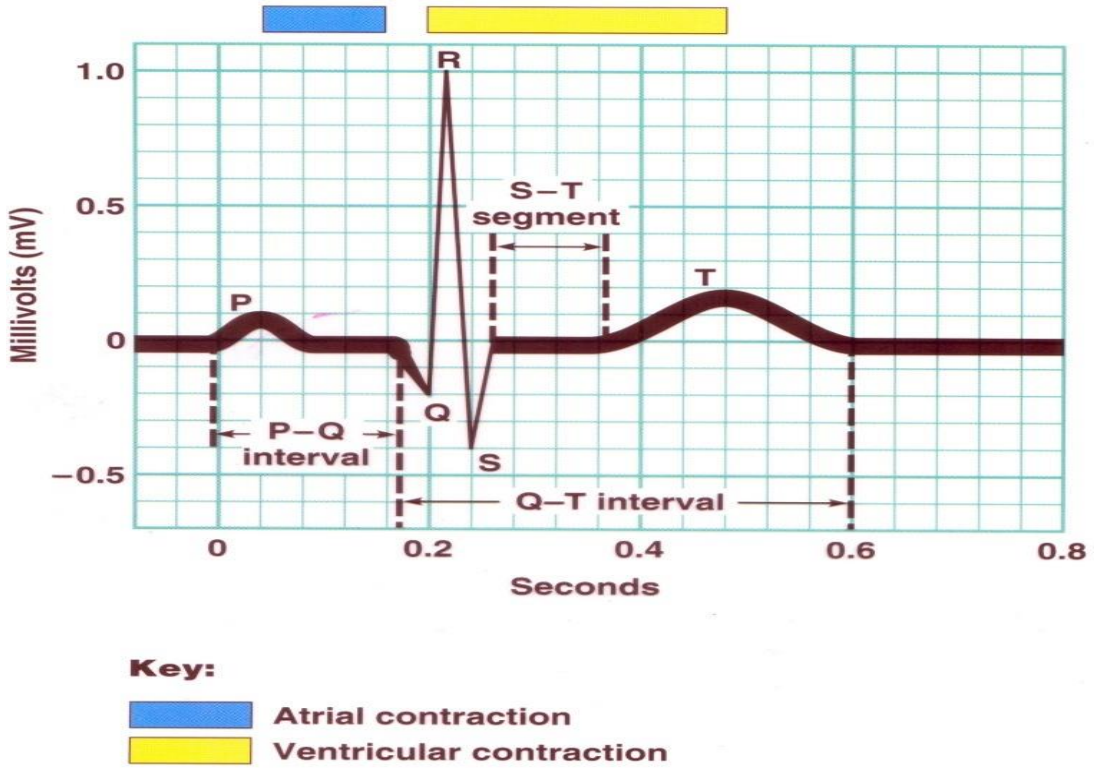

<u>Intervals :</u> (there must be a wave in between)

- the time between one R and the next R or between one T and the other T = **cardiac cycle** = one heart beat and from this we can calculate the heart rate

  heart rate (how many beats per minute)

example : if we measured the R-R interval and found that it is 1 sec ..what is the heart rate?

each heart beat occurs in 1 sec so the number of beats in one min (60 seconds) will be 60 beats

so the heart rate =60 beats / min

so when the cardiac cycle decreases the heart rate increases (If the beat needed more time to occur this means that the number of beats per min will be less)

- also from the figure we can see the **p-q interval** : which represent a complete wave from the beginning of p to the beginning of q (extends from the start of atrial depolarization to the start of ventricular depolarization **max = 2 seconds**

if it was greater than .2 this indicates damage in AV node or the conducting system for example if AV node conduction decreases the P-Q interval increases

- **Q-T interval** : the time between the beginning of the q wave to the end of t wave it represents the time required the ventricle to undergo a single cycle of depolarization and repolarization

*Q-T is variable whenever the heart rate changes Q-T value changes as well

- **QRS interval**: ventricular depolarization. It shouldn't exceed **0.12 sec**

*And there are other intervals but these are the most important

- **<u>Segments:</u>** an isoelectric line that presents complete depolarization or complete repolarization (no wave in between)

p-R segment : from the end of p to the beginning of r and represents phase 2 for the atrium (during plateau)

S-T segment : end of s to the beginning of t and presents phase 2 for the ventricles (during plateau)

These segments should be isoelectric, so if it was elevated or depressed this means there is a problem(it can be ischemia that leads to infarction)

***Remember :** ischemia is decrease in blood flow

Infarction: completel stop of blood flow

Few notes that the doctor read from the slides that is mentioned in the sheet but not in a direct way :

1.ventricular depolarization starts at the ventricular septum and the endocardial surfaces of the heart

2.the average current flow positively from the base of the heart to the apex

3.p wave precedes atrial contraction

4.qrs complex precedes ventricular contraction

5.T precedes ventricle relaxation

(depolarization precedes contraction and repolarization precedes relaxation)

- **Flow of electrical currents in the chest around the heart**

-When there is electricity there is an electric current going from negatively charged area to positively charged area



-As depolarization starts in the interventricular septum the electrical current spread this depolarization from depolarized area to the still polarized area se we have many currents that are spreading in different directions toward the polarized area. Each current is a vector (has a magnitude and a direction) so having different vectors means we must calculate a *resultant vector* (each vector has a contribution on the x axis and the y axis) so we analyze each vector and took the sum of all the vectors contribution in the x axis and the sum of their contribution in the y axis.

-After that resultant can be calculated (magnitude+ direction)

- The figure shows the mean vector through the partially depolarized heart

*depolarization starts from the IV septum then to the left and right ventricle and the last part to be depolarized is the posterior aspect of the left ventricle.

Remember that the heart is 3D so the direction of this resultant is anterior to the left

Bipolar limb head

Bipolar= EKG is recorded from **2** electrodes… limb =because the electrodes're connected to the limbs and in this figure it shows 3 bipolar limb leads

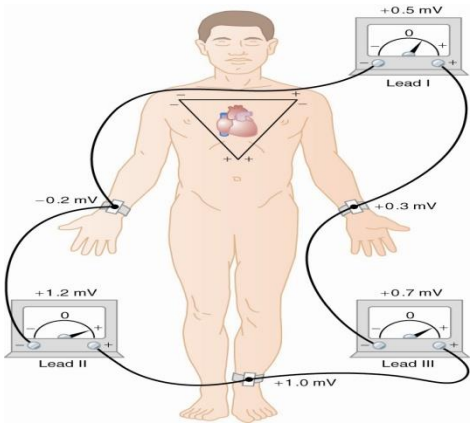

Please refer to the slides after studying the sheet

The end ☺

if your dreams don't scare you , they are not big enough