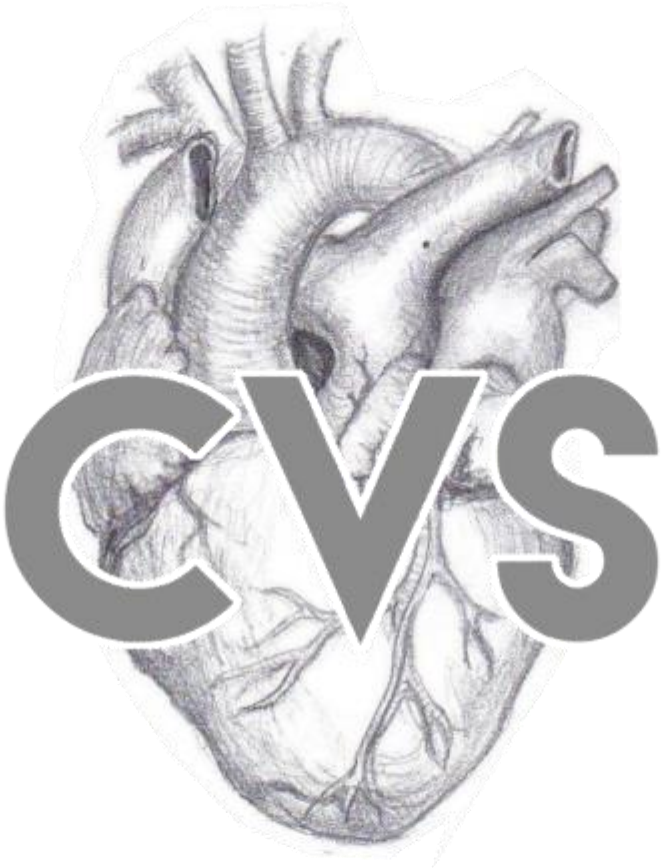

PHYSIOLOGY

☑ Sheet ○ Slide ○ Handout

Number

7

Subject

Normal and Abnormal EKG

Done By

Amer M. Sawalha

Corrected by

Hashim Ahmed

Doctor

Faisal Mohammed

Date: **00/00/2016**

Price:

Review

- QRS interval represents ventricular depolarization.
- Depolarization starts from the interventricular septum.
- Depolarization, from the interventricular septum to the rest of the ventricles, can be represented using vectors.
- These vectors have resultants and these resultants have values on the planes (Lead I, II, and III).
- At the end of depolarization or repolarization, all waves return to the isoelectric line.
- The figure on the right shows the vectors throughout the QRS interval. This can be refered to as a **vectorcardiogram**. A vectorcardiogram traces vectors throughout the cardiac cycle.
- The 4th vector in the figure is a representation of the S wave. If this vector is placed on the axial reference system (on the planes of lead I, II and III), then it would be a negative vector (this is evident on the EKG because the S wave is below the isoelectric line).
- Zero reference point, number 5, is the point of complete depolarization.

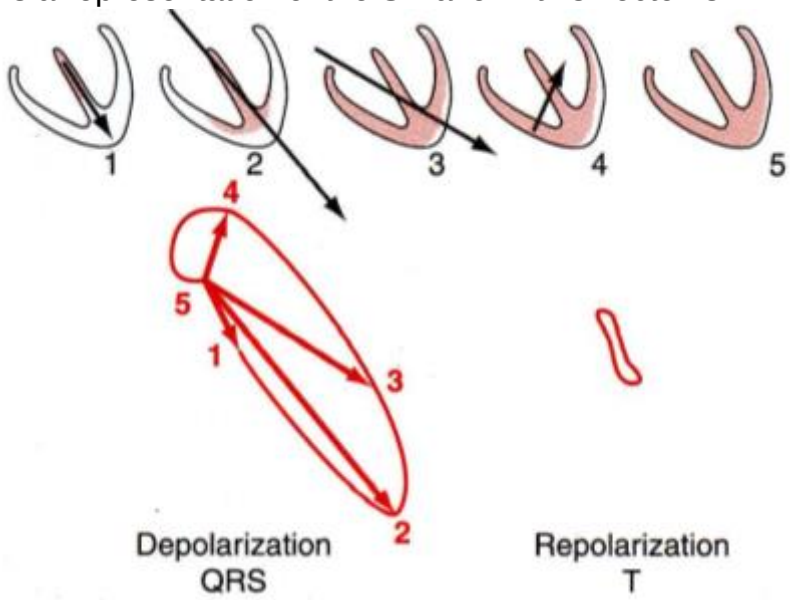

Mean Electrical Axis

- The mean electrical axis has values on the planes of lead I, II, and III.
- The mean electrical axis can be calculated using values on the planes of the leads.
- To determine the mean electrical axis:
  1. Take 2 different leads. The doctor recommends taking leads I and aVF. However, in the following example, leads I and III are used.
  2. Measure the sum of the height and the negative depth of the QRS complex. In the example shown below:
     Sum of QRS of lead I = R+Q = (+16) + (-2.5) = +13.5
     Sum of QRS of lead III = R+S = (+14) + (-5) = +9
     Q was used in lead I because S was not visible. S was used in lead III because Q did not show up on the EKG as shown below.
  3. Use the summations calculated for each of the 2 leads to measure the distance starting from the center of the circle to a certain point on the corresponding axis (move 13.5 mm on lead I from the center of the circle, and move 9 mm on the axis of lead III from the center of the circle).
  4. From the points you reach on the axes, draw perpendicular lines. The intersection of the lines will guide you to the location of the mean electrical axis.
  5. Draw the mean electrical axis line from the center of the circle to the point of intersection.
  6. Use a protractor or trigonometry (tan θ = Opposite/Adjacent) to determine the angle of the mean electrical axis. In the example below, the mean electrical axis is 58º. Physiologically normal values for mean electrical axis range from -30º to 110º.

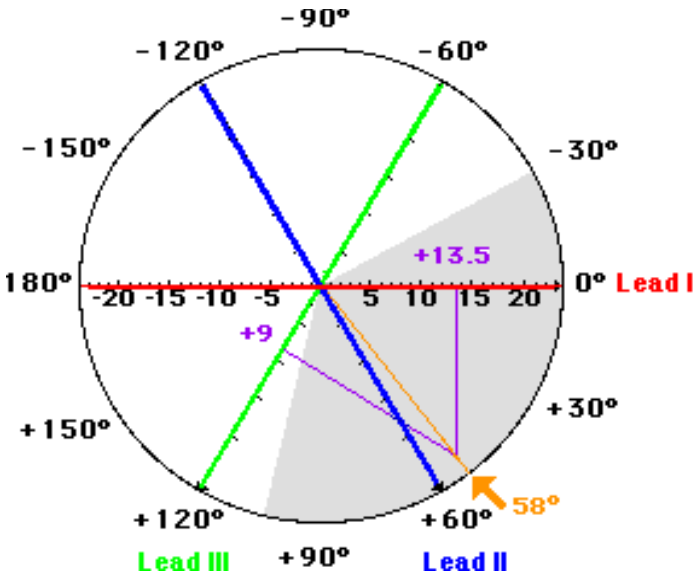

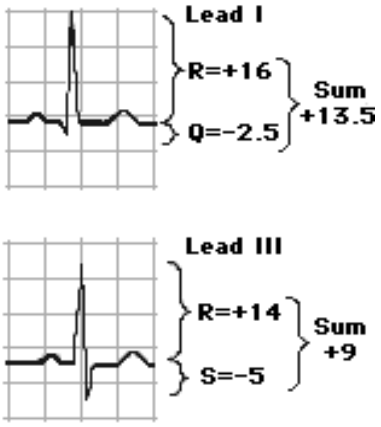

- Why did the doctor recommend using lead I and aVF not lead I and III?
    - tan θ = Opposite/Adjacent
    - **aVF would be the opposite and lead I would be the adjacent in the above equation**.
    - Enter the following into a calculator:
      $\tan^{-1}$ (aVF value / lead I value)
    - The answer would be θ (the angle of the mean electrical axis).
    - The diagram below is a graphical demonstration of the abovementioned.

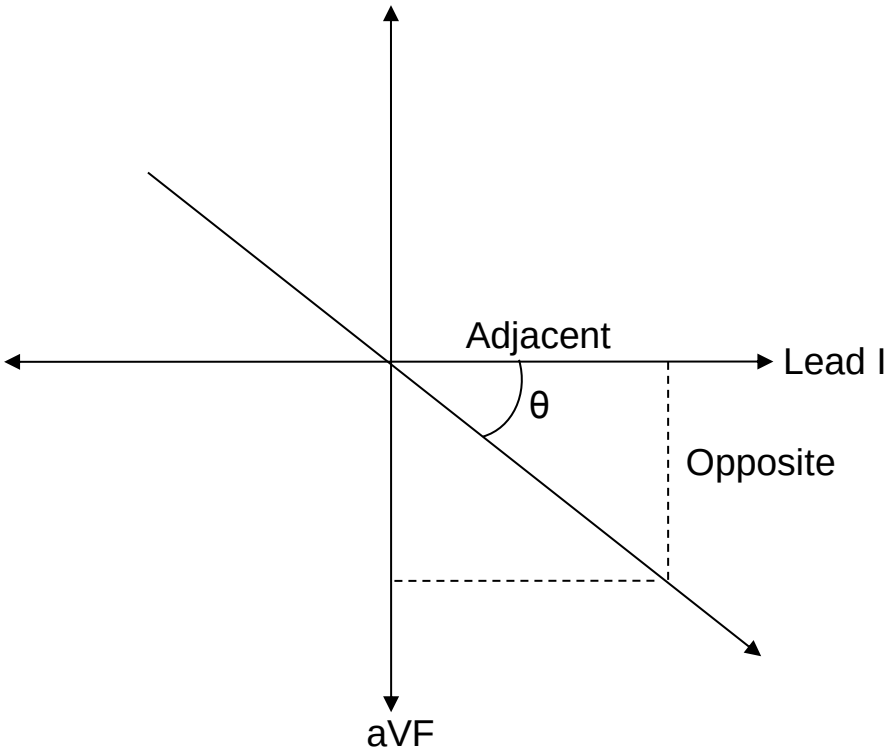

- When both lead I and aVF are positive, the angle of the mean electrical axis is between 0 and +90. This is called **normal mean electrical axis of QRS**.
- When both lead I and aVF are negative, the angle of the mean electrical axis is between -90 and +180 (or from 180 to 270). This is referred to as **severe right or left axis deviation of QRS**. A physician can determine whether it is a severe right or sever left axis deviation from the history of the patient. If the patient has left heart disease, the patient has severe left axis deviation and vice versa.
- When lead I is positive and aVF is negative, the angle of the mean electrical axis is between 0 and -90. This is called **left axis deviation of QRS**.
- When lead I is negative and aVF is positive, the angle of the mean electrical axis is between +90 and +180. This is called **right axis deviation of QRS**.

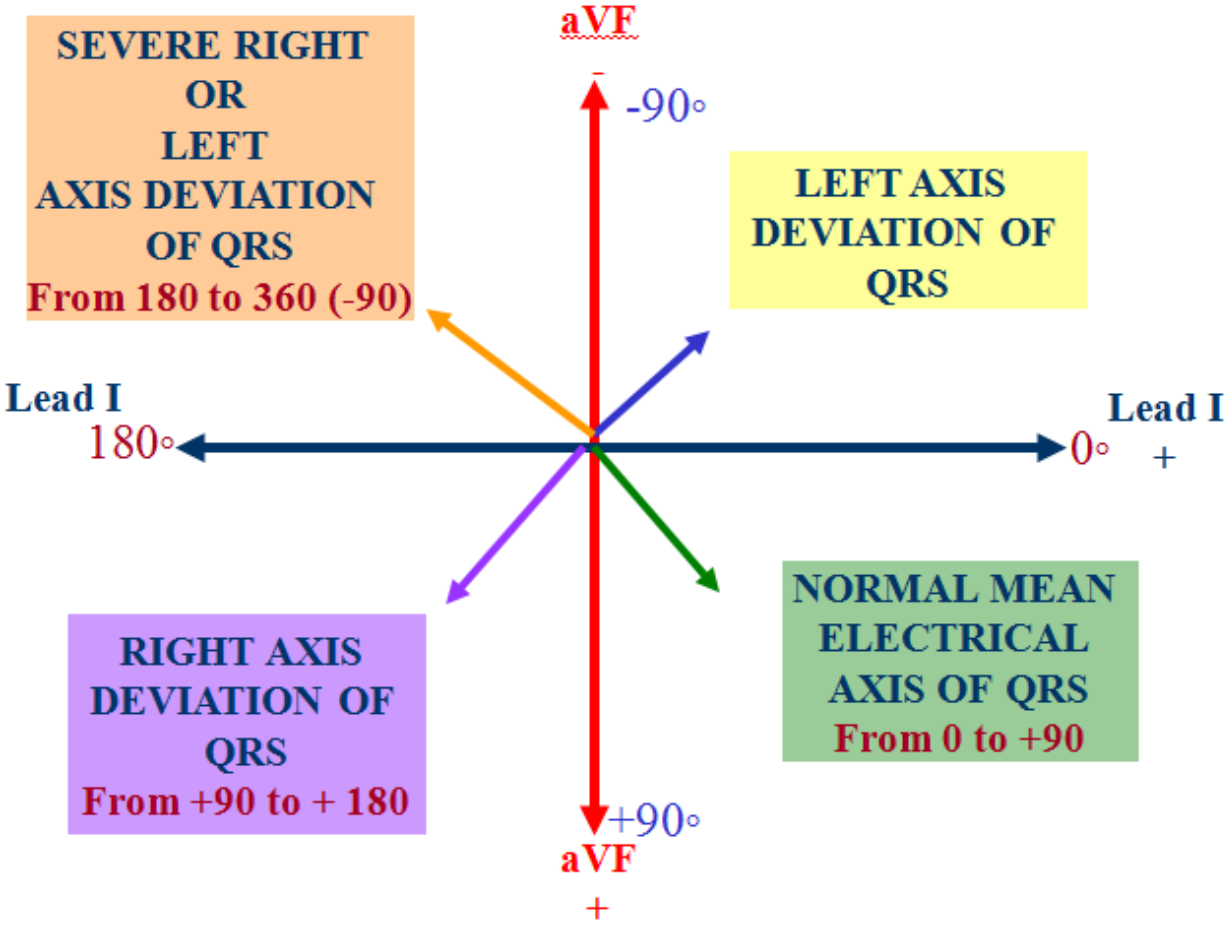

Heart Rate Calculation

- The heart rate can be calculated from the EKG using the **R-R interval**.
- The R-R interval represents **one complete cardiac cycle**.
- The R-R interval is calculated through multiplying the number of small squares on the grid of the EKG between 2 consecutive R waves by 0.04 seconds (which is the value of each small square).
- Suppose the R-R interval was 0.83 seconds, the heart rate would be:

$$\text{Heart Rate} = \frac{60 \text{ seconds per minute}}{0.83 \text{ seconds}} = 72 \text{ beats per minute}$$

***Remember**:*

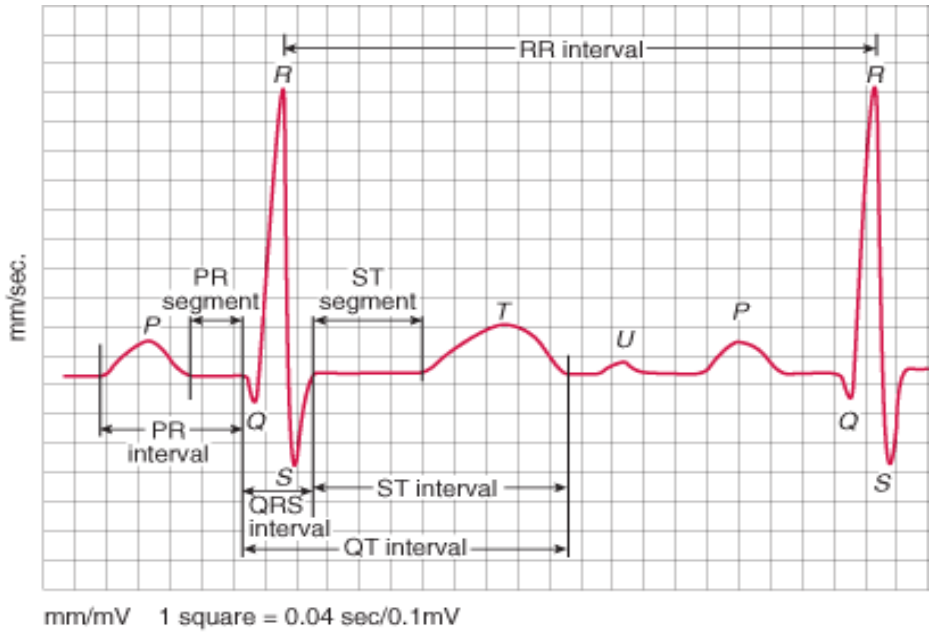

- ✓ PR interval is usually 0.16 seconds and it should not exceed 0.2 seconds.
- ✓ QRS interval should not exceed 0.12 seconds.
- ✓ QT interval is usually 0.35 seconds and it should not exceed 0.4 seconds. It is variable and usually half of the R-R interval.
- ✓ The P wave immediately precedes atrial contraction.
- ✓ The QRS complex immediately precedes ventricular contraction.
- ✓ If the PR or ST segments are deflected upward or downward, it means that there is ischemia (or an infraction).
- ✓ Every 5 small squares equal 0.2 seconds.
- ✓ The speed of the EKG machine is 25 mm/seconds.
- ✓ Sometimes the machine is overclocked (sped up) to 50 mm/seconds for cases of tachycardia to make measurement of the intervals easier.
- ✓ If a patient, for example, has an abnormality in the posterior aspect of the heart, then an esophageal lead is needed.

Determining Regularity

- Determining regularity of the EKG does not require much effort or tools.
- Simply mark the peak of the first and second R waves using a pen and paper and check if the other R-R intervals are equidistant.
- A caliper can also be used to determine regularity.
- A regular EKG would have equal distances between consecutive R waves.
- Other classifications include: occasionally irregular, regularly irregular, and irregularly irregular.

EKG Abnormalities

- Causes of the **cardiac arrhythmias** include:
  1. **Abnormal rhythm** of the pacemaker.
  2. **Shift of pacemaker** from sinus node.
  3. **Blocks** at different points in the transmission of the cardiac impulse.
  4. **Abnormal pathways** of transmission in the heart.
  5. Spontaneous generation of abnormal impulses from any part of the heart (**ectopic pacemaker**).

Abnormal Rhythm of the Pacemaker

- Abnormal rhythm of the pacemaker means either bradycardia or tachycardia.
- **Bradycardia** means slow heart rate which is **less than 60 beats/min**.
- **Tachycardia** means fast heart rate which is **more than 100 beats/min**.
- An EKG for a typical case of tachycardia (shown below) graphically demonstrates the shortened R-R intervals. <u>R-R intervals are less than 0.6 seconds</u>.

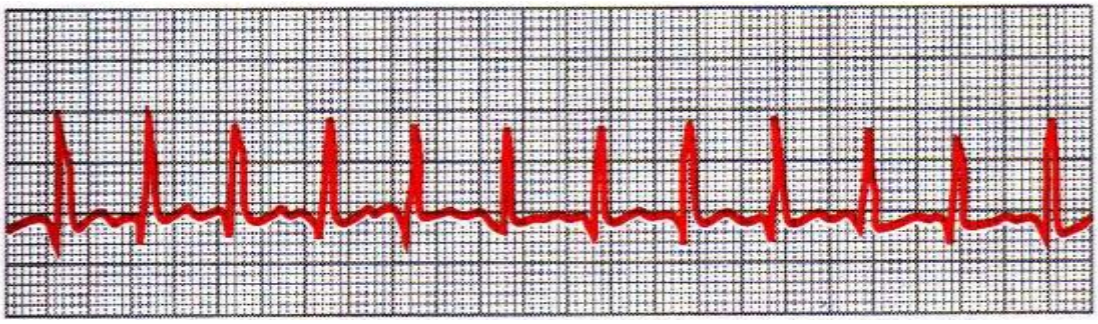

- **Tachycardia** is caused by:
  1. Increased body temperature.
  2. Sympathetic stimulation (positive chronotropic effect).
  3. Toxic conditions of the heart.
- **Sinus tachycardia** means that the electrical impulses are coming from the SA node. If there is no SA node, no impulses will be transmitted to the atria and consequently there will be no P wave.

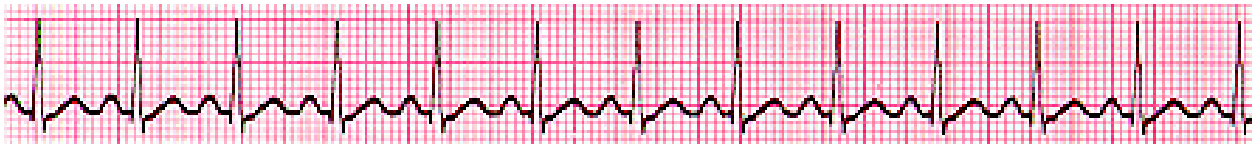

- SA node is depolarizing faster than normal, impulse is conducted normally.
- Sinus tachycardia is a response to physical or psychological stress, not a primary arrhythmia.
- **Bradycardia** is usually present in athletes with a large stroke volume because they have hypertrophic ventricles. This is normal.
- **Bradycardia** can be caused by vagal stimulation, one example of which is the carotid sinus syndrome.
- When the R-R interval is more than 1 second, then there is bradycardia.

- In **sinus bradycardia**, the SA node is depolarizing the atria slower than normal, impulse is conducted normally (i.e. normal PR and QRS interval) and the rate is slower than 60 beats per minute.

Blocks at Different Points in the Transmission of the Cardiac Impulse

(a) Sinus rhythm (normal)

(b) Nodal rhythm – no SA node activity

- The absence of the P wave in the above EKG indicates that there might be a SA node block (rare) or atrial fibrillation.
- **Atrial fibrillation** is when the muscle fibers of the atria DO NOT contract at the same time.
- Unlike ventricular fibrillation which could be fatal, atrial fibrillation does nothing and it could be found in healthy people because atrial contraction is not essential for the normal cardiac cycle.
- New pacemaker is found in the region of the heart with the fastest discharge rate, usually the A-V node.
- AV node block prevents the normal conduction of the AV node. This abnormality could be partial or complete. Partial means that the AV node sometimes conducts the impulse from the atria but not always.
- PR interval is longer than 0.2 seconds when the AV node is blocked.
- If every P wave is followed by QRS interval and the PR interval is longer than 0.2 seconds, then this is a **first degree AV block**. P-R interval seldom increases above 0.35 to 0.45 seconds.
- In the **second degree AV block**, the PR interval is longer than 0.2 seconds but not all P waves are followed by QRS interval. There are 2 types of second degree AV blocks.

- Second degree AV blocks show a regular irregularity. This means that following a certain number of P waves, there has to be a specific number of QRS intervals. The number of P waves preceding the successive QRS intervals is always higher. For example, patient X's EKG shows that there are 4 P waves before every 3 QRS intervals, while patient Y's EKG shows that there are 3 P waves before every 2 QRS intervals.
- In the **third degree AV block**, the AV node is completely destroyed. The heart rate is actually coming from the purkinje fibers. **Heart rate is less than 40** (it is between 15-40). The ectopic pacemakers are the purkinje fibers in this case.
- Unlike second degree AV blocks which have a regular irregularity, third degree AV block shows no relationship between the P waves and the QRS interval.
- The first and second degree AV blocks are called incomplete heart blocks while the third degree AV blocks is called a complete heart block.

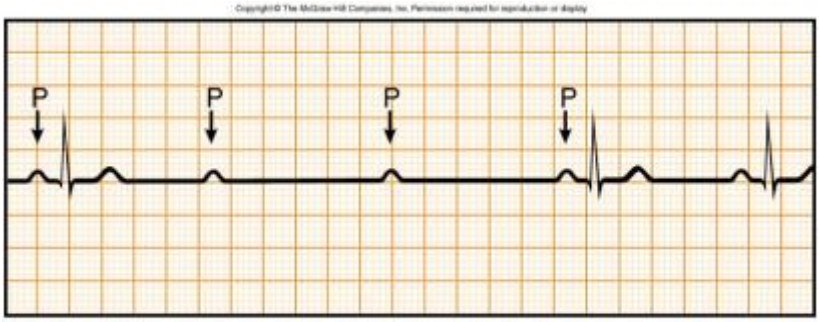

(c) Heart block

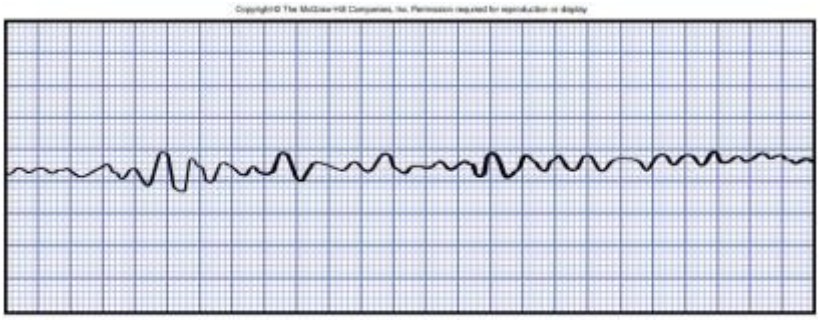
(e) Ventricular fibrillation

- **Ventricular fibrillation** is fatal. No P,Q,R,S,T waves are evident on the EKG (shown above).
- **Ventricular fibrillation** is an emergency. The first intervention would be defibrillation using a defibrillator to retrieve the normal sinus rhythm.

- Impulses through A-V node and A-V bundle (bundle of His) are slowed down or blocked due to :
  1. **Ischemia** of AV node or AV bundle fibers (can be caused by coronary ischemia)
  2. **Compression** of AV bundle (by scar tissue or calcified tissue)
  3. AV nodal or AV bundle **inflammation**
  4. **Excessive vagal stimulation**

EKGs of Different Degrees of Heart Blocks

1st Degree AV Block

2nd Degree AV Block

3rd Degree AV Block

Stokes Adam Syndrome

- Complete A-V block comes and goes.
- Ventricles stop contracting for 5-30 sec because of <u>overdrive suppression</u> meaning they are used to atrial drive.
- Patient faints because of poor cerebral blood flow.
- Then, ventricular escape occurs with A-V nodal or A-V bundle rhythm (15-40 beats /min).
- Artificial pacemakers connected to right ventricle are provided for these patients.

Factors Causing Electrical Axis Deviation

- **Left ventricular hypertrophy** causes **left axis deviation**. Hypertrophy of the left ventricle signifies that the right ventricle reaches complete depolarization before the left ventricle. In this case, the vectors will be pointed to the left. Hypertrophy of the left ventricle is caused by hypertension, aortic stenosis or aortic regurgitation. The result is a slightly prolonged QRS and high voltage.
- **Left bundle branch block** also causes **left axis deviation**. The left bundle branch moves the impulse from the AV node to AV bundle to the left ventricle. Should this left bundle branch be blocked, the left ventricle will depolarize through the ventricular muscles. Depolarization through the ventricular muscles (by gap junctions) is very slow (0.5 meters/sec). Depolarization through the purkinje fibers is 4 meters/sec.
- **Left axis deviation** also occurs in short and obese people. It might be normal since it would not be less than -30°.
- Changes in heart position due by expiration and lying down cause **left axis deviation**.
- **Right axis deviation** occurs in tall and thin people.
- **Right ventricular hypertrophy** and **right bundle branch block** cause **right axis deviation.** Hypertrophy of the right ventricle is caused by pulmonary hypertension, pulmonary valve stenosis, or interventricular septal defect. All of them cause slightly prolonged QRS and high voltage.
- In both bundle branch blocks, QRS complex is prolonged.

Good luck!