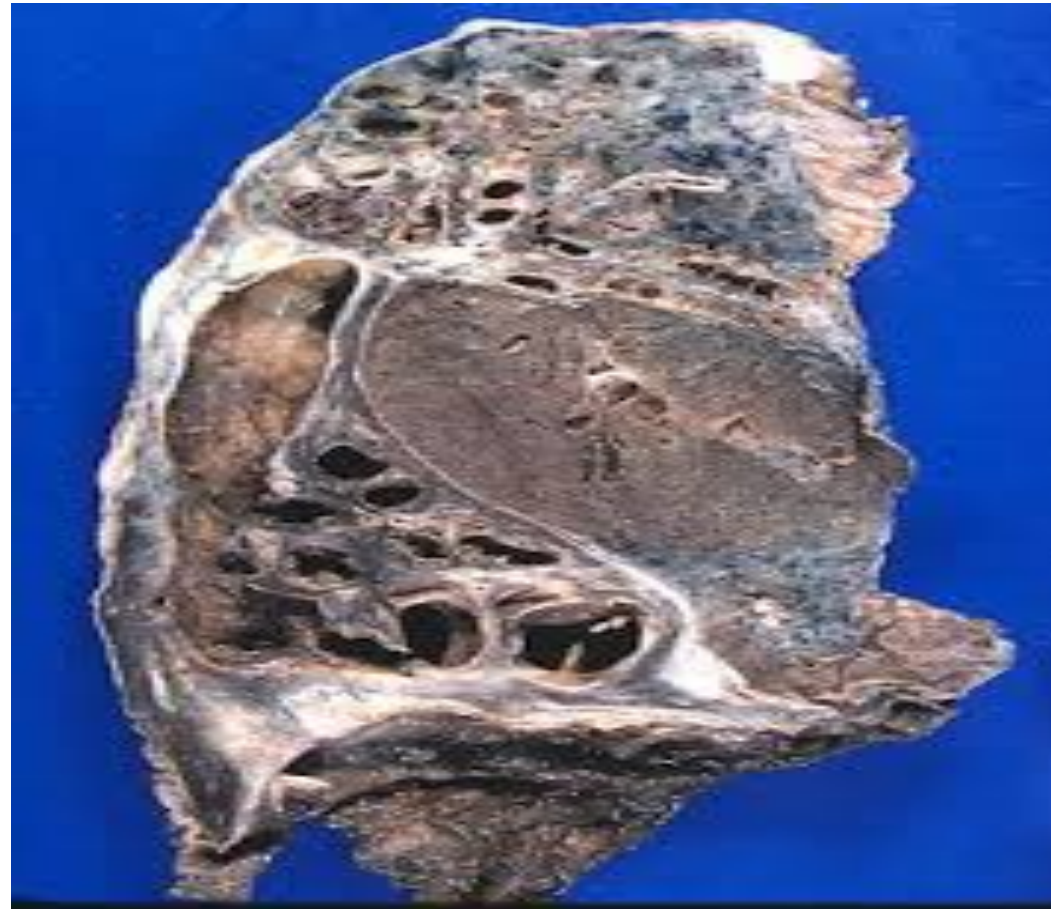

Diseases of the respiratory system pics 3&4

Dr H Awad

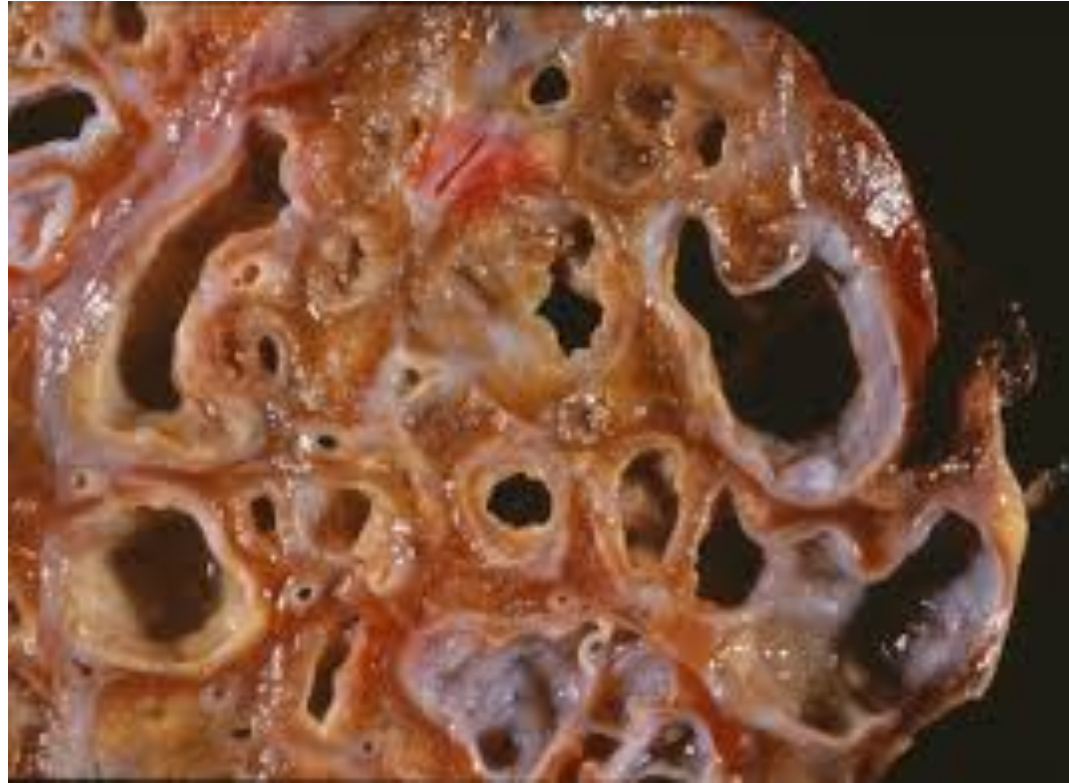Bronchiectasis



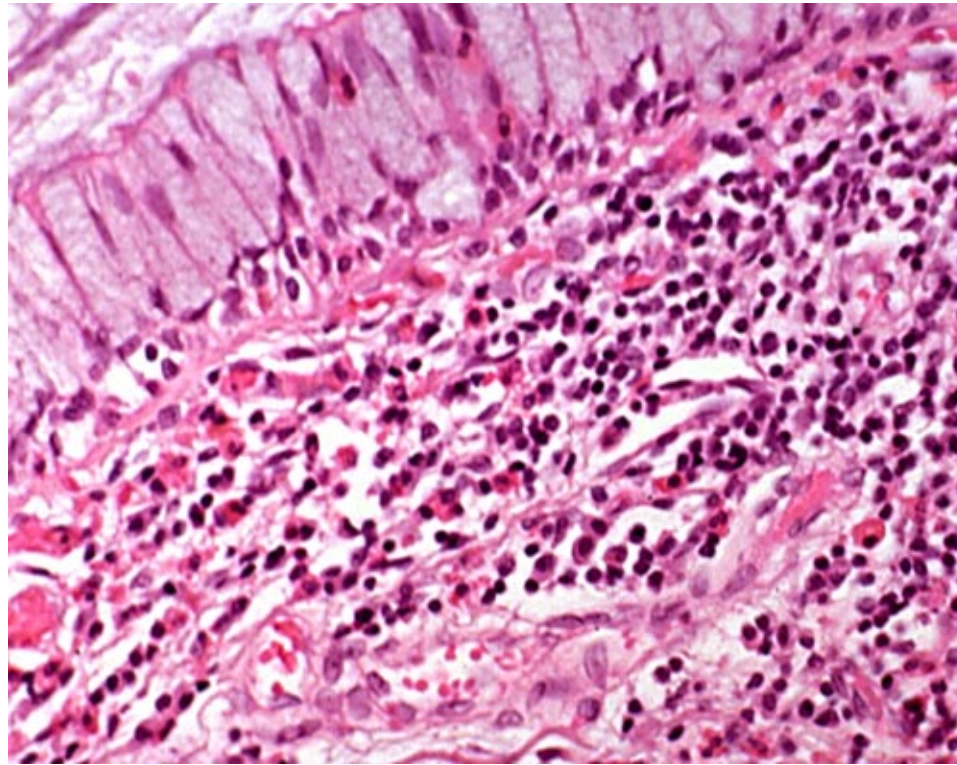
Bronchiectasis



Bronchiectasis

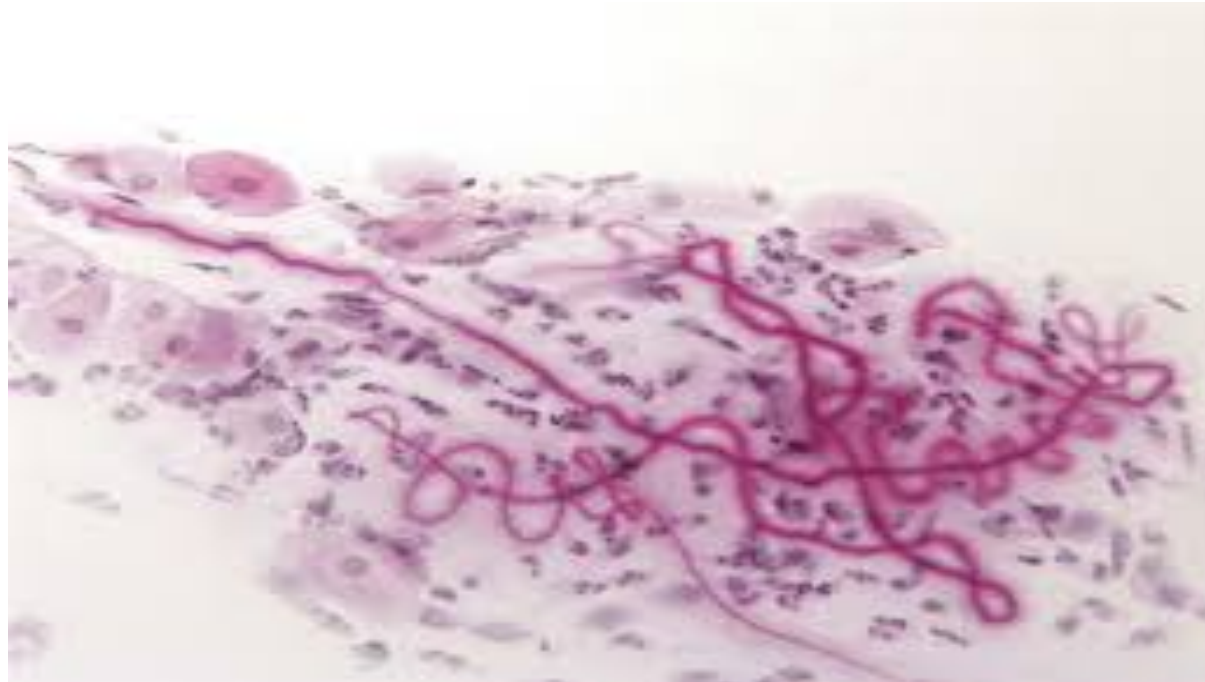

Bronchial asthma.. Note the large amount of eosinophils

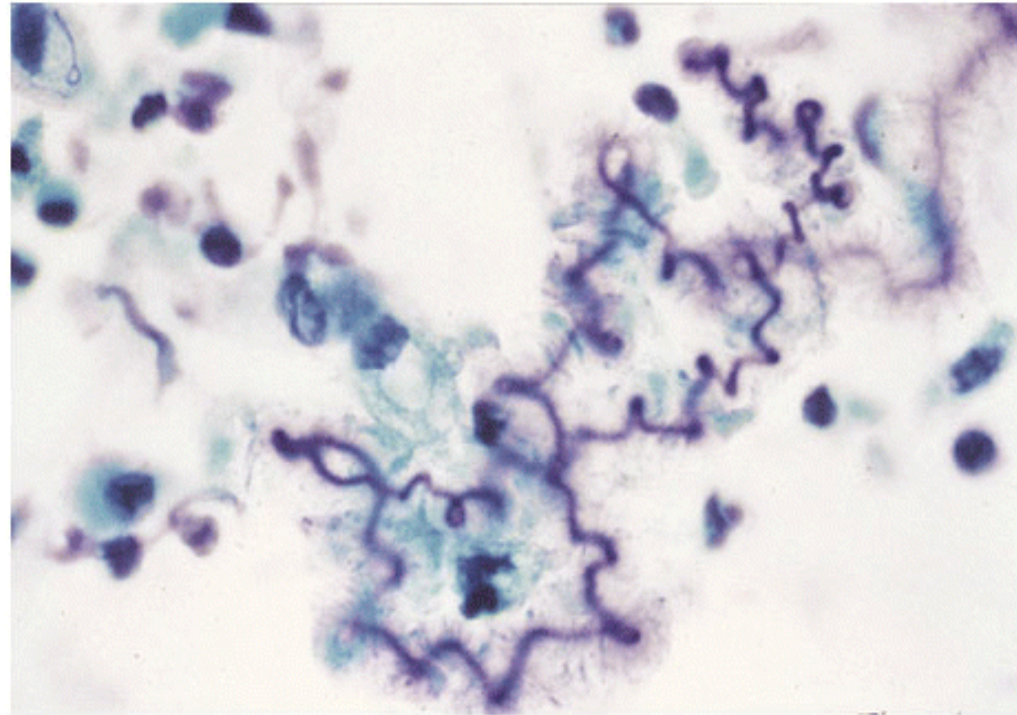


Bronchial asthma

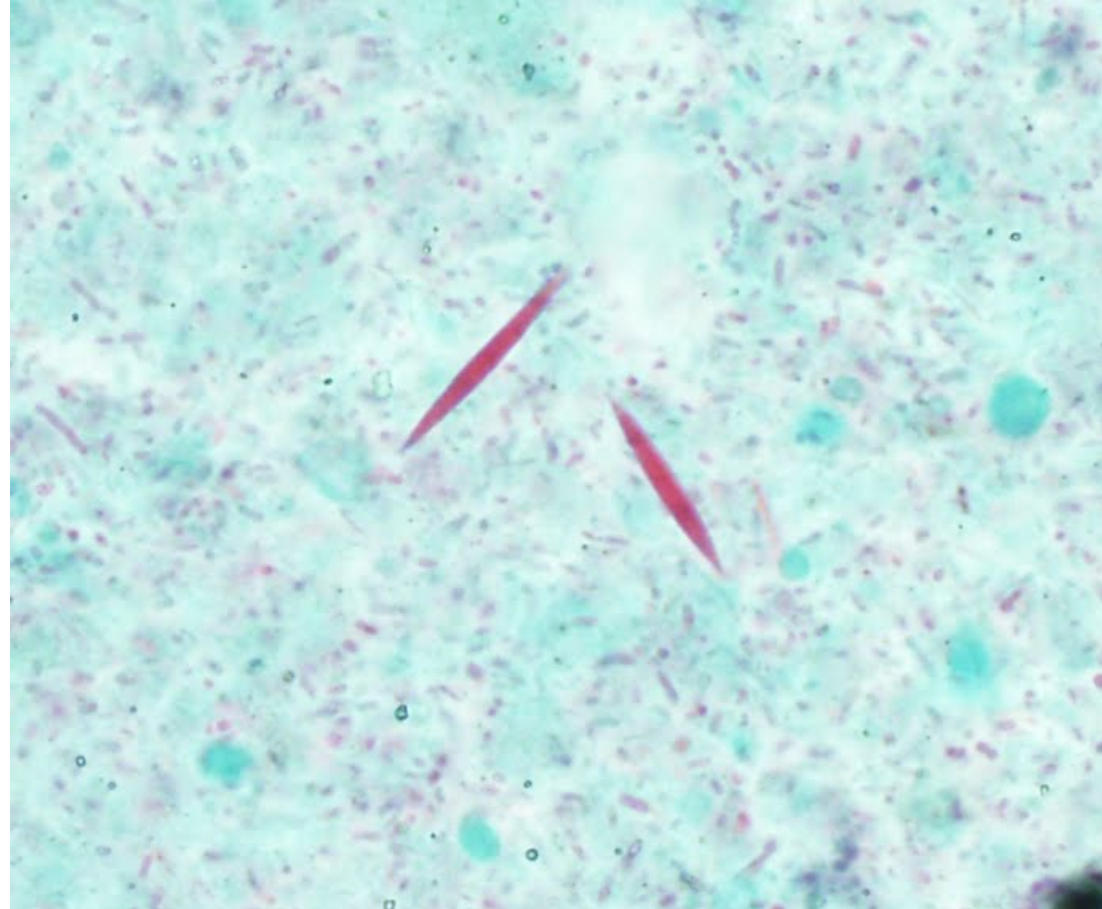
- Curshmann spirals are mucous plugs containing whorls of shed epithelium



Curshmann spirals



Charcot –Leyden crystals: crystals made up of eosinophil proteins



Airway remodeling in asthma

