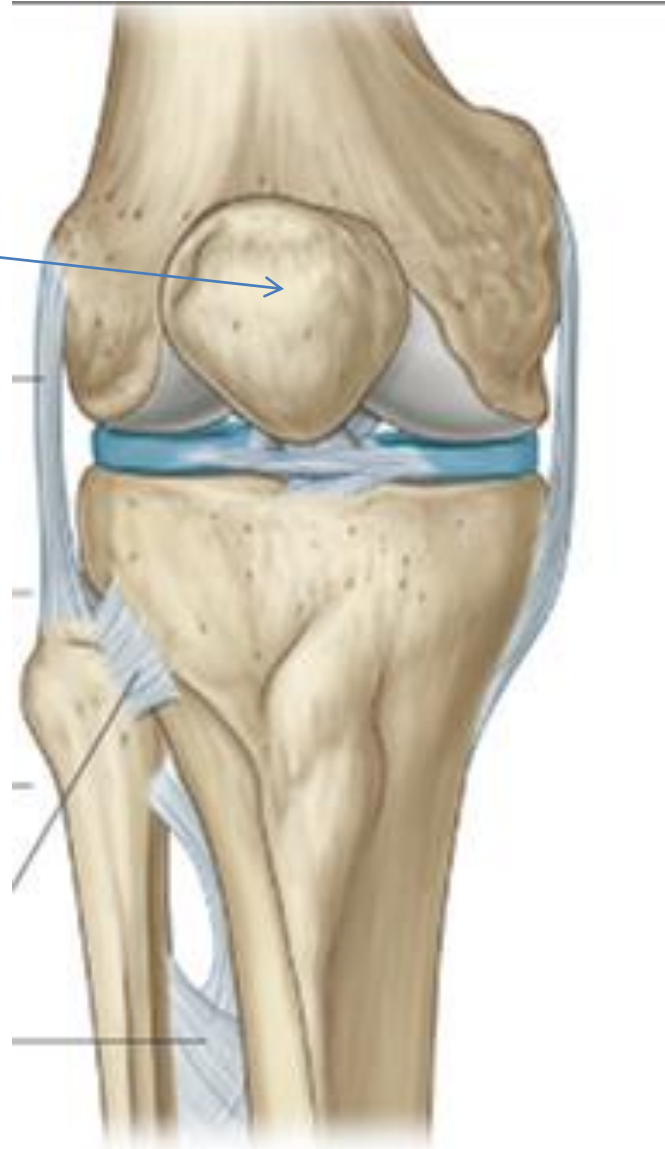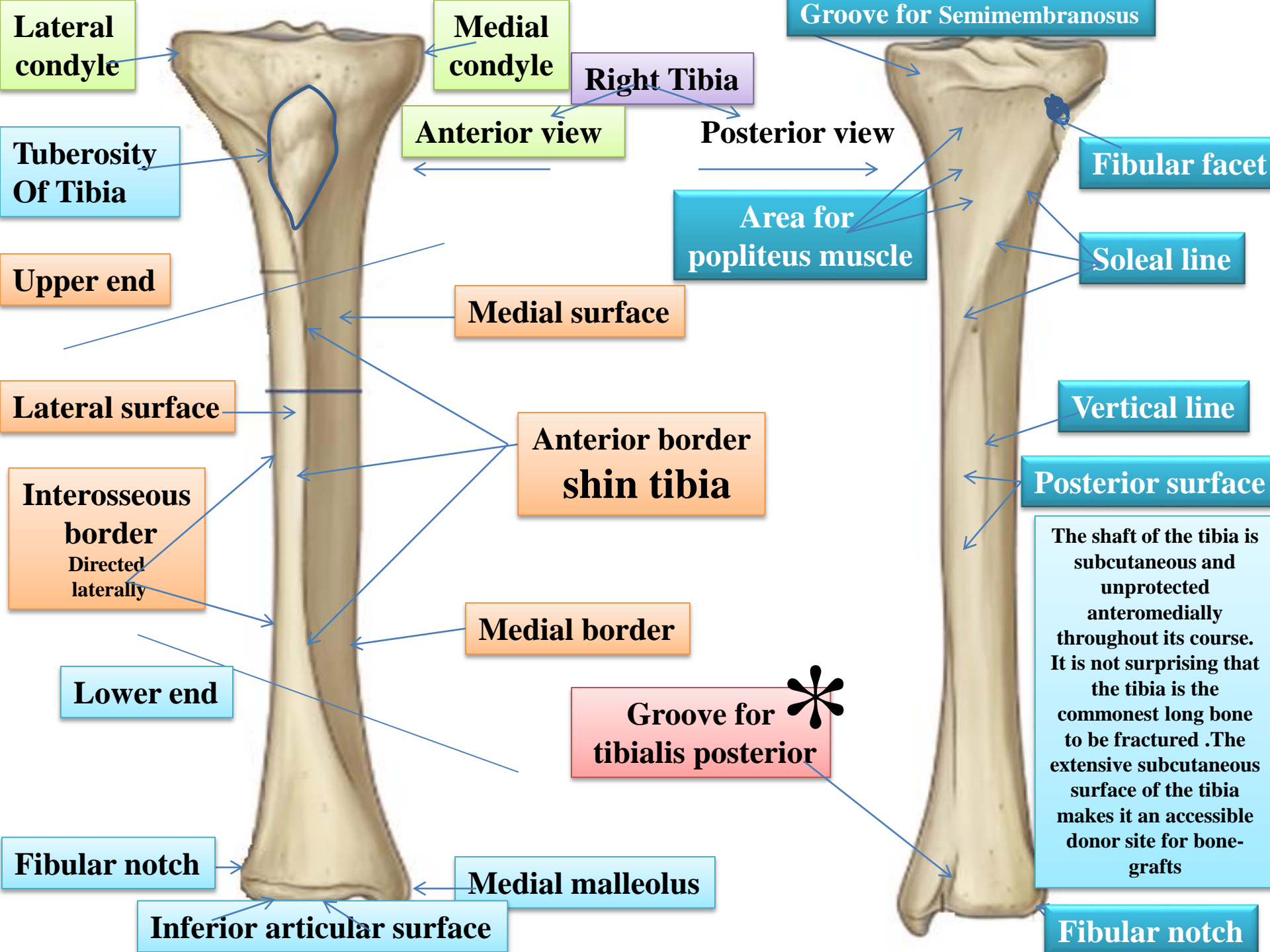


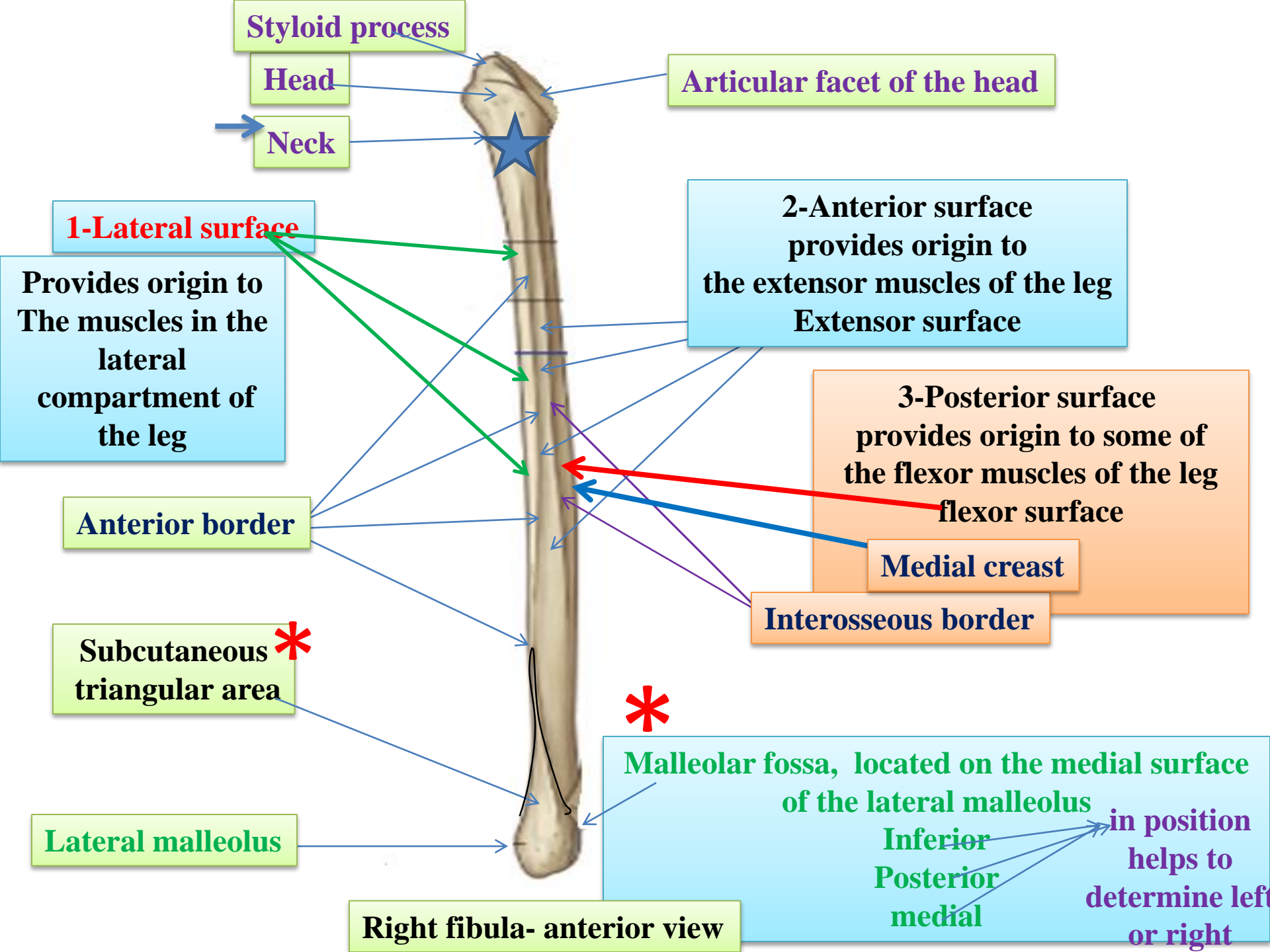
Patella

Triangular sesamoid bone

Contained within patellar ligament



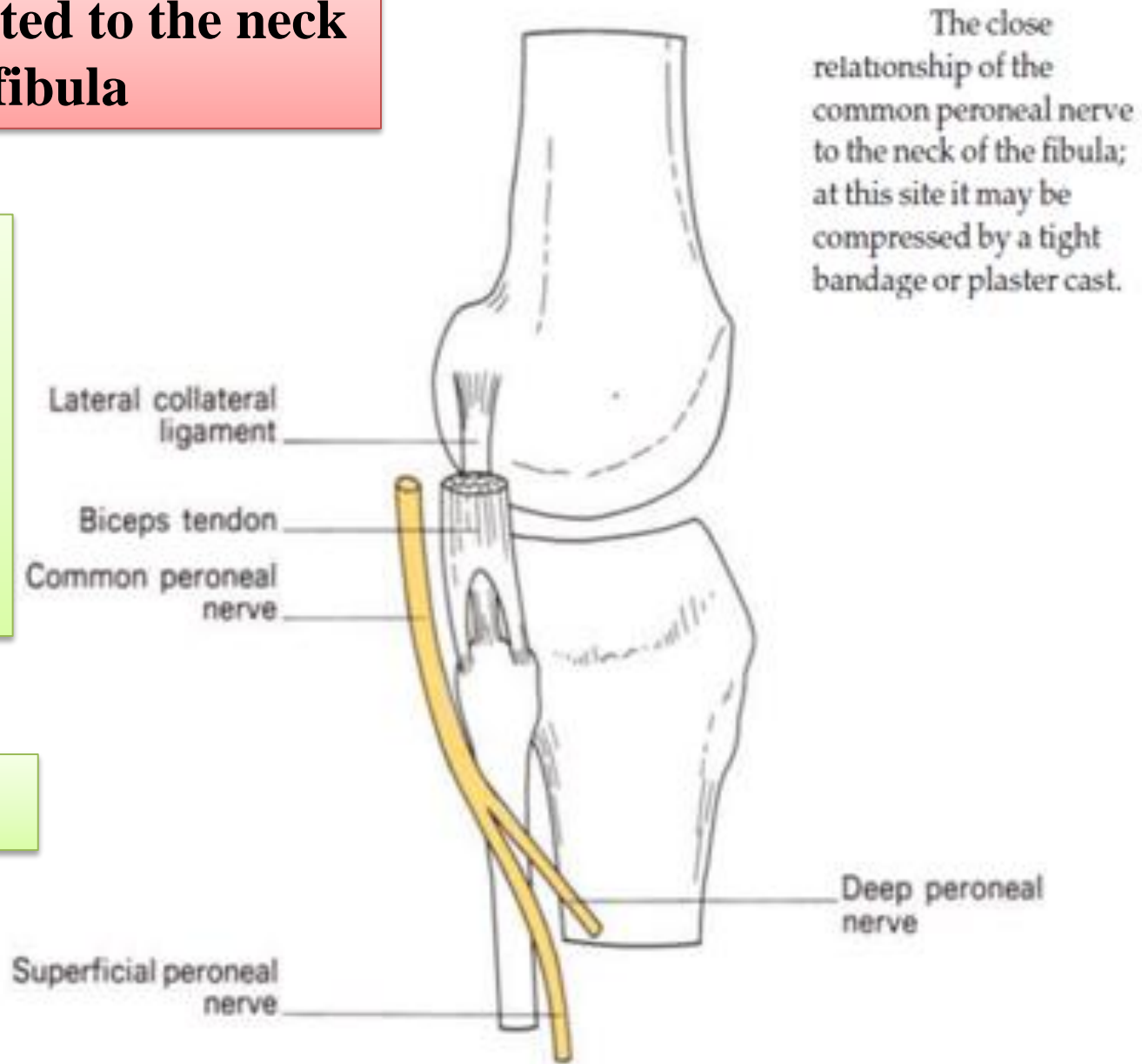


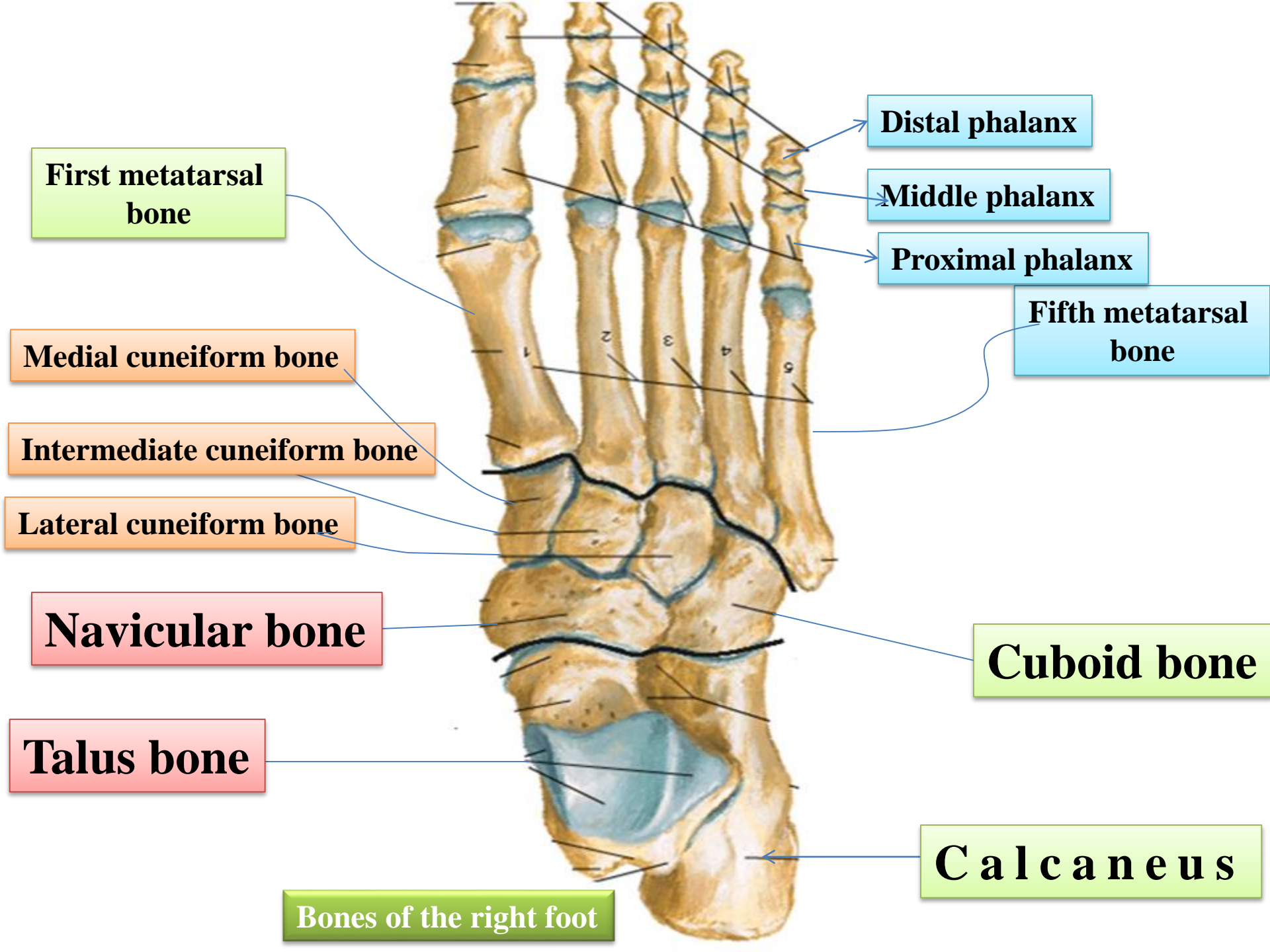


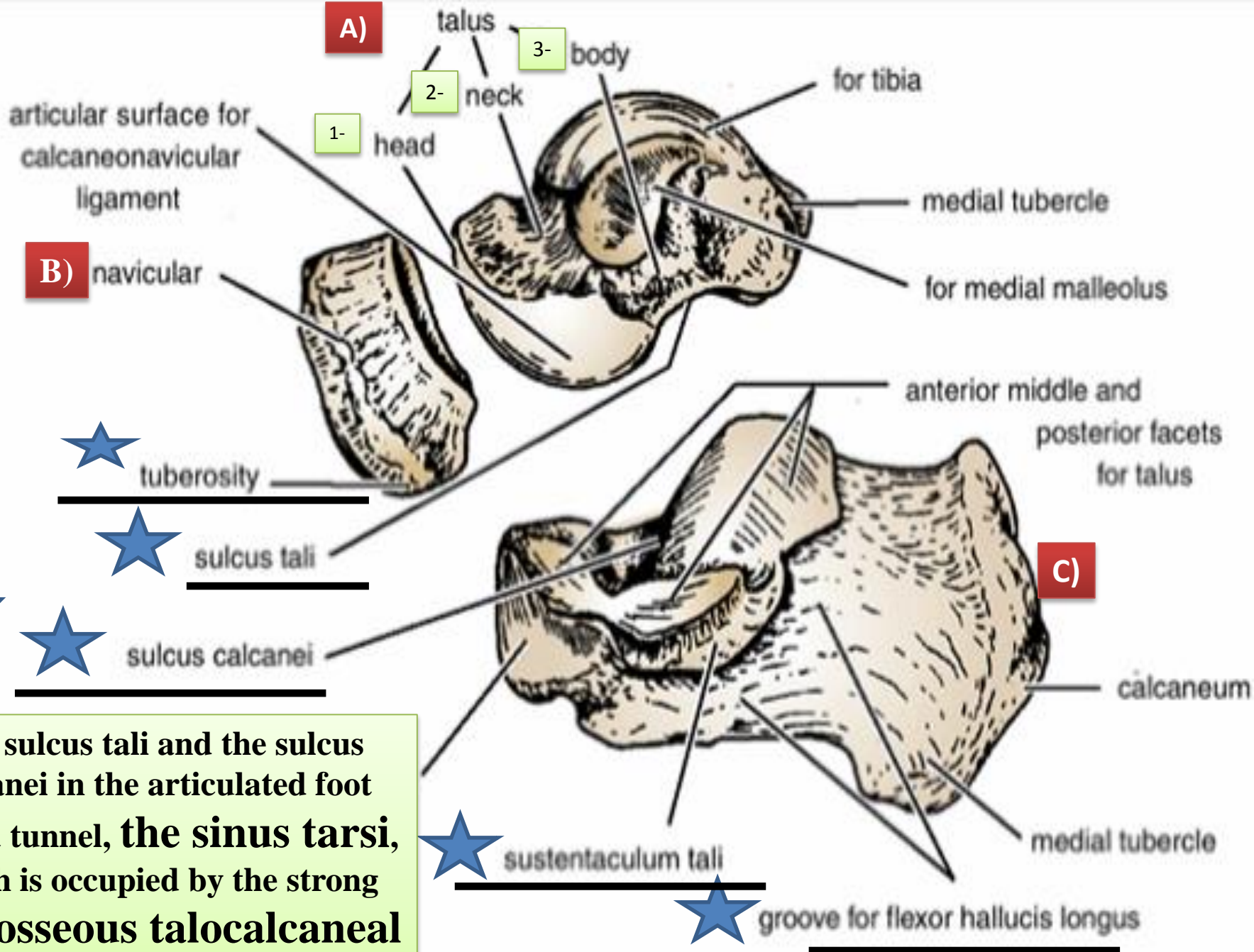
The common peroneal nerve is related to the neck of fibula

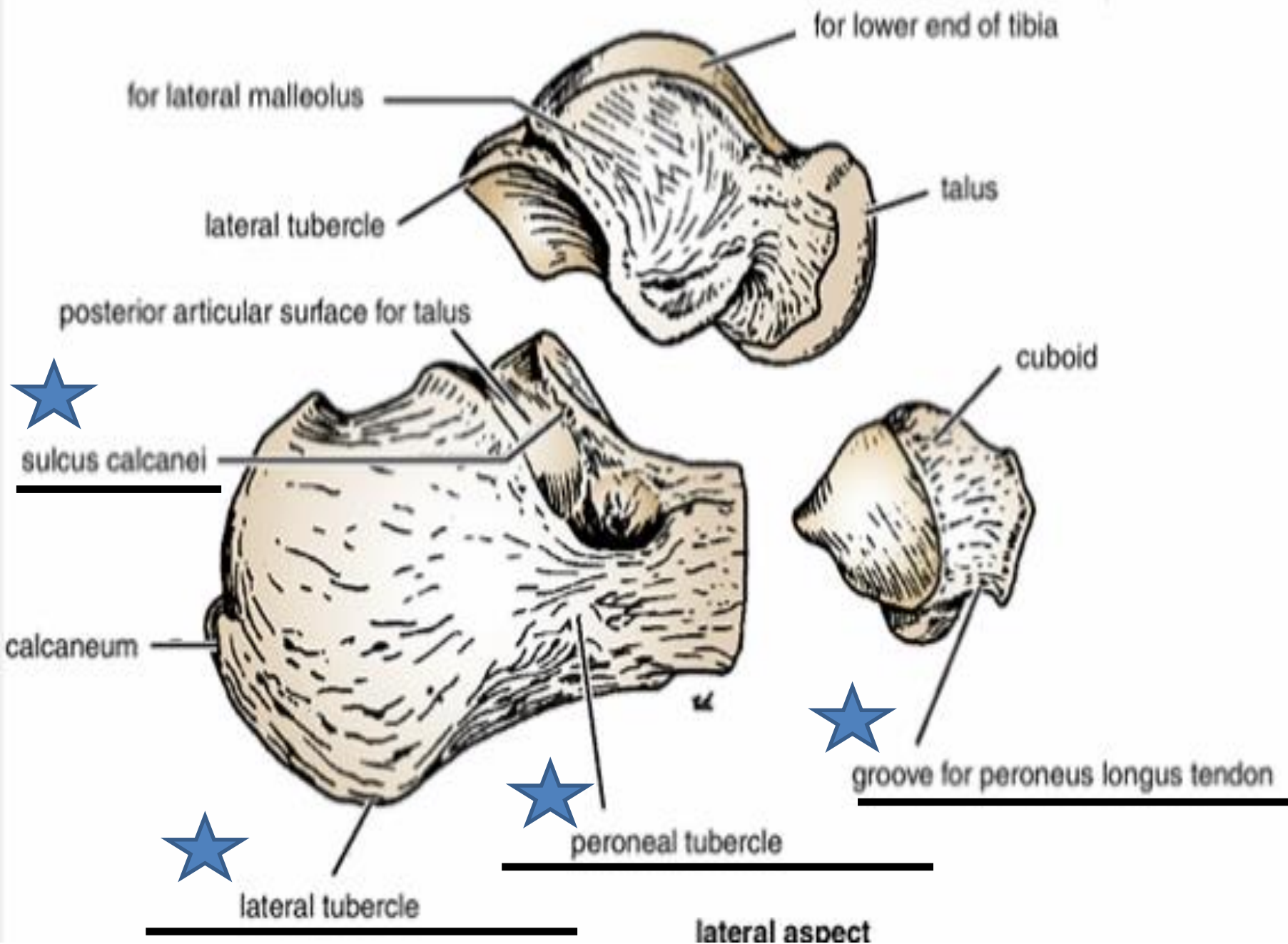
The common peroneal nerve in this area is covered by skin and fascia only therefore it is exposed to injuries

Foot drop





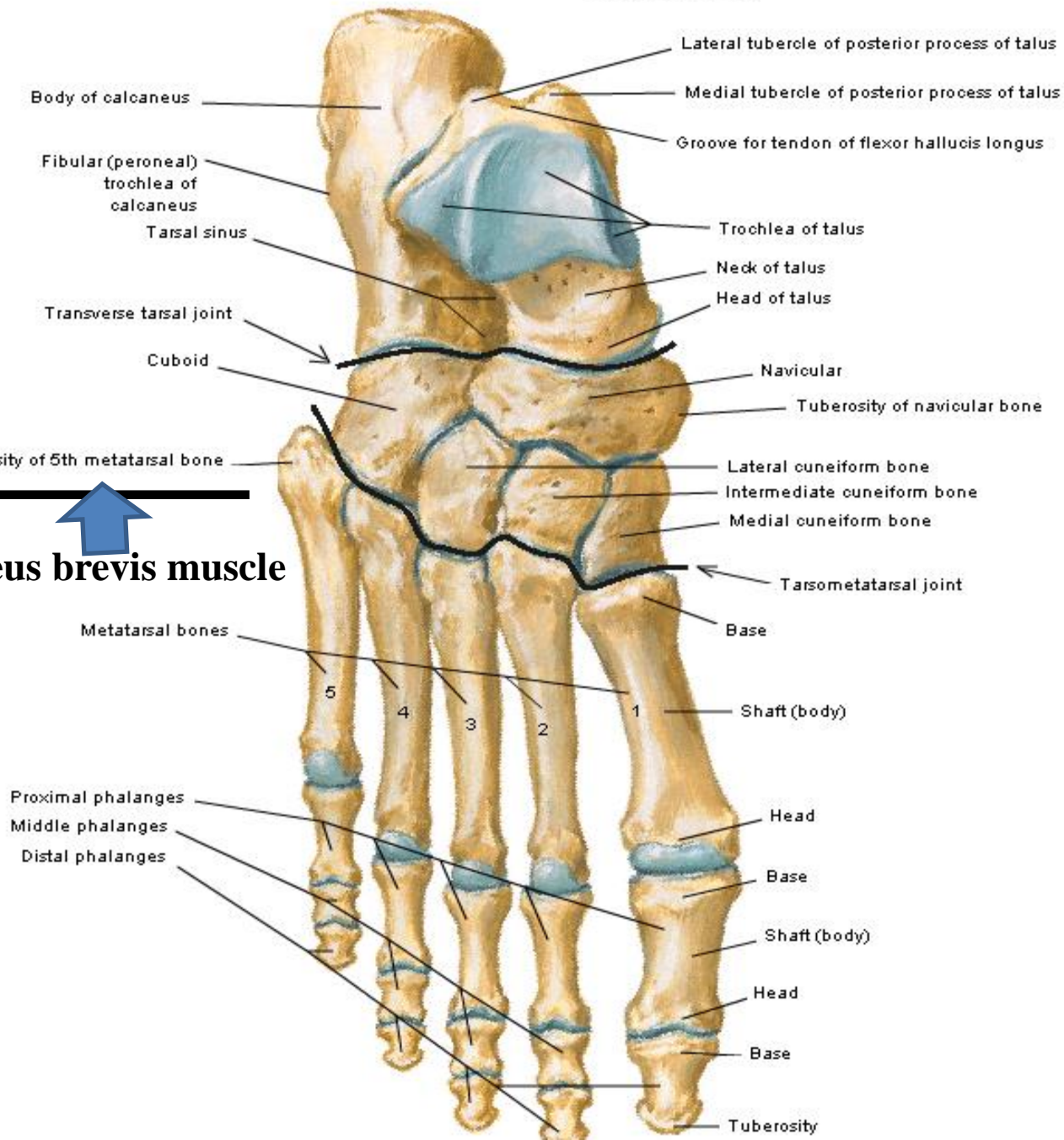




Bones of Foot

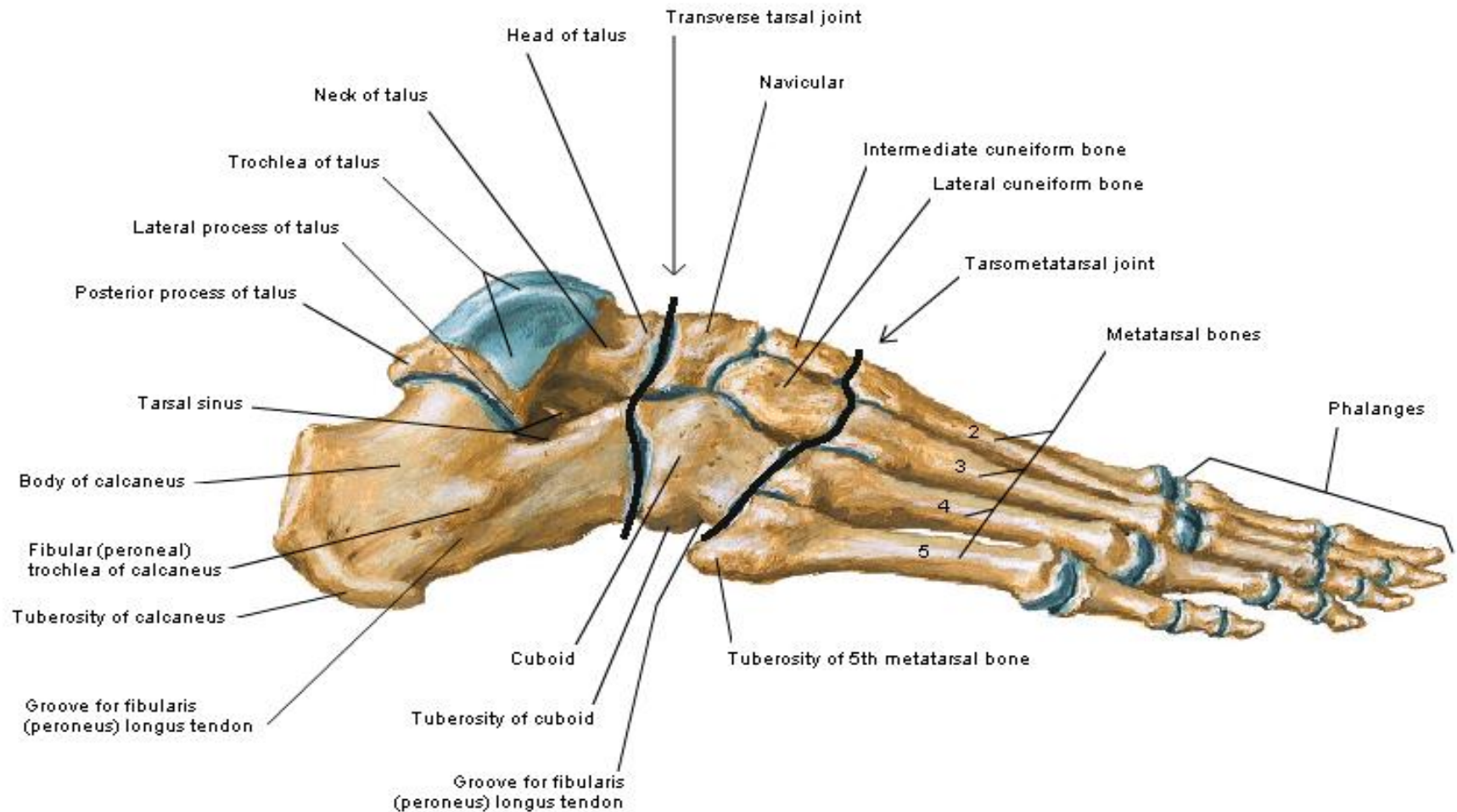
Dorsal View

Insertion of peroneus brevis muscle



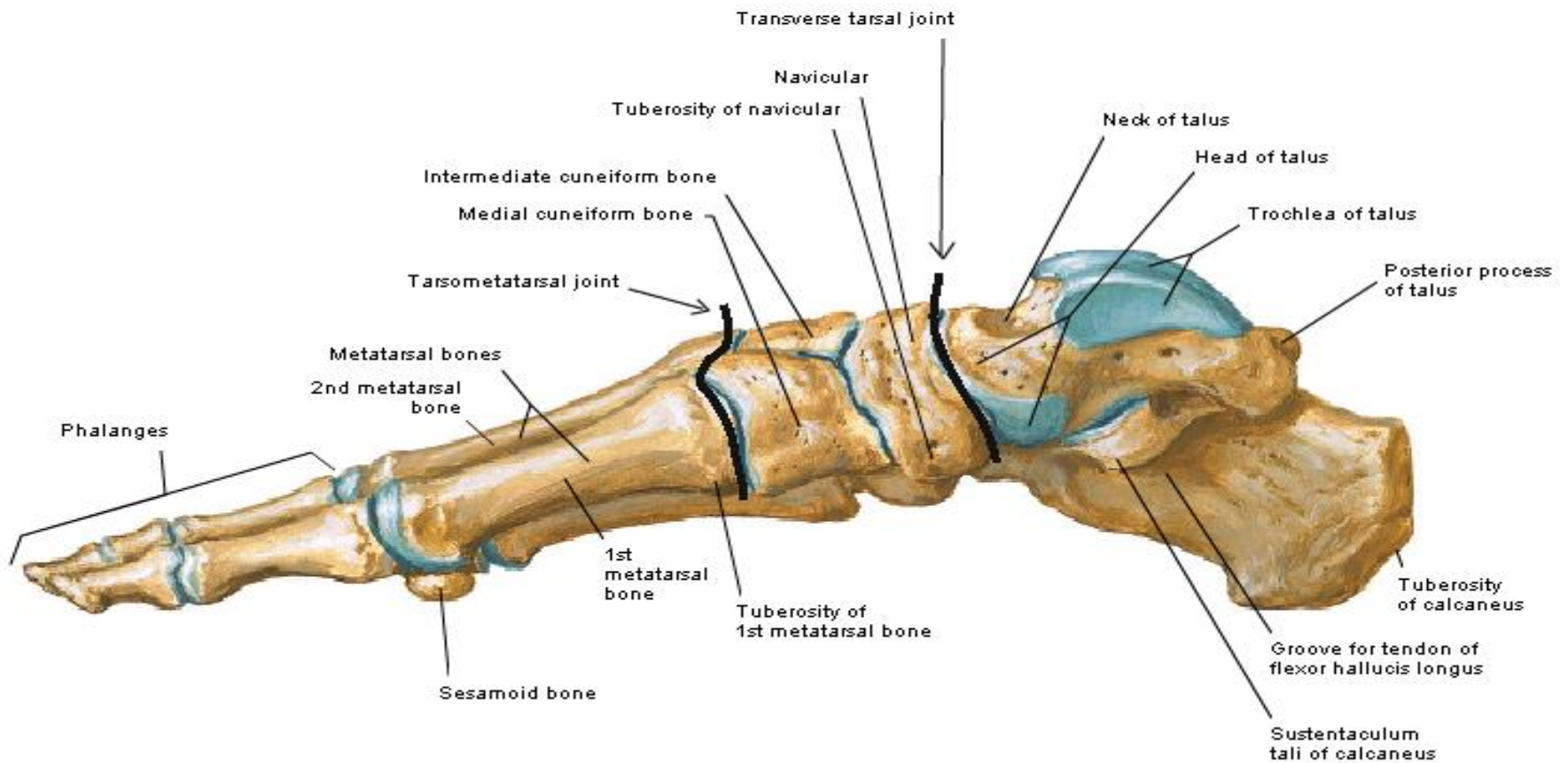
Bones of Foot

Lateral View



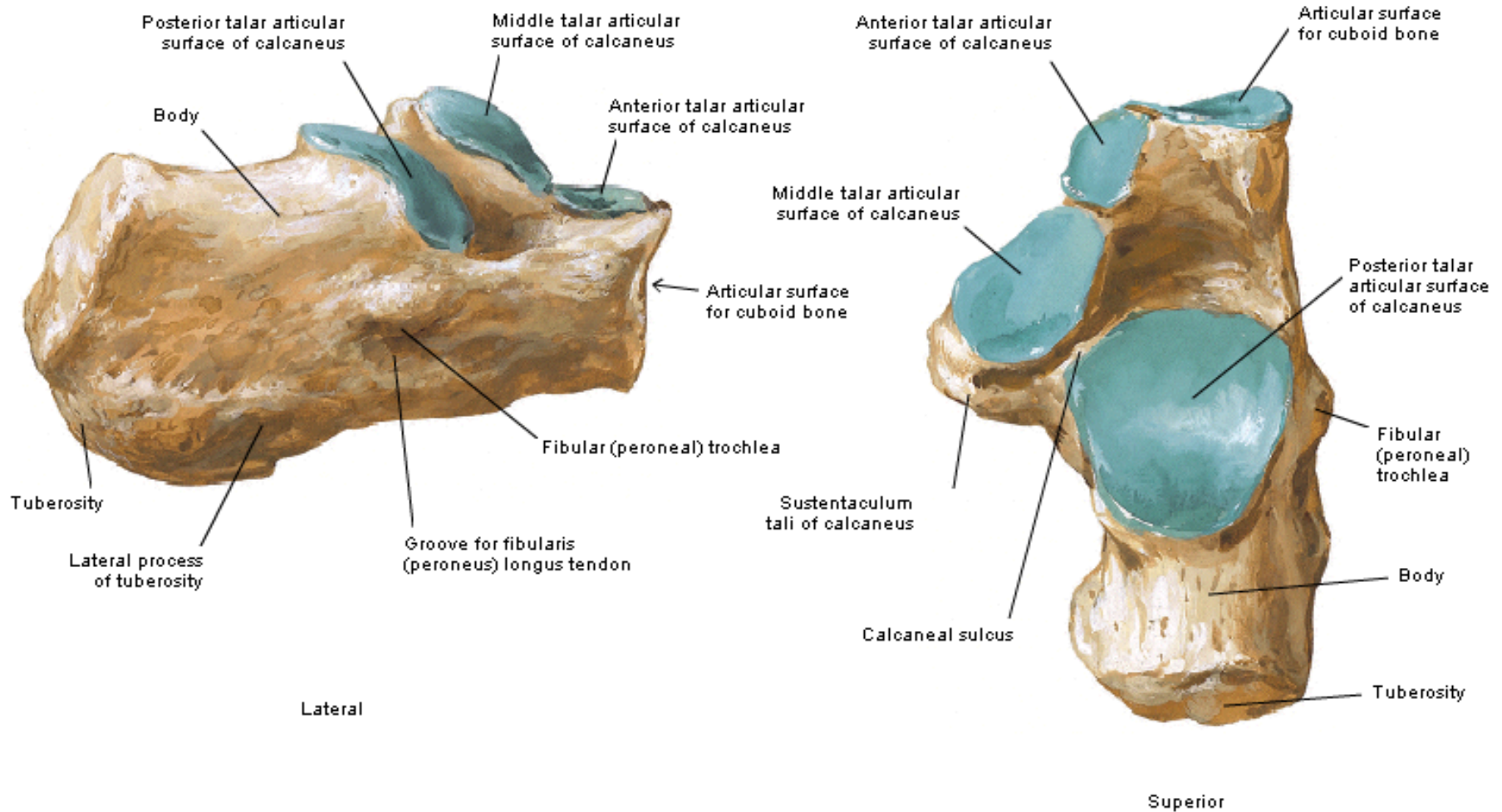
Bones of Foot

Medial View



Calcaneus of Right Foot

Lateral and Superior Views



Calcaneus of Right Foot

Medial and Posterior Views

