Renal System Histology

Professor: Faraj Bustami
Notes by: Hashim A. Mohammad

- These notes are written according to the recording of section 3.

- Contents:
1- Histology of the renal cortex and medulla.
2- Histology of the ureter.
3- Histology of the urinary bladder.

ملاحظة: عادة ما يسأل د. فرج عن أحد الشرائح المشروحة هنا، ويطلب إما الجمل الصحيحة أو الخاطئة عن القطاع الهستولوجي المشار إليه، باستخدام أسلوب أ+ب أو ليست أ+ليست ب.

The Kidney

Cortex of kidney

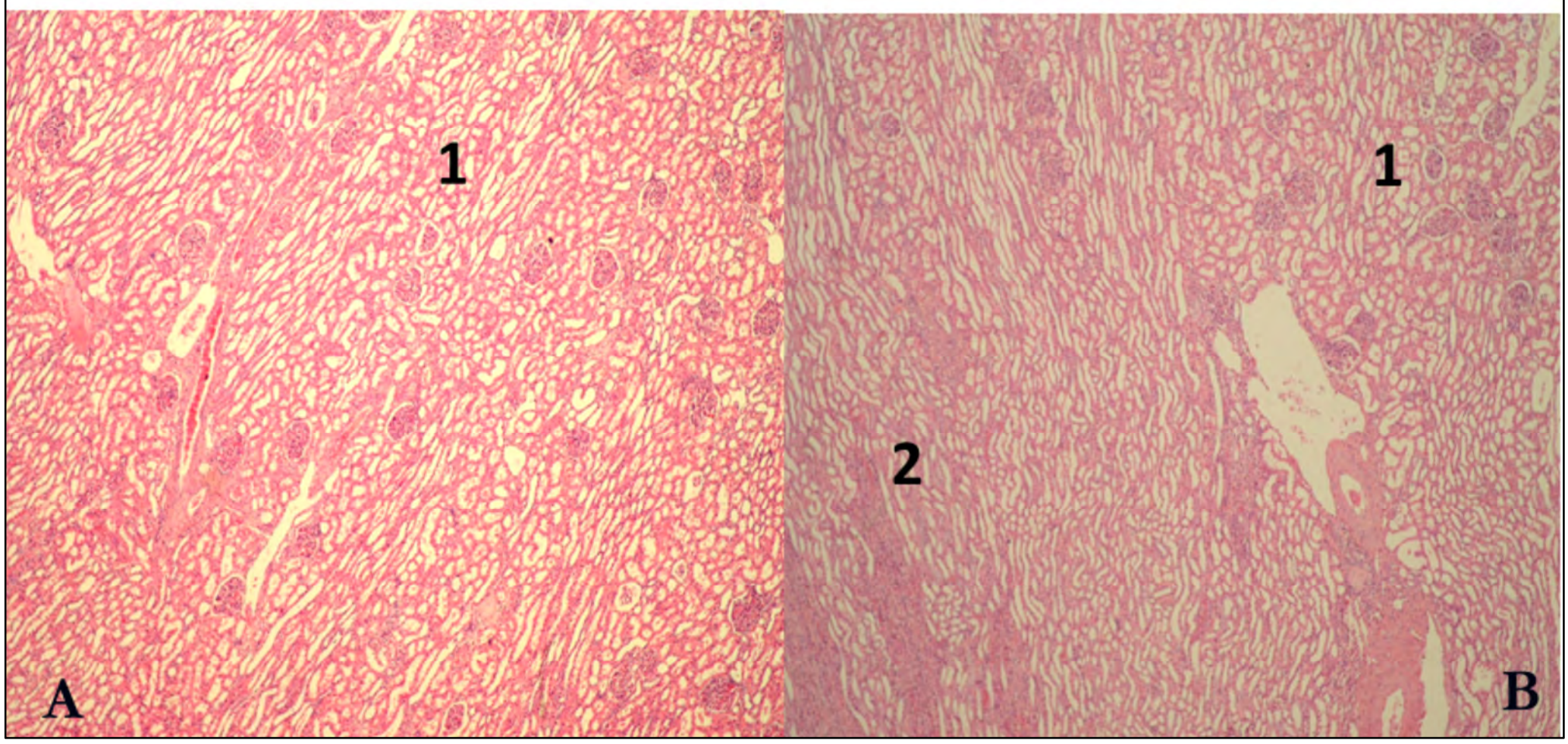

- **Sections in the cortex of the kidney:**

A:
Whenever we see a section in the kidney, we should know whether it's in the cortex or in the medulla.

The cortex contains renal corpuscles. When we recognize these renal corpuscles, we know that this is the cortex not the medulla.

Which parts of the uriniferous tubules do we see in the cortex?
1- The glomeruli
2- Proximal Convolutes Tubules
3- Distal Convoluted Tubules
4- medullary rays (collecting tubules in the cortex).

- PCTs are 15 mm long, while the DCTs are only 8 mm long. A section in the cortex is more likely to pass through PCTs.

B:
1- There are renal corpuscles, surrounded by PCTs and DCTs → Cortex
2- This part is devoid of renal corpuscles, and contains only tubules → Medulla

Outer zone of medulla

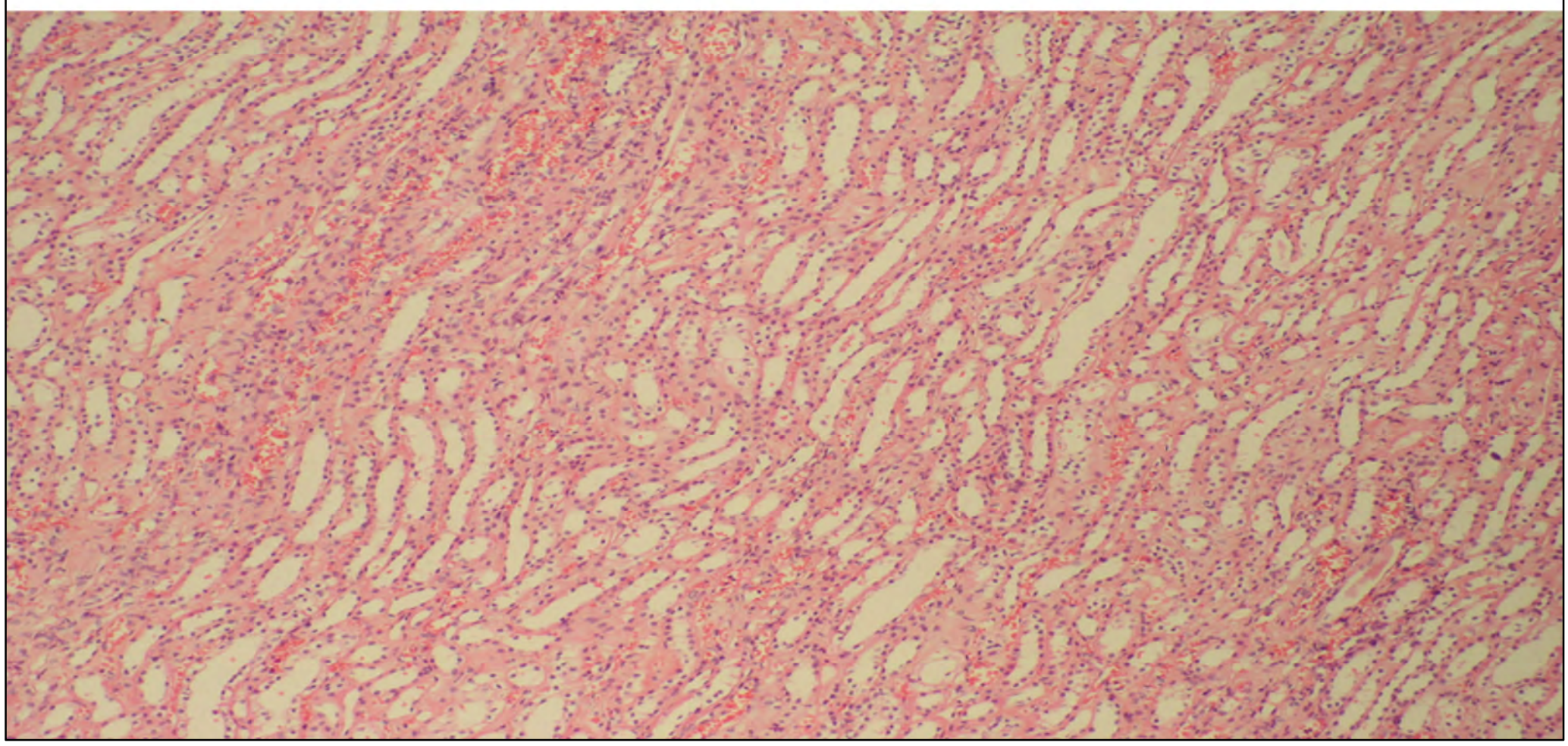

- This area is devoid of any renal corpuscles. There are tubules, sectioned in different directions → This is outer zone of medulla.

- Collecting tubules in the cortex are different from those in the outer and inner zones of the medulla.

→Collecting tubules in the cortex are impermeable to water and urea, even in the presence of ADH.

→Medullary collecting tubules are permeable to water and urea, in the presence of ADH.

- In the inner zone of the medulla, the reabsorption of water and urea across the collecting tubules is optimal, in the presence of ADH.
- The reabsorbed water will be taken by the vasa recta that surround the loop of Henle in the medulla → Reabsorption of water will not ruin the hyperosmolar medium in the medulla.

Inner Zone of the Medulla

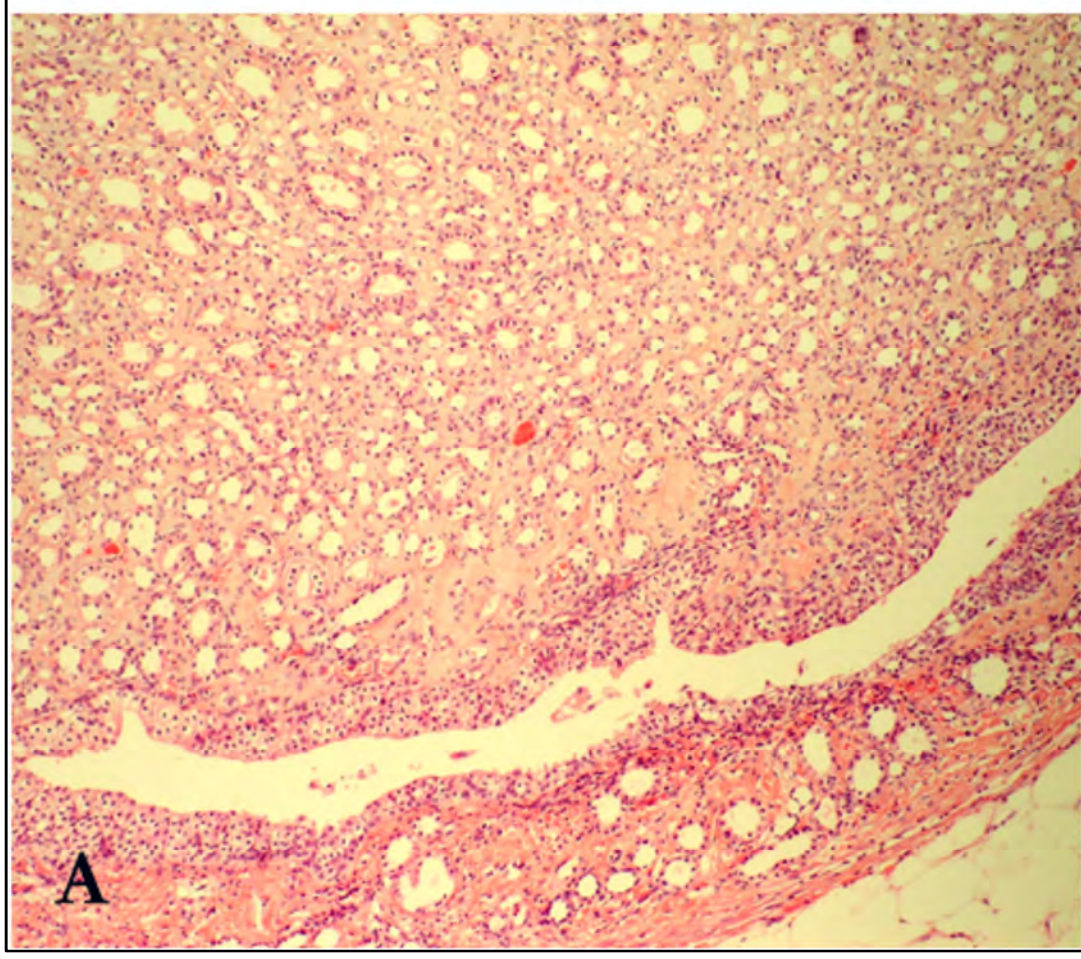

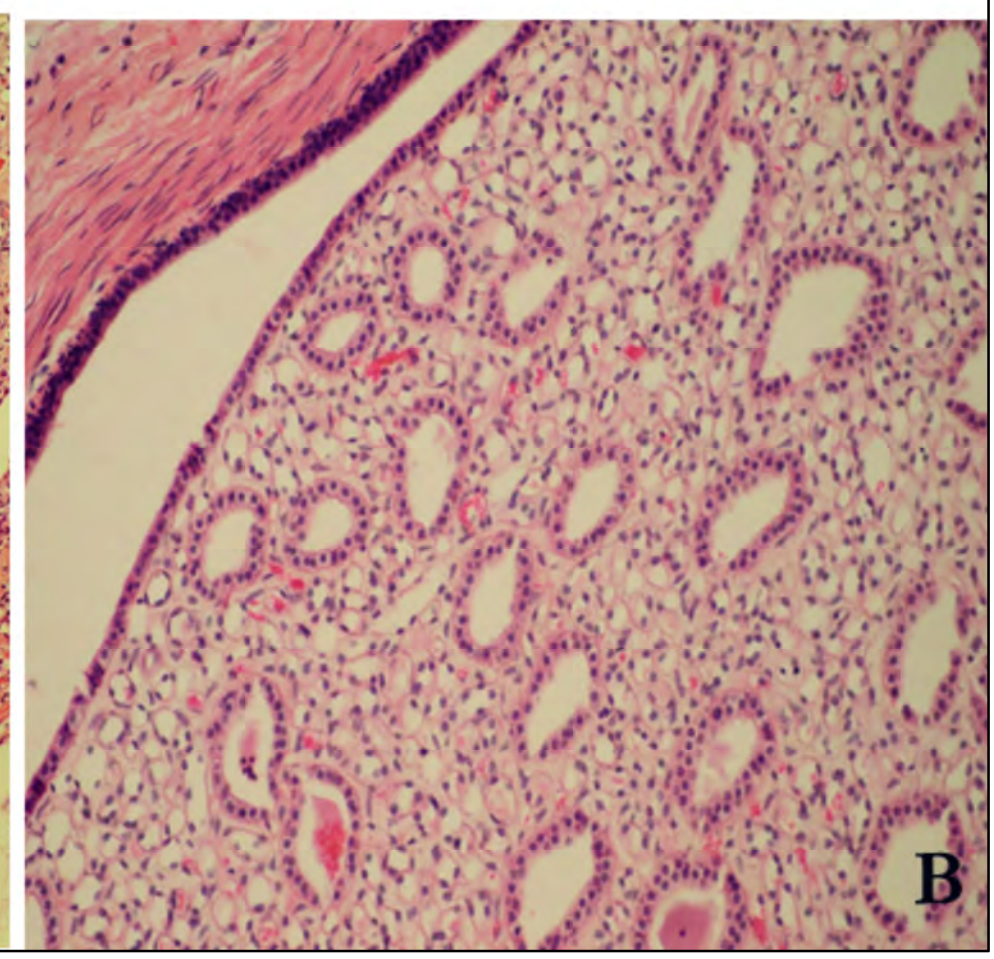

A: Inner Zone of Medulla
Many collecting ducts and tubules are seen within the medulla. **How can we differentiate between them?**

1- **The Size of the lumen**
Large lumen → Collecting duct.
Small lumen → Collecting tubule.

2- **The lining epithelium**
Cuboidal epithelium → tubule
Low-columnar or columnar epithelium → duct

B: Inner Zone of Medulla

There are multiple collecting ducts and tubules (that can be differentiated based on the size of the lumen and the lining epithelium). Around these ducts and tubules are multiple sections passing through the thin and thick segments of the loop of Henle, as well as the vasa recta.

- At this level of magnification, it's very hard to differentiate between the thin segment, thick segment of the loop of Henle and vasa recta.

Cortex: Medullary Rays

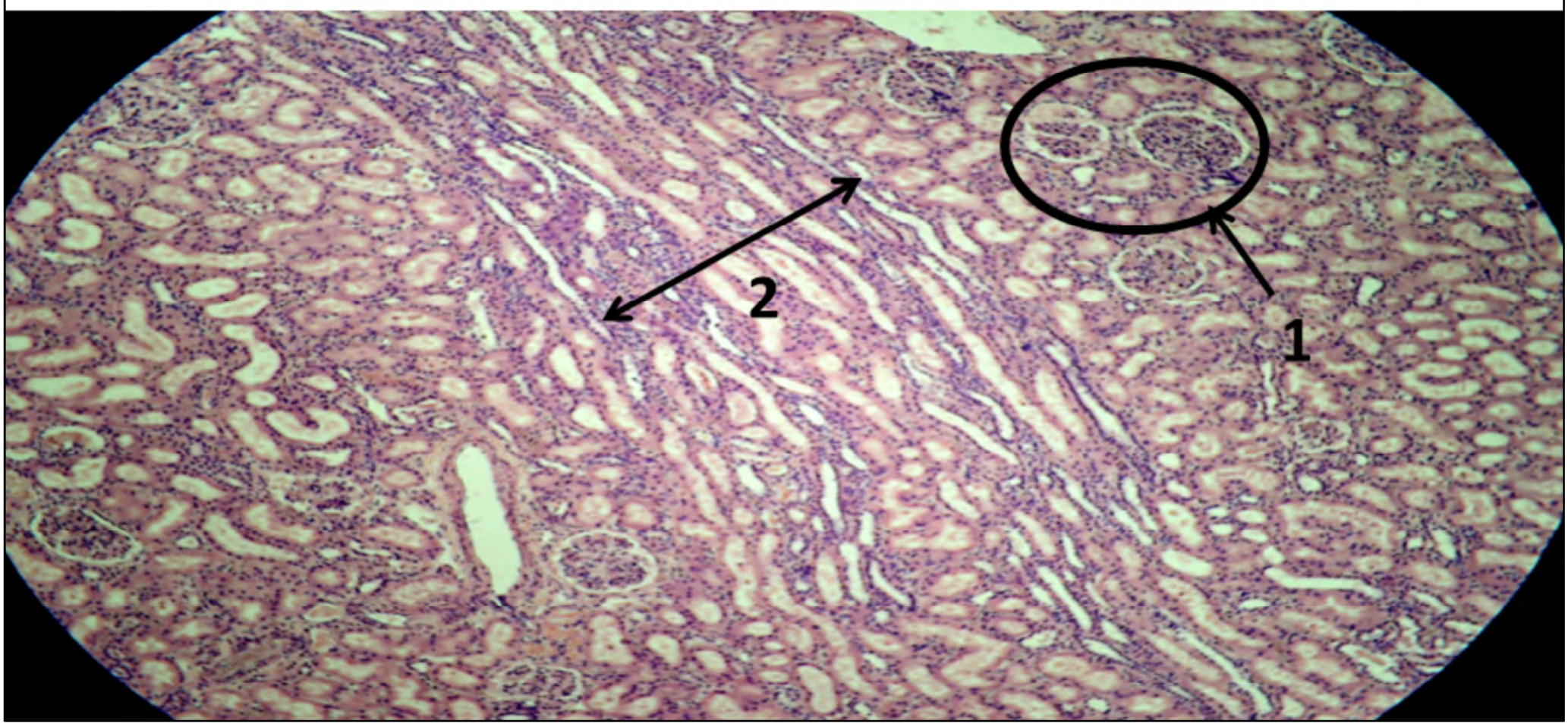

A section in the cortex (renal corpuscles appear on the right and left).

1- Renal Corpuscles.

Between the renal corpuscles, there are tubules (PCTs and DCTs), but we can’t differentiate between them at this magnification.

2- Medullary rays (collecting tubules receiving tubular fluid from the DCTs of nearby nephrons).

Renal lobule: The collecting tubule and the nephrons from which it receives tubular fluid.

- Renal lobule lies between two interlobular arteries.

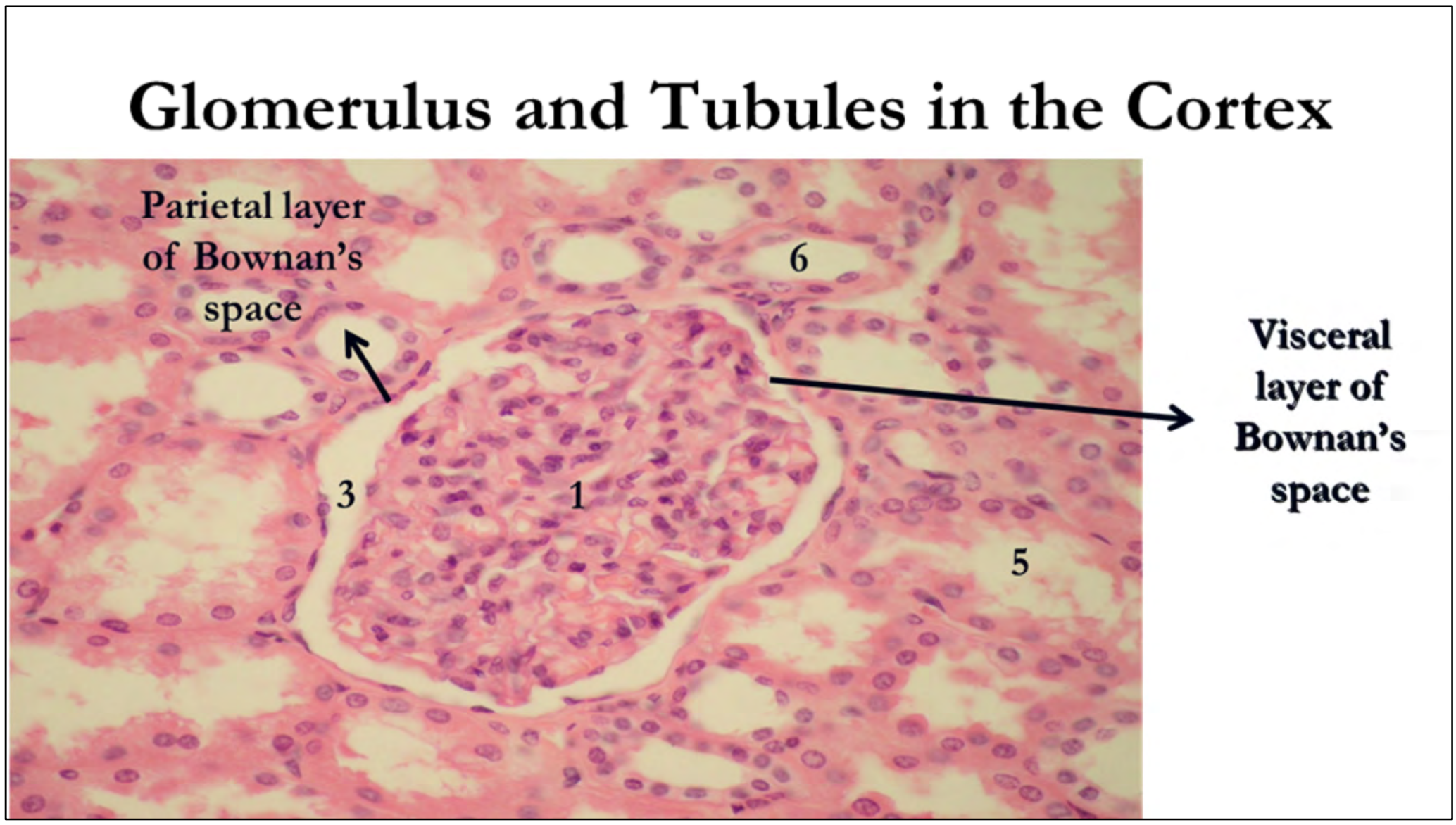

A section in the cortex showing renal corpuscle, as well as PCTs and DCTs.

Here at this magnification, we can see the following:

1- The glomerulus
2- Parietal and visceral layers of the Bowman's capsule.
3- Bowman's space
4- Mesangium (connective tissue between the capillaries)
5- PCTs
6- DCTs

- Intraglomerular mesangium supports the capillaries and has phagocytic activity
- At this magnification, we can differentiate between PCTs and DCTs:
  1- PCTs are more abundant in a cortical section. Why?
  Because they are longer, and a section is more likely to pass through them.

2- PCTs have a wider diameter. 3- PCTs have a brush border, while DCTs don't → the lumen of the PCTs appears filled, while that of DCTs appears empty.

Regular lumen → DCT Irregular lumen → PCT

- What's the nature of the fluid in Bowman's space and PCTs?
  Isosmotic (300 mOsm), because filtration is free filtration (water and solutes will be filtered in the exact same ration).
- What's the most important structure in the tubular cells (cells lining PCTs and other parts of the nephron)?
  Na+-K+ pump

- Cells lining the PCTs are intensely eosinophilic. Why?
  Because they are rich in mitochondria, that are needed for energy production for the pump.

- PCTs have two parts: A- The first half: Reabsorption of Na+ along with glucose, amino acids and bicarbonate.

- All glucose is reabsorbed in the first half of PCTs.

B- The second half: Na+ is reabsorbed along with Cl-

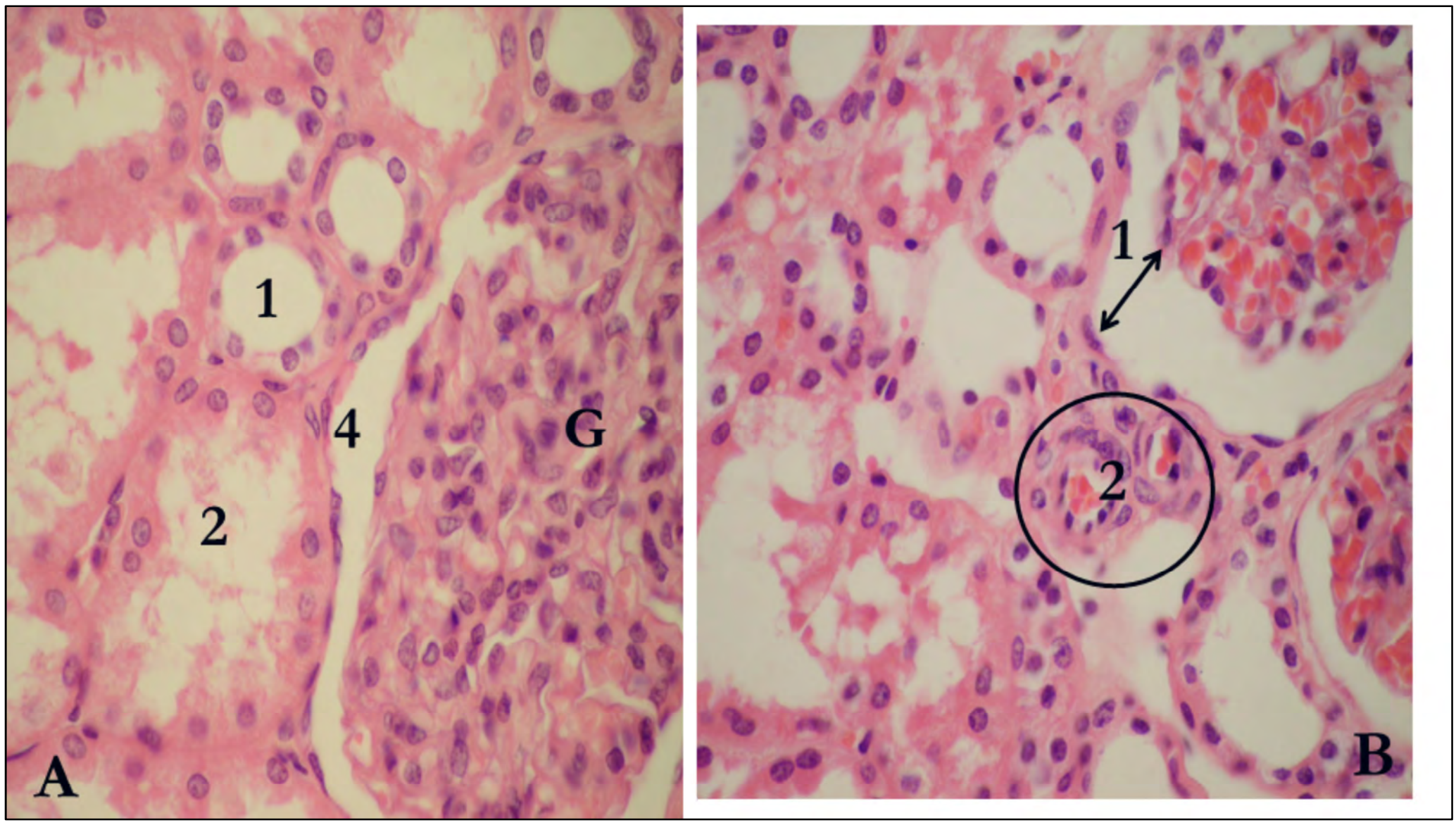

A: A section in the cortex, showing the following:
G: Glomerulus 1: DCTs 2: PCTs 4: Bowman's Space

- What pathological conditions might increase pressure in 4?
  A- Renal stone B- Enlargement of the prostate

Why? Obstruction of the ureter in A or the urethra in B will cause backflow of urine into the Bowman's space. This will increase the opposing force and decrease GFR.

B: A section in the cortex showing the afferent and efferent arterioles.
1- Bowman's space
2- The vascular pole: this is the site at which the afferent and efferent arterioles enter and leave the glomerulus, respectively. Inside the arterioles, we see RBCs.

- Structure 1: late distal tubule

Tubular fluid passes through the descending limb of loop of Henle, which is highly permeable to water and thus becomes hypertonic. Then, it passes through the ascending limb, which is impermeable to water and becomes hypotonic → Tubular fluid reaches the DCTs as hypotonic or isotonic solution but is never hypertonic.

<u>True or False:</u>

1- In the second half of structure 2, Na+ moves downhill along with glucose uphill.

False. This occurs in the first half of PCTs not the second half.

2- Structure 1 contains tubular fluid that has an osmolarity of 1200 mOsm.

False. DCTs may contain hypotonic or isotonic fluid but never hypertonic.

Urinary and Vascular Poles of Renal Corpuscle

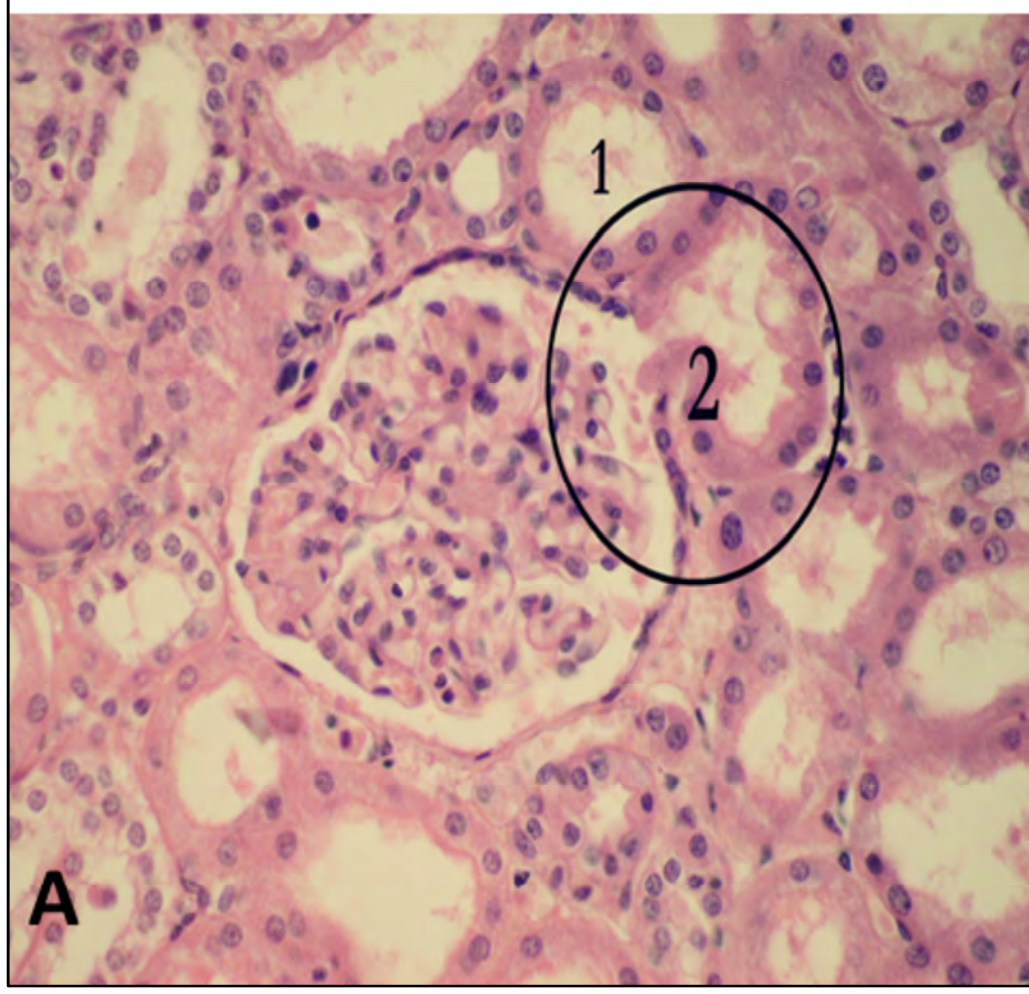

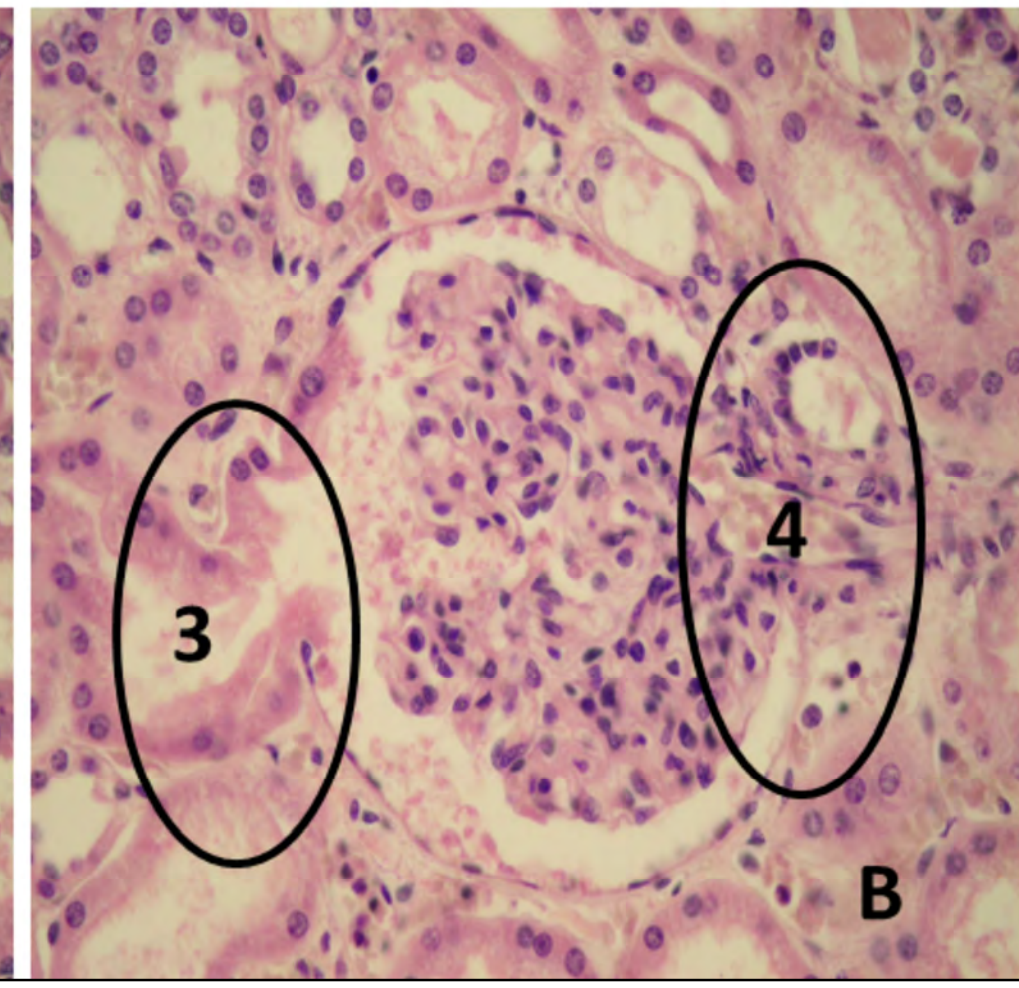

A: Urinary Pole of Renal Corpuscle

The glomerulus is continuous with PCTs. The site of the renal corpuscle at which the glomerulus is continuous with PCTs is called the urinary pole.

<u>True or False:</u>

1- Structure 2 is continuous with the glomerulus and they both contain fluid of the same osmolarity.

True

2- Structure 2 contains isotonic fluid, while structure 1 contains hypotonic or hypertonic fluid.

False. Structure 1 is DCTs and it never contains hypertonic fluid.

3- The connective tissue between glomerular capillaries is called the mesangium and it supports them.

True.

4- The circled part is the vascular pole of renal corpuscle.

False. This is the urinary pole.

B: Urinary and Vascular Poles of the Renal Corpuscle

3- Urinary pole 4- Vascular pole

Inside the circle, there are closely-packed columnar cells. These are the macula densa.

A: Urinary and Vascular Poles of Renal Corpuscle
B: Distal Convoluted Tubules

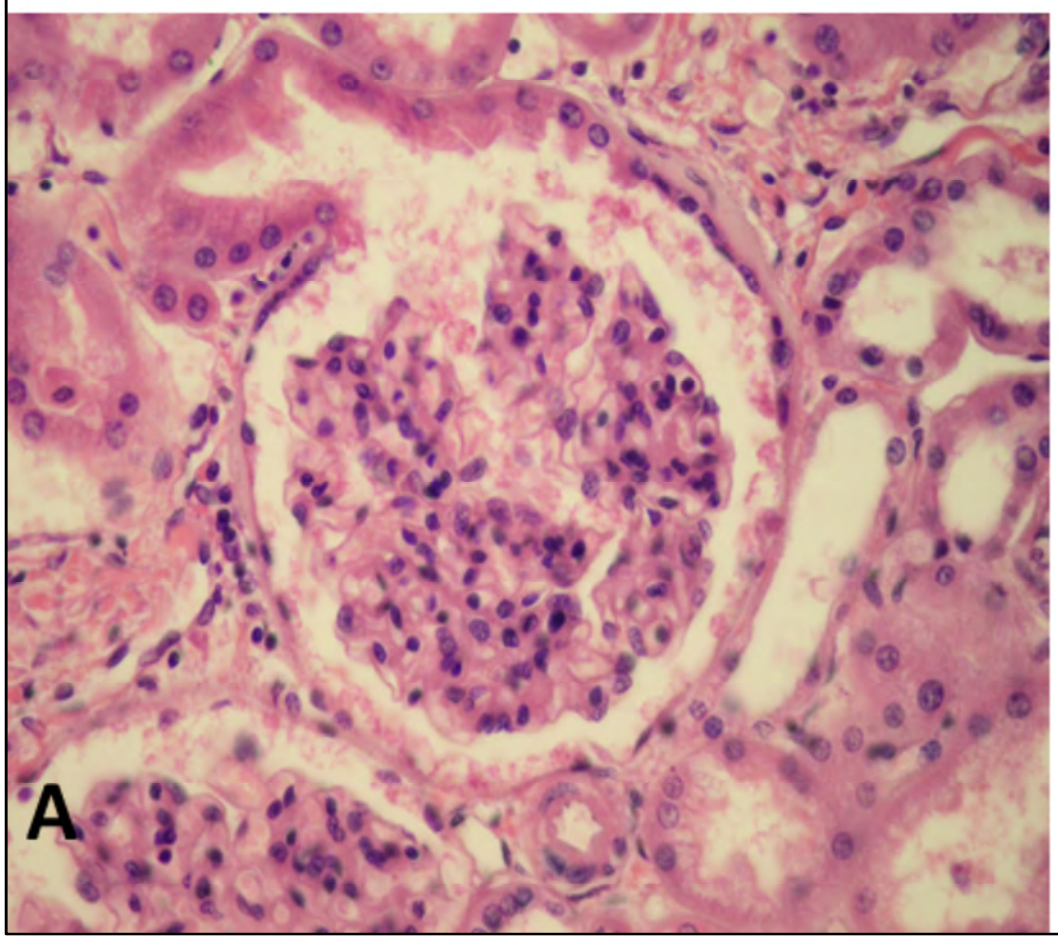

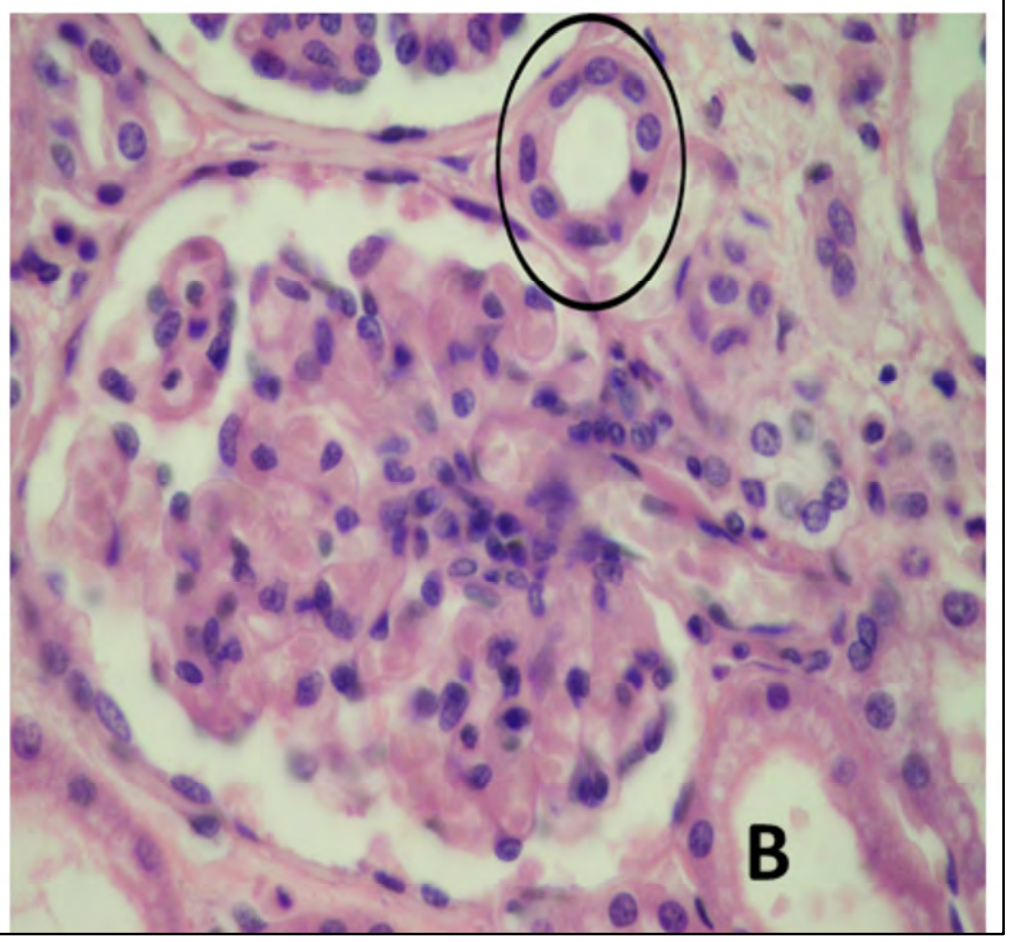

Macula densa

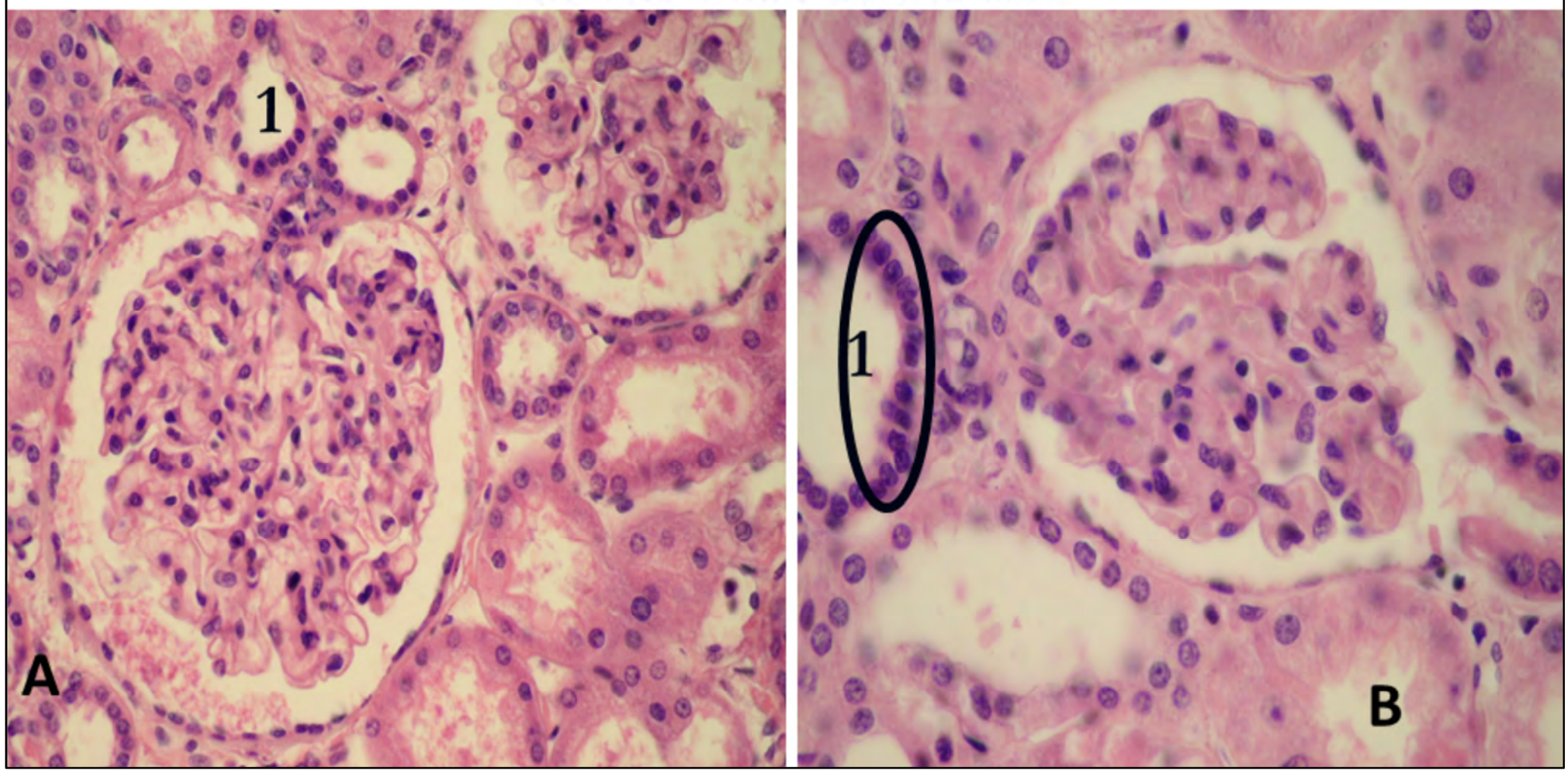

A & B:

1- Macula densa

- Closely-packed columnar cells in the wall of the intermediate part of the distal convoluted tubules.
- They are special cells that act as osmoreceptors, and are thus affected by the concentrations of sodium and chloride.
- They are integral part of the juxtaglomerular apparatus

- **How does the macula densa act?**
  The macula densa acts indirectly in response to decreased Na+.
  Decreased Na+ will be reflected as a decrease in blood volume and blood pressure.
  → Decreased blood pressure will be sensed by the JG cells that will secrete renin and activate RAAS.
  → Decreased blood pressure will decrease GFR, and sodium concentration in the DCT → Macula densa will act as osmoreceptors and stimulate renin release by JG cells through the release of prostaglandins.

- **Q: Which of the following is true about structure 1:**
  a- These are JG cells b- These cells secrete renin
  c- both a and b d- neither a nor b
  Answer: D

Macula Densa

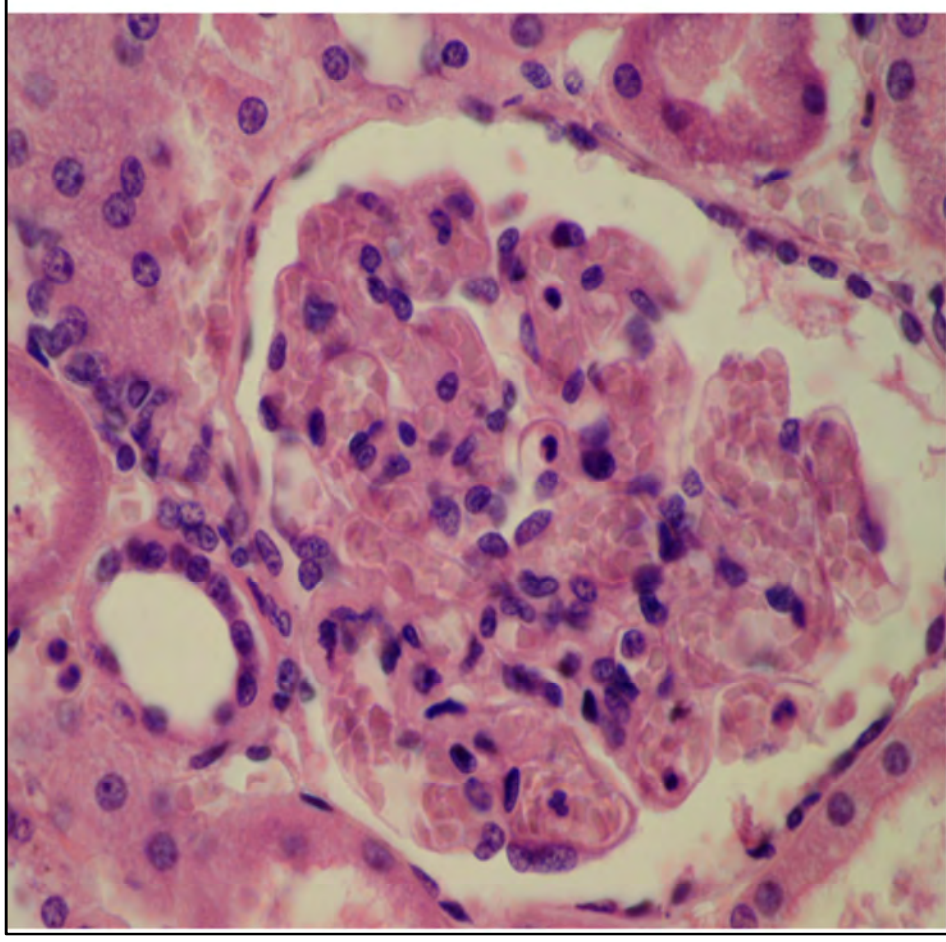

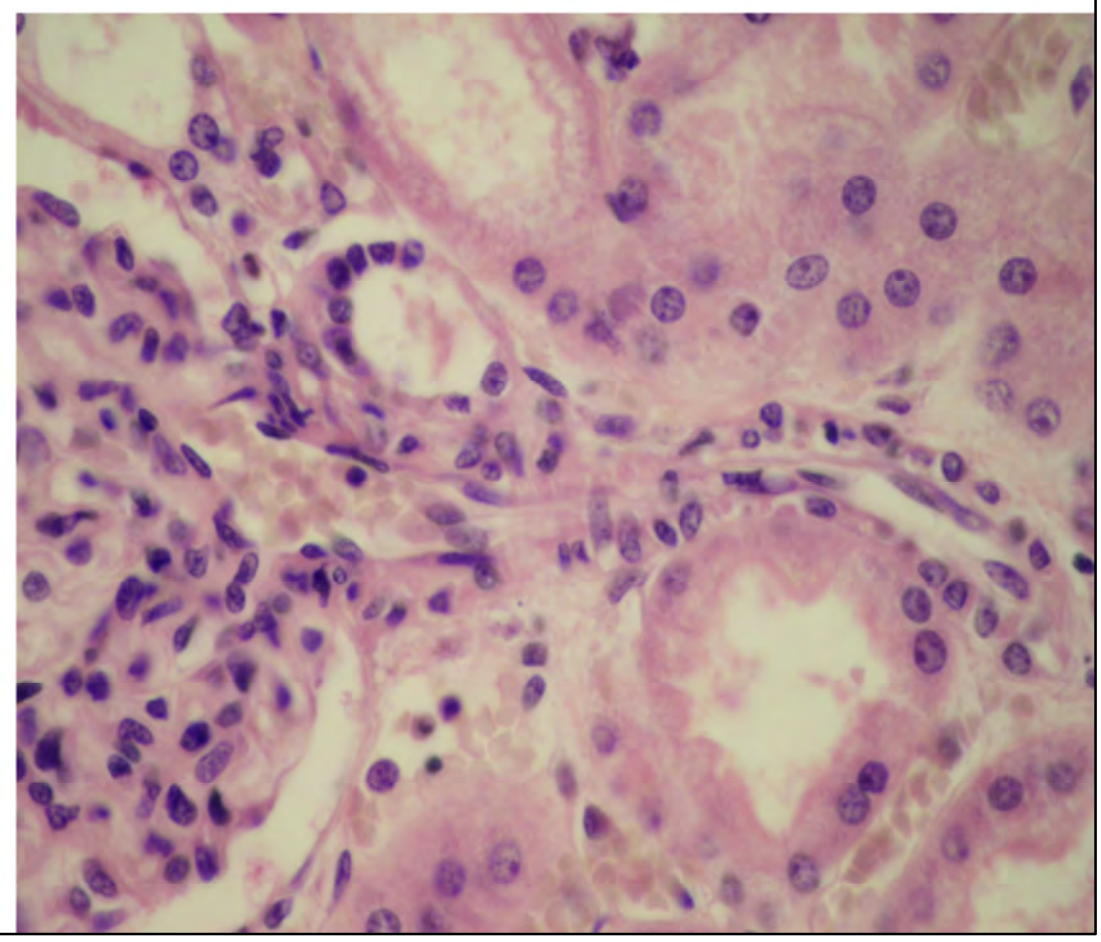

- Localize the following:

1- Macula densa
2- Glomerulus
3- Bowman's space
4- Vascular pole and urinary pole

Juxtaglomerular apparatus

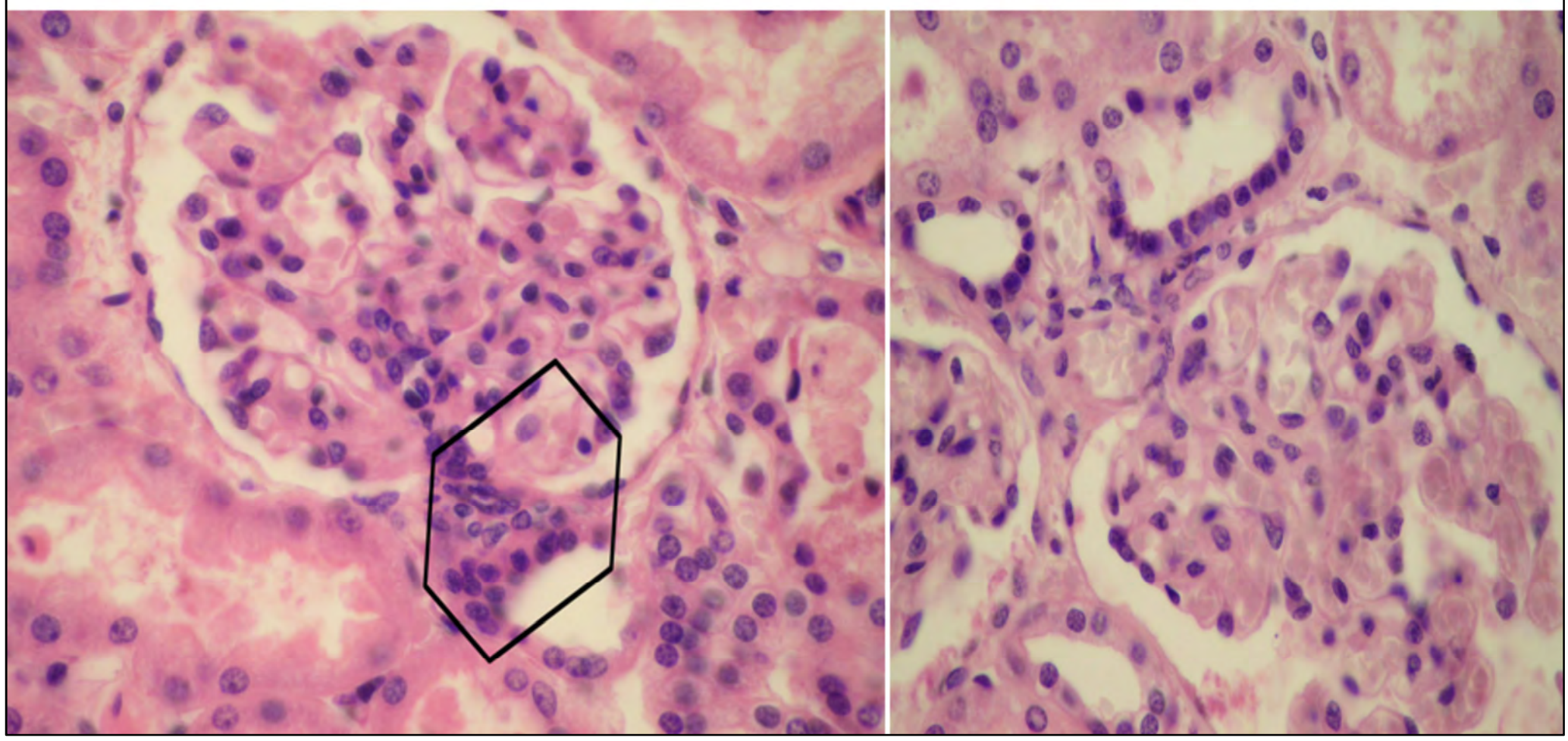

Juxtaglomerular Apparatus:

Formed of:

A- Macula Densa

B- Juxtaglomerular cells in the wall of the afferent arteriole (not clear here)

C- Extraglomerular mesangium (unknown function)

These structures are close to each other, so if you see the Macula Densa, you should know that the JG cells and the extraglomerular mesanigum are adjacent.

Medullar Ray and Collecting Tubules in the Cortex

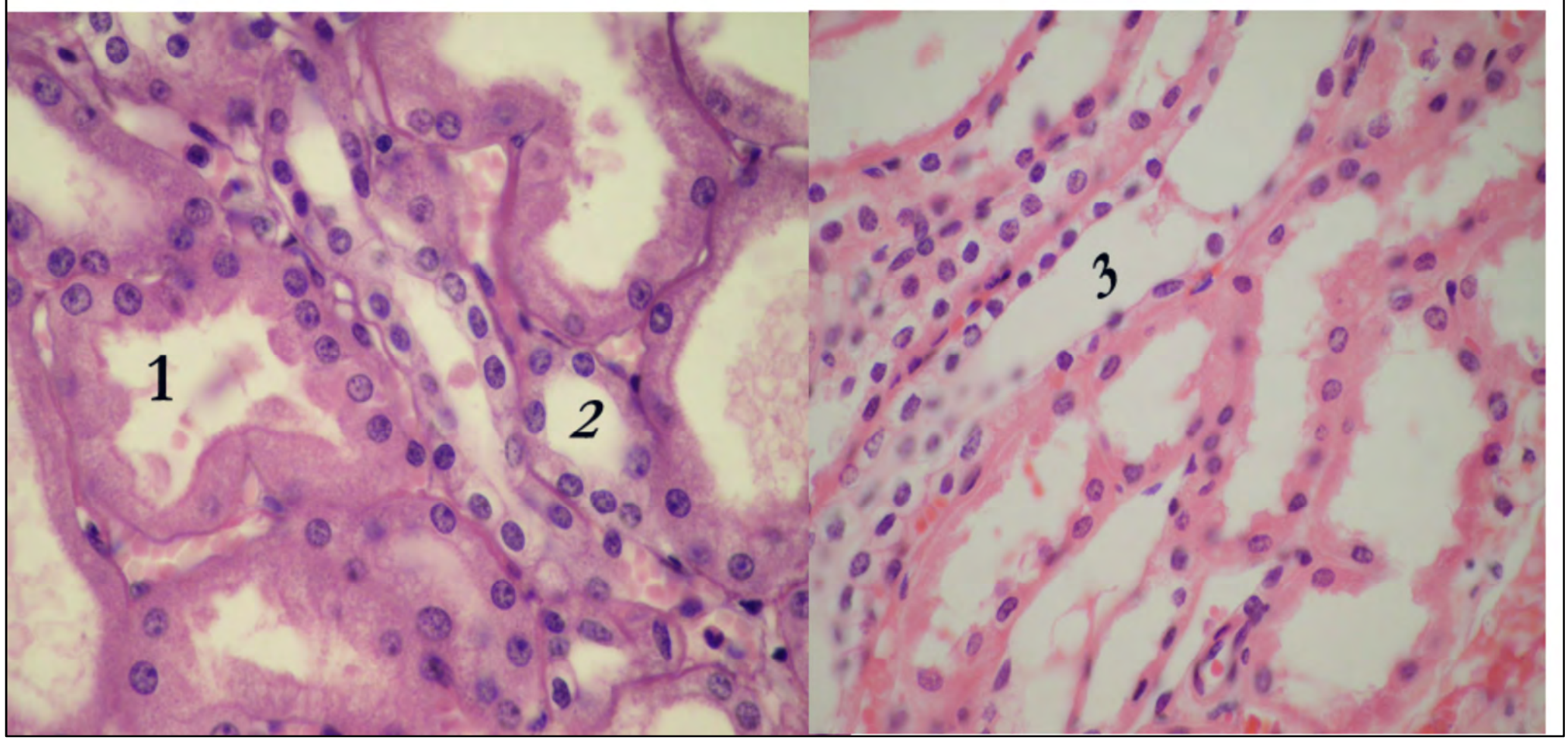

Medullary ray in the cortex (collecting tubules in the cortex).

Here, the permeability to water in minimal, even in the presence of ADH.

1- PCT
2- DCT
3- Collecting tubule

- When the tubular fluid reaches the collecting tubules in the cortex, they can be either hypotonic or isotonic but never hypertonic.

PAS Reaction in the Basement Membrane

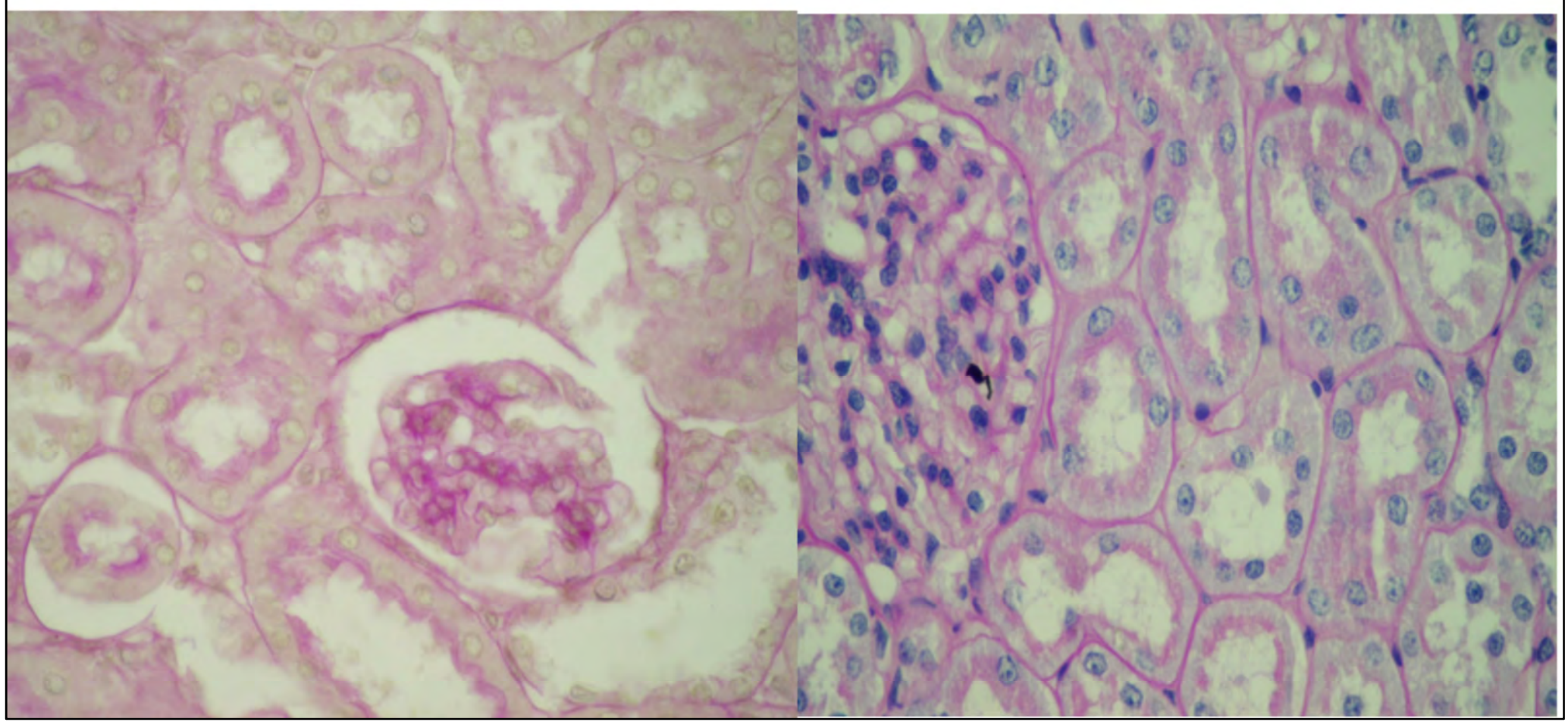

- The basement membrane of the glomerulus, and tubules stains positive with PAS (Periodic-acid Schiff reaction).

- Extra info: PAS reaction stains complex carbohydrate-containing cell components, which become magneta (shades of purplish pink). PAS is used most commonly to demonstrate cells filled with mucin granules, glycogen deposits, or the glycocalyx.

- See this: http://library.med.utah.edu/WebPath/RENAHTML/RENAL080.html

Medulla of the Kidney (Thin Segments)

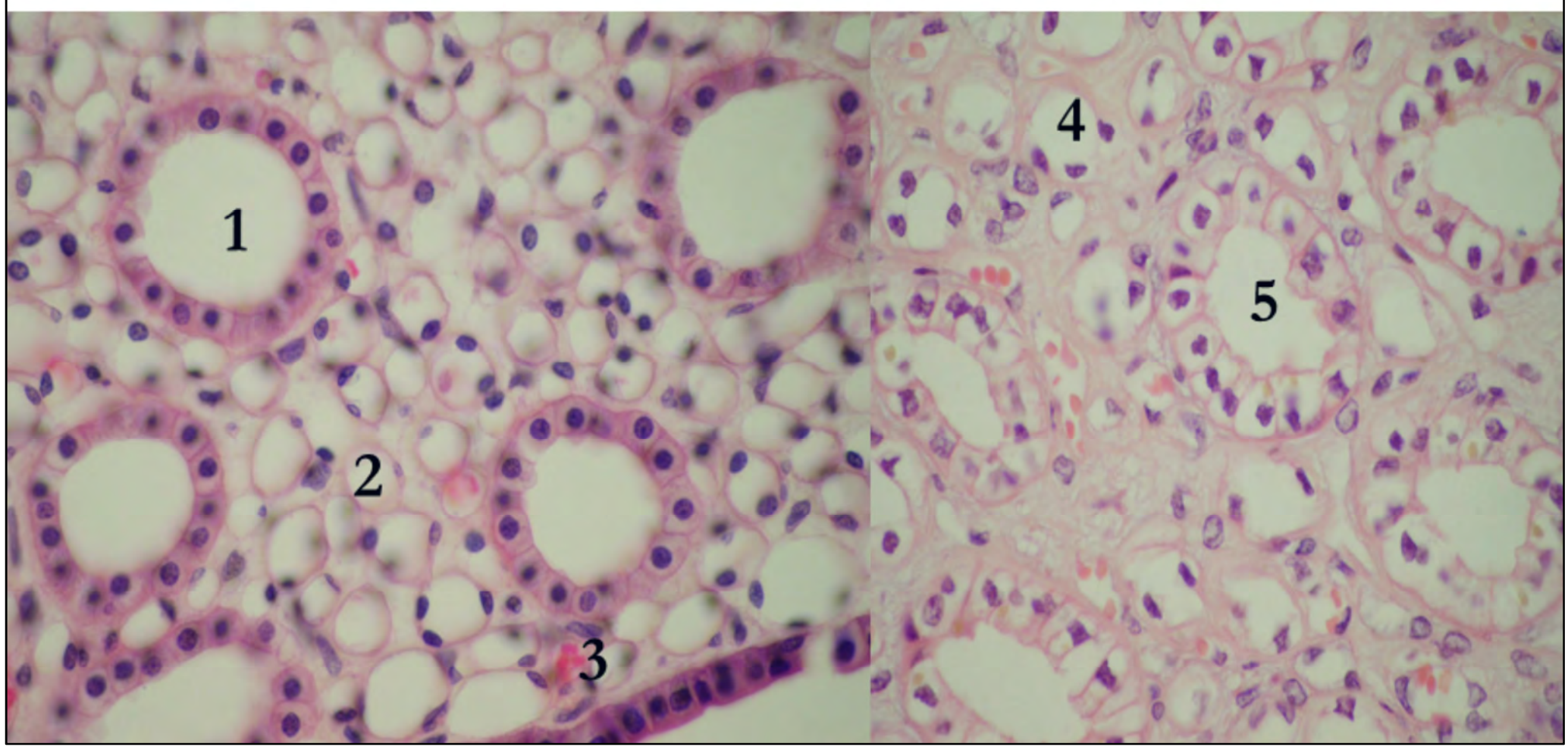

- **A section in the medulla showing the following:**

1- Collecting tubule (the lining epithelium is cuboidal) 2- Thin limb of loop of Henle 3- Vasa recta 4- Thin limb of loop of Henle 5- Collecting duct (Columnar epithelium).

Note that in the thin lmb the nuclei are bulging to the lumen.

Q: Can you tell whether the thin limb is ascending or descending?

No. At the level of the LM, we cannot differentiate.

Q: True of False:

1- Structure 2 contains fluid that can be hypotonic or hypertonic.

True. Because this might be an ascending limb or descending limb.

2- Structure 2 may be a vasa rectum.

False. In order to consider it a vasa rectum, there must RBCs inside it.

3- Structure 2 could be highly permeable or highly impermeable to water.

True. Because it might be ascending limb or descending limb.

4- Structure 2 has eosinophilic cytoplasm and performs active transport.

False. Cells of the loop of Henle (in the thin segments) contain minimal amounts of organelles and don't perform active transport.

Q: In which conditions structure 1 may contain hypertonic urine?
In the presence of ADH (in a normal person, drinking normal amounts of fluids).
And in which conditions structure 1 may contain hypotonic or isotonic urine?
1- In a normal person drinking huge amounts of fluids (this will inhibit ADH secretion and concentration of urine). 2- Diabetes insipidus

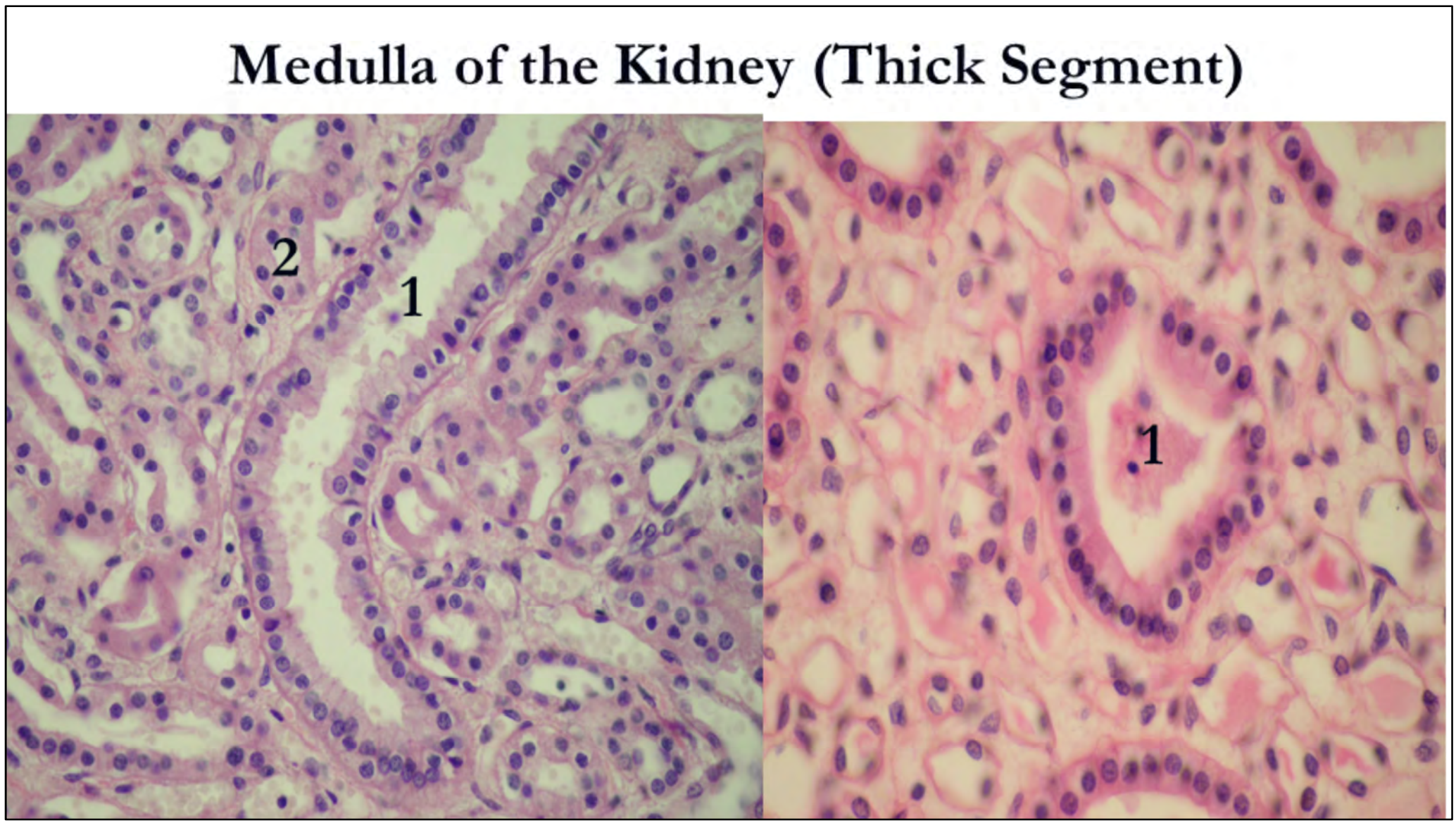

Longitudinal section in the medulla:

1- Collecting Duct:

- Lined by columnar epithelial cells (and hence it is a collecting duct rather than tubule).
- The fluid here is most likely hypertonic. However, if someone is drinking excess fluids, deficient in ADH (central diabetes insipidus) or not responding to ADH (nephrogenic diabetes insipidus), the fluid may be isotonic or even hypotonic.
- Briefly, in the presence of normal ADH → Concentrated hypertonic urine.

In the absence of normal ADH → isotonic or hypotonic urine.

2- Thick segment of loop of Henle:

- Active reabsorption of Na+, Cl- downhill and K+ uphill.
- Cells are rich in K+.
- K+ channels in the apical membrane transport potassium into the lumen, creating a positive voltage across the tubular cells. This voltage difference plays a major role in driving the passive paracellular reabsorption of various types of cations (Na+, Mg++ .. Etc).
- Loop diuretics (Furosemide) work on this thick segment of loop of Henle.

<u>True or False:</u>

1- In structure 2, reabsorption of Na+ is passive.

False. Reabsorption in the thin segment is passive, but is active in the thick segment.

Ureter

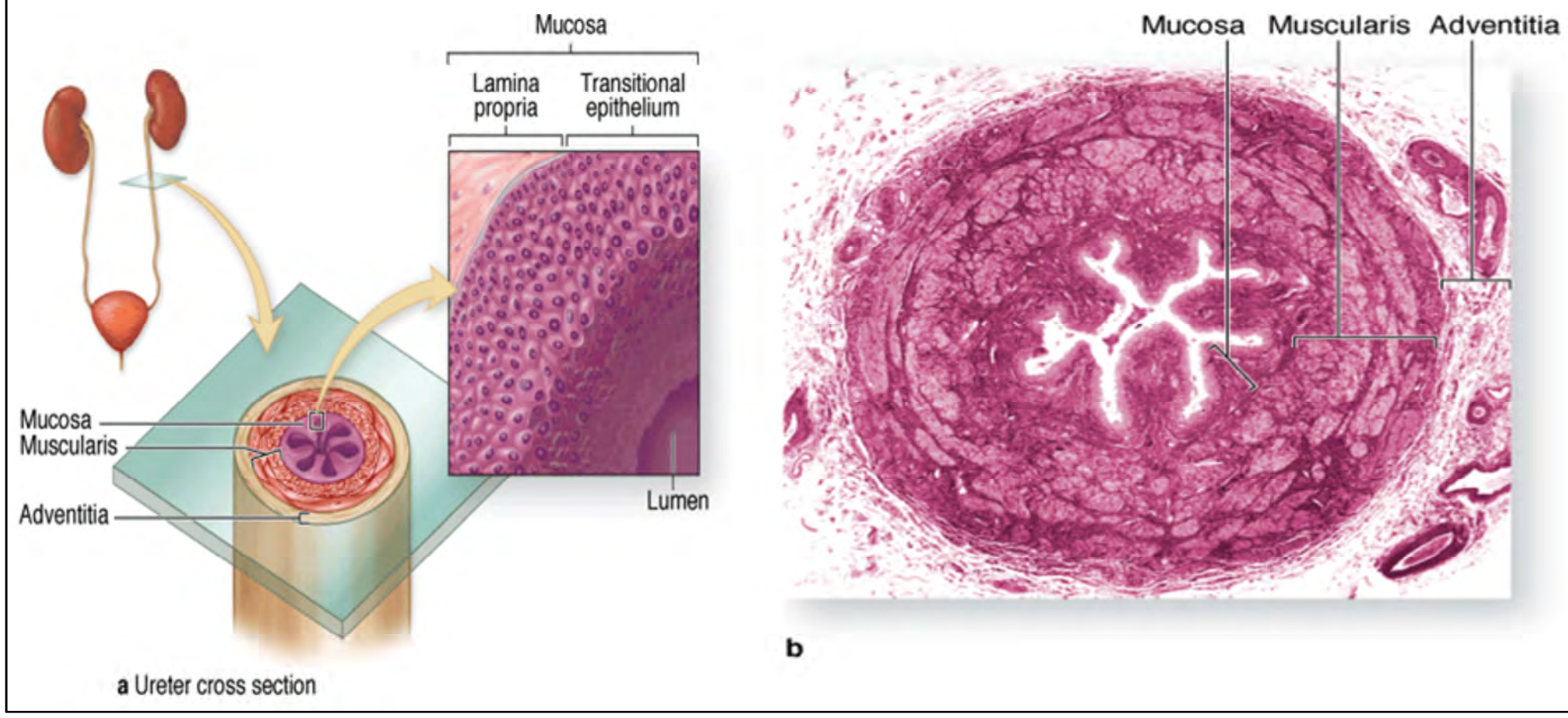

- The ureters are muscular tubes which conduct urine from the kidneys to the bladder. Urine is conducted from the pelvi-calyceal system as a bolus which is propelled by the peristaltic action of the ureteric wall.

Q: How does the ureter conduct urine?
By peristalsis, not by gravity. So, there must be layers of muscle in the wall of the ureter.

- Renal colic associated with ureteric stone is attributable to the strong peristalsis in the ureter. The ureter will contract very forcefully trying to get rid of the stone, and thus will produce the pain.

Layers of the Ureter

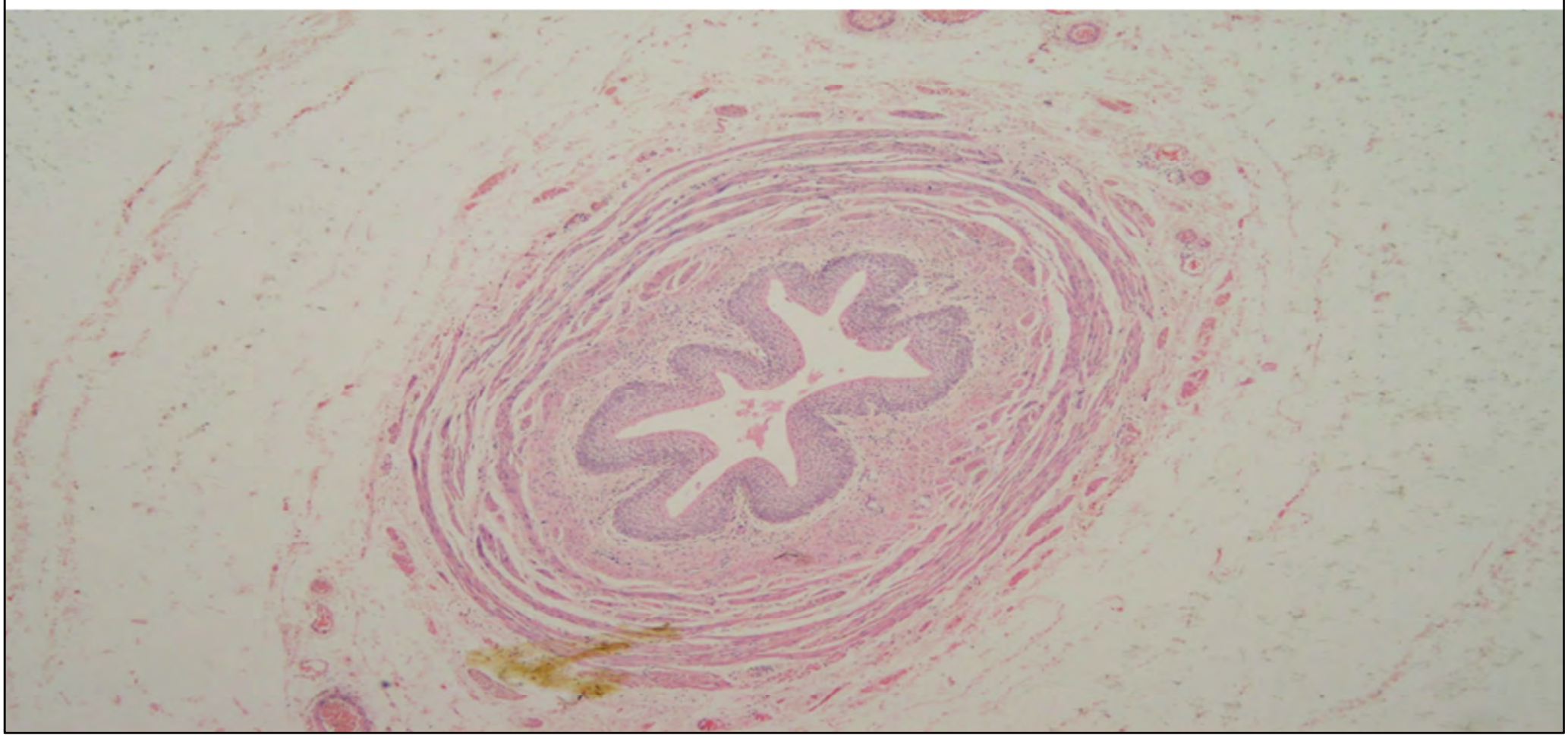

Cross-section in the ureter.

→The ureter is a muscular tube formed of main three layers:

1- Mucosa 2- Muscularis 3- Adventitia

- In the GI tract, the layers are mucosa, submucosa, muscularis and serosa.
- Serosa is a layer of peritoneum (simple squamous epithelium).
- Intraperitoneal structures are covered by serosa. However, the ureter is a retroperitoneal structure (covered by peritoneum only from the anterior surface). → the lateral and posterior surfaces of the ureter are covered by a connective-tissue layer, called the adventitia.
- The arrangement of muscles here are opposite to the gut. In the gut, muscularis layer is divided into outer longitudinal and inner circular muscles.

- The ureter:

1- upper two thirds: two layer, inner longitudinal and outer circular.

2- lower third: three layers (similar to the urinary bladder), inner longitudinal, middle circular and outer longitudinal.

Q: If there was a stone in the ureter, where would it be more likely to descend? In the upper two thirds or the lower third?
The lower third is covered by three layers of smooth muscle, and peristalsis is thus stronger here. So, a stone in the lower third will be more likely to descend and be excreted with urine that a stone in the upper two third (here there are two layers of smooth muscle and peristalsis is weaker).

Layers of the Ureter

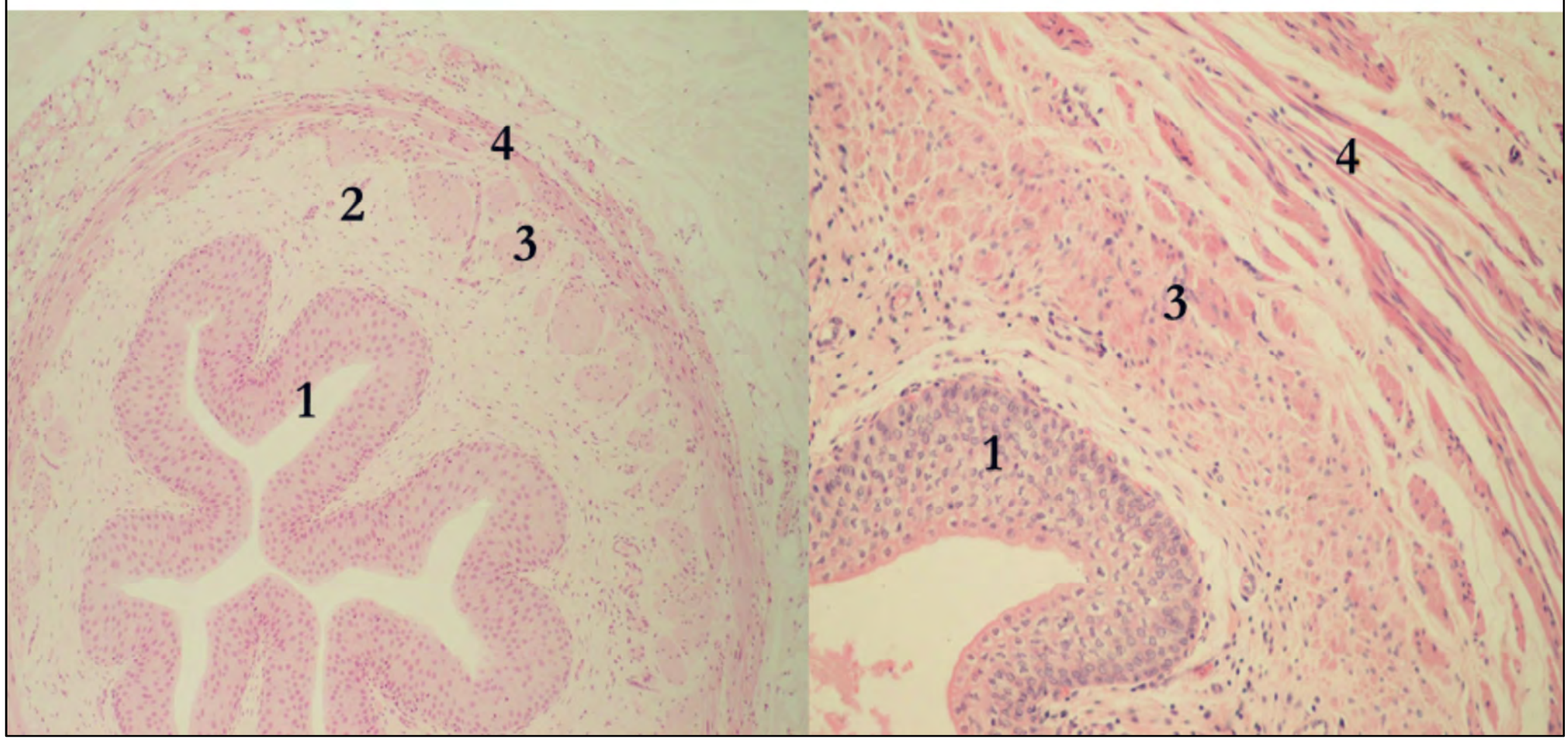

- The wall of the ureter contains 2-3 layers of smooth muscle, that are arranged into an inner longitudinal layer and an outer circular layer.
- These smooth muscle layers are richly supplied by the sympathetic nervous system.
- Nerve supply of the ureter is very important:
  A- Sympathetic innervation (from T10-L1): this is important for the peristaltic action of the ureter.
  B- Afferents also reach T10-L1 spinal segments (Remember referred pain).

Q: True of False:
1- A stone impacted in the structure shown here will never descend.
False. Strong peristalsis in the ureter will help get rid of the stone.

Q: In spite of the fact that the diameters of the ureter and the urethra are 3 mm and 6 mm, respectively, the patient can excrete a stone with a larger diameter (ex: 9 mm). Explain.
The strong peristalsis in the ureter helps the patient get rid of the stone, even if it's larger in size than the diameter of the ureter and the urethra.

Continue …

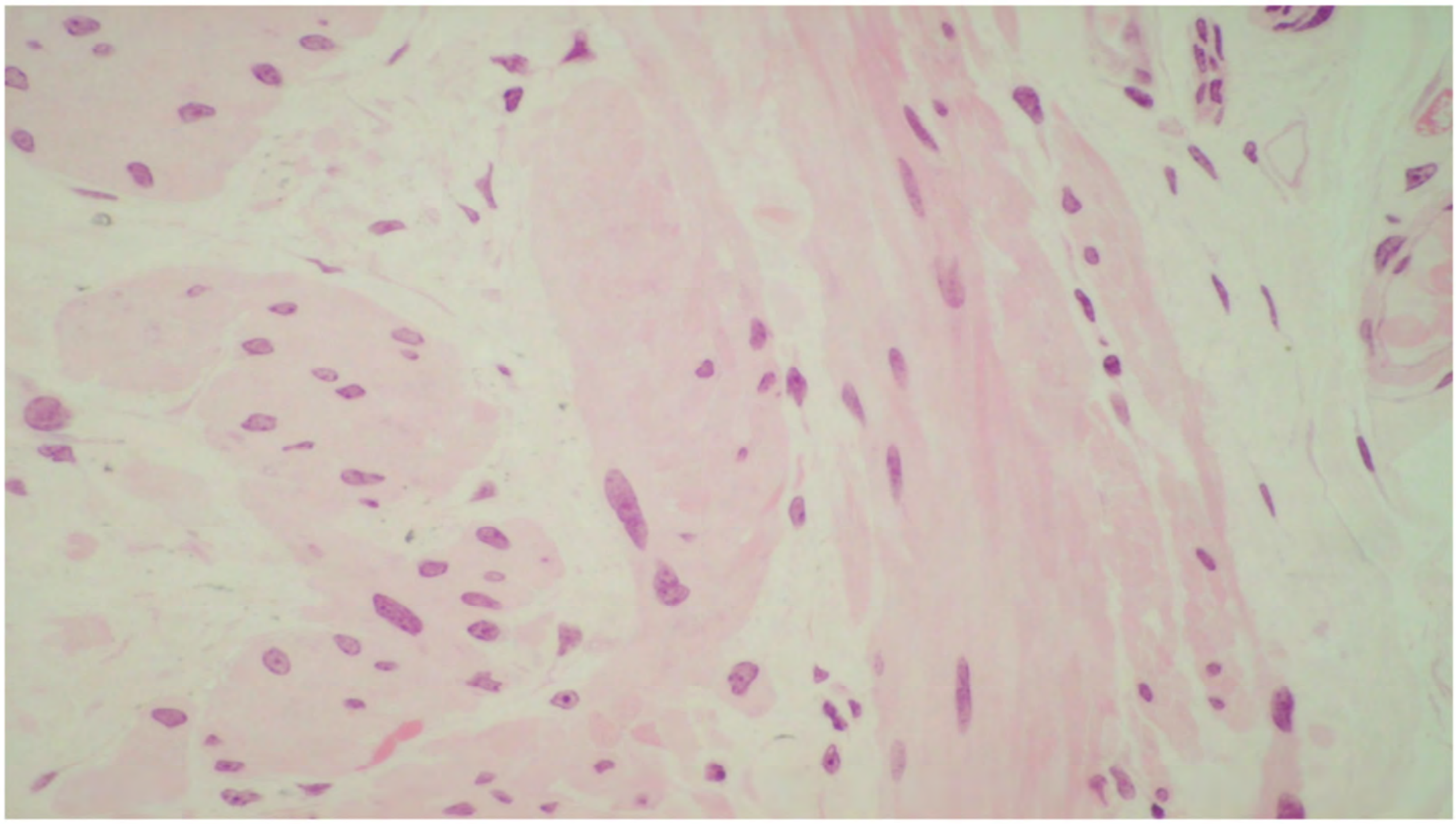

Continue …

- In the hospital, the use Laser Lithotripsy (جهاز تفتيت الحصى بالليزر) to make it easier for the urologist to get rid of large impacted stones, but this doesn't mean that ureteric stones cannot descend without it.

Read this: https://en.wikipedia.org/wiki/Laser_lithotripsy

- Structures shown in the sections:

1- Urinary epithelium (transitional epithelium).
2- Lamina propria
3- Inner longitudinal layer
4- Outer circular layer

- Urinary epithelium (transitional epithelium) is found only within the conducting passages of the urinary system. It's characterized by large, dome-like cells. When the ureter is filled with urine, these cells undergo distension (as if the layers decrease in number). Explained further later on.

Transitional epithelium

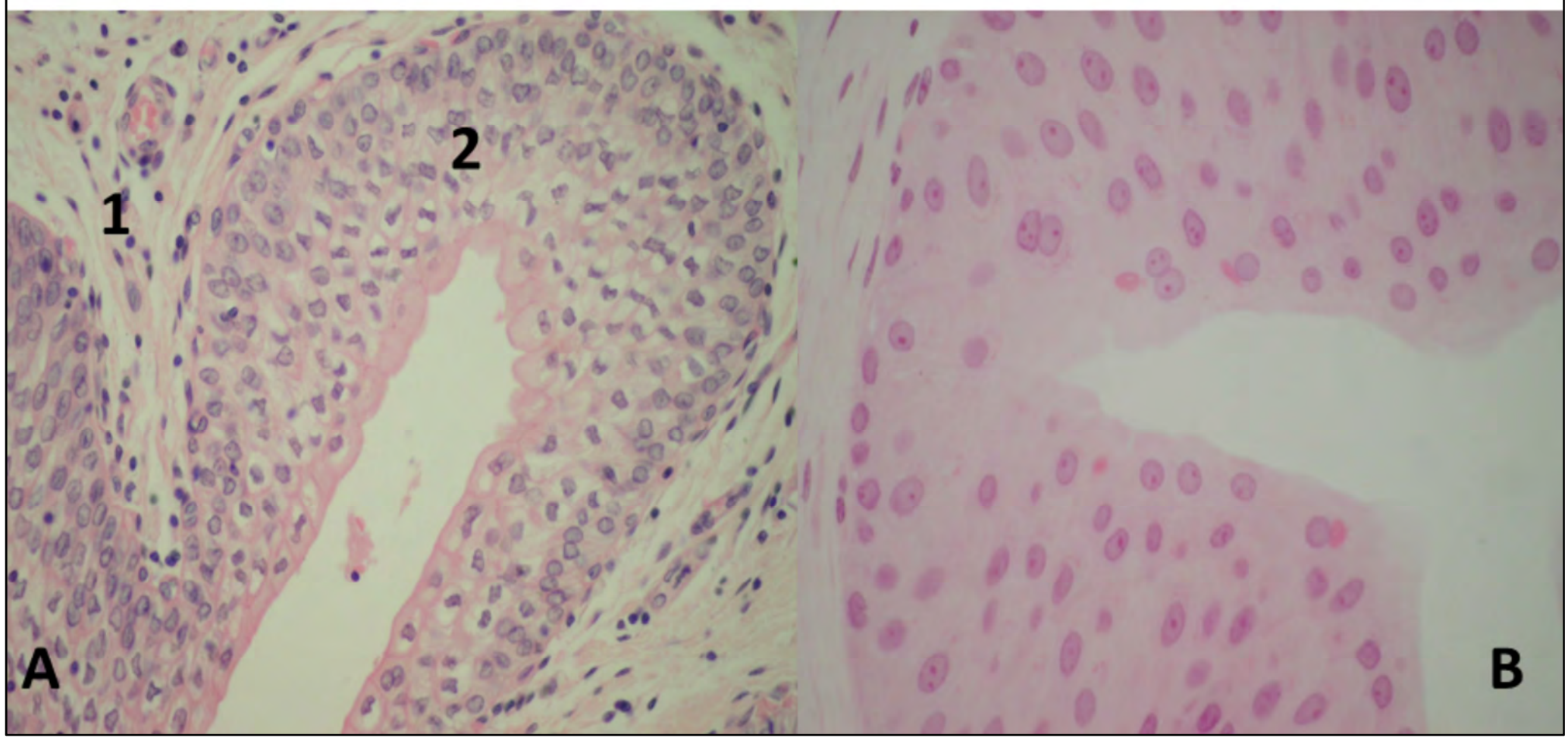

Transitional epithelium:

A: A section in the transitional epithelium of the ureter.
- Multilayered.
- When the ureter is full of urine, these layers will decrease in number.

B: A section in the transitional epithelium of the ureter.
- The superficial cells of the transitional epithelium are dome-shaped (They are not simple squamous, cuboidal or columnar).

Urinary Bladder

The Wall of the Urinary Bladder

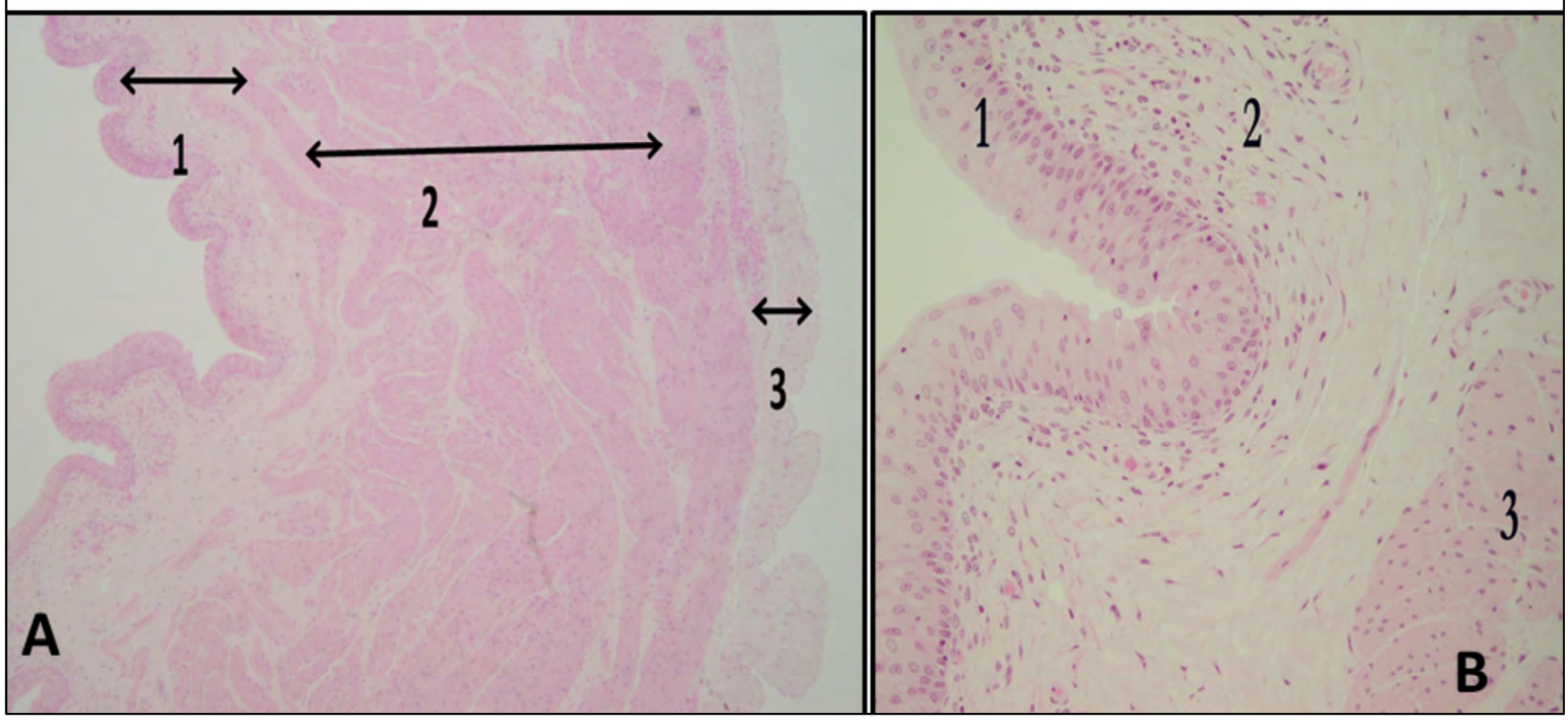

Urinary Bladder- Layers of its wall.

A: The wall of the urinary bladder is formed of three layers:
1- Mucosa 2- Muscularis 3- Adventitia

- The urinary bladder lies below the peritoneum (sub-peritoneal structure)
→ only the superior surface of the urinary bladder is covered by peritoneum.
→ Histologically, the walls of all surfaces of the urinary bladder have adventitia as the outer layers, except the superior surface which is covered by serosa.

- Remember: Serosa is the simple squamous epithelial layer of the peritoneum.

- The muscular layer is divided into three layers: Inner longitudinal, middle circular, and outer longitudinal. These group of muscles are called Detrusor muscle, that's important for evacuation of the urinary bladder.
- Sometimes, the three muscular layers are difficult to differentiate and run in an irregular pattern.

- The mucosa is lined by transitional epithelium.

B: Layers of the wall of the urinary bladder
1- Mucosa lined by transitional epithelium 2- Lamina propria
3- Muscularis

Transitional Epithelium

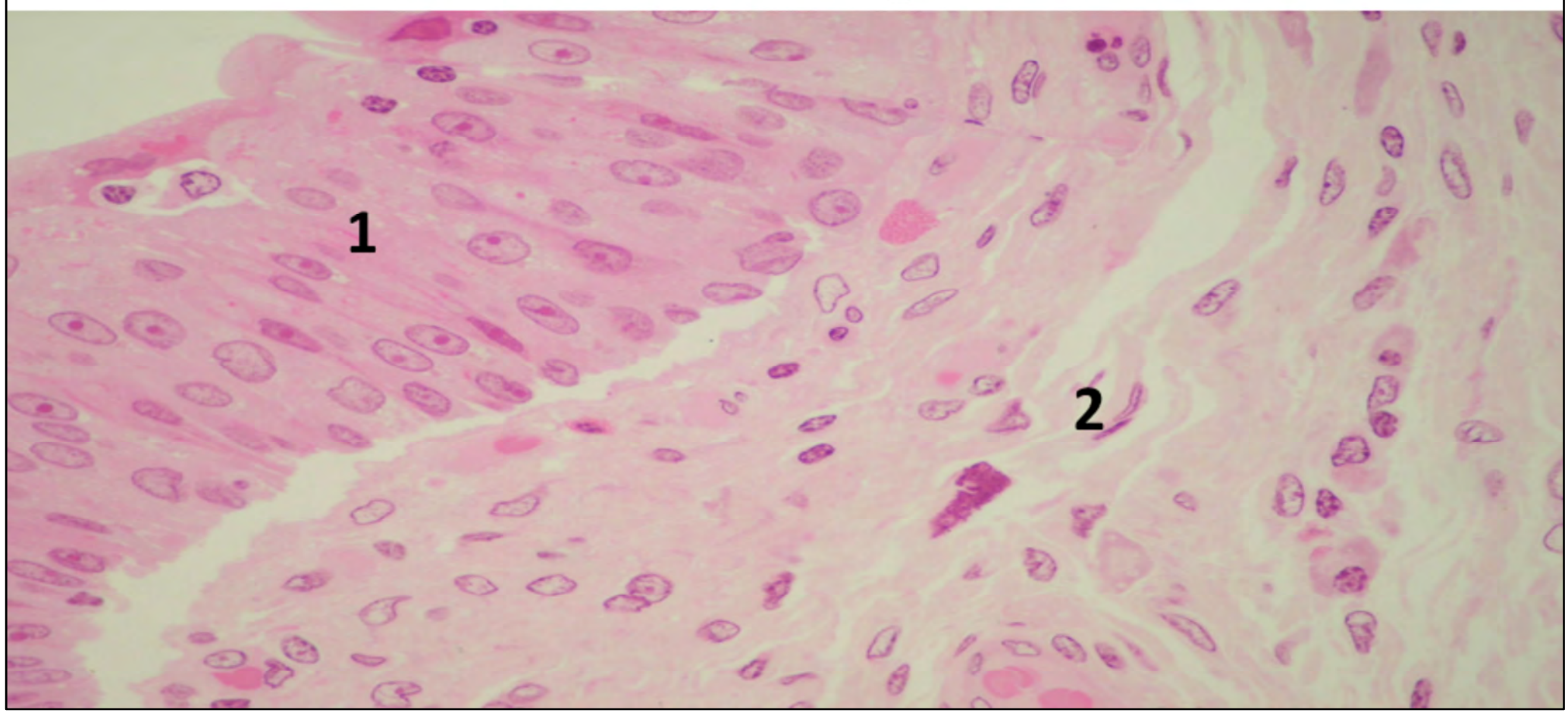

Transitional epithelium:

1- Mucosa lined by transitional epithelium:
- Dome-shaped cells

2- Lamina propria:
Wherever there's lamina propria, it carries out a defensive role. It contains plasma cells, phagocytic cells and other immune cells. If a microbe gains entry into the bladder or the ureter, these cells in the lamina propria will try to defend against it.

Characteristics of Transitional Epithelium

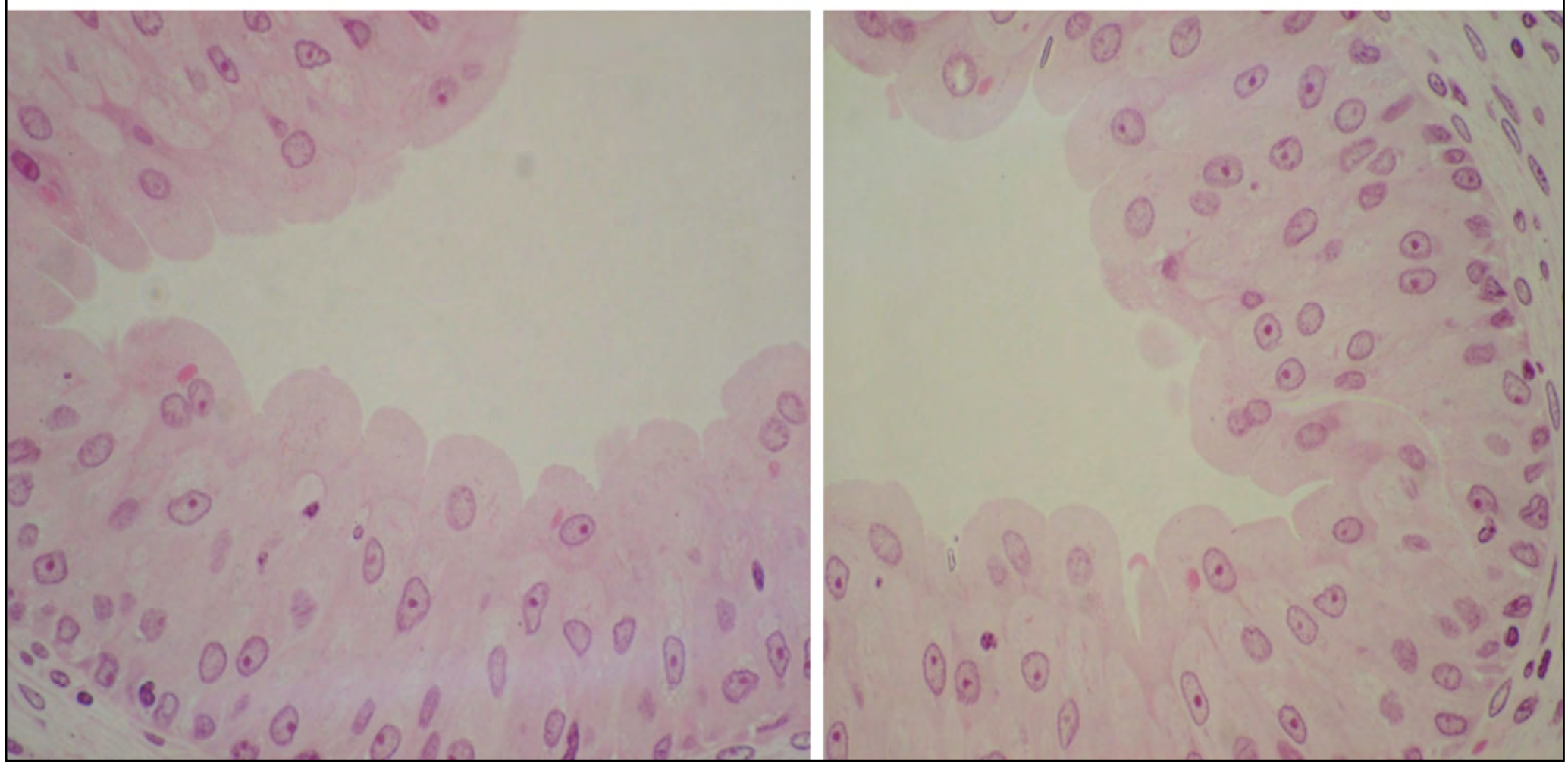

Transitional epithelium in the relaxed phase (when the bladder is empty).

Characteristics of the transitional epithelium:
1- The are capable of changing their shape when the bladder is filled with urine.

2- The most important feature of transitional epithelium is the thick plasmalemma. What's the significance of this?

The urine reaches the urinary bladder as a hypertonic solution
→ A- This hypertonic urine is surrounded by isotonic medium in the blood vessels in the wall of the urinary bladder. If the plasma membrane was not thick enough, osmotic equilibration will occur by movement of water from the blood vessels into the bladder. This will cause loss of blood volume, as well as diluting urine. To avoid this, the plasma membrane is thick to prevent this undesirable movement of water.
→ B- This hypertonic urine contains concentrated toxic substances (drugs, urea, .. etc), that if allowed to enter the cells will injure them. To avoid this, the plasma membrane is thick to prevent the passage of toxic substances into the cells.

Muscularis and Serosa

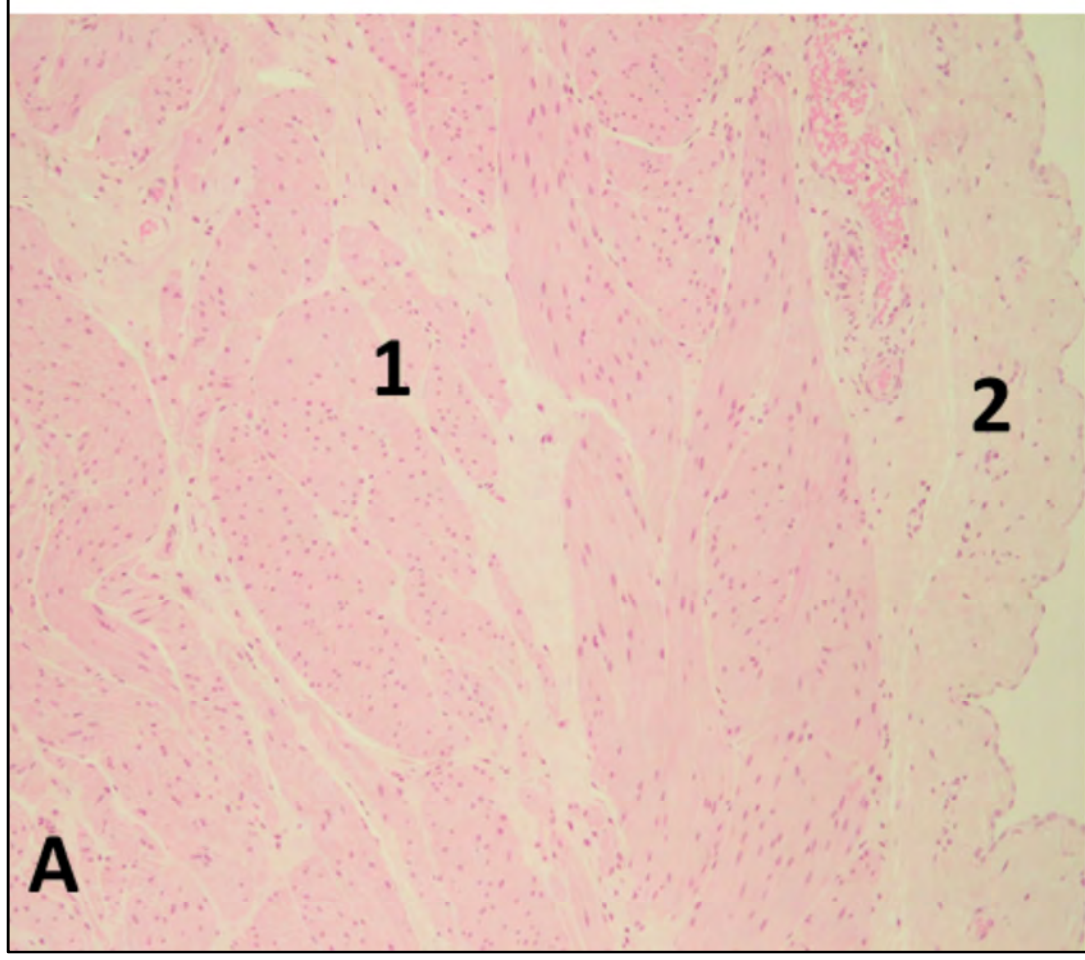

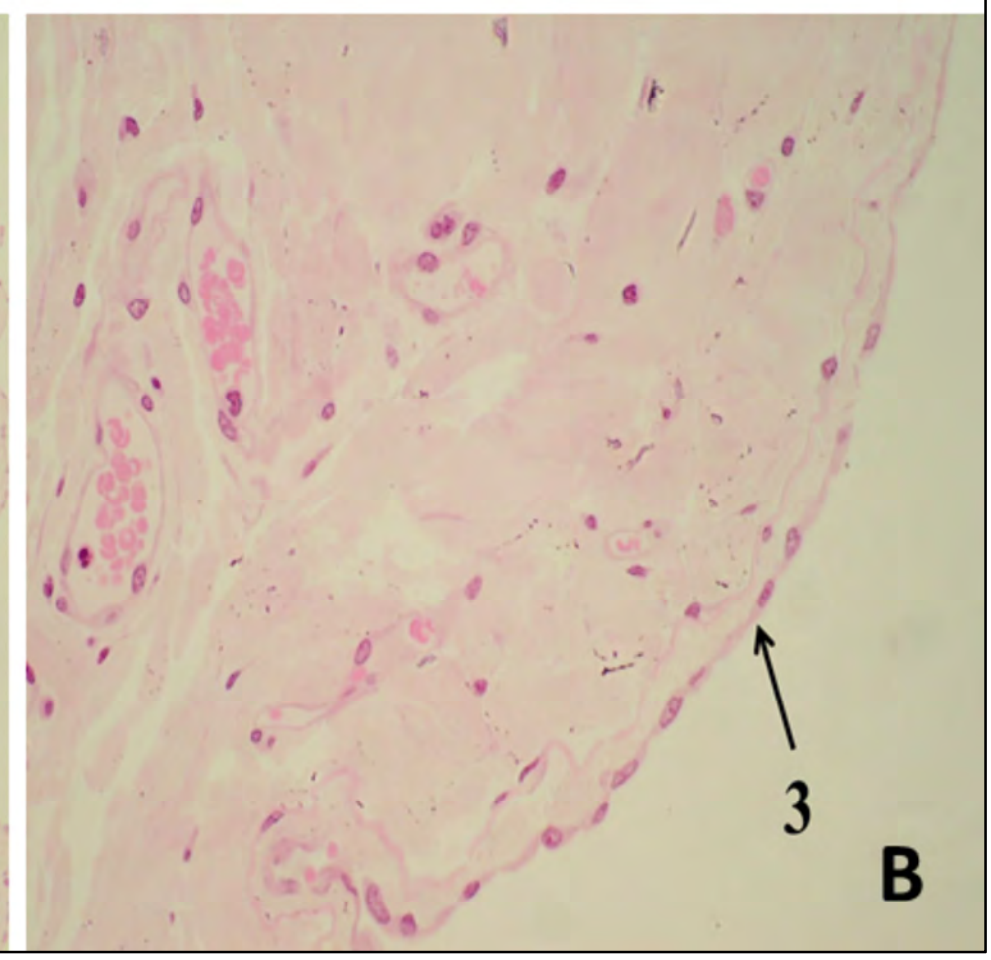

Structures shown in these sections:

A:
1- The muscularis layer.
- Consists of three layers of smooth muscle (inner longitudinal, middle circular and outer longitudinal). These layers are poorly delineated and seem to be sometimes irregularly arranged.
- These three layers are collectively called the detrusor muscle, which contract to empty the bladder.

2- Serosa

B:
3- Serosa covering the superior surface of the bladder, and is lined by simple squamous epithelium.

Note: All the urinary passages are covered by an outer adventitial layer (a layer of connective tissue), except the anterior part of the ureter and the superior surface of the urinary bladder, which are covered by serosa (serous peritoneum formed of simple squamous epithelium).