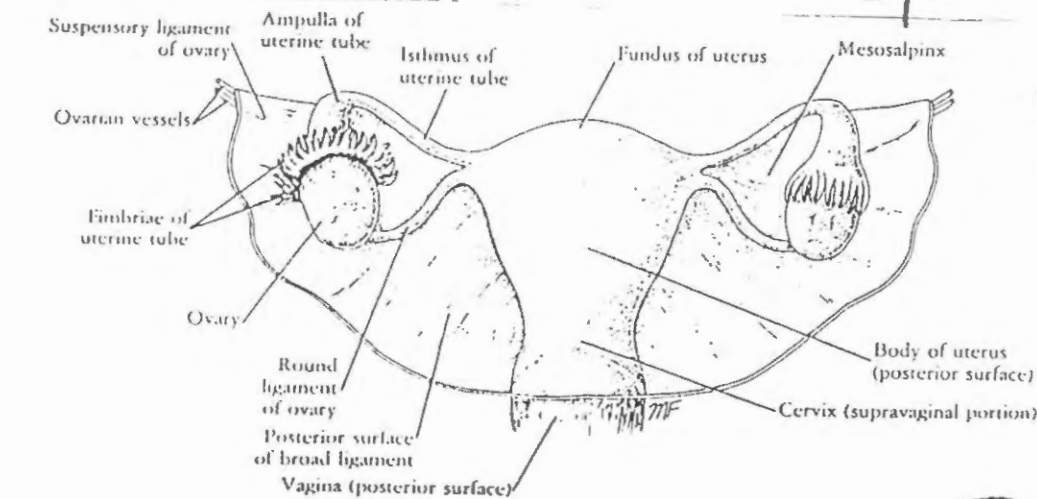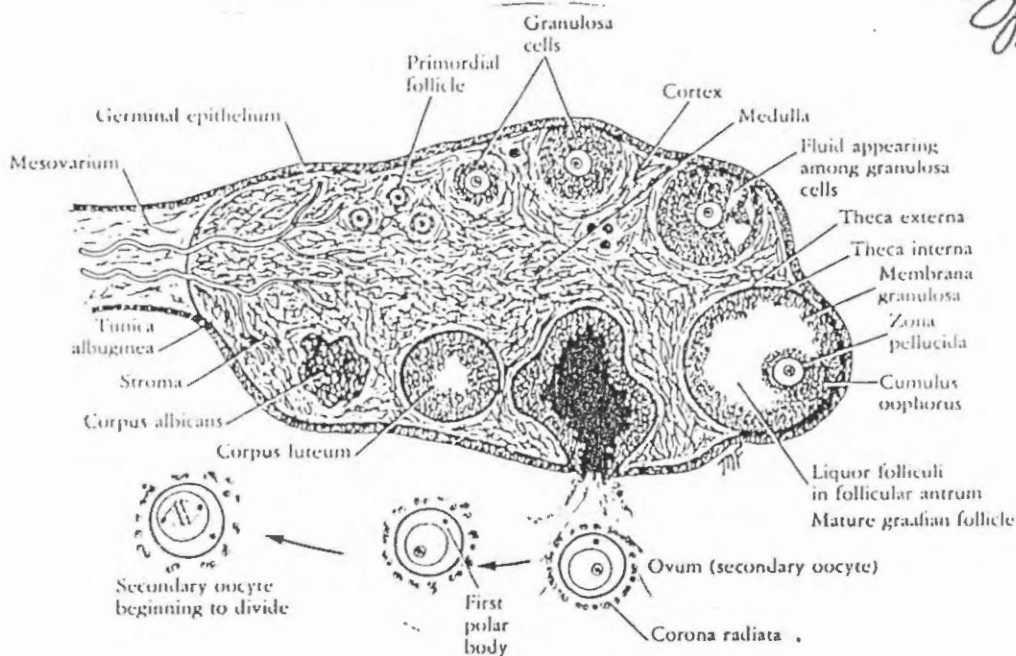


Abustami



Abustami

The female reproductive system consists of a pair of ovaries, a pair of uterine tubes, a uterus, a vagina, and the external genital organs. The structure of the mammary glands also will be described, because they undergo changes that are related to the reproductive system.

OVARIES

The ovaries are the organs responsible for the production of the female germ cells, the *ova*, and the female sex hormones, *estrogens* and *progesterone*, in the sexually mature female. Each ovary is an almond-shaped organ measuring 1.5 x .75 inches (4 x 2 cm) and is attached to the back of the broad ligament by the *mesovarium* (Figs. 15-1 and 15-2). Usually the ovary lies with its long axis vertical, but it shares in any movement of the broad ligament and uterus. The ovary is suspended from the lateral wall of the pelvis by that part of the broad ligament that extends between the mesovarium and the lateral pelvic wall; this structure is known as the *suspensory ligament* of the ovary and contains the ovarian vessels and nerves. The *round ligament* of the ovary lies

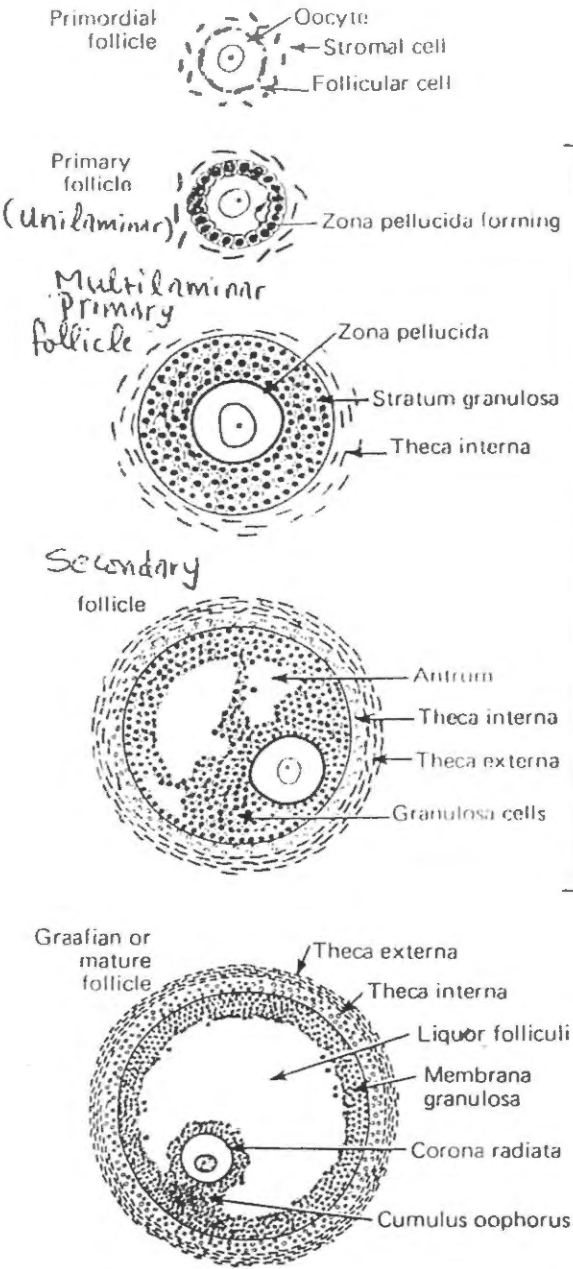
within the broad ligament and connects the medial margin of the ovary to the lateral wall of the uterus.

The ovaries are surrounded by a thin fibrous capsule, the *tunica albuginea* (Fig. 15-3). This capsule is covered externally by a single layer of cuboidal cells called the *germinal epithelium* (Fig. 15-4; see Fig. 15-3). The term *germinal epithelium* is a misnomer, because the layer does not give rise to ova. The germinal epithelium is a modified area of peritoneum and is continuous with the squamous mesothelial cells of the general peritoneum at the hilus of the ovary, where the mesovarium is attached. The ovary has an *outer cortex* and an *inner medulla*, but the *division between the two is ill defined*. The compact connective tissue *stroma* of the cortex is composed of a network of *reticular fibers* and spindle-shaped cells (see Fig. 15-4). The *stromal cells may be responsible for the secretion of androgens*. The connective tissue stroma of the medulla is very vascular and contains elastic fibers and smooth muscle fibers. *Embedded in the stroma of the cortex are the ovarian follicles, in different stages of development and degeneration* (Fig. 15-5; see Fig. 15-3).

of Sustami

ovarian follicles

(25)



→ Located in the cortex of the ovary

→ deep to the tunica albuginea

→ consist of an IMMATURE OVUM enclosed by one or more layers of Epithelial cells

→ At birth → 300,000 - 400,000
↓
few of these reach maturity & become ovulated

→ During the menstrual cycle → several follicles begin to grow & develop
↓
ONLY ONE attains → full maturity
THE REST → degenerate

Primordial follicle → Unilaminar Primary follicle


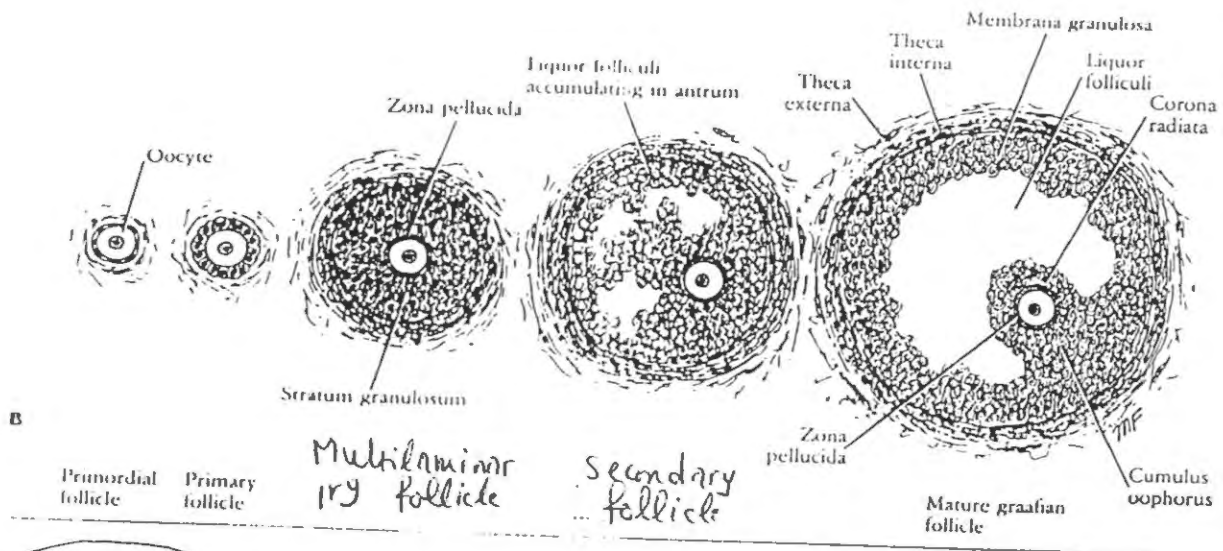
→ Present at the periphery of the cortex just beneath the tunica albuginea

→ consist of

- immature ovum → 1st oocyte suspended in the diplotene stage of the Prophase of 1st meiotic division
- surrounded by a SINGLE layer of flattened follicular cells which rest on a basement membrane

→ AS it develops into a Primary follicle → changes occur in the

- ovum
- follicular cells
- C-T. stroma of cortex

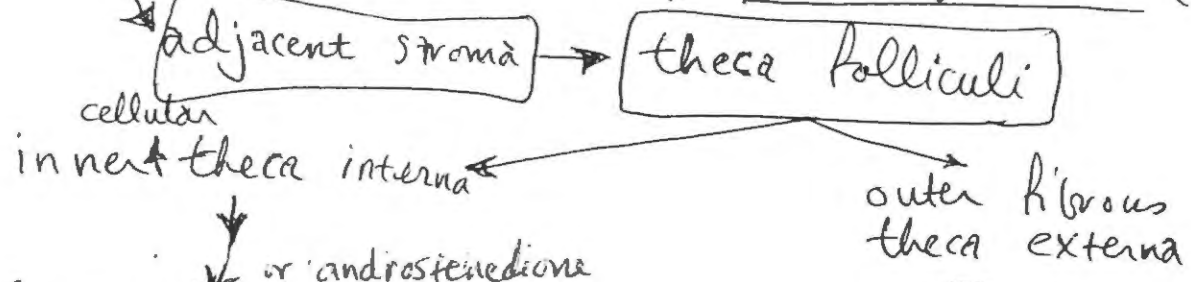


Oocyte increase in size,
↑ in No. of Golgi, RER, ribosomes

a clear refractile glycoprotein membrane
→ the Zona pellucida ← develop between
the oocyte & the adjacent follicular cells
→ the flattened follicular cells → become
Cuboidal or columnar

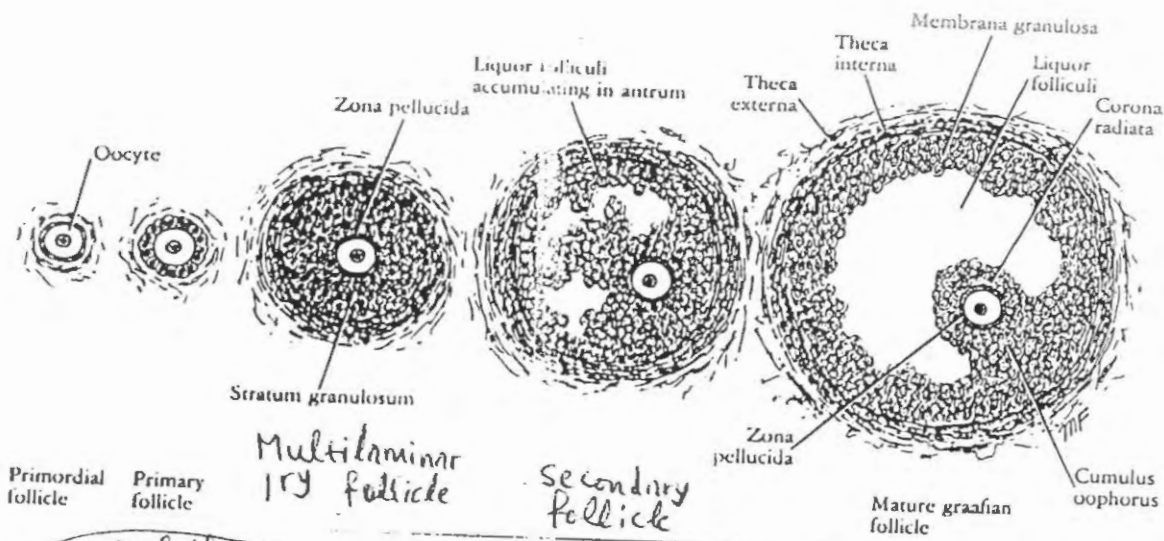
Proliferate to form
several layers of cells → Multilaminar primary follicle

granulosa cells → Stratum granulosum (vascular)



Synthesize testosterone which diffuses
from the theca cells to the nearby granulosa
cells which contain AROMATASE
In the granulosa cells, testosterone is
converted to 17β-estradiol

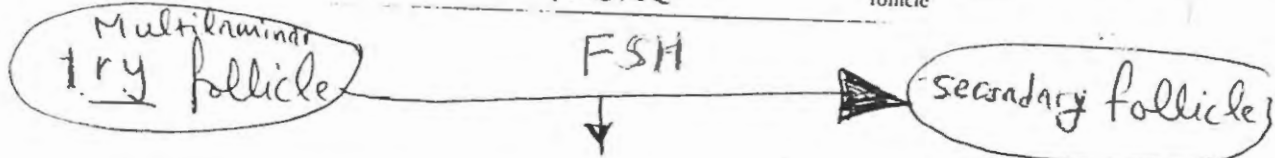
LH stimulates
cholesterol desmolase
in the theca cells
FSH stimulates
aromatase in the
granulosa cells.



(27)
Dr. Bustami
Histology & Refrac
1999

(27)
Bustami

Bustami



- * gradually comes to lie deeper in the cortex
- * irregular spaces filled with clear fluid = liquor folliculi = appear among the granulosa cells

The spaces later coalesce to form a single cavity
 → the **FOLLICULAR ANTRUM**



- the follicle continue to ↑ in size (in part due to continued accumulation of liquor folliculi)
- the OVUM now occupies an **ECCENTRIC** position in the follicle surrounded by a mass of granulosa cells that project into the fluid-filled antrum as the → **CUMULUS OOPHORUS** ←
- the cells that line the cavity make up the **MEMBRANA GRANULOSA**
- the granulosa cells that surround the oocyte form the **CORONA RADIATA**
- the cells of the theca interna → have the cytologic features of steroid-secreting cells secrete androgens
- After 10-14 days of growth → G. follicle measures about 10 mm in diameter

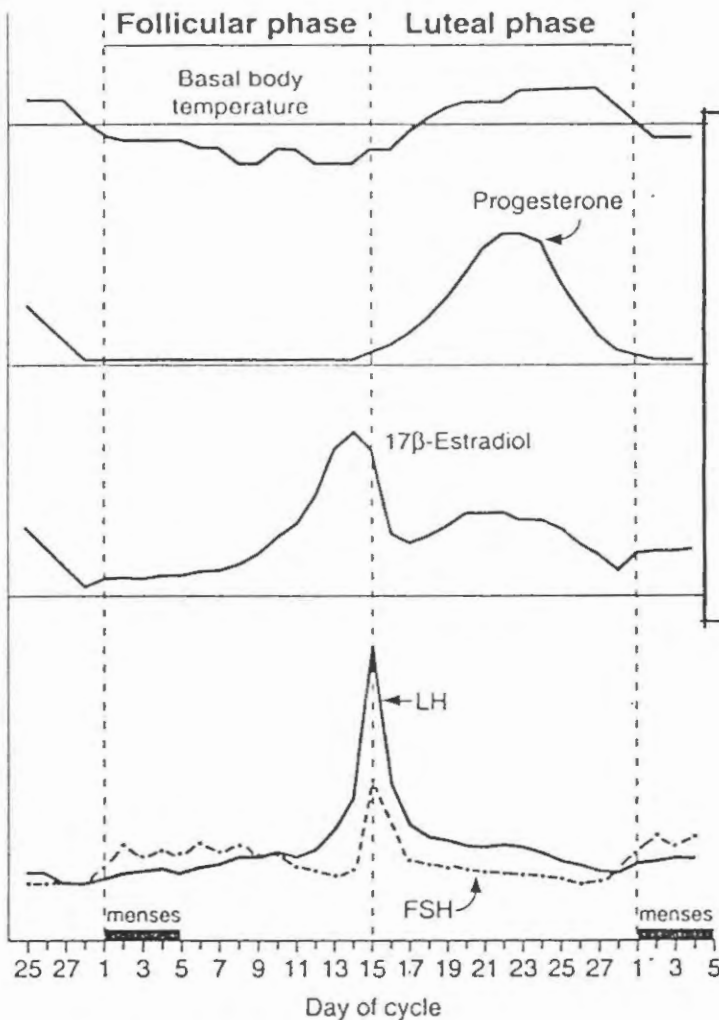
E. Menstrual cycle (Figure 7-19)

1. Follicular phase (days 5–14)

- A **primordial follicle** develops to the graafian stage with atresia of the neighboring follicles.
- LH and FSH receptors are induced in theca and granulosa cells so that they can stimulate synthesis of androgen (LH, theca cells) and estradiol (FSH, granulosa cells).
- Estradiol levels steadily increase** and cause **proliferation of the uterus**.
- FSH and LH levels are suppressed** by negative feedback of estradiol on the anterior pituitary.
- Progesterone levels are low.

28

of Sustan.



Events of the Menstrual Cycle

The menstrual cycle recurs approximately every 28 days over the reproductive period of the female: from puberty until menopause. The events of the cycle include development of an ovarian follicle and its oocyte, ovulation, preparation of the reproductive tract to receive the fertilized ovum, and shedding of the endometrial lining if fertilization does not occur. Cycle length can vary from 21–35 days, but the average length is 28 days. The variability in cycle length is attributable to variability in the duration of the follicular phase; the luteal phase is constant. The hormonal changes and events of a 28-day menstrual cycle are illustrated in Figure 10–10 and described in the following steps. *By convention, day 1 marks the onset of menses from the previous cycle.*

Figure 7-19. The menstrual cycle.

2. Ovulation (day 15)

- occurs 14 days prior to menses, regardless of cycle length. Thus, in a 35-day cycle, ovulation occurs on day 21.
- A burst of estradiol synthesis at the end of the follicular phase has a **positive feedback** effect on secretion of FSH and LH (**LH surge**).
- Ovulation** occurs as a result of the **estrogen-induced LH surge**.
- Estrogen levels fall just after ovulation (but rise again in the luteal phase).
- Cervical mucus** increases in quantity; it becomes less viscous and more penetrable by sperm.

3. Luteal phase (days 15–28)

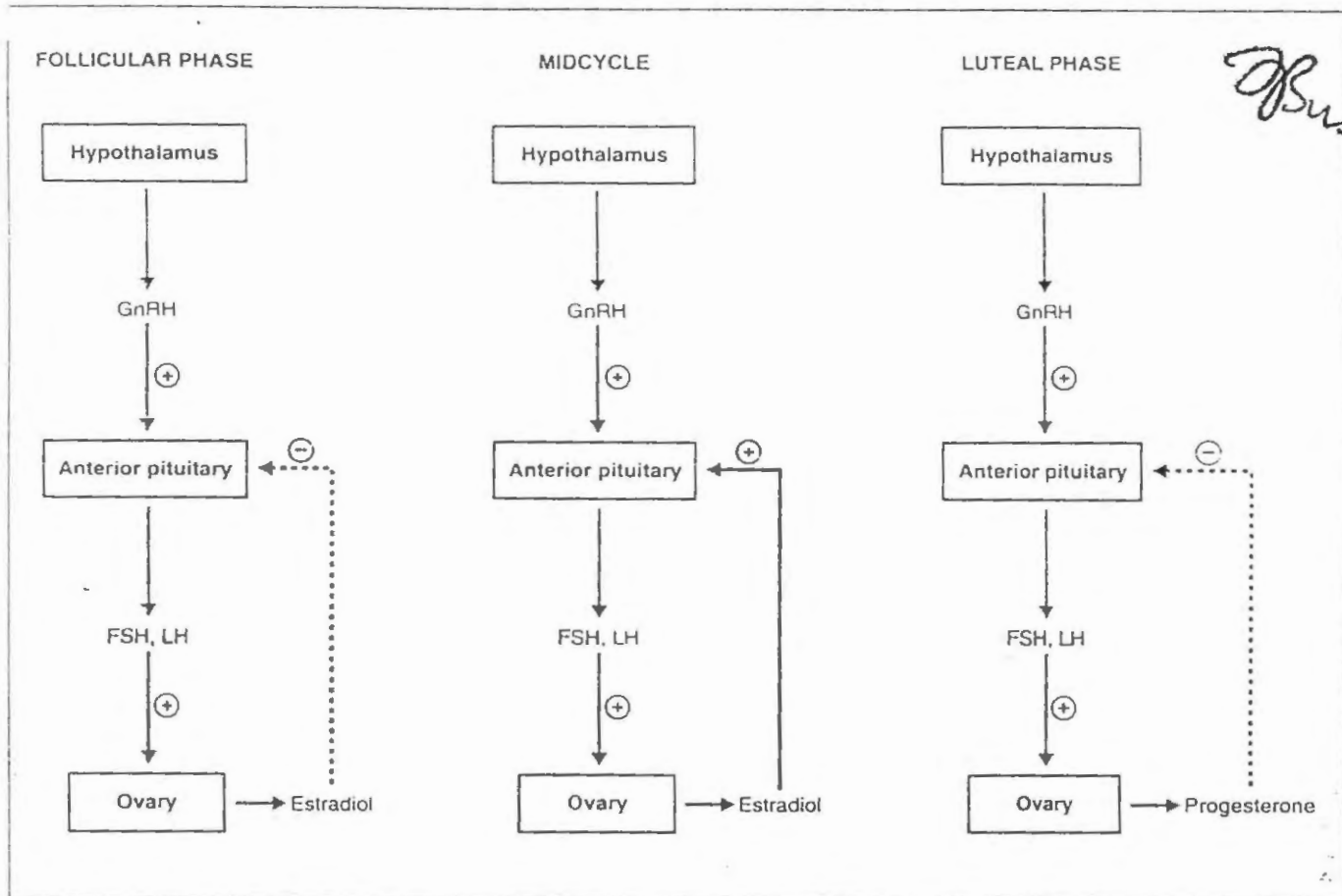
- Development of the **corpus luteum** begins, and it synthesizes **estrogen and progesterone**.
- There is **increased vascularity and secretory activity** of the **endometrium** to prepare for receipt of a fertilized egg.
- Basal body temperature** increases because of progesterone's effect on the hypothalamic thermoregulatory center.

- If fertilization does not occur, the corpus luteum regresses. As a result, there is an abrupt decrease in estradiol and progesterone levels.

29

4. Menses (days 1-4)

- The endometrium is sloughed because of the withdrawal of estradiol and progesterone (During this time, Primordial follicles for the next cycle are being recruited and are beginning to develop)



of Sustains

FIGURE 10-9. Control of follicle-stimulating hormone (FSH) and luteinizing hormone (LH) secretion in females during the menstrual cycle. The follicular and luteal phases are characterized by negative feedback of estradiol and progesterone, respectively, on the anterior pituitary. Midcycle is characterized by positive feedback of estradiol on the anterior pituitary. GnRH, gonadotropin-Negative and Positive Feedback

In females, the hypothalamic-pituitary axis is controlled by both negative and positive feedback, depending on the phase of the menstrual cycle (Figure 10-9).

- In the follicular phase, FSH and LH stimulate synthesis and secretion of estradiol by follicular cells. One of the actions of estradiol is negative feedback on the anterior pituitary cells to inhibit further secretion of FSH and LH. Thus, the follicular phase is dominated by estradiol and is regulated by negative feedback.

At midcycle, the pattern changes. Estradiol levels rise sharply as a result of the proliferation of follicular cells and the stimulation of estradiol synthesis that occurred during the follicular phase. When a critical level of estradiol is reached (of at least 200 picograms per milliliter of plasma), estradiol has a positive feedback effect on the anterior pituitary, causing further secretion of FSH and LH. This burst of hormone secretion by the anterior pituitary, called the ovulatory surge of FSH and LH, then triggers ovulation of the mature oocyte.

In the luteal phase, the major hormonal secretion of the ovaries is progesterone. One of the actions of progesterone is negative feedback on the anterior pituitary to inhibit secretion of FSH and LH.

FSH → the granulosa cells are the only ovarian cells with FSH receptors
 ↳ initial action: stimulates the growth of granulosa cells in primary follicles and stimulate estradiol synthesis
 the locally produced estradiol then supports the growth effects of FSH on follicular cells

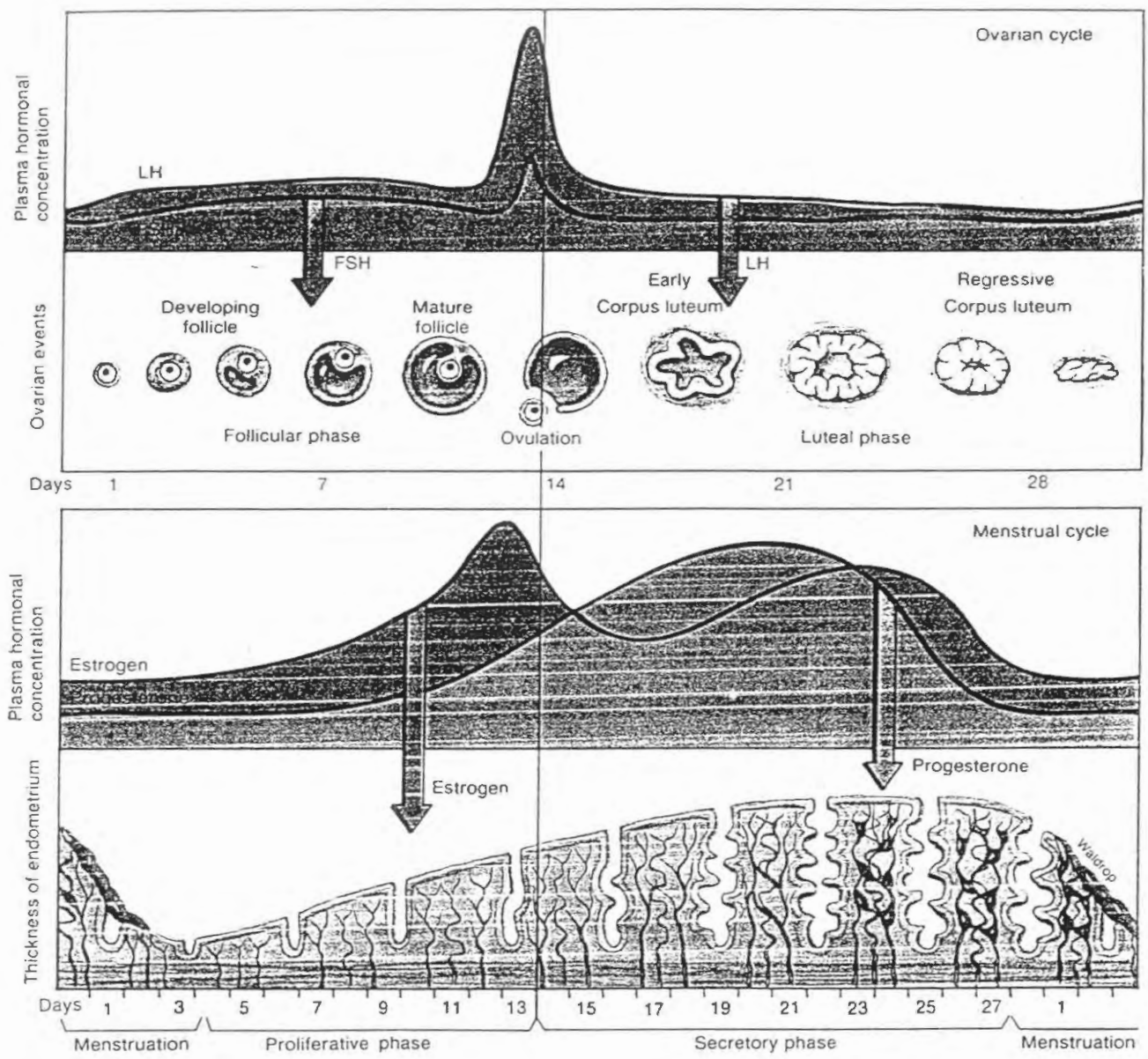
* More cells (by FSH) → more estradiol (by cells) → more cells (by estradiol)

LH → ovulation is initiated by LH
 ↳ just before ovulation, the concentration of LH in blood rises sharply & induces rupture of the dominant follicle, releasing the oocyte
 ↳ also stimulates formation of the corpus luteum → a process called luteinization
 ↳ maintains steroid hormone production by the corpus luteum during the luteal phase of the menstrual cycle

30

Dr. S. K. Singh

Figure 28.15. Phases of the menstrual cycle in relation to ovarian changes and hormone secretion, and the relationship between changes in the ovaries and the endometrium of the uterus during different phases of the menstrual cycle

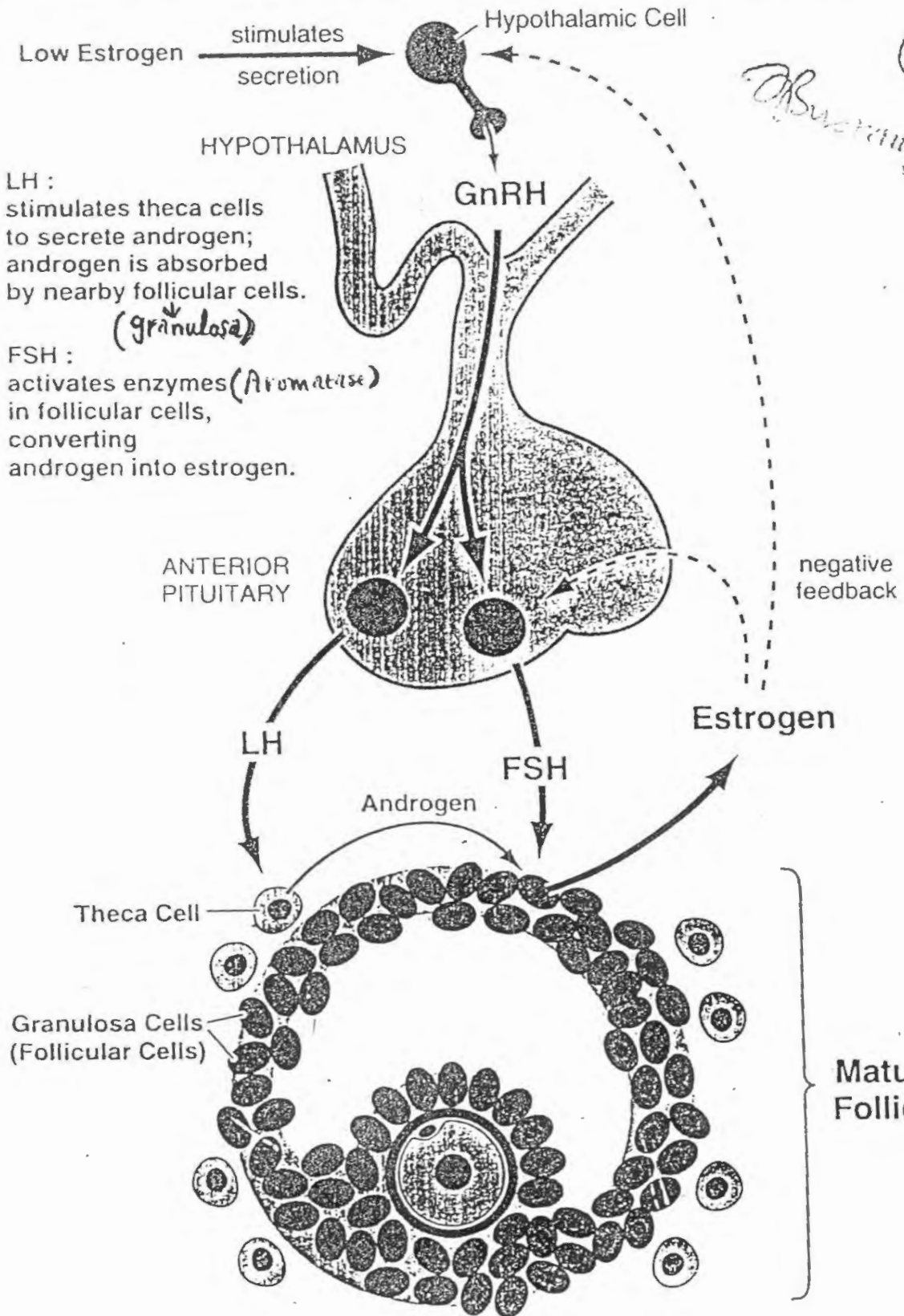


Phase of cycle		Hormonal changes		Tissue changes	
Ovarian	Endometrial	Pituitary	Ovary	Ovarian	Endometrial
Follicular (days 1-4)	Menstrual	FSH and LH secretion low	Estradiol and progesterone remain low	Primary follicles grow	Outer two-thirds of endometrium is shed with accompanying bleeding
Follicular (days 5-14)	Proliferative	FSH slightly higher than LH secretion in early follicular phase	Estradiol secretion rises (due to FSH stimulation of follicles)	Follicles grow; vesicular ovarian follicle develops (due to FSH stimulation)	Mitotic division increases thickness of endometrium; spiral arteries develop (due to estradiol stimulation)
Ovulatory (day 15)	Proliferative	LH surge (and increased FSH) stimulated by positive feedback from estradiol	Fall in estradiol secretion	Vesicular ovarian follicle is ruptured and ovum is extruded into fallopian tube	No change
Luteal (days 16-28)	Secretory	LH and FSH decrease (due to negative feedback of steroids)	Progesterone and estrogen secretion increase, then fall	Development of corpus luteum (due to LH stimulation); regression of corpus luteum	Glandular development in endometrium (due to progesterone stimulation)

FEMALE REPRODUCTIVE HORMONES

(31)

Abhishek



LH : stimulates theca cells to secrete androgen; androgen is absorbed by nearby follicular cells.

(granulosa)

FSH : activates enzymes (Aromatase) in follicular cells, converting androgen into estrogen.

ANTERIOR PITUITARY

negative feedback

LH

FSH

Androgen

Estrogen

Theca Cell

Granulosa Cells (Follicular Cells)

Mature Follicle

OVULATION (day 15)

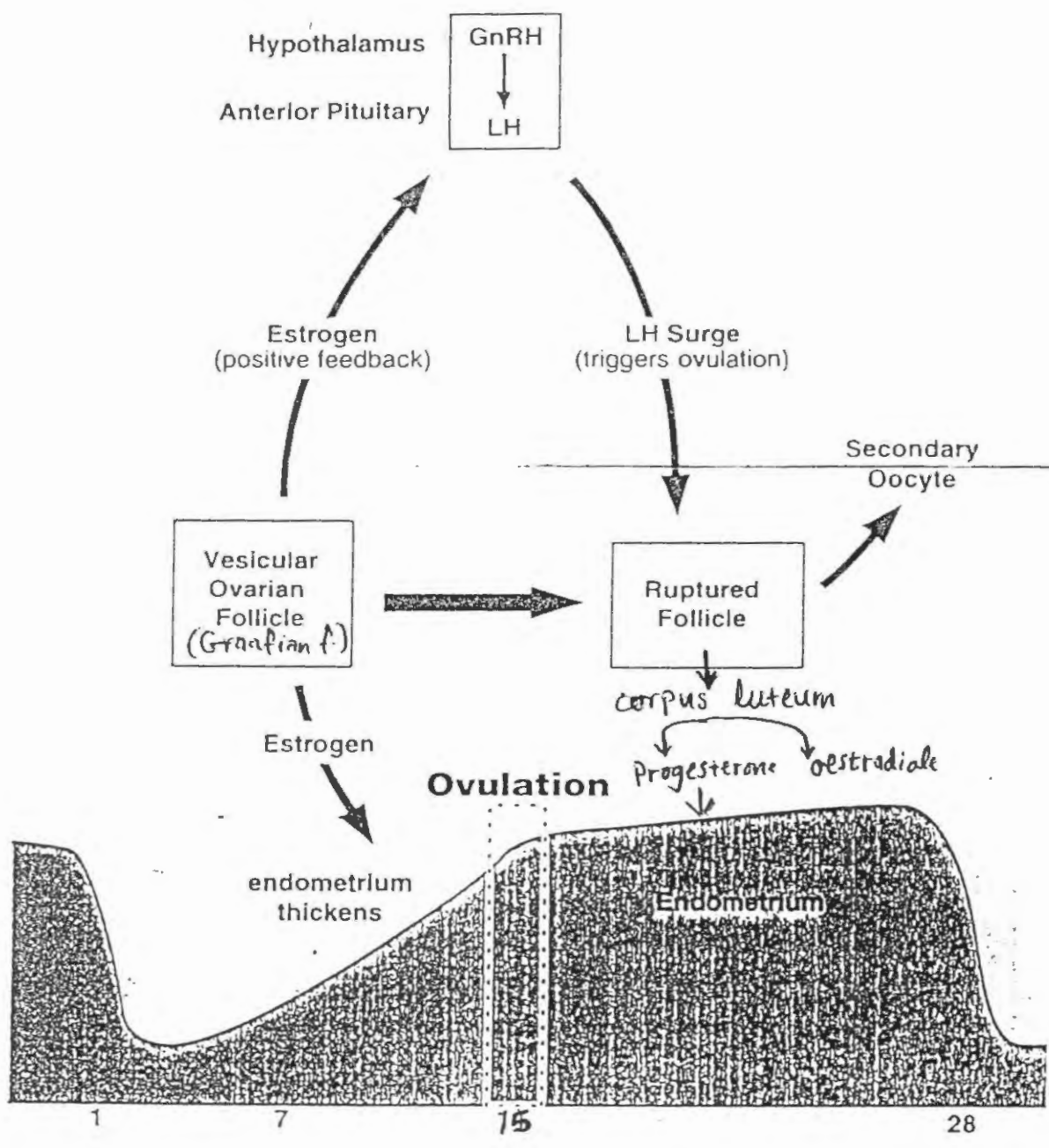
Hypothalamus : GnRH released; stimulated by high levels of estrogen.

Anterior Pituitary : LH released in large quantities (called the LH surge).

Ovary : LH surge triggers ovulation.

Vesicular ovarian follicle ruptures, releasing the secondary oocyte.

Uterus : Endometrium thickens; stimulated by high levels of estrogen.



Follicular atresia (degeneration)

Dr. Bustami
1999

(33)

may occur at any stage in the development of the ovum

Bustami

In an atretic primary follicle

ovum shrinks, degenerates & undergoes cytolysis
follicular cells show similar degenerative changes
→ follicle is resorbed


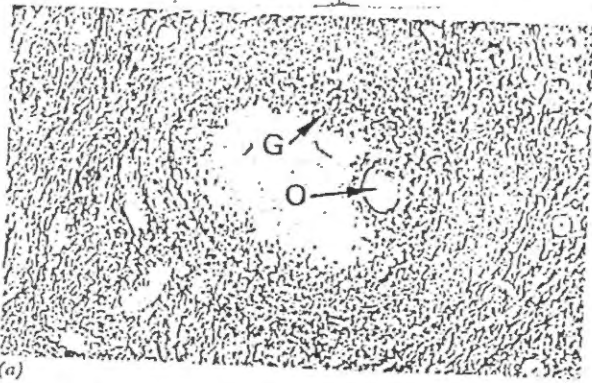


Fig. 19.10 Atretic follicles

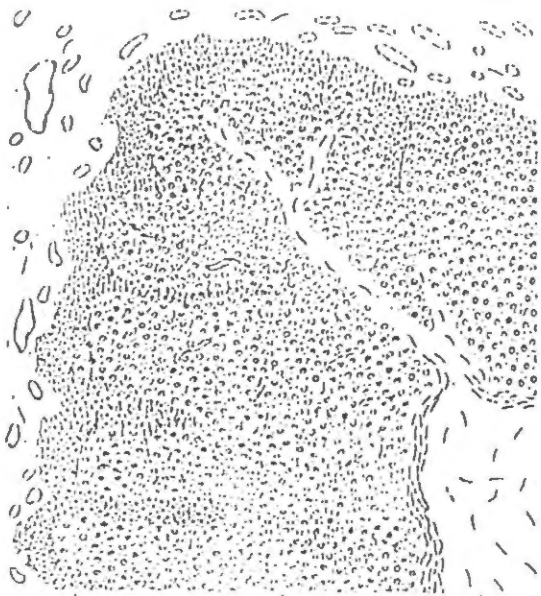
In larger follicles

→ Zona pellucida may persist for a time after dissolution of the oocyte & follicular cells

→ cells of the theca interna remain for a longer time than do those of the stratum granulosum → form cord-like arrangement

→ The basal lamina between the granulosa cells and theca interna forms a hyalinized layer → the glassy membrane → characteristic of atretic growing follicle

→ ultimately → the degenerated remains of the follicle are removed & a scar resembling a small corpus albicans results



Theca lutein cells Granulosa lutein cells Connective tissue



Dr. Bustamam
1999
34

Bustamam

CORPUS LUTEUM



Following ovulation $\left\{ \begin{array}{l} \text{Granulosa cells} \\ \text{theca interna} \end{array} \right\}$ that remain in the ovary

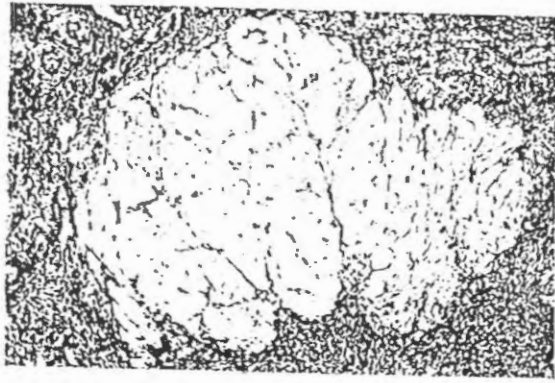


Under the influence of luteinising hormone \rightarrow form a temporary endocrine gland \rightarrow corpus luteum



- ① The walls of the follicle collapse
- ② Stratum granulosum \rightarrow thrown into folds
- ③ Bleeding from the capillaries in the theca interna may result in the formation of blood clot in the centre of the corpus luteum.

- * ④ **Granulosa cells**
- \rightarrow luteal
 - Produce Progesterone
 - Convert androgens produced by theca lutein cells into estrogen
- $\left\{ \begin{array}{l} \uparrow \text{ in size} \\ \text{become polyhedral} \\ \text{lipid accumulate in cytoplasm} \end{array} \right\}$ large amount of pale-stained vacuolated cytoplasm
- \uparrow SER, mitochondria
- ⑤ **Luteal cells** - smaller, less vacuolated cytoplasm
- Secrete progesterone, androgens, estrogens
- ⑥ Capillaries & C.T \rightarrow penetrate the mass of lutein cells & form a network around them
- ⑦ fully formed corpus luteum \rightarrow secrete both $\left\{ \begin{array}{l} \text{oestrogen} \\ \text{progesterone} \end{array} \right.$



CORPUS ALBICANS (dominant feature in human ovary)

If the ovum is (not) fertilized → the corpus luteum persists for about 14 days & then undergoes involution — cells ↓ in size

- accumulate much lipid & degenerate
- Hyaline material accumulates between the lutein cells
- C.T. cells become pyknotic (i.e. with condensed nuclei)

Corpus luteum gradually is replaced by an irregular white scar → disappears over the following months

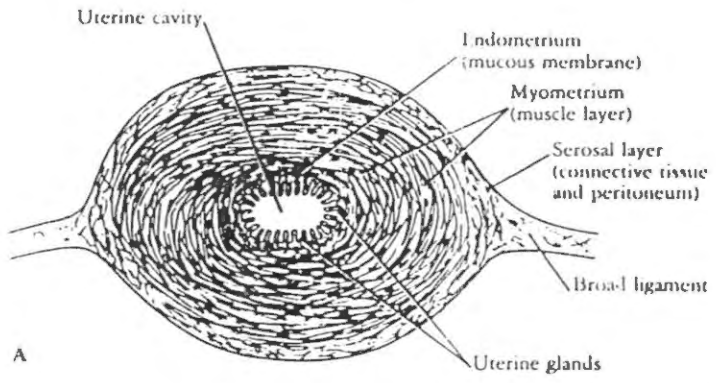
Fibroblasts enter, manufacture type I collagen & form a fibrous scar known as corpus albicans

Uterine wall → Perimetrium → a layer of squamous mesothelial cells resting on areolar tissue

→ Myometrium (muscular wall) → very thick composed of smooth muscle fibres and connective tissue

→ Endometrium (mucous membrane) → muscle fibres INTERLACE in many directions

36



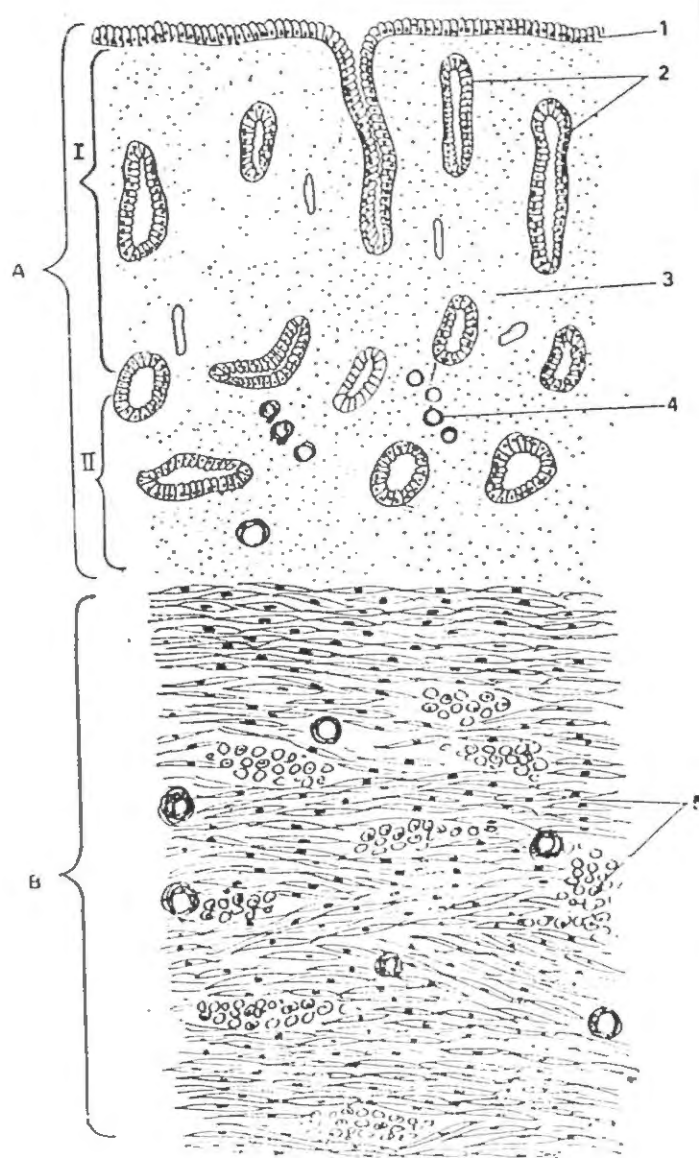
internal → thin longitudinal, thin circular

middle → thickest longitudinal, transverse

outermost → oblique, many blood vessels

mainly longitudinal

Shurani



The endometrium is a complex mucous membrane that, in the human female, undergoes cyclic changes in structure and function in response to the ovarian cycle. The cyclic activity begins at puberty and continues until menopause. In the body of the uterus, the endometrium consists of a thick lamina propria, the endometrial stroma, and a covering epithelium. The stroma resembles mesenchymal tissue and consists of stellate, loosely arranged stromal cells with large round or ovoid nuclei, supported by a fine connective tissue network in which lymphocytes, granular leukocytes and macrophages are present. The endometrial stroma lies directly on the myometrium to which it is firmly attached and there is no intervening submucosa.

The stroma is covered by a simple columnar epithelium that contains ciliated cells and nonciliated secretory cells. The epithelium dips down into the stroma to form numerous uterine glands which extend deeply into the stroma and occasionally penetrate into the myometrium. Most of the glands are simple tubular glands but some branching may occur near the muscle. A basement membrane underlies both the glandular and surface epithelium.

The endometrium can be divided into two layers: the stratum basale (basal layer) and the stratum functionale (functional layer). These differ in their structure, function and blood supply. The basal layer is narrower, more cellular and fibrous than the functional layer and lies directly on the myometrium. It undergoes few changes during the menstrual cycle and is not shed at menstruation, but rather serves as the source from which the functional layer is restored. The stratum functionale extends to the lumen of the uterus, and it is this portion of the endometrium in which cyclic changes occur and which is sloughed during menstruation. The stratum functionale is sometimes divided into the compacta, a narrow superficial zone, and the spongiosa, a broader zone that comprises the bulk of the functionalis.

Fig. 87.

- UTERUS: Follicular Phase = proliferative phase
1. Columnar epithelium — ciliated
 2. Uterine glands — non-ciliated
 3. Lamina propria (stroma)
 4. Coiled artery
 5. Smooth muscle fibres
- A. Endometrium
 B. Myometrium
 I. Functionalis
 II. Basalis

Read this part 1st

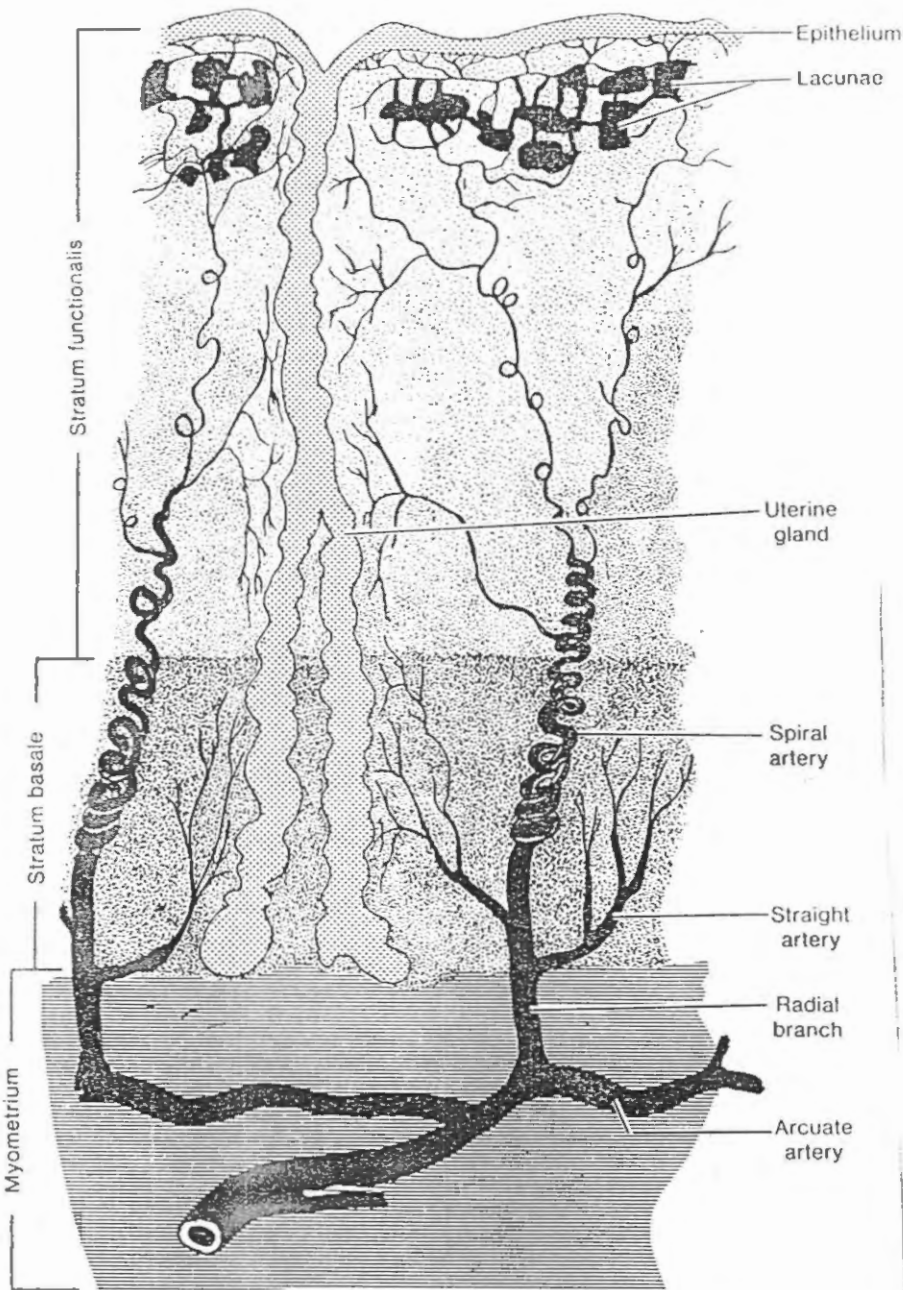


Figure 18-1 Arrangement of blood vessels in the endometrium.

Cyclic Changes in the Endometrium

KEY WORDS—proliferative, maturation of follicle, secretory phase, corpus luteum, ischemic (premenstrual) and menstrual stages

During the normal menstrual cycle, the endometrium undergoes a continuous sequence of changes in which four stages can be described. The stages correlate with the functional activity of the ovaries and constitute the proliferative, secretory, ischemic (premenstrual) and menstrual stages.

Ruorani

In the nonpregnant uterus the smooth muscle cells are about 30 to 50 μm in length but during pregnancy they hypertrophy to reach lengths of 500 to 600 μm or greater. During pregnancy there is production of new muscle from undifferentiated cells and possibly from division of mature cells also. In spite of the total increase in the muscle mass, the muscle layers are thinned during pregnancy as the uterus becomes distended. The connective tissue of the myometrium also increases in amount. Following delivery, the muscle cells rapidly diminish in size but the uterus does not regain its original nonpregnant dimensions.

The myometrium normally undergoes intermittent contractions which, however, are usually not of sufficient intensity to be perceived. The intensity of the contractions may increase during menstruation to result in cramp-like pains. The contractions are diminished during pregnancy, possible as the result of the hormone relaxin. At parturition strong contractions of the uterine musculature occur, as a result of which the fetus is expelled. Uterine contractions are increased following administration of oxytocin, a hormone produced by the neurohypophysis. They also are increased in response to prostaglandins, and a rise in the level of prostaglandins occurs just prior to delivery.

The blood supply of the endometrium is

unique and plays an important role in the events of menstruation. Branches of the uterine artery penetrate the myometrium to the middle layer where they provide the arcuate arteries which run circumferentially in the myometrium. One set of branches from these arteries supplies the superficial layers of the myometrium, while radial branches pass inward to supply the endometrium. At the junction of myometrium and endometrium the radial branches provide a dual circulation to the endometrium. Straight arteries supply the stratum basale, while the stratum functionalis is supplied by highly contorted coiled arteries. As the latter pass through the functional layer, they provide terminal arterioles which then unite with a complex network of capillaries and thin walled dilated vascular structures, the lacunae. The venous system also forms an irregular network of venules and veins with irregular sinusoidal enlargements, then drains into a plexus at the junction of myometrium and endometrium. During the menstrual cycles the spiral arteries constrict periodically so that the functional layer is subjected to intermittent periods of blanching. The distal portion of the arterial supply in the functionalis undergoes degeneration and regeneration with each menstrual cycle, whereas the straight arteries of the basal layer show no such changes. *

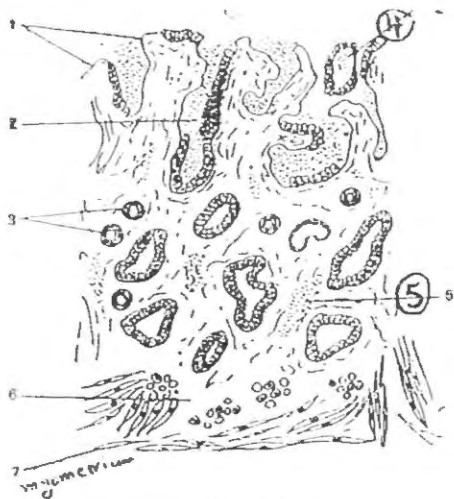
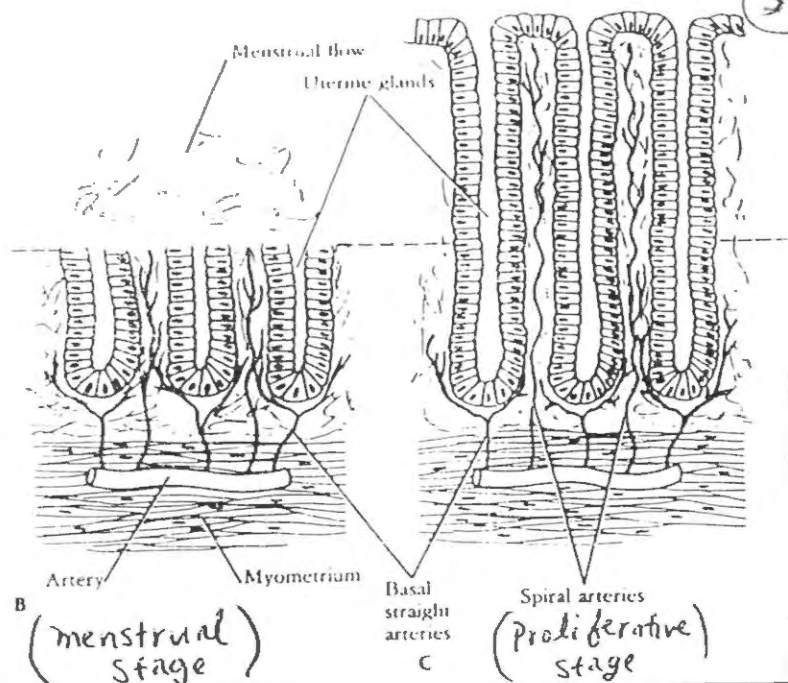


Fig. 89. ↑

Uterus : Menstrual Phase

1. Superficial endometrium without epithelium
2. Glandular lumen filled with blood
3. Coiled arteries
4. Fragments of disintegrated mucosa
5. Erythrocytes in lamina propria
6. Inter glandular lamina propria of basal region



Menstrual cycle divided into → Menstrual phase
 → Proliferative (Follicular) "
 → Secretory (Luteal) "

Menstrual phase (Day 1 to 4)

- Main change → desquamation of the functionalis layer of the endometrium

- when fertilization does not take place → the corpus luteum becomes non functional about 14 days after ovulation thus REDUCING THE LEVELS OF PROGESTERONE & OESTROGEN

of Busrani

A couple of days before ↓ bleeding begins → the functionalis layer of the endometrium becomes deprived of blood as the spiral (helical) arteries constrict intermittently

After 2 days the spiral ↓ arteries become Permanently constricted

- * The functionalis layer becomes ischemic → necrotic → & shed
- * The spiral arteries also become necrotic & rupture → blood accumulate deep to mucosa → further shed of functionalis layer

Proliferative stage (Follicular phase) → (days 4-14) (38) B

Main change → Regeneration & Repair of the endometrium

- ↓
- * Begins when the menstrual flow ceases on about day 4 & continues through day 14
 - * during this phase the functional layer becomes much thicker (up to 2-3 mm) because of Proliferation of cells at the base of the glands (that remain unaffected during the menstrual phase, because their blood supply was intact) ① the endometrial glands increase in number & in length ② glycogen accumulate at the base of the glands ③ spiral arteries lengthen & do not extend into the superficial $\frac{1}{3}$ of endometrium

Proliferative phase → corresponds to maturation of ovarian follicle up to the time of ovulation

↓

Secretion of estrogen by the developing follicles stimulates growth of the endometrium

Secretory phase (luteal phase) → Days 15-28

of Strömli

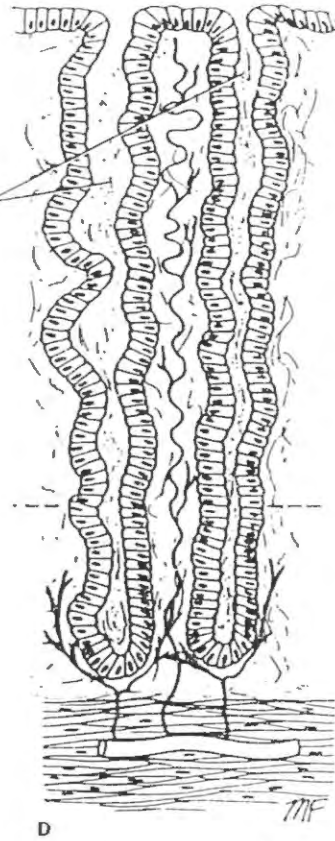
- commences after ovulation
- the endometrium continues to increase in thickness as a result of
 - hypertrophy of glandular cells (store glycogen, first in base of cell → apex → lumen)
 - stromal edema
 - increased vascularity
- Spiral arteries extend into the superficial part of endometrium glands ↑ in length & become tortuous
- The secretory phase is associated with the development of the corpus luteum & is maintained as long as the corpus luteum remains functional.

↓

Progesterone secreted by the corpus luteum is responsible for the secretory changes in the endometrial lining

The onset of menstrual cycle coincides with the beginning involution of the corpus luteum

Long tortuous glands distended with secretion



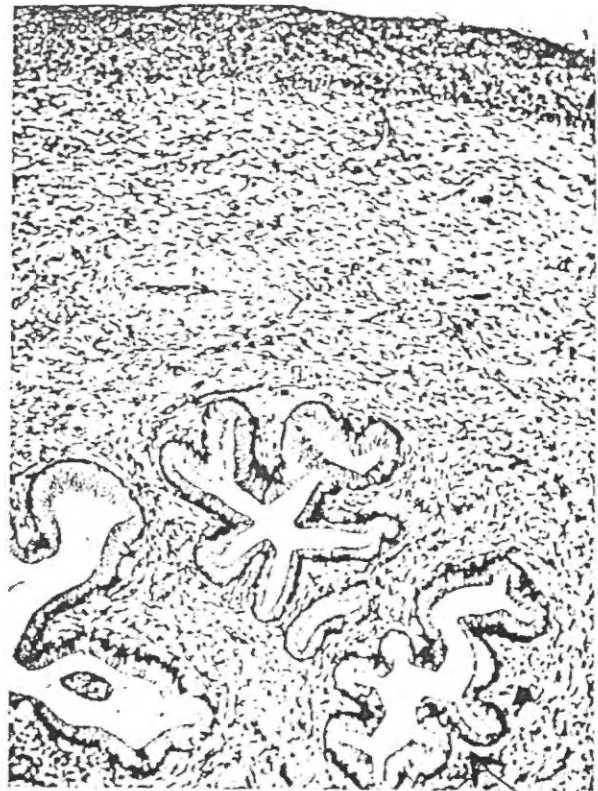
(Secretory phase)

(38)c

The menstrual discharge ??

- consists of
- ① arterial & venous blood
 - ② degenerated epithelial & stromal cells
 - ③ glandular secretion

Bustani



Bustan
151. 9 Reprint
1999
(39)
Bustan

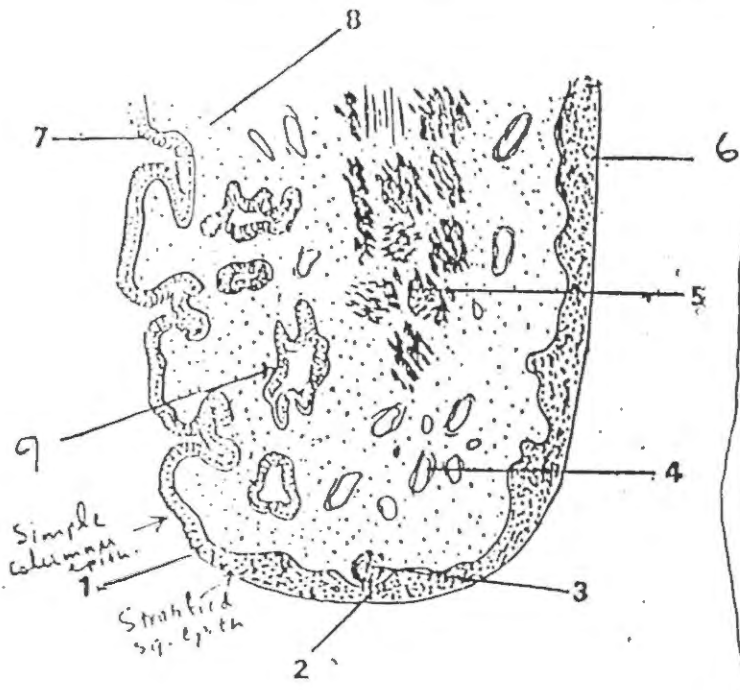


Fig. 90. Cervix.

- Ext.
1. Os or vaginal opening of the cervical canal
 2. Epithelium of Portio vaginalis
 3. Lymphatic nodule
 4. Venous plexus
 5. Muscularis (smooth muscle)
 6. Stratified squamous epithelium
 7. Mucus secreting columnar epithelium
 8. Lamina propria
 9. mucous glands

Cervix

① From inside

- * Mucosa or endocervix
- * forms complex branching folds
- * Epith. lining → tall columnar cells which secrete mucous
- Some tall ciliated columnar cells are present

② * Numerous large branched glands are present → lined by mucus secreting columnar cells

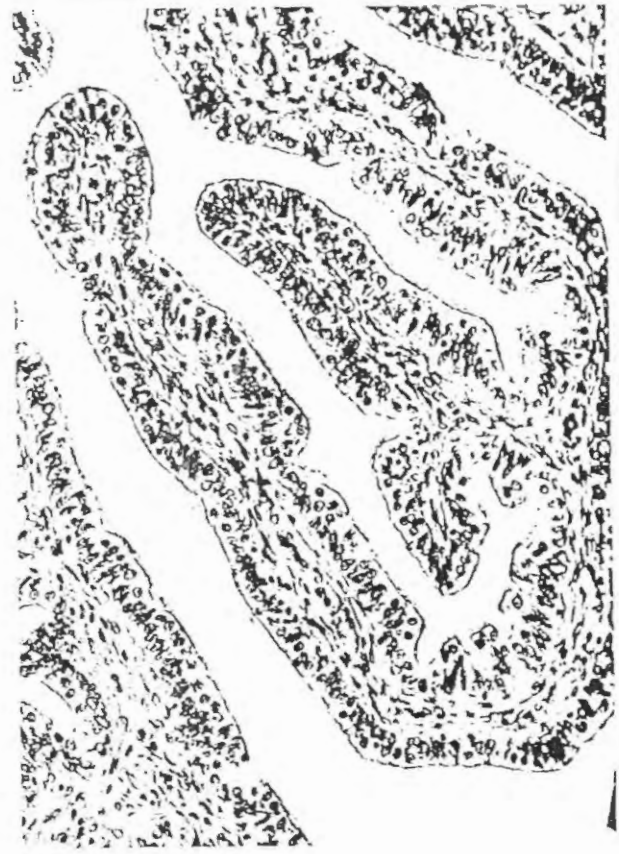
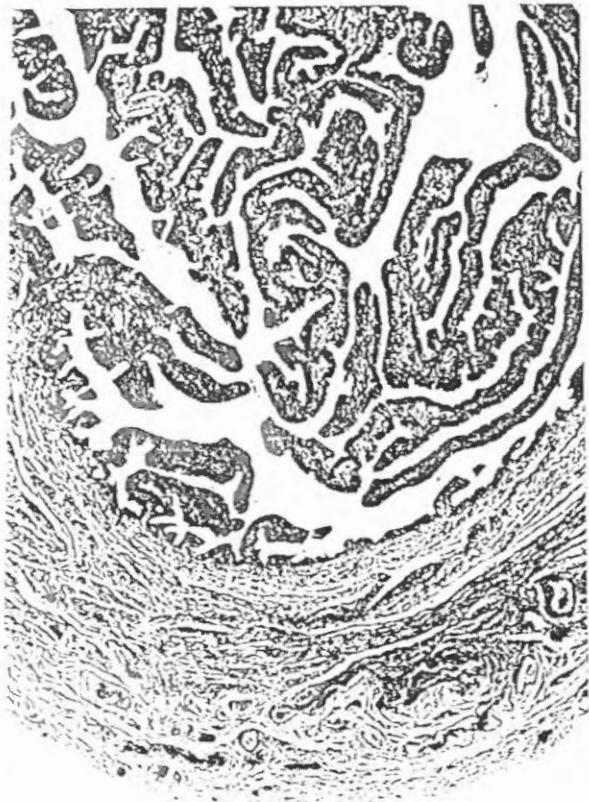
When occluded → filled with secretion → form Nabothian cysts

③ the wall → consists mainly of dense collagenous tissue & elastic fibres

little smooth muscle

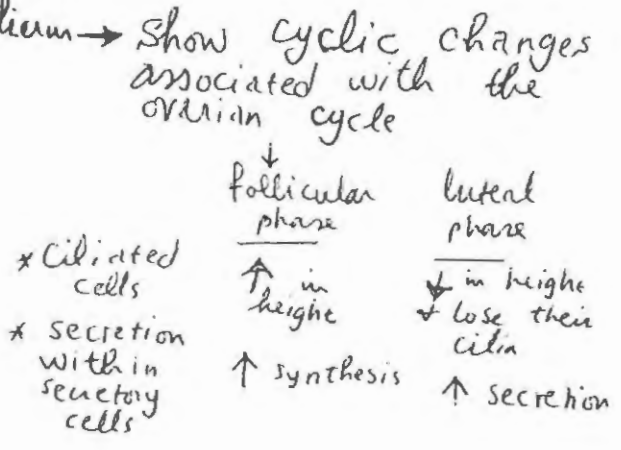
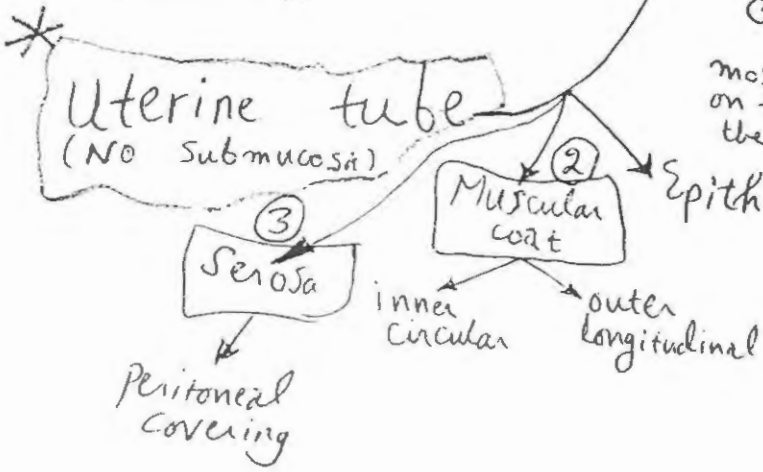
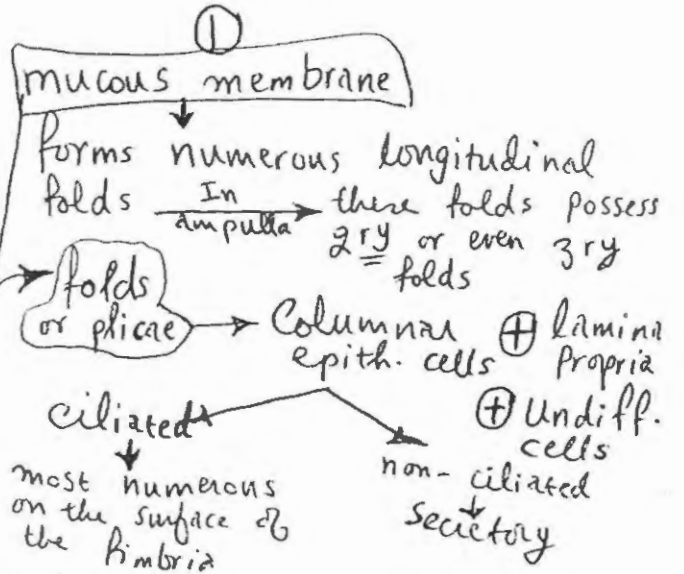
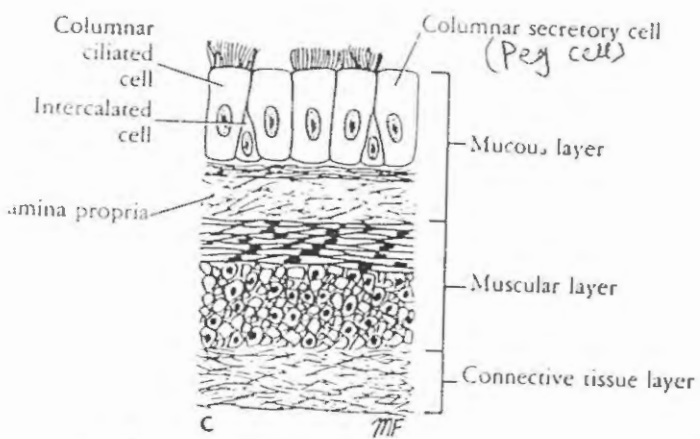
from outside → portio vaginalis is covered by non-keratinized strat. sq. epith.

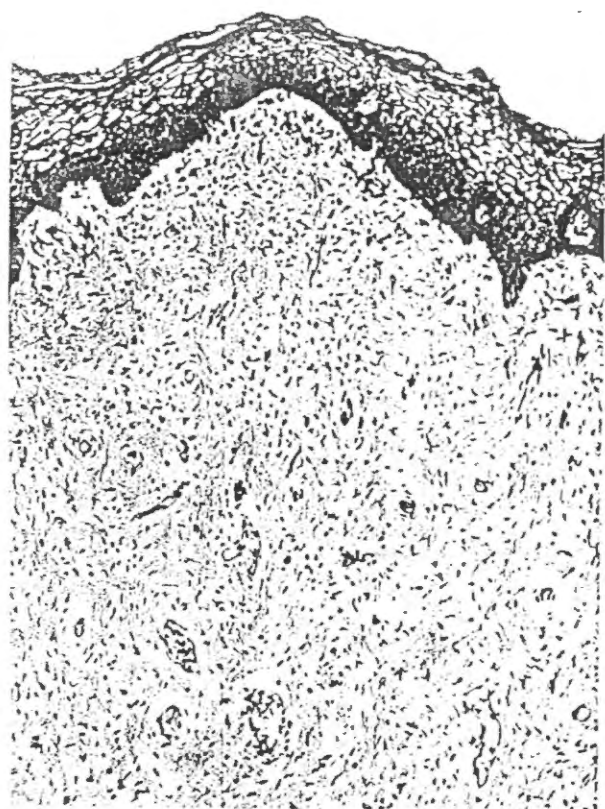
* The junction between the simple columnar and strat. sq. epith. is just within the external Os



Dr. Bustami
Histology & Refs
1999
(40)

Bustami





Submucosa → glands
NO
Vagina

Bustami

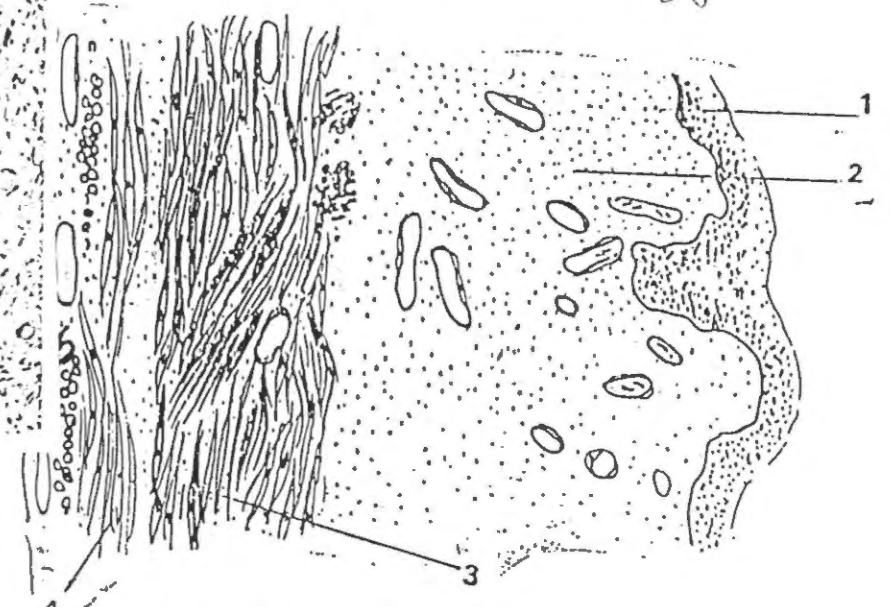


Fig. 91. Vagina (Longitudinal Section):
1. Stratified squamous epithelium
2. Lamina propria
3. Oblique bundles of smooth muscle fibres
4. Longitudinal bundles of smooth muscle fibres
5. Adventitia

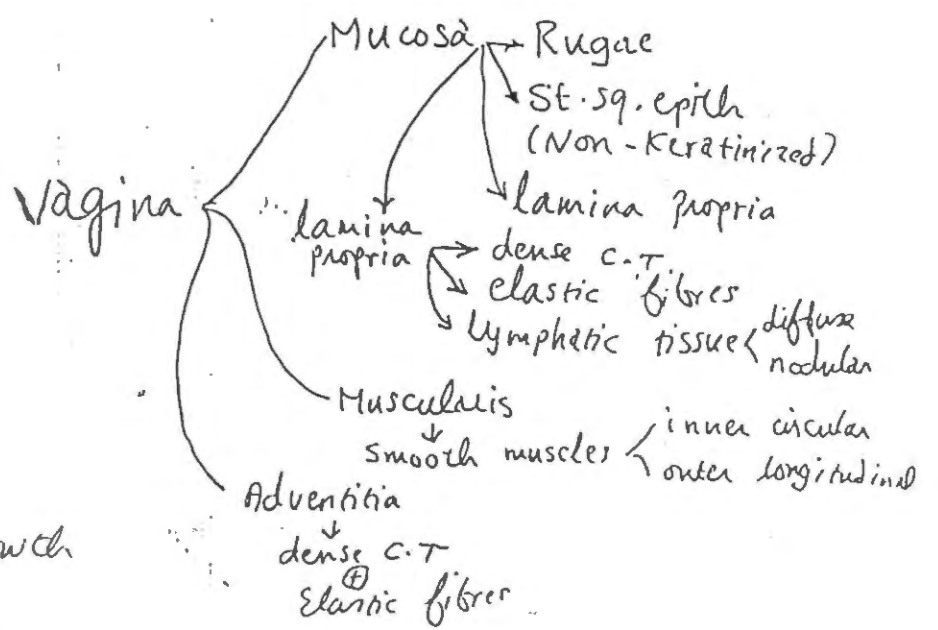
Between Puberty & menopause



The epith. is thick & the cells contain large amounts of glycogen in their cytoplasm → giving the cytoplasm a vacuolated appearance in H&E ----



As the surface cells are desquamated → the glycogen is liberated & fermented by Döderlein's bacilli which convert it into lactic acid → The low pH of the vaginal lumen → inhibits the growth of pathogenic bacteria

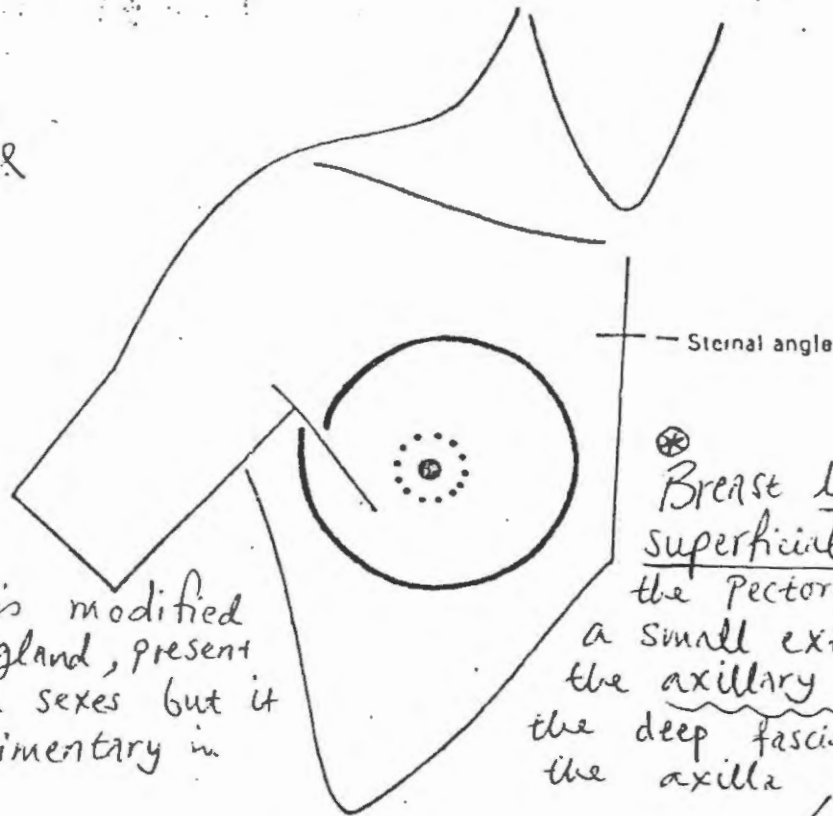


Mucous present in the vagina → has been secreted by the glands of the cervix

(Breast)

- (i) vertically it extends from the 2nd to 6th rib
- (ii) Horizontally at the level of the fourth costal cartilage, it extends from the lateral sternal border to the mid-axillary line.
- (iii) The superolateral part of the gland is prolonged upwards and laterally, pierces deep fascia at the anterior fold of axilla, and lies in the axilla at the level of the third rib. The process of the gland is known as 'axillary tail of Spence', and the opening in the deep fascia is known as 'foramen of Langer'.

2003
 الامتحان
 في طب
 جراحة
 الثدي



Breast is modified sweat gland, present in both sexes but it is rudimentary in males

Fig. 3 Extent of the breast.

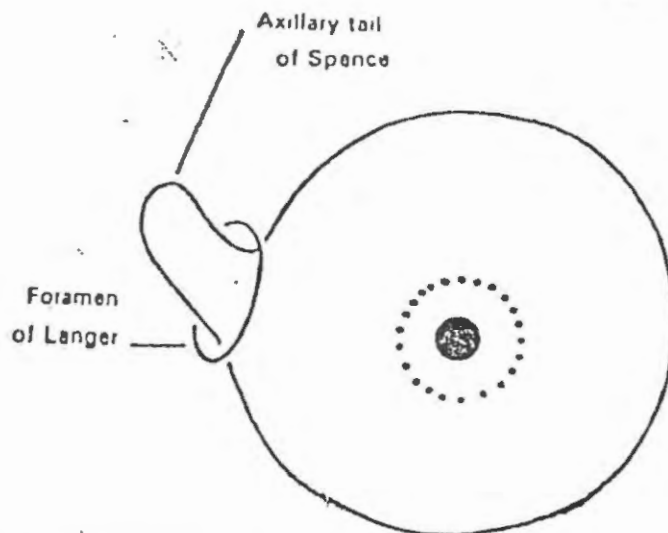


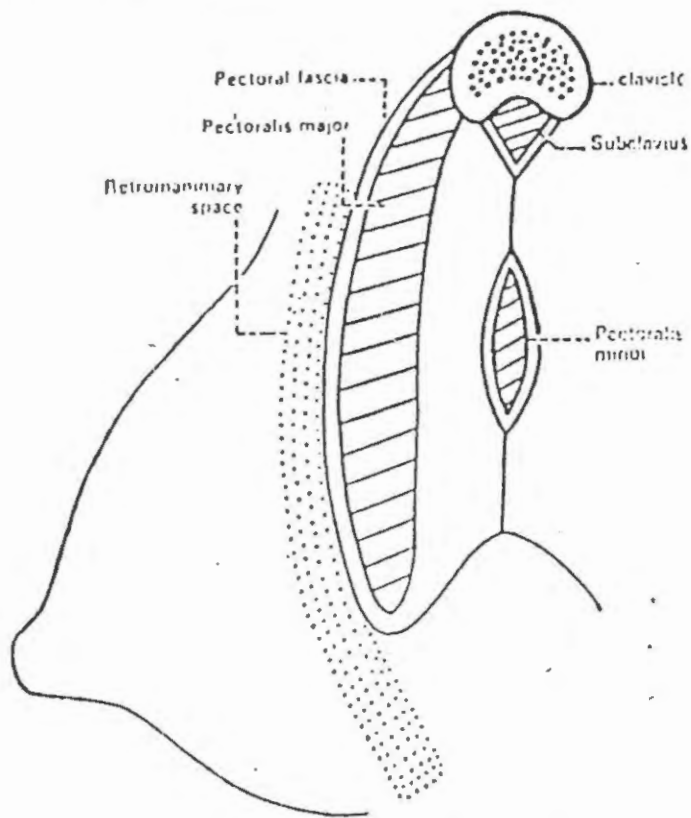
Fig. 4 Axillary tail of the breast lies deep to the deep fascia. The opening in the deep fascia is called 'foramen of Langer'.

Deep relations. The deep surface of the breast is related to the following structures in that order (Figs. 5,6)

43

of Sustami

1. The retromammary space of loose areolar tissue makes the breast freely movable over the pectoralis major muscle. According to the former concept of the free flow of lymphatics in this space, it was known as lake of Marcille.



(142) (143)

Dr. Sustami

(44) A

Fig. 5 Deep relations of the breast.

2. Deep fascia (pectoral fascia) covering the pectoralis major.
3. Still deeper there are pectoralis major, serratus anterior and external oblique muscle of the abdomen.

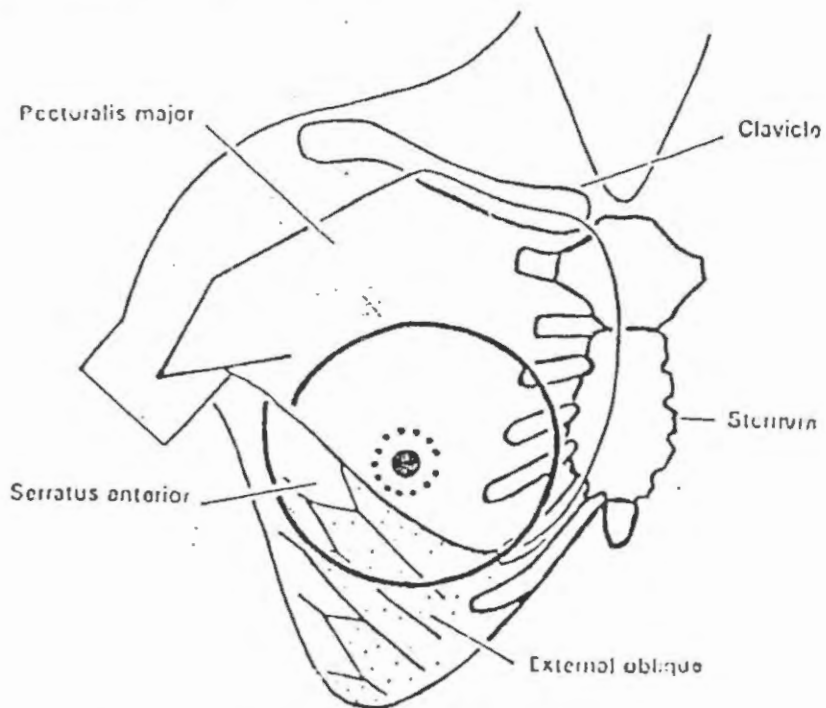


Fig. 6 Muscles situated deep to the breast.

(44/B) (N/A) (A) (X)

Structure of the breast. The structure of the breast may be conveniently studied by dividing it into the skin, parenchyma, and the stroma.

→ **A. Skin.** It covers the gland and forms :

1. **Nipple**, a conical projection from just below the centre of the breast at the level of the fourth space. It is pierced by 15-20 lactiferous ducts. It contains circular and longitudinal smooth muscle fibres which can erect or flatten it respectively. It has ~~few modified sweat and~~ sebaceous glands. It is rich in its nerve supply and has many end organs.
2. **Areola**, a pigmented area of skin surrounding the base of the nipple. It is rich in modified sebaceous glands, particularly at its outer margin. These become enlarged during pregnancy and lactation to form raised tubercles, the 'tubercles of Montgomery'. Oily secretion of these glands lubricates nipple and areola, and prevents them from cracking during lactation. Apart from sebaceous glands, it also contains some sweat and accessory mammary glands. Fat is absent beneath the nipple and areola, both of which are devoid of hair.

→ **B. Parenchyma (mammary gland).** It is made up of glandular tissue which secretes milk. The gland consists of 15-20 lobes, Each lobe is a cluster of alveoli, and is drained by a lactiferous duct. Each duct is dilated into a lactiferous sinus beneath the areola. The lactiferous ducts converge at the nipple like the spokes of a wheel; the incisions are therefore given radially.

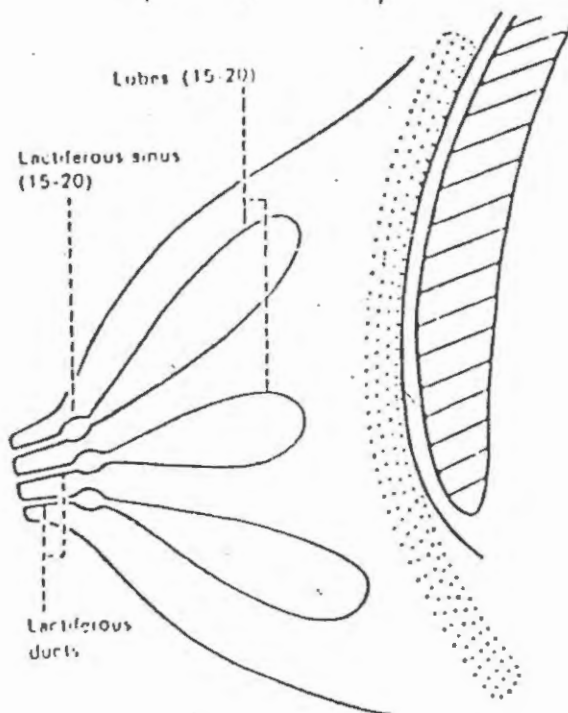


Fig. 7 Lobes of the mammary gland.

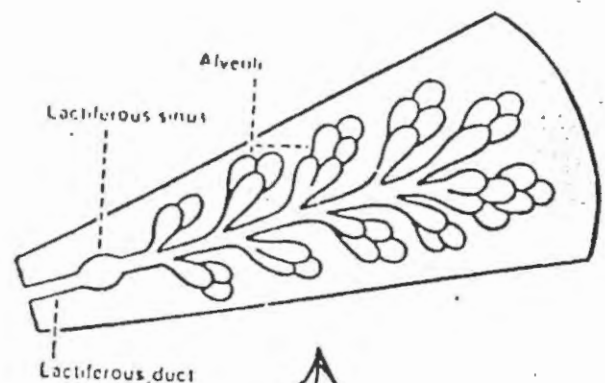


Fig. 8 Structure of one lobe of the mammary gland.

→ **C. Stroma.** It forms the supporting framework of the gland.

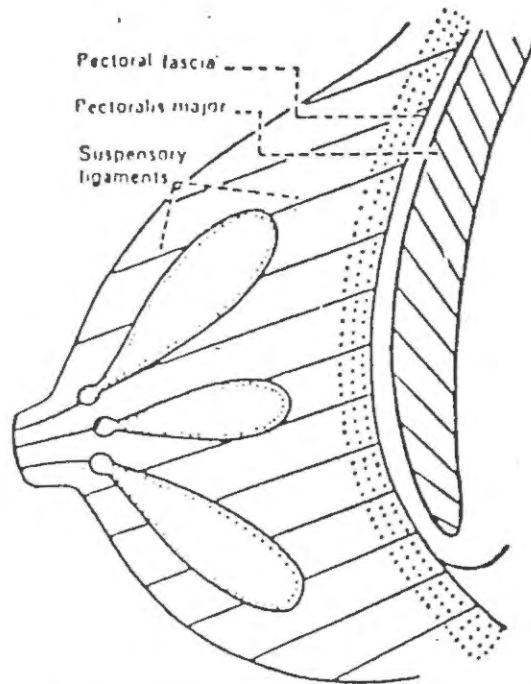
It may be divided into :

1. **Fibrous stroma.** It forms septa, known as suspensory ligaments of Cooper, which anchor the skin and gland to the pectoral fascia.

↔ PLD ↔

Infiltration of these ligaments by the cancer cells causes fixity of the gland and puckering of the skin.

2. *Fatty stroma*. It forms main bulk of the gland. It is distributed all over, except beneath the nipple and areola.



Handwritten notes: *Dr. Sustans*, *44*, and a circled 'C'.

Fig. 9 Suspensory ligaments of the breast.

Arterial supply. The mammary gland is extremely vascular. It is supplied by :

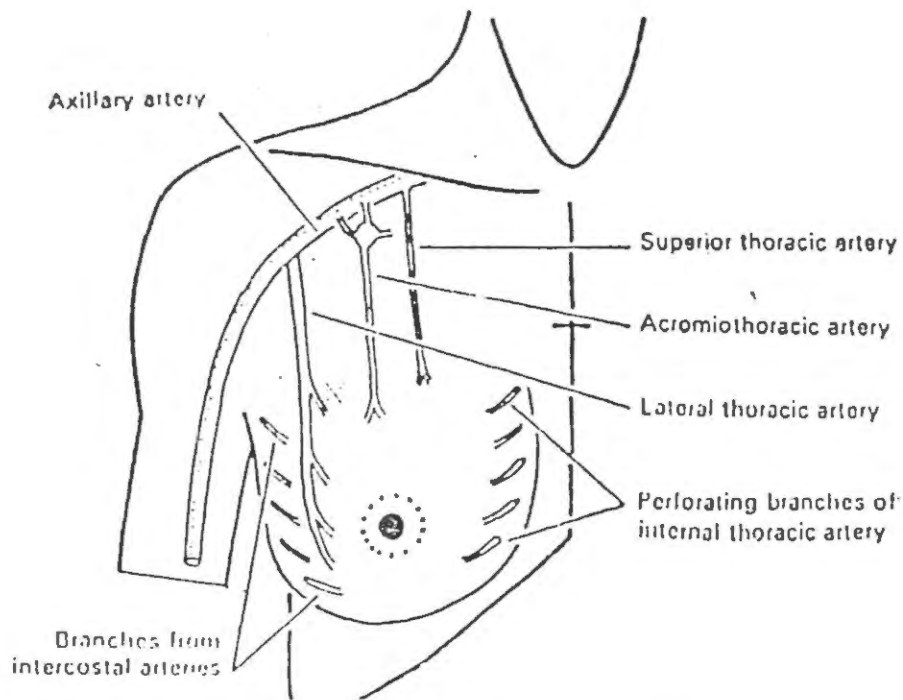


Fig. 10 Arterial supply of the breast.

1. Internal thoracic artery (a branch of subclavian artery), through its perforating branches (2-6 spaces).
 2. Lateral thoracic
 3. Superior thoracic
 4. Acromio-thoracic
- } branches of the axillary artery.

5. Lateral branches of the posterior intercostal arteries.

The arteries converge on the breast and are distributed from the anterior surface. Posterior surface is relatively avascular.

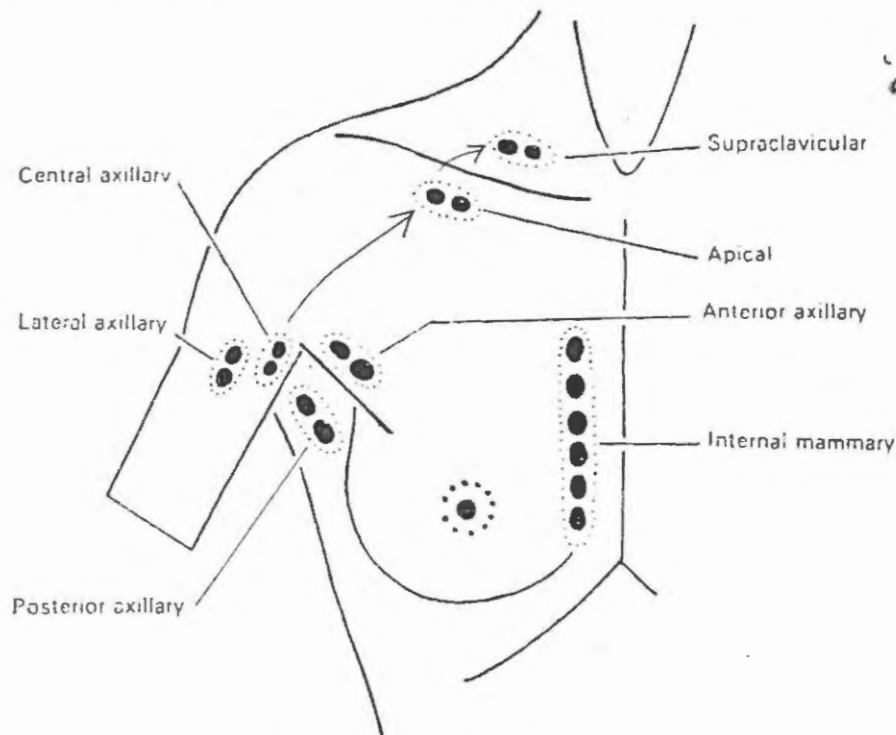
Venous drainage. Veins follow the arteries. These are important for following reasons : (i) because they indicate lymphatic pathways, (ii) because carcinoma can spread through the veins, and (iii) because they communicate with the vertebral plexus of veins through which malignancy can spread to bones and nervous system.

The veins first converge toward the base of the nipple where they form an anastomotic venous circle, from where the veins run in superficial and deep sets.

1. Superficial veins drain in the internal thoracic and superficial veins of the lower neck.
2. Deep veins drain into the internal thoracic, axillary and posterior intercostal veins. The connection of the posterior intercostal veins with the vertebral plexus of veins provides route for the carcinomatous spread to the bones and nervous system.

Nerve supply. The breast is supplied by the anterior and lateral cutaneous branches of the 4th to 6th intercostal nerves. The nerves convey sensory fibres to the skin, and autonomic fibres to the smooth muscles and blood vessels. Nerves do not control secretion of the milk. It is regulated by a hormone, prolactin, secreted by the anterior pituitary.

Lymphatic drainage of breast. The malignant disease of the breast spreads (metastasizes) mostly through the lymphatics to the associated lymph nodes. Therefore the subject assumes great importance to the surgeon.



UjDustami

Fig. 11 Lymph nodes draining the breast.

Lymph nodes draining the breast

A. Principal nodes

1. Axillary nodes, chiefly the anterior (pectoral) group. The posterior, lateral, central and apical groups of nodes are also associated, either directly or indirectly.

- (10/8)
44
E
4. The lymphatics from the deep surface of the breast pass through the pectoralis major and clavipectoral fascia to reach the apical nodes, and also to the internal mammary nodes. Lymphatic plexus on the deep fascia (lake of Marcille) is not a normal pathway for the lymphatics as was formerly thought to be (Fig. 13).
 5. Lymphatics from the lower and inner quadrant of the breast may communicate with the subdiaphragmatic and subperitoneal lymph plexuses, after crossing the costal margin and then piercing the anterior abdominal wall through the upper part of the linea alba. Thus cancer cells from breast may spread to the liver, and from the peritoneal cavity may drop into the pelvis.

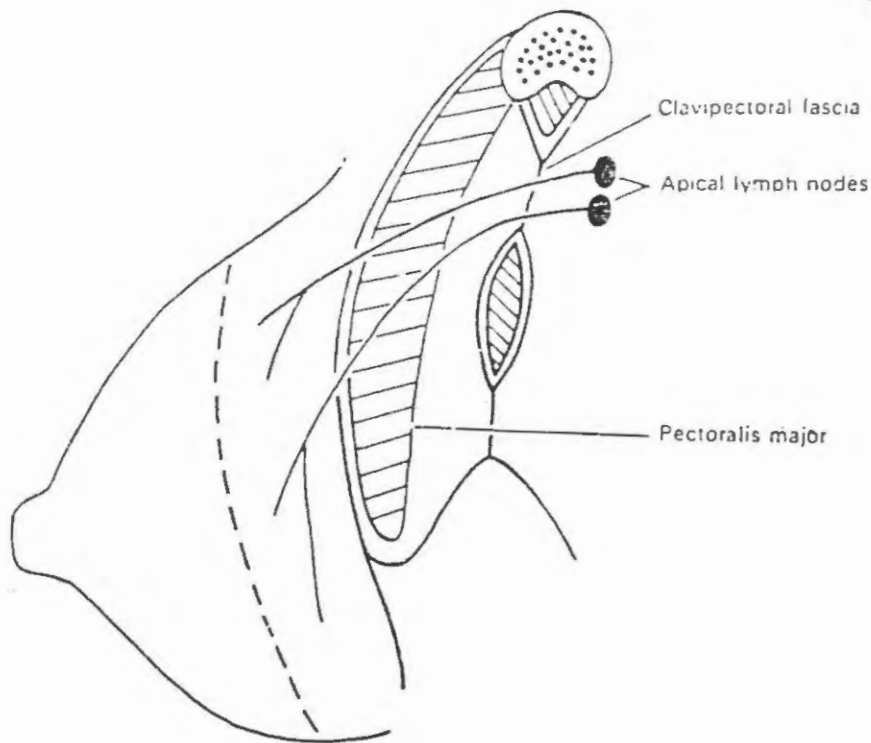


Fig. 13 Deep lymphatics of the breast drain into the apical lymph nodes.

Clinical application. Carcinoma of the breast may give rise to the following features, which may be of diagnostic and prognostic values.

1. Retraction or puckering of the skin due to invasion of the ligaments of Cooper.
2. Peau d'orange or oedema with pitting; oedema is due to obstruction of the cutaneous lymphatics by cancer cells, and pitting due to fixation of the hair follicles to the subcutaneous tissue.
3. Axillary lymph nodes may be involved; these are stony hard and fixed.
4. Retraction of the nipple is due to extension of the growth along the lactiferous ducts with accompanying fibrosis.
5. Breast may become fixed to the deep fascia, pectoral muscle and chest wall, due to direct spread of the growth to the subjacent structures.
6. Carcinoma may spread to distant places, like liver, lungs, bones, and ovary.

THE PECTORAL REGION

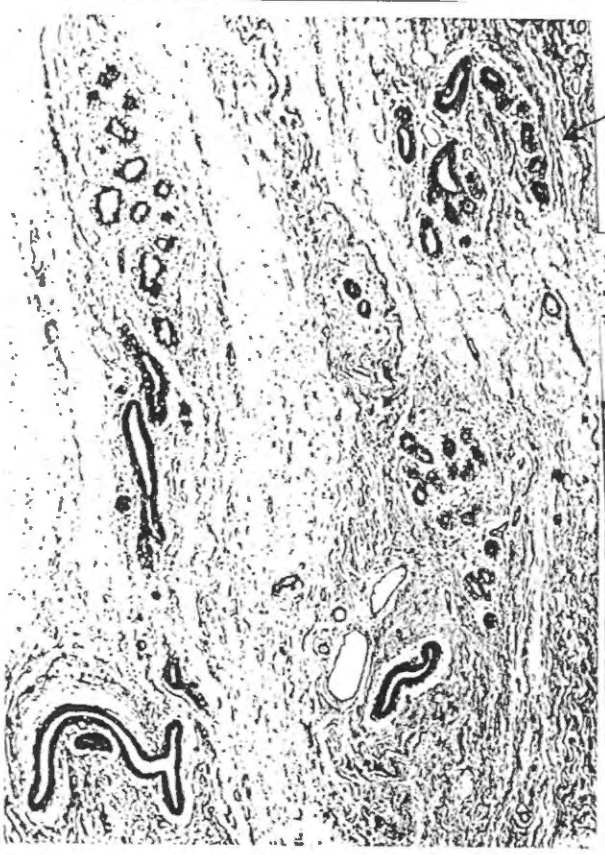76
44

Development of the breast

1. Breast develops from an ectodermal thickening, called mammary ridge, milk line, or line of Schultz, which extends from the axilla to the inguinal region. The ridge appears during the 4th week of development, but disappears in humans except in the pectoral region. Gland is ectodermal and the stroma mesodermal in origin.
2. Stages of development
 - (i) The remaining ridge is converted into a mammary pit.
 - (ii) Secondary buds (15-20) grow down from the floor of the pit. These buds divide and redivide to form lobes.
 - (iii) Entire system is canalized.
 - (iv) At birth or later nipple is everted.
3. Growth at puberty is caused by the oestrogens; secretory alveoli develop under the influence of oestrogens and progesterone, and anterior pituitary hormone. Lactation is controlled by prolactin secreted by the anterior pituitary.
4. Developmental anomalies of the breast
 - (i) Absence of breast = amastia
 - (ii) Absence of nipple = athelia
 - (iii) Supernumerary breasts = Polymastia
 - (iv) Supernumerary nipples = Polythelia
 - (v) Gynaecomastia is developed breast in males, as in Klien-Felter syndrome.

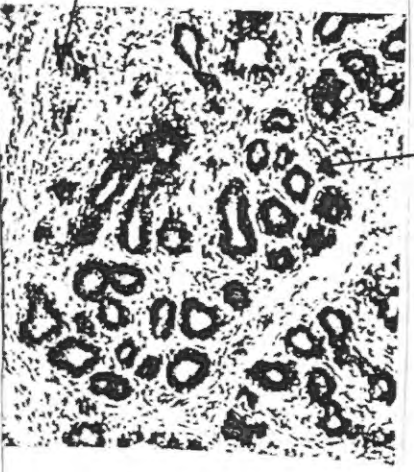Ujwarami





Fibrous interlobular
C-T

44 علی



cellular loose
intralobular
C-T

Bustami

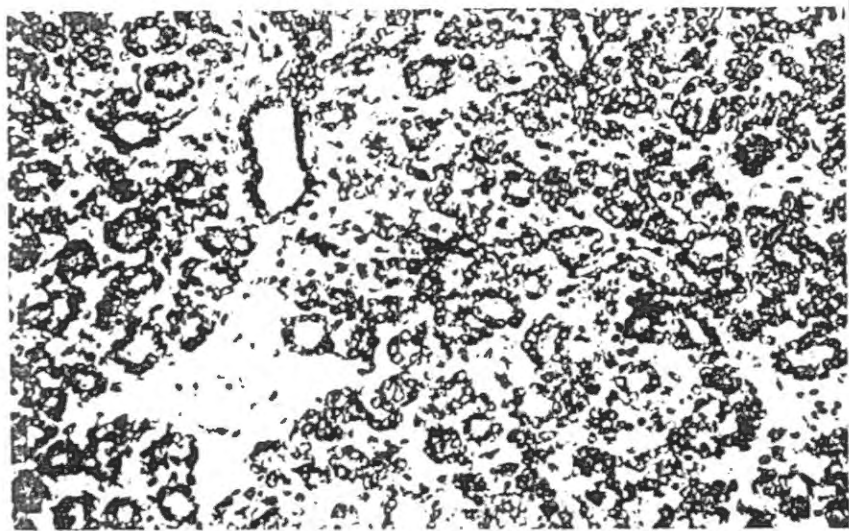
RESTING BREAST

is a Postpubertal female breast that has not yet been hormonally stimulated to secrete & therefore still in the inactive (non-lactating) state

The internal epithelial tissue (i.e. Parenchyma) consists of **DUCTS** which are grouped together to form **LOBULES**

- The intralobular connective tissue between ducts is loose, cellular & devoid of fat (derived from downgrowth of papillary layer of dermis)
- the interlobular C-T around the lobules is abundant dense & rich in fat cells (derived from reticular layer of dermis)
- lined with Cuboidal to low columnar epith. cells

in wider ducts → arranged as 2 double layer
" narrower " → " = " single layer



→ How to differentiate from thyroid?

- presence of ducts & branching alveoli
- lack of colloid material

Dr. Bostani
Hist. & Repr. S.
1994

(45)



Bostani

The Active Proliferative breast → associated with pregnancy
 characterized by ↓

ABUNDANT ALVEOLI lined by simple cuboidal epith.

⊕ myoepith. cells around

These alveoli arise by budding off from the ends of its intralobular ducts

The intra- & interlobular C.T. becomes markedly reduced

Note: In 3rd trimester of pregnancy } alveoli begin to secrete a protein-containing serous fluid that also has a low fat content → this fluid is called → Colostrum

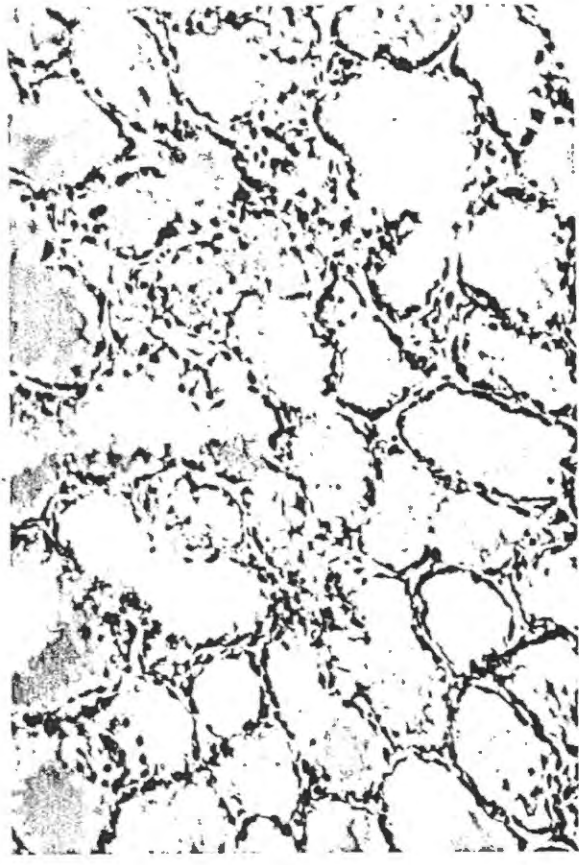
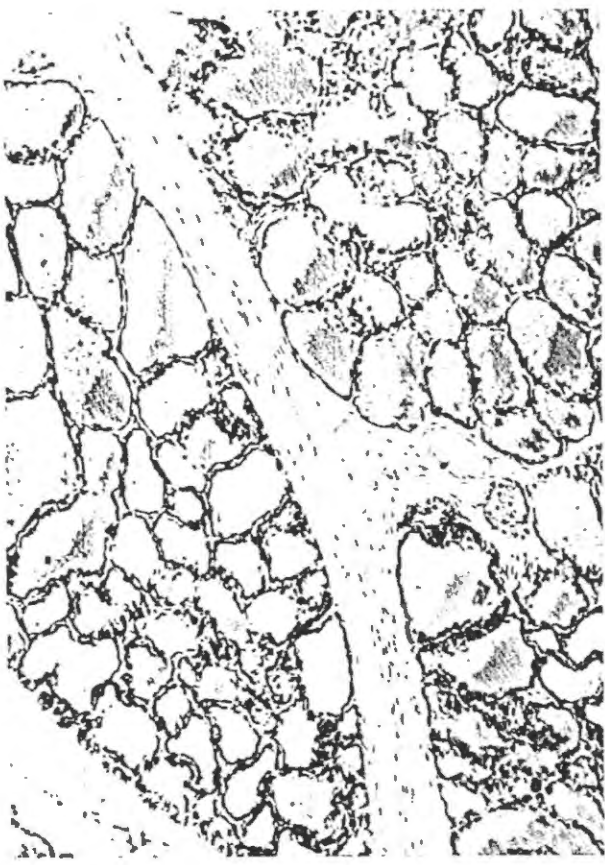
Milk is NOT produced until a few days after delivery

* A characteristic microscopic feature of breast tissue that has reached this stage → that its secretory alveoli & ducts become more distended in some lobules than in others due to UNEVEN RATES of secretion.

Dr. Bustami
Hist. & Repr.
1999

46

Bustami



Active LACTATING breast

Alveoli become saccular & distended with milk

↓ But ??

Not all of the breast tissue is functioning at the same time → In some areas the alveoli are distended with milk → the epith. lining is flattened & the lumen is distended; in other areas the alveoli are resting & have narrow lumina lined by tall epith. cells.

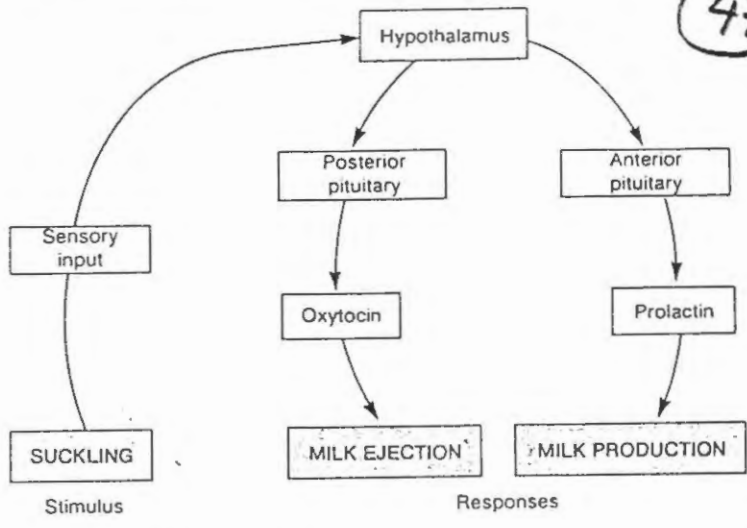
The interlobular c.t. ↓ is reduced to thin septa between lobules

Sudhakar

Table 28.4 Hormonal factors affecting lactation		
Hormones	Major source	Effects
Insulin, cortisol, thyroid hormones	Pancreas, adrenal cortex, and thyroid	Permissive effects—adequate amounts of these must be present for other hormones to exert their effects on mammary glands
Estrogen and progesterone	Placenta	Growth and development of secretory units (alveoli) and ducts in mammary glands
Prolactin	Anterior pituitary	Production of milk proteins, including casein and lactalbumin
Oxytocin	Posterior pituitary	Stimulates milk-ejection reflex

Figure 28.21. Lactation occurs in two stages: milk production (stimulated by prolactin) and milk ejection (stimulated by oxytocin). The stimulus of suckling triggers a neuroendocrine reflex that results in increased secretion of oxytocin and prolactin.

47



HORMONES OF PREGNANCY

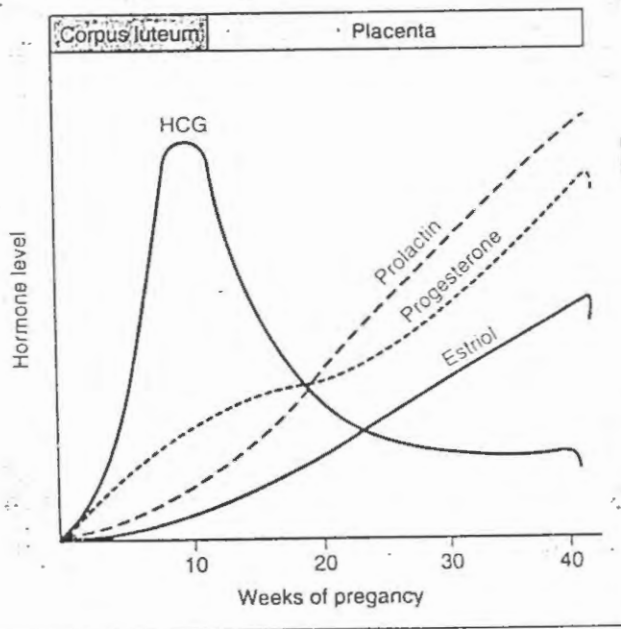


FIGURE 10-11. Hormones of pregnancy. Number of weeks of pregnancy are counted from the onset of the last menses. HCG, human chorionic gonadotropin.

Throughout pregnancy → oestrogens & progesterone stimulate growth & development of the breasts preparing them for lactation.
 Oestrogen also stimulates PROLACTIN SECRETION by the ant. Pituitary & prolactin levels steadily ↑ over the course of pregnancy (look at fig. 10-11)

* Although prolactin levels are very high during pregnancy lactation DOES NOT OCCUR because oestrogen & progesterone BLOCK the action of prolactin on the breast.

After parturition → oestrogen & progesterone levels fall (the placenta was removed) → their inhibitory effects on the breast are removed and lactation can proceed

* LACTATION → maintained by suckling which stimulates the secretion of both oxytocin & prolactin.
 * As long as lactation continues (ovulation is mostly suppressed)

because of the inhibitory effects of prolactin on GnRH secretion by the hypothalamus & on FSH & LH secretion by the anterior pituitary.

Menstrual cycle

(48)

Primordial follicle → Ovum surrounded by a single layer of granulosa cells

Throughout childhood → granulosa cells secrete an Oocyte-maturation-inhibiting factor that keeps the ovum suspended in the prophase of 1st meiotic division.

② During the follicular phase ----- the stimulatory effect of FSH on the follicles increases despite the fact that FSH levels in the blood do not increase throughout the follicular phase??

A. Oestrogen secreted into the follicle → causes the granulosa cells to form increasing numbers of FSH receptors → this makes the granulosa cells more sensitive to FSH

B. Pituitary (FSH +) oestrogens → together promote LH receptors on the granulosa cells → LH stimulation + FSH stimulation -----

C. increasing oestrogens from the follicles + increasing LH from the pituitary } act together to cause proliferation of follicular thecal cells and increase their secretion

③ Ovulation → The process of releasing the secondary oocyte from the graafian follicle

a. Under the influence of FSH the graafian follicle becomes large but with thin wall → a part of the wall becomes ischemic → degenerate rupture ----- releasing the ovum, assisted by proteolytic enzymes from theca externa

b. the follicle sets the time for its own ovulation??
Ovulation is triggered by an LH surge & LH surge is triggered by increased oestradiol secretion that occurs while the follicle grows → In this way, the graafian follicle is not normally ovulated until it has reached the proper size

1. Development of Primary follicles is independent ⁴⁹
of FSH

↓
Signaling molecules activin produced by oocyte
causes proliferation of the granulosa cells of
the primordial & early (unilaminar) primary
follicles to develop

2. Continued proliferation of the granulosa cells of
the secondary follicle depends on FSH (released
by basophil cells of the anterior pituitary)



GnRH (LHRH)

↓
Binds to receptors on basophils of
pars distalis (pituitary)

Synthesis ↓ Release

FSH & LH

↓
Binds to specific receptors
on the granulosa cells of
multilaminar primary follicles
stimulates their development
into secondary follicles

→ stimulates the production of
receptors on the theca interna
cells for LH → binds to these receptors &
thus inducing theca interna cells to produce androgens
from cholesterol → Androgens enter granulosa cells
& under the effect of aromatase enzyme are
converted into oestrogens

→ granulosa cells of the secondary follicles → also produce
several other hormones (inhibin, follistatin, activin)
which help to regulate release of FSH

4. Luteal phase

(50)

After ovulation the empty follicle is stimulated by LH to become the corpus luteum → This change in structure is accompanied by a change in function.

Developing follicle secretes only estradiol
→ corpus luteum secretes both estradiol & progesterone

{ high blood levels of estradiol & progesterone } → Negative feedback on FSH & LH

{ corpus luteum also produces inhibin during the luteal phase } → suppress FSH secretion or action

↓
Retard development of new follicles → further ovulation does not normally occur during that cycle

{ However new follicles start to develop toward the end of one cycle ?? may be due to decreased production of inhibin toward the end of luteal phase

Regression of corpus luteum ? luteolysis in lower animals

could be prevented by high levels of LH

→ Prostaglandins in human

its level remains low during the luteal phase

LH Surge

- ① When does it occur? just before the midpoint of the menstrual cycle (the 14th day before onset of menstruation)
- ② Triggered by? high estrogen level in the blood stimulates gonadotrophs of pituitary g.

- ③ Effects ?
 - ① Sudden high blood LH level stimulates the primary oocyte (by activating meiosis-inducing substance) to COMPLETE MEIOSIS I forming a secondary oocyte ⊕ first polar body
 - Enters Meiosis II and arrested in metaphase until fertilization triggers its completion
 - ② triggers ovulation where a secondary oocyte is expelled from the mature follicle

The granulosa cells & theca interna cells of the remaining ovulated follicle - Both of which have LH receptors are activated by LH to form corpus luteum

* granulosa cells $\xrightarrow{\text{converted to}}$ granulosa-lutein cells
 * theca interna cells $\xrightarrow{\text{"}}$ theca-lutein cells
 } Both actively produce progesterone (mostly by granulosa L. cells)

* In addition $\left\{ \begin{array}{l} \text{inhibin} \\ \text{follicle-statin} \\ \text{activin} \end{array} \right\}$ feedback regulators of FSH
 continue to be produced by corpus luteum

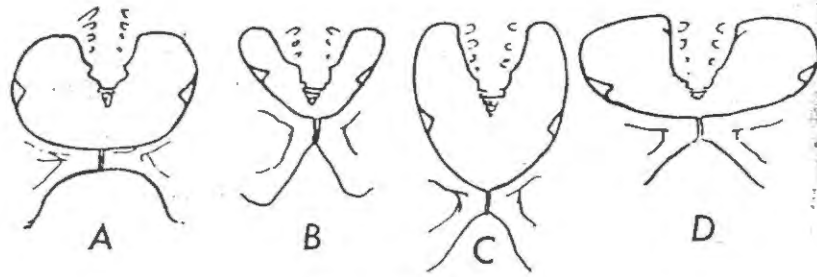


FIG. 16. TYPES OF PELVIS.

Diagram shows brim shape (exaggerated) and subpubic angle.
A, Gynaecoid; B, Android; C, Anthropoid; D, Platypelloid.

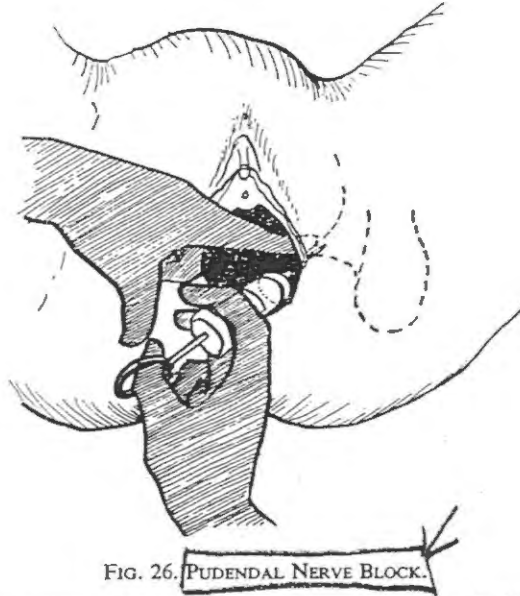


FIG. 26. PUDENDAL NERVE BLOCK.

Injection of local anaesthetic round Pudendal nerve in region of ischial spine. (Transvaginal approach).

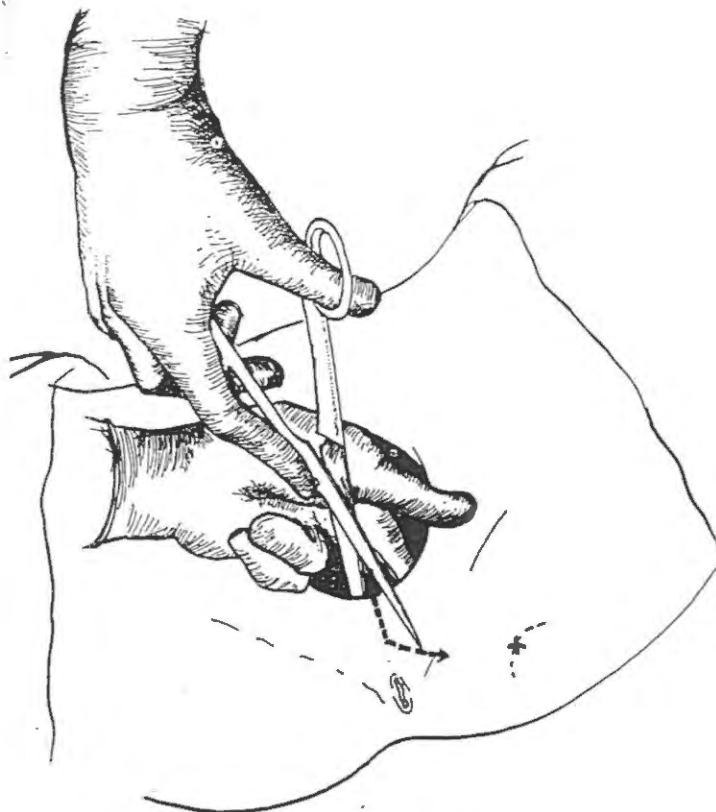


FIG. 18. EPISIOTOMY. CUT STARTING IN MIDLINE.